

*Advances in Brief***Persistence of Genetically Altered Fields in Head and Neck Cancer Patients: Biological and Clinical Implications<sup>1</sup>**

Maarten P. Tabor, Ruud H. Brakenhoff,  
Viola M. M. van Houten, J. Alain Kummer,  
Mireille H. J. Snel, Peter J. F. Snijders,  
Gordon B. Snow, C. René Leemans, and  
Boudewijn J. M. Braakhuis<sup>2</sup>

Departments of Otolaryngology/Head and Neck Surgery [M. P. T., R. H. B., V. M. M. v. H., M. H. J. S., G. B. S., C. R. L., B. J. M. B.] and Pathology [J. A. K., P. J. F. S.], Vrije Universiteit Medical Center, de Boelelaan 1117, 1081 HV Amsterdam, the Netherlands

**Abstract**

In 1953, Slaughter *et al.* [D. P. Slaughter *et al.*, *Cancer (Phila.)*, 6: 963–968, 1953] proposed the concept of field cancerization in patients with squamous cell carcinoma of the head and neck (HNSCC) and discussed its clinical significance for the development of second primary tumors and local recurrences. To define the process of field cancerization and its putative clinical implications, we analyzed genetic aberrations in HNSCC and the accompanying macroscopically normal mucosa. In 28 HNSCC patients, loss of heterozygosity was determined in tumor and five noncontiguous mucosal biopsies using eight microsatellite markers at 9p, 3p, and 17p. For patients who showed loss of heterozygosity in their mucosal biopsies, all margins of the surgical specimen were subsequently analyzed to determine the extension of the field. In these cases, additional markers at 8p, 13q, and 18q as well as *p53* mutations were included to determine subclonal differences between field and tumor. Genetically altered fields were detected in 36% (10 of 28) of the HNSCC patients. The field varied in size between patients and consisted of genetically different subclones. In 7 of 10 cases, the field extended into the surgical margins. One particular patient with a genetically altered field in a surgical margin developed a local recurrence after 28 months of follow-up. Microsatellite analysis showed that this recurrence had more molecular markers in common with the nonresected premalignant field than with the original tumor, suggesting that this persistent field has progressed further into a new malignancy. Our data show that genetically altered mucosa remains after treatment in a significant

proportion of HNSCC patients, which may explain in part the high frequency of local recurrences and second primary tumors. Adequate identification and risk assessment of these genetically altered fields may have profound implications for future patient management.

**Introduction**

HNSCC<sup>3</sup> comprises about 5% of all newly diagnosed cancer cases in the northern and western European countries and the United States (1). Despite advances in therapy, long-term survival of HNSCC patients has not improved significantly during the last 20 years (2). An important reason for this lack of progress is the relatively high recurrence rates observed in these patients. Local recurrences occur in about 10–30% of the cases with advanced tumors, even with histopathologically tumor-free surgical margins after resection (3). Another reason for this lack of progress is the development of SPTs in the upper aerodigestive tract (4). The reported incidence of these SPTs varies, but on average, they develop with a constant rate of 2–3% new cases per year.

Two theories have been postulated to explain the high frequency of SPTs: (a) micrometastatic spread of (pre)malignant cells gives rise to genetically related SPTs; or (b) multiple transforming events give rise to genetically unrelated SPTs. The theory of micrometastatic spread was proposed by Bedi *et al.* (5). Other authors also suggested that at least a proportion of SPTs in HNSCC patients have arisen from one clonal population (6, 7).

The second theory is based on the concept of field cancerization. This concept was already proposed in 1953 by Slaughter *et al.* (8), who hypothesized that oral carcinomas (including SPTs) originate by a process of field cancerization, in which an area of epithelium has been preconditioned by long-term exposure to carcinogens. The authors based their theory on multiple histopathological observations in a group of 783 patients with oral cancer. They presented as supporting evidence that: (a) the surgical margins contained areas of abnormal mucosa; (b) multiple independent lesions were observed within the same resection specimen; (c) the incidence of SPTs found in their patient population was high; (d) the pattern of distribution of the SPTs was typical because in half of these patients the two separate tumors occurred in the same anatomical area; and (e) the local recurrence rate in oral cancer is high, which may be due to abnormal mucosa that was not excised during treatment of the primary tumor.

This concept of field cancerization can be interpreted in various ways to explain the phenomenon of SPTs. In the classical view, which is most commonly referred to, large areas of

Received 11/16/00; revised 2/20/01; accepted 3/1/01.

The costs of publication of this article were defrayed in part by the payment of page charges. This article must therefore be hereby marked *advertisement* in accordance with 18 U.S.C. Section 1734 solely to indicate this fact.

<sup>1</sup> Supported by Dutch Cancer Society Grant VU 1998-1674.

<sup>2</sup> To whom requests for reprints should be addressed, at Tumor Biology Section, Department of Otolaryngology/Head and Neck Surgery, Vrije Universiteit Medical Center, P. O. Box 7057, 1007 MB Amsterdam, the Netherlands. Phone: 31-20-4440905; Fax: 31-20-4440983; E-mail: bjm.braakhuis@azvu.nl.

<sup>3</sup> The abbreviations used are: HNSCC, head and neck squamous cell carcinoma; LOH, loss of heterozygosity; SPT, second primary tumor.

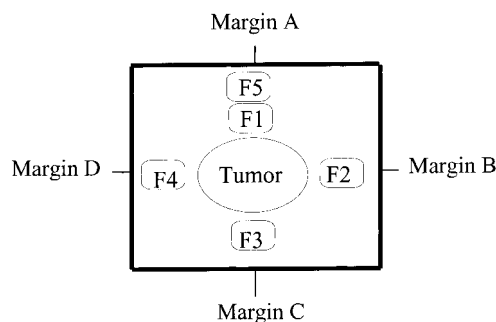
the aerodigestive tissue are affected by long-term exposure to carcinogens. In this preconditioned epithelium, multifocal carcinomas can develop as a result of independent mutations and thus would not be genetically related (9, 10). An alternative view of the field concept may also explain the phenomenon of SPTs. In this alternative model, a single cell is transformed and gives rise to one large extended premalignant field by clonal expansion and gradual replacement of normal mucosa. In this field of various subclones, two separate tumors can develop after accumulation of additional genetic alterations. Both tumors have the same clonal origin and would thus share at least one early genetic event, which occurred before the initial clonal expansion. Intriguingly, this model of “expanding fields” could also explain the high rate of seemingly local recurrences. A premalignant field that extends beyond surgical margins and thus is not excised after surgical treatment of the index tumor could progress further and give rise to a “new” tumor at the same site.

It is now generally accepted that most solid tumors result from a multistep process involving the clonal evolution of abnormal cell populations that gain a selective growth advantage over normal cells by accumulating specific alterations in two group of genes, the proto-oncogenes and the tumor suppressor genes (11, 12). HNSCC is thought to progress through a series of well-defined histopathological stages that run parallel to specific genetic changes. Using microsatellite analysis, several chromosomal areas have been identified that are likely to harbor tumor suppressor genes for HNSCC (13–16). Chromosomal loss at 9p, 3p, and 17p is supposed to be an early transforming event in HNSCC and is therefore an ideal marker to study the concept of field cancerization (11). Mutations in the *p53* gene as well as chromosomal loss at 13q, 18q, and 8p are supposed to be late transforming events and are therefore more suitable to study subclonal differences between field and tumor (11).

The aim of this study was to determine the frequency, extension, and persistence of the process of field cancerization in patients with HNSCC using extensive microsatellite analysis. Subclonal differences between tumor and field(s) were studied by microsatellite and *p53* mutation analysis. In addition, the clinical significance of genetically altered mucosa remaining after treatment was discussed with respect to the development of SPTs and/or local recurrences.

## Materials and Methods

**Patients and Biopsies.** The field cancerization study was approved by the Institutional Review Board Vrije Universiteit Medical Center, and written informed consent was obtained from all patients. In a pilot study, we enrolled 11 HNSCC patients to assess whether field cancerization could be detected at various sites by LOH. In total, two mucosal biopsies were analyzed from these patients, one < 0.5 cm (F1) and one > 0.5 cm (F5) from the edge of the tumor (Fig. 1). Genetically altered fields could be detected, but they appeared to be limited in size and distribution, and we decided to increase the number of biopsies for analysis to reduce the sampling error. In total, 28 patients who underwent surgical treatment for HNSCC in 1999 were subsequently included. Selection criteria used to include



*Fig. 1* Schematic drawing of the surgical specimen. Biopsies of the tumor and macroscopically normal mucosa were taken from the surgical specimens; four biopsies (F1–F4; one per quadrant) were <0.5 cm from the edge of the tumor, and one biopsy (F5) was >0.5 cm from the edge of the tumor. The specimen was marked to enable reorientation after analysis of the biopsies. In patients who showed molecular evidence of field cancerization, the paraffin-embedded surgical margins (A–C or A–G, depending on the size of the specimen) were also analyzed to study the extension of the fields.

patients were tumor site (oral cavity and oropharynx) and histopathologically tumor-free margins. Selection on site was performed to enable sampling of exfoliated cells during clinical follow-up. Tumor stages (pTNM) were determined according to the criteria of the International Union Against Cancer (UICC) (17): T<sub>1</sub>N<sub>0</sub> (seven patients), T<sub>2</sub>N<sub>0</sub> (eight patients), T<sub>2</sub>N<sub>1</sub> (three patients), T<sub>2</sub>N<sub>2b</sub> (six patients), T<sub>3</sub>N<sub>0</sub> (one patient), T<sub>3</sub>N<sub>1</sub> (one patient), and T<sub>3</sub>N<sub>2b</sub> (two patients). The distribution of the tumors by anatomical site was as follows: 20 tumors were located in the oral cavity (12 in the tongue, 6 in the floor of mouth, and 2 in the retromolar trigone); and 8 were located in the oropharynx (1 in the soft palate, 3 in the tonsil, 1 in the base of the tongue, and 3 in the anterior tonsillar pillar). Fourteen patients were treated postoperatively with radiotherapy. The age of the patients ranged from 38–77 years, with an average age of 57 years. In total, 13 patients were male, and 15 were female. Twenty patients were smokers, and 8 were never-smokers.

Immediately after surgery, the surgical specimen was taken to the pathology department. In addition to the standard sampling, the specimens were analyzed according to another protocol: biopsies of the tumor and of macroscopically normal mucosa were taken from the surgical specimen, four of which (F1–F4; one per quadrant) were <0.5 cm from the edge of the tumor, and one of which (F5) was >0.5 cm from the edge of the tumor (Fig. 1). The distant mucosal biopsy (>0.5 cm from the edge of the tumor) was taken only when the size of the surgical specimen was large enough (in 20 of 28 cases). All samples were directly snap-frozen in liquid nitrogen and stored at –80°C until further processing. For patients who showed genetic evidence of field cancerization, the routinely paraffin-embedded surgical margins (used for histopathological assessment of complete tumor excision) were also analyzed to study the extension of the field. Moreover, persistence of field cancerization was examined in exfoliated cells taken from the scar during clinical follow-up. Cells were collected using a cytobrush (Cytobrush Plus; Medscand AB, Malmö, Sweden). The brushes were stirred in 4 ml of PBS, allowing the cells to be released.

The cells were washed once with PBS, and DNA was isolated from the pellets according to the protocol described for tissues (see below).

**Microdissection and DNA Extraction.** Freshly frozen tumor and mucosa samples were cut on a cryomicrotome, and tissue sections (10  $\mu\text{m}$ ) were mounted on microscopical glass slides. From the paraffin-embedded surgical margins, 10- $\mu\text{m}$  sections were obtained, placed on microscopic glass slides, and subsequently deparaffinized in xylene. In all cases, the first and last tissue sections were stained with H&E for histological assessment and to guide microdissection. After consultation of a pathologist (J. A. K.), the other tissue sections were stained with 1% toluidine blue and 0.2% methylene blue and microdissected under a stereomicroscope. In the mucosal biopsies, histopathologically normal mucosal epithelium was dissected separately from histopathologically abnormal mucosal epithelium. All microdissected samples contained >80% of cells of interest (normal epithelium, dysplasia, or tumor). Dissected tissues were treated with 1 mg/ml proteinase K for 24 h at 52°C in a 100- $\mu\text{l}$  buffer containing 100 mM Tris (pH 9.0), 10 mM NaCl, 1% SDS, and 5 mM EDTA. The DNA was purified by phenol chloroform extraction and collected by ethanol precipitation using 2  $\mu\text{g}$  of glycogen as a carrier. The DNA was redissolved in LoTE buffer [3 mM Tris and 0.2 mM EDTA (pH 7.5)]. Normal DNA was isolated from blood samples obtained at the time of surgery. The DNA concentration was measured by microfluorometry with the Hoefer Dynaquant (Amersham/Pharmacia Benelux NV, Roosendaal, the Netherlands).

**Histopathological Classification.** All H&E-stained slides were examined by a pathologist (J. A. K.) and scored according to the standard criteria of the WHO international histological classification of tumors (18). Lesions were classified as: (a) normal mucosa; (b) mild dysplasia; (c) moderate dysplasia; (d) severe dysplasia or carcinoma *in situ*; and (e) squamous cell carcinoma. A representative selection of cases was independently screened by a second pathologist (Dr. P. J. van Diest). In the few cases for which there was a discrepancy in classification, a final consensus judgement was made. Neither pathologist had information on clinical and molecular data before screening.


**Selection of Chromosomal Loci for Microsatellite Analysis.** To detect the molecular presence of field cancerization, we examined the status of chromosomes 9p, 3p, and 17p using eight polymorphic microsatellite markers. The specific markers used in this study were selected because they identify a minimal area of loss at putative tumor suppressor gene loci and because they are lost frequently and early during HNSCC tumorigenesis (11). The tumor and concordant microdissected mucosal biopsies were analyzed using the following eight microsatellite markers at 3p12 (D3S1284), 3p14 (D3S1766), 3p21 (D3S1029), 3p24 (D3S1293), 9p21 (D9S171), 9p22 (D9S157), 17p11–12 (CHRN1), and 17p13 (TP53). From patients who showed LOH in one or more mucosal biopsies, microsatellite markers at other chromosomal loci were also examined to study the differences between tumor and genetically altered field in the mucosa. These markers are proposed to detect late events in the HNSCC carcinogenesis, based on the frequencies with which these alterations are found at different premalignant stages (11, 19). The additional microsatellite markers used were located at the following chromosomal regions: (a) 8p22 (D8S261); (b) 8p23

(D8S1130); (c) 13q14 (D13S294); (d) 13q31 (D13S170); (e) 18q12 (D18S34 and D18S57); and (f) 18q21 (D18S35). Moreover, in these patients, the routinely paraffin-embedded surgical margins were also analyzed (with both marker sets) to study the extension of the field. Primer sequences were obtained from the Genome Database<sup>4</sup> for all of these markers.

**Microsatellite Analysis.** The analysis of microsatellite markers was performed with two different methods. The first experiments were performed by PCR amplification with radioactively labeled primers (Isogen Bioscience, Maarsse, the Netherlands), followed by electrophoretic gel separation. Before amplification, one primer (5 pmol) was end-labeled with [ $\gamma$ -<sup>32</sup>P]ATP (0.74 MBq; Amersham, Hertogenbosch, the Netherlands) and T4 polynucleotide kinase (Roche, Almere, the Netherlands) in a total volume of 10  $\mu\text{l}$ . The PCR reactions were carried out in a final reaction volume of 10  $\mu\text{l}$  containing 10 ng of genomic DNA, 0.5 pmol of labeled primer, and, respectively, 1.5 or 2.0 pmol of each unlabeled primer. The PCR buffer included 10 mM Tris-HCl (pH 8.3), 50 mM KCl, 1.5 mM MgCl<sub>2</sub>, 0.2 mM deoxynucleotide triphosphate, and 0.5 unit of Taq DNA polymerase (AmpliTaq; Perkin-Elmer, Gouda, the Netherlands). PCR amplification was performed for 35 cycles consisting of denaturation at 94°C for 1 min, annealing at 55°C to 65°C (depending on the primer set) for 1 min, and extension at 72°C for 2 min. One-third of the PCR product was separated electrophoretically on 6% urea-formamide-polyacrylamide gels and visualized by autoradiography. All PCR products were quantified by scanning densitometry and ImageQuant software (version 3.1; Molecular Dynamics). Allelic loss was defined when (S<sup>n</sup>/L<sup>n</sup>)/(S<sup>l</sup>/L<sup>l</sup>) was <0.5 or >2.0. S<sup>n</sup> and S<sup>l</sup> are the densitometric signals from the small allele of the normal and tumor DNA, respectively, and L<sup>n</sup> and L<sup>l</sup> are the densitometric signals from the large allele of the normal and tumor DNA, respectively. When the alleles differed in size by only 2 or 4 bp, a stutter band from the large allele often comigrated with the full-length product amplified from the smaller allele. In these cases, stutter correction was used. For a particular marker, the relative contribution to the stutter bands is calculated from a noninformative sample and used to calculate the relative abundance of the second allele to the first stutter band of the first allele (20).

Later experiments were carried out on an automated ABI PRISM sequencer (310 Genetic Analyzer; PE Applied Biosystems, Nieuwerkerk a/d IJssel, the Netherlands). One primer of each marker was end-labeled with one of the fluorescent dyes (FAM, HEX, or NED; PE Applied Biosystems). Microsatellites (10 ng) were amplified by multiplex PCR (involving two or three markers) in a total volume of 10  $\mu\text{l}$  containing 2 pmol of each labeled and unlabeled primer. Details of the multiplex PCR are available on request. PCR buffer and PCR conditions were the same as those described above. The amplified product was diluted in sterilized water, usually five times. For analysis, 12  $\mu\text{l}$  of deionized formamide were combined with 0.5  $\mu\text{l}$  of GeneScan-350 (ROX) size standard (PE Applied Biosystems) and 1  $\mu\text{l}$  of diluted PCR product in a Genetic Analyzer sample tube. The samples were loaded on an ABI PRISM 310 Genetic

<sup>4</sup> <http://gdbwww.gdb.org/>.



Analyzer and run following the supplier's protocol. The data were analyzed with GeneScan Analysis software (version 1.2; PE Applied Biosystems). LOH was scored using the formula described above when necessary after stutter correction.

**p53 Sequencing and Plaque Assay.** For patients whose mucosal biopsies showed genetic evidence of field cancerization, tumor DNA was analyzed for *p53* mutations. When a mutation was detected, DNA of the genetically altered fields were subsequently sequenced. Sequencing was performed as described previously (21). In short, a 1.8-kb fragment of the *p53* gene encompassing the exons 5–9 was amplified from the DNA of microdissected tissue specimens. Purified PCR products were sequenced directly by exon-specific primers using the radioactive dideoxynucleotide method (AmpliCycle Sequencing Kit; Perkin-Elmer, Norwalk, CT; Ref. 21). Primer sequences and reaction conditions are available on request. Plaque assays were performed on *p53* exon fragments amplified from exfoliated cell DNA as described by Van Houten *et al.* (20). In short, the amplimers were digested with *EcoRI*, cloned in 56  $\lambda$  GT11 vector arms, packaged *in vitro*, and plated on *Escherichia coli* K12 LE392. Approximately 5000 plaques were hybridized differentially with either an end-labeled mutant or wild-type oligonucleotide as probe. After autoradiography, the number of mutant/wild-type plaques was calculated.

## Results

**Molecular Evidence for Field Cancerization.** In the pilot study of 11 patients, we analyzed two mucosal biopsies, one < 0.5 cm (*F1*) and one > 0.5 cm (*F5*) from the edge of the tumor (Fig. 1). In 2 of 11 patients, genetic alterations were detected in both mucosal biopsies. In the first patient, the field also extended into the margins of the surgical specimen, whereas in the second patient the field appeared to be limited in size because it did not reach the resection margins. Based on these observations, we concluded that analysis of biopsies taken in only a single quadrant adjacent to the tumor could result in an underestimation of the number of patients with genetically altered fields. For the 28 patients subsequently enrolled, we therefore analyzed the tumor and four adjacent mucosal biopsies surrounding the tumor (one per quadrant; < 0.5 cm from the edge of the tumor) and, when available, one distant mucosal biopsy (>0.5 cm from the edge of the tumor).

The tumors and the mucosal epithelium of the biopsies were microdissected and analyzed for LOH. When present, histologically abnormal mucosal epithelium was microdissected separately from the histologically normal mucosal epithelium. In the tumors of these 28 patients, LOH was scored in at least one chromosomal locus (Table 1). In 10 of 28 (36%) patients, at least one mucosal biopsy showed LOH in one or more micro-

Table 1 Frequency of LOH in HNSCC<sup>a</sup>

Locus	Map position <sup>b</sup>	LOH (%) <sup>c</sup>
<i>D3S1284</i>	3p12	17/21 (81)
<i>D3S1766</i>	3p14	18/23 (78)
<i>D3S1029</i>	3p21	13/22 (59)
<i>D3S1293</i>	3p24.3	16/22 (73)
<i>D9S171</i>	9p21	20/21 (95)
<i>D9S157</i>	9p22	20/25 (80)
<i>CHRN1</i>	17p11-12	15/21 (71)
<i>TP53</i>	17p13.1	16/24 (67)

<sup>a</sup> Results were generated from analysis of tumor DNA from 28 patients.

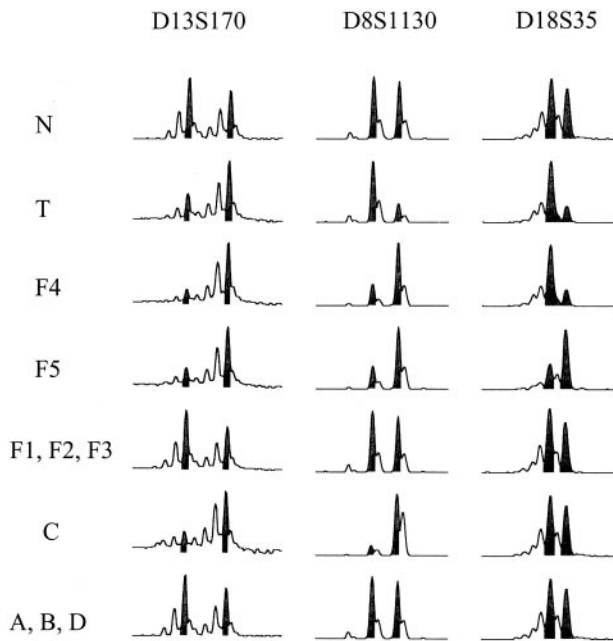
<sup>b</sup> The map positions are based on the Genome Database.<sup>4</sup>

<sup>c</sup> Number of tumors with LOH/total number of informative patients.

satellite marker(s). Fig. 2 shows the summary of the microsatellite analysis of these 10 patients. The number of mucosal biopsies with genetic alterations varied from one to three per patient (Fig. 2). In the 10 patients who showed genetic evidence of field cancerization, the paraffin-embedded surgical margins were also analyzed to study the extension of the field. In 7 of 10 patients, the surgical margins showed LOH in one or more microsatellite marker(s) (Fig. 2). In all cases, the localization of the surgical margins that showed genetic alterations corresponded to that of the mucosal biopsy or biopsies with LOH, strongly suggesting that these genetically altered fields were connected. The number of surgical margins that showed genetic alterations varied from one to two per patient (Fig. 2). Hence, the size of the field varies considerably between patients and can extend beyond the surgical margins.

**Genetic Comparison between Field and Tumor.** In 2 of 10 cases, the tumor and field showed similar genetic alterations (patients 7 and 17; Fig. 2). In 6 of 10 cases, the tumor showed additional losses, indicative of progression (patients 1, 2, 10, 11, 16, and 28; Fig. 2). In another 4 of 10 patients (patients 2, 11, 16, and 26), the field showed losses that were not present in the tumor, suggesting that these losses occurred after the divergence of two subclones, one of which progressed into invasive carcinoma. In some patients, the various mucosal biopsies showed the same genetic alterations, suggesting expansion of one clone. However, in 6 of 10 patients (patients 7, 10, 11, 16, 26, and 28), the various biopsies showed differences in the LOH pattern suggesting the expansion of different subclones within the field. Fig. 3 shows the genetic differences between the tumor and the various field subclones of patient 26. At chromosome 13q, the tumor and field samples showed the same losses. However, at chromosome 8p, the alternative allele is lost in the field samples as compared with the tumor. Moreover, at

Fig. 2 Results of the 10 patients who showed genetic evidence of field cancerization. *F1–F5* represent the five mucosal biopsies taken of the surgical specimen (see Fig. 1), and *A–G* represent the surgical margins (see Fig. 1). The *p53* mutations are indicated as *NEG* (negative) and *POS* (positive). The codon and type of mutation are listed in Table 2. In all cases, the surgical margins that showed genetic alterations corresponded to the localization of the mucosal biopsy (or biopsies) with LOH, making it likely that these genetically altered fields were connected. Please note that the margins were randomly coded by the pathologist, independent of the coding that was used for the mucosal biopsies. Therefore, each patient has a unique orientation of the mucosal biopsies with respect to the surgical margins (unlike the one that is presented in Fig. 1). For example, in one case, *F1* is located proximal to *A*, and in another case, *F1* is located proximal to *C*, and so forth.



**Fig. 3** Results of microsatellite analysis of markers D13S170 (13q31), D8S1130 (8p23), and D18S35 (18q21) of patient 26 (see Fig. 2). *Highlighted peaks* show the two alleles that were used for calculation of LOH, as compared with normal DNA (-N). Results of marker D13S170 showed that the tumor samples (T), F4, F5, and C (see Fig. 1) were all scored as LOH2 (loss of smaller allele) and that F1–F3 and A, B, D were scored as having no loss. Results of marker D8S1130 show genetic differences between tumor and field. The tumor showed loss of the larger allele (LOH1), whereas mucosal samples F4, F5, and margin C showed loss of the smaller allele (LOH2). Results of marker D18S35 show different subclones and genetic heterogeneity. Tumor and mucosal sample F4 showed LOH1; however, mucosal sample F5 showed loss of the other allele (LOH2), whereas margin C showed no loss at all.

chromosome 18q, there are also genetic differences between the different field samples, clearly demonstrating the existence of various subclones.

**p53 Mutation Analysis of Field and Tumor.** In all 10 patients with genetically altered fields, the tumors were sequenced for *p53* mutations in exons 5–9. In 8 of 10 patients, a *p53* mutation was found in the tumor (Table 2). To detect differences between the field and tumor, the DNA of the field was also sequenced to confirm the mutation of the tumor. In six of eight patients, the field had the same mutation as the tumor, whereas in two of eight patients, the field lacked the mutation found in the tumor.

**Persistence of Field Cancerization.** In 7 of 10 patients, the field extended beyond the surgical margins (Fig. 2). In six of seven patients, a *p53* mutation was found in the tumor, and in three of six patients (patients 2, 16, and 26), the *p53* mutation could be confirmed in the resection margin (Table 2). Exfoliated cells taken from the scars of these three patients at 3 and 6 months after surgery were analyzed to follow the persistence of field cancerization. The exfoliated cells were analyzed for mutated DNA by the plaque assay using *p53* mutations as a marker. Patient 2 clearly showed *p53*-mutated cells at 3 and 6 months (0.17% and 0.56% of the screened plaques, respectively) after

excision of the tumor (data not shown). However, patients 16 and 26 did not show *p53*-mutated cells in the exfoliated cell samples.

**Histology.** All tumor and mucosa samples were reviewed and histopathologically classified and compared with the genetic analysis. In 12 patients, all mucosal biopsies were classified as normal mucosa, and in 16 patients, one or more mucosal biopsies were classified as mild, moderate, or severe dysplasia. The results of the genetic analysis and the histology of the 10 patients who showed genetic evidence of field cancerization are summarized in Table 3. The comparison between histological assessment and microsatellite analysis of all mucosal biopsies is depicted in Table 4A. In total, 132 mucosal biopsies were analyzed; 103 were classified as normal mucosa, 19 were classified as mild dysplasia, 8 were classified as moderate dysplasia, and 2 were classified as severe dysplasia. The presence of genetic alterations coincided in most cases with the results of the histopathological assessment; of the 17 mucosal biopsies that showed LOH, 14 were dysplastic, and 3 were normal. Conversely, the presence of dysplasia agreed less with the results of LOH analysis; 6 of the 19 mild dysplasias and 6 of the 8 moderate dysplasias showed LOH. For the 10 patients who showed genetic evidence of field cancerization, the paraffin-embedded margins were also reviewed and classified. The results of histological assessment and microsatellite analysis are shown in Table 4B. In this material, the presence of genetic alterations was completely concordant with the histopathological assessment: all 9 margins that showed LOH were classified as dysplastic. The presence of dysplasia coincided well with LOH analysis in this selected group; four of the eight mildly dysplastic, all three moderately dysplastic, and both severely dysplastic margins showed LOH.

**Clinical Implications.** The clinical significance of the persistent fields could not be established in this study, mainly because the number of analyzed patients is rather small and, more importantly, because the follow-up period is rather short (range, 8–18 months; average follow-up, 12 months). To date, none of the seven patients whose surgical margins showed genetic alterations have developed a local recurrence or SPT. However, in the small pilot group in which only two biopsies adjacent to the tumor were analyzed, one patient did show a local recurrence in a field. This patient presented initially with a T<sub>1</sub>N<sub>0</sub> floor of the mouth carcinoma and developed a clinically defined local recurrence at 1.5 cm from the scar after 28 months of follow-up. The results of the microsatellite analysis of the tumors as well as the intervening resection margins (additional markers at 9p and 13q were used) are shown in Fig. 4. The results strongly suggest that the local recurrence developed in a genetically altered field that had not been resected when the primary tumor was treated surgically. All biopsies shared the same genetic alterations at markers D9S1748 and D9S1751. Mucosal biopsy F5, surgical margin D of tumor 1, and local recurrence and surgical margin A as well as B (of tumor 2) showed the same additional hit at marker D13S158, which was not present in the first tumor. In fact, there were no differences in microsatellite alterations between the local recurrence (tumor 2) and surgical margin D of tumor 1. Mucosal biopsy F1 was classified as mild dysplasia, whereas mucosal biopsy F5 and all surgical margins [D (T1), A (T2), and B (T2)] were classified as

Table 2 Mutations of the *p53* gene in patients with field cancerization

Patient	Tumor				Field	
	Mutation	Exon	Change	Codon	Amino acid change	Mutation <sup>a</sup>
1	+	6	1-bp ins	220–221	Frameshift	Id. (F2)
2	+	7	G→A	238	Cys→Tyr	Id. (F1, F2, F4, A, B)
7	–					
10	+	8	G→T	298	Glu→Stop	Neg. (F4, B)
11	+	5	G→A	175	Arg→His	Neg. (F5, D, E)
16	+	8	C→G	283	Arg→Gly	Id. (F3, C); Neg. (F2, F5)
17	+	5	G→A	141	Cys→Tyr	Id. (F1)
25	+	8	1-bp del	280	Frameshift	Id. (F4)
26	+	7	C→T	248	Arg→Trp	Id. (F4, F5, C)
28	–					

<sup>a</sup> Id. means that the *p53* mutation of the tumor was identical to the mutation of the field samples listed in parentheses. Neg. means that the mutation of the tumor was not confirmed in the field samples listed in parentheses. Confirmation was established by sequencing. ins, insertion; del, deletion.

Table 3 Comparison between histology and genetic alterations in the patients with field cancerization

Patient no.	F1	F2	F3	F4	F5
1	N/– <sup>a</sup>	Mild/+	N/–	N/–	
2	Mod/+	Mod/+	N/–	Mod/+	
7	Sev/+	N/–	N/–	Sev/+	N/–
10	N/–	N/–	N/–	Mod/+	
11	N/–	N/–	N/–	N/–	Mod/+
16	N/–	<b>N/+<sup>b</sup></b>	Mild/+	N/–	<b>N/+</b>
17	Mod/+	N/–	N/–	N/–	N/–
25	N/–	N/–	N/–	Mild/+	N/–
26	N/–	<b>Mild/–</b>	N/–	Mild/+	Mild/+
28	N/–	<b>N/+</b>	<b>Mild/–</b>	Mild/+	<b>Mod/–</b>

<sup>a</sup> N, normal mucosa; Mild, mild dysplasia; Mod, moderate dysplasia; Sev, severe dysplasia. –, no LOH; +, LOH.

<sup>b</sup> Bold values represent an apparent lack of association between histology and genetic analysis.

moderate dysplasia. *p53* mutations were not detected in either of the tumors (T1 and T2, Fig. 4).

## Discussion

The present genetic analysis of macroscopically normal mucosa surrounding HNSCC has revealed a molecular basis for the process of field cancerization. There is molecular evidence for field cancerization in 36% (10 of 28) patients with HNSCC. The size of the field varies considerably between patients, and in 70% (7 of 10) of the patients, the field extended beyond the surgical margins.

The presence of genetic alterations in the mucosa samples and surgical margins was found to be associated with histopathological changes (Table 4). The majority of the genetically altered fields were classified as dysplastic, and in a few cases, genetic alterations were detected in histopathological normal mucosa, as also shown previously (22). The presence of dysplasia in the mucosal epithelium, however, was not always associated with genetic alterations because approximately half of the dysplastic lesions did not show LOH (Table 4). A possible explanation for this finding could be the difficulties of histopathological assessment of freshly frozen tissues because the

Table 4 Comparison between histology and genetic alterations in 28 HNSCC patients

In A, the comparison between histological assessment (degree of dysplasia) and LOH analysis of the 132 frozen mucosal biopsies obtained from all 28 patients is depicted. In B, the same comparison is shown of the 43 paraffin-embedded surgical margins obtained from the 10 field patients.

A. Comparison of 132 frozen mucosal biopsies					
	Normal	Mild	Moderate	Severe	
+ LOH	3	6	6	2	17
– LOH	100	13	2	0	115
Total	103	19	8	2	132
B. Comparison of 43 paraffin-embedded surgical margins					
	Normal	Mild	Moderate	Severe	
+ LOH	0	4	3	2	9
– LOH	30	4	0	0	34
Total	30	8	3	2	43

histopathological classification of the paraffin-embedded samples was more concordant with genetic analysis. Moreover, interobserver variability in the scoring/grading of mild dysplasia could play a role (23) because the most cases without genetic alterations were observed in the mild dysplasia group. A third explanation is that mild dysplastic lesions harbor genetic alterations that have not been investigated. However, the markers used in this study are supposed to reflect the early transforming events in HNSCC (11).

Comparison of the spectrum of genetic alterations in premalignant field lesions provides insight into the carcinogenesis of HNSCC. In six of eight patients, the field had the same *p53* mutation as the tumor, strongly indicating a clonal relationship between the surrounding field(s) and tumor. Despite this clonal relationship, there were differences in most patients in the genetic alterations between field and tumor. In 6 of 10 patients, the tumor showed additional microsatellite alterations, and in 2 of 8 patients, *p53* mutations present in the tumor were not detected in the field. These additional genetic alterations are indicative of progression of the tumor according to the multistep

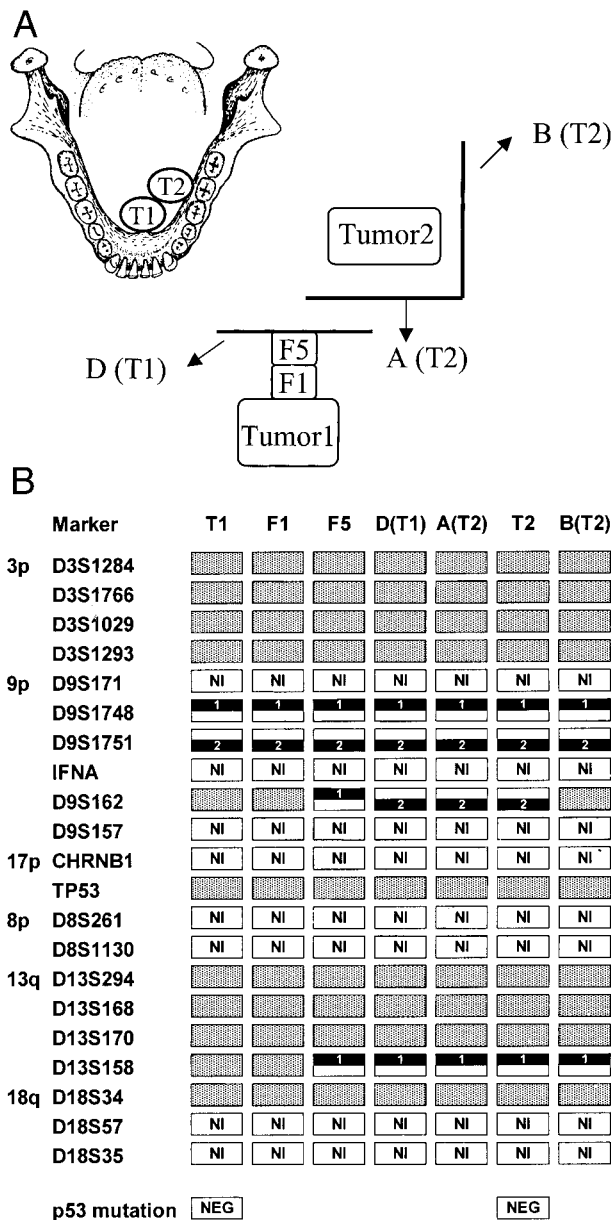


Fig. 4 Field analysis of a patient with a T<sub>1</sub>N<sub>0</sub> floor of the mouth carcinoma (T1) who developed a (clinically) local recurrence (T2) 1.5 cm from the scar after 28 months of follow-up. A, schematic drawing of the orientation of the surgical specimens. Biopsies of both tumors and intervening mucosa were taken from the surgical specimen [one (F1) < 0.5 cm and one (F5) > 0.5 cm from the edge of the tumor]. Also, the paraffin-embedded resection margins of both surgical specimens [D (T1), A (T2), and B (T2)] were analyzed to study the extension of the field. B, the results of the microsatellite analysis suggest that the local recurrence has developed in the persistent field. All biopsies share the same genetic alterations at markers D9S1748 (9p21) and D9S1751 (9p21). Mucosal biopsy F1, surgical margin D of tumor 1, and local recurrence (T2) and surgical margin A and B of tumor 2 show the same additional hit at marker D13S158 (13q32), which was not present in the index tumor (T1). For an explanation of the other symbols, see Fig. 2.

model (11, 12). In contrast, in 4 of 10 patients, the field showed microsatellite alterations that were not present in the tumor. The picture emerges that all lesions share a common initiating event and that progression leads to the evolution of related subclones and genetic heterogeneity. One subclone eventually progresses into a tumor. The presence of different subclones throughout the field supports this hypothesis (Fig. 2). Other authors have described comparable findings (24, 25). The presented data support the following interpretation of the field cancerization concept: a single cell is genetically altered and gives rise to a large premalignant field that extends by clonal expansion and gradually replaces the normal mucosa. Subsequent progression of the different but related subclones in the field leads to the development of (multiple) tumor(s).

In this study, not only was the presence of genetically altered fields established, but the persistence during clinical follow-up using the plaque assay. Microsatellite analysis is an insensitive molecular assay for tumor (or premalignant) cell detection, and a clinical sample should at least contain more than 50% aberrant cells to score LOH (see the formula in "Materials and Methods"). In all patients, the clinical aspect of the mucosa around the scar appeared normal after surgery. Therefore, it was not possible to select an area with a high percentage of genetically altered cells by visual inspection. The plaque assay is a highly specific and sensitive methodology for the identification of rare tumor (or premalignant) cells in clinical samples based on the detection of mutated *p53* (20). As an example, the exfoliated cells of patient 2 were analyzed for mutated DNA. This patient clearly showed *p53*-mutated cells at 3 and 6 months (0.17% and 0.56% of the screened plaques, respectively) after excision of the tumor (data not shown), indicating that these genetically altered fields can persist for at least half a year after removal of the tumor. In patients 16 and 26, however, we could not detect *p53*-mutated cells during clinical follow-up, although the mucosal biopsy as well as the resection margin showed the same *p53* mutation as seen in the tumor. An explanation could be that the fields remaining in these two patients were too small to be detected by the plaque assay. Only a small part of the single positive margins of patients 16 and 26 consisted of genetically altered cells, whereas the two resection margins of patient 2 consisted completely of genetically altered cells. Another even more interesting explanation could be that not all fields persist over time, but some might regress and disappear spontaneously [a phenomenon that is also observed in other premalignant lesions in the upper aerodigestive tract such as oral leukoplakia (26)].

A nonresected field could (in part) explain the high rate of local recurrence of HNSCC. A field that extends beyond surgical margins and thus has not been excised can progress after treatment into a new tumor at the same site. Such an example was seen in a patient of the pilot study (Fig. 4). This patient was surgically treated for a T<sub>1</sub>N<sub>0</sub> tumor in the floor of the mouth and developed a local recurrence after 28 months. The results of the microsatellite analysis strongly suggest that the local recurrence developed in a genetically altered field that had not been resected when the primary tumor was treated surgically. According to the presently used clinical criteria, this new tumor in the field was classified as a local recurrence; however, the issue of



whether it should be defined as a SPT can be discussed based on the molecular criteria.

Persistence of fields could also explain a subgroup of the clinically defined SPTs. Hypothetically, a persistent genetically altered field could extend into a large area of the mucosa. A new tumor developing in this field would then clinically be classified as a SPT, based on the distance (>2 cm) to the index tumor (27). Califano *et al.* (28) suggested that two tumors ( $T_1$ , hypopharynx;  $T_2$ , lower esophagus) that were separated by 40 cm of normal-appearing mucosa but showed identical genetic alterations apparently originated by a process of clonal expansion of a single progenitor cell. The same notion was also reported by Worsham *et al.* (6) for two synchronous tumors of the floor of the mouth and pyriform sinus that were separated by 4–6 cm. However, the presence of genetic alterations in the intervening mucosa was not confirmed in these studies.

A number of parameters may determine whether a field develops into a new tumor. A very important factor might be the follow-up period because a premalignant field may need a longer time to progress into a new tumor than a tumor that develops from remaining tumor cells. The follow-up time of the seven field patients varied from 8–18 months, with an average of 12 months, and to date, no new tumors have been observed. Mao *et al.* (29) and Rosin *et al.* (30) have shown that oral premalignant lesions might need up to 67 or 96 months, respectively, to progress to invasive cancer.

In addition, the pattern of LOH of the persistent fields might also play an important role in the progression to cancer (30). Rosin *et al.* (30) showed that patients with oral premalignant lesions with LOH at 3p and/or 9p had a 3.8-fold increased relative risk of developing cancer. In contrast, patients with additional losses of other chromosomes (4q, 8p, 11q, or 17p) showed up to a 33-fold increase in relative cancer risk. In our study, the surgical margins of some patients showed almost an identical LOH pattern as the tumor (Fig. 2).

In summary, our study provides the molecular basis for expanding fields and the presence of various genetically distinguishable subclones therein. Additional studies are needed to monitor the clinical implications of these persistent fields. Adequately identifying the extension of genetically altered fields and their risk for progression may have profound implications for future patient management.

## Acknowledgments

We thank Fedor Denkers for sequencing the p53 mutations and performing the plaque assays and Dr. Paul J. van Diest for additional histopathological review of tissue sections.

## References

- Muir, C., and Weiland, L. Upper aerodigestive tract cancers. *Cancer (Phila.)*, 75: 147–153, 1995.
- Vokes, E. E., Weichselbaum, R. R., Lippman, S. M., and Hong, W. K. Head and neck cancer. *N. Engl. J. Med.*, 328: 184–194, 1993.
- Leemans, C. R., Tiwari, R., Nauta, J. J., van der Waal, I., and Snow, G. B. Recurrence at the primary site in head and neck cancer and the significance of neck lymph node metastases as a prognostic factor. *Cancer (Phila.)*, 73: 187–190, 1994.
- Lippman, S. M., and Hong, W. K. Second malignant tumors in head and neck squamous cell carcinoma: the overshadowing threat for patients with early-stage disease. *Int. J. Radiat. Oncol. Biol. Phys.*, 17: 691–694, 1989.
- Bedi, G. C., Westra, W. H., Gabrielson, E., Koch, W., and Sidransky, D. Multiple head and neck tumors: evidence for a common clonal origin. *Cancer Res.*, 56: 2484–2487, 1996.
- Worsham, M. J., Wolman, S. R., Carey, T. E., Zarbo, R. J., Benninger, M. S., and Vandyke, D. L. Common clonal origin of synchronous primary head and neck squamous cell carcinomas: analysis by tumor karyotypes and fluorescence *in situ* hybridization. *Hum. Pathol.*, 26: 251–261, 1995.
- Scholes, A. G. M., Woolgar, J. A., Boyle, M. A., Brown, J. S., Vaughan, E. D., Hart, C. A., Jones, A. S., and Field, J. K. Synchronous oral carcinomas: independent or common clonal origin? *Cancer Res.*, 58: 2003–2006, 1998.
- Slaughter, D. P., Southwick, H. W., and Smejkal, W. “Field cancerization” in oral stratified squamous epithelium. *Cancer (Phila.)*, 6: 963–968, 1953.
- Chung, K. Y., Mukhopadhyay, T., Kim, J., Casson, A., Ro, J. Y., Goepfert, H., Hong, W. K., and Roth, J. A. Discordant p53 gene mutations in primary head and neck cancers and corresponding second primary cancers of the upper aerodigestive tract. *Cancer Res.*, 53: 1676–1683, 1993.
- Van Oijen, M. G. C. T., van der Straat F. G. J. L., Tilanus, M. G. J., and Slootweg, P. J. The origins of multiple squamous cell carcinomas in the aerodigestive tract. *Cancer (Phila.)*, 88: 884–893, 2000.
- Califano, J., van der Riet, P., Westra, W., Nawroz, H., Clayman, G., Piantadosi, S., Corio, R., Lee, D., Greenberg, B., Koch, W., and Sidransky, D. Genetic progression model for head and neck cancer: implications for field cancerization. *Cancer Res.*, 56: 2488–2492, 1996.
- Fearon, E. R., and Vogelstein, B. A genetic model for colorectal tumorigenesis. *Cell*, 61: 759–767, 1990.
- Partridge, M., Emilion, G., Pateromichelakis, S., Phillips, E., and Langdon, J. Location of candidate tumour suppressor gene loci at chromosomes 3p, 8p and 9p for oral squamous cell carcinomas. *Int. J. Cancer*, 83: 318–325, 1999.
- Sunwoo, J. B., Holt, M. S., Radford, D. M., Deeker, C., and Scholnick, S. B. Evidence for multiple tumor suppressor genes on chromosome arm 8p in supraglottic laryngeal cancer. *Genes Chromosomes Cancer*, 16: 164–169, 1996.
- Gupta, V. K., Schmidt, A. P., Pashia, M. E., Sunwoo, J. B., and Scholnick, S. B. Multiple regions of deletion on chromosome arm 13q in head-and-neck squamous-cell carcinoma. *Int. J. Cancer*, 84: 453–457, 1999.
- Takebayashi, S., Ogawa, T., Jung, K. Y., Muallem, A., Mineta, H., Fisher, S. G., Grenman, R., and Carey, T. E. Identification of new minimally lost regions on 18q in head and neck squamous cell carcinoma. *Cancer Res.*, 60: 3397–3403, 2000.
- Sobin, L. H., and Wittekind, C. *TNM Classification of Malignant Tumors*, 5th ed. New York: Wiley-Liss, 1997.
- Shanmugaratnam, K. *Histological Typing of Tumours of the Upper Respiratory Tract and Ear*, 2nd ed. Berlin: Springer-Verlag, 1993.
- Pearlstein, R. P., Benninger, M. S., Carey, T. E., Zarbo, R. J., Torres, F. X., Rybicki, B. A., and van Dyke, D. L. Loss of 18q predicts poor survival of patients with squamous cell carcinoma of the head and neck. *Genes Chromosomes Cancer*, 21: 333–339, 1998.
- van Houten, V. M. M., Tabor, M. P., van den Brekel, M. W. M., Denkers, F., Wishaupt, R. G. A., Kummer, J. A., Snow G. B., and Brakenhoff, R. H. Molecular assays for the diagnosis of minimal residual head and neck cancer: methods, reliability, pitfalls, and solutions. *Clin. Cancer Res.*, 6: 3803–3816, 2000.
- Sidransky, D., Von Eschenbach, A., Tsai, Y. C., Jones, P., Summerhayes, I., Marshall, F., Paul, M., Green, P., Hamilton, S. R., Frost, P., *et al.* Identification of p53 gene mutations in bladder cancers and urine samples. *Science (Wash. DC)*, 252: 706–709, 1991.

22. Lydiatt, W. M., Anderson, P. E., Bazzana, T., Casale, M., Hughes, C. J., Huvos, A. G., Lydiatt, D. D., and Schantz, S. P. Molecular support for field cancerization in the head and neck. *Cancer (Phila.)*, 82: 1376–1380, 1998.
23. Cross, S. S. Grading and scoring in histopathology. *Histopathology*, 33: 99–106, 1998.
24. Galipeau, P. C., Prevo, L. J., Sanchez, C. A., Longton, G. M., and Reid, B. J. Clonal expansion and loss of heterozygosity at chromosomes 9p and 17p in premalignant esophageal (Barrett's) tissue. *J. Natl. Cancer Inst.*, 91: 2087–2095, 1999.
25. Partridge, M., Emilion, G., Pateromichelakis, S., Phillips, E., and Langdon, J. Field cancerisation of the oral cavity: comparison of the spectrum of molecular alterations in cases presenting with both dysplastic and malignant lesions. *Oral Oncol.*, 33: 332–337, 1997.
26. Pindborg, J. J., Daftary, D. K., and Mehta, F. S. A follow-up study of sixty-one oral dysplastic precancerous lesions in Indian villagers. *Oral Surg. Oral Med. O.*, 43: 383–390, 1977.
27. Hong, W. K., Lippman, S. M., Itri, L. M., Karp, D. D., Lee, J. S., Byers, R. M., Schantz, S. P., Kramer, A. M., Lotan, R., Peters, L. J., Dimery, I. W., Brown, B. W., and Goepfert, H. Prevention of second primary tumors with isotretinoin in squamous-cell carcinoma of the head and neck. *N. Engl. J. Med.*, 323: 795–801, 1990.
28. Califano, J., Leong, P. L., Koch, W. M., Eisenberger, C. F., Sidransky, D., and Westra, W. H. Second esophageal tumors in patients with head and neck squamous cell carcinoma: an assessment of clonal relationships. *Clin. Cancer Res.*, 5: 1862–1867, 1999.
29. Mao, L., Lee, J. S., Fan, Y. H., Ro, J. Y., Batsakis, J. G., Lippman, S., Hittelman, W., and Hong, W. K. Frequent microsatellite alterations at chromosomes 9p21 and 3p14 in oral premalignant lesions and their value in cancer risk assessment. *Nat. Med.*, 2: 682–685, 1996.
30. Rosin, M. P., Cheng, X., Poh, C., Lam, W. L., Huang, Y. Q., Lovas, J., Berean, K., Epstein, J. B., Priddy, R., Le, N. D., and Zhang, L. W. Use of allelic loss to predict malignant risk for low-grade oral epithelial dysplasia. *Clin. Cancer Res.*, 6: 357–362, 2000.