

# Persistence of SARS-CoV-2 in the first trimester placenta leading to transplacental transmission and fetal demise from an asymptomatic mother

Prajakta Shende<sup>1</sup>, Pradip Gaikwad<sup>1\*</sup>, Manisha Gandhewar<sup>1</sup>, Pawankumar Ukey<sup>2</sup>, Anshul Bhide<sup>3</sup>, Vainav Patel<sup>4</sup>, Sharad Bhagat<sup>4</sup>, Vikrant Bhor<sup>5</sup>, Smita Mahale<sup>6</sup>, Rahul Gajbhiye<sup>7</sup>, and Deepak Modi<sup>3,\*</sup>

<sup>1</sup>Department of Obstetrics and Gynecology, ESI-PGIMSR and Model Hospital Andheri, E.S.I.S. Hospital Kandivali, Mumbai, India <sup>2</sup>Department of Microbiology, ESI-PGIMSR and Model Hospital Andheri, E.S.I.S. Hospital Kandivali, Mumbai, India <sup>3</sup>Molecular and Cellular Biology Laboratory, ICMR-National Institute for Research in Reproductive Health, Indian Council of Medical Research (ICMR), Mumbai, India <sup>4</sup>Department of Biochemistry, ICMR-National Institute for Research in Reproductive Health, Indian Council of Medical Research (ICMR), Mumbai, India <sup>5</sup>Department of Molecular Immunology and Microbiology, ICMR-National Institute for Research in Reproductive Health, Indian Council of Medical Research (ICMR), Mumbai, India <sup>6</sup>Director and Department of Structural Biology, ICMR-National Institute for Research in Reproductive Health, Indian Council of Medical Research (ICMR), Mumbai, India <sup>7</sup>Department of Clinical Research, ICMR-National Institute for Research in Reproductive Health, Indian Council of Medical Research (ICMR), Mumbai, India

\*Correspondence address. Department of Obstetrics and Gynecology, ESI-PGIMSR and Model Hospital Andheri, E.S.I.S. Hospital Kandivali, Mumbai, India. E-mail: drpradipgaikwad@gmail.com (P.G.) or Molecular and Cellular Biology Laboratory, ICMR-National Institute for Research in Reproductive Health, Indian Council of Medical Research (ICMR), JM Street, Parel, Mumbai 400012, India. E-mail: deepaknmodi@yahoo.com, modid@nirrh.res.in (D.M.)

Submitted on September 16, 2020; resubmitted on December 6, 2020; editorial decision on December 10, 2020

**ABSTRACT:** Coronavirus disease 2019 (COVID-19) is caused by infection of the respiratory tract by severe acute respiratory syndrome coronavirus 2 (SARS-CoV-2) which survives in the tissues during the clinical course of infection but there is limited evidence on placental infection and vertical transmission of SARS-CoV-2. The impact of COVID-19 in first trimester pregnancy remains poorly understood. Moreover, how long SARS-CoV-2 can survive in placenta is unknown. Herein, we report a case of a pregnant woman in the first trimester who tested positive for SARS-CoV-2 at 8 weeks of gestation, although her clinical course was asymptomatic. At 13 weeks of gestation, her throat swab tested negative for SARS-CoV-2 but viral RNA was detected in the placenta, and the Spike (S) proteins (S1 and S2) were immunolocalized in cytotrophoblast and syncytiotrophoblast cells of the placental villi. Histologically, the villi were generally avascular with peri-villus fibrin deposition and in some areas the syncytiotrophoblast layer appeared lysed. The decidua also had fibrin deposition with extensive leukocyte infiltration suggestive of inflammation. The SARS-CoV-2 crossed the placental barrier, as the viral RNA was detected in the amniotic fluid and the S proteins were detected in the fetal membrane. Ultrasonography revealed extensively subcutaneous edema with pleural effusion suggestive of hydrops fetalis and the absence of cardiac activity indicated fetal demise. This is the first study to provide concrete evidence of persistent placental infection of SARS-CoV-2 and its congenital transmission is associated with hydrops fetalis and intrauterine fetal demise in early pregnancy.

**Key words:** virus / COVID-19 / coronavirus / pregnancy / vertical transmission / abortion / hydrops fetalis / congenital / placenta / fetal membrane

## Introduction

In March 2020, the World Health Organization declared coronavirus disease 2019 (COVID-19) as a global pandemic. Caused by infection

of the respiratory tract with severe acute respiratory syndrome coronavirus 2 (SARS-CoV-2), the numbers of confirmed cases have escalated rapidly. Despite this, the information on the effects of SARS-CoV-2 infection in pregnancy is limited to description of

presenting symptoms and outcomes during late trimester infections (Allotey et al., 2020; Gajbhiye et al., 2020; Waghmare et al., 2021). Since the maternal physiology changes dynamically throughout pregnancy, the information on late trimester infections cannot be extrapolated directly to infection earlier in gestation.

During pregnancy, the placenta is an anatomical barrier that acts as the first line of defense to avoid transmission of pathogens from mother to fetus. However, some infectious agents can breach the placental barrier resulting in vertical transmission and activating innate immune responses causing major maternal and fetal complications (Parker et al., 2020). For pregnant women with COVID-19, vertical transmission of SARS-CoV-2 and the pregnancy complications like miscarriage, fetal malformations and/or stillbirth, are potentially serious concerns. The spike (S) proteins of SARS-CoV-2 bind to the host receptor ACE2 allowing the virus to enter the cells and replicate (Hoffmann et al., 2020; Jagtap et al., 2020). The placental syncytiotrophoblast, cytotrophoblasts and the extra-villous trophoblasts express the ACE2 receptors and also the genes necessary for S protein processing, viral replication and budding (Ashary et al., 2020; Colaco et al., 2020; Singh et al., 2020; Taglauer et al., 2020). These observations imply that the placenta is permissive for SARS-CoV-2 infection. Indeed, SARS-CoV-2 RNA and protein are detected in placenta of mothers with COVID-19 (Ashary et al., 2020; Hosier et al., 2020; Taglauer et al., 2020; Vivanti et al., 2020). In clinical cases and experimentally induced infections, SARS-CoV-2 is detected in multiple tissues (Best Rocha et al., 2020; Bradley et al., 2020; Chandrashekar et al., 2020; Costa et al., 2020; Yao et al., 2020; Zhang et al., 2020) during acute viremia; extended periods of viral shedding after clearing pulmonary infection have also been observed (Gupta et al., 2020; Wu et al., 2020; Zhang et al., 2020). Whether SARS-CoV-2 can also survive and shed from the placenta for extended periods is hitherto unknown.

Congenital infection of SARS-CoV-2 from fetomaternal interface is a matter of controversy. Some case series suggest that there is lack of vertical transmission of SARS-CoV-2 (Masmajan et al., 2020; Li et al., 2020b). However, large-scale systematic reviews reveal that a proportion of babies born to mother with COVID-19 are positive for viral RNA (Allotey et al., 2020; Gajbhiye et al., 2020). Whether this infection is due to transmission of SARS-CoV-2 in utero or the infection is acquired during the course of delivery or after birth remains unclear.

Herein, we report a case of first trimester asymptomatic SARS-CoV-2 infection associated with hydrops fetalis and fetal death. We observed that the viremia persisted in the placenta weeks after the mother cleared it from the pulmonary tract and there was transplacental transmission as SARS-CoV-2 could be detected in the amniotic fluid and fetal membranes.

## Materials and methods

### Ethics statement

The study was approved by the Institutional Ethics Committee of ESI-PGIMS and Model Hospital, Mumbai, India. Written informed consent was taken from the patient.

This case is described in the preprint (Shende et al., 2020). A woman with 13 weeks of amenorrhea reported for routine antenatal

checkup at the hospital. She had history of asymptomatic SARS-CoV-2 infection in the nasopharyngeal swabs 5 weeks ago. Upon examination, ultrasound evaluation showed hydrops fetalis with fetal demise. Dilation and curettage were done according to hospital norms and necessary precautions were taken to avoid contamination of the placental and amniotic fluid. Clear amniotic fluid was carefully aspirated from the gestational sac and transported in a sterile container. Serum was sent for TORCH (Toxoplasmosis, Rubella Cytomegalovirus, Herpes Simplex), antiphospholipid (APLA) IgG and IgM, anti-double strand DNA, cardiolipin (ACL) IgG and IgM testing. Pieces of the placental tissue were fixed in 10% buffered formalin processed for paraffin embedding and sectioning. Placental histopathology was evaluated by routine hematoxylin and eosin staining. Fluorescence *in situ* hybridization on paraffin sections was done to determine aneuploidy of chromosomes 13, 18, 21, X and Y as described previously (Modi et al., 2003). Placental villi were collected in virus transport medium. Total RNA was isolated from placental villi using the Trizol reagent as per manufacturer's instructions (Thermo Fisher Scientific, Waltham, MA, USA). To test the presence of SARS-CoV-2, reverse transcriptase polymerase chain reaction (RT-PCR) for ORF1b, RdRP, N and E genes was done using commercial kits. Immunofluorescence was done as described earlier with minor modifications (Godbole et al., 2017). The SARS-CoV-2 spike proteins S1 and S2 were detected using 1:25 dilution of the monoclonal antibodies (MP Biomedicals, Catalogue number: SKU: 08720301, SKU: 08720411, Asia Pacific, Singapore) and the Opal 7 kit (catalog #NEL797001KT; PerkinElmer, Waltham, MA, USA), which uses individual tyramide signal amplification-conjugated fluorophores was used for signal detection.

## Results

### Case details

A 26-year-old woman, third gravida, one living child and one first trimester spontaneous abortion reported to the hospital after a positive pregnancy test. She had conceived spontaneously with no history of any medical or surgical comorbidities. Her obstetric ultrasonography report revealed a gestational age of 7.6 weeks. Three days later she came in contact with a symptomatic COVID-19 positive patient and hence was immediately tested for SARS-CoV-2 in the nasopharyngeal swab by RT-PCR. The throat swab was positive for ORF1b gene of SARS-CoV-2 with a Ct value of 28 (Table I). She was asymptomatic and hence was quarantined for 10 days at a local hospital. She was discharged with further advice of home quarantine for next 7 days. She remained asymptomatic throughout this period.

Five weeks after the first ultrasound (expected 13 weeks of gestation), she reported for antenatal care where she was advised routine blood investigations along with ultrasonography for nuchal translucency. The ultrasound evaluation showed hydrops fetalis along with fetal demise. Since there was fetal demise, the products of conception were sent for further routine evaluation and SARS-CoV-2 testing. The repeat throat swab taken on the day prior of dilation and curettage was negative for SARS-CoV-2 (Table I).

**Table 1** RT-PCR for SARS-CoV-2 in the nasopharyngeal swabs, placenta and amniotic fluid from a pregnant woman with asymptomatic COVID-19 in first trimester.

Tissue	Gene tested	Ct value	Result	Load
Maternal nasopharyngeal swab (I)	ORF1b	28	Positive	Moderate
Maternal nasopharyngeal swab (II)	ORF1b	ND	Negative	Absent
Placental tissue transport medium	E gene	28.4	Positive	Moderate
	RdRp	27.5		
Placenta	E gene	34.0	Positive	Mild to moderate
	N gene	38.26		
Amniotic fluid	E gene	26.3	Positive	Moderate
	RdRp	25.4		
Negative control	E gene	ND	Negative	Absent
	N gene	ND		
	ORF1b	ND		
	RdRp	ND		

Maternal nasopharyngeal swab (I) is maternal swab collected at 8 weeks of gestation during active infection. Maternal nasopharyngeal swab (II) is nasopharyngeal swab collected at 13 weeks of gestation at the time of abortion. Placental tissue transport medium is the viral transport medium in which the placental villi were incubated overnight. Negative control is from the kit. Loads are interpreted as per kit standards. ND is below detectable range. Ct values are cycle threshold value for each sample.

### First trimester SARS-CoV-2 infection is associated with hydrops fetalis and fetal demise

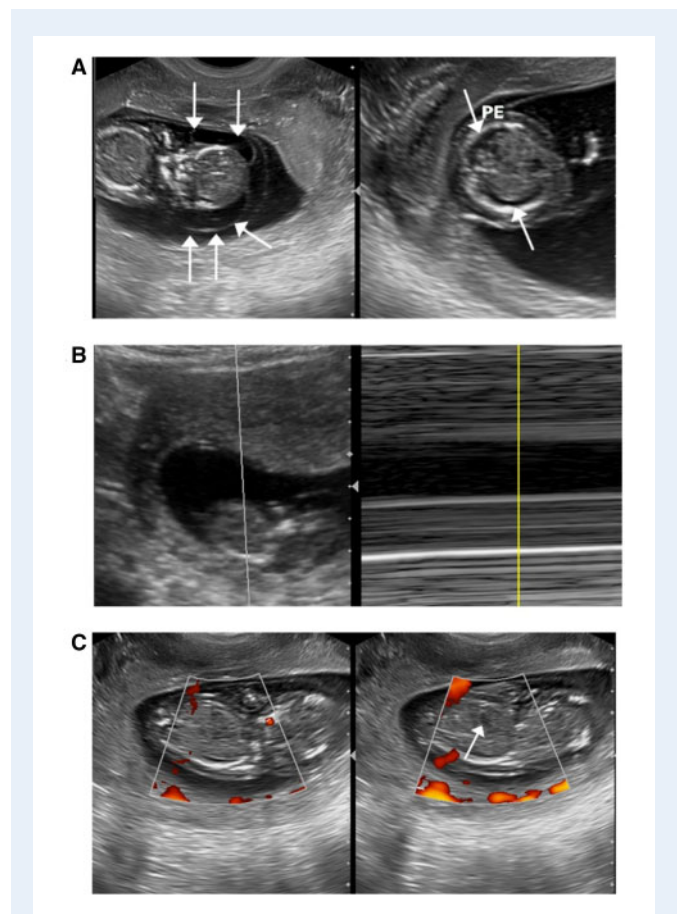
At 8 weeks of amenorrhea, ultrasonography revealed a single live fetus with a crown rump length (CRL) of 14.6 mm corresponding to 7.6 weeks of gestation. Five weeks later, the second ultrasound evaluation revealed a CRL of 38 mm corresponding to 10.5 weeks of gestation (Fig. 1). There was extensive bilateral pleural effusion and subcutaneous edema suggestive of hydrops fetalis (Fig. 1). There was no cardiac activity or blood flow in the fetal heart suggestive of fetal demise (Fig. 1).

### Serum antiphospholipid, anti-nuclear and anticardiolipin, TORCH screening and chromosomal aneuploidies in placenta

Her blood group was O +ve ruling out possibility of autoimmune cause of hydrops. Fluorescence *in situ* hybridization of placental villi showed disomy for 13, 18, 21, and X chromosomes ruling out possibility of major chromosome aneuploidies causing hydrops fetalis (not shown). Serum testing revealed that she was negative for antiphospholipid, anti-nuclear and anticardiolipin antibodies. She was also negative for IgM antibodies of TORCH which indicated absence of active infection. However, she was positive for IgG antibodies against *Toxoplasma gondii*, Rubella, Cytomegalovirus and Herpes simplex virus 1 (Supplementary Table S1) suggestive of past infection.

### Presence of SARS-CoV-2 in placental cells

RNA for both E gene and RdRp gene of SARS-CoV-2 were detected in the supernatants of placental villi incubated in virus transport medium. The Ct value for E gene was 28.4 and RdRp gene was 27.5, suggestive of moderate viral load (Table 1). In the total RNA from placental villi, the E and the N genes of SARS-CoV-2 were detected at



**Figure 1.** Transabdominal ultrasound at 13 weeks of amenorrhea showing hydrops fetalis and demise in a pregnant woman who was positive for SARS-CoV-2 at 8 weeks of gestation. (A) Extensive subcutaneous edema (white arrows) and pleural effusion (PE). (B) Images showing absent cardiac activity. (C) Absence of blood flow in the fetal heart (arrow).

Ct values of 34.0 and 38.2, respectively suggestive of low to moderate viral carriage (Table I). To localize SARS-CoV-2 in placental cells we carried out immunofluorescence using monoclonal antibodies against the spike protein S1 and S2 on placental sections (Fig. 2). Both, S1 and S2 proteins were diffusely localized mainly in the cytoplasm of syncytiotrophoblast and some cytotrophoblast cells. Some villus stromal cells were also positive for both the proteins. In some syncytiotrophoblast cells, S2 was also found as aggregates (Fig. 2).

### Histopathology of the placenta

Placental histopathology (Fig. 3) revealed conspicuously avascular villi with extensive perivascular fibrin deposition. The intervillous area had large numbers of stromal cells and extensive vacuolation. In some areas, the syncytiotrophoblast layer appeared lysed. The decidua also had extensive fibrin deposition and large dilated blood vessels engorged with blood. There were signs of widespread inflammation as evident by presence of large numbers of leukocytes including the polymorphonuclear leukocytes in the decidual bed as well as in the intervillous spaces. A comparative assessment of the histological features of first trimester feto-maternal interface and that observed in the present case is shown in Supplementary Table SII).

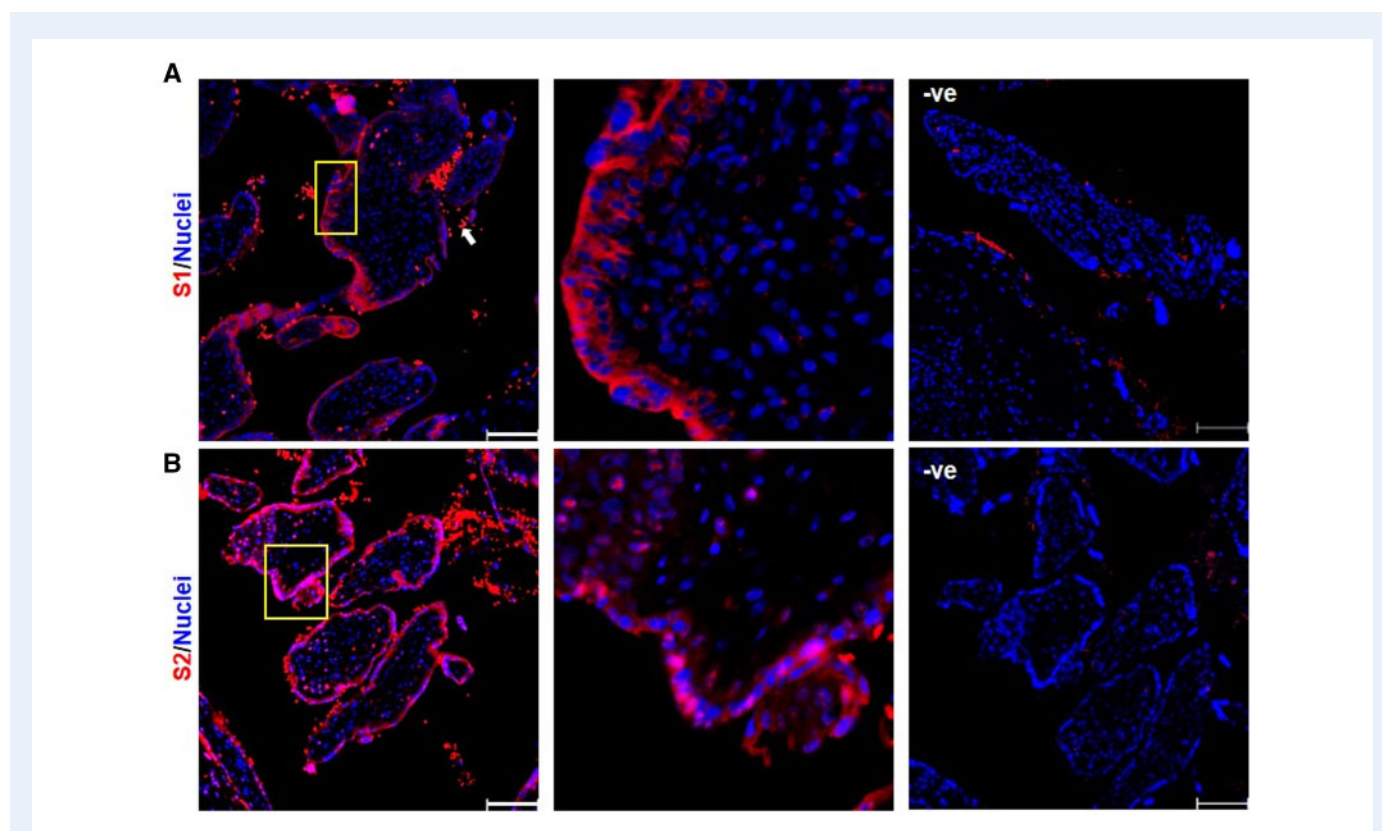
### Presence of SARS-CoV-2 virus in amniotic fluid and fetal membranes

To test if SARS-CoV-2 crosses the placental barrier, we carried out RT-PCR for viral RNA in the amniotic fluid and immunofluorescence of spike proteins in fetal membrane. In the amniotic fluid aspirate, the Ct value for the E gene was 26.3 and the RdRp gene 25.4 (Table I). By immunofluorescence, the viral S proteins were also detected in cells of fetal membrane where both S1 and S2 were diffusely localized in cytoplasm (Fig. 4).

### Discussion

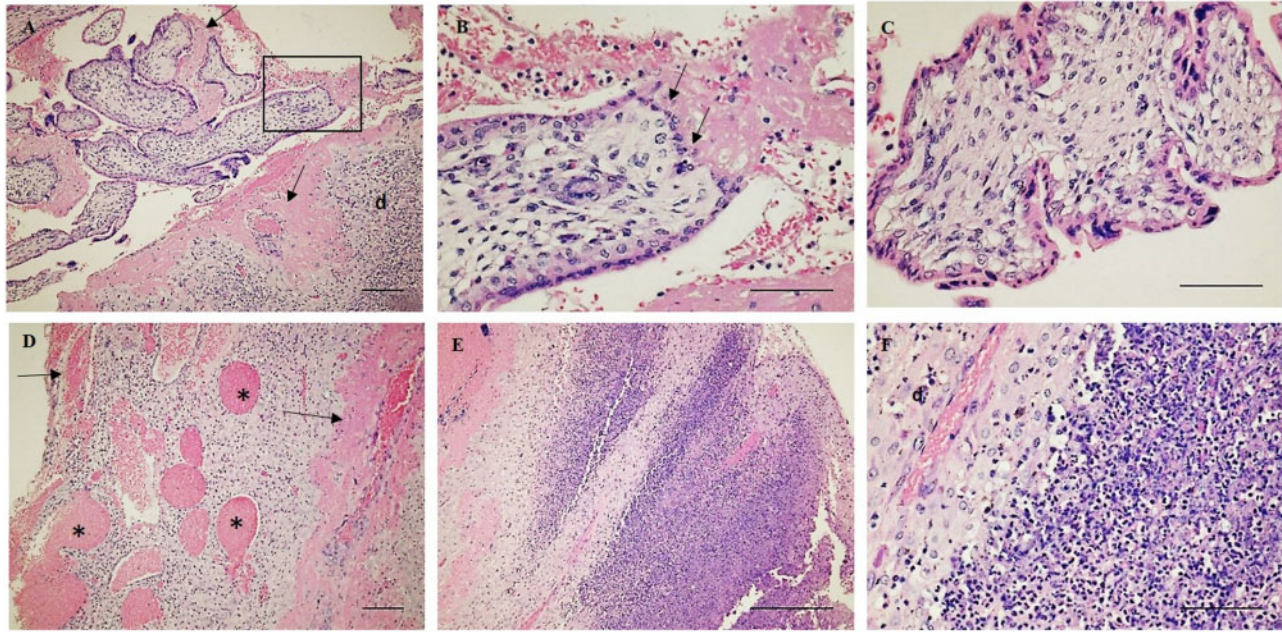
To our knowledge, this is the first case demonstrating persistence of SARS-CoV-2 in the placenta from an asymptomatic mother in the first trimester. This was associated with hydrops fetalis and fetal demise. The study also provides evidence for transmission of the virus from the placenta in to the amniotic fluid and fetal membrane.

Prior studies have shown the presence of viral RNA in tissues during the clinical course of active COVID-19 infection. Herein, we show that while the mother was negative for SARS-CoV-2 in the pulmonary passage, extensive viremia was observed in the placenta. SARS-CoV-2



**Figure 2.** Localization of spike proteins of SARS-CoV-2 in villi of first trimester placenta of a women with asymptomatic COVID-19 at 8 weeks of gestation. Paraffin sections were immunostained for spike proteins S1 (A) and S2 (B) of SARS-CoV-2 using monoclonal antibodies. Boxed area is enlarged in the next panel to show the specific cell types. Negative are sections of same tissues incubated without primary antibody. In all the sections the red staining in the inter villus spaces is autofluorescence of red blood cells. Scale bar represents 100  $\mu$ m.





**Figure 3. Histopathology of placenta and decidual tissue from a woman with asymptomatic SARS-CoV-2 infection in first trimester.** (A–C) Placental villi and D–F is the decidual tissue stained with hematoxylin and eosin. (A) Lower magnification image showing fibrin deposition (arrow) in the intervillous space and decidua (d). Boxed area is enlarged in (B) showing lysis of syncytiotrophoblast cells in the villi (arrow), leukocyte infiltration in intervillous spaces and fibrin deposition. (C) Vacuolated avascular villi with vacuolated cells in the villus stroma. (D) Low magnification image showing dilated blood vessels (\*) in the decidua and fibrin deposition (arrow). (E) Infiltration of immune cells in the decidual tissues. (F) Higher magnification of E showing leukocytes in the decidual bed (d). In all the images scale bar represents 100  $\mu\text{m}$ .

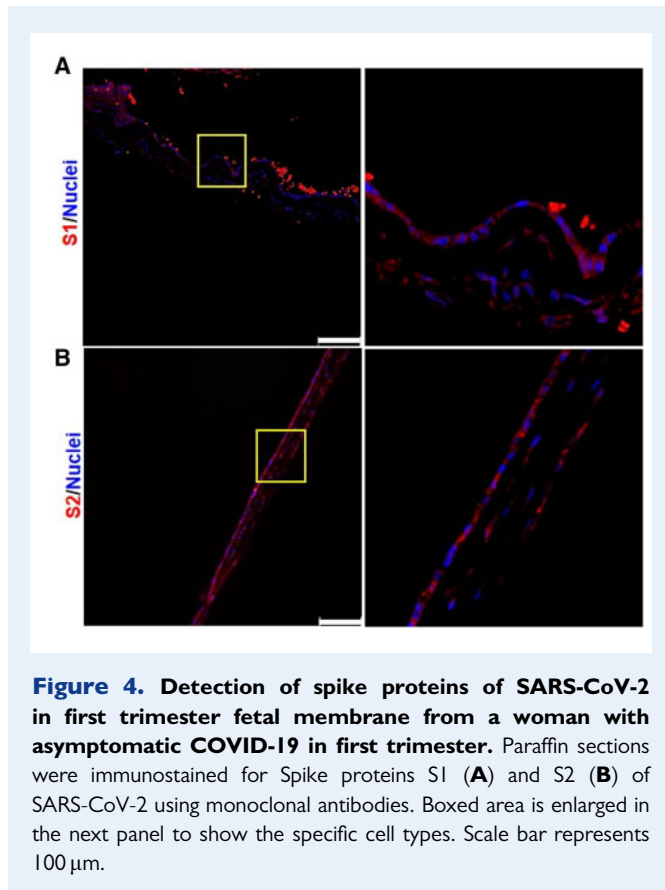
RNA was detected in the supernatant of viral transport medium containing the placental villi and also in total RNA extracted from placenta. Along with viral RNA, the viral proteins could be readily detected in the cytotrophoblasts, syncytiotrophoblast and some villus stromal cells. Although, a lag in systemic viremia and placental infection is known, in the present study, the woman was detected positive for SARS-CoV-2 in the respiratory tract at 8 weeks of gestation, the placenta was positive 5 weeks later. At this time, her throat swab was negative for the virus. These results imply that the virus persisted in the placental tissue weeks after it was cleared from the pulmonary passage.

Earlier studies have shown that intracellular detection of SARS-CoV spike proteins is indicative of viral replication and budding within the cells (Stertz *et al.*, 2007). Herein, we observed that the SARS-CoV-2 spike proteins are detected in the cytoplasm of the cytotrophoblasts, syncytiotrophoblast and some stromal cells of the first trimester villi weeks after the pulmonary infection was cleared. In women with active COVID-19 in the third trimester, the spike proteins are localized in cytoplasm of the placental cells (Taglauer *et al.*, 2020). These results together tempt us to suggest that the virus not only infects but also replicates in the placenta. Indeed, by analyzing single-cell RNAseq data, we have shown that the ACE2 positive placental cells express mRNA for proteins involved in viral budding and replication (Ashary *et al.*, 2020). While it will be of interest to detect subgenomic

RNA to study viral replication dynamics in the placental cells, we did detect the presence of E and N gene of SARS-CoV-2 in the RNA extracted from the placenta suggestive of viral replication. Thus, we propose that the placenta is a permissive site for SARS-CoV-2 replication and to the best of our knowledge this is the first study demonstrating such long-term presence of the virus in any tissues post clearance from the pulmonary sites.

The viremia of the placental cells was further coupled with extensive inflammation as deduced by leukocyte infiltration in the intervillous spaces and decidua, fibrin deposition and lysis of syncytiotrophoblast of the villus cells. Inflammatory changes and fetal vascular malperfusion or fetal vascular thrombosis are reported in second and term placental tissues obtained from mothers infected with COVID-19 and exhibiting active viremia (Baergen and Heller, 2020; Hosier *et al.*, 2020; Shanes *et al.*, 2020; Vivanti *et al.*, 2020). These observations imply that SARS-CoV-2 does not just reside in placental cells but also elicits an inflammatory response. This is not surprising as ACE2 positive cells in the placenta abundantly expressed genes in the Toll-like receptor pathway and were also enriched for components of the other pathways that drive inflammation (Ashary *et al.*, 2020).

How the pulmonary virus reaches extrapulmonary sites such as the placenta is an enigma. Although coronaviruses usually infect the respiratory tract, viral shedding in blood circulation is known and circulating lymphocytes are also known to be infected by SARS-CoV-2



**Figure 4.** Detection of spike proteins of SARS-CoV-2 in first trimester fetal membrane from a woman with asymptomatic COVID-19 in first trimester. Paraffin sections were immunostained for Spike proteins S1 (A) and S2 (B) of SARS-CoV-2 using monoclonal antibodies. Boxed area is enlarged in the next panel to show the specific cell types. Scale bar represents 100  $\mu$ m.

(Zhang et al., 2020; Zhurakivska et al., 2020). Peripheral blood viremia was not investigated in the present case, although it would be a rare event in mild/asymptomatic diseases, it is possible that the virus spread through the systemic route to reach the placenta. Further studies are needed to investigate this idea.

Once the virus reaches the feto-maternal interface and infects the placental cells, it may be able to break the barrier to cause congenital infections. Epidemiological evidence suggests a low possibility of mother to child transmission of SARS-CoV-2 (Allotey et al., 2020; Gajbhiye et al., 2020). However, these are classified only as probable cases as the virus in the newborn was detected hours or even days after birth (Gajbhiye et al., 2020). Recently, a case of transplacental transmission of SARS-CoV-2 in a neonate born to a mother infected at term was reported (Vivanti et al., 2020). In the present case, we observed congenital transmission of SARS-CoV-2 in the first trimester as we not only detected the virus in the placental cells but also in the amniotic fluid and the fetal membrane *in utero*. However, we were unable to establish if the fetus was also infected because no fetal tissue was available for autopsy and study of the virus particles. Nevertheless, as fetal tissues like the liver, heart, lungs and hematopoietic cells also express ACE2, the presence of the virus in the amniotic fluid would make the fetal infection likely (Li et al., 2020a). It will be of interest to investigate various fetal tissues that may get infected with the virus and contribute to fetal hydrops as seen in the present case.

The transplacental transmission of the virus in the present case was also associated with gross fetal hydrops and demise. Immune hydrops

fetalis is most often a complication of Rh incompatibility where the mother is Rh negative and an immune reaction could trigger fetal hydrops. However, in this case, the mother was Rh positive ruling out immune hydrops fetalis. A number of chromosome abnormalities are associated with nonimmune hydrops fetalis (Norton et al., 2015; Kosinski et al., 2020). In the present case, the placenta was disomic for chromosomes 13, 18, 21, and X ruling out these factors in etiology of hydrops; although other rare genetic causes of hydrops are not ruled out. Vertical transmission of many types of virus is known to cause fetal hydrops; however, no such association has been reported for coronaviruses. In our case the mother was negative for IgM of herpes simplex virus and *Toxoplasma gondii*, ruling out active infection with these organisms. She was also negative for antiphospholipid, anti-nuclear and anticardiolipin antibodies which are associated with spontaneous abortions. Thus, it appears that SARS-CoV-2 infection is the most likely cause of fetal hydrops and fetal demise in the present case.

## Conclusion

This is the first study to provide evidence of persistent tissue infection of SARS-CoV-2 and its congenital transplacental transmission in early pregnancy associated with hydrops fetalis and fetal demise. Further studies are required to throw more light on vertical transmission of SARS-CoV-2 infection in first trimester so that universal screening of all pregnant women can be considered in such cases to avoid adverse fetal outcome.

## Data availability

The associated data is made available in the manuscript.

## Acknowledgements

We are thankful to Dr Vidhyadhar Suryakar (Consultant Radiologist ESIC Hospital) and Dr Samir Patel (Consultant Radiologist, Shubh Diagnostic Center) for providing critical opinion on the ultrasound data. The manuscript bears NIRRH ID RA/956/08-2020 and is a part of National Registry of Pregnant Women with COVID-19 in India (PregCovid Registry) <https://pregcovid.com/>.

## Authors' roles

P.S., P.G. and P.U. were involved in, case identification, diagnosis, clinical workup and patient management. M.G. did the clinical laboratory investigations and interpreted the data. V.P., S.B. and V.B. were involved in SARS-CoV-2 RT-PCR. A.B. and D.M. performed the histopathology and immunofluorescence and interpreted the data. R.G. and S.M. coordinate the work and helped in data analysis. P.S., R.G., D.M. and A.B. wrote the first draft. D.M., S.M., R.G., A.B. and P.G. edited the drafts. All the authors approved the final version of the manuscript.

## Funding

D.M. and A.B. are thankful to Science and Engineering Research Board (SERB), Department of Science and Technology, Govt of India for the

IMPRINT IIC grant (IMP/2019/000115/HT). R.G. is an awardee of the DBT Wellcome India alliance clinical and public health intermediate fellowship (IA/CPHI/18/1/503933). The authors are thankful to Indian Council of Medical Research (ICMR), Govt of India for financial support.

## Conflict of interest

The authors declare no conflict of interest.

## References

- Allotey J, Stallings E, Bonet M, Yap M, Chatterjee S, Kew T, Debenham L, Llavall AC, Dixit A, Zhou D *et al.* Clinical manifestations, risk factors, and maternal and perinatal outcomes of coronavirus disease 2019 in pregnancy: living systematic review and meta-analysis. *BMJ* 2020;**370**:m3320.
- Ashary N, Bhide A, Chakraborty P, Colaco S, Mishra A, Chhabria K, Jolly MK, Modi D. Single-cell RNA-seq identifies cell subsets in human placenta that highly expresses factors driving pathogenesis of SARS-CoV-2. *Front Cell Dev Biol* 2020;**8**:783.
- Baergen RN, Heller DS. Placental pathology in Covid-19 positive mothers: preliminary findings. *Pediatr Dev Pathol* 2020;**23**:177–180.
- Best Rocha A, Stroberg E, Barton LM, Duval EJ, Mukhopadhyay S, Yarid N, Caza T, Wilson JD, Kenan DJ, Kuperman M *et al.* Detection of SARS-CoV-2 in formalin-fixed paraffin-embedded tissue sections using commercially available reagents. *Lab Invest* 2020;**100**:1485–1489.
- Bradley BT, Maioli H, Johnston R, Chaudhry I, Fink SL, Xu H, Najafian B, Deutsch G, Lacy JM, Williams T *et al.* Histopathology and ultrastructural findings of fatal COVID-19 infections in Washington State: a case series. *Lancet* 2020;**396**:320–332.
- Chandrashekar A, Liu J, Martinot AJ, McMahan K, Mercado NB, Peter L, Tostanoski LH, Yu J, Maliga Z, Nekorchuk M *et al.* SARS-CoV-2 infection protects against rechallenge in rhesus macaques. *Science* 2020;**369**:eabc4776.
- Colaco S, Chhabria K, Singh N, Bhide A, Singh D, Singh A, Husein A, Mishra A, Sharma R, Ashary N *et al.* Expression of SARS-CoV-2 receptor ACE2 and the spike protein processing enzymes in developing human embryos. ; arXiv 2020; arXiv:2004.04935v2.
- Costa S, Posteraro B, Marchetti S, Tamburrini E, Carducci B, Lanzone A, Valentini P, Buonsenso D, Sanguinetti M, Vento G *et al.* Excretion of SARS-CoV-2 in human breast milk. *Clin Microbiol Infect* 2020;**26**:1430–1432.
- Gajbhiye R, Modi D, Mahale S. Pregnancy outcomes, newborn complications and maternal-fetal transmission of SARS-CoV-2 in women with COVID-19: a systematic review. medRxiv 2020; 2020.04.11.20062356.
- Godbole G, Suman P, Malik A, Galvankar M, Joshi N, Fazleabas A, Gupta SKS, Modi D. Decrease in expression of HOXA10 in the decidua after embryo implantation promotes trophoblast invasion. *Endocrinology* 2017;**158**:2618–2633.
- Gupta S, Parker J, Smits S, Underwood J, Dolwani S. Persistent viral shedding of SARS-CoV-2 in faeces—a rapid review. *Colorectal Dis* 2020;**22**:611–620.
- Hoffmann M, Kleine-Weber H, Schroeder S, Krüger N, Herrler T, Erichsen S, Schiergens TS, Herrler G, Wu NH, Nitsche A *et al.* SARS-CoV-2 cell entry depends on ACE2 and TMPRSS2 and is blocked by a clinically proven protease inhibitor. *Cell* 2020;**181**:271–210.
- Hosier H, Farhadian SF, Morotti RA, Deshmukh U, Lu-Culligan A, Campbell KH, Yasumoto Y, Vogels CBBF, Casanovas-Massana A, Vijayakumar P *et al.* SARS-CoV-2 infection of the placenta. *J Clin Invest* 2020;**130**:4947–4953.
- Jagtap D, Sk C, Mahale S, Patel V. Modelling and docking of Indian SARS-CoV-2 spike protein I with ACE2: implications for comorbidity and therapeutic intervention. 2020; arXiv:2004.06361v1.
- Kosinski P, Krajewski P, Wielgos M, Jezela-Stanek A. Nonimmune hydrops fetalis—prenatal diagnosis, genetic investigation, outcomes and literature review. *J Clin Med* 2020;**9**:1789.
- Li M, Chen L, Zhang J, Xiong C, Li X. The SARS-CoV-2 receptor ACE2 expression of maternal-fetal interface and fetal organs by single-cell transcriptome study. *PLoS One* 2020a;**15**:e0230295.
- Li Y, Zhao R, Zheng S, Chen X, Wang J, Sheng X, Zhou J, Cai H, Fang Q, Yu F *et al.* Lack of vertical transmission of severe acute respiratory syndrome coronavirus 2, China. *Emerg Infect Dis* 2020b;**26**:1335–1336.
- Masmejan S, Pomar L, Favre G, Panchaud A, Giannoni E, Greub G, Baud D. Vertical transmission and materno-fetal outcomes in 13 patients with coronavirus disease 2019. *Clin Microbiol Infect* 2020;**26**:1585–1587.
- Modi DN, Sane S, Bhartiya D. Accelerated germ cell apoptosis in sex chromosome aneuploid fetal human gonads. *Mol Hum Reprod* 2003;**9**:219–225.
- Norton ME, Chauhan SP, Dashe JS. Society for maternal-fetal medicine (SMFM) clinical guideline #7: nonimmune hydrops fetalis. *Am J Obstet Gynecol* 2015;**212**:127–139.
- Parker EL, Silverstein RB, Verma S, Mysorekar IU. Viral-immune cell interactions at the maternal-fetal interface in human pregnancy. *Front Immunol* 2020;**11**:522047.
- Shanes ED, Mithal LB, Otero S, Azad HA, Miller ES, Goldstein JA. Placental pathology in COVID-19. *Am J Clin Pathol* 2020;**154**:23–32.
- Shende P, Gaikwad P, Gandhewar M, Ukey P, Bhide A, Patel V, Bhagat S, Bhor V, Mahale S, Gajbhiye R *et al.* Persistence of SARS-CoV-2 in the first trimester placenta leading to vertical transmission and fetal demise from an asymptomatic mother. medRxiv 2020;2020.08.18.20177121. Available from: <https://doi.org/10.1101/2020.08.18.20177121>.
- Singh M, Bansal V, Feschotte C. A single-cell RNA expression map of human coronavirus entry factors. *Cell Rep* 2020;**32**:108175.
- Stertz S, Reichelt M, Spiegel M, Kuri T, Martínez-Sobrido L, García-Sastre A, Weber F, Kochs G. The intracellular sites of early replication and budding of SARS-coronavirus. *Virology* 2007;**361**:304–315.
- Taglauer E, Benarroch Y, Rop K, Barnett E, Sabharwal V, Yarrington C, Wachman EM. Consistent localization of SARS-CoV-2 spike glycoprotein and ACE2 over TMPRSS2 predominance in placental villi of 15 COVID-19 positive maternal-fetal dyads. *Placenta* 2020;**100**:69–74.
- Vivanti AJ, Vauloup-Fellous C, Prevot S, Zupan V, Suffee C, Cao J, Do Benachi A, Luca D. De Transplacental transmission of SARS-CoV-2 infection. *Nat Commun* 2020;**11**:7.



- Waghmare R, Gajbhiye R, Mahajan N, Modi D, Mukherjee S, Mahale S. Universal screening identifies asymptomatic carriers of SARS-CoV-2 among pregnant women in India. *Eur J Obstet Gynecol Reprod Biol* 2021;256:503–505.
- Wu Y, Guo C, Tang L, Hong Z, Zhou J, Dong X, Yin H, Xiao Q, Tang Y, Qu X et al. Prolonged presence of SARS-CoV-2 viral RNA in faecal samples. *Lancet Gastroenterol Hepatol* 2020;5:434–435.
- Yao XH, He ZC, Li TY, Zhang HR, Wang Y, Mou H, Guo Q, Yu SC, Ding Y, Liu X et al. Pathological evidence for residual SARS-CoV-2 in pulmonary tissues of a ready-for-discharge patient. *Cell Res* 2020;30:541–543.
- Zhang Y, Geng X, Tan Y, Li Q, Xu C, Xu J, Hao L, Zeng Z, Luo X, Liu F et al. New understanding of the damage of SARS-CoV-2 infection outside the respiratory system. *Biomed Pharmacother* 2020;127:110195.
- Zhurakivska K, Troiano G, Pannone G, Caponio VCA, L Lo M. An overview of the temporal shedding of SARS-CoV-2 RNA in clinical specimens. *Front Public Health* 2020;8:487.