

# Phantom Limbs and Neural Plasticity

Vilayanur S. Ramachandran, MD, PhD; Diane Rogers-Ramachandran, PhD

**T**he study of phantom limbs has received tremendous impetus from recent studies linking changes in cortical topography with perceptual experience. Systematic psychophysical testing and functional imaging studies on patients with phantom limbs provide 2 unique opportunities. First, they allow us to demonstrate neural plasticity in the adult human brain. Second, by tracking perceptual changes (such as referred sensations) and changes in cortical topography in individual patients, we can begin to explore how the activity of sensory maps gives rise to conscious experience. Finally, phantom limbs also allow us to explore intersensory effects and the manner in which the brain constructs and updates a “body image” throughout life.

*Arch Neurol.* 2000;57:317-320

The phenomenon of phantom limbs has been known since antiquity and has always been shrouded in mystery. After Lord Nelson lost his right arm during an attack on Santa Cruz de Tenerife, he experienced compelling phantom limb pain, including the strange sensation of fingers digging into his phantom palm. The emergence of these ghostly sensations led the Sea Lord to proclaim that he now had “direct proof” for the existence of the soul. For if an arm can survive physical annihilation, why not the whole person?

The first clear clinical description of phantom limbs was by Silas Weir Mitchell in 1872<sup>1</sup> (see review by Melzack<sup>2</sup>). Although there have been hundreds of case studies since that time, systematic experimental work began only 7 years ago,<sup>3,4</sup> inspired in part by the demonstration of striking changes in somatotopic maps following deafferentation.<sup>5,6</sup> Pons et al<sup>7</sup> demonstrated that 11 years after dorsal rhizotomy in adult monkeys, the region corresponding to the hand in the cortical somatotopic map, area 3b, can be activated by stimuli delivered to the monkey's ipsilateral face—direct evidence that a massive reorganization of topography had occurred in area 3b. That a similar reorganization occurs in the adult human

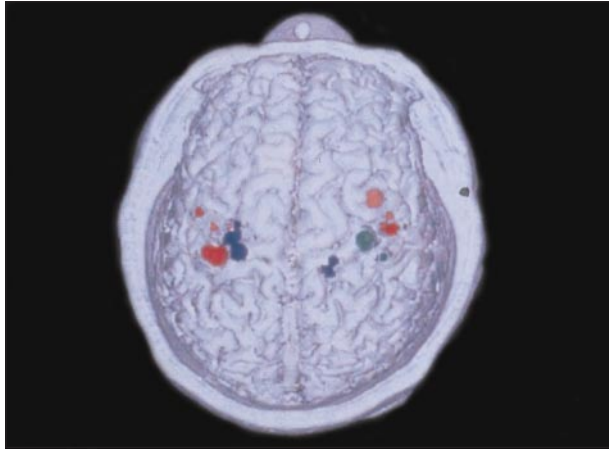
cortex over distances of 2 to 3 cm was first shown by our group using magnetoencephalography (**Figure 1**).<sup>3,8-10</sup> After amputation of an arm, sensory input from the face begins to activate the hand area of the Penfield homunculus in cortical area S1.

Given this massive reorganization, what would the person feel if his face were touched? Since the stimulus now activates the hand area of the cortex, would the person feel that he was being touched on his hand as well?

## REFERRED SENSATIONS IN PHANTOM LIMBS

We tested 18 patients with either arm amputation or brachial avulsion, and found that 8 patients systematically referred sensation from the face to the phantom limb.<sup>3,4</sup> In many of them, there was a topographically organized map of the hand on the lower face region (**Figure 2**) and the referred sensations were modality specific. For example, hot, cold, vibration, rubbing, metal, or massage are felt as hot, cold, vibration, rubbing, metal, and massage at precisely localized points on the phantom limb.<sup>3,11</sup> Points on other parts of the body were usually ineffective in eliciting referred sensations in the phantom limb, but there was often a second topographically organized map proximal to the am-

*From the Center for Brain and Cognition, University of California, San Diego, La Jolla.*



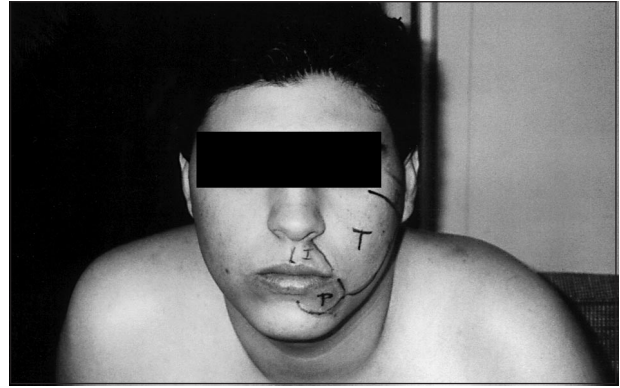
**Figure 1.** Changes in cortical topography in S1 revealed by magnetoencephalography. Top view of combined magnetoencephalography and 3-dimensional surface-rendered magnetic resonance image from an adult whose left arm was amputated below the elbow. Red indicates face; green, hand; and blue, upper arm. Notice that the hand area (green) is missing from the right hemisphere and is now being activated by sensory input from the flanking face region and upper arm.<sup>3,9</sup>

putation stump. Since the hand area in the Penfield map is flanked on one side by the upper arm and the other side by the face, this is precisely the arrangement of points that one would expect if the afferents from the upper arm skin and face skin were to invade the hand territory from either side.

The fact that stimulating certain trigger points near the stump,<sup>12</sup> or sometimes remote from the stump, can elicit referred sensation in the phantom limb has been noted before in the older clinical literature, but the occurrence of a topographically organized map on the face and modality-specific referral from face to phantom limb has not been described. Consequently, no attempt was made to relate these findings to somatotopic brain maps, and the referred sensations were often attributed either to stump neuromas or to activation of a “diffuse neural matrix.”<sup>13</sup> Our results suggest, instead, that referred sensations emerge as a direct consequence of the changes in topography following deafferentation—an idea that we refer to as “the remapping hypothesis.”<sup>3</sup>

Based on the remapping hypothesis, we also predicted<sup>14</sup> that after trigeminal nerve section, one should observe a map of the face on the hand, and this has been confirmed in a study by Clarke et al.<sup>15</sup> Also, after amputation of the index finger in one patient, a map of the index finger was found neatly draped across the ipsilateral cheek.<sup>16</sup> Finally, our suggestion that these effects are based partly on unmasking of preexisting connections<sup>3</sup> rather than sprouting receives support from our recent observation that modality-specific referral from the face to the phantom limb can occur even a few hours after amputation.<sup>17</sup>

Taken collectively, these findings provide strong support for the remapping hypothesis. They may allow us to track the time course of perceptual changes in humans and relate these in a systematic way to anatomy. The occurrence of topography and modality specificity rules out any possibility of the referral being due to non-specific arousal.



**Figure 2.** Points on the face of a patient that elicit precisely localized, modality-specific referral in the phantom limb 4 weeks after amputation of the left arm below the elbow. Sensations were felt simultaneously on the face and phantom limb.

Finally, we predicted<sup>14</sup> that if the remapping were at least partly cortical (rather than thalamic), then after deafferentation caused by central white matter lesions, one should observe sensations by referral from normal skin areas to the deafferented zones. For instance, if a stroke produces partial sensory loss, touching the spared “islands” of normal skin should evoke sensations referred to the deafferented regions. We have recently seen at least one patient in whom this prediction was confirmed. He had a left cerebrovascular accident and clearly referred sensations from normal skin to the deafferented zones on his right arm. Referral usually occurred from the adjacent normal skin but also occasionally from the ipsilateral leg (Eric Altschuler, MD, and V.S.R., unpublished observations, 1998). The reason for this is obscure but may be related to the fact that in S2 cortex, the foot representation is right next to the arm<sup>7</sup> and deafferentation of cortex corresponding to the arm in S1 may lead to a reorganization in S2 so that leg stimulation begins to activate arm cortex. These conjectures are important because they would imply that reorganization can occur even in the adult human cortex analogous to what is seen after S1 lesions in monkeys or after limb amputation in humans.

## SYNESTHESIA

Some patients claim that they can experience vivid voluntary movements<sup>2</sup> in their phantom limb, presumably because reafference signals from motor commands sent to the phantom limb are monitored in the cerebellum and parietal lobes. However, over time, the phantom limb becomes “frozen” or “paralyzed,” perhaps because of a continuous absence of visual and proprioceptive confirmation that the commands have been obeyed. Some patients experience excruciatingly painful involuntary clenching spasms in the phantom limb; they experience their nails digging into their phantom palm and are unable to open the hand voluntarily to relieve the pain.

In our studies, we placed a midvertical sagittal mirror on the table in front of the patient. If the patient's paralyzed phantom limb was, say, on the left side of the mirror, he placed his right hand in an exact mirror-symmetric location on the right side of the mirror (**Figure 3**). If he looked into the shiny right side of the

mirror, the reflection of his own right hand is optically superimposed on the felt location of his phantom limb so that he has the distinct visual illusion that the phantom limb had been resurrected. If he now made mirror-symmetric movements while looking in the mirror, he received visual feedback that the phantom limb was obeying his command.

Remarkably, 6 of 10 patients using this procedure claimed that they could now actually feel—not merely see—movements emerging in the phantom limb. This was often a source of considerable surprise and delight to the patient.<sup>18</sup>

Indeed, 4 patients were able to use the visual feedback provided to them by the mirror to “unclench” a painfully clenched phantom hand and this seemed to relieve the clenching spasm, as well as associated cramping pain (the burning and lancinating pains in the phantom limb remained unaffected by the mirror procedure, suggesting that the relief of the clenching was probably not confabulatory in origin). The elimination of the spasm is a robust effect that was confirmed in several patients. Patients reported the elimination of the associated pain but this requires confirmation with double-blind control subjects, given the notorious susceptibility of pain to placebo and suggestion. In one patient, repeated use with the mirror for 2 weeks resulted in a permanent and complete disappearance of the phantom arm and elbow (and a “telescoping” of fingers into the stump) for the first time in 10 years. The associated pain in the elbow and wrist also vanished. This may be the first known instance of a successful amputation of a phantom limb!

#### Visual Feedback for Other Neurological Syndromes?


Other syndromes such as focal dystonia, dyspraxia, and hemiparesis (following strokes) usually result from destruction of neural tissue but is it conceivable that there is a “learned paralysis” component to some of these disorders<sup>14</sup>? If so, can this component caused by a temporary neural inhibition or “block” be overcome by using a mirror? We are currently exploring these possibilities.

#### Reality of Phantom Limbs

We also studied intermanual “interference” in patients with phantom limbs. A person with intact limbs finds it very difficult to tap his head with one hand while making circular movements on his belly simultaneously with the other hand. We now find that if a patient with a “moveable” phantom limb (ie, one he can control volitionally) tries to produce dissimilar movements with his phantom limb and his real arm, he experiences a similar interference. But no interference occurs in a patient with a “paralyzed” phantom limb who simply imagines that he is moving his phantom limb.<sup>19</sup> Thus, the interference must be of cortical origin and is not a result of feedback from the arm.

#### What Use is Plasticity?

Is the remapping that occurs in the adult somatosensory cortex beneficial to the organism? Or is it an “epi-



**Figure 3.** Mirror box used to provide visual feedback. Patient views the reflection of his own hand in the mirror.

phenomenon”—a manifestation, in the adult, of a process that is ordinarily expressed only in early brain development?

Since a larger amount of cortex is now devoted to the region proximal to the stump, would there be an improvement in tactile acuity in these regions? An early study by Teuber et al<sup>20</sup> hinted at this possibility but further experiments are needed to confirm this. It would be especially interesting to see if such an improvement also occurs on the face skin ipsilateral to amputation. It seems likely that such improvement would occur more readily for tactile hyperacuity rather than 2-point discrimination. Also, perhaps such improvement would be seen only after the referred sensations have faded so that sensory stimulation on the face is felt only on the face.

#### PHANTOM LIMBS IN NONAMPUTATED INDIVIDUALS

Phantom limbs are not unique to amputees. Indeed, even in individuals with intact limbs, the body image is highly malleable; one can lengthen one’s nose, or even project one’s sensations onto external objects, such as Halloween masks, tables, and chairs merely by using appropriate patterns of tactile stimulation. For instance, if you watch the experimenter stroking a shoe or a table surface while he simultaneously, in perfect synchrony, strikes and taps your knee hidden from you under the table, you will experience the touch sensations as emerging from the shoe or table. If the experimenter then hits the shoe or table with a hammer, you will register a strong galvanic skin response, as though the object was now part

of your body.<sup>21</sup> But if the shoe (or table) and your hand are stimulated out of synchrony, no illusion occurs and no galvanic skin response is seen (so the response is not just due to startle).

## CONCLUSIONS

The experiments on referred sensations in phantom limbs are important for 2 reasons: First, they suggest that, contrary to the static picture of brain maps provided by neuroanatomists, topography is extremely labile. Even in the adult brain, massive reorganization can occur over extremely short periods, and referred sensations can therefore be used as a “marker” for plasticity in the adult human brain. Second, the findings allow us to relate perceptual qualia (subjective sensations) to the activity of brain maps and to test some of the most widely accepted assumptions of sensory psychology and neurophysiology, such as Müller’s law of specific nerve energies, “pattern coding” vs “place coding” (ie, the notion that perception depends exclusively on which particular neuron fires rather than the overall pattern of activity), and, more generally, to understand how neural activity leads to conscious experience. For instance, after arm amputation, patients usually have dual sensations, ie, sensations are experienced in both the face and the hand, presumably because 2 separate points are activated on the cortical map. But after section of the fifth nerve, the patient felt the sensation only on the face when the hand was touched.<sup>15</sup> Perhaps there is an initial “overshoot” during remapping so that the anomalous input from the hand to the face territory actually comes to dominate perception and masks or suppress the “real” sensation from the hand.

The experiments with mirrors have 3 implications. First, they may be clinically useful in alleviating abnormal postures and spasms in phantom limbs. Indeed, it is not inconceivable that even other neurological syndromes such as focal dystonias, dyspraxias, and hemipareses may be caused, at least in part, by a temporary “inhibition” of sorts and may therefore benefit from visual feedback provided by the mirror. Second, it suggests that the modular, hierarchical, “bucket brigade” model of the brain popularized by computer engineers needs to be replaced by a more dynamic view of the brain in which there is a tremendous amount of back-and-forth interaction between different levels in the hierarchy and across different modules. The fact that the mere visual appearance of the moving phantom limb feeds all the way back from the visual to the somatosensory areas of the brain to relieve a spasm in a nonexistent hand shows how extensive these interactions can be. Third, the resurrection of a long-lost phantom in some patients,<sup>4</sup> and its “amputation” in others, suggest that the body image, despite all its appearance of durability and permanence,

is in fact a purely transitory internal construct, a mere shell that our brain creates temporarily for passing on our genes to the next generation.

Accepted for publication February 19, 1999.

This work was supported by the National Institute of Mental Health, Rockville, Md.

Reprints: Vilayanur S. Ramachandran, MD, PhD, Center for Brain and Cognition, University of California, San Diego, La Jolla, CA, 92093-0109 (e-mail: vramacha@ucsd.edu).

## REFERENCES

1. Weir MS. *Injuries of Nerves and Their Consequences*. Philadelphia, Pa: Lippincott; 1872.
2. Melzack R. Phantom limbs. *Sci Am*. 1992;266:120-126.
3. Ramachandran VS. Behavioral and MEG correlates of neural plasticity in the adult human brain. *Proc Natl Acad Sci U S A*. 1993;90:10413-10420.
4. Ramachandran VS, Hirstein W. The perception of phantom limbs: The D. O. Hebb Lecture. *Brain*. 1998;121:1603-1630.
5. Wall PD. The presence of ineffective synapses and the circumstances which unmask them. *Philos Trans R Soc Lond*. 1977;B278:361-372.
6. Merzenich MM, Nelson RJ, Stryker MS, Cyander MS, Schoppmann A, Zook JM. Somatosensory cortical map changes following digit amputation in adult monkeys. *J Comp Neurol*. 1984;224:591-605.
7. Pons TP, Garraghty PE, Ommaya AK, Kaas JH, Taub E, Mishkin M. Massive reorganization of the primary somatosensory cortex after peripheral sensory deafferentation. *Science*. 1991;252:1857-1860.
8. Ramachandran VS. What neurological syndromes tell us about human nature: some lessons from phantom limbs, Capgras syndrome, and anosognosia. *Cold Spring Harb Symp Quant Biol*. 1996;61:115-134.
9. Yang T, Gallen C, Ramachandran VS, Cobb S, Schwartz BJ, Bloom FE. Noninvasive detection of cerebral plasticity in adult human somatosensory cortex. *Neuroreport*. 1994;5:701-704.
10. Flor H, Elbert T, Knecht S, et al. Phantom limb pain as a perceptual correlate of cortical reorganization following arm amputation. *Nature*. 1995;375:482-484.
11. Halligan PW, Marshall JC, Wade DT. Sensory disorganization and perceptual plasticity after limb amputation: a follow-up study. *Neuroreport*. 1994;5:1341-1345.
12. Cronholm B. Phantom limbs in amputees: a study of changes in the integration of centripetal impulses with special reference to referred sensations. *Acta Psychiatr Neurol Scand Suppl*. 1951;72:1-310.
13. Melzack R. Phantom limbs and the concept of a neuromatrix. *Trends Neurosci*. 1990;13:88-92.
14. Ramachandran VS. Phantom limbs, neglect syndromes, and Freudian psychology. *Int Rev Neurobiol*. 1994;37:291-333.
15. Clarke S, Regli L, Janzer RC, Assal G, de Tribolet N. Phantom face: conscious correlates of neural reorganization after removal of primary sensory neurons. *Neuroreport*. 1996;7:2853-2857.
16. Aglioti SA, Bonazzi A, Cortese F. Phantom lower limb as a perceptual marker for neural plasticity in the mature human brain. *Proc R Soc Lond*. 1994;255:273-278.
17. Borsook B, Becerra L, Fishman S, et al. Acute plasticity in human somatosensory cortex following amputation. *Neuroreport*. 1998;9:1013-1017.
18. Ramachandran VS, Rogers-Ramachandran D. Synaesthesia in phantom limbs induced with mirrors. *Proc R Soc Lond*. 1996;263:377.
19. Franz E, Ramachandran VS. Bimanual coupling in amputees with phantom limbs. *Nat Neurosci*. 1998;1:443-444.
20. Teuber HL, Krieger HP, Bender MB. Reorganization of sensory function in amputation stumps. *Fed Proc*. 1949;8:156.
21. Ramachandran VS, Hirstein W. Three laws of qualia: what neurology tells us about the biological functions of consciousness. *J Conscious Stud*. 1997;4:429-457.