

PICTURE LANGUAGES IN AUTOMATIC RADIOLOGICAL PALM INTERPRETATION

RYSZARD TADEUSIEWICZ, MAREK R. OGIELA

Institute of Automatics, AGH University of Science and Technology
Al. Mickiewicza 30, 30–059 Cracow, Poland
e-mail: {rtad, mogiela}@agh.edu.pl

The paper presents a new technique for cognitive analysis and recognition of pathological wrist bone lesions. This method uses AI techniques and mathematical linguistics allowing us to automatically evaluate the structure of the said bones, based on palm radiological images. Possibilities of computer interpretation of selected images, based on the methodology of automatic medical image understanding, as introduced by the authors, were created owing to the introduction of an original relational description of individual palm bones. This description was built with the use of graph linguistic formalisms already applied in artificial intelligence. The research described in this paper demonstrates that for the needs of palm bone diagnostics, specialist linguistic tools such as expansive graph grammars and EDT-label graphs are particularly well suited. Defining a graph image language adjusted to the specific features of the scientific problem described here permitted a semantic description of correct palm bone structures. It also enabled the interpretation of images showing some in-born lesions, such as additional bones or acquired lesions such as their incorrect junctions resulting from injuries and synostoses.

Keywords: syntactic pattern recognition, image understanding, medical image analysis, computer-aided diagnosis, palm disease diagnostics

1. Introduction

A significant breakthrough in the field of medical IT has brought about the elaboration of new, artificial intelligence-based methods that provide opportunities to conduct an automatic analysis of two- and three-dimensional medical images (Albus and Meystel, 2001; Tadeusiewicz and Ogiela, 2004a). These methods were based on a newly established class of linguistic formalisms, based, in turn, on the terms of ETPL (k)-class graph grammars, EDG and IE graphs, used as a new tool for the description and discovering of important diagnostic features of a broad range of various medical images. The new methodology of automatic understanding of medical images, developed by the authors during the last ten years and described in detail in the book (Tadeusiewicz and Ogiela, 2004a), can be considered as the next step on the way from image processing algorithms (e.g., the contrast enhancement), towards the image analysis (e.g., densitometry) and automatic recognition or classification. The linguistic approach to the description, analysis, classification and understanding of medical images can be practically performed thanks to the development of methods and algorithms of effective syntac-

tic analysers created for such grammar types. The implementation of such techniques brought about important progress such that the application of syntactic recognition methods for medical images became not only possible, but also extremely effective. We use these techniques for the analysis of a wide range of medical images, describing the obtained results in numerous papers (Ogiela and Tadeusiewicz, 2003a; 2003b; 2003c; Tadeusiewicz and Ogiela, 2004b; 2004c).

We discovered syntactic methods of pattern recognition as the most effective method for diagnostic analysis of complex medical images. This is in particular true for those imaging a number of structures at the same time and has significant diagnostic meaning, mainly due to semantic information contained therein. Classical image analysis techniques were strongly limited in this respect and the content-oriented analysis of their semantic meaning was always very difficult, sometimes even impossible (Duda *et al.*, 2001; Meyer-Baese, 2003).

The proposed structural AI intelligence techniques not only enable a perception analysis of many images for diagnostic purposes, but they can also be more and more frequently used to create intelligent medical IT systems, supporting medical diagnosis by means of intelli-

gent searching in big medical databases (Meyer-Baese, 2003). Such systems are dedicated to various meaning and interpretation tasks for numerous medical data types, while their operation is based on the use of advanced AI techniques labelled in general by the term 'soft computing' (Ogiela and Tadeusiewicz, 2003b; Tadeusiewicz and Ogiela, 2004b).

The determination of medical meaning and an image semantic content results mainly from two factors: an expansion of possibilities for medical image analysis offered by traditional techniques, and by obtaining new possibilities of automatic interpretation of images. The new (proposed) methods can be used for image analysis and classification, as well as many other image processing techniques, but they have unique abilities of finding answers to the following questions:

1. What medical conclusions can be drawn from morphological details found in an image?
2. What is the semantic meaning of parameters measured and features found in a given image?
3. What conclusions can be drawn from the fact that the diagnosed objects belong to particular disease units?

The analysis of images conducted in this paper will go in the direction pointed out by the formulated questions. Its objective will be, in particular, to present and evaluate the possibilities of expansive graph grammar application to the recognition and intelligent meaning analysis of wrist ligaments and bone radiogrammes. In the performed research we defined effective syntactic analyser algorithms for graphs describing both cases of morphological elements falling within physiological norms, and for selected cases of diseases showing their symptoms as visible irregularities on analysed radiograms. The purposefulness of cognitive analysis of such structures using computer semantic analysis methods has been dictated, among other things, by the following factors:

1. 2D image analysis of most objects under consideration is more difficult than typical image analysis tasks described by other authors for other problems since in palm images some details are blurred as a result of bones overlapping each other. This may lead to apparent disappearing of some bones, hidden behind other bones, and the algorithm must 'guess' the form of the bone and its relation to other elements in the image.
2. Sometimes one can find additional bones or bone decrements in a palm image, not described *a priori* by anatomical maps. Such phenomena can be caused by joints, falling within physiological norms, and belong to normal individual differences between people.

3. Images can display fractures and displacements, caused by injuries and other pathological processes.

Cognitive analysis of palm images may supply information of diagnostic and therapeutic importance. This is true not only for traumas and diseases in the area of the wrist. Lesions of bone morphology may point to the existence of a number of in-born pathological lesions but they can also suggest acquired disease lesions demonstrating, for example, metabolic disorders. Of course, the above-listed factors can in various combinations contribute to deformations caused by mechanic injuries. Upper limb differential diagnosis allows us also to recognise, and later to treat, a number of soft-tissue diseases. Such cases, however, will not be considered at this stage of research.

The research described in this paper is primarily focused on the analysis of the number of and spatial relations between individual wrist bones. An intelligent interpretation of the analysed cases can enable the identification of lesions such as the occurrence of *os centrale* or other additional wrist bones. It may also point to the lack or lesions in the shape of the scaphoid or capitate bones, as well as their synostoses with other wrist parts. As the development of research and syntactic image recognition techniques progress, analyses will be growingly complex, plus more and more subtle irregularities in their number, structure and mutual location in the wrist will be detected.

2. Structure of the Analyzed Data Set

The analysis of palm structure correctness was based on the examples of about a dozen selected X-ray palm images, obtained both from the palm and dorsal projection.

It should be noted that a complete set of analysed radiogrammes covered initially about 30 real images, of which some presented correct structures (falling within anatomical and physiological norms with respect to their location, mobility and the number of wrist bones) that originated from radiological screening research. Some images were selected since they showed pathologies of interest to us. The latter, at the current stage of conceptual development (but not yet efficiency analysis) of syntactic method analysis of wrist bone pathology were not obtained by the authors but were taken from diagnostic atlases (Burgener and Kormano, 1997). Consequently, a morphology description as well as diagnostic classification for these images could be considered as certain and unquestioned. Moreover, owing to the use of these very examples every reader can check the functioning of the methods proposed by us by referring to the same, known and commonly available data.

We would like to emphasise that the authors are aware of the need to conduct significant verification and

validation of new algorithms on possibly large sets of original data. This is why after preparing and optimising the method described here, wider empirical research will be conducted on its properties and limitations, based on original images from a number of orthopaedic clinics. In the future, analysis results of many concrete examples will make it possible to collect and present credible statistics showing the efficiency of the syntactic analysis method used as a tool for cognitive analysis of the form of medical images considered here. This, however, will take place later and will be the subject of a separate publication, and hence this paper is aimed only at presenting the method proposed by us, and encouraging to try using it, but does not cover its assessment. For this reason the paper contains no analysis of statistical results and the information quoted in it should be treated solely as examples and rough data.

The two described medical image subsets played different roles during examinations whose results are presented in this paper. The correct images constituted material that allowed us to define the necessary linguistic mechanisms in the form of a graph. This constituted a basis for creating an appropriate expansive grammar defining the set of possible wrist bone cases as well as their mutual relations, falling within physiological norms. Owing to the codification of the physiological norm in the form of basic rules of the analysed grammar, syntax analysis of all generated descriptions for new analysed images became a sufficient tool to establish whether the researched case is within the norms accepted and specifying a correct palm image, or whether we are dealing with some form of pathology.

On the other hand, selected cases of pathological images allowed us to add to the generated grammar a set of rules introducing some special patterns of typical morphological irregularities. Owing to the inclusion of these incorrect situations in the categories of additional (going beyond physiology frameworks) grammar rules, it became possible to recognise some additional bones that can occur in X-ray images of an irregular wrist. Grammar analysis of wrist bone morphology enables us also to diagnose and interpret correctly a reduction in their number, for example, as a result of neighbouring bone synostosis. The diagram showing a possible occurrence of additional bones, initially taken into consideration in the research, is shown in Fig. 1. However, due to a large number of such potentially possible irregularities and due to a negligible population fraction registered with the occurrence of some of them, further analysis issues were restricted only to objects marked with grey dots in Fig. 1. Fields marked grey show the most frequent places in which additional bones of the closer series and located between the closer and further wrist series (Burgener and Korman, 1997) cover the

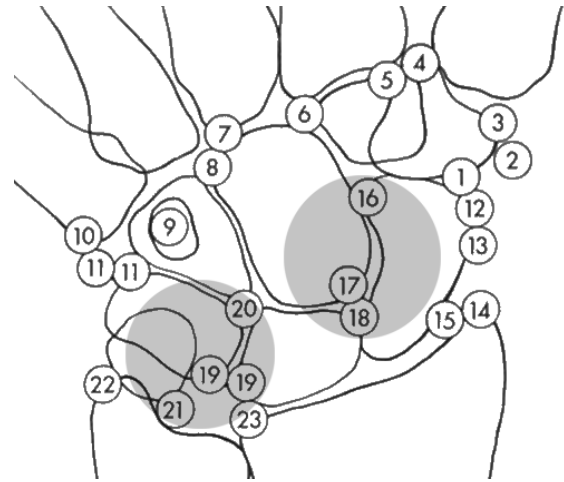


Fig. 1. The location and number of possible additional wrist and palm bones. Grey dots stand for additional bones of palm closer bone series recognisable by the grammar defined in this paper.

set of about 90% of most frequent images of pathologically formed wrists.

Real examples of images showing pathological lesions in the form of wrist bone dislocation, necrosis, and fusion are shown in Fig. 2. Such irregularities are to be detected and interpreted correctly by the syntactic image recognition method described in this paper.

Let us point out here one methodological remark. As was proven during the research process, only a few typical images are enough for establishing all necessary grammar rules. This means that even a small size of the research sample can give a necessary outcome for the initial specification of a certain model pattern, for which image languages have been defined. Such languages, however, enable a generalisation of pattern classification and, as a result, they enable an effective recognition of a practically unlimited number of new cases, similar (in a way) to elements registered during the formation of grammar rules. A correct definition of graphs spanning metacarpal bones and finger bones (phalanx) was made based on EDG-type graphs (Skomorowski, 1998).

All images analysed here were, before their analysis, subjected to pre-processing (Bankman, 2002; Ogiela and Tadeusiewicz, 2003a; Tadeusiewicz and Ogiela, 2004a) aimed to show bone contours of the closer and further palm bone series and their identification (*labelling*) enabling a later search of the spanned graph with a selected width analysis technique. To binarise palm radiogrammes, the method of simple thresholding was used. For more complex cases it was discovered that good results can be achieved by the background elimination method, as described in this paper (Pietka *et al.*, 2001).

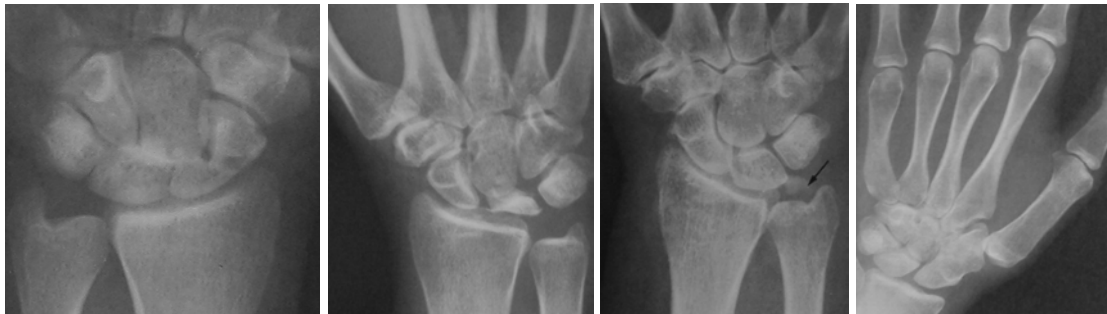

Fig. 2. (a) Image showing lesions in the form of the lunate dislocation. (b) A case of avascular necrosis of the lunate (Kienbock's disease). (c) Image showing calcification (arrow) in the region triangular of the wrist. (d) Fusion of the scaphoid with distal row of carpal bones.

3. Syntactic Description of Wrist Radiograms

In order to introduce a graph representation, it is necessary to define both the graphical elements (the so-called primitives, which have to be recognised automatically in the first step of the classification process) and spatial relations between the recognised objects. In order to obtain a spanning graph (a formal description of the examined bones) from the analysed image, it is necessary first to identify and label all bones of the closer and further wrist series: their analysis is important from the diagnostic point of view. Next, it is necessary to specify spatial relations in accordance with the accepted order (Fig. 3).

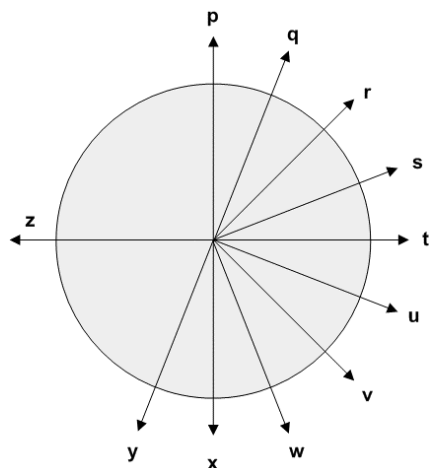


Fig. 3. Graph spatial relationships.

The described scheme is a simplified one, because in X-ray photographs obtained in real life, instead of this regular pattern, one can find a very complicated and irregular system of wrist bone forms and locations, necessitating a proper adjustment of the theoretical graph description to real X-ray images. In fact, a real representation of a three-dimensional system of palm bones on a 2-D plane may

cause trouble in such a process. This is so because sometimes some details become blurred or even disappear. In the case of a palm skeleton this phenomenon can be observed, for example, with the trapezoid bone, which becomes hidden under the trapezium and capitate bones or, in the case of the pisiform one, hidden by the triquetrum bone. On the other hand, the scaphoid and the capitate bones overlap resulting in the fact that the limits between them blur (they are shown differently, depending on the analysed palm or dorsal projection) (Burgener and Korman, 1997).

Having in mind the above-specified difficulties, we should use a graph representing a correct bone system (spanned also on the metacarpal) for the analysis of the most common type of images. The sample image shown in Fig. 4 allows us to determine a graph that describes these palms in a very simple way. This is so because the presented wrist has a correct structure, the position of the palm is properly adjusted and the hand of the patient is healthy, without any disease lesions or mechanical injuries (see Fig. 4). This example proves that a graph description of palm images can be used to determine its form in correct cases as well as to diagnose various irregularities as exceptions from the accepted norm. In the case of a correct structure of the palm and a well-taken X-ray photo, it is also possible to identify all the primary components and the relations between them in accordance with previously accepted patterns. In the case of illnesses, some of them can be missing.

For the introduced representation of the examined structures in the form of EDG graphs (graphs with directed peaks and with labelled peaks and edges) (Flasiński, 1993; Skomorowski, 1998), it is necessary to define an appropriate linguistic formalism that is an appropriate graph grammar defining a language. The language is defined so that one could describe using it, without any ambiguities, every image representing a spatial system composed of elements similar to the wrist bone system. In this way we create a tool describing all possi-

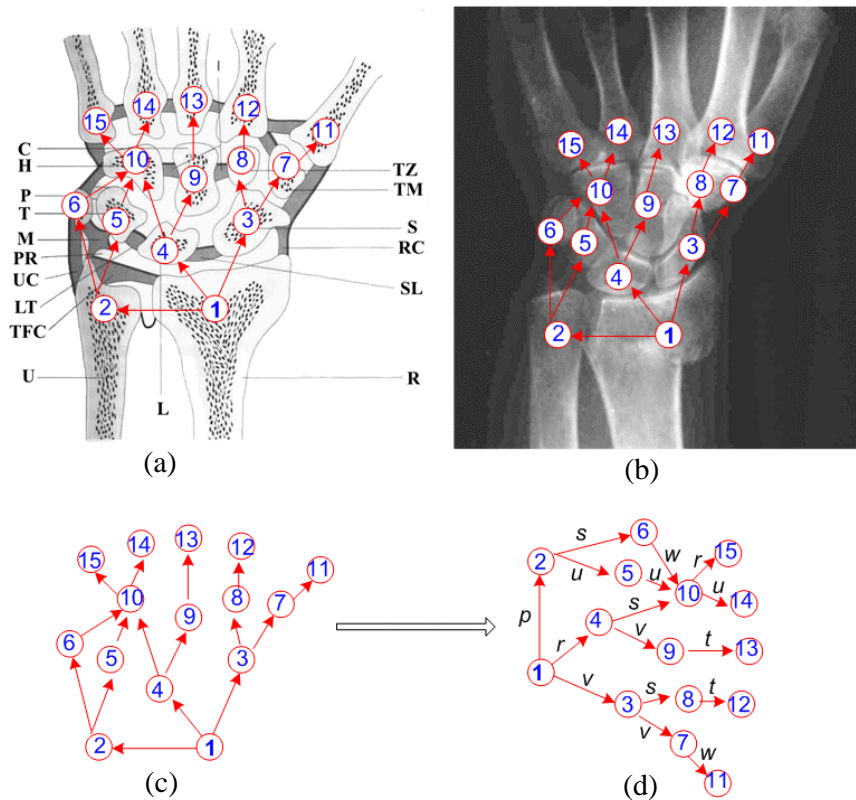


Fig. 4. Definition of an EDG graph describing the hand skeleton: (a) Anatomical scheme of a regular wrist (carpus) bone system with selected elements which are necessary for a formal definition of the constitutive parts of the linguistic description based on the graph-grammar under consideration. (b) A defined graph spanned on a real (correct) radiographic palm image. (c) A graph extracted from the analysed image. (d) A graph in a form suitable for the analysis by a graph grammar analyser. In this graph numbers mark peaks standing for neighbouring wrist bones while letters stand for spatial relations between these bones (for an easier analysis the graph is rotated by 90 degrees clockwise).

ble shapes and locations of wrist bones, both the correct and pathological ones. The linguistic formalism that we propose in this paper in order to execute the task of mirroring real medical image forms into graph formulae for computer processing will be an expansive graph grammar (Flasiński, 1993). After defining such a grammar, every X-ray image will be converted into a linguistic formula built in accordance with the rules of that grammar. The effective parsing of that formula conducted by the computer, compliant with the rules of the created grammar, will lead to an automatic assessment of photograph contents. This will make it possible to determine whether the structure of a wrist falls within the norm or whether it has pathological deviations.

4. Graph Language Describing the Wrist Structure

The analysis above shows that the key to automatic interpretation of X-ray palm bone images considered in this

paper is the expansive graph grammar, to be formally defined below.

Definition 1. The expansive graph grammar G_{exp} generating EDG graphs is the quintuple

$$G_{exp} = (N, \Sigma, \Gamma, P, S),$$

where N is a set of non-terminal peak labels, Σ denotes a set of terminal peak labels, Γ signifies a set of edge labels, S stands for the start symbol and P is a finite production set of one of the following forms:

1. the reduced form: $A \rightarrow a, A \in N, a \in \Sigma,$
2. the expansive form: $A \rightarrow ax_1B_1x_2B_2e^2 \dots x_rB_re^r,$ where $a \in \Sigma, A, B_i \in N, x_i \in \Gamma (i = 1, \dots, r), e_i \in \{*, \lambda\}$ are location operators.

In the conducted research, aimed at generating a linguistic description of the correct location and the number

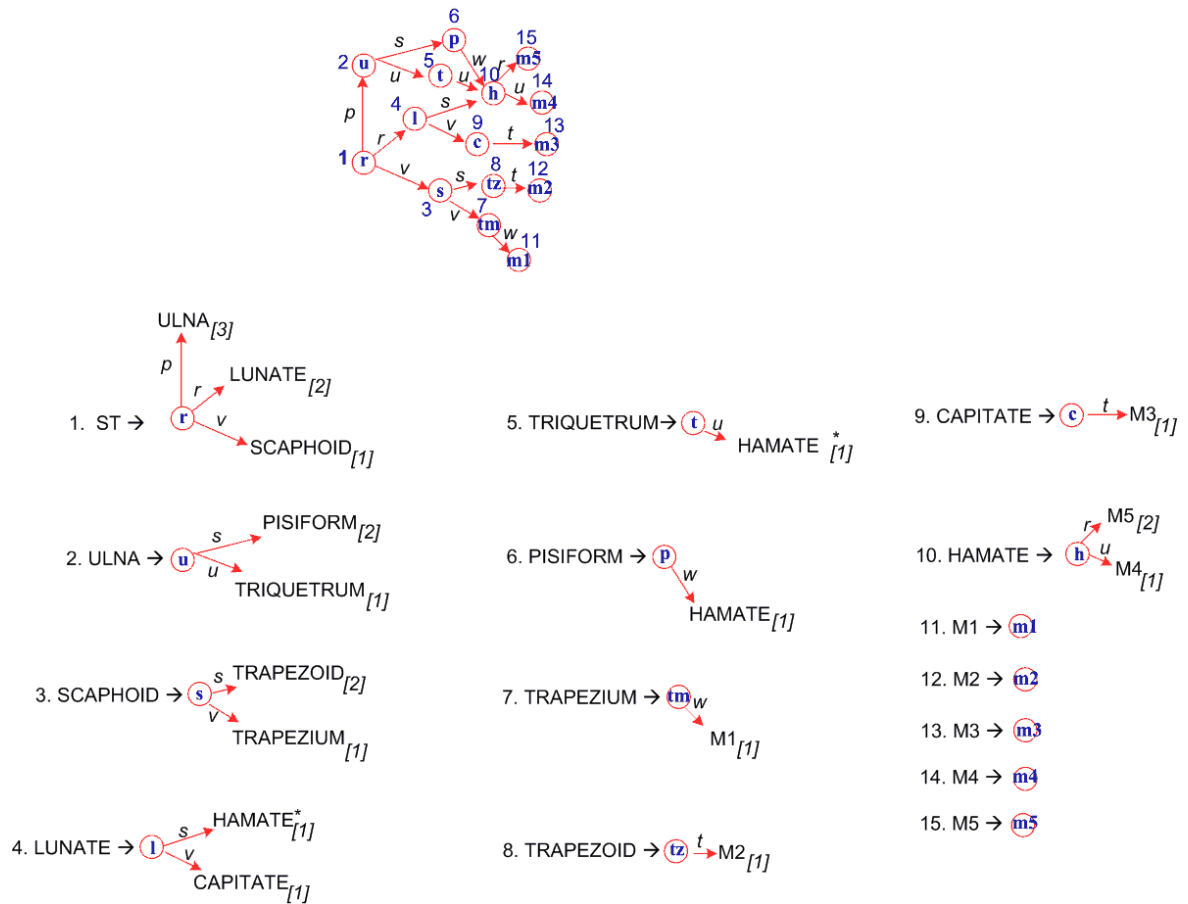


Fig. 5. Production/graph set introducing a representation of the correct structure and the number of the bones in the wrist.

of wrist bones, individual sets of the prepared grammar were defined in the following way (the labels are compliant with Fig. 4 and the names of individual bones, on which graph peaks were spanned):

- Non-terminal set of peak labels

$$N = \{ST, ULNA\ SCAPHOID, LUNATE, TRIQUETRUM, PISIFORM, TRAPEZIUM, TRAPEZOID, CAPITATE, HAMATE, M1, M2, M3, M4, M5, \}$$

- Terminal set of peak labels
- $$\Sigma = \{r, u, s, l, t, p, tm, tz, c, h, m1, m2, m3, m4, m5\}$$

- Γ – edge label set presented in Fig. 3,
- Start symbol $S = ST$,
- P as a finite production set presented in Fig. 5.

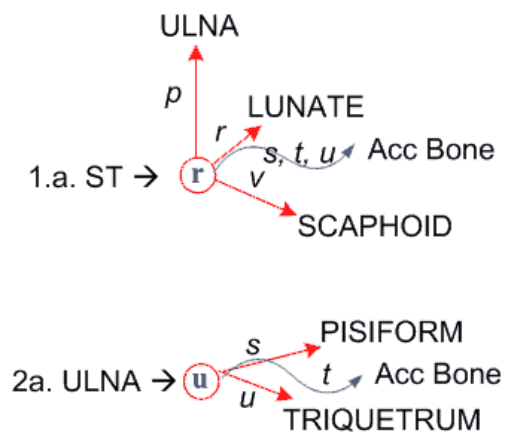


Fig. 6. Production set describing additional bones located in areas marked with circles in Fig. 1. For simplification, in these productions peak and graph ordinals as well graph location, operators were omitted.

Possibilities to describe image cases showing additional wrist bones can be obtained by enriching the above set of rules introducing the formulae of the analysed gram-

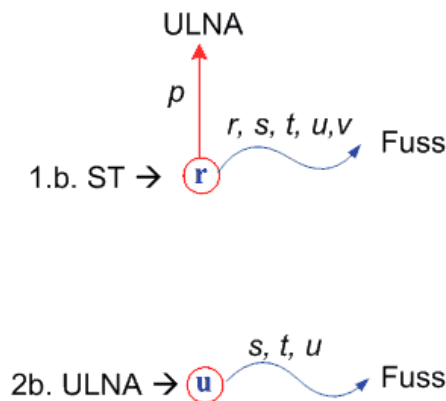


Fig. 7. Production set describing bone defects caused by bone joints or by bone dislocation.

mar by productions defined in Fig. 6. The set of non-terminal labels N will then also contain an additional peak label, 'Acc Bone', standing for the reasoning tree for the new object/bone appearing in the image (in the first series) and located in accordance with the labelled directions. An image showing other pathology forms in the wrist image (synostoses or bone defects) can be recognised with the use of alternative rules specified in Fig. 7. In this case an additional 'Fuss' peak appears and stands for the introduction of an additional bone, originating from the merger of two neighbouring ones.

5. Selected Results

As a result of the conducted research, linguistic formalisms in the form of EDT graphs were defined. They described both the radiogrammes of regular palm bones and radiogrammes presenting some lesions falling within physiological norms, such as the appearance of additional bones or a reduction in their number. The presented methods were used for computer analysis of selected radiogramme sequences that originated from both radiological examinations and specially selected, extremely rare cases, taken from books on radiology. All cases of the disappearance or appearance of objects important from the point of view of medical diagnostics were analysed independently for their palm and dorsal projections. The approach presented in this paper relates also to changes in the number of bones and their location if they occur in a closer series or between the closer and further series. In further research these methods will be also adopted to analyse additional formations appearing in the metacarpus as a result of disease processes, in particular broken bones, incorrect synostoses and processes related to degeneration diseases (e.g., the degenerative articular disease).

It should be emphasised that with the accepted methodology of the structural (syntactic) image descrip-

tion, the key element is to define the grammar correctly so that it enables one to obtain a linguistic description of the foreseen images, both the correct and pathological forms of the analysed anatomical structure (in this case, the wrist). Recognising the structure of the examined image (wrist) is therefore a set of routine activities that can be fully automated. In our case we decided to use a two-course syntax analyser that generates first characteristic descriptions of peaks for the examined graphs and next making a generation analysis (top-down). As a result, sequences of grammar rule numbers are obtained as the output of the image analysing system. They allow one to generate the analysed graph description. Details of this kind of analysis can be found in (Flasiński, 1993). It is worth emphasising, however, that the complexity of structural analysis with the use of such grammars is polynomial. This means that the analysing software can perform some activities very quickly, supporting in real time the decision of a medical doctor who analyses archive images, for example in the PACS system.

The methods prepared were aimed at building an automatic detection and semantic interpretation system for detected regularities as well as the diagnosed irregularities in carpus bones. It is worth noticing, however, that the test data set used for defining the output rules in the presented grammar was composed of only about 30 radiogrammes. Despite such an insignificant representation and owing to a great descriptive and generation power of the used graphs, it is possible to classify practically any number of analysed images. The initially assessed efficiency exceeds the 90% threshold. On the other hand, the appearance of difficult and ambiguous cases can be quickly considered by enriching grammar formalisms by new (not considered so far due to the lack of empirical data) reasoning rules and by specifying the meaning interpretation or such new cases. This is also the direction that will be followed in the conducted research.

6. Conclusion

This paper presents a new approach to semantic interpretation of difficult multi-object medical images that can contain important diagnostic information. Such possibilities have been created owing to the use of graph image languages based on EDT graphs and expansive graph grammars. Indeed, such methods significantly enrich the application field for medical image analysis algorithms and go in the direction of expanding the possibilities of meaning interpretation of pathological disease lesions, visible on some types of radiological images. So far, the lack of effectively operating structural analysers resulted in that computing complexities of previous analysis methods used for similar systems were too complex to consider their practical application in medicine. Even af-

ter they were discovered, it turned out that it was not easy to present in a spatial graph the complex anatomical structure of selected organs. Such difficulties are caused by differences in the physiological structure of every patient, errors made by machines taking photographs and, frequently, by the poor quality of carriers used to register such images. Pioneer understanding of such a meaning description problem, which resulted in defining probabilistic IE and EDT graphs and the specification of a syntax analyser for grammars generating this type of languages, formed the basis for the dualism in solving the issue and classification of complex medical images and enabled a meaningful interpretation of multi-object images, including complex biological structures. Describing the approach to semantic analysis outlined in this paper provides an effective support to the work of a medical doctor in the field of diagnosing and automatic computer categorisation of medical images (Ogiela and Tadeusiewicz, 2003c).

Acknowledgments

This work was supported by the AGH University of Science and Technology under Grant No. 10.10.120.39.

References

- Albus J.S. and Meystel A.M. (2001): *Engineering of Mind: An Introduction to the Science of Intelligent Systems*. — New York: Wiley.
- Bankman I. (Eds.) (2002): *Handbook of Medical Imaging: Processing and Analysis*. — San Diego: Academic Press.
- Burgener F.A. and Korman M. (1997): *Bone and Joint Disorders*. — Thieme: Stuttgart.
- Duda R.O., Hart P.E. and Stork D.G. (2001): *Pattern Classifications, 2nd Ed.*. — New York: Wiley.
- Flasiński M. (1993): *On the parsing of deterministic graph languages for syntactic pattern recognition*. — Pattern Recognition, Vol. 26, No. 1, pp. 1–16.
- Meyer-Baese A. (2003): *Pattern Recognition in Medical Imaging*. — San Diego: Elsevier.
- Ogiela M.R. and Tadeusiewicz R. (2003a): *Artificial intelligence structural imaging techniques in visual pattern analysis and medical data understanding*. — Pattern Recogn., Vol. 36, No. 10, pp. 2441–2452.
- Ogiela M.R. and Tadeusiewicz R. (2003b): *Cognitive vision systems in medical applications*. — Lect. Notes Artif. Intell., Vol. 2871, pp. 116–123.
- Ogiela M.R. and Tadeusiewicz R. (2003c): *New approach for cognitive analysis and understanding of medical patterns and visualizations*. — Proc. SPIE, Vol. 5203 *Applications of Digital Image Processing XXVI*, SPIE, Bellingham, WA, pp. 615–622.
- Pietka E., Gertych A., Pospiech S., Fei-Cao, Huang H.K. and Gilsanz V. (2001): *Computer-assisted bone age assessment: Image preprocessing and epiphyseal/metaphyseal ROI extraction*. — IEEE Trans. Medical Imag., Vol. 20, No. 8, pp. 715–729.
- Skomorowski M. (1998): *Parsing of random graphs for scene analysis*. — Int. J. Mach. Graph. Vision, Vol. 7, No. 1/2, pp. 313–323.
- Tadeusiewicz R. and Ogiela M.R. (2004a): *Medical Image Understanding Technology*. — Berlin: Springer.
- Tadeusiewicz R. and Ogiela M.R. (2004b): *The new concept in computer vision: automatic understanding of the images*. — Lect. Notes Artif. Intell., Vol. 3070, pp. 133–144, Berlin: Springer.
- Tadeusiewicz R. and Ogiela M.R. (2004c): *Processing, analysis, recognition, and automatic understanding of medical images*, In: *Optical Methods, Sensors, Image Processing, and Visualization in Medicine* (A. Nowakowski and B.B. Kosmowski, Eds.). — Proc. SPIE, Vol. 5505 (*Progress in Biomedical Optics and Imaging*, Vol. 5, No. 31), pp. 101–109.

Received: 22 November 2004
 Revised: 17 February 2005