

Review

Pituitary disorders in pregnancy

Alexandra Chrisoulidou,¹ Maria Boudina,¹ Niki Karavitaki,³ Eleni Bili,² John Wass³

¹Unit of Endocrinology, Theagenio Hospital, ²1st Department of Obstetrics & Gynaecology, Aristotle University of Thessaloniki, Greece; ³Department of Endocrinology, Oxford Centre for Diabetes, Endocrinology and Metabolism, Churchill Hospital, Oxford, UK

ABSTRACT

The pituitary gland is significantly affected during gestation in terms of both size and function. Due to this physiologic adaptation, endocrine evaluation and interpretation of imaging is far more complex than in the non-pregnant state. Pituitary disorders are rare in pregnancy, as they are usually associated with gonadal dysfunction, thereby posing difficulties with fertility. This review will focus on pituitary adenomas (prolactinomas, GH-secreting and ACTH-secreting), their diagnostic handicaps and the recommendations for treatment. We will also discuss the two pituitary disorders encountered in pregnancy, Sheehan's syndrome and lymphocytic hypophysitis.

Key words: Pituitary gland, Pregnancy

1. INTRODUCTION

During normal pregnancy, major endocrine and metabolic alterations occur due to the physiological hormonal secretion from the placenta.¹ The pituitary adapts to these changes and all secretory axes are affected. In addition, pituitary size is increased, mainly due to lactotroph cells hyperplasia.² As a result, pituitary imaging and interpretation of endocrine tests is difficult.

When a pituitary disorder appears during pregnancy or a patient with a pituitary disorder achieves pregnancy, the difficulties in recognizing the disease and

establishing the diagnosis are even greater. As these rare conditions can be dangerous for both mother and foetus, it is essential to identify and treat them successfully. Pituitary disorders in pregnancy are certainly challenging and require a multidisciplinary approach from endocrinologists, gynaecologists, radiologists and neurosurgeons to achieve the best outcome.

2. PROLACTINOMAS

2.1. General issues

Prolactinomas represent the commonest pituitary disorder encountered in pregnancy. These tumours account for about 40% of all pituitary adenomas in the general population and are common in women of reproductive age.³ Untreated women with prolactinomas are not able to achieve pregnancy, as the hyperprolactinaemia affects the pulsatility of GnRH, diminishes FSH and LH secretion and induces amen-

Address for correspondence:

Dr. Alexandra Chrisoulidou, Consultant Endocrinologist, Unit of Endocrinology, Theagenio Hospital, Thessaloniki, Greece, Tel.: +30 2310 898618, Fax: +30 2310 845514, E-mail: a.chrisoulidou@gmail.com

Received: 22-5-2014, Accepted: 15-12-2014

orrhoea, infertility and hypogonadism.⁴ As a result, in most cases the diagnosis of a prolactinoma is made prior to conception.

Prolactinomas are classified based on size as micro- (<1 cm) and macroprolactinomas (>1 cm). Most of them are microadenomas and present with manifestations attributed to hyperprolactinaemia, i.e. oligo/amenorrhoea, galactorrhoea and infertility. Larger tumours may cause additional pressure symptoms/signs, such as visual disturbances and headaches. Dopamine agonists (DA), which constitute the cornerstone in the treatment of prolactinomas, normalize PRL levels in 80-90% of patients and enable resumption of menses.⁵ It should be noted that restoration of ovulation after commencing DA therapy occurs before the achievement of normoprolactinaemia and women should be informed about this effect.⁶ Apart from the PRL lowering effect, DA may induce shrinkage of the pituitary tumour in women treated before conception (a reduction in tumour size greater than 25% is expected in around 70% of patients).⁵ Therefore, pre-treatment with these agents may render a macroadenoma to a microadenoma or abolish a microprolactinoma. The duration of DA treatment prior to pregnancy is critical in this respect, as therapy for more than one year seems to reduce the risk of tumour enlargement.⁷ Fertility rates after managing the hyperprolactinaemia successfully via a DA are high, with more than 80% of patients achieving pregnancy.⁸

The currently available dopamine agonists are bromocriptine, cabergoline and quinagolide (the latter not approved for use in the United States). Bromocriptine is the “oldest” of the dopamine agonists and has been tested more extensively than the other compounds. The vast majority of evidence supports the safety of bromocriptine for use in early pregnancy.⁹ Additionally, its continuous use throughout pregnancy in around 100 cases has also indicated optimal outcome for most cases. Similarly, cabergoline appears to be safe in early pregnancy,^{8,10} although less data are available compared to bromocriptine. Cabergoline’s long half-life may be a problem in pregnancy, as even after its discontinuation, PRL suppression may persist for months.¹¹ Follow-up of children born from mothers who received cabergoline in the first trimester has identified a few abnormalities, including epilepsy.¹² Quinagolide is probably less effective than cabergoline

in hyperprolactinaemic women,¹³ although its short half-life (22 hours) may be an advantage in pregnancy.¹⁴ It is the least tested DA for use in pregnancy. Although there are some studies supporting its safe profile,¹⁵ it is not frequently used.

2.2. Tumour growth

Various degrees of enlargement of microprolactinomas, between 1.5-4.5%,^{16,17} during pregnancy are expected, with symptomatic growth occurring in about 2% of the cases. The low risk of clinically significant tumour increase makes discontinuation of DA treatment a safe option in these patients. Due to the absence of mass effects from microprolactinomas, pregnant women can be usually followed up clinically (focusing on the presence of headaches or visual deterioration) without formal assessment of visual fields or MRI, which could be reserved for the rare symptomatic cases.

The possibility of growth in macroprolactinomas is substantially higher than in smaller tumours and may reach 31% for women who had no surgery or radiotherapy prior to conception.¹⁸ In pregnant women on DA, symptomatic enlargement occurs in about 5%. Macroprolactinomas have been associated with visual field loss during progression of pregnancy¹⁹ and frequent clinical assessment is needed. It is also recommended that women with prolactinoma close to the optic chiasm avoid pregnancy until treatment with a DA has shrunk the tumour, thereby decreasing the risk of clinically significant enlargement during pregnancy.

2.3. Recommendations for management during pregnancy

Over the years, cabergoline has been proved more efficacious than bromocriptine in the treatment of hyperprolactinaemia.²⁰ As soon as pregnancy is confirmed, the standard recommendation for women with prolactinoma is to discontinue the DA therapy.²¹ As DAs cross the placenta, their discontinuation is advised for two reasons: to minimize foetal exposure during the critical period of organogenesis and to withhold treatment at a time (i.e. first trimester) when it is less likely for any significant tumour growth to occur. In the majority of women with prolactinoma, clinical evaluation will be unremarkable and treatment with a DA is not necessary. Follow-up for manifestations

suggesting adenoma growth (mainly headaches or visual deterioration) and formal assessment of the visual fields (in patients with macroprolactinoma) are recommended every trimester (or earlier if there are clinical concerns or if the adenoma prior to conception is close to the optic chiasm). When such manifestations appear, imaging with unenhanced MRI should be performed. If growth of the pituitary mass is identified, re-institution of DA (preferably bromocriptine) for the remainder of the pregnancy may provide tumour control and monthly clinical assessment is required (including visual fields). If treatment with the DA does not improve vision within 2-3 weeks, transphenoidal surgery has to be considered (in the second trimester or at delivery if this delay does not have a negative impact on vision). Women at risk for such an adverse event are those with macroprolactinomas, especially if they did not have any treatment (surgery or radiotherapy) prior to conception.²¹ It is important

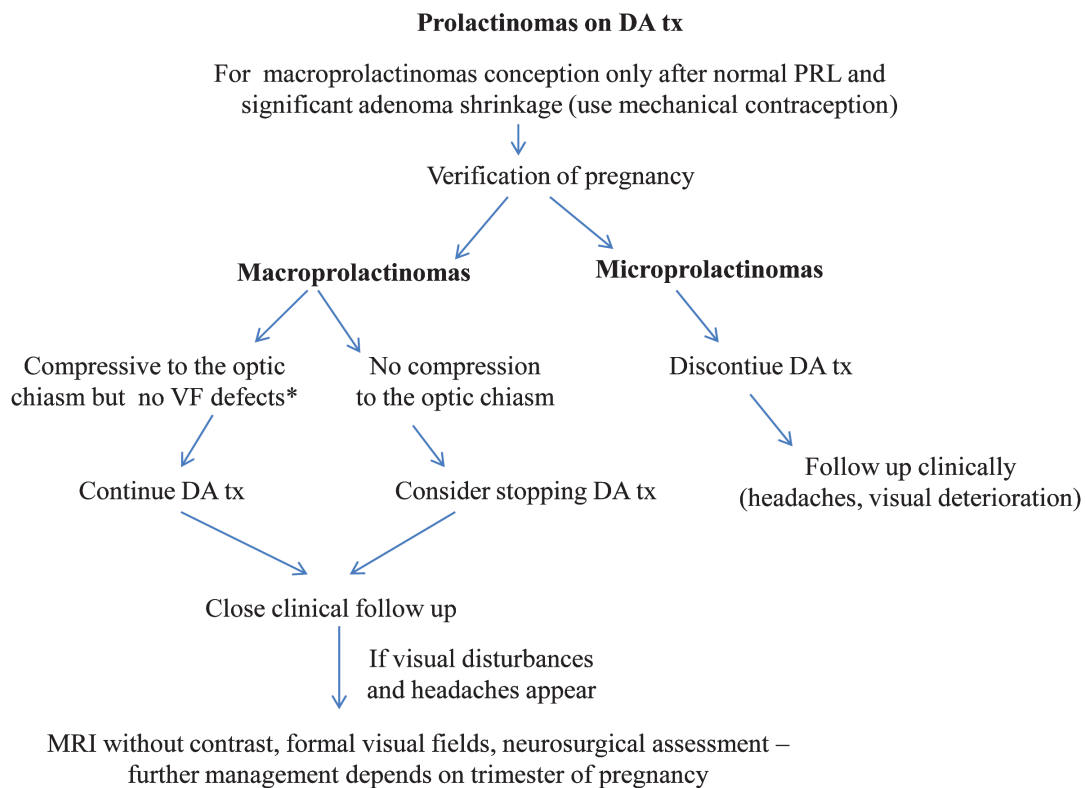
to carefully identify these patients, as continuous DA therapy may also be an option (Figure 1).

3. ACROMEGALY

3.1. General issues

Acromegaly is usually caused by macroadenomas hypersecreting growth hormone. The disease is associated with numerous complications [metabolic (hyperglycaemia and diabetes), cardiovascular (hypertension, cardiomyopathy) and skeletal] and has increased mortality.²² Treatment of acromegaly includes surgical removal of the adenoma, radiotherapy and medical therapy with somatostatin analogues, dopamine agonists and GH receptor antagonists.

Active acromegaly causes gonadal dysfunction due to: a) the adverse effects of raised GH/IGF-1 on the gonadotropic axis and the ovary,²³ b) the concurrent hyperprolactinaemia in about a third of cases (as a



*Counseling regarding surgical treatment should be offered prior to pregnancy if no response to DA tx

DA tx: dopamine agonist treatment, PRL: prolactin, VF: visual fields, MRI: magnetic resonance imaging

Figure 1. Algorithm for management of prolactinomas in pregnancy

result of the “stalk effect” or co-secretion of prolactin by the adenoma)²⁴ and c) the hypogonadotropic hypogonadism developing from mass effects originating from the adenoma.²⁵ The existing data on the outcome of medically treated pregnant acromegalic women are limited.²¹

Pregnancy is a state of mild acromegaly due to placental production of GHV (GH variant) that starts increasing at 10 weeks of gestation and reaches a plateau after 30 weeks.^{1,2} Normally, pituitary GH is decreased in pregnancy but in acromegaly this adaptation is lost. IGF-1 levels are affected by pituitary and placental GH but they are not as high as might be expected, since the high levels of oestrogen in pregnancy suppress IGF-1 production.²⁶ As a result, IGF-1 during pregnancy is not usually increased.²⁷ Due to the alterations in the GH/IGF-1 axis, the diagnosis of acromegaly in pregnancy and the follow-up of patients who subsequently become pregnant, by means of biochemical assessment, is difficult.²²

Pregnancy in women with acromegaly may aggravate the already mentioned complications of the disease. In particular, gestational diabetes and gravid hypertension are seen more frequently in uncontrolled acromegalic patients.²⁸ Cardiovascular complications, often present in acromegaly, have not been examined in detail throughout pregnancy, although acromegalic pregnancies are considered high risk. Apart from the adverse impact on the mother’s health, these complications are potentially harmful for the foetus. Miscarriages and foetal losses have been reported² among many otherwise uneventful pregnancies. An association between somatostatin analogue treatment and low birth weight has recently been suggested by studies indicating reduced uterine blood flow after short-term octreotide²⁹ and by the clinical observation of increased frequency of microsomic babies in pregnancies treated with somatostatin analogues.²⁷ On the whole, regular clinical assessment is mandatory throughout pregnancy in these cases to unravel potential maternal and foetal complications.

3.2. Tumour growth

The main concern in pregnant acromegalic women is tumour growth. This potential risk increases with the size of the initial tumour: microadenomas have, similarly to prolactinomas, a low probability of further

increase in size.² Additionally, the treatment offered prior to conception is critical, as previous surgery or radiotherapy diminishes the risk of tumour growth. As these tumours are mostly macroadenomas and often exhibit PRL co-secretion, the increase in size with progression of pregnancy is a real issue. Therefore, when visual fields defects appear, suggestive of compression of the optic chiasm, immediate evaluation is warranted: surgery represents in these cases a reasonable approach.³⁰ A similar approach is valid for the very rare occurrence of pituitary apoplexy.³¹ However, the majority of data on the outcome of acromegalic pregnancies indicate that they are uncomplicated.³²

3.3. Recommendations for management during pregnancy

Optimal control of the acromegaly (biochemical and tumour size) is required prior to conception. Medical treatment should be withdrawn on confirmation of pregnancy, unless the clinical condition of the patient necessitates continuous treatment.²² In the last 15 years, data on the safety of somatostatin analogues until pregnancy is verified have been encouraging^{27,33} and also continuous therapy has been reported uneventful in specific cases.³⁴ The increased risk of microsomic babies from mothers treated with somatostatin analogues and macrosomic babies from mothers treated with DA²⁷ needs to be thoroughly examined in additional studies. Supporting data on the safety of pegvisomant during pregnancy are very limited. The first case with successful use of pegvisomant throughout pregnancy was reported in 2007 (Brian 2007) and isolated reports were published thereafter.²⁷ During pregnancy, routine hormonal assessment for acromegaly status is usually not needed but close follow-up for metabolic complications (diabetes and hypertension) is recommended. Follow-up for manifestations suggesting adenoma growth (mainly headaches or visual deterioration) and formal assessment of the visual fields (in patients with macroadenoma) are suggested every trimester (or earlier if there are clinical concerns or if the adenoma prior to conception is close to the optic chiasm). Subcutaneous somatostatin with or without bromocriptine may be beneficial for the persistent headaches experienced by some patients. When such manifestations appear, imaging with unenhanced MRI should be performed. In the event of visual compromise, surgery will need to take place.

On the whole, even in persistent acromegaly,³⁶ most acromegalic women have uncomplicated pregnancies. Interestingly, gestation may be beneficial for the course of acromegaly following pregnancy.

4. CUSHING'S DISEASE

4.1. General issues

Cushing's disease (CD) causes hypercortisolaemia due to pituitary ACTH hypersecretion from a pituitary adenoma. Hypercortisolaemia often causes menstrual disturbances (mostly oligo/amenorrhoea) and in severe cases, hypogonadotrophic hypogonadism compromising fertility.³⁷

CD rarely occurs in pregnancy and, since the first description in 1953,³⁸ the published literature mostly includes isolated case reports.^{39,40} In contrast to the preponderance of CD in non-pregnant hypercortisolaemic patients, hypercortisolaemia in pregnancy is less frequently associated with CD.⁴¹ Signs and symptoms of CD resemble the many physical and emotional changes developing in normal pregnancy (as weight gain and development of striae), making the clinical and biochemical diagnosis difficult during pregnancy.

Pregnant women with CD need close follow-up due to the high risk of maternal and foetal complications.⁴² Hypertension, diabetes and pre-eclampsia may complicate these pregnancies, especially in uncontrolled patients. Foetal mortality is increased, as well as prematurity and intrauterine growth retardation in babies born from mothers with CD.^{42,43}

In normal pregnancy, major alterations occur in the hypothalamic-pituitary-adrenal axis (HPA) due to a) placental production of CRH and ACTH, b) increase in cortisol production and c) increased oestrogen-induced corticosteroid-binding globulin secretion from the liver.⁴⁴ Also, the urinary free cortisol (UFC) is increased up to 3-fold by the third trimester. The circadian variation of cortisol is maintained, but the evening, midnight and salivary cortisol levels are higher than in the non-pregnant state, although the normal pregnancy intervals are not known.⁴⁵ In addition, dexamethasone suppression is blunted and the overnight 1 mg-test cannot be safely used in pregnancy as a screening test.⁴⁴ The CRH test was first used in

1995 to confirm the diagnosis in pregnant patients.⁴⁶ Administration of CRH in pregnancy has not proven to be teratogenic in animal studies,^{45,47} however, ovine CRH has been graded as a category C drug by the FDA (for use only when clinically indicated). Alternatively, the desmopressin test yields sensitivity and specificity higher than 80% for cortisol responses, although it is inferior to CRH testing.^{42,48} In doubtful and very selected cases, bilateral inferior petrosal sinus sampling has been used, despite the risk of exposure to ionizing radiation and the invasiveness of the procedure, which has certainly limited its use.^{40,45} The high-dose dexamethasone suppression test (HD-DST) is generally useful for discrimination between ectopic Cushing's syndrome and CD; in the latter, cortisol suppression greater than 50% is expected. Both the 8-mg overnight DST and the 2-day test may be used for this purpose, keeping in mind that in normal pregnancy dexamethasone suppression is blunted. More commonly, the use of HD-DST in pregnancy is proposed for the distinction between pituitary and adrenal causes of Cushing's syndrome, as cortisol suppression higher than 80% is only seen in CD.^{45,49} HD-DST is not uniformly accepted as a useful test in pregnancy and, as with all tests assessing the HPA axis, it should be used in conjunction with other ones to establish the diagnosis.

It has been proposed that in women with clinical suspicion of CD, biochemical diagnosis should be based on the following: a) UFC levels higher than 3-fold the reference range and b) loss of circadian rhythm of cortisol secretion.⁵⁰

Imaging is performed with unenhanced MRI in the second and third trimester. MRI has been proven safe after the 32nd week of pregnancy,⁵¹ but in mid-gestation the advantages should be weighed against the risks. Since most ACTH secreting pituitary tumours are microadenomas, the absence of gadolinium contrast compromises the detection rate.⁵²

4.2. Recommendations for management during pregnancy

CD should be treated during pregnancy because if left untreated, there is a risk of significant maternal and foetal complications. Radical treatment for CD is transphenoidal removal of the pituitary mass, performed in the second trimester.⁵³ In persistent disease, bilateral

adrenalectomy has been tried. In previously irradiated patients the outcome of pregnancy is good; however, evaluation of pituitary function is essential due to the risk of hypopituitarism.⁵⁴ Follow-up for manifestations suggesting adenoma growth (mainly headaches or visual deterioration) and formal assessment of the visual fields (in patients with macroadenoma) are suggested every trimester (or earlier if there are clinical concerns or if the adenoma prior to conception is close to the optic chiasm). Medical treatment of CD is limited in pregnancy. Metyrapone is the most commonly used agent to control hypercortisolaemia,⁵⁵ however, it may precipitate to pre-eclampsia and the hazards of treatment should be thoroughly evaluated.⁵⁶ Mitotane is contra-indicated due to its teratogenicity⁵⁷ and similarly aminoglutethimide and cyproheptadine are not recommended. Administration of ketokonazole in isolated cases was uneventful,⁵⁸ but it is usually offered in patients who cannot tolerate metyrapone (FDA category C drug).

5. OTHER PITUITARY TUMOURS

Gonadotrophin-secreting adenomas (GSAs) and TSH-secreting adenomas are exceptionally rare in pregnancy. GSAs are associated with spontaneous ovarian hyperstimulation syndrome⁵⁹ and can be treated with bromocriptine, which normalizes ovarian size and ovulation.⁶⁰ TSH-secreting adenomas cause hyperthyroidism and need differential diagnosis from thyroid hormone resistance syndrome.⁶¹ Apart from treatment with antithyroid drugs,⁶² transsphenoidal removal during the second trimester of pregnancy aiming to reduce the mass effects has been described.⁶³ In addition, treatment with octreotide in the first month and the third trimester of pregnancy in a patient⁶⁴ and throughout pregnancy⁶⁵ in a second one were reported as successful and uncomplicated.

Non-functioning adenomas (NFAs) are also rare in women of reproductive age. At diagnosis, they are usually macroadenomas often causing hypogonadism and impaired fertility and women require ovulation induction or *in vitro* fertilization to become pregnant.⁶⁶ As specific medical therapy is not available, bromocriptine may reduce the normal (during pregnancy) pituitary enlargement and prevent optic chiasm compression.⁶⁷ Transsphenoidal surgery is an option in mid-pregnancy.

Craniopharyngiomas are rarely encountered in pregnancy due to the hypopituitarism that they cause. Isolated reports exist on patients who became pregnant after they received surgical treatment⁶⁸ and irradiation.⁶⁹ Recurrence and symptomatic enlargement with progression of pregnancy may be a concern in these tumours.⁷⁰

In all abovementioned tumours, follow-up for manifestations suggesting adenoma growth (mainly headaches or visual deterioration) and formal assessment of the visual fields (in patients with macroadenoma) are suggested every trimester (or earlier if there are clinical concerns or if the adenoma prior to conception is close to the optic chiasm).

6. LYMPHOCYTIC HYPOPHYSITIS

Lymphocytic hypophysitis (LH) is a rarely recognized autoimmune disorder histologically characterized by infiltration of the pituitary gland by lymphocytes and less often plasma cells, eosinophils, macrophages and neutrophils. The infiltrating cells lead to destruction of the pituitary parenchyma and its replacement with fibrotic tissue.⁷¹ Histology reveals diffuse infiltration of the pituitary gland by CD3+ CD4+ T cells and CD20 plasma cells and antipituitary antibodies are often detected in the patient's serum.^{72,73}

LH usually affects females during late pregnancy or within a year postpartum, although cases diagnosed in the first or second trimester of pregnancy and also in men and children have been described.^{74,75} The disease is usually diagnosed postpartum in women failing to lactate or to resume menses after delivery. The aetiology is unclear, with autoimmune mechanisms being the most widely accepted. LH is associated with other autoimmune diseases, as Hashimoto's thyroiditis, Addison's disease, type 1 diabetes and pernicious anaemia in about 30% of the reported cases.⁷⁶⁻⁷⁸ LH presents as a sellar mass causing headache or visual defects, manifestations of pituitary deficiency and more rarely polyuria or polydipsia (diabetes insipidus) in cases of infundibulo-hypophysitis.^{76,77} Hyperprolactinaemia is found in about 30% of the patients, secondary to the mass effect or to PRL released by the destructed gland or to PRL-stimulating antibodies. Paradoxically, corticotroph and thyrotroph reserves are the first to be affected, while lactotrophs and somatotrophs are affected later.⁷⁹ Lactation failure postpartum result-

ing from hypoprolactinaemia may also appear.⁸⁰ LH should be suspected in pregnant or early postpartum women with a newly found pituitary tumour and /or hypopituitarism.

Pituitary imaging is usually helpful for the diagnosis. MRI reveals diffuse thickening of the pituitary stalk, homogeneous contrast enhancement of the gland which is symmetrically enlarged and loss of the 'bright spot' of the neurohypophysis, thus differentiating LH from pituitary adenoma. However, approximately 50% of patients are misdiagnosed as having a non-functioning pituitary adenoma, which leads to unnecessary surgery.^{81,82}

The suspicion of LH is confirmed by pituitary biopsy. However, the diagnosis of LH may be suspected in women with a history of gestational or postpartum hypopituitarism characterized based on early loss of corticotroph and thyrotroph function, a symmetrically enlarged sellar mass and absence of hypovolaemia or shock which characterizes Sheehan's syndrome. Antipituitary antibodies may also be found in some patients with LH, although their specificity is low as they may also exist in patients with non-autoimmune pituitary diseases and in normal postpartum women without hypophysitis.⁸³ The natural course of the disease is variable depending on the aggressiveness of the disorder and cases of spontaneous partial or full recovery of the pituitary function and resolution of pituitary mass have been reported. Moreover, a significant number of women are never diagnosed or are misdiagnosed.⁸⁴

Treatment of LH consists of replacement of the deficient pituitary hormones. Corticosteroids have been used successfully for reducing the mass effect in a number of cases,⁸⁵⁻⁸⁷ although it is yet not clear whether the improvement of symptoms may be attributed to corticosteroid treatment or to the natural course of the disease. DAs have been tried in the case of hyperprolactinaemia leading to improvement of the visual fields.⁸⁸ Transphenoidal surgery for decompression has been used in cases of progression of neurological symptoms and visual fields deterioration,⁷⁸ despite conservative therapy.

7. SHEEHAN'S SYNDROME

Pituitary necrosis after heavy blood loss during or just after delivery is called Sheehan's syndrome (SS)

and was first described by Simmonds in 1913.⁸⁹ Its frequency has decreased over the years in developed countries as a consequence of improved obstetrical care with the advent of acute medicine and the prompt management of hypovolaemia with blood transfusion and intravenous fluids.⁹⁰ However, due to its heterogeneous clinical presentation, ranging from mild symptoms to lethal outcome, the clinician should be able to recognize women at risk and treat them appropriately.

The clinical manifestations of SS are variable and non-specific, ranging from weakness, fatigue and anaemia to severe pituitary insufficiency with coma and death. The acute form of the disease is very rare and may present with severe hypopituitarism, headache and hyponatraemia following delivery. In the majority of patients, mean time between postpartum haemorrhage and clinical symptoms ranges from months to many years postpartum.⁹¹

Pituitary apoplexy after delivery should be considered in the differential diagnosis of SS, in shocked patients with postpartum haemorrhage, as it requires urgent surgical intervention. Lymphocytic hypophysitis should also be ruled out. They are all characterized by pituitary enlargement in MRI, although in SS it is later followed by atrophy and development of empty sella.^{92,93} The degree of pituitary necrosis is not related to the severity of clinical manifestations.⁹⁴

The suggested diagnostic criteria of SS depend on the clinical presentation, the symptoms and the imaging and include: 1) heavy vaginal bleeding after delivery, 2) significant hypotension or shock requiring urgent medical care, 3) failure to lactate postpartum, 4) absence of menses after delivery, 5) partial or total hypopituitarism, 6) empty sella on CT or MRI.⁹¹

Antipituitary and antihypothalamic antibodies are present in SS females and not in normal ones, indicating a pituitary autoimmune process that causes late pituitary dysfunction in SS patients.⁹⁵

Treatment of SS consists of replacement of the deficient hormones. Glucocorticoids are life-saving when administered at the onset at the minimum dose that improves clinical symptoms.^{96,97} Women who desire another pregnancy may undergo ovulation induction. SS patients may also become pregnant spontaneously due to later improvement of the pituitary function after delivery.⁹⁸

8. HYPOPITUITARISM IN PREGNANCY

The average annual incidence of hypopituitarism in the general population is about 42 cases/million.⁹⁹ The most common pituitary hormone deficiencies are those of GH and FSH/LH and, in the case of hypogonadism, fertility treatment will be required for achieving pregnancy. Women with hypopituitarism have increased mortality from cerebrovascular disease:¹⁰⁰ therefore, they need close follow-up during pregnancy. In most cases, hypopituitarism occurs as a result of pituitary tumours and their treatment and in females is managed via replacement therapy with hydrocortisone, thyroid hormone, GH, oestrogens/progestogens and desmopresin, (if there is also posterior hypopituitarism).

Hydrocortisone is the preferred glucocorticoid for use in pregnant women with ACTH deficiency compared to dexamethasone. The dose may need upward adjustment with the progression of pregnancy,¹⁷ especially in the third trimester. In addition, prior to labour extra parenteral cover will be required to overcome the stress of delivery.¹⁰¹ Levothyroxine is given in pregnant women with secondary hypothyroidism aiming at fT4 levels in the upper half of the normal range,¹⁰² as low fT4 in early gestation may have an adverse impact on the child's psychomotor development.¹⁰³ TSH is not a useful marker for monitoring thyroxine replacement. Treatment with recombinant GH injections is not approved for use in pregnancy. However, women who became pregnant while receiving GH therapy and stopped it during the first trimester had uneventful pregnancies and normal babies.¹⁰⁴ Since GH deficiency in adulthood is associated with subfertility, GH has been used in protocols for ovulation induction of hypopituitary women with satisfactory outcome.¹⁰⁵ Desmopressin therapy appears safe for use throughout pregnancy, despite its oxytocin-like activity.^{106,107} Placental vasopressinase during gestation, in addition to increased glomerular filtration rate, increases the degradation of vasopressin. Therefore, therapy in diabetes insipidus must be modified accordingly.

9. CONCLUSION

Pituitary disorders are uncommon in pregnancy and clinical experience concerning their manage-

ment is limited, necessitating international registries aiming to identify their prevalence and establish the optimal protocols for their diagnosis and management. Follow-up of these patients in centres with expertise is required for the safe outcome of both mother and foetus/newborn.

CONFLICT OF INTEREST

The authors declare no conflict of interest.

REFERENCES

1. Feldt-Rasmussen U, Mathiesen ER, 2011 Endocrine disorders in pregnancy: physiological and hormonal aspects of pregnancy. *Best Pract Res Clin Endocrinol Metab* 25: 875-884.
2. Karaca Z, Kelestimur F, 2010 Pregnancy and other pituitary disorders (including GH deficiency). *Best Pract Res Clin Endocrinol Metab* 25: 897-910.
3. Fernandez A, Karavitaki N, Wass JA, 2010 Prevalence of pituitary adenomas: a community-based, cross-sectional study in Banbury (Oxfordshire, UK). *Clin Endocrinol (Oxf)* 72: 377-382.
4. Kaiser UB, 2012 Hyperprolactinemia and infertility: new insights. *J Clin Invest* 122: 3467-3468.
5. Molitch M, 2002 Medical management of prolactin-secreting pituitary adenomas. *Pituitary* 5: 55-65.
6. De Bernal M, de Villamizar M, 1982 Restoration of ovarian function by low nocturnal single daily doses of bromocryptine in patients with the galactorrhea-amenorrhea syndrome. *Fertil Steril* 37: 392-396.
7. Holmgren U, Bergstrand G, Hagenfeldt K, Werner S, 1986 Women with prolactinomas-effect of pregnancy and lactation on serum prolactin and on tumour growth. *Acta Endocrinol* 111: 452-459.
8. Ono M, Miki N, Amano K, et al, 2010 Individualised high dose cabergoline therapy for hyperprolactinemic infertility in women with micro- and macroprolactinomas. *J Clin Endocrinol Metab* 95: 2672-2679.
9. Molitch ME, 2006 Pituitary disorders during pregnancy. *Endocrinol Metab Clin North Am* 35: 99-116.
10. Colao AM, Abs R, Barcena DG, Chanson P, Paulus W, Kleinberg DL, 2008 Pregnancy outcomes following cabergoline treatment: extended results from a 12-year observational study. *Clin Endocrinol (Oxf)* 68: 66-71.
11. Ciccarelli E, Camanni E, 1996 Diagnosis and drug therapy of prolactinoma. *Drugs* 51: 954-965.
12. Stalder G, Mallea-Gil MS, Guitelman M, et al, 2010 Effects of cabergoline on pregnancy and embryo-fetal development: retrospective study on 103 pregnancies and a review of the literature. *Pituitary* 13: 345-350.
13. Webster J, 1996 A comparative review of the tolerability profile of dopamine agonists in the treatment

- of hyperprolactinemia and inhibition of lactation. *Drug Saf* 14: 228-238.
14. Crosignani PG, 2006 Current treatment issues in female hyperprolactinemia. *Eur J Obstet Gynecol Reprod Biol* 125: 152-164.
 15. Barlier A, Jaquet P, 2006 Quinagolide-a valuable treatment option for hyperprolactinemia. *Eur J Endocrinol* 154: 187-195.
 16. Molitch ME, 1985 Pregnancy and the hyperprolactinemic woman. *N Engl J Med* 312: 1364-1370.
 17. Karaca Z, Tanriverdi F, Unluhizarci K, Kelestimur F, 2010 Pregnancy and pituitary disorders. *Eur J Endocrinol* 162: 453-475.
 18. Gillam MP, Molitch ME, Lombardi G, Colao A, 2006 Advances in the treatment of prolactinomas. *Endocr Rev* 27: 485-534.
 19. Kupersmith MJ, Rosenberg C, Kleinberg D, 1994 Visual loss in pregnant women with pituitary adenomas. *Ann Intern Med* 121:473-477.
 20. Wang AT, Mullan RJ, Lane MA, et al, 2012 Treatment of hyperprolactinemia: a systematic review and meta-analysis. *Syst Rev* 1: 33.
 21. Melmed S, Casanueva FF, Hoffman AR, et al, 2011 Diagnosis and treatment of hyperprolactinemia: an Endocrine Society Clinical Practice Guideline. *J Clin Endocrinol Metab* 96: 273-288.
 22. Melmed S, Casanueva FF, Klibanski A, et al, 2013 A consensus on the diagnosis and treatment of acromegalic complications. *Pituitary* 16: 294-302.
 23. Urdl W, 1988 Polycystic ovarian disease: endocrinological parameters with specific reference to growth hormone and somatomedin C. *Arch Gynecol Obstet* 243: 13-36.
 24. Molitch ME, 2003 Pituitary tumors and pregnancy. *Growth Hormone & IGF Research* 13: suppl A: 38-44.
 25. Grynberg M, Salenave S, Young J, Chanson P, 2010 Female gonadal function before and after treatment of acromegaly. *J Clin Endocrinol Metab* 95: 4518-4525.
 26. Isoton AC, Wender MC, Czepielewski MA, 2008 The influence of estrogen and progesterone replacement on growth hormone activity in women with hypopituitarism. *Arq Bras Endocrinol Metab* 52: 901-916.
 27. Cheng S, Grasso L, Martinez-Orozco JA, et al, 2012 Pregnancy in acromegaly: experience from two referral centers and systematic review of the literature. *Clin Endocrinol (Oxf)* 76: 264-271.
 28. Caron P, Broussaud S, Bertherat J, et al, 2010 Acromegaly and pregnancy: a retrospective multicenter study of 59 pregnancies in 46 women. *J Clin Endocrinol Metab* 95: 4680-4687.
 29. Maffei P, Tamagno G, Nardelli GB, et al, 2010 Effects of octreotide exposure during pregnancy in acromegaly. *Clin Endocrinol (Oxf)* 72: 668-677.
 30. Koshy TG, Rajaratnam S, Mathews JE, Rajshekhar V, 2012 Acromegaly in pregnancy. *Indian J Endocrinol Metab* 16: 1029-1031.
 31. Atmaca A, Dagdelen S, Erbas T, 2006 Follow-up of pregnancy in acromegalic women: different presentations and outcomes. *Exp Clin Endocrinol Diabetes* 114: 135-139.
 32. Cozzi R, Attanasio R, Barausse M, 2006 Pregnancy in acromegaly: a one-center experience. *Eur J Endocrinol* 155: 279-284.
 33. De Menis E, Billeci D, Marton E, Gussoni G, 1999 Uneventful pregnancy in an acromegalic patient treated with slow-release lanreotide: a case report. *J Clin Endocrinol Metab* 84: 1489.
 34. Fassnacht M, Capeller B, Arlt W, Steck T, Allolio B, 2001 Octreotide LAR treatment throughout pregnancy in an acromegalic woman. *Clin Endocrinol (Oxf)* 55: 411-415.
 35. Brian SR, Bidlingmaier M, Wajnrajch MP, Weinzimer SA, Inzucchi SE, 2007 Treatment of acromegaly with pegvisomant during pregnancy: maternal and fetal effects. *J Clin Endocrinol Metab* 92: 3374-3377.
 36. Hierl T, Ziegler R, Kasperk C, 2000 Pregnancy in persistent acromegaly. *Clin Endocrinol (Oxf)* 53: 262-263.
 37. Kaltsas GA, Korbonits M, Isidori AM, et al, 2000 How common are polycystic ovaries and the polycystic ovarian syndrome in women with Cushing's syndrome? *Clin Endocrinol (Oxf)* 53: 493-500.
 38. Hunt AB, McConahey CW, 1953 Pregnancy associated with diseases of the adrenal glands. *Am J Obstet Gynecol* 66: 970-987.
 39. Coyne TJ, Atkinson RI, Prins JB, 1992 Adrenocorticotrophic hormone-secreting pituitary tumor associated with pregnancy: case report. *Neurosurgery* 31: 953-955.
 40. Pinette MG, Pan YQ, Oppenheim D, Pinette SG, Blackstone J, 1994 Bilateral inferior petrosal sinus sampling with corticotrophin releasing hormone stimulation in a pregnant patient with Cushing's syndrome. *Am J Obstet Gynecol* 171: 563-564.
 41. Guilhame B, Sanson ML, Billaud L, Beragna X, Laudat MH, Luton JP, 1992 Cushing's syndrome and pregnancy: aetiologies and prognosis in twenty-two patients. *Eur J Med* 1: 83-89.
 42. Villar L, da Coneicao Freitas M, Lima LHC, Lyra R, Kater CE, 2007 Cushing's syndrome in pregnancy: an overview. *Arq Bras Endocrinol Metabol* 51: 1293-1302.
 43. Murakami S, Saitoh M, Kubo T, Kawakami Y, Yamashita K, 1998 A case of mid-trimester intrauterine fetal death with Cushing's syndrome. *J Obstet Gynaecol Res* 24: 153-156.
 44. Lindsay JR, Nieman LN, 2005 The hypothalamic-pituitary-adrenal axis in pregnancy: challenges in disease detection and treatment. *J Clin Endocrinol Metab* 26: 775-779.
 45. Lindsay JR, Jonklaas J, Oldfield EH, Nieman LK, 2005 Cushing's syndrome during pregnancy: personal experience and review of the literature. *J Endocrinol Metab* 90: 3077-3083.
 46. Ross RJ, Chew SL, Perry L, Erskine K, Medbak S, Afshar F, 1995 Diagnosis and selective cure of Cushing's disease during pregnancy by transphenoidal surgery. *Eur J Endocrinol* 132: 722-726.

47. Iwase TI, Ohyama N, Umeshita C, Inazaka K, Namiki M, Ikeda Y, 1992 Reproductive and developmental toxicity studies of hCRH (corticotroph releasing hormone [human])(II): Study on intravenous administration of hCRH during the period of organogenesis in rats. *Yakuri To Chiryō* 20: Suppl 5: 89-102.
48. Ragonese M, Cotta OR, Ferrau F, Trimarchi F, Cannavò S, 2012 How to diagnose and manage Cushing's disease during pregnancy, when hypercortisolism is mild? *Gynecol Endocrinol* 28: 637-639.
49. Arnaldi G, Angeli A, Atkinson AB, et al, 2003 Diagnosis and complications of Cushing's syndrome: a consensus statement. *J Clin Endocrinol Metab* 88: 5593-5602.
50. Nieman LK, Biller BMK, Findling JW, et al, 2008 The diagnosis of Cushing's syndrome: an endocrine society clinical practice guideline. *J Clin Endocrinol Metab* 93: 1526-1540.
51. Lindsay JR, Nieman LK, 2005 The hypothalamic-pituitary-adrenal axis in pregnancy: Challenges in disease detection and treatment. *Endocr Rev* 26: 775-799.
52. Wang PI, Chong ST, Kielar AZ, et al, 2012 Imaging of pregnant and lactating patients: part 1, evidence-based review and recommendations. *AJR Am J Roentgenol* 198: 778-784.
53. Casson IF, Davis JS, Jeffreys RV, Silas JH, Williams J, Belchetz PE, 1987 Successful management of Cushing's disease during pregnancy by transphenoidal adenectomy. *Clin Endocrinol (Oxf)* 27: 423-428.
54. Ferrau F, Losa M, Cotta OR, et al, 2012 Course of pregnancies in women with Cushing's disease treated by gamma-knife. *Gynecol Endocrinol* 28: 827-829.
55. Lekarev O, New MI, 2011 Adrenal disease in pregnancy. *Best Pract Res Clin Endocrinol Metab* 25: 959-973.
56. Connell JM, Cordiner J, Davies DL, Fraser R, Frier BM, McPherson SG, 1985 Pregnancy complicated by Cushing's syndrome: potential hazard of metyrapone therapy. Case report. *Br J Obst Gynaecol* 92: 1192-1195.
57. Leiba S, Weinstein R, Shindel B, et al, 1989 The protracted effect of o,p'-DDD in Cushing's disease and its impact on adrenal morphogenesis of young human embryo. *Ann Endocrinol* 50: 49-53.
58. Boronat M, Marrero D, Lopez-Plasencia Y, Barber M, Schamann Y, Nóvoa FJ, 2011 Successful outcome of pregnancy in a patient with Cushing's disease under treatment with ketokonazole during the first trimester of gestation. *Gynecol Endocrinol* 27: 675-677.
59. Chayuri M, Liu JH, 2007 Ovarian hyperstimulation syndrome caused by pituitary gonadotroph adenoma secreting follicle-stimulating hormone. *Obstet Gynecol* 109: 547-549.
60. Murata Y, Ando H, Nagasama T, et al, 2003 Successful pregnancy after bromocriptine therapy in a anovulatory woman complicated with ovarian hyperstimulation caused by follicle stimulated hormone-producing plurihormonal pituitary microadenoma. *J Endocrinol Metab* 88: 1988-1993.
61. Siristatidis C, Mastorakos G, Vitoratos N, et al, 2004 Thyroid hormone resistance and enlargement of the sella turcica during pregnancy. *Arch Gynecol Obstet* 269: 152-155.
62. Bolz M, Körber S, Schober HC, 2013 TSH secreting adenoma of pituitary gland-rare cause of hyperthyroidism in pregnancy. *Dtsch Med Wochenschr* 138: 362-366.
63. Chaiamnuay S, Moster M, Katz MR, Kim YN, 2003 Successful management of a pregnant woman with a TSH secreting pituitary adenoma with surgical and medical therapy. *Pituitary* 6: 109-113.
64. Caron P, Gerbeau C, Pradayrol L, Simonetta C, Bayard F, 1996 Successful pregnancy in an infertile woman with a thyrotropin-secreting macroadenoma treated with somatostatin analog (octreotide). *J Clin Endocrinol Metab* 81:1164-1168.
65. Blackhurst G, Strachan MW, Collie D, Gregor A, Statham PF, Seckl JE, 2002 The treatment of a thyrotropin-secreting macroadenoma with octreotide in a twin pregnancy. *Clin Endocrinol (Oxf)* 57: 401-404.
66. Bronstein MD, Salgado LR, de Castro Musolino NR, 2002 Medical management of pituitary adenomas: the special case of management of the pregnant woman. *Pituitary* 5: 99-107.
67. Masding MG, Lees PD, Gawne-Caain ML, Sandeman DD, 2003 Visual field compression by anon-secreting pituitary tumour during pregnancy. *J R Soc Med* 96: 27-28.
68. Johnson RJ Jr, Voorhies RM, Witkin M, Robichaux AG III, Broussard WA Jr, 1993 Fertility following excision of a symptomatic craniopharyngioma during pregnancy: case report. *Surg Neurol* 39: 975-979.
69. Kodama T, Matsukado Y, Miura M, Takada A, 1986 Natural pregnancy and normal delivery after intracapsular irradiation for symptomatic craniopharyngioma-case report. *Neurol Med Chir (Tokyo)* 26: 40-43.
70. Maniker AH, Krieger AJ, 1996 Rapid recurrence of craniopharyngioma during pregnancy with recovery of vision: a case report. *Surg Oncol* 45: 324-327.
71. Caturegli P, Lupi I, Landek-Salgado M, Kimura H, Rose NR, 2008 Pituitary autoimmunity: 30 years later. *Autoimmun Rev* 7: 631-637.
72. Nishiki M, Muarakami Y, Ozawa Y, et al, 2001 Serum antibodies to human pituitary membrane antigens in patients with autoimmune lymphocytic hypophysitis and infundibuloneurohypophysitis. *Clin Endocrinol (Oxf)* 54: 327-333.
73. Gutenberg A, Buslei R, Fahlbusch R, Buchfelder M, Bruck W, 2005 Immunopathology of primary hypophysitis. Implications for pathogenesis. *Am J Surg Pathol* 29: 329-338.
74. Noto H, Tsukamoto K, Hoyashi S, Takano K, Fujita T, Kimura S, 2001 Spontaneous recovery from hypopituitarism in a man with lymphocytic hypophysitis: a case report. *Endocr J* 48: 483-486.
75. Kalra AA, Riel-Romero RM, Gonzalez-Toledo E, 2011 Lymphocytic hypophysitis in children: a novel presentation and literature review. *J Child Neurol* 26: 87-94.

76. Bellastella A, Bizzarro A, Coronella C, Bellastella G, Sinisi AA, De Bellis A, 2003 Lymphocytic hypophysitis: a rare or underestimated disease? *Eur J Endocrinol* 149: 363-376.
77. Caturegli P, Newschaffer C, Olivi A, Pomper MG, Burger PC, Rose NR, 2005 Autoimmune hypophysitis. *Endocr Rev* 26: 599-614.
78. Rivera J-A, 2006 Lymphocytic hypophysitis: disease spectrum and approach to diagnosis and therapy. *Pituitary* 9: 35-45.
79. Thodou H, Asa SL, Kontogeorgos G, Kovaks K, Horvath E, Ezzat S, 1995 Clinical case seminar: lymphocytic hypophysitis: clinicopathological findings. *J Clin Endocrinol Metab* 80: 2302-23011.
80. Gutenberg A, Hans V, Puchner MJ, et al, 2006 Primary hypophysitis: clinical-pathological correlations. *Eur J Endocrinol* 155: 101-107.
81. Lury KM, 2005 Inflammatory and infectious processes involving the pituitary gland. *Top Magn Reson Imaging* 16: 301-306.
82. Peruzzotti-Jametti L, Strambo D, Sangalli F, De Bellis A, Comi G, Sessa M, 2012 Bilateral intracavernous carotid artery occlusion caused by invasive lymphocytic hypophysitis. *J Stroke Cerebrovasc Dis*: 21:918.
83. Crock PA, 1998 Cytosolic autoantigens in lymphocytic hypophysitis. *J Clin Endocrinol Metab* 83: 609-618.
84. Castle D, de Villiers JC, Melvill R, 1988 Lymphocytic adenohypophysitis. Report of a case with demonstration of spontaneous tumour regression and a review of the literature. *Br J Neurosurg* 2: 401-405.
85. Feigenbaum SL, Martin MC, Wilson CB, Jaffe RB, 1991 Lymphocytic adenohypophysitis: a pituitary mass lesion occurring in pregnancy. Proposal for medical treatment. *Am J Obstet Gynecol* 164: 1549-1555.
86. Kristof RA, Van Roost D, Klingmuller D, Springer W, Schramm J, 1999 Lymphocytic hypophysitis: non-invasive diagnosis and treatment by high dose methylprednisolone pulse therapy? *J Neurol Neurosurg Psychiatry* 67: 398-402.
87. Reusch JE, Kleinschmidt-DeMasters BK, Lillehei KO, Rappe D, Gutierrez-Hartmann A, 1992 Preoperative diagnosis of lymphocytic hypophysitis (adenohypophysitis) unresponsive to short course dexamethasone case report. *Neurosurgery* 30: 268-272.
88. Beressi N, Beressi JP, Cohen R, Modigliani E, 1999 Lymphocytic Hypophysitis. A review of 145 cases. *Ann Med Interne (Paris)* 150: 327-341.
89. Sheehan HL, 1965 The frequency of post-partum hypopituitarism. *J Obstet Gynaecol Br Commonw* 72: 103-111.
90. Feinberg EC, Molitch ME, Endres LK, Peaceman AM, 2005 The incidence of Sheehan's syndrome after obstetric hemorrhage. *Fertil Steril* 84: 975-979.
91. Kelestimur F, 2003 Sheehan's Syndrome. *Pituitary* 6: 181-188.
92. Dejager S, Gerber S, Foubert L, Turpin G, 1998 Sheehan's Syndrome: differential diagnosis in the acute phase. *J Intern Med* 244: 261-266.
93. Lavalee G, Morcos R, Palardy J, Aube M, Gilbert D, 1995 MR of nonhemorrhagic postpartum pituitary apoplexy. *Am J Neuroradiol* 16: 1939-1941.
94. Dash RJ, Gupta V, Suri S, 1993 Sheehan's Syndrome: clinical profile, pituitary hormone responses and computed sellar tomography. *Aust N Z J Med* 23: 26-31.
95. De Bellis A, Kelestimur F, Sinisi AA, et al, 2008 Anti-hypothalamus and anti-pituitary antibodies may contribute to perpetuate the hypopituitarism in patients with Sheehan's syndrome. *Eur J Endocrinol* 158: 147-152.
96. Kelestimur F, Jonsson P, Molvalilar S, et al, 2005 Sheehan's Syndrome: baseline characteristics and effect of 2 years of growth hormone replacement therapy in 91 patients in KIMS. *Eur J Endocrinol* 152: 581-587.
97. Soares DV, Spina LD, De Lima Oliveira Brasil RR, et al, 2006 Two years of growth hormone replacement therapy in a group of patients with Sheehan's syndrome. *Pituitary* 62: 127-135.
98. See TT, Lee SP, Chen HF, 2005 Spontaneous pregnancy and partial recovery of pituitary function in a patient with Sheehan's syndrome. *J Chin Med Assoc* 68: 187-190.
99. Regal M, Páramo C, Sierra SM, Garcia-Mayor RV, 2001 Prevalence and incidence of hypopituitarism in an adult Caucasian population in northwestern Spain. *Clin Endocrinol (Oxf)* 55: 735-740.
100. Bülow B, Hagmar L, Mikoczy Z, Nordström CH, Erfurth EM, 1997 Increased cerebrovascular mortality in patients with hypopituitarism. *Clin Endocrinol (Oxf)* 46: 75-81.
101. Trainer PI, 2002 Corticosteroids and pregnancy. *Semin Reprod Med* 20: 375-380.
102. Abalovich M, Amino N, Barbour LA, et al, 2007 Management of thyroid dysfunction during pregnancy and postpartum: an endocrine society clinical practice guideline. *J Clin Endocrinol Metab* 92: Suppl: 1-47.
103. Pop VJ, Brouwers EP, Vader HL, Vulmsa T, van Baar AL, de Vijlder JJ, 2003 Maternal hypothyroxinemia during early pregnancy and subsequent child development: a 3-year follow up study. *Clin Endocrinol (Oxf)* 59: 282-288.
104. Sakai S, Wakasugi T, Yagi K, et al, 2011 Successful pregnancy and delivery in a patient with adult growth hormone deficiency: role of GH replacement therapy. *Endocr J* 58: 65-68.
105. Salle A, Klein M, Pascal-Vigneron V, Dousset B, Leclere J, Weryha G, 2000 Successful pregnancy and birth after sequential cotreatment with growth hormone and gonadotropins in a woman with panhypopituitarism: a new treatment protocol. *Fertil Steril* 74: 1248-1250.
106. Kallen BA, Carlsson SS, Bengtsson BK, 1995 Diabetes insipidus and use of desmopressin (Minirin) during pregnancy. *Eur J Endocrinol* 132: 144-146.
107. Ray JG, 1998 DDAVP use during pregnancy: an analysis of its safety for mother and child. *Obstet Gynecol Sur* 53: 450-455.