

# Pleuropericardial cyst torsion: case report

## Torção de cisto pleuropericárdico: relato de caso

Davi Wen Wei Kang<sup>1</sup>, Maria Carolina Ercoli Corpa<sup>2</sup>, Marcelo de Castro Jorge Racy<sup>3</sup>, Ronaldo Hueb Baroni<sup>4</sup>, Fabiano Cataldi Engel<sup>5</sup>, Laert de Oliveira Andrade Filho<sup>6</sup>, Marco Aurélio Scarpinella Bueno<sup>7</sup>

### ABSTRACT

Pericardial cysts account for 12-18% of all mediastinal masses. They are usually asymptomatic and incidentally detected. However, when large, they can cause symptoms. Most pericardial cysts are located in the right cardiophrenic angle, but they can be anywhere in the mediastinum. We reported a pleuropericardial cyst torsion after physical stress, a very rare complication of this condition. The diagnosis was made by computed tomography and confirmed by video-assisted thoracoscopy.

**Keywords:** Mediastinal cyst; Torsion abnormality; Diagnostic imaging; Case reports

### RESUMO

Cistos pericárdicos constituem 12-18% de todas as massas mediastinais. Geralmente, são assintomáticos e detectados incidentalmente, podendo manifestar sintomas quando alcançam um tamanho aumentado. Na maioria das vezes, estão situados no seio cardiofrênico direito, mas podem ocupar outra localização no mediastino. Neste artigo, relatamos uma torção de cisto pleuropericárdico após esforço físico, uma complicação raríssima dessa condição, cujo diagnóstico foi realizado por meio da tomografia computadorizada do tórax e confirmado posteriormente por videotoracoscopia.

**Descritores:** Cisto mediastínico; Anormalidade torcional; Diagnóstico por imagem; Relatos de casos

### INTRODUCTION

Pericardial cysts are also known as mesothelial, pleuropericardial or pericardial celomic cysts and result

from aberrations in the development of the celomic cavities. They are made up of connective tissue and a layer of mesothelial cells and usually contain a serous fluid inside. They are always attached to the pericardium, although a visible communication between the cyst and the pericardium is rarely found in surgeries<sup>(1-2)</sup>. Most cysts originate from the anterior cardiophrenic angle, more frequently on the right side (77%), as compared to the left side (22%)<sup>(3-4)</sup> and account for 12-18% of mediastinal tumors<sup>(5)</sup>. Its incidence is of, approximately, 1:100,000 persons<sup>(4)</sup>. About 75% of the cysts are asymptomatic, and they are incidentally found in chest radiographs and echocardiograms.

There are reports in the literature of giant cysts<sup>(6)</sup>, atypical location cysts (anterior and posterior mediastinum), in different shapes<sup>(7)</sup>, associated to other diseases – Fanconi anemia<sup>(8)</sup> – and hemorrhagic cysts<sup>(9-10)</sup>. Bava et al.<sup>(11)</sup> described a case of torsion of the cyst intrapericardial pedicle with consequent ischemia and tamponade<sup>(11)</sup>.

The present case is of a pericardial cyst that suffered torsion over its own axis, leading to one ischemic portion and another that was intact as far as vascularization is concerned, and the diagnosis was carried out by means of a computed tomography (CT) scan with multidetectors, later confirmed by video-assisted thoracoscopy.

### CASE REPORT

A male 49-year-old patient was admitted to the emergency department with pain on the right

*Study carried out at Hospital Israelita Albert Einstein – HIAE, São Paulo (SP), Brazil.*

<sup>1</sup> MD; Thoracic Surgeon of Hospital Israelita Albert Einstein – HIAE, São Paulo (SP), Brazil.

<sup>2</sup> MD; Post-graduate degree in Computed Tomography and Magnetic Resonance Imaging at Hospital Israelita Albert Einstein – HIAE, São Paulo (SP), Brazil.

<sup>3</sup> PhD; Radiologist of Hospital Israelita Albert Einstein – HIAE; Assistant Physician of Santa Casa de Misericórdia de São Paulo – SCMSp, São Paulo (SP), Brazil.

<sup>4</sup> MD; Radiologist of Hospital Israelita Albert Einstein – HIAE; Assistant Physician of Instituto de Radiologia do Hospital das Clínicas da Faculdade de Medicina da Universidade de São Paulo – USP, São Paulo (SP), Brazil.

<sup>5</sup> MD; Thoracic Surgeon of Hospital Israelita Albert Einstein – HIAE; Assistant Physician of Thoracic Surgery Department of Complexo Hospitalar do Mandaqui, São Paulo (SP), São Paulo (SP), Brazil.

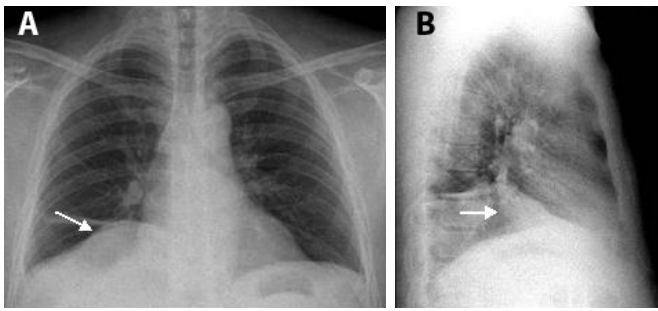
<sup>6</sup> MD; Thoracic Surgeon of Hospital Israelita Albert Einstein – HIAE, São Paulo (SP), São Paulo (SP), Brazil.

<sup>7</sup> PhD; Pneumologist of Hospital Israelita Albert Einstein – HIAE, São Paulo (SP), Brazil.

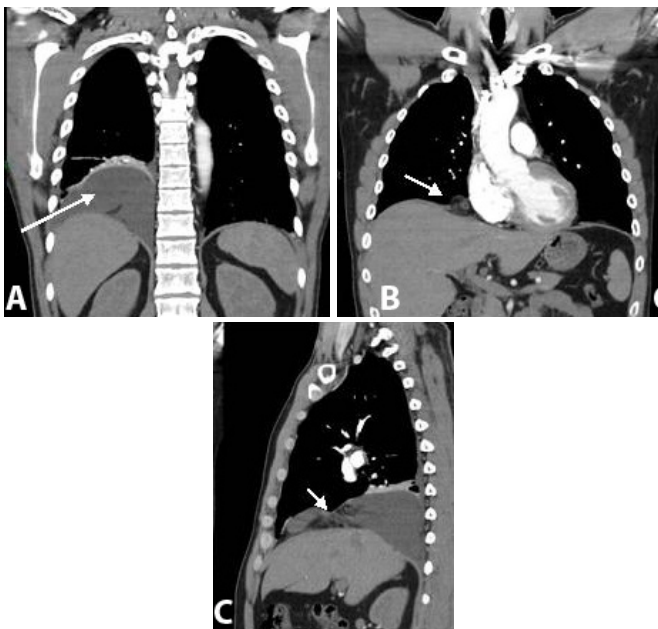
Corresponding author: Davi Wen Wei Kang – Avenida Rebouças, 2849 – Pinheiros – CEP 05401-350 – São Paulo (SP), Brasil – Tel.: 11 3062-8122 – e-mail: daviwenk@einstein.br

Received on Jul 2, 2008 – Accepted on Mar 31, 2010

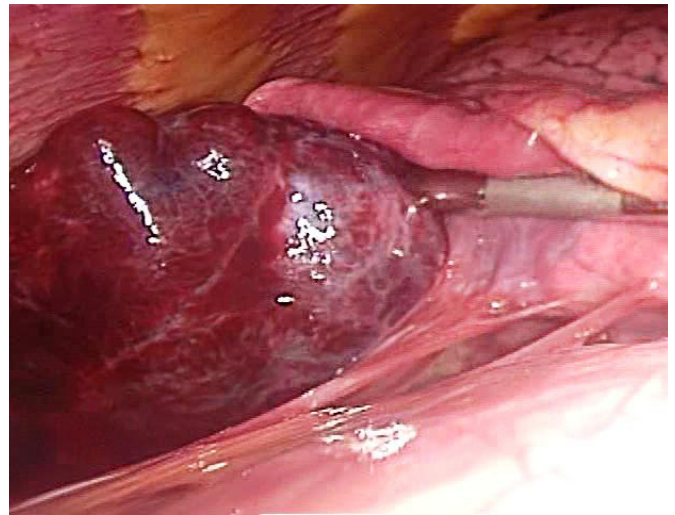
hemothorax for two days, after physical exertion, which worsened with movement and during inhalation; he presented no dyspnea or fever. Chest radiographs with posteroanterior and lateral views showed a well-defined oval-shaped homogeneous mass, adjacent to the heart, in the right cardiophrenic angle, with a visible right-side heart margin and laminar atelectasis adjacent to it (Figure 1). He was then submitted to a CT scan under a study protocol for pulmonary thromboembolism, based on the patient's clinical history, which demonstrated the pleuropericardial cyst on the right hemithorax base (Figure 2), with its anterior portion in contact with the pericardial fat and posterior portion in contact with the pleural surface, measuring 17 x 12.5 cm in its longest axis. In its mid-anterior view, the mass was filled by fat tissue and dense linear structures, which suggested torsion (Figures 3 and 4).



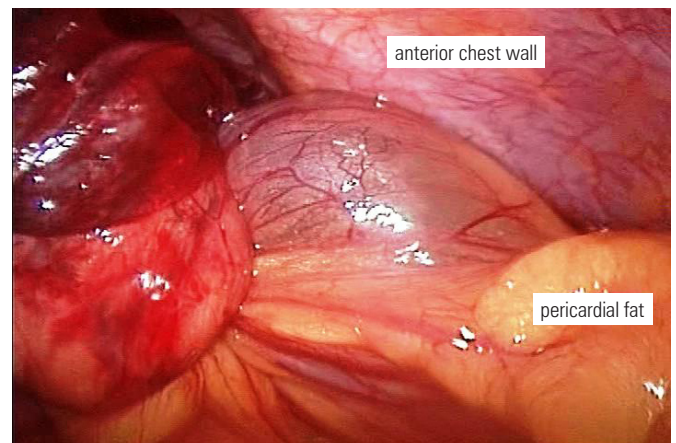
**Figure 1.** (A) Chest radiograph in PA view showing a well-defined homogeneous mass in the right cardiophrenic angle, with a clearly visible right-side heart margin and laminar atelectasis adjacent to it. (B) Chest radiograph in lateral view shows the mass predominantly on the posterior position.



**Figure 2.** Computed tomography. (A) Coronal section shows a pleuropericardial cyst on the right hemithorax base. (B) Coronal section: in the mid-anterior view, the cyst is filled by fat tissue and dense linear structures ("whirl sign"), suggesting torsion. (C) Sagittal section: torsion site (arrow).



**Figure 3.** Posterior portion of the cyst showing firm adhesences between the lung (raised by the forceps) and the diaphragm, besides the ischemic aspect of the cyst.



**Figure 4.** Anterior portion of the cyst showing ischemic cyst (on the left), the torsion region and the whole cyst that is attached to pericardial fat.

## DISCUSSION

This is a very peculiar case because the "whirl sign", originally described in intestinal volvulus, was evident, indicating torsion of the pleuropericardial cyst. Fischer described such sign on CT scan as a mass of soft tissue in which there was an internal intertwine with fat and soft tissue attenuation<sup>(12-13)</sup>. In this case, the spiral shape seen on multidetector CT scan indicated torsion of the mediastinal cyst pedicle. With the development of devices with multidetectors, the twisted pedicle can be seen, thus providing the ultimate diagnosis in this case<sup>(14)</sup>. Contrast CT scan has been described as the gold standard for diagnosis and follow-up of pericardial cysts; it shows the cyst as a homogeneous mass, with well-defined contours and thin walls<sup>(3,13,15)</sup>.

Cysts are occasionally pedicled<sup>(2)</sup>. Their attenuation is a bit higher than water density, up to 30 to 40 UH, because of their viscous material, sometimes simulating solid masses<sup>(3,15,16)</sup>.

Most cystic lesions found in the cardiophrenic space are benign. Image findings (US, CT and MRI) are very useful in order to establish whether the lesion is cystic or solid. According to the literature, usually those purely cystic lesions are benign<sup>(3)</sup>. Differential diagnosis can be made considering other mediastinal cystic masses, especially bronchiogenic cyst, which has similar characteristics, although its location in the cardiophrenic space is atypical. Hydatid cyst is another uncommon cystic lesion that may affect this area, when there is a herniation through the Morgagni foramen<sup>(3)</sup>.

These cysts are usually asymptomatic; however, when large then can cause symptoms, such as retrosternal chest pain, dyspnea and cough<sup>(7,17)</sup>. There are descriptions of some severe complications associated with pericardial cysts, such as right ventricular obstruction, pulmonary stenosis, cardiac tamponade<sup>(10-11)</sup>, partial erosion of the superior vena cava and congestive heart failure<sup>(18)</sup>. They usually appear on the fourth and fifth decades of life and there are no gender differences<sup>(15,19)</sup>. Nonetheless, they are considered congenital, since in their pathophysiology there is a fusion failure of the primitive pericardial lacunas or because of formation of abdominal folds on the embryological pleura during the process of pericardium development<sup>(3,17,20)</sup>.

The treatment of the pericardial cyst is still controversial in the literature, and its management is diverse: watchful waiting, percutaneous aspiration of the cyst content, followed by sclerosis or not<sup>(21)</sup>, and surgical resection.

Those who advocate that treatment by surgical resection is not necessary argue that the pericardial cysts do not have a malignant potential, making the procedure only indicated in cases of diagnostic doubt (atypical location or high density seen on CT) or when there are symptoms. On the other hand, we are not sure about the future clinical behavior of these cysts.

Percutaneous aspiration is a treatment mode reported in the literature with no evidence of recurrence in the short/mid-run; however, there are no long-term follow-up data or comparative studies against surgical resection. It is usually coupled to some imaging method, such as an echocardiogram or chest CT scan in order to reduce the risk of complications from the puncture<sup>(22)</sup>.

Videothoracoscopy may be considered the method of choice for resection of pericardial cysts<sup>(23,24)</sup>, since they do not tend to malignization. Even in giant cysts, videothoracoscopy is feasible, since it is possible to open the cyst and drain its fluid content in order to remove the cyst capsule through a small incision on the chest wall<sup>(25)</sup>. There is also a description of robotic surgery for pericardial cysts, through smaller incisions and minimum blood loss<sup>(26)</sup>.

We believe that surgical resection is the treatment of excellence for asymptomatic and symptomatic pericardial cysts. Watchful waiting can be risky because of the rare but severe complications already described in the literature. Percutaneous aspiration of pericardial cyst must be used only in selected cases: comorbidities that contraindicate surgical resection, temporary decompression preceding a symptomatic cyst resection<sup>(27)</sup> and patient's refusal to surgery.

## REFERENCES

1. Kim JH, Goo JM, Lee HJ, Chung MJ, Jung SI, Lim KY, et al. Cystic tumors in the anterior mediastinum. Radiologic-pathological correlation. *J Comput Assist Tomogr.* 2003;27(5):714-23.
2. Jeung MY, Gasser B, Gangi A, Bogorin A, Charneau D, Wihlm JM, et al. Imaging of cystic masses of the mediastinum. *Radiographics.* 2002; 22 Spec No: S79-93.
3. Pineda V, Andreu J, Cáceres J, Merino X, Varona D, Domínguez-Oronoz R. Lesions of the cardiophrenic space: findings at cross-sectional imaging. *Radiographics.* 2007;27(1):19-32.
4. Stoller JK, Shaw C, Matthay RA. Enlarging, atypically located pericardial cyst. Recent experience and literature review. *Chest.* 1986;89(3):402-6.
5. Takeda S, Miyoshi S, Minami M, Ohta M, Masaoka A, Matsuda H. Clinical spectrum of mediastinal cysts. *Chest.* 2003;124(1):125-32.
6. Nina VJS, Manzano NCE, Mendes VGC, Salgado-Filho N. Giant pericardial cyst: case report. *Rev Bras Cir Cardiovasc.* 2007;22(3):349-51.
7. Ozturk E, Aparci M, Haholu A, Sonmez G, Mutlu H, Basekim CC, et al. Giant, dumbbell-shaped pericardial cyst. *Tex Heart Inst J.* 2007;34(3):386-7.
8. Balci YI, Tavil B, Akinci D, Karcaaltincaba M, Gümruk F. Diaphragmatic mesothelial cyst in a child with Fanconi aplastic anemia. *J Pediatr Hematol Oncol.* 2007;29(12):860-1.
9. McLeod AL, Dewhurst NG. An unusual cause of chest pain. *Scott Med J.* 2002;47(2):38-9.
10. Tanoue Y, Fujita S, Kanaya Y, Tominaga R. Acute cardiac tamponade due to a bleeding pericardial cyst in a 3-year-old child. *Ann Thorac Surg.* 2007;84(1):282-4.
11. Bava GL, Magliani L, Bertoli D, Gorrieri PF, Rimini A, Zaccagnini G, et al. Complicated pericardial cyst: atypical anatomy and clinical course. *Clin Cardiol.* 1998;21(11):862-4.
12. Khurana B. The whirl sign. *Radiology.* 2003;226(1):69-70.
13. Fisher JK. Computed tomographic diagnosis of volvulus in intestinal malrotation. *Radiology.* 1981;140(1):145-6.
14. Agarwal PP, Seely JM, Matzinger FR. Wandering pleuropericardial cyst. *J Comput Assist Tomogr.* 2006;30(2):276-8.
15. Mouroux J, Venissac N, Leo F, Guillot F, Padovani B, Hofman P. Usual and unusual locations of intrathoracic mesothelial cysts. Is endoscopic resection always possible? *Eur J Cardiothorac Surg.* 2003;24(5):684-8.
16. Brunner DR, Whitley NO. A pericardial cyst with high CT numbers. *AJR Am J Roentgenol.* 1984;142(2):279-80.
17. Daskalopoulos DA, Kuhn JP, Gingell RL, Pieroni DR. Diagnosis of pericardial cyst in a young child by computed tomography of the thorax. *Tex Heart Inst J.* 1983;10(1):63-5.
18. Komodromos T, Lieb D, Baraboutis J. Unusual presentation of a pericardial cyst. *Heart Vessels.* 2004;19(1):49-51.
19. Zambudio AR, Lanzas JT, Calvo MJ, Fernández PJ, Paricio PP. Non-neoplastic mediastinal cysts. *Eur J Cardiothorac Surg.* 2002;22(5):712-6.

20. Allen MS. Cysts and duplication in adults. In: Pearson FG, Cooper JD, Deslauriers J, Ginsberg RJ, Hiebert CA, Patterson GA, et al, editors. Thoracic surgery. Philadelphia: Churchill Livingstone; 2002. p. 1647-53.
21. Kinoshita Y, Shimada T, Murakami Y, Sano K, Tanabe K, Ishinaga Y, et al. Ethanol sclerosis can be a safe and useful treatment for pericardial cyst. *Clin Cardiol*. 1996;19(10):833-5.
22. Butz T, Faber L, Langer C, Wiemer M, Horstkotte D, Piper C. Images in cardiovascular medicine. Echocardiography-guided percutaneous aspiration of a large pericardial cyst. *Circulation*. 2007;116(18):e505-7.
23. Menconi GF, Ambrogi MC, Mussi A, Melfi FM, Davini F, Roggi G, et al. [Diagnosis and treatment of pleuro-pericardial cysts. Role of videosurgery]. *Minerva Chir*. 1998;53(7-8):587-92.
24. Cangemi V, Volpino P, Gualdi G, Poletti E, Frati R, Cangemi B, et al. Pericardial cysts of the mediastinum. *J Cardiovasc Surg (Torino)*. 1999;40(6):909-13.
25. Samuels LE, Cassano A. Videoscopic resection of a giant symptomatic pericardial cyst: case report. *Heart Surg Forum*. 2005;8(2):E83-4.
26. Bacchetta MD, Korst RJ, Altorki NK, Port JL, Isom OW, Mack CA. Resection of a symptomatic pericardial cyst using the computer-enhanced da Vinci Surgical System. *Ann Thorac Surg*. 2003;75(6):1953-5.
27. Menon P, Rao KL, Trehan A. Preoperative aspiration for anterior mediastinal cyst with respiratory distress. *Indian Pediatr*. 2003;40(9):897-900.