

"PNEUMOCYSTIS CARINII": ITS INCIDENCE IN RODENTS AND ENHANCEMENT OF THE INFECTION BY CORTICOSTEROIDS^{1*}

HELLY A. LAGE ** and SUELENA A. LAGE **

Instituto Oswaldo Cruz, Rio de Janeiro, Guanabara
(With 8 figures)

SUMMARY: A survey was made on the incidence of *Pneumocystis carinii* in 361 rodents including sewer rats, albino rats, albino mice, guinea-pigs and rabbits. *P. carinii* was found in 4 of the 215 *Rattus norvegicus* examined (1.8%). These results accord with recent observations but disagree with investigations made by the researchers who first studied this parasite in the past when high indexes of infection were found. However, in 20 albino rats treated with corticosteroids (betamethazone) we found 8 positive (40%) and in 20 albino mice treated by the same way, 9 were positive for *P. carinii* (45%). These results confirm the opportunistic character of *P. carinii* in rodents already well demonstrated in man.

ALTHOUGH *Pneumocystis carinii* was first described in rodents and in man in Brazil by Carlos Chagas (1909-1911) and subsequently studied by some Brazilian investigators at that time (1, 5, 18), it has then been forgotten for some years. In the last years some papers appeared on this subject here (2, 4, 14, 16). Notwithstanding in the last issue (1969) of "Pesquisas em Progresso no Brasil" we could not find any report on *P. carinii*. On the contrary European and American literature are very extensive (3, 8, 9 to 13, 15, 17, 19), specially after this parasite was recognized as the cau-

sative agent of young infant's pneumonia ("Interstitial Plasma Cell Pneumonia") (10, 11, 17). Lately *P. carinii* has been observed associated with other pulmonary disorders of children and adults specially of those treated with corticosteroids on account of leukemia or lymphoma and in hypogammaglobulinemic children (3, 9, 12, 16, 19).

This report is concerned with the incidence of *P. carinii* in laboratory rodents and sewer rats of Rio de Janeiro and some observations on the enhancement of the infection by corticosteroids.

1 Recebido para publicação a 22 de dezembro de 1972.

* Paper of Instituto Oswaldo Cruz partially supported by Grants of "Conselho Nacional de Pesquisas".

** Laboratório de Protozoologia, Instituto Oswaldo Cruz, C.P. 926. Guanabara. Brasil.

MATERIAL AND METHODS

Animals — The animals used in these experiments were laboratory rodents and sewer rats received from “Serviço de Controle da Peste” (Health Ministry, Brazil).

From the lungs of animals dead or sacrificed a piece was taken to make smears either by imprint or by tearing it into small pieces and crushing it between two slides. After fixation by methyl-alcohol the smears were stained by the conventional Giemsa-method or by strong Giemsa (3 drops/ml — 15 min.).

Paraffin sections were made from the rest of the organ previously fixed in 10% formalin or in Carnoy's fixative and stained with hematoxylin-eosin, periodic acid-Schiff (PAS) and McNamara.

Corticosteroid-treated animals — *a)* A group of 20 albino rats received 8 doses of 1.5 mg of betamethazone* during 10 days. *b)* A group of 20 albino mice received 10 doses of 0.4 mg of betamethazone during 15 days.

Human lungs — Lungs of 4 stillborn or liveborn babies (all of them suffering of pulmonary diseases) were examined after the same staining techniques referred above. Suspensions of those organs triturated in saline were inoculated directly into the lungs or by nasal instillation in 4 groups of 6 suckling-mice. One month after inoculation these mice were treated with betamethazone as described for the other groups.

RESULTS

Table I summarizes the natural infection. A total of 361 rodents belonging to 8 species were examined. *P. carinii* was found in 4 *Rattus norvegicus* only (1.8% of positivity for the

species and 1.1% for the total of animals examined).

Negative results were also found for one specimen of *Akodon arvicantis* and another of *Oryzomys elliurus*.

From the animals treated with corticosteroids, 8 (40%) of the albino rats and 9 (45%) of the 20 albino mice showed *P. carinii* in smears and/or in sections.

Histopathological findings — In the sections of the corticosteroid-treated animals we could sometimes find foamy cells in the alveolar spaces. (Plate I, figures 1 and 2). Parasites were seen in these lesions in the alveoli and in the alveolar lining. However the so-called honeycombed aspect, considered by some authors to be characteristic of this infection, was never observed.

Parasites — The parasites in Giemsa-stained material appeared as fully developed cysts limited by a thin capsule and containing eight crescentic shaped spores. The spores stained blue each with a red nucleus encircled by a clear zone. (Plate II, figures 2 to 5). In some occasions we could observe smaller cysts with eight corpuscles not so well defined. (Plate II, figure 1). In sections earlier developmental stages were seen. Cysts with one, two, four or eight bodies were present in the alveoli. (Plate II, figure 6).

Preparations made from human lungs were negative for *P. carinii* and so were the inoculations made with this material into mice even after corticosteroid treatment.

* Schering's "Celestone" (R) — 9-alpha-fluor-16-beta-methyl-prednisolone.

TABLE I

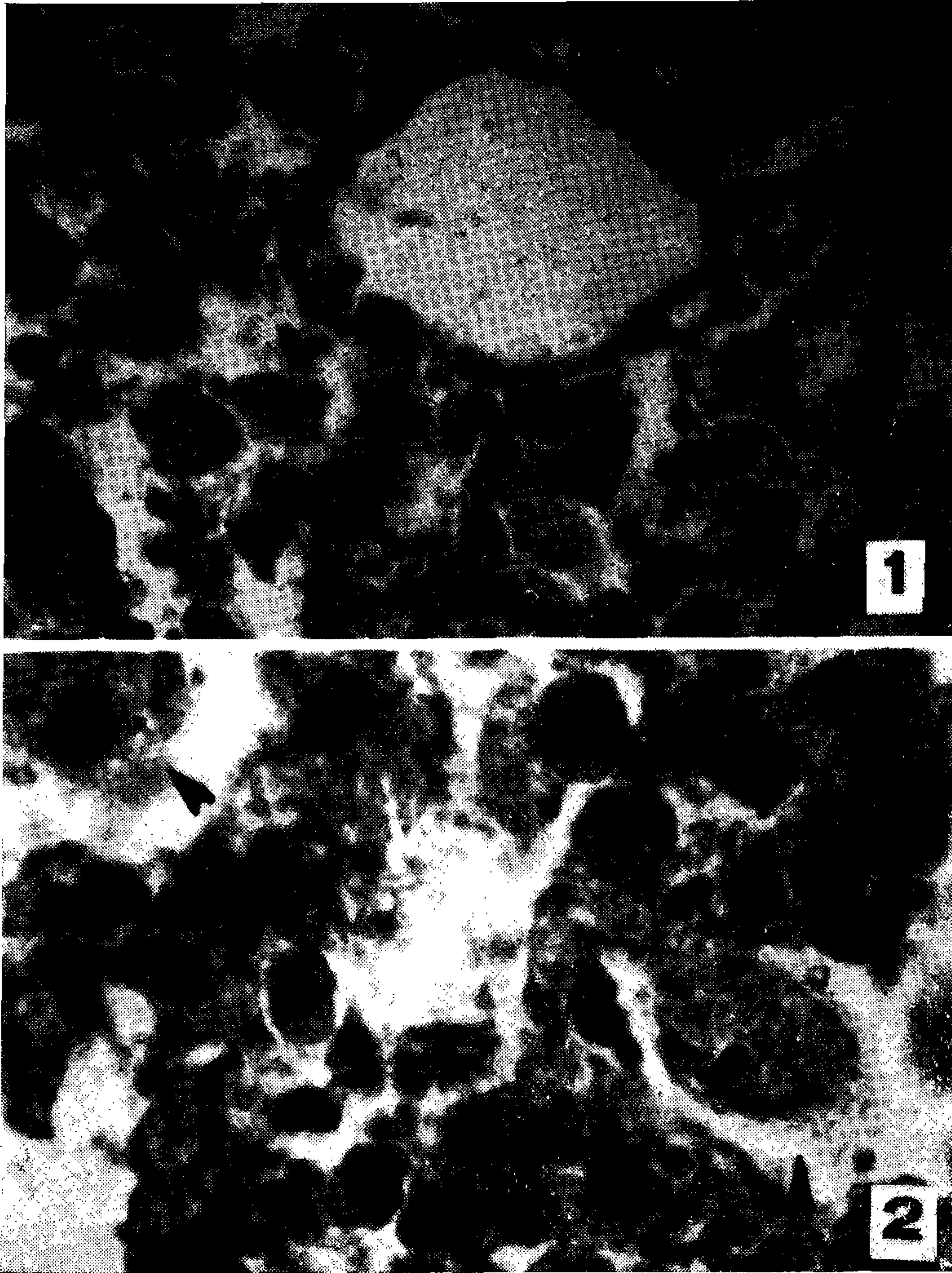
"PNEUMOCYSTIS CARINII" IN LABORATORY RODENTS AND SEWER RATS OF RIO DE JANEIRO

Animals	N.º of animals examined	N.º of animals with <i>P. carinii</i>	%
<i>Rattus norvegicus</i>	215	4	1.8
<i>R. alexandrinus</i>	10	0	—
<i>R. frugivorus</i>	10	0	—
<i>R. rattus</i>	4	0	—
Albino rats	15	0	—
Albino mice	58	0	—
Guinea-pigs	17	0	—
Rabbits	32	0	—
Totals	361	4	1.1

TABLE II

"P. CARINII" IN LABORATORY RODENTS TREATED WITH BETAMETHAZONE

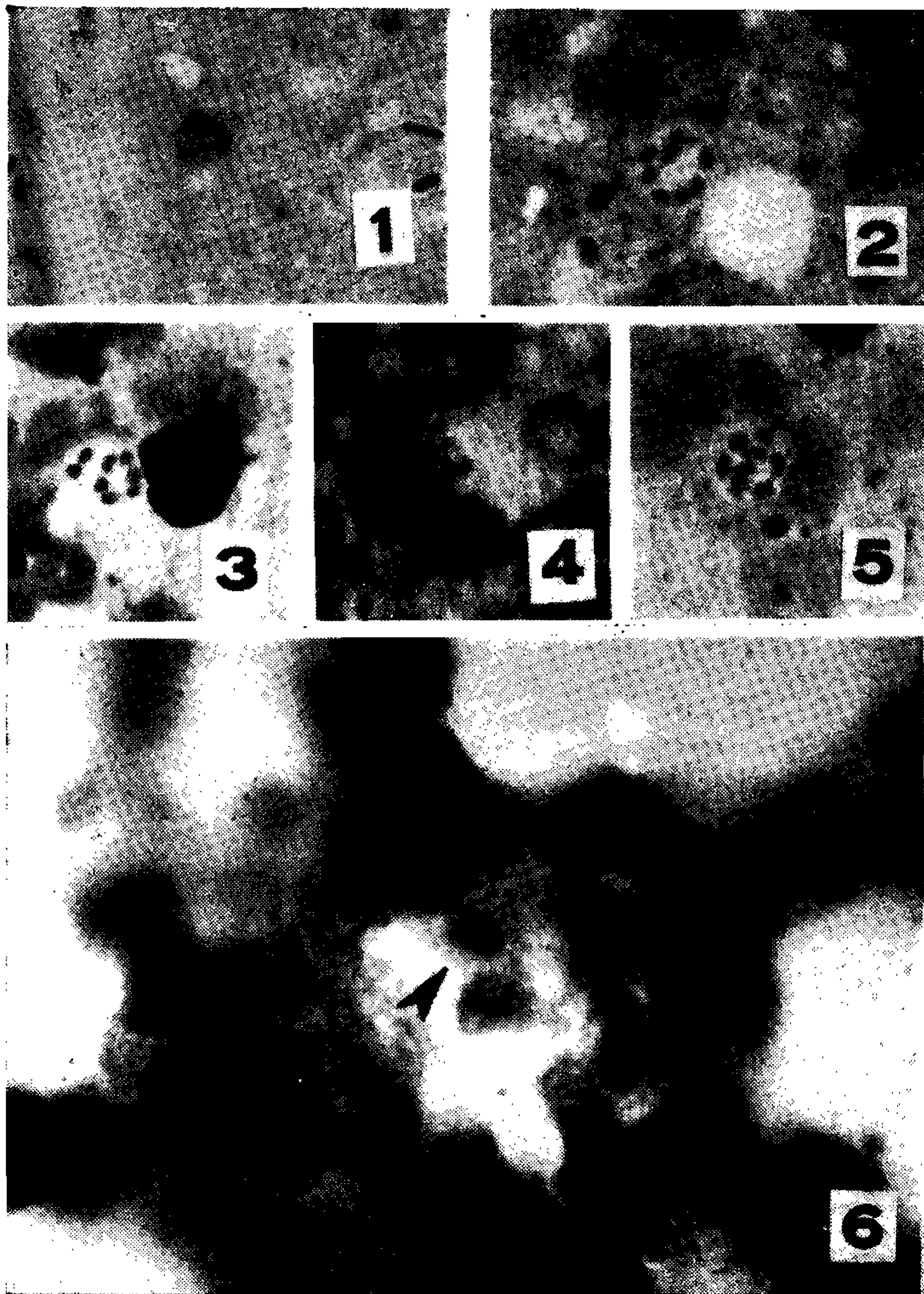
Animals	N.º of animals examined	N.º of animals with <i>P. carinii</i>	%
Albino rats	20	8	40
Albino mice	20	9	45
Totals	40	17	42,5



Lung section of betamethazone-treated albino mice.

Figure 1 — General aspect of lesions with numerous foamy cells. (Hematoxylin-eosin, $\times 400$).

Figure 2 — Portion of figure 1 magnified to show foamy cells (arrows). (Hematoxylin-eosin, $\times 1.000$).



Pneumocystis carinii. Figures 1 to 5 — Lungs imprints of sewer rats (*Rattus norvegicus*) showing cysts with eight spores. (Giemsa stain, $\times 1.000$).

Figure 6 — Lung section of betamethazone-treated albino rat showing a cyst in the alveolus (arrow). (Hematoxylin-eosin, $\times 1.200$).

DISCUSSION

In natural conditions, excepting *R. norvegicus*, all the other animals were negative for *P. carinii*. This fact may be explained by the smaller number of animals examined in each group. The positivity found for *R. norvegicus* (1.8%) is based in the examen of 215 specimens and accords with the observations of other investigators. **Cabral** (1956) found only two animals positive (0.6%) in a survey of 301 sewer rats. Even in other animals he found small percentages: 1.4% of positivity in 215 guinea-pigs. Nevertheless in the first years of study of *P. carinii* several authors referred much higher indexes of infection; for example, **Aragão** (1913) in Rio, referred: 28.6% for sewer rats; 25.8% for rabbits and 23.9% for guinea-pigs. In young adult sewer rats from Paris, **Delanoë & Delanoë** (1912) found 100% of infections (22 positive in 22 examined). So, at present, in natural conditions, the incidence of *P. carinii* in rodents is much smaller than it had been referred sixty years ago.

Comparing the results of the corticosteroid-treated and untreated animals, the rate of infection of those which received betamethazone was relatively high. The positivity of the treated albino rats was 40% and of the treated albino mice was 45%. However, the untreated groups of both animals were completely nega-

tive. These observations accord with the results referred by many authors, specially **Frenkel** (1966). So the opportunistic character of pneumocystosis, already demonstrated in humans (9, 10, 11, 19) is valid for animals.

SUMÁRIO

Foi feita uma investigação sobre a ocorrência de *P. carinii* em 361 roedores, incluindo ratos de esgoto, ratos albinos, camundongos albinos, cobaias e coelhos. Só foram encontrados positivos 4 *Rattus norvegicus* em 215 examinados (1.8%). Estes resultados estão de acordo com observações feitas nos últimos anos, os quais contrastam com as verificações feitas nos primeiros anos de estudo do *P. carinii*, quando foram assinalados altos índices infecciosos. Entretanto, em 20 ratos albinos tratados com corticosteróides (betametasona) foram encontrados 8 positivos (40%); e em 20 camundongos albinos, tratados do mesmo modo, foram encontrados 9 positivos (45%). Estes resultados confirmam o caráter oportunístico do *P. carinii* nos roedores, do mesmo modo como acontece no homem.

ACKNOWLEDGEMENTS

We want to thank Dr. Mario Santos for furnishing the sewer rats and Dr. Aparecida Garcia for the material of human origin. We are also grateful to Mr. Nilton Azevedo and Mrs. Maria da Penha Costa for preparing the photomicrographs.

REFERÊNCIAS BIBLIOGRÁFICAS

- 1 — ARAGÃO, H. DE B. — 1913 — “Nota sobre as schizogonias e gametogonias dos trypanosomos”. *Bras. Med.* 27:271-2.
- 2 — BRANDÃO, I.A.F.; CHAMMAS, F. & DE BRITO, T. — 1967 — “Pneumonia Intersticial Aguda na Infância”. *Matern. Inf. São Paulo* 26(4):391-4.
- 3 — BURKE, BARBARA A.; KROVETZ, J. L. & GOOD, R. A. — 1961 — “Occurrence of *Pneumocystis carinii* in children with agammaglobulinemia” — *Pediatrics* 28(2):196-205.
- 4 — CABRAL, A.S. — 1956 — “Notas sobre o *Pneumocystis carinii*. Raridade atual deste parasito em animais de laboratório”. *Mem. Inst. Oswaldo Cruz* 54(1):87-91 (1 fig.).
- 5 — CARINII, A. — 1914 — “Formas de Schizogonia do *Trypanozoma lewisi*”. *Ann. Paul. Soc. Med. e Cir.*, 205.
- 6 — CHAGAS, C. — 1909 — “Nova tripanozomiase humana”. *Mem. Inst. Oswaldo Cruz* 1(2):159-218 (5 plates and 10 figures)
- 7 — DELANOË, P. & DELANOË M^{me}. — 1912 — Sur les rapports des Cystes de Carinii du poumon des rats avec le *Trypanosoma lewisi*. *C. R. Acad. Sci.*, 155:658.
- 8 — FRENKEL, J. K.; GOOD, J. T. & SCHULTZ, A. — 1966 — “Latent Pneumocystis Infection of Rats, Relapse and Chemotherapy”. *Lab. Invest.* 15(10):1559-1577.
- 9 — FRENKEL, J. K. — 1968 — “Experimental Model of Pneumocystosis in Rats. Pathogenesis and Therapy”. *Abstracts of the 8th Intern. Cong. trop. Med. Mal.* 7-15 Sept. Teheran-Iran., p. 928.
- 10 — GAJDUSEK, D. C. — 1957 — “*Pneumocystis carinii* — Etiologic Agent of Interstitial Plasma Cell Pneumonia of Premature and Young Infants” *Pediatrics* 19(4) Part I: 543-565.
- 11 — GOETZ, O. — 1968 — “The significance of *Pneumocystis carinii* as etiologic factor in pneumonia of infants and children”. *Abstracts of the 8th Intern. Cong. trop. Med. Mal.* 7-15 Sept - Teheran-Iran., p. 930.
- 12 — JÍROVEC, O. — 1968 — “Les problemes concernant la Pneumocystose de l'enfant et de l'adulte”. *Abstracts of the 8th Intern. Cong. trop. Med. Mal.* 7-15 Sept. Teheran-Iran.
- 13 — KUCERA, K. — 1968 — “Our results on the epidemiologic survey in Pneumocystosis”. *Abstracts of the 8th Intern. Cong. trop. Med. Mal.* 7-15 Sept. Teheran-Iran.
- 14 — LUISI, A. — 1960 — “Pneumonia Pneumocística”. *Matern. Inf.*, São Paulo 19(2):157-167. (7 fig.).
- 15 — SHELDON, W. H. — 1959 — “Experimental Pulmonary *Pneumocystis carinii* Infection in Rabbits”. *Jour. Exptl. Med.* 110(1):147-160 (10 fig.).
- 16 — SILVA, G. R.; GOMES, M. C. & SANTOS, R. F. — 1965 — “Pneumocystis Pneumonia in the adult. Report of a case Associated with Corticosteroid Therapy for Rheumatoid Arthritis”. *Rev. Inst. Med. trop. S. Paulo.* 7(1):31-38 (2 fig.).
- 17 — VANEK, J. & JÍROVEC, O. — 1952 — “Parasitäre Pneumonie: ‘Interstitielle’ Plasmazellenpneumonie der Frühgeborenen, verursacht durch *Pneumocystis carinii*”. *Zbl. Bakt.*, 158:120-126 (5 fig.).
- 18 — VIANNA, G. — 1912 — “Notas sobre a biologia dos Trypanosomas gambiense, equineo, congolense e equiperdum”. *Brasil Med.*; 6:51.
- 19 — VORTEL, V. & FINGERLAND, A. — 1968 — “Pneumocystis Pneumonia in the adults”. *Abstracts of the 8th Intern. Cong. trop. Med. Mal.* 7-15 Sept. Teheran-Iran., p. 934.