

## REVIEW ARTICLE

## CURRENT CONCEPTS

## Point-of-Care Ultrasonography

Christopher L. Moore, M.D., and Joshua A. Copel, M.D.

ULTRASONOGRAPHY IS A SAFE AND EFFECTIVE FORM OF IMAGING THAT has been used by physicians for more than half a century to aid in diagnosis and guide procedures. Over the past two decades, ultrasound equipment has become more compact, higher quality, and less expensive, which has facilitated the growth of point-of-care ultrasonography — that is, ultrasonography performed and interpreted by the clinician at the bedside. In 2004, a conference on compact ultrasonography hosted by the American Institute of Ultrasound in Medicine (AIUM) concluded that “the concept of an ‘ultrasound stethoscope’ is rapidly moving from the theoretical to reality.” This conference included representatives from 19 medical organizations; in November 2010, the AIUM hosted a similar forum attended by 45 organizations.<sup>1-3</sup> Some medical schools are now beginning to provide their students with hand-carried ultrasound equipment for use during clinical rotations.<sup>4</sup>

Although ionizing radiation from computed tomographic (CT) scanning is increasingly recognized as a potentially major cause of cancer, ultrasonography has been used in obstetrics for decades, with no epidemiologic evidence of harmful effects at normal diagnostic levels.<sup>5,6</sup> However, ultrasonography is a user-dependent technology, and as usage spreads, there is a need to ensure competence, define the benefits of appropriate use, and limit unnecessary imaging and its consequences.<sup>7-10</sup> This article provides an overview of the history and current status of compact, point-of-care ultrasonography, with examples and discussion of its use.

## HISTORY OF ULTRASONOGRAPHY AND THE BASIC TECHNOLOGY

Medical ultrasonography was developed from principles of sonar pioneered in World War I,<sup>11</sup> and the first sonographic images of a human skull were published in 1947.<sup>12</sup> The first ultrasound images of abdominal disease were published in 1958,<sup>13</sup> and ultrasonography was widely adopted in radiology, cardiology, and obstetrics over the next several decades. Although clinicians from other specialties occasionally reported using ultrasonography, point-of-care ultrasonography did not really begin to progress until the 1990s, when more compact and affordable machines were developed. The early portable machines were hampered by poor image quality, but in 2010, many point-of-care units can nearly match the imaging quality of the larger machines.

Ultrasound is defined as a frequency above that which humans can hear, or more than 20,000 Hz (20 kHz). Therapeutic ultrasound, designed to create heat using mechanical sound waves, is typically lower in frequency than diagnostic ultrasound and is not discussed in this article. The frequency of diagnostic ultrasound is in the millions of Hertz (MHz). Lower-frequency ultrasound has better penetration, but at lower resolution. Higher-frequency ultrasound provides better images, but it does not visualize deep structures well. A typical transabdominal or

From the Departments of Emergency Medicine (C.L.M.) and Obstetrics, Gynecology, and Reproductive Sciences (J.A.C.), Yale University School of Medicine, New Haven, CT. Address reprint requests to Dr. Moore at the Department of Emergency Medicine, Yale University School of Medicine, 464 Congress Ave., Suite 260, New Haven, CT 06519, or at [chris.moore@yale.edu](mailto:chris.moore@yale.edu).

N Engl J Med 2011;364:749-57.

Copyright © 2011 Massachusetts Medical Society.

cardiac probe has a frequency in the range of 2 to 5 MHz, whereas some dermatologic ultrasound probes have frequencies as high as 100 MHz.

Ultrasonography uses a “crystal” — a quartz or composite piezoelectric material — that generates a sound wave when an electric current is applied. When the sound wave returns, the material in turn generates a current. The crystal thus both transmits and receives the sound. Early ultrasonography used a single crystal to create a one-dimensional image known as A-mode. The standard screen image that machines now generate is known as B-mode (also called two-dimensional or gray-scale ultrasonography), and is created by an array of crystals (often 128 or more) across the face of the transducer. Each crystal produces a scan line that is used to create an image or frame, which is refreshed many times per second to produce a moving image on the screen (Fig. 1). Additional modes, including three-dimensional, four-dimensional, Doppler, and tissue Doppler modes, are now commonly available but are not addressed in this article.

Ultrasound penetrates well through fluid and solid organs (e.g., liver, spleen, and uterus); it does not penetrate well through bone or air, limiting its usefulness in the skull, chest, and areas of the abdomen where bowel gas obscures the image. Fluid (e.g., blood, urine, bile, and ascites), which is completely anechoic, appears black on ultrasound images, making ultrasonography particularly useful for detecting fluid and differentiating cystic or vascular areas from solid structures.

Two-dimensional ultrasound is used to visualize a plane that is then shown on the screen. This plane may be directed by the user in any anatomical plane on the patient: sagittal (or longitudinal), transverse (or axial), coronal (or frontal), or some combination (oblique). An indicator on the probe is used to orient the user to the orientation of the plane on the screen. By convention, in general and obstetrical imaging, the indicator corresponds to the left side of the screen as it is viewed. Cardiology uses the opposite convention for echocardiography, with the indicator corresponding to the right of the screen. Users should be aware of these conventions when conducting integrated examinations that include both general and cardiac imaging.<sup>14</sup>

## POINT-OF-CARE APPLICATIONS

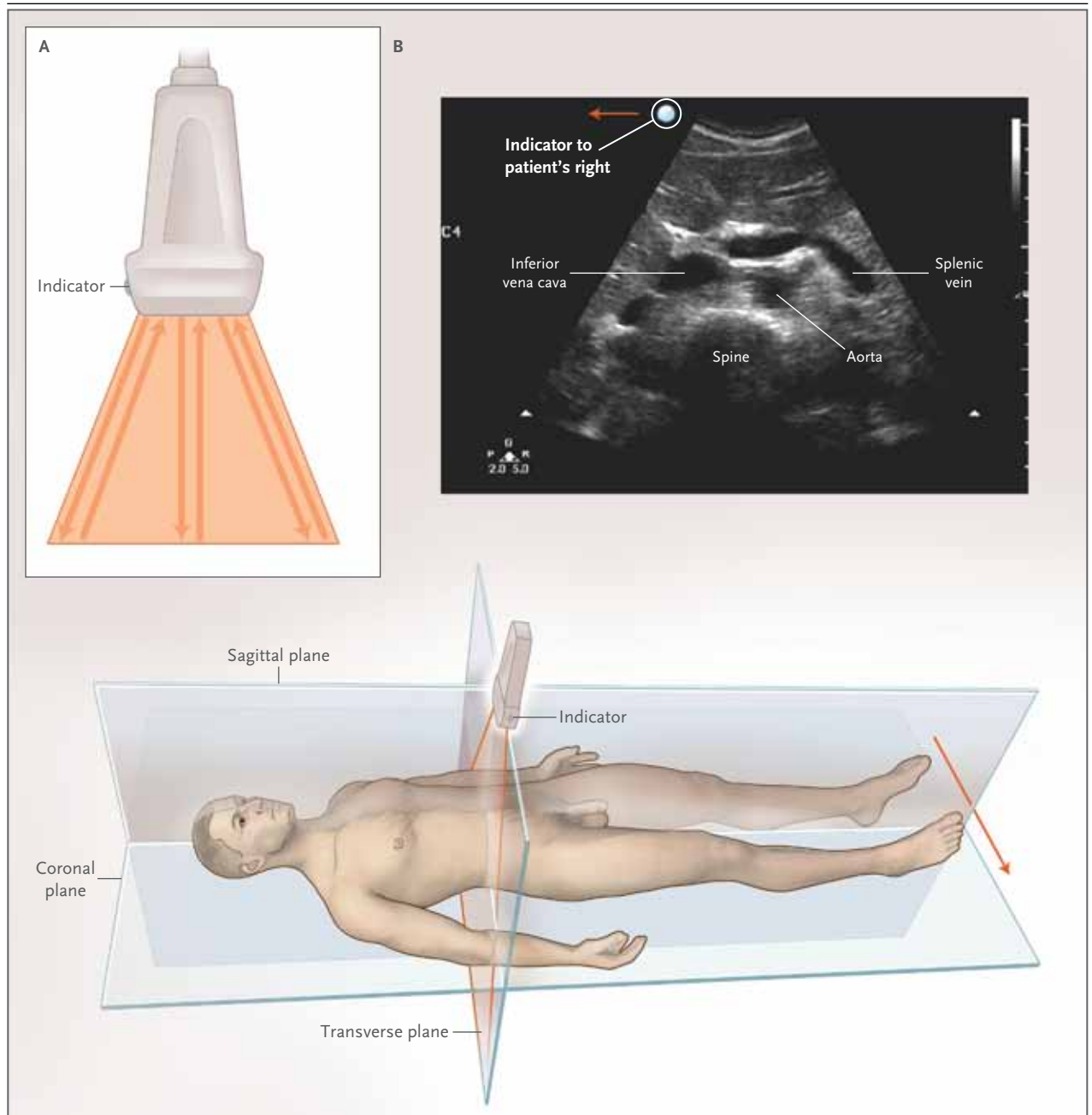
Point-of-care ultrasonography is defined as ultrasonography brought to the patient and performed by the provider in real time. Point-of-care ultrasound images can be obtained nearly immediately, and the clinician can use real-time dynamic images (rather than images recorded by a sonographer and interpreted later), allowing findings to be directly correlated with the patient's presenting signs and symptoms.<sup>15</sup> Point-of-care ultrasonography is easily repeatable if the patient's condition changes. It is used by various specialties in diverse situations (Table 1) and may be broadly divided into procedural, diagnostic, and screening applications.

### PROCEDURAL GUIDANCE

Ultrasound guidance may improve success and decrease complications in procedures performed by multiple specialties, including central and peripheral vascular access, thoracentesis, paracentesis, arthrocentesis, regional anesthesia, incision and drainage of abscesses, localization and removal of foreign bodies, lumbar puncture, biopsies, and other procedures.<sup>16</sup>

Procedural guidance may be static or dynamic. With static guidance, the structure of interest is identified, and the angle required by the needle is noted, with the point of entry marked on the skin. In dynamic procedures, ultrasonography visualizes the needle in real time. Static guidance may initially be easier to perform, but properly performed dynamic guidance provides more accurate guidance and is generally preferred by experienced users.

In response to the 1999 Institute of Medicine report *To Err Is Human*, the Agency for Healthcare Research and Quality listed “use of real-time ultrasound guidance during central line insertion to prevent complications” as 1 of the 12 most highly rated patient safety practices designed to decrease medical errors.<sup>17</sup> The use of ultrasound to guide central venous access has been shown to reduce the failure rate, the risk of complications, and the number of attempts, as compared with the landmark technique, particularly in the case of less experienced users or patients with more complex conditions.<sup>18,19</sup> The evidence for these benefits of ultrasound guidance is greatest



**Figure 1. Basic (B-Mode) Two-Dimensional Ultrasound Image.**

A typical ultrasound transducer, shown in Panel A, has 128 or more crystals arranged across the face of the probe. Each crystal transmits and receives bursts of sound (typically in the megahertz range), creating a scan line. The scan lines together make up a frame, which is refreshed many times per second and displayed on a two-dimensional screen to create a moving image. As shown in Panel B, the plane of the ultrasound can be directed in any anatomical plane or between planes. By convention, in abdominal imaging, the probe indicator (a bump or groove on the probe) is to the left of the screen and is generally directed toward the patient's right side in a transverse plane. The ultrasound image shown is a transverse image of the abdominal aorta. The aorta is black (fluid-filled) and located just anterior to the vertebral bodies. (See also Video 4, available with the full text of this article at NEJM.org.)

**Table 1. Selected Applications of Point-of-Care Ultrasonography, According to Medical Specialty.\***

Specialty	Ultrasound Applications
Anesthesia	Guidance for vascular access, regional anesthesia, intraoperative monitoring of fluid status and cardiac function
Cardiology	Echocardiography, intracardiac assessment
Critical care medicine	Procedural guidance, pulmonary assessment, focused echocardiography
Dermatology	Assessment of skin lesions and tumors
Emergency medicine	FAST, focused emergency assessment, procedural guidance
Endocrinology and endocrine surgery	Assessment of thyroid and parathyroid, procedural guidance
General surgery	Ultrasonography of the breast, procedural guidance, intraoperative assessment
Gynecology	Assessment of cervix, uterus, and adnexa; procedural guidance
Obstetrics and maternal–fetal medicine	Assessment of pregnancy, detection of fetal abnormalities, procedural guidance
Neonatology	Cranial and pulmonary assessments
Nephrology	Vascular access for dialysis
Neurology	Transcranial Doppler, peripheral-nerve evaluation
Ophthalmology	Corneal and retinal assessment
Orthopedic surgery	Musculoskeletal applications
Otolaryngology	Assessment of thyroid, parathyroid, and neck masses; procedural guidance
Pediatrics	Assessment of bladder, procedural guidance
Pulmonary medicine	Transthoracic pulmonary assessment, endobronchial assessment, procedural guidance
Radiology and interventional radiology	Ultrasonography taken to the patient with interpretation at the bedside, procedural guidance
Rheumatology	Monitoring of synovitis, procedural guidance
Trauma surgery	FAST, procedural guidance
Urology	Renal, bladder, and prostate assessment; procedural guidance
Vascular surgery	Carotid, arterial, and venous assessment; procedural assessment

\* FAST denotes focused assessment with sonography for trauma.

for the internal jugular site, with less evidence for the femoral and subclavian sites and in pediatric patients.<sup>20</sup>

A needle may be imaged dynamically with the use of either an “in-plane” or “out-of-plane” ultrasound approach (Fig. 2, and Video 1, available at NEJM.org). For vascular access, an in-plane approach corresponds to the long axis of the vessel. An in-plane, or long-axis, approach is generally preferred for dynamic vascular access, particularly for central venous access, because the entire length of the needle, including the tip, can be visualized throughout the procedure. However, it may be more difficult to keep the needle in view with the use of an in-plane approach, and for smaller vessels, it may be challenging to image the entire vessel in the long axis.

An out-of-plane approach is perpendicular to

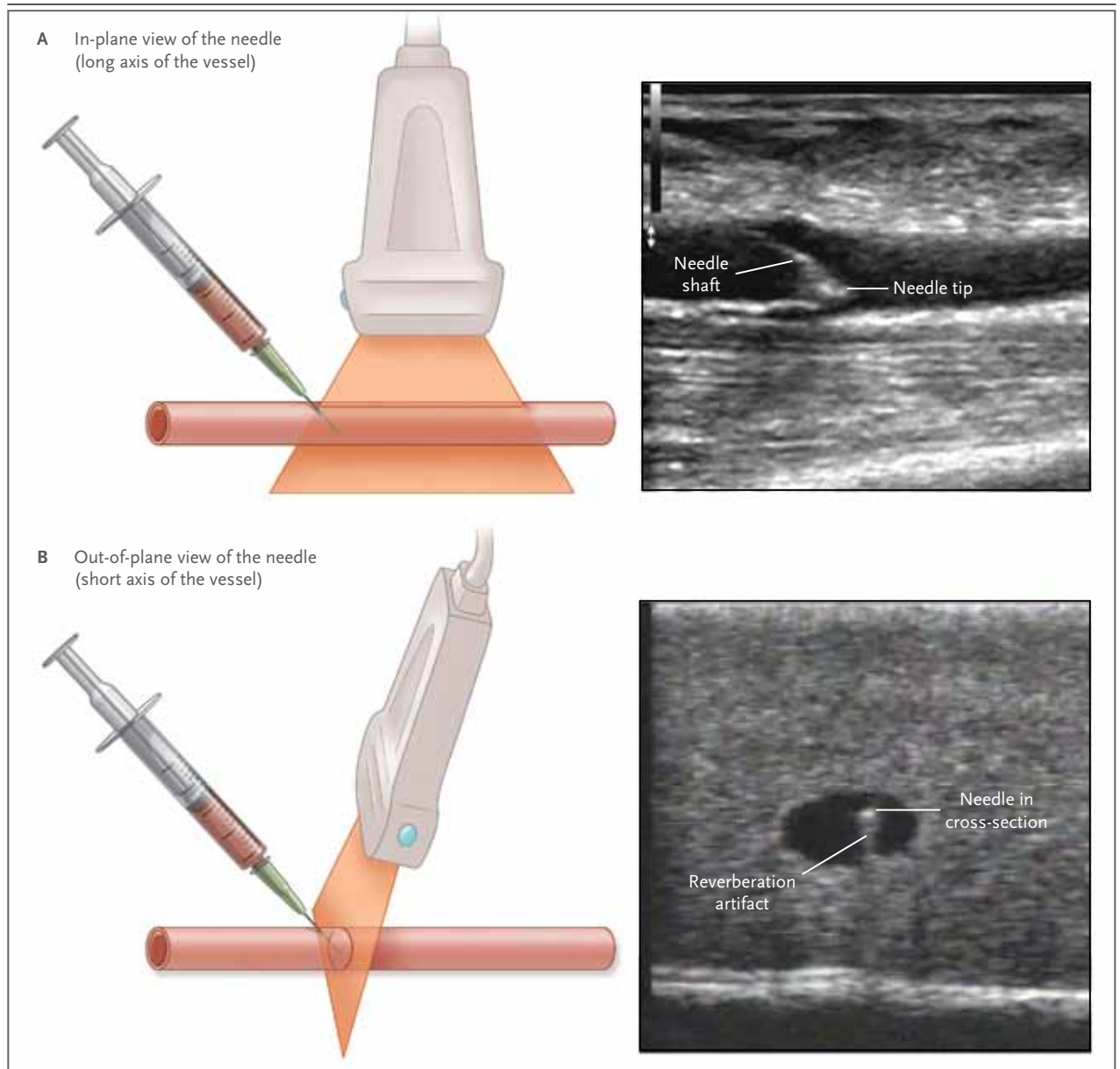
the needle and corresponds to the short axis of the vessel. The advantage of this approach is that the needle can be centered over the middle of the vessel. It is also easier to keep the vessel and the needle in view in the short axis. However, an out-of-plane approach may underestimate the depth of the needle tip if the ultrasound plane cuts across the shaft of the needle, proximal to the tip. A detailed description of ultrasound-guided central venous access of the internal jugular vein is provided by Ortega et al. as part of the *Journal's* Videos in Clinical Medicine series.<sup>21</sup>

#### DIAGNOSTIC ASSESSMENT

The concept of a focused (“limited,” or “goal-directed”) examination is important in point-of-care ultrasonography. Clinicians from diverse specialties can become very adept at using ultra-



Videos showing point-of-care ultrasonography are available at NEJM.org

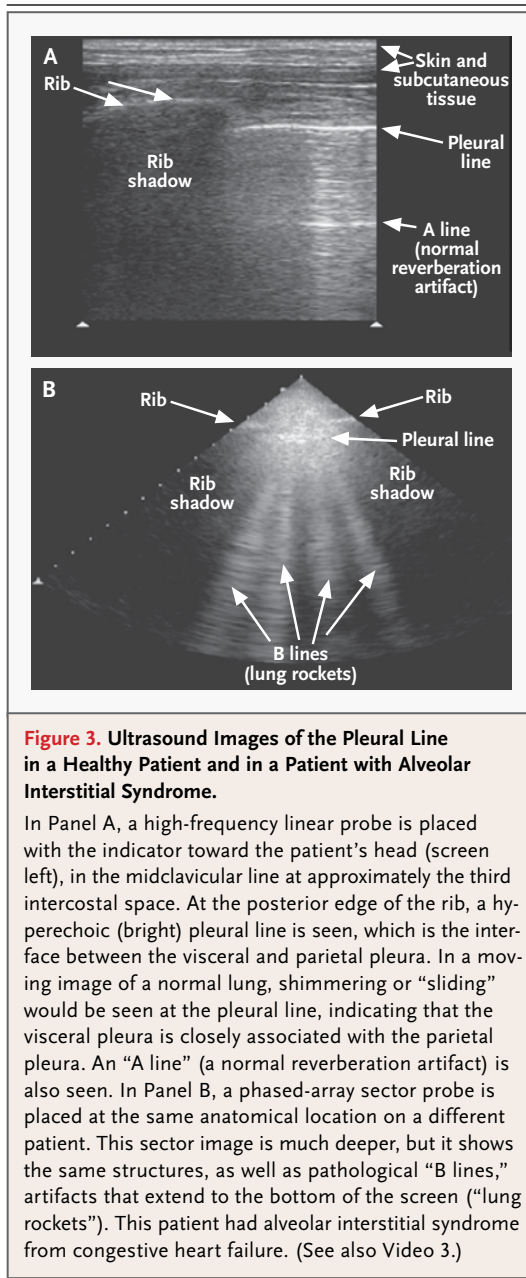


**Figure 2. Ultrasound Guidance for Vascular Access and Other Procedures Involving Needles.**

Panel A shows a long-axis, “in-plane” view of the needle. Although it may be more difficult to keep the needle and structure of interest in view, the long-axis view is advantageous because it shows the entire needle, including the tip (ultrasound image at right). Panel B shows a short-axis approach, with the characteristic “target sign” of the needle in the vessel lumen. The ultrasound image also shows a reverberation artifact, which occurred in this case when the ultrasound beam struck a metallic object. The artifact appears as closely spaced, tapering lines below the needle. Although the visualized portion of the needle is centered in the lumen, the disadvantage of the short axis is that the plane of the ultrasound may cut through the needle shaft proximally, underestimating the depth of the tip. (See also Video 1.)

sonography to examine a particular organ, disease, or procedure that is directly relevant to their area of expertise, whereas imaging specialists typically perform more comprehensive examinations (Table 1).

Point-of-care ultrasonography may involve the use of a series of focused ultrasonographic examinations to efficiently diagnose or rule out certain conditions in patients presenting with particular symptoms or signs, such as hypoten-



sion, chest pain, or dyspnea. In patients with trauma, this approach is known as FAST (focused assessment with sonography for trauma). Point-of-care ultrasonography allows immediate, dynamic, and repeated assessments in these situations and has the potential for detecting conditions such as pneumothorax in which ultrasonography was traditionally thought to be unhelpful. Here we focus on an integrated point-of-care examination for trauma (FAST), as well as

the use of point-of-care ultrasonography for pulmonary assessment.

#### FAST Examination

FAST was a term coined at an international consensus conference in 1996 to describe an integrated, goal-directed, bedside examination to detect fluid, which is likely to be hemorrhage in cases of trauma.<sup>22</sup> The extended FAST (e-FAST) also includes examination of the chest for pneumothorax.<sup>23</sup>

The e-FAST examination combines five focused examinations for the detection of: free intraperitoneal fluid, free fluid in the pelvis, pericardial fluid, pleural effusion, and pneumothorax. Peritoneal fluid is detected using views of the hepatorenal space (Morison's pouch), splenorenal space, and retrovesicular spaces. The thorax is evaluated for fluid at the flanks and for pneumothorax anteriorly. The pericardium may be evaluated for effusion, particularly in cases of penetrating trauma (see Video 2).

A FAST examination may be completed in less than 5 minutes and has been shown to have a sensitivity of 73 to 99%, a specificity of 94 to 98%, and an overall accuracy of 90 to 98% for clinically significant intraabdominal injury in trauma.<sup>24</sup> The use of the FAST examination has been shown to reduce the need for CT or diagnostic peritoneal lavage and to reduce the time to appropriate intervention, resulting in a shorter hospital stay, lower costs, and lower overall mortality, although more rigorous study of patient-centered outcomes is recommended.<sup>25,26</sup> A complete or partial FAST examination may also be helpful in evaluating patients who do not have trauma for ascites, intraperitoneal hemorrhage, pleural effusion, pneumothorax, or pericardial effusion.

#### Pulmonary Ultrasonography

The use of ultrasound to detect pneumothorax was first described in a horse in 1986, and then in humans shortly afterward.<sup>27</sup> In a normal lung, the visceral and parietal pleura are closely associated, and ultrasound shows shimmering or sliding at the pleural interface during respiration (Fig. 3, and Video 3). The absence of sliding indicates a pneumothorax. A small pneumothorax may be missed with the use of ultrasonography, and patients with blebs or scarring may have false positive findings.<sup>28</sup> However, for assessing pa-

tients with trauma for pneumothorax, ultrasonography has been shown to be more than twice as sensitive as conventional supine chest radiography for detecting occult pneumothorax (pneumothorax seen only on CT), with similarly high specificity (>98%).<sup>23</sup> The presence of a “lung point” sign, where the visceral pleura intermittently comes in contact with the parietal pleura, is nearly 100% specific for the detection of pneumothorax.

Comet tails are an ultrasound artifact that arises when ultrasound encounters a small air-fluid interface. In 1997, Lichtenstein et al. described the sonographic identification of alveolar interstitial syndrome, diagnosed on the basis of comet tails that extend from the pleural line to the bottom of the screen, also known as “B lines” (Fig. 3B). Alveolar interstitial syndrome is an ultrasonographic finding in several different conditions.<sup>29</sup> In an acute condition, alveolar interstitial syndrome usually represents pulmonary edema, but it may also be seen in the acute respiratory distress syndrome and more chronic interstitial diseases and may be a focal finding in infectious or ischemic processes. Characteristics of the artifacts may be helpful in distinguishing these conditions.

Ultrasonography has been shown to be more accurate than auscultation or chest radiography for the detection of pleural effusion, consolidation, and alveolar interstitial syndrome in the critical care setting.<sup>30</sup> In the emergency care setting, the presence of B lines on pleural ultrasonography predicts fluid overload, adding diagnostic accuracy to the physical examination and measurement of brain natriuretic peptide.<sup>31</sup> The presence of B lines has been shown to be dynamic, disappearing in patients undergoing hemodialysis.<sup>31,32</sup>

## SCREENING

Screening with ultrasonography is attractive because it is noninvasive and lacks ionizing radiation. Ultrasonography has been described as a screening test for cardiovascular and gynecologic disease, and compact ultrasonography has been incorporated into “mobile screening labs.”<sup>33</sup> However, the benefits of screening must be weighed against the harms, particularly false positive findings that lead to unnecessary testing, intervention, or both. The U.S. Preventive Services Task Force (USPSTF) has specifically recommended that ultrasonography not be used for

routine screening for carotid stenosis, peripheral vascular disease, or ovarian cancer in the general population (class D recommendation — “ineffective or harms outweigh benefits”), although research is ongoing to determine whether more narrowly defined populations may benefit from such screening.<sup>34</sup>

In 2005, the USPSTF gave a class B recommendation for one-time ultrasound screening for abdominal aortic aneurysm in men between the ages of 65 and 75 years who had ever smoked, leading to the incorporation of screening for abdominal aortic aneurysm into Medicare reimbursement.<sup>35,36</sup> The USPSTF reports that ultrasonography has a sensitivity of 95% and a specificity of nearly 100% when performed in “a setting with adequate quality assurance.”

Imaging of the abdominal aorta is performed with a curvilinear probe of 2 to 5 MHz. With the patient in a supine position, gentle pressure is applied to move bowel gas out of the way. The aorta should be imaged as completely as possible from the proximal (celiac trunk) to the distal bifurcation and should include assessment of the iliac arteries when possible. It should be measured at its maximum diameter from outside wall to outside wall in two planes, transverse and longitudinal. Challenges include ensuring that the aorta is imaged, not the inferior vena cava or another fluid-filled structure, and ensuring that the entire diameter is measured (Fig. 1, and Video 4).

Ultrasonography of the abdominal aorta has been shown to be fairly straightforward to learn as a focused examination, and screening by primary care providers using point-of-care ultrasonography may provide an economical method for wider screening, although more study is needed in this area.

---

## POINT-OF-CARE ULTRASONOGRAPHY IN OTHER SETTINGS

---

Point-of-care ultrasonography is increasingly being used in resource-limited settings. The World Health Organization states that plain radiography and ultrasonography, singly or in combination, will meet two thirds of all imaging needs in developing countries.<sup>37</sup> Ultrasonography has been used at the Mount Everest base camp to diagnose high-altitude pulmonary edema, and ultrasonography is the only diagnostic imaging technique

used on the International Space Station, where astronauts obtain images that are interpreted on earth.<sup>38,39</sup> The use of hand-carried ultrasonographic devices has been described in prehospital settings, including ambulance and disaster settings, as well as in battlefield medicine (the scenario for which hand-carried ultrasonography was initially developed).<sup>40-42</sup> The e-FAST examination for internal bleeding and pneumothorax has been the most extensively described application in the prehospital setting (Video 2).

#### POLICY CONSIDERATIONS

From 2000 to 2006, physician fees billed for medical imaging in the United States more than doubled, with the proportion of billing for “in-office” imaging rising from 58 to 64%.<sup>43</sup> Although the rate of imaging increased among both radiologists and nonradiologists, the rate of increase was faster among nonradiologists.<sup>44,45</sup> Most of this increase was related to “advanced” imaging (CT, magnetic resonance imaging, and nuclear medicine), but certain applications of ultrasonography by nonradiologists (particularly breast and cardiac applications) increased at a very rapid rate.<sup>46</sup>

With appropriate use, point-of-care ultrasonography can decrease medical errors, provide more efficient real-time diagnosis, and supplement or replace more advanced imaging in appropriate situations. In addition, point-of-care ultrasonography may allow more widespread, less-expensive screening for defined indications. It may be particularly cost-effective in a reimbursement scheme based on episodes of care (“bundling”),

in some cases obviating the need for more resource-intensive imaging performed by a consulting radiologist.<sup>47</sup> However, indiscriminate use of ultrasonography could lead to further unnecessary testing, unnecessary interventions in the case of false positive findings, or inadequate investigation of false negative findings. More imaging could simply lead to increased expense without added benefit, or might even be harmful.

As a user-dependent technology, point-of-care ultrasonography requires consideration of appropriate training and quality assurance. In addition, methodologically rigorous studies are needed to assess patient-centered outcomes for point-of-care ultrasonography.<sup>25,48-50</sup>

#### CONCLUSIONS

The use of point-of-care ultrasonography will continue to diffuse across medical specialties and care situations. Future challenges include gaining a better understanding of when and how point-of-care ultrasonography can be used effectively, determining the training and assessment that will be required to ensure competent use of the technology, and structuring policy and reimbursement to encourage appropriate and effective use.

Dr. Moore reports receiving consulting fees from SonoSite and Philips; and Dr. Copel, speaking fees from Siemens, World Class CME, the Institute for Advanced Medical Education, and Educational Symposia, grant support from Philips, and reimbursement for travel expenses from Philips and Esaote and serving as a paid member of the editorial board of *Contemporary OB/GYN* at modernmedicine.com. No other potential conflict of interest relevant to this article was reported.

Disclosure forms provided by the authors are available with the full text of this article at NEJM.org.

#### REFERENCES

- Greenbaum LD, Benson CB, Nelson LH III, Bahner DP, Spitz JL, Platt LD. Proceedings of the Compact Ultrasound Conference sponsored by the American Institute of Ultrasound in Medicine. *J Ultrasound Med* 2004;23:1249-54.
- Alpert JS, Mladenovic J, Hellmann DB. Should a hand-carried ultrasound machine become standard equipment for every internist? *Am J Med* 2009;122:1-3.
- AIUM Ultrasound Practice Forum, 2010: point-of-care use of ultrasound. (<http://www.aium.org/advertising/2010Forum.pdf>)
- Rao S, van Holsbeeck L, Musial JL, et al. A pilot study of comprehensive ultrasound education at the Wayne State University School of Medicine: a pioneer year review. *J Ultrasound Med* 2008;27:745-9.
- Brenner DJ, Hall EJ. Computed tomography — an increasing source of radiation exposure. *N Engl J Med* 2007;357:2277-84.
- Barnett SB. Routine ultrasound scanning in first trimester: what are the risks? *Semin Ultrasound CT MR* 2002;23:387-91.
- Filly RA. Is it time for the sonoscope? If so, then let's do it right! *J Ultrasound Med* 2003;22:323-5.
- Adler RS. The use of compact ultrasound in anesthesia: friend or foe. *Anesth Analg* 2007;105:1530-2.
- Bree RL, Benson CB, Bowie JD, et al. The role of radiology in the era of compact ultrasound systems: SRU Conference, October 14 and 15, 2003. *Ultrasound Q* 2004;20:19-21.
- Greenbaum LD. It is time for the sonoscope. *J Ultrasound Med* 2003;22:321-2.
- Dussik KT. On the possibility of using ultrasound waves as a diagnostic aid. *Z Neurol Psychiat* 1942;174:153-68. (In German.)
- Edler I, Lindström K. The history of echocardiography. *Ultrasound Med Biol* 2004;30:1565-644.
- Donald I, Macvicar J, Brown TG. Investigation of abdominal masses by pulsed ultrasound. *Lancet* 1958;1:1188-95.
- Moore C. Current issues with emer-



- gency cardiac ultrasound probe and image conventions. *Acad Emerg Med* 2008;15:278-84.
15. Gluckman JL, Mann W, Portugal LG, Welkoborsky H-J. Real-time ultrasonography in the otolaryngology office setting. *Am J Otolaryngol* 1993;14:307-13.
16. Nicolaou S, Talsky A, Khashoggi K, Venu V. Ultrasound-guided interventional radiology in critical care. *Crit Care Med* 2007;35:Suppl:S186-S197.
17. Making health care safer: a critical analysis of patient safety practices. Rockville, MD: Agency for Healthcare Research and Quality. (AHRQ publication no. 01-E058.)
18. Randolph AG, Cook DJ, Gonzales CA, Pribble CG. Ultrasound guidance for placement of central venous catheters: a meta-analysis of the literature. *Crit Care Med* 1996;24:2053-8.
19. Hind D, Calvert N, McWilliams R, et al. Ultrasonic locating devices for central venous cannulation: meta-analysis. *BMJ* 2003;327:361-8.
20. Kumar A, Chuan A. Ultrasound guided vascular access: efficacy and safety. *Best Pract Res Clin Anaesthesiol* 2009;23:299-311.
21. Ortega R, Song M, Hansen CJ, Barash P. Ultrasound-guided internal jugular vein cannulation. *N Engl J Med* 2010;362(16):e57. (Video available at [NEJM.org](http://NEJM.org).)
22. Scalea TM, Rodriguez A, Chiu WC, et al. Focused Assessment with Sonography for Trauma (FAST): results from an international consensus conference. *J Trauma* 1999;46:466-72.
23. Kirkpatrick AW, Sirois M, Laupland KB, et al. Hand-held thoracic sonography for detecting post-traumatic pneumothoraces: the Extended Focused Assessment with Sonography for Trauma (EFAST). *J Trauma* 2004;57:288-95.
24. Melanson SW. The FAST Exam: a review of the literature. In: Jehle D, Heller MB, eds. *Ultrasonography in trauma: the FAST Exam*. Dallas: American College of Emergency Physicians, 2003:127-45.
25. Melniker LA, Leibner E, McKenney MG, Lopez P, Briggs WM, Mancuso CA. Randomized controlled clinical trial of point-of-care, limited ultrasonography for trauma in the emergency department: the first Sonography Outcomes Assessment Program trial. *Ann Emerg Med* 2006;48:227-35.
26. Hosek WT, McCarthy ML. Trauma ultrasound and the 2005 Cochrane Review. *Ann Emerg Med* 2007;50:619-20.
27. Rantanen NW. Diseases of the thorax. *Vet Clin North Am Equine Pract* 1986;2:49-66.
28. Dulchavsky SA, Schwarz KL, Kirkpatrick AW, et al. Prospective evaluation of thoracic ultrasound in the detection of pneumothorax. *J Trauma* 2001;50:201-5.
29. Lichtenstein D, Mézière G, Biderman P, Gepner A, Barré O. The comet-tail artifact: an ultrasound sign of alveolar-interstitial syndrome. *Am J Respir Crit Care Med* 1997;156:1640-6.
30. Lichtenstein D, Goldstein I, Mourgeon E, Cluzel P, Grenier P, Rouby JJ. Comparative diagnostic performances of auscultation, chest radiography, and lung ultrasonography in acute respiratory distress syndrome. *Anesthesiology* 2004;100:9-15.
31. Liteplo AS, Marill KA, Villen T, et al. Emergency Thoracic Ultrasound in the Differentiation of the Etiology of Shortness of Breath (ETUDES): sonographic B-lines and N-terminal pro-brain-type natriuretic peptide in diagnosing congestive heart failure. *Acad Emerg Med* 2009;16:201-10.
32. Noble VE, Murray AF, Capp R, Sylvia-Reardon MH, Steele DJR, Liteplo A. Ultrasound assessment for extravascular lung water in patients undergoing hemodialysis. *Chest* 2009;135:1433-9.
33. Payne JW. Screening with holes in it? *Washington Post*. July 19, 2005. (<http://www.washingtonpost.com/wp-dyn/content/article/2005/07/18/AR2005071801175.html>.)
34. Screening for carotid artery stenosis. Rockville, MD: U.S. Preventive Services Task Force, December 2007. (<http://www.uspreventiveservicestaskforce.org/uspstf/uspasacs.htm>.)
35. U.S. Preventive Services Task Force. Screening for abdominal aortic aneurysm: recommendation statement. *Ann Intern Med* 2005;142:198-202.
36. Thompson SG, Ashton HA, Gao L, Scott RA. Screening men for abdominal aortic aneurysm: 10 year mortality and cost effectiveness results from the randomised Multicentre Aneurysm Screening Study. *BMJ* 2009;338:2307-18.
37. Aide-memoire for diagnostic imaging services. Geneva: World Health Organization, 2009. (<http://whqlibdoc.who.int/aide-memoire/a71903.pdf>.)
38. Otto C, Hamilton DR, Levine BD, et al. Into thin air: extreme ultrasound on Mt Everest. *Wilderness Environ Med* 2009;20(3):283-9.
39. Sargsyan AE, Hamilton DR, Jones JA, et al. FAST at MACH 20: clinical ultrasound aboard the International Space Station. *J Trauma* 2005;58:35-9.
40. Nelson BP, Chason K. Use of ultrasound by emergency medical services: a review. *Int J Emerg Med* 2008;1:253-9.
41. Brooks AJ, Price V, Simms M. FAST on operational military deployment. *Emerg Med J* 2005;22:263-5.
42. Beck-Razi N, Fischer D, Michaelson M, Engel A, Gaitini D. The utility of focused assessment with sonography for trauma as a triage tool in multiple-casualty incidents during the second Lebanon war. *J Ultrasound Med* 2007;26:1149-56.
43. Medicare imaging payments. Washington, DC: Government Accountability Office, 2008. (GAO-08-452.)
44. Hillman BJ, Olson GT, Griffith PE, et al. Physicians' utilization and charges for outpatient diagnostic imaging in a Medicare population. *JAMA* 1992;268:2050-4.
45. Maitino AJ, Levin DC, Parker L, Rao VM, Sunshine JH. Practice patterns of radiologists and nonradiologists in utilization of noninvasive diagnostic imaging among the Medicare population. *Radiology* 2003;228:795-801.
46. Miller ME. MedPAC recommendations on imaging services. Washington, DC: Subcommittee on Health Committee on Ways and Means, 2005.
47. Schoen C, Guterman S, Shih A, et al. Bending the curve: options for achieving savings and improving value in U.S. health spending. Washington, DC: The Commonwealth Fund, 2007.
48. Rose JS. Ultrasonography and outcomes research: one small step for mankind or another drop in the bucket? *Ann Emerg Med* 2006;48:237-9.
49. Liu SS, Ngeow JE, Yadeau JT. Ultrasound-guided regional anesthesia and analgesia: a qualitative systematic review. *Reg Anesth Pain Med* 2009;34:47-59.
50. Vance S. The FAST scan: are we improving care of the trauma patient? *Ann Emerg Med* 2007;49:364-6.

Copyright © 2011 Massachusetts Medical Society.

RECEIVE IMMEDIATE NOTIFICATION WHEN AN ARTICLE IS PUBLISHED ONLINE FIRST

To be notified by e-mail when *Journal* articles are published Online First, sign up at [NEJM.org](http://NEJM.org).