



# Polyomaviruses and disease: is there more to know than viremia and viruria?

*Volker Nickenleit and Harsharan K. Singh*

## **Purpose of review**

Polyomavirus nephropathy (PVN) mainly caused by BK virus (BKV) remains the most common productive viral infection of the kidney. Over the past decade, clinical interest often focused on BK viremia and viruria as the diagnostic mainstays of patient management. The purpose of this review is to discuss viral nephropathy in the context of BK viremia and viruria and new strategies to optimize diagnostic accuracy and patient management. The emerging roles of polyomaviruses in oncogenesis, salivary gland disease, and post-bone marrow transplantation as well as novel Polyomavirus strains are highlighted.

## **Recent findings**

Areas of investigation include proposals by the Banff working group on the classification of PVN and studies on PVN progression and resolution, including the role cellular immune responses may play during reconstitution injury. New noninvasive strategies to optimize the diagnosis of PVN, that is, the urinary 'polyomavirus-haufen' test and mRNA expression levels for BKV in the urine, hold great promise to accurately identify patients with viral nephropathy. Tools are now available to separate 'presumptive' from 'definitive' disease in various patient cohorts including individuals post-bone marrow transplantation. Recent observations also point to a currently underrecognized role of polyomaviruses in oncogenesis post-transplantation and salivary gland disease in patients with HIV-AIDS.

## **Summary**

This review summarizes recent studies on PVN and the significance of the BKV strain in disease. Current paradigms for patient management post-(renal) transplantation are discussed in the setting of new observations. Issues that still require clarification and further validation are highlighted.

## **Keywords**

biomarker, BK virus, classification, electron microscopy, haufen, outcome, pathology, polyomavirus nephropathy, transplantation, urine

## **INTRODUCTION**

Modern immunosuppression has led to improved allograft survival and optimized treatment of autoimmune diseases, such as multiple sclerosis. However, new therapeutic strategies have also introduced previously uncommon side-effects. For example, polyomaviruses of the BK strain, previously 'in-search of a disease', have now found what they were looking for, that is, they can cause polyomavirus nephropathy (PVN) or hemorrhagic cystitis. In addition, increasing evidence links the BK-virus (BKV) strain to oncogenesis in transplant recipients and possibly salivary gland disease in HIV-infected patients. In recent years, several novel human polyomavirus strains associated with some unusual pathologic changes have also been identified.

Thus, although much has been learned about polyomaviruses, new questions have arisen as well.

This review focuses on clinically significant aspects of polyomavirus infections with emphasis on the polyoma-BKV strain and PVN. Old paradigms are revisited in the light of new findings and ongoing trials.

Division of Nephropathology, Department of Pathology and Laboratory Medicine, The University of North Carolina, Chapel Hill, North Carolina, USA

Correspondence to Volker Nickenleit, MD, Division of Nephropathology, Department of Pathology and Laboratory Medicine, The University of North Carolina, Brinkhous-Bullitt Building, Room 409 Campus Box #7525, Chapel Hill, NC 27599, USA. Tel: +1 919 966 2421; fax: +1 919 966 4542; e-mail: volker\_nickeleit@med.unc.edu

**Curr Opin Organ Transplant** 2015, 20:348–358

DOI:10.1097/MOT.000000000000192

This is an open-access article distributed under the terms of the Creative Commons Attribution-NonCommercial-NoDerivatives 4.0 License, where it is permissible to download and share the work provided it is properly cited. The work cannot be changed in any way or used commercially.

## KEY POINTS

- PVN is morphologically defined by the presence of viral replication in the renal parenchyma and varying degrees of virally induced acute tubular injury.
- Based on morphology, PVN can be classified into disease grades 1–3 with disease resolution and favorable outcome in early disease grade 1 and a high risk of graft failure in grade 3.
- Novel urine-based assays allow for an accurate noninvasive diagnosis of PVN: the urinary polyomavirus-Haufen test and PCR assays targeting BKV mRNA expression levels. The concept of ‘presumptive’ and ‘definitive’ PVN can now be revisited: is it the same entity?
- The intriguing concept of so-called immune reconstitution type of graft inflammation during resolving PVN needs further studies: does it exist?
- BKV is associated with oncogenesis and potentially salivary gland disease in immunocompromised patients.

## HUMAN POLYOMAVIRUS STRAINS AND DISEASE

Polyomaviruses are ubiquitous, small, double-stranded DNA viruses that exist in symbiosis with humans and animals. In recent years, the family of human polyomaviruses has grown to 13 members, and it will likely expand further due to the introduction of novel molecular screening techniques [1,2<sup>3</sup>,3<sup>4</sup>].

After a primary infection early in life, polyomaviruses often establish latency in the genitourinary tract as well as other anatomic sites. Several human polyomavirus strains can coexist in the same host organism and even in the same organ, such as the kidney. Seroprevalence, depending on the viral strain and the patient age, ranges from 20% to greater than 90% [3<sup>5</sup>]. Latent polyomavirus strains, alone or in combination, can undergo episodes of self-limiting asymptomatic reactivation with viremia and viremia [4,5,6<sup>6</sup>]. However, despite a high prevalence of latent polyomavirus infections and transient asymptomatic activation of latent polyomaviruses, manifest viral disease is rare. It is linked to five of the 13 polyomavirus strains and limited to patients with impaired immune surveillance, such as transplant recipients [3<sup>7</sup>,7–9,10<sup>8</sup>,11<sup>9</sup>]. The ‘disease-causing’ strains show different patterns of injury: neoplasms without productive viral replication (e.g., Merkel cell carcinomas) and productive viral infections with tissue injury but without neoplasms (e.g., PVN and progressive multifocal leukoencephalopathy). Proliferative lesions and

neoplasms are mainly caused by two recently described human polyomavirus strains: trichodysplasia spinulosa-associated polyomavirus and Merkel cell polyomavirus that can cause tumors of the skin. Emerging evidence also links the polyoma-BKV strain to oncogenesis in rare cases [12–19]. Pathology of productive infections with tissue injury and varying degrees of inflammation is seen with polyoma-BK and JC viruses, the first two human polyomaviruses described in 1971 [20,21]. BKV induces PVN and hemorrhagic cystitis. In addition, BKV seems to be linked to salivary gland inflammation and sclerosis in HIV-infected patients [9]. JC virus causes lytic brain lesions, that is, progressive multifocal leukoencephalopathy [22–26]. A productive infection with the recently described New Jersey polyomavirus was seen in a pancreas transplant recipient [2<sup>2</sup>]. The patient presented with acute onset retinal blindness and vasculitic myopathy caused by viral replication in endothelial cells. Why certain polyomavirus strains cause disease in some organs while sparing others harboring the same strain in a latent state is unknown, such as JC virus causing brain lesions/progressive multifocal leukoencephalopathy but hardly ever causing PVN despite a high prevalence of latent JC virus in the renal parenchyma. In the following sections, we focus our discussion on PVN and BK virus-associated diseases.

## POLYOMAVIRUS NEPHROPATHY

PVN is typically found in renal allografts and only rarely in native kidneys [27<sup>1</sup>]. Viral nephropathy is primarily caused by the BKV strain and, in approximately 10–20% of cases, by simultaneous coactivation of BK and JC viruses. Cases of only JC virus or SV40 virus-induced PVN are rare.

The diagnosis of PVN, sometimes also referred to as ‘definitive’ PVN, requires morphologic evidence of polyomavirus replication in the renal parenchyma by biopsy or alternatively by urinary polyomavirus-haufen testing (see in further sections) [28–32,33<sup>2</sup>]. Although helpful in identifying patients at increased risk, other laboratory assays including quantitative PCR testing are not well suited for rendering a definitive diagnosis of PVN. Patients with PVN do not show symptoms of a generalized infection, the urine sediment is bland and renal function, that is, the serum creatinine levels, can be normal.

At present, the incidence of PVN in renal allograft recipients is approximately 4% with broad transplant center variations; it is highest in ABO-incompatible grafts (18%) [34,35]. Overall, risk factors for PVN are only poorly defined, in particular,

the striking prevalence for renal allografts. Conditions promoting PVN include intense long-term immunosuppression often including tacrolimus and mycophenolate mofetil (MMF); transplantation of an allograft from a BKV seropositive donor into a seronegative recipient; prior episodes of acute renal allograft rejection; induction therapy with anti-thymocyte globulin; and older age of male graft recipients among others [6<sup>11</sup>,36]. Interestingly, cyclosporine seems to have a suppressive effect on polyomavirus replication, whereas tacrolimus and MMF-based immunosuppression, introduced in the mid-1990s when PVN emerged as a severe complication, is tightly linked to viral activation and disease [37–41]. Surprisingly, nonrenal allograft recipients on high-dose tacrolimus and MMF rarely develop PVN in their native kidneys, and, vice versa, patients with kidney transplants on cyclosporine, azathioprine, or sirolimus also sporadically present with viral nephropathy [6<sup>11</sup>]. Thus, multiple ‘hits’ with tacrolimus and MMF-based therapy representing only one hit are required to provide the right window of opportunity for polyomavirus replication in the renal parenchyma. Smoldering subclinical graft inflammation and/or abnormalities of dendritic cells or natural killer cell/T-cell activation might also be significant factors promoting PVN [42,43,44<sup>11</sup>]. In particular, an abundance of BK-virus-specific T cells seems to be associated with control of polyomavirus replication, prevention of PVN, or effective disease resolution [45–48]. Whether or not these intriguing latter observations will, indeed, result in novel targeted ‘immunotherapies’ remains to be determined [49].

### POLYOMAVIRUS NEPHROPATHY PHENOTYPES

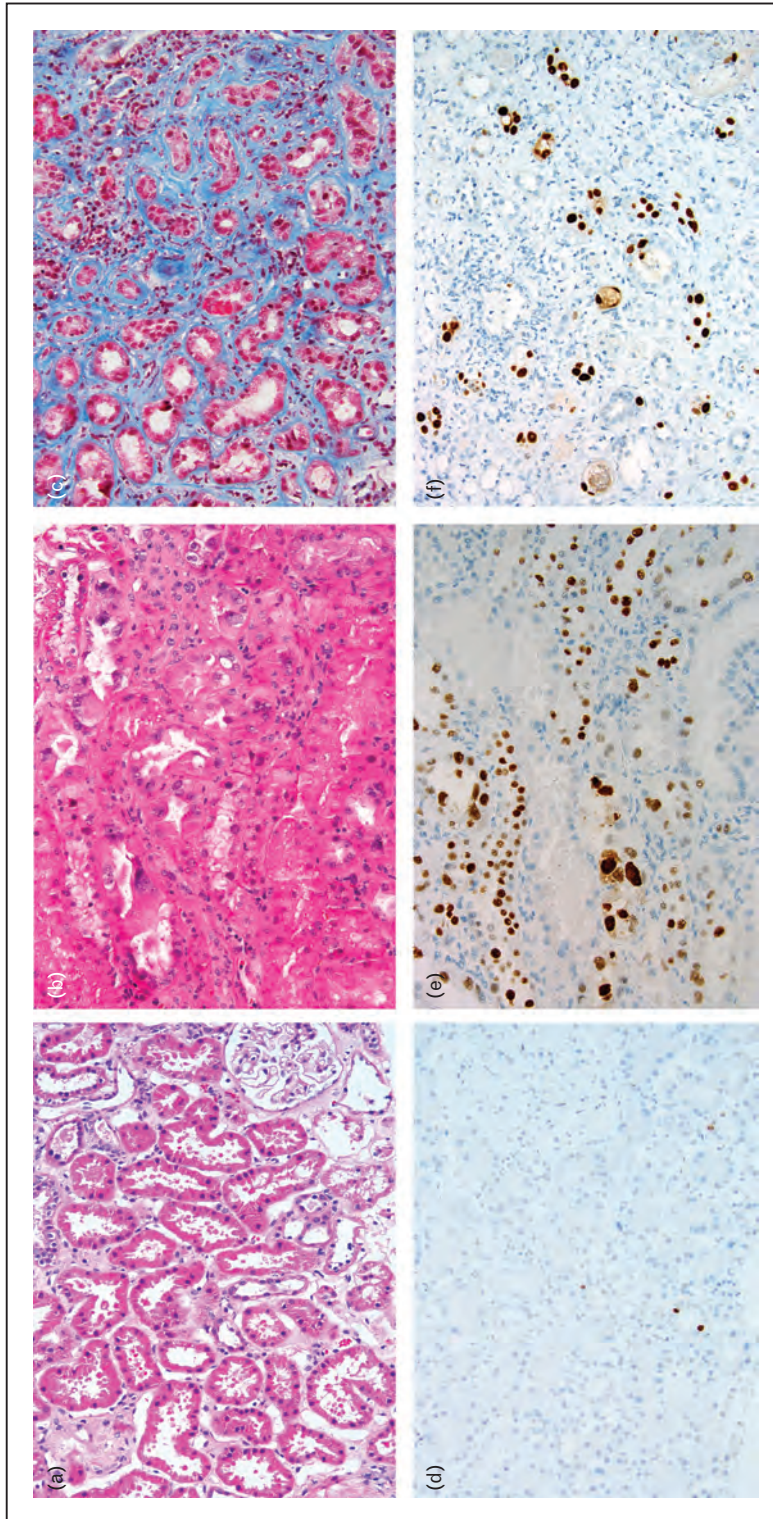
PVN is defined morphologically by intrarenal polyomavirus replication, mainly in tubular epithelial cell nuclei, that leads to host cell lysis and release of mature daughter virions into the tubular lumens. Thus, PVN is a form of virally induced tubular injury that can range from minimal, that is, polyomavirus replication in rare tubular cells only, to marked, that is, polyomavirus replication in many tubules with marked cell lysis and acute tubular necrosis (ATI) [29]. Minimal and early stages of PVN present with normal renal function and may not show intranuclear viral inclusion bodies, ATI, or significant renal injury. In such cases, a diagnosis can only be established by immunohistochemistry, usually with an antibody directed against the SV40-T antigen or by in-situ hybridization [33<sup>11</sup>]. Marked PVN with ATI typically presents clinically with elevated serum creatinine levels and histologically with edema,

inflammation, and, in protracted chronic cases, interstitial fibrosis.

Despite the marked differences in morphology and clinical presentation, PVN has traditionally not been systematically subtyped into disease grades. However, does ‘a’ mere diagnosis of PVN provide optimal diagnostic/prognostic information? Can PVN phenotypes possibly predict differences in clinical presentation and outcome [50–53]? These questions were the impetus to form a multicenter ‘Banff working group’ on PVN with the goal to define clinically relevant PVN disease grades based on histologic findings in graft biopsies. Efforts resulted in initial data presentation at the 2013 Banff meeting in Brazil [54]. Utilizing complex statistical analyses from a cohort of nearly 200 PVN study cases, the Banff working group has proposed three PVN disease grades based on the severity of polyomavirus replication and the Banff ‘ci’ interstitial fibrosis scores (Fig. 1). PVN grade 1 with limited histologic polyomavirus replication and minimal fibrosis was found early post-grafting, often without significant dysfunction, and with a 2-year graft survival rate of 90%. In contrast, PVN disease grade 2 and, in particular, grade 3, the latter characterized by marked viral injury and pronounced fibrosis, were both diagnosed more than 6–12 months post-transplantation, usually in patients with acute graft failure. Graft outcome was also less favorable (30% failure rate in grade 2 and 50% in grade 3). In addition, PVN grading seems to provide better insight into disease resolution seen in up to 80% in PVN grade 1 and 40–50% in grade 3 (unpublished personal observation). These findings, although preliminary, outline the benefits of systematic PVN grading: enhancement of comparative analyses and improvement in predicting clinical presentation and outcome. Thus, all cases of ‘definitive’ PVN are not equal and, most notably, not all cases of ‘definitive’ PVN have an ominous prognosis.

A poorly defined diagnostic aspect, in particular, considering treatment strategies based on the reduction of immunosuppression, is the concurrence of PVN and acute rejection [55,56<sup>11</sup>]. Applying previously published diagnostic criteria, we found acute rejection in 10–15% of our cases at the time of initial PVN diagnosis. Rejection as a possible contributing factor of graft dysfunction and failure in PVN is suggested by data from the Weill Cornell Medical Center, New York, New York, USA. Dadhania *et al.* [57] reported graft deterioration in those cases of PVN presenting with elevated urinary granzyme B mRNA levels that were similar to titers seen in control cohorts with acute rejection. Also, PVN with marked tubulitis, one possible sign of concurrent acute rejection, often fares poorly [58].





**FIGURE 1.** Histologic polyomavirus nephropathy (PVN) disease grades. (a) and (d) PVN disease grade 1 with mild viral nephropathy. (a) By light microscopy, no characteristic and diagnostic viral inclusion bodies are identified [H&E stain,  $\times 200$  magnification]. (d) Evidence of viral replication is provided by a positive staining signal for the SV40-T antigen found in rare tubular epithelial cell nuclei [SV40-T antigen immunostain,  $\times 200$  magnification]. (b) and (e) PVN disease grade 2 with florid viral nephropathy. (b) Severely injured tubules containing many viral inclusion bearing epithelial cells are seen both in an H&E stain ( $\times 200$  magnification) and (e) in an SV40-T antigen immunostain ( $\times 200$  magnification). (c) and (f) PVN disease grade 3 with marked sclerosing viral nephropathy [(c) trichrome stain,  $\times 200$  magnification; (f) SV40-T antigen immunostain,  $\times 200$  magnification].

## POLYOMAVIRUS NEPHROPATHY: PERSISTENT AND RESOLVING

Very little information is known about the histologic changes occurring during persistent and resolving PVN. As commonly believed, is marked chronic allograft injury with interstitial fibrosis and tubular atrophy, indeed, a typical endpoint in all stages of PVN? Does reconstitution immune injury with pronounced graft inflammation exist, and, if so, is it a typical feature of resolving PVN?

Menter *et al.* [56<sup>■</sup>] published the first histology-based study on resolving PVN in a cohort of patients initially diagnosed in early and florid disease stages; during follow-up, significant graft fibrosis and tubular atrophy was not seen at time of disease resolution. We have made similar observations: PVN often does not cause relevant scarring.

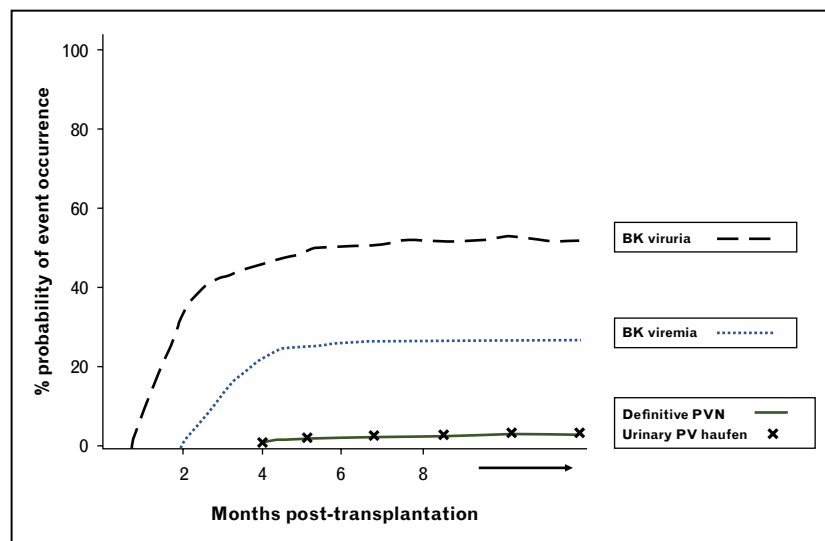
Possible immune reconstitution-associated graft inflammation during resolving PVN in a patient under 'low-dose' immunosuppression was first suggested by researchers from Basel, Switzerland, in 2007 [59]. Subsequently, Menter *et al.* [56<sup>■</sup>] presented data from patients with resolving/cleared PVN and graft inflammation mimicking Banff type I tubulointerstitial cellular rejection. The changes were interpreted as immune reconstitution-associated acute interstitial nephritis, antirejection therapy was withheld, and outcome was good [56<sup>■</sup>]. In contrast, we have not found significant inflammation in a set of protocol biopsies from patients with resolved PVN (unpublished data). In the future, multicenter analyses are needed to

thoroughly study immune reconstitution injury under 'low-dose' immunosuppression: does it exist; if so, is it a common and prominent event; is it linked to persistent/residual intrarenal polyomavirus replication and a form of polyomavirus-driven interstitial nephritis; are graft-infiltrating lymphocytes allospecific or BKV specific; and could inflammation possibly represent an unusual form of subclinical rejection?

## CURRENT PARADIGMS AND SCREENING TOOLS GUIDING PATIENT MANAGEMENT

All patients with PVN have evidence of polyomavirus activation, most often BKV, including viremia and viruria. Current clinical screening recommendations for the risk assessment of PVN postrenal transplantation are based on this paradigm [28,60–63]. Conversely, however, only few patients with BK viremia and BK viruria have or will develop disease, that is, 'definitive' PVN, as transient asymptomatic reactivation of latent polyomaviruses is common along the lower urinary tract (Fig. 2).

For example, in a cohort of 100 renal allograft recipients from the University of North Carolina at Chapel Hill (UNC), none of whom developed PVN, we found BK viruria in 51–64% (based on PCR testing or the detection of decoy cells, respectively) [30]. BK viremia is not uncommon either. It was detected in 4% of liver, 7% of heart transplant recipients, in up to 65% of pediatric patients with hemorrhagic cystitis post-bone marrow transplantation, as well as in HIV-infected individuals with



**FIGURE 2.** Schematic graph with estimates of BK-virus activation, that is, BK viruria, BK viremia, urinary polyomavirus-haufen shedding and viral nephropathy/PVN postrenal transplantation. Although viruria and viremia are detected in a high percentage of patients, 'definitive' PVN develops in only a small subgroup of 'viral activators'. Note: A positive urinary polyomavirus-haufen test is almost exclusively seen in patients with definitive PVN and can help to render a noninvasive diagnosis in patients clinically presenting with evidence of BK-virus activation. BKV, BK virus; PVN, polyomavirus nephropathy.

salivary gland disease (personal observation), all of whom usually do not develop PVN [11<sup>■</sup>,30,64–66]. In renal allograft recipients, BK viremia (based on quantitative PCR testing) has been reported in 16–54% of patients in large consecutively studied cohorts, only 14–46% of whom present with evidence of ‘definitive’ PVN [36,53,67,68]. In a prospective study at UNC including routine urinary polyomavirus-haufen testing (see in the next section), we found BK viremia in 114/399 (29%) kidney transplant recipients of whom only 36/114 (32%) developed ‘definitive’ PVN (unpublished data).

In order to improve the positive predictive value of PCR-based BK-viremia assays, threshold levels of greater than 4 log<sub>10</sub> copies/ml have been advocated. However, problems remain. PCR assays are not standardized rendering general recommendations based on threshold levels problematic. Few patients with PVN may be negative for BK viremia (PVN caused by JC virus; PCR assay targeting BK gene sequences with polymorphism/mutations). Other patients with PVN may present at time of initial diagnosis with very low BK-viremia titers (occasionally as low as 2 log<sub>10</sub>, BK copies/ml) [30,67,68]. Conversely, even high BK-viremia titers do not necessarily allow for a diagnosis of ‘definitive’ PVN as shown in a cohort of 17 disease-free patients with mean BK-viremia levels greater than 4 log<sub>10</sub>

and in 3/17 UNC patients (18%) collected in a control cohort [30,69<sup>■</sup>]. Similar overall observations were reported from the University of Basel [56<sup>■</sup>].

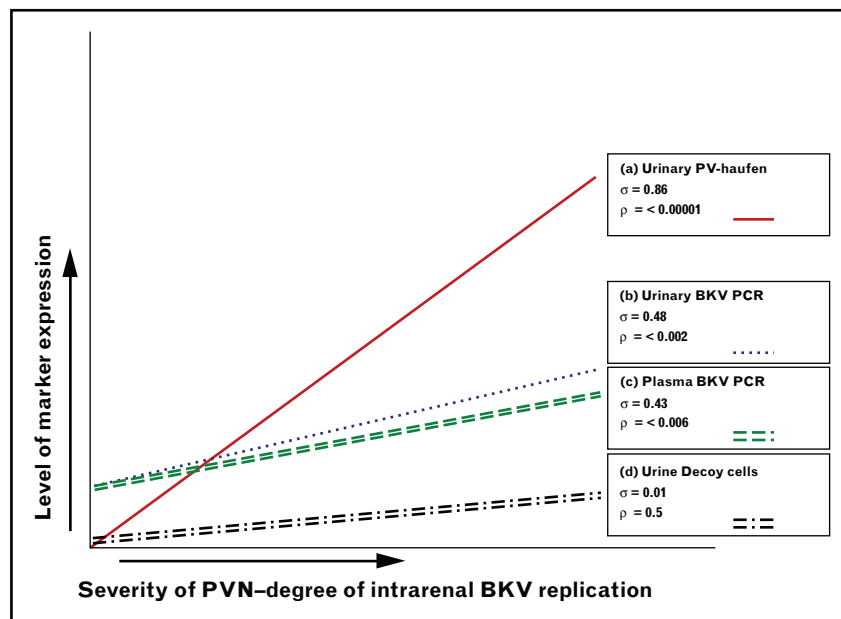
In patients with ‘definitive’ PVN, BK viremia titers correlate only moderately well with the severity of intrarenal disease and BKV replication (Fig. 3) [31<sup>■</sup>,56<sup>■</sup>]. This latter observation casts further doubt on the assumption that PCR-based BK-viremia testing accurately reflects intrarenal events and the severity of PVN in a linear fashion.

Thus, although the negative predictive value of ‘BKV replication/activation-based laboratory tests’, that is, viruria and viremia, is excellent at higher than 90% to rule out a diagnosis of PVN, the positive predictive values are lower, ranging between 25% and 75% [28,30].

## ADDITIONAL NEW TESTS

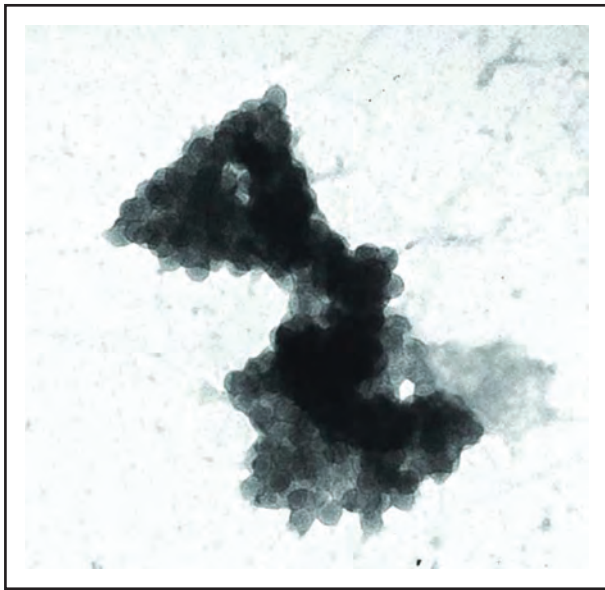
### Urinary polyomavirus-haufen test

A diagnosis of ‘definitive’ PVN can now be rendered noninvasively with a novel urine-based assay, called the ‘urinary polyomavirus-haufen test’ (haufen is a German term for heap or pile) (Fig. 4). Polyomavirus-haufen form in the kidneys, that is, in virally injured tubules, subsequent to polyomavirus replication, host cell lysis, and release of virions into



**FIGURE 3.** Cases of ‘definitive’ polyomavirus nephropathy (PVN): severity of intrarenal disease and corresponding titers of urine and plasma markers. Correlation of the degree of marker expression (quantitative screening test results – y-axis) with the severity of PVN –intrarenal polyomavirus replication, that is, the number of SV40-T expressing tubular epithelial cells in a biopsy sample with PVN (x-axis). (a) Urinary polyomavirus-haufen: number of haufen/ml urine; (b) urine PCR for BK virus (BKV): number of BKV copies/ml urine; (c) plasma PCR for BKV: number of BKV copies/ml plasma; and (d) urine decoy cells: number of decoy cells/ThinPrep cytology preparation. Regression lines with corresponding correlation coefficients ( $\sigma$ ) and  $\rho$  values are depicted. Adapted from [31<sup>■</sup>].





**FIGURE 4.** Voided urine sample with polyomavirus-haufen in a patient with ‘definitive’ polyomavirus nephropathy. Negative staining electron microscopy depicting a characteristic polyomavirus-haufen in a voided urine sample. Polyomavirus-haufen are tight cast-like three-dimensional viral aggregates composed of at least six individual virions. Note the large size of this polyomavirus-haufen resembling a tubular cast. The diagnostic viral capsid substructure and uniformity of virions allow for accurate identification by electron microscopy (uranyl acetate stain:  $\times 100\,000$  magnification).

tubular lumens. The genesis of polyomavirus-haufen depends upon high concentrations of uromodulin (Tamm–Horsfall protein) and is very similar to the formation of other intratubular casts, such as red blood cell casts [70]. Once the polyomavirus casts are flushed out of the kidney, they can be detected as the so-called polyomavirus-haufen in voided urine samples. They are specific biomarkers for intrarenal viral disease with positive and negative predictive values of higher than 90% (Fig. 5) [30].

Post-transplantation, polyomavirus-haufen shedding follows a dynamic course – the test turns from negative to positive at time of PVN onset, remains positive during persistent disease, and becomes negative again at the time of disease resolution [30]. The titer of polyomavirus-haufen in the urine (#haufen/ml urine) tightly correlates with the degree of intrarenal polyomavirus replication (correlation coefficient 0.86) (Fig. 3). Thus, quantitative urinary polyomavirus-haufen testing can provide additional information on the severity of PVN that is relevant for diagnosis and monitoring of disease resolution during follow-up [31<sup>\*\*\*</sup>].

Although experience is still limited and results obtained with the urinary polyomavirus-haufen test

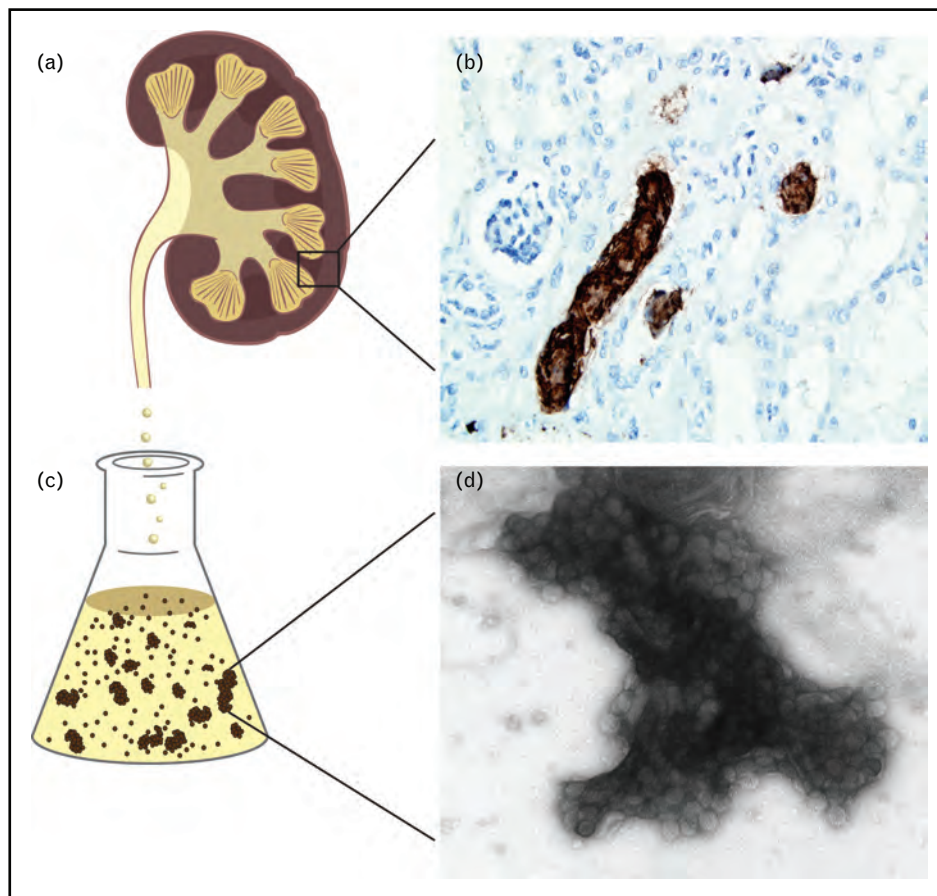
require further validation, published data are very promising. We finally seem to have an assay based on a novel approach that not only accurately and noninvasively identifies patients with ‘definitive’ PVN but also predicts the disease severity.

### Urinary VP1 mRNA measurements

In 2002, the team from Weill Cornell Medical Center evaluated BKV VP1 mRNA levels in voided urine samples from patients with and without PVN [71]. Using a cutoff value of  $6.5 \times 5 \log_{10}$  BKV VP1 mRNA copies per nanogram total RNA, the authors reported a 94% sensitivity and specificity for PVN. In 2010, the group further validated their original findings in a larger cohort of patients. They found that urinary BKV VP1 mRNA expression as well as concurrently elevated levels of mRNA for granzyme B ( $>11$  mRNA copies/ $\mu\text{g}$  total RNA) and proteinase inhibitor-9 ( $>10$  mRNA copies/ $\mu\text{g}$  total RNA) were associated with deterioration of graft function in PVN [57]. In a subsequent follow-up study limited to patients with PVN, they described urinary cell levels of mRNA for plasminogen activator inhibitor-1 and serum creatinine levels at time of initial PVN diagnosis to represent independent prognosticators of graft failure [72<sup>\*\*\*</sup>]. These observations are intriguing because they offer not only additional strategies to noninvasively diagnose ‘definitive’ PVN but also to predict outcome. As elevated granzyme B levels are typically found in patients with acute cellular rejection, these data might indicate a higher than expected prevalence of undiagnosed concurrent cellular rejection contributing to graft deterioration in some cases.

### POLYOMAVIRUS NEPHROPATHY: DEFINITIVE AND PRESUMPTIVE

The terms ‘definitive’ and ‘presumptive’ PVN were coined a decade ago. The prefix ‘definitive’ marks cases with biopsy-proven intrarenal viral disease, the term ‘presumptive’ was introduced for patients with significant BKV replication but lack of histologic proof of PVN, potentially due to false-negative biopsy samples [56<sup>\*\*\*</sup>]. Transplant recipients with ‘presumptive’ PVN were believed to be at increased risk for graft failure due to undiagnosed viral nephropathy that carried an ominous prognosis a decade ago [60]. In current clinical practice, ‘presumptive PVN’ often equals ‘definitive PVN’ and the necessity for therapeutic intervention [28,56<sup>\*\*\*</sup>]. This approach undoubtedly potentially has some benefits in facilitating the prevention of PVN. However, reduction of baseline immunosuppression as the common therapeutic strategy is also associated with clinical



**FIGURE 5.** Polyomavirus-haufen in patients with polyomavirus nephropathy. A cartoon image of a bivalved kidney (a) highlighting an area of parenchyma sampled by renal biopsy (square box). An immunostain for the polyomavirus VP1 capsid protein (b) shows strong staining of cast-like intratubular dense polyomavirus aggregates in injured renal tubules. These cast-like viral structures are shed into the urine (c) and can serve as robust ‘structural’ urinary biomarkers for intrarenal disease, that is, they give rise to a positive polyomavirus-haufen test (d) [30–32].

acute rejection rates of 8–14% and subclinical rejection rates of 20–33% [36,73,74]. Notably, in 30% of patients with BK viremia/‘presumptive’ PVN reported in one series, preemptive reduction of immunosuppression could not prevent the subsequent development of ‘definitive’ PVN [74].

‘Presumptive’ and ‘definitive’ PVN – is it time for a fresh contemporary approach? We believe the following six findings are noteworthy and can guide future discussions: definitive PVN in early disease grades has good outcome; less than 50% of patients with BK viremia develop intrarenal disease with definitive PVN; BK viremia can originate from extrarenal sites; the noninvasive urinary polyomavirus-haufen test and mRNA test for BKV capsid protein offer strategies to diagnose ‘definitive’ PVN and disease severity; preemptive therapeutic intervention in patients with BK-viremia/presumptive PVN does not always prevent the development of ‘definitive’ PVN; and reduction of immunosuppression increases the risk of rejection.

These observations might pave the way for future studies and targeted therapies focusing on patient screening, an accurate definitive diagnosis of early PVN, and personalized treatment of individual patients with disease. Is the current ‘one size-fits-all’ therapeutic approach in presumptive PVN, triggered by nonstandardized PCR test results and BK-viremia titers, still the best we have to offer?

## ONCOGENESIS

Over the past decade, approximately 20 publications reported high-grade invasive renal or urothelial neoplasms expressing polyomavirus large T antigen. These unusual and rare tumors occur in organ transplant recipients, most often post-kidney transplantation with or occasionally without a history of PVN. They arise either in the (transplanted) kidney or the ureters/host bladder [19,75,76]. Likely, oncogenesis in these neoplasms is similar to that described in Merkel cell carcinoma



with integration of polyomaviruses, presumably BKV, into the human genome representing a 'rare' biological accident with dire consequences [19,77,78]. There is no compelling evidence of viral replication or productive polyomavirus infections in the neoplasms and screening for BK viremia or viruria is not suited for early tumor detection [79].

### SALIVARY GLAND DISEASE

BKV has been detected in tonsils and nasopharyngeal aspirates, usually representing latent viral infections. Recently, BKV has also been associated with a sclerosing lymphocytic inflammatory salivary gland disease found in a subgroup of HIV-infected individuals. Preliminary data suggest that certain BKV strains preferentially infect salivary gland cells over kidney cells and replicate with viremia and shedding of daughter virions into saliva ( $>5 \log_{10}$  BK copies/ml) [9,10].

Although BKV-associated salivary gland disease does not seem to be of great clinical significance post-transplantation, these data are, nevertheless, intriguing. They suggest that replication of BKV including viremia can originate outside the urinary tract in immunocompromised patients not suffering from PVN. Future studies are needed to further investigate the significance of BKV replication in salivary glands of organ transplant recipients.

### POLYOMAVIRUS DISEASE IN THE SETTING OF BONE MARROW TRANSPLANTATION

Post-hematopoietic stem cell transplantation (HSCT) BKV activation and replication is associated with various clinical findings ranging from asymptomatic viruria, viremia, cystitis without hematuria, and hemorrhagic cystitis with increased morbidity and mortality [11,64,65,80]. BK viremia levels higher than  $4 \log_{10}$  viral copies/ml mark an increased risk for hemorrhagic cystitis in adult HSCT recipients (odds ratio = 21) [81]. In the pediatric HSCT population, Laskin *et al.* [11] showed that BK viremia at any titer, but especially viral copy numbers higher than  $5 \log_{10}$ /ml plasma, independently predicted the development of hemorrhagic cystitis in the first 100 days post-transplantation. So far, standardized clinical definitions and screening guidelines have not been established [64].

As invasive biopsy procedures are generally avoided in HSCT recipients because of increased risk for severe bleeding, only little information is known about the prevalence of PVN in this patient cohort, and clinical experience is largely limited to few case reports [82,83]. Does PVN possibly contribute to the

development of chronic kidney disease seen in at least 20% of children post-HSCT [84,85]? In a pilot analysis, Laskin *et al.* found evidence of PVN, based on a positive urinary polyomavirus-haufen test, in five out of 11 pediatric patients with HSCT presenting with BK viremia and either with or without concurrent cystitis (personal communication). Thus, post-HSCT, PVN might be more common than previously thought and the urinary polyomavirus-haufen test may prove to be of great clinical value.

### CONCLUSION

PVN, historically considered to carry an ominous prognosis, has evolved into a manageable and treatable disease. Patient screening protocols for risk assessment and classification schemes to grade PVN have led to the characterization of early disease grades that are responsive to therapeutic intervention and heal without significant chronic graft injury. Novel diagnostic assays, such as the urinary polyomavirus-haufen test, now provide accurate noninvasive means to diagnose 'definitive' PVN and assess disease severity in voided urine samples. As BKV replication and BK viremia are seen in patients without renal injury and viral nephropathy, accurate noninvasive diagnostic testing becomes crucial not only for personalized therapeutic intervention but also for enhancing knowledge. Are so-called 'presumptive' and 'definitive' PVN the same disease entity?

The novel and currently only poorly understood concept of immune reconstitution injury and graft inflammation in patients with resolving PVN is an area for future investigation. Is this a cellular response driven by virus-specific T cells that is self-limiting and beneficial for viral clearance? Or, might this type of inflammation represent a more harmful form of subclinical rejection with graft infiltrating allospecific T cells detrimental to long-term transplant integrity?

In immunocompromised patients, BKV is associated with oncogenesis, possibly salivary gland disease, and hemorrhagic cystitis. New members of the polyomavirus family are being identified with novel disease profiles. Thus, much has been learned about polyomaviruses over the past 10 years but many aspects still await further in-depth analysis. Viremia and viruria alone cannot illuminate the entire saga of polyomaviruses, viral nephropathy, and human disease.

### Acknowledgements

None.

## Financial support and sponsorship

None.

## Conflicts of interest

V.N. is supported by an investigator-initiated grant from Astellas Pharmaceuticals and serves as central review pathologist for Alexion. H.K.S. has no conflicts of interest.

## REFERENCES AND RECOMMENDED READING

Papers of particular interest, published within the annual period of review, have been highlighted as:

- of special interest
- of outstanding interest

1. Rinaldo CH, Hirsch HH. The human polyomaviruses: from orphans and mutants to patchwork family. *Acta Pathol Microbiol Immunol Scand* 2013; 121:681–684.
2. Mishra N, Pereira M, Rhodes RH, *et al.* Identification of a novel polyomavirus in a pancreatic transplant recipient with retinal blindness and vasculitic myopathy. *J Infect Dis* 2014; 210:1595–1599.

This is the first description of a novel polyomavirus strain with possible tropism for vascular endothelium commonly not seen in productive polyomavirus infections.

3. Dalianis T, Hirsch HH. Human polyomaviruses in disease and cancer. *Virology* 2013; 437:63–72.

An excellent up-to-date overview of the various human polyomaviruses identified thus far and their role in driving disease and cancer.

4. Husseiny MI, Anastasi B, Singer J, Lacey SF. A comparative study of Merkel cell, BK and JC polyomavirus infections in renal transplant recipients and healthy subjects. *J Clin Virol* 2010; 49:137–140.
5. van der Meijden E, Wunderink HF, van der Blij-de Brouwer CS, *et al.* Human polyomavirus 9 infection in kidney transplant patients. *Emerg Infect Dis* 2014; 20:991–999.
6. Hirsch HH, Babel N, Comoli P, *et al.* European perspective on human polyomavirus infection, replication and disease in solid organ transplantation. *Clin Microbiol Infect* 2014; 20 (Suppl 7):74–88.

This is a comprehensive article discussing human polyomaviruses in solid-organ transplant recipients, and current recommendations for screening, management, and treatment of the various human diseases caused by polyomaviruses with particular focus on PVN.

7. Bloomgren G, Richman S, Hotermans C, *et al.* Risk of natalizumab-associated progressive multifocal leukoencephalopathy. *N Engl J Med* 2012; 366:1870–1880.
8. Rinaldo CH, Tylden GD, Sharma BN. The human polyomavirus BK (BKPv): virological background and clinical implications. *Acta Pathol Microbiol Immunol Scand* 2013; 121:728–745.
9. Jeffers L, Webster-Cyriaque JY. Viruses and salivary gland disease (SGD): lessons from HIV SGD. *Adv Dental Res* 2011; 23:79–83.
10. Burger-Calderson R, Madden V, Hallett RA, *et al.* Replication of oral BK virus in human salivary gland cells. *J Virol* 2014; 88:559–573.

This article describes BKV infections of salivary gland cells and the potential role for BKV in the development of salivary gland disease in immunocompromised HIV-infected patients. Data suggest a role for BKV and productive infections in disease processes outside the urogenital tract with BK shedding into body fluids.

11. Laskin BL, Denburg M, Furth S, *et al.* BK viremia precedes hemorrhagic cystitis in children undergoing allogeneic hematopoietic stem cell transplantation. *Biol Blood Marrow Transplant* 2013; 19:1175–1182.

This is the largest series of pediatric patients who received hematopoietic stem cell transplants in which plasma samples were collected prospectively and BK viral load levels measured systematically. The findings demonstrate a very strong association of BK viremia and the development of hemorrhagic cystitis. Data also underscore that BK viremia can originate from sites other than the kidney itself.

12. Coursaget P, Samimi M, Nicol JT, *et al.* Human Merkel cell polyomavirus: virological background and clinical implications. *Acta Pathol Microbiol Immunol Scand* 2013; 121:755–769.
13. Carter JJ, Paulson KG, Wipf GC, *et al.* Association of Merkel cell polyomavirus-specific antibodies with Merkel cell carcinoma. *J Natl Cancer Inst* 2009; 101:1510–1522.
14. Feng H, Shuda M, Chang Y, Moore PS. Clonal integration of a polyomavirus in human Merkel cell carcinoma. *Science (New York, NY)* 2008; 319:1096–1100.
15. Kassem A, Schopflin A, Diaz C, *et al.* Frequent detection of Merkel cell polyomavirus in human Merkel cell carcinomas and identification of a unique deletion in the VP1 gene. *Cancer Res* 2008; 68:5009–5013.

16. Viscidi RP, Rollison DE, Sondak VK, *et al.* Age-specific seroprevalence of Merkel cell polyomavirus, BK virus, and JC virus. *Clin Vaccine Immunol* 2011; 18:1737–1743.
17. Matthews MR, Wang RC, Reddick RL, *et al.* Viral-associated trichodysplasia spinulosa: a case with electron microscopic and molecular detection of the trichodysplasia spinulosa-associated human polyomavirus. *J Cutaneous Pathol* 2011; 38:420–431.
18. van der Meijden E, Kazem S, Burgers MM, *et al.* Seroprevalence of trichodysplasia spinulosa-associated polyomavirus. *Emerg Infect Dis* 2011; 17:1355–1363.
19. Geetha D, Tong BC, Racusen L, *et al.* Bladder carcinoma in a transplant recipient: evidence to implicate the BK human polyomavirus as a causal transforming agent. *Transplantation* 2002; 73:1933–1936.
20. Gardner SD, Field AM, Coleman DV, Hulme B. New human papovavirus (B.K.) isolated from urine after renal transplantation. *Lancet* 1971; 1:1253–1257.
21. Padgett BL, Walker DL, ZuRhein GM, *et al.* Cultivation of papova-like virus from human brain with progressive multifocal leukoencephalopathy. *Lancet* 1971; 1:1257–1260.
22. Gosert R, Kardas P, Major EO, Hirsch HH. Rearranged JC virus noncoding control regions found in progressive multifocal leukoencephalopathy patient samples increase virus early gene expression and replication rate. *J Virol* 2010; 84:10448–10456.
23. Khanna N, Wolbers M, Mueller NJ, *et al.* JC virus-specific immune responses in human immunodeficiency virus type 1 patients with progressive multifocal leukoencephalopathy. *J Virol* 2009; 83:4404–4411.
24. Schroder A, Lee DH, Hellwig K, *et al.* Successful management of natalizumab-associated progressive multifocal leukoencephalopathy and immune reconstitution syndrome in a patient with multiple sclerosis. *Arch Neurol* 2010; 67:1391–1394.
25. Hirsch HH, Kardas P, Kranz D, Leboeuf C. The human JC polyomavirus (JCPv): virological background and clinical implications. *Acta Pathol Microbiol Immunol Scand* 2013; 121:685–727.
26. Maginnis MS, Nelson CD, Atwood WJ. JC polyomavirus attachment, entry, and trafficking: unlocking the keys to a fatal infection. *J Neurovirol* 2014. [Epub ahead of print]
27. Sharma SG, Nickeleit V, Herlitz LC, *et al.* BK polyoma virus nephropathy in the native kidney. *Nephrol Dialysis Transplant* 2013; 28:620–631.

This is a series of eight cases of PVN diagnosed in native kidneys; pathologic features, risk factors, and outcome data are discussed.

28. Hirsch HH, Randhawa P. BK polyomavirus in solid organ transplantation. *Am J Transplant* 2013; 13 (Suppl 4):179–188.
29. Nickeleit V, Colvin RB, Mengel M. Renal transplant pathology. In: Jennette JC, Olson JL, D'Agati VD, Silva FG, editors. *Heptinstall's pathology of the kidney*. 2. Philadelphia, PA: Lippincott, Williams & Wilkins; 2014. pp. 1441–1446.
30. Singh H, Andreoni KA, Madden V, *et al.* Presence of urinary haufen accurately predicts polyomavirus nephropathy. *J Am Soc Nephrol* 2009; 20:416–427.
31. Singh HK, Reisner H, Derebail VK, *et al.* Polyomavirus nephropathy: quantitative urinary polyomavirus-haufen testing accurately predicts the degree of intrarenal viral disease. *Transplantation* 2015; 99:609–615.

This paper describes the utility of a novel non-invasive assay for PVN, the urinary polyomavirus-Haufen test, with special emphasis on quantitative test results. The authors report that the number of cast-like polyomavirus Haufen per ml of urine tightly correlates with the severity of 'intra renal' polyomavirus nephropathy. Such correlation is, in comparison, not seen with quantitative PCR assays for BK-viremia and viremia. The findings shed serious doubts on the common clinical practice of assuming that BK viremia levels and PCR results accurately reflect the degree of virally induced renal injury.

32. Singh HK, Donna Thompson B, Nickeleit V. Viral Haufen are urinary biomarkers of polyomavirus nephropathy: new diagnostic strategies utilizing negative staining electron microscopy. *Ultrastruct Pathol* 2009; 33:222–235.
33. Adam B, Randhawa P, Chan S, *et al.* Banff initiative for quality assurance in transplantation (BIFQUIT): reproducibility of polyomavirus immunohistochemistry in kidney allografts. *Am J Transplant* 2014; 14:2137–2147.

This is a large multicenter reproducibility study mainly evaluating the immunohistochemical staining and scoring of SV40 large T antigen on tissue. Results confirm the diagnostic role of immunostains for SV40-T as a reliable marker for PVN.

34. Sharif A, Alachkar N, Bagnasco S, *et al.* Incidence and outcomes of BK virus allograft nephropathy among ABO- and HLA-incompatible kidney transplant recipients. *Clin J Am Soc Nephrol* 2012; 7:1320–1327.
35. Sharif A, Alachkar N, Kraus E. Incompatible kidney transplantation: a brief overview of the past, present and future. *QJM* 2012; 105:1141–1150.
36. Sood P, Senanayake S, Sujeet K, *et al.* Management and outcome of BK viremia in renal transplant recipients: a prospective single-center study. *Transplantation* 2012; 94:814–821.
37. Li YJ, Weng CH, Lai WC, *et al.* A suppressive effect of cyclosporine A on replication and noncoding control region activation of polyomavirus BK virus. *Transplantation* 2010; 89:299–306.
38. Binet I, Nickeleit V, Hirsch HH, *et al.* Polyomavirus disease under new immunosuppressive drugs: a cause of renal graft dysfunction and graft loss. *Transplantation* 1999; 67:918–922.
39. Nickeleit V, Hirsch HH, Zeiler M, *et al.* BK-virus nephropathy in renal transplants-tubular necrosis, MHC-class II expression and rejection in a puzzling game. *Nephrol Dialysis Transplant* 2000; 15:324–332.

40. Hirsch HH, Vincenti F, Friman S, *et al.* Polyomavirus BK replication in de novo kidney transplant patients receiving tacrolimus or cyclosporine: a prospective, randomized, multicenter study. *Am J Transplant* 2013; 13:136–145.
41. Brennan DC, Agha I, Bohl DL, *et al.* Incidence of BK with tacrolimus versus cyclosporine and impact of preemptive immunosuppression reduction. *Am J Transplant* 2005; 5:582–594.
42. Trydzenskaya H, Juerchott K, Lachmann N, *et al.* The genetic predisposition of natural killer cell to BK virus-associated nephropathy in renal transplant patients. *Kidney Int* 2013; 84:359–365.
43. Womer KL, Huang Y, Herren H, *et al.* Dendritic cell deficiency associated with development of BK viremia and nephropathy in renal transplant recipients. *Transplantation* 2010; 89:115–123.
44. Schmidt T, Adam C, Hirsch HH, *et al.* BK polyomavirus-specific cellular immune responses are age-dependent and strongly correlate with phases of virus replication. *Am J Transplant* 2014; 14:1334–1345.
- A comprehensive study demonstrating the age-dependent cellular immune responses to BK polyomavirus in both immunocompetent adults and patients with renal transplants emphasizing the role of T-cell responses and cytokine expression in regulating polyomaviruses replication.
45. Prosser SE, Orentas RJ, Jurgens L, *et al.* Recovery of BK virus large T-antigen-specific cellular immune response correlates with resolution of BK virus nephritis. *Transplantation* 2008; 85:185–192.
46. Comoli P, Hirsch HH, Ginevri F. Cellular immune responses to BK virus. *Curr Opin Organ Transplant* 2008; 13:569–574.
47. Schachtner T, Muller K, Stein M, *et al.* BK virus-specific immunity kinetics: a predictor of recovery from polyomavirus BK-associated nephropathy. *Am J Transplant* 2011; 11:2443–2452.
48. Binggeli S, Egli A, Schaub S, *et al.* Polyomavirus BK-specific cellular immune response to VP1 and large T-antigen in kidney transplant recipients. *Am J Transplant* 2007; 7:1131–1139.
49. Mani J, Jin N, Schmitt M. Cellular immunotherapy for patients with reactivation of JC and BK polyomaviruses after transplantation. *Cytotherapy* 2014; 16:1325–1335.
50. Vasudev B, Hariharan S, Hussain SA, *et al.* BK virus nephritis: risk factors, timing, and outcome in renal transplant recipients. *Kidney Int* 2005; 68:1834–1839.
51. Ramos E, Drachenberg CB, Papadimitriou JC, *et al.* Clinical course of polyoma virus nephropathy in 67 renal transplant patients. *J Am Soc Nephrol* 2002; 13:2145–2151.
52. Schwarz A, Linnenweber-Held S, Heim A, *et al.* Factors influencing viral clearing and renal function during polyomavirus BK-associated nephropathy after renal transplantation. *Transplantation* 2012; 94:396–402.
53. Jacobi J, Prignitz A, Buttner M, *et al.* BK viremia and polyomavirus nephropathy in 352 kidney transplants; risk factors and potential role of mTOR inhibition. *BMC Nephrol* 2013; 14:207.
54. Haas M, Sis B, Racusen LC, *et al.* Banff 2013 meeting report: inclusion of c4d-negative antibody-mediated rejection and antibody-associated arterial lesions. *Am J Transplant* 2014; 14:272–283.
55. Nicleleit V, Mihatsch MJ. Polyomavirus allograft nephropathy and concurrent acute rejection: a diagnostic and therapeutic challenge. *Am J Transplant* 2004; 4:838–839.
56. Menter T, Mayr M, Schaub S, *et al.* Pathology of resolving polyomavirus-associated nephropathy. *Am J Transplant* 2013; 13:1474–1483.
- This is the first large biopsy-based series of patients with resolving/healed PVN evaluating histologic features, clinical presentation, and treatment strategies. The authors discuss the concept of immune reconstitution type of graft inflammation and outline potential diagnostic and therapeutic implications.
57. Dadhania D, Snopkowski C, Ding R, *et al.* Validation of noninvasive diagnosis of BK virus nephropathy and identification of prognostic biomarkers. *Transplantation* 2010; 90:189–197.
58. Drachenberg CB, Papadimitriou JC, Hirsch HH, *et al.* Histological patterns of polyomavirus nephropathy: correlation with graft outcome and viral load. *Am J Transplant* 2004; 4:2082–2092.
59. Schaub S, Mayr M, Egli A, *et al.* Transient allograft dysfunction from immune reconstitution in a patient with polyoma BK-virus-associated nephropathy. *Nephrol Dialysis Transplant* 2007; 22:2386–2390.
60. Hirsch HH, Brennan DC, Drachenberg CB, *et al.* Polyomavirus-associated nephropathy in renal transplantation: interdisciplinary analyses and recommendations. *Transplantation* 2005; 79:1277–1286.
61. Dadhania D, Snopkowski C, Ding R, *et al.* Epidemiology of BK virus in renal allograft recipients: independent risk factors for BK virus replication. *Transplantation* 2008; 86:521–528.
62. Nicleleit V, True K, Detwiler R, *et al.* Risk assessment for polyomavirus nephropathy using urine cytology and the detection of decoy cells: cheap and efficient. *Transplantation* 2012; 94:e42–e44.
63. Chakera A, Dyar OJ, Hughes E, *et al.* Detection of polyomavirus BK reactivation after renal transplantation using an intensive decoy cell surveillance program is cost-effective. *Transplantation* 2011; 92:1018–1023.
64. Rorije NM, Shea MM, Satyanarayana G, *et al.* BK virus disease after allogeneic stem cell transplantation: a cohort analysis. *Biol Blood Marrow Transplant* 2014; 20:564–570.
65. Gilis L, Morisset S, Billaud G, *et al.* High burden of BK virus-associated hemorrhagic cystitis in patients undergoing allogeneic hematopoietic stem cell transplantation. *Bone Marrow Transplant* 2014; 49:664–670.
66. Razonable RR, Brown RA, Humar A, *et al.* A longitudinal molecular surveillance study of human polyomavirus viremia in heart, kidney, liver, and pancreas transplant patients. *J Infect Dis* 2005; 192:1349–1354.
67. Hassan S, Mittal C, Amer S, *et al.* Currently recommended BK virus (BKV) plasma viral load cutoff of  $\geq 4 \log_{10}/\text{mL}$  underestimates the diagnosis of BKV-associated nephropathy: a single transplant center experience. *Transplant Infect Dis* 2014; 16:55–60.
68. Renoult E, Coutlee F, Paquet M, *et al.* Evaluation of a preemptive strategy for BK polyomavirus-associated nephropathy based on prospective monitoring of BK viremia: a kidney transplantation center experience. *Transplant Proc* 2010; 42:4083–4087.
69. Knight RJ, Gaber LW, Patel SJ, *et al.* Screening for BK viremia reduces but does not eliminate the risk of BK nephropathy. *Transplantation* 2013; 95:949–954.
- The article outlines single-center results on screening for BK viremia and protocols for minimization of immunosuppression. Therapeutic intervention could not prevent graft failure in patients with BK viremia when compared with controls. These data might suggest the lack of therapeutic benefits in patients with 'presumptive' PVN treated preemptively. Unfortunately, however, data analysis does not allow for a clear distinction between patients with 'presumptive' and 'definitive' PVN, and PVN disease grades are unknown.
70. Nicleleit V, Brylawski B, Rivier L, Singh HK. Urinary polyomavirus-haufen shedding in mouse and man: a proof-of-concept study for a non-invasive urine biomarker for polyomavirus nephropathy. *Modern Pathol* 2013; 26:390A.
71. Ding R, Medeiros M, Dadhania D, *et al.* Noninvasive diagnosis of BK virus nephritis by measurement of messenger RNA for BK virus VP1 in urine. *Transplantation* 2002; 74:987–994.
72. Dadhania D, Snopkowski C, Muthukumar T, *et al.* Noninvasive prognostication of polyomavirus BK virus-associated nephropathy. *Transplantation* 2013; 96:131–138.
- In patients with 'definitive' PVN, urinary cell levels of mRNA for plasminogen activator inhibitor-1 and serum creatinine levels at time of initial PVN diagnosis are independent prognosticators of graft failure. Data outline noninvasive diagnostic strategies for diagnosis and prognosis of PVN.
73. Almeras C, Vetromile F, Garrigue V, *et al.* Monthly screening for BK viremia is an effective strategy to prevent BK virus nephropathy in renal transplant recipients. *Transplant Infect Dis* 2011; 13:101–108.
74. Schaub S, Hirsch HH, Dickenmann M, *et al.* Reducing immunosuppression preserves allograft function in presumptive and definitive polyomavirus-associated nephropathy. *Am J Transplant* 2010; 10:2615–2623.
75. Rollison DE, Sexton WJ, Rodriguez AR, *et al.* Lack of BK virus DNA sequences in most transitional-cell carcinomas of the bladder. *Int J Cancer* 2007; 120:1248–1251.
76. Roberts IS, Besarani D, Mason P, *et al.* Polyoma virus infection and urothelial carcinoma of the bladder following renal transplantation. *Br J Cancer* 2008; 99:1383–1386.
77. Narayanan M, Szymanski J, Slavcheva E, *et al.* BK virus associated renal cell carcinoma: case presentation with optimized PCR and other diagnostic tests. *Am J Transplant* 2007; 7:1666–1671.
78. Alexiev BA, Randhawa P, Vazquez Martul E, *et al.* BK virus-associated urinary bladder carcinoma in transplant recipients: report of 2 cases, review of the literature, and proposed pathogenetic model. *Hum Pathol* 2013; 44:908–917.
79. Nicleleit V, Singh HK, Goldsmith CS, *et al.* BK virus-associated urinary bladder carcinoma in transplant recipients: productive or nonproductive polyomavirus infections in tumor cells? *Hum Pathol* 2013; 44:2870–2871.
80. Uhm J, Hamad N, Michelis FV, *et al.* The risk of polyomavirus BK-associated hemorrhagic cystitis after allogeneic hematopoietic SCT is associated with myeloablative conditioning, CMV viremia and severe acute GVHD. *Bone Marrow Transplant* 2014; 49:1528–1534.
81. Erard V, Storer B, Corey L, *et al.* BK virus infection in hematopoietic stem cell transplant recipients: frequency, risk factors, and association with postengraftment hemorrhagic cystitis. *Clin Infect Dis* 2004; 39:1861–1865.
82. Lekakis LJ, Macrinici V, Baraboutis IG, *et al.* BK virus nephropathy after allogeneic stem cell transplantation: a case report and literature review. *Am J Hematol* 2009; 84:243–246.
83. Limaye AP, Smith KD, Cook L, *et al.* Polyomavirus nephropathy in native kidneys of nonrenal transplant recipients. *Am J Transplant* 2005; 5:614–620.
84. Hingorani S. Chronic kidney disease in long-term survivors of hematopoietic cell transplantation: epidemiology, pathogenesis, and treatment. *J Am Soc Nephrol* 2006; 17:1995–2005.
85. Ellis MJ, Parikh CR, Inrig JK, *et al.* Chronic kidney disease after hematopoietic cell transplantation: a systematic review. *Am J Transplant* 2008; 8:2378–2390.