



McCREADY OUTPATIENT SERVICES CENTER  
U.S. ENVIRONMENTAL PROTECTION AGENCY

## Possible Estuary-Associated Syndrome: Symptoms, Vision, and Treatment

Ritchie C. Shoemaker<sup>1</sup> and H. Kenneth Hudnell<sup>2</sup>

<sup>1</sup>McCready Outpatient Services Center, Pocomoke City, Maryland, USA; <sup>2</sup>U.S. Environmental Protection Agency, National Health and Environmental Effects Research Laboratory, Neurotoxicology Division, Research Triangle Park, North Carolina, USA

The human illness designated as possible estuarine-associated syndrome (PEAS) by the Centers for Disease Control and Prevention (CDC) has been associated with exposure to estuaries inhabited by toxin-forming dinoflagellates, including members of the fish-killing toxic *Pfiesteria* complex (TPC), *Pfiesteria piscicida* and *Pfiesteria shumwayae*. Humans may be exposed through direct contact with estuarine water or by inhalation of aerosolized or volatilized toxin(s). The five cases reported here demonstrate the full spectrum of symptoms experienced during acute and chronic stages of this suspected neurotoxin-mediated illness. The nonspecific symptoms most commonly reported are cough, secretory diarrhea, headache, fatigue, memory impairment, rash, difficulty in concentrating, light sensitivity, burning skin upon water contact, muscle ache, and abdominal pain. Less frequently encountered symptoms are upper airway obstruction, shortness of breath, confusion, red or tearing eyes, weakness, and vertigo. Some patients experience as few as four of these symptoms. The discovery that an indicator of visual pattern-detection ability, visual contrast sensitivity (VCS), is sharply reduced in affected individuals has provided an objective indicator that is useful in diagnosing and monitoring PEAS. VCS deficits are present in both acute and chronic PEAS, and VCS recovers during cholestyramine treatment coincident with symptom abatement. Although PEAS cannot yet be definitively associated with TPC exposure, resolution with cholestyramine treatment suggests a neurotoxin-mediated illness. **Key words** cholestyramine, chronic neurotoxic illness, harmful algal blooms, *Pfiesteria*, possible estuary-associated syndrome, visual contrast sensitivity. *Environ Health Perspect* 109:539–545 (2001). [Online 14 May 2001] <http://ehpnet1.niehs.nih.gov/docs/2001/109p539-545shoemaker/abstract.html>

### Case Presentation

#### Case 1

A 32-year-old male commercial fisherman worked on the Pocomoke River, a tributary of the Chesapeake Bay on the Eastern Shore of Maryland, since age 16 without any significant illness until October 1996. In association with harvesting multiple species of fish with deep, penetrating ulcers, the patient had initial onset of memory impairment, headache, hypersensitivity to bright light, fatigue, cough, muscle ache, skin rash, diarrhea, and anorexia. Subsequently, the patient was treated by several local physicians with antibiotics for recurrent pneumonia (seven episodes in 6 months). The diagnoses of pneumonia were based on clinical parameters alone, without additional confirmatory tests. The patient lost 40 pounds, became weak and lethargic, and continued to suffer from the symptoms listed above. He continued to work in the estuaries.

The patient was exposed to an active fish kill 5–8 August 1997 (Table 1), which was thought to be caused by the estuarine dinoflagellate, *Pfiesteria piscicida*, or other members of the toxic *Pfiesteria* complex

(TPC), after which he experienced increased severity of the symptoms. The patient was evaluated by a multidisciplinary team of researchers from the University of Maryland and Johns Hopkins University on 19 August 1997 as a participant in a study on human contact with estuaries around the time of fish kills associated with TPC. Neurocognitive tests indicated an extremely low level of executive functioning.

The patient remained ill; he sought medical assistance and was evaluated by an author (R.C.S.) in September 1997. He reported that his symptoms (Table 2), which were unremitting since initial onset, had been exacerbated by the August 1997 fish-kill contact. Complete blood count, comprehensive metabolic profile, and pulmonary-function test results were within normal parameters. His medical history revealed no previous illness involving neurologic dysfunction, alcoholism, chronic soft-tissue injury, Lyme disease, chronic ciguatera-seafood poisoning, or possible building-related illness. Occupational history indicated little or no exposure to solvents or petroleum products, metals fumes, pesticides, or other neurotoxicants. It was

concluded that his chronic (i.e., symptom duration > 1 month) illness may have been caused by estuarine-associated neurotoxins. The patient was treated with cholestyramine (CSM), a polymer previously approved by the U.S. Food and Drug Administration (FDA) for treatment of hypercholesterolemia and considered an exempt usage for toxin elimination, according to a standard protocol (Table 3). His symptoms improved beginning 36 hr after treatment initiation. He continued treatment, with subsidence of all symptoms within 2 weeks and subsequent regain of weight. His neurocognitive scores were within normal range when subsequently evaluated in a 3-month follow-up by the University of Maryland and Johns Hopkins University research team.

The patient began a maintenance program of two doses of CSM daily while continuing to work in areas of previous fish kills. He stayed well until June 1998, 5 days after cessation of the CSM prevention regime, when he again harvested lesioned fish from the Pocomoke River (Table 1). The patient presented with a characteristic rash, mild secretory diarrhea (i.e., non-osmotic, continuation without food or liquid intake), and exertional cough, and he reported extreme fatigue (Table 2). Again, the clinical and laboratory tests produced negative results, and

Address correspondence to H.K. Hudnell, U.S. Environmental Protection Agency, National Health and Environmental Effects Research Laboratory, Neurotoxicology Division, MD-74B, Research Triangle Park, NC 27711 USA. Telephone: (919) 541-7866. Fax: (919) 541-4849. E-mail: hudnell.ken@epamail.epa.gov

We thank J. Shoemaker for assistance in preparation of this manuscript. No grants were involved in this work.

This manuscript was reviewed by the National Health and Environmental Effects Research Laboratory, U.S. Environmental Protection Agency, and approved for publication. Approval does not signify that the contents necessarily reflect the views and policies of the agency, nor does mention of trade names or commercial products constitute endorsement or recommendation.

Received 21 December 2000; accepted 1 February 2001.

the patient reported no other new illnesses or neurotoxic exposures. CSM treatment was reinstated, and his acute illness resolved within 1 week.

**Case 2**

A 41-year-old male soil scientist sampled submerged sediments and porewater for dinoflagellate DNA and pollutants on 19–20 July 1999 in the Chesapeake Bay, Pocomoke River, and Bulbeggan Creek in Virginia, where a 4-day fish kill attributed to TPC activity began on 24 July 1999, and in surrounding areas (Table 1). Sampling involved direct immersion in water, exposure to spray, and inhalation of air at the water surface. Visual acuity and visual contrast sensitivity (VCS) were measured with the Functional Acuity Contrast Test (F.A.C.T.) apparatus (Stereo Optical Co., Inc., Chicago, IL; Figure 1) (6,7). The test measures the least amount (threshold) of luminance difference between adjacent areas (contrast) necessary for an observer to detect a visual pattern. VCS is the inverse of contrast threshold. Visual acuity and VCS measurements before estuary exposure on 19 July 1999 and at the end of exposure on 20 July 1999 (Figure 2) were within normal limits (acuity, Snellen distance equivalent scores ≤ 20:40; VCS

scores > 64 at 6 cycles/degree of visual arc). The patient became ill on the night of 21 July 1999, 24 hr after sampling ended. The patient was seen on 23 July 1999 while suffering memory impairment, mild confusion, severe bifrontal throbbing headache, intermittent cramping, profuse secretory diarrhea, nonproductive cough, fatigue, and abdominal pain (Table 2). He was previously healthy and had no history of illness involving neurologic dysfunction, allergy, asthma, eosinophilia, or neurotoxicant exposure, and the clinical and laboratory tests were negative as with Case 1. VCS was markedly depressed (Figure 2), but visual acuity was unaffected. The patient met the case definition for possible estuary-associated syndrome (PEAS), a syndrome described by the Centers for Disease Control and Prevention (CDC) following human illness associated with estuarine contact around the time of the August 1997 TPC-related fish kill in Maryland estuaries. Treatment with CSM was initiated immediately (Table 3). Symptoms and VCS abnormalities responded promptly (Figure 2), clearing completely by 31 July 1999, the ninth day of treatment.

Case 2 developed a similar acute illness on 20 October 1999 following estuarine sampling in areas of the inland Delaware

bays found to contain *Pfiesteria shumwayae*, another member of the TPC (Table 1), when sampling resumed in May 2000. He treated himself with CSM at standard doses, with complete recovery and normal VCS on 25 October 1999 (Figure 2). The patient's VCS remained normal on 27 November 1999, after he stopped taking CSM (Figure 2). He returned to the inland Delaware bays the next day (Table 1) and was seen in the clinic on 1 December 1999 while suffering a third acquisition of acute illness characterized by headache, upper airway obstruction, cough, diarrhea, fatigue, muscle ache, and depressed VCS (Table 2, Figure 2). Multiple medications were prescribed, including CSM. Follow-up was not obtained, but according to his wife, he took CSM until his symptoms abated in a few days. She reported that he had reexposure to the Delaware Bay sampling site on 15 December 1999 and saw a different physician on 21 December 1999 while experiencing fever, shortness of breath, and cough. Antibiotics were prescribed and bronchodilators initiated, followed by prompt improvement in cough and reduction of fever. The patient exhibited intense snoring during the night of 22–23 December 1999, suggestive of upper airway obstruction, and was found dead in the morning.

**Table 1.** Estuarine exposure and illness.

|               | PEAS condition       | Illness date      | Estuarine contact < 2 weeks before illness onset | Dead or lesioned fish contact | Ever tested positive for TPC | References |
|---------------|----------------------|-------------------|--|-------------------------------|------------------------------|------------|
| Case 1        | Chronic <sup>a</sup> | Oct 1996–Sep 1997 | Pocomoke River, MD                               | Y                             | Y                            | (1)        |
|               | Acute                | Jun 1998          | Pocomoke River, MD                               | Y                             | Y                            | (1)        |
| Case 2        | Acute                | Jul 1999          | Pocomoke River, MD and Bulbeggan Creek, VA       | Y                             | Y                            | (1,2)      |
|               | Acute                | Oct 1999          | Indian River, DE                                 | N                             | Y                            | (3)        |
| Case 3        | Acute                | Dec 1999          | Rehoboth Bay and tributaries, DE                 | Y                             | Y                            | (3)        |
|               | Acute                | Dec 1998          | Chicamacomico River, MD                          | Y                             | Y                            | (4)        |
|               | Acute                | Feb 1999          | Chicamacomico River, MD                          | Y                             | Y                            | (4)        |
| Cases 4 and 5 | Chronic              | Sep 1998–Mar 1999 | Back Creek, Manokin River, MD                    | Y                             | Y                            | (4,5)      |
|               | Acute                | Jul 1999          | Back Creek, Manokin River, MD                    | N                             | Y                            | (4,5)      |

<sup>a</sup>Chronic PEAS is defined as PEAS symptoms present > 1 month.

**Table 2.** Symptoms reported.

| Case/type (date)              | CDC                 |                        |          |                        |                           |                |                   |              |    |               |                 |       |                 |         |             |          |                |         |
|-------------------------------|---------------------|------------------------|----------|------------------------|---------------------------|----------------|-------------------|--------------|----|---------------|-----------------|-------|-----------------|---------|-------------|----------|----------------|---------|
|                               | Memory <sup>a</sup> | Confusion <sup>a</sup> | Headache | Skin rash <sup>a</sup> | Burning skin <sup>a</sup> | Eye irritation | Upper respiratory | Muscle cramp | GI | Concentration | Light sensitive | Cough | Short of breath | Fatigue | Muscle ache | Weakness | Abdominal pain | Vertigo |
| Case 1                        |                     |                        |          |                        |                           |                |                   |              |    |               |                 |       |                 |         |             |          |                |         |
| Chronic (Oct 1996–Sep 1997)   |                     |                        | +        | +                      |                           |                |                   | +            |    |               | +               | +     | +               | +       | +           | +        |                |         |
| Acute (5 Jun 1998)            |                     |                        |          | +                      |                           |                |                   | +            |    |               |                 | +     |                 |         |             |          |                |         |
| Case 2                        |                     |                        |          |                        |                           |                |                   |              |    |               |                 |       |                 |         |             |          |                |         |
| Acute (Jul 1999) <sup>b</sup> | +                   | +                      | +        |                        |                           |                |                   | +            |    |               |                 | +     |                 | +       |             |          |                | +       |
| Acute (Oct 1999) <sup>b</sup> |                     |                        | +        |                        |                           |                |                   | +            |    |               |                 | +     |                 | +       | +           |          |                |         |
| Acute (Dec 1999) <sup>b</sup> |                     |                        | +        |                        |                           |                |                   | +            |    |               |                 | +     | +               | +       | +           |          |                |         |
| Case 3                        |                     |                        |          |                        |                           |                |                   |              |    |               |                 |       |                 |         |             |          |                |         |
| Acute (Dec 1998)              |                     |                        | +        |                        | +                         | +              |                   | +            | +  |               | +               |       |                 |         |             |          |                |         |
| Acute (Feb 1999) <sup>b</sup> | +                   |                        | +        | +                      |                           |                |                   | +            | +  |               | +               | +     |                 | +       |             |          |                | +       |
| Case 4                        |                     |                        |          |                        |                           |                |                   |              |    |               |                 |       |                 |         |             |          |                |         |
| Chronic (Sep 1998–Mar 1999)   | +                   |                        | +        | +                      | +                         | +              |                   | +            | +  |               | +               | +     |                 | +       |             |          |                | +       |
| Acute (Jul 1999)              |                     |                        | +        | +                      | +                         | +              |                   | +            | +  |               | +               | +     |                 | +       |             |          |                | +       |
| Case 5                        |                     |                        |          |                        |                           |                |                   |              |    |               |                 |       |                 |         |             |          |                |         |
| Chronic (Sep 1998–Mar 1999)   | +                   |                        | +        | +                      | +                         | +              |                   | +            | +  |               | +               | +     |                 | +       |             |          |                | +       |
| Acute (Jul 1999)              | +                   |                        | +        | +                      | +                         | +              |                   | +            | +  |               | +               | +     |                 | +       |             |          |                | +       |

GI, gastrointestinal.

<sup>a</sup>The CDC case definition for PEAS includes memory loss, confusion, skin rash and burning skin sensation of any duration. Other symptoms must persist for > 2 weeks. <sup>b</sup>CSM treatment was initiated and all symptoms resolved in less than 2 weeks from onset.

Findings at autopsy included multiple foci of patchy bronchopneumonia, hyalinized airways consistent with reactive airway disease, and an intense eosinophilic infiltrate of soft tissues above the larynx.

### Case 3

A 75-year-old male recreational fisherman began to notice bass and perch with punched out ulcerative lesions during November 1998 in the Chicamacomico River, Maryland, a tributary of the Chesapeake Bay located 50 miles from the Pocomoke River. The patient remained well until 16 December 1998 when he caught several fish with lesions from the Chicamacomico (Table 1). He reported that the water felt "hot" to the touch, even though the water temperature was 46°F. The patient reported abrupt onset of tearing during exposure, and subsequent eye irritation, headache, confusion, diarrhea, cough, and vertigo when seen in the clinic on 18 December 1998 (Table 2). His VCS was markedly reduced (Figure 3), although visual acuity was normal. He was previously healthy and had no history of neurotoxicant exposure or illness involving neurologic dysfunction, and the complete blood count, comprehensive metabolic profile, and pulmonary-function test results were negative. He enrolled in an ongoing double-blinded, placebo-controlled, crossover trial designed to assess the efficacy of CSM treatment for PEAS. Two

weeks of treatment with placebo gave no improvement in VCS (Figure 3) or symptoms. VCS, but not visual acuity, improved markedly with CSM treatment (Figure 3) coincident with symptom abatement. The time course of VCS recovery is shown for the middle spatial frequency in Figure 3.

The patient was well until he returned to the same area of the Chicamacomico on 16 February 1999 (Table 1). Again, the water temperature was cold, 42°F, and he caught lesioned fish (Figure 4). Two days later, his clinical presentation suggested a more severe case of PEAS. The syndrome consisted of a rash similar to that seen in previous PEAS cases, memory impairment, confusion, headache, diarrhea, hypersensitivity to bright light, cough, and fatigue (Table 2). VCS was markedly reduced, similar to that seen during his first bout of PEAS. He was again treated with CSM, which he took for 8 days. His symptoms abated and VCS, shown at the midspatial frequency in Figure 3, returned to normal during treatment. He has remained well while avoiding known endemic TPC areas.

### Cases 4 and 5

A 28-year-old female and her 37-year-old husband became ill in the fall of 1998 after catching crabs in a tributary of the Manokin River (in Maryland 20 miles north of Pocomoke City) known to be inhabited by

TPC (Table 1). Both reported a burning skin sensation when touching the water, and within 24 hr they experienced abrupt onset of memory impairment, headache, skin rash, red stinging eyes, difficulty in concentrating, light sensitivity, cough, fatigue, and abdominal pain. Only the male reported diarrhea (Table 2). Their symptoms persisted, but they did not seek medical assistance for almost 6 months.

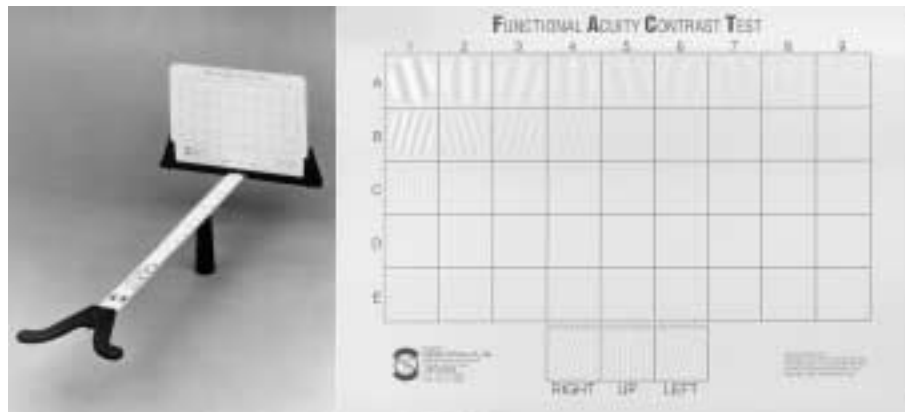
The husband came to the clinic on 6 March 1999 and described his symptoms and the events surrounding onset. He scored positive on the VCS test; was negative on the blood, metabolic, and pulmonary function tests; and had no history of confounding illness or neurotoxicant exposure. He was diagnosed with chronic PEAS and volunteered for the clinical trial on CSM efficacy. On 10 March 1999, the woman accompanied her husband to his initial follow-up visit and requested medical assistance. She also showed severely reduced VCS (Figure 5) and described similar symptoms (Table 2) and the same events prior to onset as her husband (Table 1). Clinical and laboratory tests were negative, and she was free of potentially confounding factors other than a history of head trauma. She attributed mild memory impairment to the head trauma, but reported exacerbation since symptom onset. She was diagnosed with chronic PEAS and volunteered for the CSM clinical trial. She showed no improvement when she was retested on 12 March 1999 while taking the randomly assigned placebo medication. At the follow-up visits on 20 March 1999, the husband reported complete resolution of symptoms and showed normal VCS, whereas the wife stated that she had stopped taking her medication (the placebo) on 17 March 1999 and began taking her husband's medication (CSM). She was adamant that she receive the same medication that her husband was taking because his symptoms were dramatically reduced while hers persisted. She was treated with CSM, and her symptoms, including a rash on her breast that had not responded to self treatment in 6 months, abated within 10 days and VCS returned to the normal range (Figure 5). Visual acuity was unchanged.

Both patients returned to a nearby area of the Manokin River System for recreation on 25 July 1999. More than 1 hr after being near the water, both made initial water contact and again felt a burning skin sensation, which prompted them to leave the area. Fish kills were reported in this part of the Manokin on 10 August 1999, and the presence of TPC was confirmed (Table 1). Both patients experienced symptom onset within 36 hr, but waited 2 weeks before seeking medical assistance. The woman presented

**Table 3.** Standard protocol for PEAS treatment.

| Compound                       | Dose   |
|--------------------------------|--|
| Cholestyramine (CSM, Questran) | One scoop, 9 g, on an empty stomach 30 min before food or taking other medication, four times a day for 2 weeks (FDA exemption letter issued 28 June 1999); CSM should be mixed well in water or apple juice |
| Sorbitol, 70% solution         | 15 cc three times a day as needed to relieve constipation  |
| Prilosec (or Prevacid)         | Daily, one capsule as needed to treat reflux   |

The dose of CSM used is approved for treatment of hypercholesterolemia by the FDA.



**Figure 1.** A simple card test, the Functional Acuity Contrast Test was used to measure VCS in the current PEAS cases using a standard procedure (6). This test measures contrast sensitivity for five sizes (spatial frequencies) of light and dark bar patterns (sinusoidal gratings) because spatial vision is mediated by populations of neurons selectively tuned to different spatial frequency (7). If neurons subserving high spatial-frequency (smaller bars) vision are functionally impaired but those underlying low spatial-frequency (larger bars) vision are functionally normal, for example, then visual perception also will be impaired for high frequency patterns but normal for low frequency patterns.

with reappearance of a rash at the same location on her breast as in March 1999. Both patients reported the same set of symptoms experienced during the first episode, although memory loss and difficulty in concentrating were less severe. (Table 2). Neither had changes in health or exposure history, and the laboratory and clinical tests were again negative. The woman's VCS was again markedly reduced (Figure 5), as was her husband's, and both were diagnosed with acute PEAS. The standard regime of CSM treatment produced excellent results: their symptoms abated and VCS recovered in less than 2 weeks.

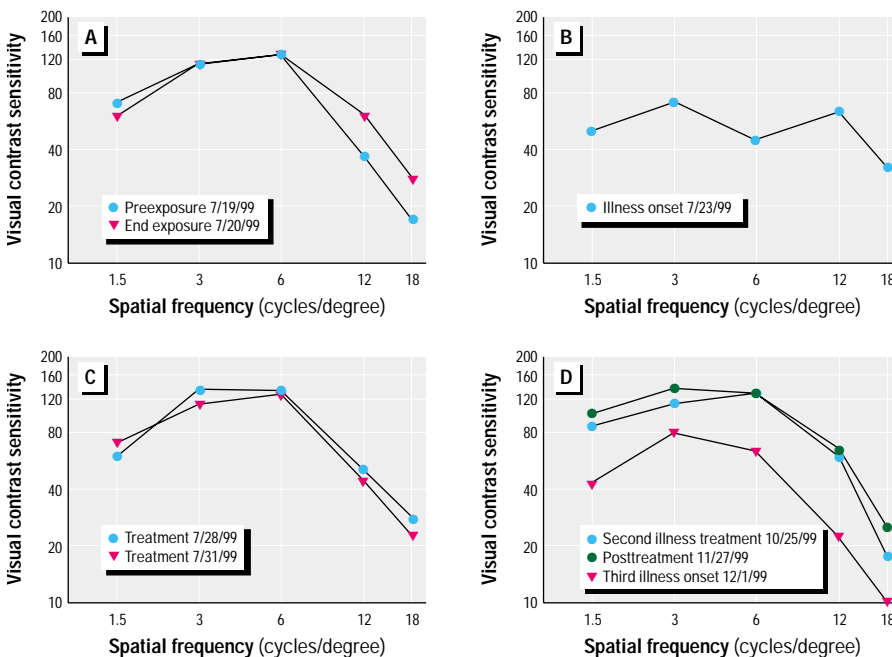
## Discussion

Recent evidence has suggested that the estuarine dinoflagellates *Pfiesteria piscicida* and *P. shumwayae* not only kill fish (8–10) on the Eastern Seaboard from Delaware to Florida (11) but also may pose a human health risk in laboratory (12) and natural settings (13–15). Humans who were exposed to estuaries of the Chesapeake Bay, Maryland, around the time of fish kills in 1997 had severe exposure- and duration-related reductions in neuropsychologic tests of cognitive and motor functions relative to unexposed, matched-control study participants (14). Although the test scores of affected individuals returned to within

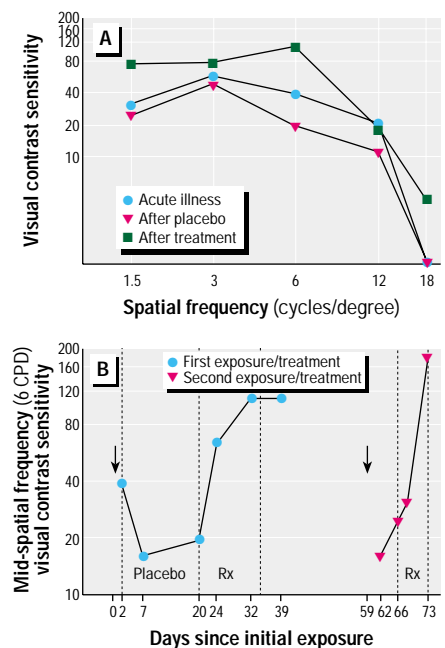
normal ranges in 3–6 months (14), little is known about the potential acute and chronic health effects of PEAS (16). The CDC case definition of PEAS consists of three components: *a*) exposure potential (symptoms reported within 2 weeks of exposure to estuarine waters); *b*) symptoms, including memory loss or confusion of any duration and/or three or more selected symptoms (i.e. headache, skin rash at the site of water contact, sensation of burning skin, eye irritation, upper respiratory irritation, muscle cramps, and gastrointestinal symptoms) that, with the exception of skin rash and burning skin sensation, persist for > 2 weeks; and *c*) confounders (a health care provider cannot identify another cause of the symptoms). Definitive diagnosis of PEAS has been hampered by the lack of identification of, and an indicator for, the putative toxin(s) made by TPC (17) or other readily available, low-cost objective indicators of exposure. The five patients reported here met the CDC case definition for PEAS, with the exception that some cases were successfully treated during some episodes prior to having symptoms for 2 weeks (Table 2). Data from these cases suggested that a measure of visual function and recognition of additional symptoms may assist in the diagnosis of PEAS. Measurements of VCS, an indicator of the

ability to detect visual patterns, were made because a study conducted in 1997 showed a sharp and apparently persistent reduction in North Carolina watermen exposed to estuaries inhabited by TPC relative to unexposed offshore watermen (15). In a subsequent study, VCS was significantly lower in watermen on estuaries where TPC was identified than in watermen on estuaries where TPC sampling was negative (18). The current cases illustrate the spectrum of symptoms in acute and chronic PEAS associated with single and repeated estuarine exposures. Treatment with the toxin-binding polymer CSM (19) led to symptom abatement and VCS recovery within 2 weeks of treatment initiation, apparently by enhancing toxin-elimination rates.

These cases suggested that PEAS is an acute illness which develops into chronic illness in some individuals. All five cases con-



**Figure 2.** Spatial frequency profiles of visual contrast sensitivity for Case 2. (A) A normal VCS profile was measured at the beginning and end of a 2-day project of sampling sediment and water in Maryland estuaries known to harbor TPC. (B) Case 2 became symptomatic approximately 24 hr after leaving the estuaries and showed severely depressed VCS, particularly at the midspatial frequency, when seen in the clinic approximately 62 hr after leaving the estuaries. (C) The patient showed a return of normal VCS after 6 and 9 days of cholestyramine treatment, coincident with symptom abatement. (D) After working in other estuaries, the patient experienced a second suspected episode of PEAS and began self-treatment with cholestyramine. VCS was normal when measured in the clinic after 6 days of treatment and remained normal 2 days after treatment ended. He returned to the estuaries the next day and was seen in the clinic 3 days later with depressed VCS and a suspect third case of acute PEAS. Cholestyramine was prescribed, but follow up was not obtained.



**Figure 3.** Spatial frequency profiles and time-course of visual contrast sensitivity for Case 3. (A) VCS remained depressed while the patient was enrolled in the placebo arm of a double-blinded, cross-over clinical trial. VCS improved after 2 weeks of CSM treatment. (B) VCS at the midspatial frequency (VCS-6), where PEAS-related deficits are typically greatest, is plotted to show the time course of VCS change. Arrows indicate last day of exposure before onset of illness. During the first acute PEAS episode, VCS-6 was depressed 2 days after exposure and deteriorated further during placebo treatment. VCS-6 was improved after 4 days of CSM treatment (Rx). Full recovery was seen after 12 days of treatment and was retained 5 days after treatment cessation. During the second acute PEAS episode, VCS-6 was markedly depressed 3 days after exposure (plot day 59) and showed little change 4 days later when treatment was initiated. Only slight improvement was seen after 2 days of treatment, but full recovery was seen after 8 days of treatment.


tracted acute PEAS, and Cases 2 and 3 repeatedly acquired acute PEAS. Chronic PEAS was thought to have been contracted by Cases 1, 4, and 5. The symptoms, the VCS deficit, and the response to CSM treatment were similar for acute and chronic PEAS cases. As shown in Table 2, the most commonly reported symptoms were cough, secretory diarrhea, headache, fatigue, memory impairment, rash, difficulty concentrating, light sensitivity, burning skin upon water contact, muscle ache, and abdominal pain. Less frequently encountered symptoms were upper airway obstruction, shortness of breath, confusion, red or tearing eyes, weakness, and vertigo. These symptoms suggested that a variety of organs may be affected in PEAS, including the brain and nervous system (including the visual system), muscle, mucus membranes, skin, and the gastrointestinal system. Effects seen in Cases 1 and 2 suggested that immunologic function may be compromised, which is consistent with the report by Glasgow et al. (12). Although these cases met the CDC symptom criteria for PEAS, except for the duration requirement as noted above, expansion of the CDC symptom list might improve case recognition.

These cases illustrate several additional pertinent points. First, in this limited sample, PEAS symptoms and the response to treatment did not appear to differ with gender or age. Second, the onset of acute illness usually occurred within 24–36 hr after exposure, as suggested by Cases 2, 3, 4, and 5, and was indicated by the objective measurement of VCS. Third, VCS recovery and symptom abatement began about 48 hr after the initiation of CSM treatment as suggested by Case

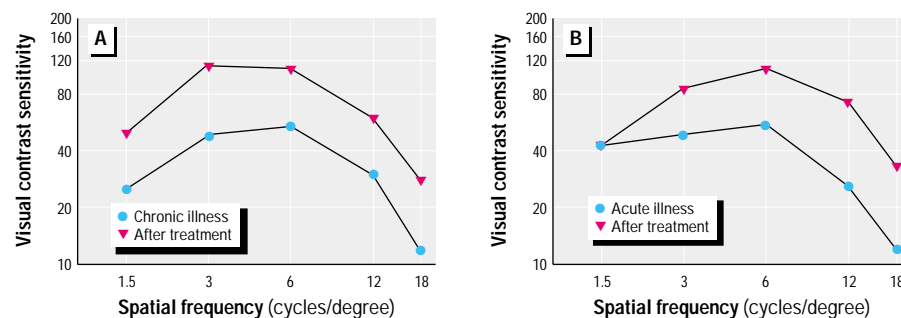
2, both acute episodes of Case 3, and the chronic and acute episodes of Cases 4 and 5. Fourth, repeat exposure resulted in reacquisition of illness in all cases. It is unclear whether repeated acquisition of PEAS was associated with increased symptom severity because exposure dose was undefined, or whether there are cumulative effects. Fifth, individuals may differ in susceptibility to PEAS. Three researchers accompanied Case 2 during estuarine sampling on 19–20 July 1999 and received comparable estuarine exposure. Case 2 and one researcher did not take CSM prophylactically. Case 2, but not the non-CSM researcher, contracted acute PEAS. If PEAS is caused by TPC toxin(s), the possible biologic bases for differences in susceptibility are many; individual responses to TPC toxin(s) may vary due to differences in absorption or elimination rates, metabolism, the concentration of specific receptor binding sites, endogenous protective ligands, the vulnerability of target organs to the mechanism(s) of action, compensatory mechanisms, or other factors. Sixth, some of these factors also may contribute to individual differences in recovery rate without treatment. Anecdotal evidence indicates that some individuals with acute PEAS do not go on to develop chronic PEAS, whereas Cases 1, 4, and 5 did so. Of the 10 cases seen at the 3-month follow-up reported by Grattan et al. (14), two cases had not returned to the normal range of cognitive function, Case 1 was in the normal range following CSM treatment, and 7 cases had returned to the normal range without treatment (14). Seventh, CSM use as a prophylactic may prevent the acquisition of acute PEAS, as apparently seen in Case 1. The second researcher who accompanied Case 2 during sampling used CSM at a standard dose before exposure and throughout the sampling period, and did not contract PEAS. The third accompanying researcher took only one dose of CSM before sampling (on a full stomach) and did contract PEAS. Therefore, prophylactic

use of 2 doses/day CSM may be a reasonable disease prevention strategy for known susceptible individuals with high potential for exposure to affected estuaries. Eighth, although conclusive evidence is lacking, PEAS or its repeated acquisition was temporally associated with, and may have been a contributing factor to, the upper airway inflammation, pneumonia, and respiratory arrest that resulted in the death of Case 2. Repeated acute PEAS acquisition may have altered his immunologic response, predisposing him to pneumonia development. Furthermore, it is highly unusual for the clinical course of pneumonia in a previously healthy 41-year-old male to include fever and cough reduction in response to antibiotic treatment, followed paradoxically by a strong increase in snoring and death from respiratory arrest. Although eosinophilic infiltration is a nonspecific response associated with Addison's disease, asthma, and parasitic and other conditions, eosinophilia was previously observed in skin biopsies from two patients with acutely acquired, TPC-related skin lesions (20) and in the study of Grattan et al. (14). Although speculative, the upper airway eosinophilic infiltration seen in Case 2 at autopsy (21) may have been in response to TPC toxin(s)-induced inflammation, which led to upper airway obstruction and respiratory failure. Appropriate tissue and fluid samples from Case 2 were preserved for further analysis when a satisfactory assay for toxin(s) in human tissue is available.

Previous studies suggested an association between VCS deficits and hours spent at fish kills (15) and work or recreation on TPC-inhabited estuaries (15,18). The current cases repeatedly showed severe VCS deficits shortly after exposure to TPC-inhabited estuaries and complete VCS recovery following CSM therapy. Case 3 showed no VCS or symptomatic improvement for 2 weeks while in the placebo arm of the double-blind, placebo-controlled, crossover clinical trial on CSM efficacy. No other neurotoxicant exposures or



**Figure 4.** Case 3 acquired acute PEAS a second time after catching fish with lesions in a Chesapeake Bay estuary on 16 February 1999 when the water temperature was 42°F. (A) Whole fish brought to the clinic 3 days later, showing ulcerative lesions around the anal vent. (B) Close-up of the anal vent area showing a fresh ulcerative lesion right of the anal vent and a deeper, older-appearing lesion superior to the anal vent.



**Figure 5.** Spatial frequency profiles of visual contrast sensitivity for Case 5. (A) Case 5 became ill shortly after catching crabs in an estuary and experienced symptoms of chronic PEAS for approximately 6 months before seeking medical attention, at which time her VCS was severely depressed. VCS was normal after 2 weeks of CSM treatment. (B) The patient remained well until she returned to the estuary about 4 months later. At that time, she developed symptoms of acute PEAS, and VCS was again markedly depressed. VCS again returned to normal after 2 weeks of CSM treatment.

medications have been reported in the literature to cause such rapid and dramatic alterations in VCS (6,7). These data suggest that VCS measurement is useful in both assisting PEAS diagnosis and monitoring treatment. Inclusion of the VCS deficit in the CDC case definition of PEAS would add an objective component to an otherwise symptomatically defined syndrome.

VCS is a measure of the ability to detect visual patterns (6,7,22,23). Whereas standard tests of visual acuity measure the visual system's resolution limit for high contrast stimuli, a task critically dependent on the functional integrity of the eye's physiologic optics system, VCS is primarily an indicator of neurologic function in the visual pathways from the retina to the cortex (7). VCS, but not visual acuity, improved after CSM treatment in the cases and during the clinical trial, suggesting a neural rather than optical physiologic basis for the impairment. Furthermore, stronger parvocellular than magnocellular pathway (24) involvement is suggested by the effect bias for mid-to-higher spatial frequencies. VCS deficits are not specific for TPC toxin(s) or PEAS (25). The VCS spatial frequency profile showing greatest reduction at midspatial frequency in PEAS was similar to that seen in workers chronically exposed to organic solvents (6,26). However, VCS appeared to be an early, persistent, highly sensitive, inexpensive, and easily measured indicator of PEAS, which in combination with information on potential exposure to estuaries, symptoms, and confounding factors, greatly assisted in the diagnosis of PEAS. Both the data from the cases and the clinical trial (27) suggest that VCS improvement may be strongly associated with symptom subsidence during recovery.

The TPC toxin(s) thought to be responsible for PEAS was not the first toxin(s) that had been effectively eliminated by CSM treatment. Case reports and animal studies suggested that CSM binds and enhances elimination rates of many organic toxins including Kepone (28,29), DDE (30), other organochlorine pesticides (31), polychlorinated biphenyl compounds (32), *Clostridium difficile* toxin (33,34), *Escheria coli* and *Vibrio cholera* toxins (35,36), a cytotoxin(s) from an unidentified gastrointestinal microorganism(s) (37,38), the mycotoxins ochratoxin A (39,40) and fumonisin B1 (41), the cyanobacterial toxin microcystin LR (42), the fusarium toxin zearalenone (43), and a toxin from the Chinese herbal product Jin Bu Huan (44). Toxins that circulate systemically were thought to enter the small intestine with bile and become bound by CSM, thereby interrupting enterohepatic recirculation and preventing systemic recirculation. CSM, a highly charged quaternary

ammonium resin, may act as an absorbent by binding toxins through its strong anion-exchange capacity or by entrapment of molecules in its polymeric structure. CSM taken orally is not absorbed due to its large molecular size and is not metabolized in the digestive system. The clinical improvement seen in the cases treated with CSM was thought to be due to interruption of enterohepatic recirculation of toxin(s). Confirmation of this hypothesis will not be possible until the toxin, or suite of toxins and their metabolites, are identified. There are intriguing studies under way (45,46) that focus on the three-dimensional structure of organic toxins and the existence of a molecular dipole in those toxins, particularly in polycyclic ether toxins identified in other dinoflagellate species (47) and in carboxylic acid ether toxins of fungal species (40,45,46), into which the quaternary ammonium side chain of CSM fits exactly, much as it fits into particular crown-6-ether structures (48). Further research is needed to clarify the mechanisms by which CSM leads to the elimination of the TPC and other organic toxins.

Although it has been suggested that treatment of PEAS cases with CSM is premature (49), we hope that these cases and the clinical trial will help document the benefit of CSM use in acute and chronic PEAS. We suggest that a PEAS diagnosis be made immediately when: a) VCS at midspatial frequency (6 cycles/degree) is < 70 or < 50 at 12 cycles/degree, the Snellen equivalent visual acuity is at least 20:50, and the CDC symptoms criteria are met, other than the duration criterion, or when they are met by including the other symptoms listed in Table 1; b) the individual was exposed to estuaries where TPC can be reasonably suspected around the time of symptom onset and; c) and no other probable cause of the symptoms can be found. There is little reason to withhold treatment in an acute case because the morbidity of the illness can cause significant disruption in quality of life and work performance. There is also potential for the development of chronic PEAS or other complications. As the basic science of molecular biology proceeds toward identification of toxins (50) and modes of action (51,52), VCS testing can assist in accurately diagnosing PEAS, and the medical standard of care should include CSM therapy (according to the standard protocol in Table 3). However, physicians treating cases with CSM or recommending its prophylactic use should know that treatment is not totally benign. The potential side effects of reflux, bloating, and constipation can be bothersome and warrant monitoring and intervention by the physician as indicated (see Table 3).

These cases of reexposure and reacquisition of PEAS suggest that casual exposure to estuaries inhabited by TPC may be a risk factor for the acquisition of illness. Although the acquisition of PEAS was temporally associated with exposure to estuarine waters inhabited by TPC, no data directly establish a causal relationship between exposure to TPC toxin(s) and development of PEAS. The definitive establishment of PEAS as a TPC toxin-mediated illness must await delineation of the toxin(s) structure and a rigorous test for its presence in biologic tissue (17). Previous cases thought to be due to environmental TPC toxin(s) exposure occurred in warm weather near the time of large fish kills (14). However, there are no conclusive data to suggest that TPC toxin formation in nature occurs only in the presence of large schools of fish or warm water temperatures. The perception that TPC toxin(s) production occurs only in warm weather may arise from the fact that large schools of fish such as menhaden are in the estuaries only in warm weather and, therefore, that is the only time when large fish kills can occur. Cases 2, 3, 4, and 5 repeatedly acquired PEAS in the absence of a large fish kill, and Cases 2 and 3 experienced episodes of acute PEAS following contact with cool estuarine waters. Research is needed to determine whether areas of low water flow in shallow rivers may provide year-round conditions for TPC to emerge from the cyst form in response to unknown signals, perhaps in widely distributed micro-environments. The lack of many TPC-related fish kills in attack zones of the Eastern Shore of the Chesapeake Bay in 1999 and 2000 and the continued presentation of new PEAS cases at the McCready Outpatient Services Center suggest that sick patients, in addition to lesioned or dead fish, may be indicators of environmental toxin(s). Research is needed to identify the extent of the public health risk posed by both single and repeated episodes of PEAS. VCS measurements and CSM provide safe, inexpensive, and reliable tools for assisting in the diagnosis and treatment of PEAS, respectively.

#### REFERENCES AND NOTES

1. Maryland Department of Natural Resources. Summary of Maryland *Pfiesteria* Sampling and Results. Annapolis, MD: Department of Natural Resources, Resource Assessment Service, Tidewater Ecosystem Assessment, 1997.
2. Woodley JP. 2000 Biennial Report of the Secretary of Natural Resources to the Virginia General Assembly. Chesapeake Bay and Its Resources: Results of Monitoring Programs and Status of Resources. Richmond, VA: Commonwealth of Virginia, 2000:41.
3. Delaware Department of Natural Resources and Environmental Control, Division of Water Resources. Fish Health Activity, DNA Results and Ancillary Data. Dover, DE: State of Delaware, 2000.
4. Oldach DW, Delwiche CF, Jakobsen KS, Tengs T, Brown EG, Kempton JW, Schaefer EF, Bowers HA, Glasgow HB Jr, Burkholder JM, et al. Heteroduplex mobility

- assay-guided sequence discovery: elucidation of the small subunit (18S) rDNA sequence of *Pfiesteria piscicida* and related dinoflagellates from complex algal culture and environmental sample DNA pools. *Proc Natl Acad Sci USA* 97:4303–4308 (2000).
- Maryland Department of Natural Resources. Back Creek 1999: *Pfiesteria* Laboratory Results. Annapolis, MD: Department of Natural Resources, Resource Assessment Service, Tidewater Ecosystem Assessment, 1999.
  - Hudnell HK, Otto DA, House DE. The influence of vision on computerized neurobehavioral test scores: a proposal for improving test protocols. *Neurotoxicol Teratol* 18:391–400 (1996).
  - Bodis-Wollner I, Ghilardi MF, Mylin LH. The importance of stimulus selection in VEP practice: the clinical relevance of visual physiology. In: *Frontiers of Clinical Neuroscience, Vol 3: Evoked Potentials* (Cracco RQ, Bodis-Wollner I eds). New York: Alan R Liss, Inc., 1986:15–27.
  - Burkholder JM, Noga EJ, Hobbs CH, Glasgow HB Jr. New phantom dinoflagellate is the causative agent of major estuarine fish kills. *Nature* 358:407–410 (1992).
  - Noga EJ, Khoo L, Stevens JB, Fan Z, Burkholder JM. Novel toxic dinoflagellate causes epidemic disease in estuary fish. *Mar Pollut Bull* 32:219–224 (1996).
  - Glasgow HG Jr. The Biology of the Toxic *Pfiesteria* Complex in the Neuse Estuary, North Carolina [PhD Dissertation]. Raleigh, NC: North Carolina State University, 2000.
  - Burkholder JM, Glasgow HB Jr, Hobbs CW. Fish kills linked to a toxic ambush-predator dinoflagellate: distribution and environmental conditions. *Mar Ecol Prog Ser* 124:443–461 (1995).
  - Glasgow HB Jr, Burkholder JM, Schmechel DE, Tester PA, Rublee PA. Insidious effects of a toxic estuarine dinoflagellate on fish survival and human health. *J Toxicol Environ Health* 46:501–522 (1995).
  - Shoemaker R. Diagnosis of *Pfiesteria* human illness syndrome. *MD Med J* 46(10):521–523 (1997).
  - Grattan LM, Oldach D, Perl TM, Lowitt MH, Matuszak DL, Dickson C, Parrott C, Shoemaker RC, Kauffman CL, Wasserman MP, et al. Learning and memory difficulties after environmental exposure to waterways containing toxin-producing *Pfiesteria* or *Pfiesteria*-like dinoflagellates. *Lancet* 352:532–539 (1998).
  - Hudnell HK, House D, Schmid J, Koltai D, Wilkins J, Stopford W, Savitz D, Swinker M, Music S. Human visual function in the North Carolina Clinical Study on Estuary Associated Syndrome. *J Toxicol Environ Health* 62:101–120 (2001).
  - Centers for Disease Control and Prevention. Notice to readers: possible estuary associated syndrome. *Morb Mortal Wkly Rep* 48:381–382 (1999).
  - Fairey ER, Edmunds JSG, Deamer-Melia NJ, Glasgow H Jr, Johnson FM, Moeller PR, Burkholder JM, Ramsdell JS. Reporter gene assay for fish-killing activity produced by *Pfiesteria piscicida*. *Environ Health Perspect* 107:711–714 (1999).
  - Turf E, Ingrisawang L, Turf M, Ball JD, Stutts M, Taylor J, Jenkins S. A cohort study to determine the epidemiology of estuary-associated syndrome. *VA J Sci* 50:299–310 (1999).
  - Shoemaker R. Treatment of persistent *Pfiesteria*-human illness syndrome. *MD Med J* 47(2):64–66 (1998).
  - Taylor R. Skin Biopsy Report No. S97-10648 and S97-10372. Salisbury, MD: Peninsula Regional Medical Center, 1997.
  - Pestaner J. Autopsy No. 99-7751. Baltimore, MD: Office of the Chief Medical Examiner, State of Maryland, 1999.
  - Ginsburg AP. A new contrast sensitivity vision test chart. *Am J Optom Physiol Opt* 61:403–407 (1984).
  - Ginsburg AP, Evans D, Cannon M, Mulvanny P. Large sample norms for contrast sensitivity. *Am J Optom Physiol Opt* 61:80–84 (1984).
  - Livingstone M, Hubel D. Segregation of form, color, movement and depth: anatomy, physiology and perception. *Science* 240:740–749 (1988).
  - Hudnell HK, Skalik I, Otto D, House D, Subrt P, Sram R. Visual contrast sensitivity deficits in Bohemian children. *Neurotoxicology* 17(3-3):615–628 (1996).
  - Mergler D. Behavioral neurophysiology: quantitative measures of sensory toxicity. In: *Neurotoxicology: Approaches and Methods* (Chang LW, Slikker W Jr, eds). San Diego, CA: Academic Press, 1995:727–736.
  - Shoemaker RC. Treatment of possible estuary-associated syndrome: neurotoxins, contrast sensitivity and cholestyramine [Abstract]. Presented at the CDC National Conference on *Pfiesteria*: from Biology to Public Health, 18–20 October 2000, Stone Mountain, GA.
  - Boylan JJ, Egle JL, Guzelian PS. Cholestyramine: use as a new therapeutic approach for chlordecone (kepone) poisoning. *Science* 199:893–895 (1978).
  - Cohn WJ, Boylan JJ, Blanke RV, Fariss MW, Howell JR, Guzelian PS. Treatment of chlordecone (kepone) toxicity with cholestyramine. Results of a controlled clinical trial. *N Engl J Med* 298:243–248 (1978).
  - Mutter LC, Blanke RV, Jandacek RJ, Guzelian PS. Reduction in the body content of DDE in the Mongolian gerbil treated with sucrose polyester and caloric restriction. *Toxicol Appl Pharmacol* 92:428–435 (1988).
  - Reigart JR, Roberts JR. Recognition and Management of Pesticide Poisoning. EPA 735-R-98-003. Washington, DC: U.S. Environmental Protection Agency, 1999.
  - Bungay PM, Dedrick RL, Matthews HB. Pharmacokinetics of halogenated hydrocarbons. *Ann NY Acad Sci* 320:257–270 (1979).
  - Moncino MD, Falletta JM. Multiple relapses on *Clostridium difficile*-associated diarrhea in a cancer patient: successful control with long-term cholestyramine therapy. *Am J Pediatr Hematol Oncol* 14:361–364 (1992).
  - Liacouras CA, Piccoli DA. Whole-bowel irrigation as an adjunct to the treatment of chronic, relapsing *Clostridium difficile* colitis. *J Clin Gastroenterol* 22:186–189 (1996).
  - Rateau JG, Broillard M, Morgant G, Aymard P. Etude expérimentale chez le lapin de l'effet de la cholestyramine dans le traitement des diarrhées infectieuses d'origine cholérique. *Actual Ther* 22:289–296 (1986).
  - Brouillard MY, Rateau JG. La Cholestyramine fixe les toxines d'*Escherichia coli* et de *Vibrio cholerae* par une liaison ionique. *Ann Gastroenterol Hepatol* 26:27–30 (1990).
  - Humphrey CD, Condon CW, Canteley JR, Pittman FE. Partial purification of a toxin found in hamsters with antibiotic-associated colitis. Reversible binding of the toxin by cholestyramine. *Gastroenterology* 76:468–476 (1979).
  - Andersen T, Andersen JR, Tvede M, Franzmann M-B. Collagen colitis: are bacterial cytotoxins responsible? *Am J Gastroenterol* 88:375–377 (1993).
  - Creppy EE, Baudrimont I, Belbeder A-M. Prevention of nephrotoxicity of ochratoxin A, a food contaminant. *Toxicol Lett* 82/83:869–877 (1995).
  - Kerkadi A, Barriault C, Tuchweber B, Frohlich AA, Marquardt RR, Bouchard G, Yousef M. Dietary cholestyramine reduces ochratoxin A-induced nephrotoxicity in the rat by decreasing plasma levels and enhancing fecal excretion of the toxin. *J Toxicol Environ Health* 53:231–250 (1998).
  - Visconti A, Solfrizzo M, Torres A, Chulze S, Avataggiato G. Cholestyramine as a Binding Agent for Detoxification of Fumonisin: *in vitro* Studies and Determination of Its Effectiveness in Rat Feeding Experiments. In: *International Conference on the Toxicology of Fumonisin*, 28–30 June 1999, Arlington, VA. Washington, DC: International Life Sciences Institute, 1999:59.
  - Dahlem AM, Hassan AS, Swanson SP, Carmichael WW, Beasley VR. A model system for studying the bioavailability of intestinally administered microcystin-LR, a hepatotoxic peptide from the cyanobacterium *Microcystis aeruginosa*. *Pharmacol Toxicol* 64:177–181 (1989).
  - Underhill KL, Totter BA, Thompson BK, Prelusky DB, Trenholm HL. Effectiveness of cholestyramine in the detoxification of zearalenone as determined in mice. *Bull Environ Contam Toxicol* 54:128–134 (1995).
  - Centers for Disease Control and Prevention. Jin Bu Huan toxicity in adults—Los Angeles, 1993. *Morb Mortal Wkly Rep* 42:920–922 (1993).
  - Tuchweber B. Personal communication.
  - Kerkadi A, Barriault C, Marquardt RR, Frohlich AA, Yousef M, Tuchweber B. Cholestyramine protection against ochratoxin A (OTA) toxicity: role of OTA adsorption by the resin and bile acid enterohepatic circulation. *Toxicologist* 48:1–3 (1999).
  - Lewis RJ, Sellin M, Poli MA, Norton RS, MacLeod JK, Sheil MM. Purification and characterization of ciguatoxins from moray eel (*Lycodontis javanicus*, Muraenidae). *Toxicon* 29:1115–1127 (1991).
  - Izatt J. Reaction of ammonium cations with 18-crown-6. *J Am Chem Soc* 101:6273–6276 (1979).
  - Phibbs P. Doctor claims drug can help people exposed to *Pfiesteria*. *Environ Health Lett* 37(11):202 (1998).
  - Moeller P. Toxin isolation and characterization [Abstract]. Presented at the CDC National Conference on *Pfiesteria*: from Biology to Public Health, 18–20 October 2000, Stone Mountain, GA.
  - Ramsdell J. Characterization of a P2X7 ionotropic receptor for the putative *Pfiesteria* toxin and its role in chronic inflammatory responses [Abstract]. Presented at the CDC National Conference on *Pfiesteria*: from Biology to Public Health, 18–20 October 2000, Stone Mountain, GA.
  - El-Nabawi A, Quesenberry M, Saito K, Silbergeld E, Vasta G, Eldefrawi A. The N-methyl-D-aspartate neurotransmitter receptor is a mammalian brain target for the dinoflagellate *Pfiesteria piscicida* toxin. *Toxicol Appl Pharmacol* 169:84–93 (2000).