

Pre-Brodman pioneers of cortical cytoarchitectonics II:

Carl Hammarberg, Alfred Walter Campbell, and Grafton Elliot Smith

Lazaros C. Triarhou

ORCID 0000-0001-6544-5738

Laboratory of Theoretical and Applied Neuroscience, School of Social Sciences, Humanities and Arts,
University of Macedonia, Thessalonica 54636, Greece

Concise Title: **Hammarberg, Campbell, and Elliot Smith**

Correspondence:

Lazaros C. Triarhou, University of Macedonia, Egnatia 156, Bldg. Z-312, Thessalonica 54636, Greece

E-mail: triarhou@uom.edu.gr

Abstract

The present study and the preceding paper revisit landmark discoveries that paved the way to the definition of the renowned Brodmann areas in the human cerebral cortex, in an attempt to rectify certain undeserved historical neglects. A ‘second period of discoveries’, from 1893 to 1908, is marked by the work of Carl Hammarberg (1865–1893) in Uppsala, Alfred Walter Campbell (1868–1937) in Liverpool, and Grafton Elliot Smith (1871–1937) in Cairo. Their classical findings are placed in a modern perspective.

Keywords Cerebral cortex · Brodmann areas · Cortical localisation · History of Neuroscience · Human brain function

Introduction

The present study continues the review of contributions by pioneer researchers to the field of cytoarchitectonics of the cerebral cortex up to the landmark monograph of Korbinian Brodmann (1868–1918) that defined the well-known Brodmann areas (Brodmann 1909).

The preceding companion article (Triarhou 2020) covered the work of Theodor Meynert (1833–1892), Vladimir Betz (1834–1894), and William Bevan-Lewis (1847–1929) from 1867 through 1882, which formed the foundations for the systematic study of the laminar organisation and regional variations of the cerebral cortex in the human brain. Here I present the discoveries of the second triad of pioneers who historically contributed to the study of cortical cytoarchitecture from 1893 to 1908: Carl Hammarberg (1865–1893) in Sweden, Alfred Walter Campbell (1868–1937) in the United Kingdom, and Sir Grafton Elliot Smith (1871–1937) in Egypt.

Hammarberg, especially, seems to be one of those classically unrecognised figures of science outside his native Sweden. He was the first neurohistologist to distinguish the cellular structure of diverse cortical regions in motor, sensory, and limbic areas by producing excellent illustrations of the cortical layers, by providing extensive quantitative layer and cell measurements, and by setting the stage for studying the cellular anatomy of neurodevelopmental mental disability (Hammarberg 1893, 1895).

With the dawn of the 20th century, Campbell (1904b, 1905b) and Elliot Smith (1907) were also among the pioneers who provided extensive and detailed ‘maps’ of cortical area divisions. Campbell (1905b) in particular, working on a physiological, clinical, and comparative morphological basis, presented a parcellation scheme of the most important cortical areas in humans and animals, simultaneously considering myeloarchitectonics, or the pattern of myelinated fibre distribution in the cortical layers.

Technically speaking, the term ‘pre-Brodmann’, as I adopt it in the present paper, applies loosely to Campbell and Elliot Smith, contemporaries of Brodmann, who worked during the same period; thus, there is a chronological overlap between their studies and Brodmann’s ongoing research, from him joining the laboratory of Oskar Vogt in 1901 until the publication of the 1909 neurological classic (Brodmann 1909). Brodmann’s book was actually based on a series of eight articles under the general title ‘Beiträge zur histologischen Lokalisation der Grosshirnrinde’ (‘Contributions to the histological localisation of the cerebral cortex’) that were published in Vogt’s *Journal für Psychologie und Neurologie* between 1903 and 1908. Brodmann’s last publication was a detailed chapter in which he summarised his work on cytoarchitectonics in conjunction with aspects of cerebral physiology (Brodmann 1914). In any event, Brodmann’s 1909 monograph is considered a frontier, owing to its universal acceptance by the neurological world as a milestone in cortical research.

This article concludes with a discussion of the classical discoveries in a modern perspective.

Carl Hammarberg (1865–1893)

The Swedish physician Carl Hammarberg (Fig. 1) completed the first comprehensive cytoarchitectonic study of the human cerebral cortex. His biography was not featured in either edition of *The Founders of Neurology* (Haymaker and Baer 1953; Haymaker and Schiller 1970), and his name does not retrieve any results in the MedLine/PubMed search engine.

Hammarberg should receive more recognition as a pioneer of the systematic study of the cellular structure of the human cerebral cortex in development, in the adult, and in mental disability, having carried out what is most likely the first systematic histological study with extensive quantitative data on cortical layer thickness, as well as cell size and density in diverse cortical fields. His contribution rests on the fact that he took the study of the cerebral cortex from the macroscopic to the microscopic level. In other words, Hammarberg set the foundations for the classical cytoarchitectonic studies that followed through the early part of the 20th century, by distinguishing the architectural details of motor, sensory and limbic cortical areas. In all, the cortical layer scheme as specified by Hammarberg is essentially the general scheme still in use today. Moreover, he laid the groundwork necessary for investigating individual variations among normal brains, and the morphological changes that occur in developmental brain abiotrophies in relation to behavioural outcomes and functional effects, in a true spirit of clinico-pathoanatomical correlations.

Born on 12 November 1865 in Västervik, on the southeastern coast of the Småland Province, to Marine captain Carl August Hammarberg and Augusta Charlotta Holm, Hammarberg studied medicine at Uppsala University from 1885 to 1889, and obtained his medical licence in 1892. He was affiliated with the Uppsala University Hospital, and he worked under psychiatrist Gustaf Kjellberg (1827–1893), the founder of the scientific study of psychiatry in Sweden, and neurologist Salomon Henschen (1847–1930), known for his epoch-making studies on the visual pathways, aphasia, and dyscalculia, and for coining the term acalculia. Hammarberg's first publication concerned a case of *Cerebellar Atrophy and Sclerosis* (Hammarberg 1890a, b), with an autopsy report and a review of the literature.

Prompted by Henschen to concentrate on the study of cortical histology and pathology, Hammarberg completed his M.D. thesis (*Clinico-Pathological Studies of Intellectual Disability Along with Studies of the Normal Anatomy of the Cerebral Cortex*; Fig. 2) on 26 May 1903 (Hammarberg 1893), receiving an *insigni cum laude*; the opponent at the defence (*cum laude approbatur*) was anatomist Edward Clason (1829–1912), a member of the Royal Swedish Academy of Sciences. On 22 October, Hammarberg became ill with appendicitis; professor Karl Gustaf Lennander (1857–1908) operated on him. On 1 November 1893, he succumbed to septicemia, only months after having been appointed Docent (lecturer) in practical medicine at Uppsala University in the spring of that year (Lindberg 2013). He was barely 28 years old (Levertin 1911; Sourander and Öberg 1969–1971). Being the undoubtedly beloved pupil and designated successor of Henschen, Hammarberg was interred in the Henschen family grave at Uppsala's Old Cemetery (*Gamla Kyrkogård*) (Lindberg 2013). Granting his

wish, his thesis was posthumously translated and published in German (Hammarberg 1895); every autumn thereafter, royalties of 40–80 marks for sales in Germany were sent to Carl's mother Charlotta (Lindberg 2013).

Hammarberg (1893, 1895) systematically studied various parts of the cerebral cortex in 20- μ m thick sections stained with Nissl methylene blue. He examined 12 brains of individuals who had died of non-neurological causes, including a twin foetus at 5 months of gestation, and postnatal specimens from 2 to 50 years of age. In addition, he studied nine brains of individuals with mental disability, ranging from 22 months to 26 years of age. Some of the material was provided by Gustaf Retzius (1842–1919) and faculty members of the Karolinska Institute in Stockholm.

By defining cortical areas based on cytoarchitectonic criteria rather than gyral macroscopy, Hammarberg confirmed the non-uniform cellular construction of the human cerebral cortex and described more than five structural cortical types. Hammarberg was the first author to make a clear distinction between the cytoarchitectonic differences of motor and sensory cortical areas, and he laid the foundations for the knowledge of the finer anatomy of limbic structures, including a depiction of spindle cells in layer V (Fig. 2).

Shortly after Hammarberg, Ramón y Cajal (1899–1904), using the Golgi method, also described the morphology of spindle cells in the frontoinsular cortex of a one-month-old girl, and suggested that they were a unique neuronal subtype with distinct structural features (Ramón y Cajal 1899–1904; Banovac et al. 2019). The name 'von Economo neurons' was given to the large bipolar nerve cells located in layer V of the anterior cingulate and frontoinsular cortices (Economo and Koskinas 1925; Economo 1926), distinct from pyramidal cells (Watson et al. 2006; Seeley et al. 2012). Phylogenetically, these cells are thought to be a recent evolutionary acquisition of the last 15–30 million years (Hof and Van Der Gucht 2007), and their repeated emergence among distantly related species, such as humans, the great apes, macaque monkeys, the hippopotamus, cetaceans, elephants, cetartiodactyls, perissodactyls and afrotherians, seems to represent a convergent evolution (Raghanti et al. 2015).

Hammarberg solely relied on the Nissl method and did not attempt to reconcile his findings with those of earlier investigators who had used the Golgi method (Ramón y Cajal 1899b; DeFelipe and Jones 1988). Through laborious measurements and methods that he developed, Hammarberg provided quantitative estimates for a number of cortical areas (Brodmann 1909; Garey 2006). He showed that changes caused by the preparation of the cortex were not as great as had been previously assumed; the variations in cortical thickness between non-embedded frozen sections and alcohol-treated, paraffin-embedded sections did not exceed 0.2 mm.

In the seven plates of his monograph, Hammarberg (1893, 1895) provided excellent overview drawings of several cortical localities (Fig. 3); his detailed description of cortical structure has withstood the test of time, as it largely corresponds to our present-day knowledge. Furthermore, he precisely determined the overall cortical thickness, the thickness of individual layers, as well as the

size and density of neurons per 0.001 mm³; his quantitative estimates approximately matched the measurements of Economo and Koskinas (1925) three decades later. Thus, he established the necessary basis for studying structural variations among normal individuals, as well as for comparing the brains of pathological entities with mental disability to those of control subjects.

In the footsteps of Bevan-Lewis (1878), Hammarberg (1893) adopted the hexalaminar cortical scheme, originally introduced by Jules Baillarger (1809–1890) and subsequently confirmed by Rudolf Berlin (1833–1897), who also identified the three main types of cortical neurons, the pyramidal, the granule, and the spindle cells (Baillarger 1840; Berlin 1858). The continuous renumbering of cortical layers by various authors over time had unnecessarily complicated the decipherment of their cellular structure, especially ‘if every researcher who embarks on this topic feels compelled to replace the practically approved and objectively well-founded parcellation with a new, individual scheme for insubstantial personal reasons’ (Economo and Koskinas 1925). For example, the scheme of Bevan-Lewis and Hammarberg was neglected by Ramón y Cajal (1900–1906) and Campbell (1905b), who combined layers II and IIIa into one layer and subdivided the remainder of layer III into two sublayers. Vogt (1906, 1910) defined the lower part of layer VI, i.e. sublayer VIb, as a separate layer VII. For all practical purposes, the layer scheme of Bevan-Lewis as specified by Hammarberg was adopted by Brodmann (1909), who thoroughly dealt with cytoarchitectonics and managed for that scheme to be tacitly accepted, as it continues to be the general division still in use. Table 1 in the companion paper (Triarhou 2020) shows how the classification and the naming of cerebral cortical layers evolved historically, from Meynert (1867/1868) to Economo and Koskinas (1925), including the sublayers that were distinguished within most of the main layers.

In the motor cortex, Hammarberg (1895) noted that the granular layers II and IV were virtually missing, although he did illustrate a very small number of granule cells in layer IV. He implicitly recognised six layers in the precentral gyrus, by subdividing Meynert’s fifth layer into a superficial stratum, which contained Betz cells, and a deep stratum of fusiform cells. Hammarberg noted the agranular nature of the rear two thirds of the superior frontal gyrus and of the segment of the middle frontal gyrus near the precentral gyrus. During postnatal ontogeny, only the posteriormost one third of the superior frontal gyrus was granulo-prival; with advancing age, the agranular zone extended forwards, such that it occupied one half of the gyrus. He described the occurrence of giant cells in the foot of the middle frontal gyrus (corresponding to agranular frontal area *FB* of Economo and Koskinas), as well as large-size cells in the deep parts of the internal granular layer in the inferior frontal gyrus pars opercularis (corresponding to the opercular intermediate frontal area *FC_{op}* of Economo and Koskinas).

Regarding the orbital part or ‘third area’ (*tredje området*) of the inferior frontal gyrus (or granular orbital area *FF* of Economo and Koskinas), he rightfully noted that pyramidal cells of layer V were long and narrow and that layer VI was very wide. Hammarberg only missed the size of cells in layer IIIc, which Betz had correctly described. In the pars opercularis of the inferior frontal gyrus, he

documented the paucity of granule cells, but he did not unequivocally depict the large pyramidal cells that characterise the deepest part of layer III in Broca's area (FCB_m).

He mentioned that the agranular parts of the middle frontal gyrus were restricted in its segment close to the precentral gyrus. Hammarberg characterised the orbital part or 'second area' (*andra området*) of the middle frontal gyrus with the pyramidal cells of layer III becoming long and narrow ($25 \times 10 \mu\text{m}$). Layer V contained fairly large cells ($25 \times 12 \mu\text{m}$), while layer VI was broad, and its nerve cells were not particularly large in size.

The description that Hammarberg gave for the structure of the postcentral gyrus is more exact. Its upper dorsal part is built similarly to the precentral gyrus, i.e. it contains giant cells. Hammarberg noted that the remainder of the cortex of the postcentral gyrus was extremely narrow (1.7 mm); layers II and III actually merged into a single layer, which consisted of small pyramidal cells. In its deepest rows, pyramidal cells measured $30 \times 20 \mu\text{m}$ at the most. Hammarberg described the oral postcentral area granulosa PB_1 more exactly than Betz, besides the intermediate postcentral area PC_γ and the giant pyramidal postparacentral area PA_2 . He also described the external granular layer II and external pyramidal layer III as combined into a common stratum of a granular appearance containing small-sized cells.

In the superior parietal gyrus, Hammarberg pinpointed the cellular richness of layer IV, and fittingly subdivided layer V into sublayers Va and Vb. He also underlined the similarity of the lower and upper parietal lobe. He noticed a difference between the anterior and posterior parts (supramarginal and angular areas) and properly noted that layer III in the anterior parts was rather thick (over 1.0 mm), and further back, in the angular gyrus, it continued to be rather wide as well. Moreover, he divided layer IV of the angular gyrus into two sublayers, IVa and IVb.

In the superior temporal gyrus (Fig. 3), Hammarberg (1893, 1895) recognised the six typical cortical layers. Twenty years after Betz — in a similar manner, but more exactly — Hammarberg noted that the pyramidal cells were smaller and elongated in layers III and V. His description concerned the posterior superior temporal area TA. Hammarberg did not divide the superior temporal gyrus into different fields; he seems to have overlooked the peculiarities of the Heschl gyri, which Betz had already indicated. Furthermore, the characteristic columns of the cells in the temporal lobe — the 'rainshower formation' in the supratemporal area granulosa TC of the first gyrus of Heschl and the 'organ pipe formation' in the supratemporal area simplex TB of the second gyrus of Heschl (Economo and Koskinas 1925, 2008) — escaped his attention.

According to Hammarberg (1895), the visual cortex was distinguished by a lack of giant pyramidal cells (Fig. 3), which were replaced by a broad layer of granule cells arranged in three sublayers; among these, there were two bands, poor in nerve cells, with a molecular layer-like appearance. Between the granular and the fusiform layers, there was a row of large pyramidal cells, the 'solitary cells' of Meynert, also depicted by Ramón y Cajal (1899a; DeFelipe and Jones 1988).

Hammarberg was the first to divide the occipital lobe into two areas: a 'first area' (*första*

området), part of the gyrus belonging to the lateral hemispheric facies (superior occipital gyrus O₁ and lateral occipital gyri O₂ and O₃), and a ‘second area’ (*andra området*), the part entirely belonging to the medial hemispheric surface (cuneus, internal inferior occipital gyrus, and superior lingual gyrus). That definition only partially agreed with later divisions, as Hammarberg almost considered the entire medial surface to be part of the second field. Despite his otherwise excellent depictions, Hammarberg’s specimens of the occipital lobe might have been suboptimal, particularly with regard to the calcarine sulcus. He did not see the sudden transition from parastriate area *OB* to the striate area granulosa *OC* at the medial hemispheric surface that is so conspicuous, but instead spoke of a gradual transition. Layer II could not be differentiated from layer III. Furthermore, he wrote that the cells of layer IV also filled layer V, by which he apparently meant as typical of the occipital lobe, that the cells of layer V hardly differed in size and form from those of layer IV (Economo and Koskinas 1925).

Hammarberg observed that the cingulate gyrus was agranular anteriorly: it lacked a granular layer IV, which it regained in its posterior half. He mentioned the preponderance of only layers I, III, and VI in it. Hammarberg’s anterior ventral cingulate area corresponded to the anterior agranular limbic areas LA₁–LA₃ of Economo and Koskinas (1925, 2008). In the anterior insula, Hammarberg described the narrowness of layer IV and the robustness of layer VI.

Hammarberg (1893) categorised his pathological cases under three subheadings (A, B1, B2), based on a scheme by the German psychiatrist Heinrich Schüle (1840–1916), a pioneer of institutional psychiatry in Baden and long-time director of the Illenau Sanatorium, who had classified ‘idiots’ in two main groups, *Blödsinnige* (imbecile) and *Schwachsinnige* (feeble-minded) (Schüle 1886).

In all groups of mental disability (Fig. 4), the larger part of the cortex remained at a developmental stage that corresponded to the normal foetal or early postnatal brain; normal neurogenesis did not take place, cells were lost during development, or only a small number of cells reached a higher degree of development. In group A (profound intellectual disability, *fånarne idioterna*), the developmental arrest occurred at the late stages of foetal life, and the larger part of the cerebral cortex did not develop as it would under normal conditions; the patients lacked any trace of consciousness, and mental development was unattainable. In group B1 (severe intellectual disability, *höggradigt sinnesslöe*), the inhibitory moment hit the cerebral cortex during either foetal life or the first postnatal years, and the larger part of the cortex did not reach the degree of development normally seen in the first years of life; the patients had some comprehension and conscious awareness, but mental development remained at a stage characteristic of the first years of normal life. In group B2 (moderate intellectual disability, *måttligt sinnesslöe*), the inhibitory moment hit the cortex in the first year of life and only a small component of development was fully arrested, while the larger part of the cortex grew in all aspects, except cell number; mental functions were sluggish and less developed (Fig. 5). In all three groups, disturbances of the cranial nerves, as well as motor and sensory deficits, might occur.

Hammarberg (1893) attributed the enlargement of the pericellular and perivascular spaces,

previously described by other authors, to a shrinking process during brain fixation in Müller's fluid, ethanol or xylol, and during paraffin embedding. Moreover, he attributed the misplacement of pyramidal cells in intellectual disability, reported by other authors, to incorrect observations. In the normal cerebral cortex, especially in the ganglion cell layer, it was not uncommon to observe pyramidal cells with their longest diameter displayed horizontally and the tip processes bent against the surface. In the inferior frontal gyrus, in particular, cells were normally arranged in groups inclined, such that their apical dendrites would cross each other in different directions. Such an arrangement of cells was not more pronounced in any of the pathological brains compared to normal. Only in one out of nine cases did he notice cell degeneration. He deemed this and similar changes to be of minor importance. More important and determinant of the behavioural outcome was the lack of functional cortical neurons.

Alfred Walter Campbell (1868–1937)

The only complete map of the human cerebral cortex that combined cytoarchitectonics and myeloarchitectonics was produced in the early 20th century by Campbell (1904b, 1905b), who designated 17 cortical areas and named them with either topographical or provisional functional terms (Fig. 6). He upheld that the accurate description of the cellular architecture of the cortex was crucial for the scientific advancement of neurology, and hence he studied normal human brains, various neurological conditions, and diverse animal species (Fulton 1938; Foley and Storey 2010). His monograph (Campbell 1905b) has been hailed as a landmark.

Alfred Walter Campbell (Fig. 1) was born on 18 January 1868 at Cunningham Plains, near Murrumburrah in New South Wales, the son of pastoralist David Henry Campbell, of Scottish-Danish extraction, and his wife Amelia Margaret, of French Huguenot descent. He entered the University of Edinburgh in 1885 to study medicine, and he received the M.B. and Ch.M. in 1889. His professors included anatomist Sir William Turner (1832–1916) and physiologist William Rutherford (1839–1899) (Macmillan 2009). After graduation, Campbell went to Vienna as an assistant to psychiatrist Richard von Krafft-Ebing (1840–1902); during his stay there, he also trained under Theodor Meynert (1833–1892) in neuroanatomy, Heinrich Obersteiner (1847–1922) in neuropathology, Salomon Stricker (1834–1898) in histology, and Hans Kundrat (1845–1893) in pathology. He then went to Prague as staff of the metropolitan State Asylum and the Pathology Institute of the German University, where he trained under psychiatrist Arnold Pick (1851–1924), bacteriologist Ferdinand Hueppe (1852–1938), and pathologist Hans Chiari (1851–1916) (Macmillan 2009, 2014).

In 1892, he presented his M.D. thesis (*Alcoholic Neuritis, Its Clinical Features and Pathology*) in Edinburgh, and was appointed medical officer and director of pathology at the Lancashire County Asylum in Rainhill, which thereafter became affiliated with the University of Liverpool (Fulton 1938). Having completed studies on the Continent, Campbell served outstandingly as researcher, pathologist, neurologist, psychiatrist, and writer (Marshall and Magoun 1998), with interests that also encompassed botany, ornithology, the history of science, and foreign languages.

He carried out his histological studies on the cortex in the pathology laboratory at Rainhill, having joined the circle of Sir Charles S. Sherrington (1857–1952), who, at the time, investigated cerebral localisation in primates at the University of Liverpool. Campbell began his epoch-making research under Sherrington's stimulus. In line with analysing human brains, Campbell worked up several of Sherrington's experimental brains, 'with the object of ascertaining whether the cortex of the parts which responded to electrical excitation could be differentiated from the "silent" parts, by the possession of any distinctive histological structure'. He wanted to prove that 'it is just as possible to define the motor area on the histological bench as on the operating table' (Campbell 1905b).

Having been drawn early to neurology and mental illness, Campbell aimed at establishing a correlation between morphology and physiology. The opening sentence of his first study on cortical architectonics reads, 'The essential aim of this work is to further the establishment of a correlation

between physiological function and histological structure' (Campbell 1904a). He provided accurate information on the extent and limits of functionally differentiated areas, compared with previous investigators who had only used physiological methods (Marshall and Magoun 1998).

He worked up the normal cerebral hemispheres of man, chimpanzee, orangutan, and gorilla, and he extended the comparative studies to the dog, cat, and pig brain, concluding that 'the stability of the architectural plan of any given field of cortex is directly related to the phylogenetic age of that cortex and to the importance of the function it subserves' (Campbell 1905a).

The primate brains that Campbell examined histologically were those experimented upon by Grünbaum and Sherrington (1902, 1904). Between 1900 and 1903, Campbell cut serial sections of 25 brains, alternately staining them for cells and fibres. The tissues were cut into blocks at right angles to the main sulci to provide transverse views of the principal gyri; he then obtained 15- or 25- μ m thick serial sections from celloidin-embedded blocks. Campbell stained the sections either with the Wolters–Kulschitsky method for myelin or with thionine for cell bodies (Macmillan 2009).

He defined the motor and premotor (or 'intermediate precentral') areas as they are widely recognised today (Fig. 6). In pathological material, he clarified the fine organisation of cells and fibres in the visual, motor, and parietal cortices (Fulton 1937; Bonin 1953). By examining the brains of amputated patients, Campbell showed that the atrophy in the motor region was restricted to giant pyramidal cells. In amyotrophic lateral sclerosis, he described the disappearance of Betz cells from their normal location, while the postcentral gyrus entirely escaped affection (Campbell 1904a). In tabes dorsalis, he noted a loss of neurons in the sensory cortex of the postcentral gyrus.

Sherrington and Grünbaum (1902) acknowledged Campbell for showing, 'by a laborious investigation of the microscopical character of the cerebral cortex, that the boundaries of the "motor area" as defined by anatomical characteristics accorded with those already obtained by them with physiological methods'. Campbell (1902) explained that from an examination of serial sections of the brains of two chimpanzees and one orangutan stained for nerve fibres, he defined a motor area that coincided with the one discovered by Sherrington and Grünbaum (1901a, b) in their physiological experiments. This area was posteriorly bounded by the central sulcus, while its anterior limit was less definite. The histological features that characterised the motor area were a strongly developed zonal layer or tangential field, a supraradiary field relatively rich in nerve fibres, and a radiary zone of great wealth in nerve fibres. The differences in structure between the precentral and postcentral gyri were very marked, also denoted by other structural elements, such as Betz cells. The motor type of structure did not extend into the postcentral gyrus. Campbell held that there were no Betz cells in the cortex behind the central sulcus; instead, the area was laden with granule cells, and he suggested that the arrangement of the postcentral fibres was more indicative of a sensory centre (Campbell 1905b). In Campbell's parcellation scheme, the frontal cortex was unusually large; the intermediate precentral cortex, which roughly corresponded to Brodmann area 6, was not demarcated from Broca's motor speech region (Brodmann areas 44 and 45), and the temporal area occupied the inferior and middle

temporal gyri and extended over regions of the parietal lobe (Nieuwenhuys 2013).

Mott et al. (1911) studied the brain of the gibbon and found that its lateral hemispheric surface was clad in a cortical type characterised by the absence of a distinct layer of granule or stellate cells, thus corresponding to Campbell's precentral and intermediate precentral types, or Brodmann areas 4 and 6. The distribution of Betz cells closely resembled that in the orangutan, and was also similar to that in the chimpanzee, as Campbell had shown in his diagrams. The area occupied by what Campbell described as frontal cortex, or Brodmann area 9, was restricted, only occupying a very small space above the sulcus rectus in the vicinity of the frontal pole.

Campbell opined that simple visual sensations arose in a 'visuo-sensory' area on the mesial surface of the calcarine sulcus, where nervous signals from the retina terminated; sensations were elaborated into conscious perceptions in a 'visuo-psychic' area, which morphologically formed 'an investing zone or skirt to the first' (Campbell 1904a, 1905b). The 'visuo-sensory' area corresponded to Brodmann area 17 or striate area granulosa OC of Economo and Koskinas, and the 'visuo-psychic' encompassed Brodmann areas 18 and 19 or parastriate areas OB and peristriate areas OA of Economo and Koskinas. Campbell (1904a) noted 'the presence of curious large pyramidal cells' that served for the microscopical identification of the 'visuo-psychic' field, in what may have been a hint at the magnocellular peristriate area OA_m or the giant pyramidal parastriate boundary OB_γ, designated by Economo and Koskinas (1925, 2008). Macmillan (2014) argues that Campbell's identification of two structurally different areas in the occipital lobe was the starting point for the eventual differentiation of areas V1 and V2. Campbell's visuo-psychic cortex contains, at the least, fields V2, V3, V3A, and V4; with regard to the white matter fibre projections in the occipital lobe, he recognised three main classes: the optic radiation, autochthonous fibres (short association or U-fibres connecting adjacent occipital gyri), and long ipsilateral association fibres (the superior longitudinal or arcuate fasciculus, the inferior longitudinal fasciculus, and the occipitofrontal fasciculus) (ffytche and Catani 2005).

Similarly, Campbell (1904a, b) described an 'audito-sensory area' in the transverse temporal gyri, concealed within the Sylvian fissure, and an 'audito-psychic area' in the posterior three fifths of the superior temporal gyrus. Notably, he commented that further evidence on this point was needed.

Campbell (1904b, 1905b) underlined the fact that in a surface map it was not possible to convey a true idea of the extent of many of the fields, as the cortex that was concealed within fissures and sulci could not be indicated. Thus, the floor, not the lip, of the central sulcus was the boundary between the precentral and postcentral fields; accordingly, the concealed portion of these areas was almost equivalent to that exposed. The same applied to the 'visuo-sensory field' in the calcarine sulcus and the 'audito-sensory field' in the Sylvian fissure.

In 1905, Campbell returned to Sydney, taking up a private practice in neurology and psychiatry. In November 1914, he enlisted as a volunteer in the Australian Army Medical Corps and was sent to Egypt, where he served as major at the Second Australian General Hospital of Cairo, overseeing the care of soldiers injured in the Gallipoli campaign (Foley and Storey 2010). He returned to Sydney the

following year and was appointed consultant neurologist at the Military Hospital in Randwick and the Royal Alexander Hospital for Children (Fulton 1938). Campbell never occupied an academic position in Australia and did not train any students (Bonin 1953; Ford 1979; Eadie 1981).

After 1905, his research focused on the cytoarchitectonics of the cerebral cortex of the gorilla, on localisation in the cerebellum, on the neuroses and psychoses of war, and on the pathophysiology of the insect-borne Murray Valley encephalitis. Although much of this research remains of considerable value, it had been historically neglected until recently (Macmillan 2017).

In what was the first cytoarchitectonic study of the gorilla brain, Campbell (1916) examined the right cerebral hemisphere of a juvenile gorilla provided by Sherrington. He recognised the same areas in the gorilla as he had before in human, chimpanzee, and orangutan brains, with certain differences in the frontal and prefrontal areas and the boundaries of the intermediate postcentral area. Further, he amended his earlier views on temporal and olfactory areas. He wrote that the common temporal area actually comprised two fields, a 'temporal', which contained more and larger suprastellate and infrastellate cells, and a 'subtemporal', which was poorer in cells and fibres (Campbell 1916). He also differentiated an area, homologous in humans and the great apes ('olfactory B') from the remainder ('olfactory A'); he theorised that here too there was a division of functions as 'sensory' and 'psychic' (Campbell 1916; Macmillan 2017). Further detailed analyses of Campbell's identification of the motor and visual areas in the human and ape brain and a controversy that surrounded the localisation studies can be found in Macmillan (2014).

Campbell died of a malignancy on 4 November 1937 in the Rose Bay suburb of Sydney (Bonin 1953; Ford 1979; Eadie 1981). His integrative approach was placed in a modern perspective by ffytche and Catani (2005), who appreciated that the combination of cytoarchitectonic, physiological, and clinicopathological evidence with hodology — i.e. the pattern of white matter connections between cortical areas — remains relevant today, having foreshadowed the current approach of diffusion tensor tractography (DTI), which reveals white matter bundles in the living brain.

Ramón y Cajal's alumnus Rafael Lorente de Nó (1902–1990) remarked 'in capital letters' that the only really good cytoarchitectonic pictures were those of Campbell, because he was the only cytologist 'who had described facts and only facts', adding that, although Campbell's maps only included large regions, 'they were right', while Brodmann's map was really Campbell's, with 'a few fields more' (Lorente de Nó 1938; Macmillan 2009). Brodmann (1909), as well as Cécil and Oskar Vogt (1919), refined and redefined Campbell's cortical areas and added to them detailed parcelling with sharp borders based on minute cellular differences (Marshall and Magoun 1998). While Brodmann thought mainly as a comparative neuroanatomist, Campbell thought fundamentally in terms of function: 'Not until the ground is prospected and prepared by the physiologist and clinician can the histologist hope to step in and work with any real measure of success' (Campbell 1905b).

One may only speculate about the reasons why the current generation of neuroscientists does not give full credit to Campbell, as well as the other early pioneers of cortical cytoarchitectonics. It could

be because he never had an academic teaching position to generate a 'school'; it might conceivably have something to do with nationalities; it could perhaps be because Campbell used functions — such as visuo-sensory, audito-psychic, olfactory — rather than numbers; and so forth.

Sir Grafton Elliot Smith (1871–1937)

Grafton Elliot Smith (Fig.1) added his own observations based on macroscopic criteria. An Egyptologist and anatomist, Elliot Smith (1907b) published a map of the human cerebral cortex while working in Cairo (Fig. 7). He examined unstained specimens of fresh brain sections cut with a scalpel and examined by means of a magnifying lens. He rediscovered Baillarger's procedure for examining thin slices of fresh cerebral cortex, and he used the differences in the width and distinctness of the stripes of Baillarger for his parcellation scheme. These stripes are recognised as whitish bands, contrasting with the darker cortical grey matter (Fulton 1937; Nieuwenhuys 2013). The intracortical bands were quite distinct in specimens fixed *in situ* by the intravascular injection of formalin, compared with fresh specimens. The optical contrasts pertained to cortical thickness, texture, and colouration. Elliot Smith (1907a, b, 1908) did not assume that the contrasts in appearance necessarily implied either essential distinctions in histological constitution or physiological differences. He based this gross means of localisation and the obvious macroscopic distinctive features on the arrangement of the intracortical white matter — the most distinct being the stria of Gennari in the visual cortex, discovered by Francesco Gennari (1750–1797) and published in the monograph, written in Latin, that granted him immortality (Gennari 1782). He distinguished more than 30 different types of cortical areas in the neopallium, in addition to the areas defined in the limbic system. He analysed the fissural pattern of the human cerebral hemispheres and noticed that most cortical areas had precise relations to the cerebral sulci. He concluded that the characteristics of an area did not gradually or imperceptibly merge into those of neighbouring areas; rather, the structural changes occurred abruptly, such that it became possible to precisely determine the exact boundaries of each area.

Elliot Smith was born on 15 August 1871 in Grafton, New South Wales, to an English schoolmaster and his Welsh wife. He entered medical school at the University of Sydney in 1888 and graduated as M.B. and Ch.M. in 1892 (Wilson 1938). His long-term interest in the nervous system was evidenced by his subscription to *Brain* since his early student years, and the choice of David Ferrier's book *The Functions of the Brain* as the prize for excelling in natural history and physics at the end of his freshman year (Macmillan 2009).

Stimulated by the Scottish physiologist and founder of the medical school at the University of Sydney, Sir Thomas Peter Anderson Stuart (1856–1920), the Scottish anatomist James Thomas Wilson (1861–1945), and the English physiologist Sir Charles James Martin (1866–1955), he studied the brains of monotremes and marsupials for his M.D. thesis (*Anatomy and Histology of the Cerebrum of the Non-Placental Mammal*), which he defended in March 1895. Prompted by the Irish anatomist Alexander Macalister (1844–1919), Elliot Smith continued his research on brain morphology at St. John's College in Cambridge. In 1900, he was appointed chairman of anatomy at the Cairo Medical School, where he also studied paleopathology; 9 years later, he became chairman of anatomy at the University of Manchester, where he continued his anthropological and neuroevolutionary research. In 1919, he was appointed chairman of anatomy at University College London. He was knighted in 1934

by King George V. Elliot Smith died on 1 January 1937 at Broadstairs in Kent, only months following his retirement (Wilson 1938; Walker 1953).

Wilson (1937) listed 389 publications authored by Elliot Smith, including the abstracts of presentations before scientific conferences, and Woollard (1938) provided an outline of Elliot Smith's contributions to neurology. Elliot Smith investigated the organisation and interrelationships of interhemispheric white matter pathways, especially in the parts of the brain associated with olfaction, convinced that the road to the understanding of cortical morphology lay in the study of the commissures. He investigated the development of the corpus callosum and the gradual phylogenetic expansion of the forebrain commissures in the eutherian brain. He noted that, in vertebrate evolution, the increase in size of the cerebral cortex has been two-dimensional, i.e., an increase of area, acquired by folding, oftentimes at loci where different functional areas adjoined; occasionally, folds or sulci occurred in the centre of a uniform functional area. While in Egypt, he devoted attention to the occipital lobe and the problem of cortical localisation. He applied three conceptions: the first was that cerebral fissures and sulci may be axial and so increase a functional area; the second, that they may be limiting and so bound a functional area; and the third, that a particular functional area may be distinguished by an easily recognisable structure.

He demonstrated before the Anatomical Society in 1906 the ease with which one could map out the surface of the human cerebral cortex into a number of areas, each of which presented distinctive features (thickness, colour, arrangement, and density of the intracortical white matter). Elliot Smith (1907a) was able to recognise the differences in thickness and texture of various cortical areas in the occipital lobe and map out the exact extent of each. In a sequel paper (Elliot Smith 1907b), he presented 'preliminary' maps of the entire cerebral cortex (Fig. 7). He noted that, as a rule, sulci did not develop with mathematical precision either at the exact boundary lines of adjoining areas or in the precise axis of any given territory. While fully realising the accuracy of Sherrington's observation that they 'are not reliable as landmarks', each one of the vast majority of the sulci on the hemispheric surface presented a definite causal relationship to certain given cortical areas. The edge of a cortical area might either extend beyond or not reach as far as a sulcus floor. The edge of an area might coincide with a sulcus by mere chance, in other words, in a fortuitous relationship.

He compared his charts with those of Flechsig (1894) on the chronology of myelination and Campbell's (1905b) histological analyses and found a general agreement with them. The work was based on studying more than 200 adult cerebral hemispheres, while the visual area was examined in more than 1,000 hemispheres. Ages included neonatal, 8 years, 12 years, and adults 20 years or older. He recorded an increased thickness (4.00 mm) of the precentral gyrus in the frontal lobe and a decreased thickness (1.75 mm) of the transverse gyri of Heschl in the temporal lobe. He grouped the part of the isle of Reil rostral to the central insular sulcus with frontal areas, based on their close resemblance, although the bands of Baillarger were fainter. At the insular sulcus limitans, the bands became pronounced and formed the inner lining of the frontal part of the operculum (Fig. 7).

Elliot Smith (1908) read a paper before the Anatomical Society of Great Britain that was held in Dublin, recapitulating his views on localisation and the production of a map of the entire cerebral hemispheric surface not very dissimilar from those of Campbell and Brodmann, based on the fissural pattern and his macroscopic examinations of cortical layers. Shortly afterwards, Brodmann (1907, 1908) published similar maps based on histological findings. Elliot Smith (1908) noted that there was a general agreement between the two series of charts — which became more pronounced when it was recalled that Brodmann represented one individual brain, whereas Elliot Smith had shown the average condition of a large series — as well as certain points of disagreement. Brodmann did not admit Elliot Smith's ascribed meaning to the sulci. Nonetheless, the examination of a large series of brains showed that the vast majority of sulci were constantly in close proximity to or at the boundary line between adjoining areas; in other cases, they were in the axis of a given area. Concomitantly, there was considerable variation in the case of certain sulci, especially the calcarine.

Elliot Smith (1904a, b) named the lunate sulcus in the human brain and claimed that it was homologous to the *Affenspalte* ('ape sulcus') of the great apes. Being fully aware of the degree of variability found in the lateral occipital sulci, he emphasised the relatively small number of human specimens that showed a 'primitive' form of the lunate sulcus and used these to bolster his homology argument, against the observations of earlier anatomists.

While the lunate sulcus is reliably present in the ape brain and forms the anterolateral boundary of the primary visual cortex, its presentation in humans is variable; even when present, it does not correspond to a functional region. Modern studies have shown that Elliot Smith's claim that the lunate sulcus in humans is homologous to the *Affenspalte* of other primates was overstated. Using high-resolution MRI, Allen et al. (2006) assessed the presence or absence of the lunate sulcus and its course in the adult human brain. In the vast majority of cases, the lunate sulci, which were identified on the surface of the occipital lobe, actually consisted of smaller segments that converged into an apparently continuous, composite lunate sulcus. Only in three out of 220 examined cerebral hemispheres were continuous lunate sulci found that resembled in form the respective sulcus of apes. In all, the presence of a 'true' lunate sulcus in modern humans is quite rare; a composite lunate sulcus can be identified in about half of cases. Given that the lunate sulcus in humans is not typically associated with the primary visual cortex, it would appear misleading to suggest that the human lunate sulcus is a homologous structure. In rare cases where the striate cortex may extend to a sulcus identified as a lunate, this finding should be best considered as a convergence on the form found in other primates.

In June 1919, Elliot Smith (1919a, b, c) delivered four Croonian Lectures on the evolution of the cerebral cortex. He connected the hippocampus with memory deficits and expanded on the problem of how did the cortex acquire the intellectual functions, as well as on the part played by the hypothalamus and the thalamus. Finally, Elliot Smith had an early foresight regarding the neural underpinnings of consciousness and the central role of the thalamocortical interplay (Marshall and Magoun 1998). He highlighted the importance of the thalamus as a vehicle of evolutionary pressure:

The circulation of the thalamic and cortical currents maintains this constant state of readiness and is a vital and essential part of consciousness and mind...More than thirty years ago, I directed attention to the fact that with the evolution of mammals a new cortical instrument, which I called the neopallium, came into existence, and with its expansion provoked the vastest revolution that ever occurred in the cerebral structure. It came into being to form a receptive organ for fibres coming from the thalamus, whereby touch, vision, hearing and taste — in fact all the non-olfactory senses — secured representation in the cerebral cortex. (Campion and Elliot Smith 1934, pp 24–26)

The return paths from cortex to thalami — the cortico-thalamic paths — are means of maintaining a continuous circulation of neural impulse between the thalamic and the cortex, thus keeping in an active state those ‘engrams’ or ‘schemata’ which form the neural correlates of the mental symbols or concepts which may be employed in any particular phase of consciousness through which we may at any time be passing. Here then is what must indeed at present be regarded only as a working hypothesis, but one which subsequent research may convert into an established theory — the hypothesis that the thalami which Head and Holmes regarded as the central seat of consciousness for the affective aspects of sensation, act also as central propagators of streams of neural impulse to all the ‘engrammic systems’ or ‘neural schemata’ which form the neural bases of our thought processes. (Campion and Elliot Smith 1934, p 107)

Discussion

Brodmann carried Campbell's parcellation scheme further by working on the brains of diverse mammalian species and gradually developing his well-known division of the cerebral cortex into 52 discrete areas, of which 44 are present in the human brain (Brodmann 1909; Garey 2006). Through extensive studies of the comparative anatomy of the cortex, Brodmann provided a broad scientific basis for future systematic research. According to Zilles and Amunts (2010), one of Brodmann's greatest assets was that he indicated phylogenetic homologies among different mammals with regard to cytoarchitectonic areas; thus, he integrated the comparative histological finds into a functional framework.

Campbell's monograph was a monumental achievement, and its eclipse by Brodmann's work seems unjust on several grounds (ffytche and Catani 2005). Campbell worked in comparative isolation, hidden away in a provincial asylum. The works of Campbell and Brodmann (who were actually born only 10 months apart) differ in a key respect: the emphasis given to function. As is implicit in his title, the relation of brain anatomy to brain function was central to Campbell's monograph, and his cortical maps are not labelled by numbers, but by functions, e.g. visuo-sensory, audito-psychic, olfactory, and so forth. Brodmann discussed certain functional and clinicopathological aspects, but the bulk of his book concerned comparative anatomy. Campbell's integrative approach, combining anatomical, pathological, and physiological insights, resonates with modern cognitive neuroscience.

Economo and Koskinas (1925) laid the groundwork for much of the way in which we describe and think about cortical structure to this day. They brought together the concepts of cortical organisation that had been developing over the preceding five decades by Meynert in Vienna, Betz in Kiev, Hammarberg in Sweden, Brodmann and the Vogts in Berlin, and the British scientists Bevan-Lewis and Campbell, and made fundamental discoveries of their own which remain with us today. In the words of anatomist Marion Hines (1889–1982), they 'brought to their study such a refinement, critical ability and thoroughness of observation that their atlas and descriptions will remain the classic for many years to come' (Hines 1934). The late Edward G. Jones (1939–2011) noted that 'the remarkable photomicrographs of Economo and Koskinas probably still represent the most comprehensive set of high resolution images of cortical histology that has ever been assembled' (Jones 2008). The naming of areas by lobe, gyrus, and cytological characteristics that Economo and Koskinas (1925, 2008) introduced 'was done in a systematic manner that we can only regret did not come into customary usage' (Jones 2010), although it was adopted by Percival Bailey (1892–1973) and Gerhardt von Bonin (1890–1979) in Chicago for their studies on the primate brain (Bonin and Bailey 1947; Bonin 1950; Bailey and Bonin 1951).

In appraising the work of Economo and Koskinas (1925), Elliot Smith (1927) judged that the two brain scientists had realised a much needed examination of the various cortical territories and critically compared the results obtained by different methods in compiling their maps. The work represented a

reference and a full account of everything that had been done on the anatomical localisation of the human cortex up to that time, together with a summary of comparative studies, especially those of Brodmann, whose pioneering work was fully reported and duly credited. This enormously laborious investigation marked an epoch in the history of cytoarchitectonics, as the authors did not merely bring to their work enormous patience and superb technical skill; they also dealt with the history and the literature of the subject with rare judgment and impartiality, and in particular a freedom from national bias. In the words of Elliot Smith (1927, p 264):

It can be confidently said that such a survey will not have to be done again, and that this work will become a standard treatise of reference on the topography of the human cerebral cortex...much detailed work will be done in the future on particular regions, perhaps introducing small modifications, but the work as a whole is bound to stand as a permanent achievement.

Commonly, authors use Brodmann maps either to designate cytoarchitectonic areas as such or as a 'shorthand system' to designate some region on the cerebral cortical *surface* (DeMyer 1988). In imaging studies, investigators macroscopically extrapolate Brodmann projection maps on the Atlas of Talairach and Tournoux (1988), rather than being based on real microscopic cytoarchitectonic criteria. Such specifications of Brodmann areas are inappropriate and may lead to erroneous results in delineating specific cortical regions, which may in turn lead to erroneous hypotheses with regard to the involvement of particular brain systems in normal and pathological situations (Uylings et al. 2005). On the contrary, the sectioning method of Economo and Koskinas (1925, 2008), whereby each gyrus is consistently dissected into blocks *always perpendicular to the gyral surface*, be it dome, wall or sulcus floor, virtually solves the generalised mapmaker's problem of flattening nonconvex polyhedral surfaces (Schwartz et al. 1989), one of the commonest problems at the epicentre of cortical research.

In their seminal work on cortical localisation in humans, Wilder G. Penfield (1891–1976) of McGill University and his colleagues, including Edwin B. Boldrey (1906–1988), Herbert H. Jasper (1906–1999), Theodore B. Rasmussen (1910–2002), Lamar Roberts (1919–1978), and Kenneth W. E. Paine (1921–1994), systematically studied the effects of epileptic discharge, the direct stimulation of select cortical areas, and postoperative behavioural effects, based on a long series of neurosurgical operations carried out on patients under local anaesthesia. Penfield and Boldrey (1937) indicated a certain overlap of sites in the anterolateral region of the human precentral cortex that elicit mastication and deglutition. Penfield and Rasmussen (1950) resumed the idea of the sensorimotor cortex on the grounds of motor and somatosensory responses from both the postcentral and precentral gyrus. Penfield and Jasper (1954) provided the first description in the human brain of the functionally-defined secondary somatosensory cortex (SII) in the parietal operculum, within the lateral fissure, and emphasised the somatotopic organisation of the hemibody. Like Harvey Cushing, Penfield appreciated

the value of keeping detailed patient records and repeatedly analysed them over time (Rasmussen 1977). Accordingly, Penfield and Paine (1955) reported the outcome of cortical excision operations performed over six years on 234 patients to contain recurring seizures, and addressed the position of the epileptogenic focus, the EEG detection of abnormalities in interictal periods, and the pathology of the lesion.

In all those studies, in referring to cortical areas, Penfield adopted the Brodmann system of numbers. As Penfield's work became a classic in cortical localisation research and amply cited afterwards, one may speculate that this was one plausible reason why historically the usage of Brodmann areas endured for most of the 20th century over the Economo-Koskinas nomenclature. One other reason was that the original Atlas of Economo and Koskinas was only printed in a limited run of 100 sets that mostly went to academic libraries, and some of these sets were apparently lost or destroyed during the Second World War. With an English edition of the Economo-Koskinas Atlas becoming available for the first time in 2008, the trend may eventually be reversed. The cytoarchitectonic criteria of Economo and Koskinas and their system of 107 cortical areas confer the advantage of a more detailed parcellation scheme, despite the traditional familiarity of neuroscientists with Brodmann area numbers, particularly with regard to modern studies on functional localisation (Triarhou 2007a, 2012, 2013). The Economo-Koskinas classification, with Brodmann area correlations (Triarhou 2007b), is now an option for any modern researcher who opts to adopt it.

With regard to human myeloarchitectonics, there is a particularly notable atlas and accompanying text by Theodor Kaes (1852–1913) of Hamburg. Kaes (1907) used the Weigert method for myelinated fibres and provided detailed measurements of cortical layer thickness from birth to 97 years of age. He divided the cortex into an 'outer main zone', comprising layers I–III, and an underlying 'inner main zone', consisting of layers IV–VI. Different cortical areas had different rates of growth; he reported marked changes in the outer main zone of the frontal lobe from 20 to 45 years of age, as well as much fewer fluctuations in the visual cortex. He also described the white matter line that forms the outer margin of layer III; this band was independently described by Vladimir M. Bekhterev (1857–1927) of Saint Petersburg and is eponymously known as the 'Kaes–Bekhterev stripe' (Fulton 1937). Kaes reckoned that the outer main zone played a central role in the development of individuality and intellect. Finally, Vogt (1903, 1906, 1910, 1911; Vogt and Vogt 1919) executed the preparatory works on the knowledge of myeloarchitectonics of utmost value until today.

During the Interwar period, Maksymilian Rose (1883–1937) in Vilnius provided his own account of cytoarchitectonics of the human cerebral cortex by combining the designation schemes of Brodmann with those of Economo and Koskinas (Rose 1935). Rose worked under Brodmann in Tübingen in 1912 and under Vogt in Berlin in 1925 (Pekacka-Falkowska et al. 2017). His original work involved cerebral anatomy and cytology in rodents and humans, with a strong emphasis on ontogeny, phylogeny, and pathology, and a synthesis of cytoarchitectonics with myeloarchitectonics. Like Brodmann and Economo, Rose also died in his fifties, depriving the scientific community of

further promising discoveries.

The postwar ‘modern era’ is marked by the work of Friedrich Sanides (1914–1984) in Frankfurt, who revived the interest in cortical architectonics with a totally different viewpoint that began to be appreciated by the late 1960s (Pandya 1991). Sanides (1962, 1972) pursued architectonics as a fundamental approach to brain evolution and advanced a notion of cortical architecture with the progressive differentiation of neuronal elements as the main theme. He based his research on the concept of a dual origin of the cerebral cortex as a basis for understanding the organisation of cortical and subcortical connections. While Vogt and Vogt (1919) had already spoken of ‘areal gradations’, Sanides (1962, 1964), by combining cytoarchitectonics with myeloarchitectonics, placed emphasis on the transition regions that accompany ‘streams’ of neocortical regions derived from paleocortical and archicortical sources (Pandya and Sanides 1973). He also showed that the laminar origin of long intrahemispheric connections is associated with those cytoarchitectonic features from less to more differentiated cortical areas (Sanides 1970).

By presenting a new method of mapping cortical areas based on myelin content as revealed by T₁- and T₂-weighted MRI, Glasser and Van Essen (2011) found an agreement between the gradients of myelin maps and those of cytoarchitectonically defined cortical areas. Overall, the primary and the early unimodal association cortices were heavily myelinated, while the higher, multimodal association cortices were more lightly myelinated. The general myelin pattern correlated with the ontogeny of subcortical white matter, the phylogenetic expansion of the cerebral cortex, and the maps of neuronal density in non-human primates. Glasser and Van Essen (2011) concluded that multimodal comparisons of myelin maps with resting state fMRI, coupled with the rapidly growing body of morphological and functional information, may help to accurately parcellate the complex cortical mosaic.

Dinse et al. (2015) instigated a modern concordance of cytoarchitectonic and myeloarchitectonic boundaries by presenting a novel model in an effort to bridge the gap between cortical histology and MRI macroanatomy. They modelled laminar myelin patterns in the human cerebral cortex in magnetic resonance images on the basis of known architectures and estimated intracortical contrast visible in quantitative ultra-high resolution magnetic resonance images in specific cortical areas. The identified specific signatures may help to study the spatial distribution of myelin values in the cortical grey matter across the life-span.

Scholtens et al. (2015) directly compared the measurements of Economo and Koskinas (1925; Economo 2009) of the thickness of cortical areas with current high-resolution MRI estimates from the Human Connectome Project in order to assess macroscale cortical organisation *in vivo*. Such a cross-correlation showed a strong positive association between group-averaged MRI measurements of cortical thickness and the histological data of Economo and Koskinas. These findings indicate that, by linking today’s state-of-the-art T₁-weighted imaging to the classical anatomical studies, MRI can be a valid method for the *in vivo* assessment of structural cortical attributes. Moreover, translating detailed

histological data to an MRI framework provides new opportunities to test algorithms for automated grey-white matter segmentations.

Going a step further, Scholtens et al. (2018) made the classical cytoarchitectonic data accessible and relatable to *in vivo* neuroimaging data by constructing a digital Economo–Koskinas atlas that is compatible with FreeSurfer software. The authors manually segmented the classical Economo–Koskinas atlas onto individual T₁ scans to create the digital version. Bringing the cytoarchitectonic atlas of Economo and Koskinas (1925, 2008) in stereotactic space covers the entire cortical surface and offers an additional opportunity to directly relate mapped regions back to the morphological data on which the mapping was based, information which is not accessible in the case of the Brodmann areas. Furthermore, the meticulous layer-specific measurements of nerve cell size, density, and laminar breadth that Economo and Koskinas generated can be applied to modern neuroimaging studies, for example, by comparing MRI-based and histological cortical thickness or by relating functional connectivity profiles to layer-wise neuron size or cortical type. The implementation of the FreeSurfer Economo–Koskinas atlas into existing magnetic resonance processing pipelines may facilitate further incorporation of normal cytoarchitectonic data into imaging studies.

Pandya et al. (2015) undertook a comprehensive work covering the dual nature of the organisation of the cytoarchitecture and connections of the cerebral cortex. These authors established the evolutionary origins of the cortex and systematically analysed common principles underlying the structure and connections of sensory and motor systems; they further described the frontal, limbic, and multimodal association areas, as well as long fibre pathways, and combined anatomical research with experimental findings, clinical observations, and neuroimaging data.

In his most recent atlas, Petrides (2019) provided a comprehensive identification of cerebral gyri and sulci of the cerebral cortex on the average asymmetrical ‘Montreal Neurological Institute’ brain, using the nomenclature of Economo and Koskinas (1925, 2008), as well as recent data from multiple research groups. In establishing the location of cortical areas, he consulted several sources, including the cytoarchitectonic maps of Brodmann, Economo and Koskinas, and Sanides, as well as the modern schemes of the Allen Institute, the Oskar Vogt Institute for Brain Research, and his own group at McGill University. Given that the maps of cortical areas, which are based on resting-state connectivity depend on vascular responses in fMRI, Petrides relied primarily on cytoarchitectonic criteria to identify gyral and sulcal morphology.

In particular, it has become possible with MRI to accurately differentiate between the morphological details of the diagonal and the anterior ascending sulcus of the lateral fissure in the posterior ventrolateral frontal cortex, in relation to the pars opercularis and the pars triangularis of the anterior language region in the dominant human cerebral hemisphere (Sprung-Much and Petrides 2018). Local sulcal patterns seem to affect functional activity in the ventromedial prefrontal cortex as well, which is a key region underpinning decision-making and value-coding processes, and also one of the main hubs of the so-called ‘Default Mode Network’ that is classically activated during the resting

state (Lopez-Persem et al. 2019).

Using fMRI, Amiez and Petrides (2018) have analysed gradients in the functional organisation of the lateral frontal cortex and its sulci that reflect a hierarchical organisation of action control. In primates, ventrolateral and dorsomedial frontal neocortical areas control vocalisations. Loh et al. (2020) found that ventrolateral area 44, a key component of Broca's language production region, is involved in the cognitive selection of orofacial, speech, and non-speech vocal responses, and the midcingulate cortex is involved in the analysis of speech and non-speech vocal feedback that drives the adaptation of such responses. On the other hand, the additional recruitment of area 45 and the presupplementary motor area is also necessary for the cognitive selection of speech vocal information in the language dominant hemisphere of the human brain. Thus, functional imaging may even shed light into the evolutionary changes that enabled speech production in humans.

The 'Allen Atlas' of the adult human brain is multimodal and comprises a comprehensive 'all genes-all structures' dataset of gene expression and complementary transcription neuroanatomical data. It is freely available (www.brain-map.org), and aims to accelerate basic and clinical research on the normal human brain and its state in diseases (Shen et al. 2012). Brain-wide variations are reflected in the distribution of the major cell classes, such as neurons, their discrete subtypes and synaptic patterns, as well as astrocytes, oligodendrocytes, and brain macrophages (Hawrylycz et al. 2012). To further unravel the functional cytoarchitecture of the human brain, Ding et al. (2016) integrated, into the existing Allen gene expression atlases, a new digital atlas, also publicly accessible (www.brainspan.org), which incorporates neuroimaging (MRI and DWI), and annotated cytoarchitectonic and chemoarchitectonic structures demonstrated by Nissl-stained and immunocytochemically-labelled preparations that are transferred onto the matching MRI dataset. The delineations of cortical gyri, sulci, and modified Brodmann areas link the macroscopic to the microscopic cytoarchitectonic parcellations.

To comply with variability among individuals, there is a necessity for cortical maps to be 'probabilistic', because area boundaries and functional foci are highly variable. Moreover, a multi-level approach may be necessary that would include repetitive modular-like structures, micro-maps, and meso-maps in two and three dimensions, extending from cortical areas to individual neurons and subcellular molecules (Amunts and Zilles 2015). Today's cytoarchitectonic brain research aims at providing a microstructural frame for data produced by the multimodal analysis of the cortex; for example, the mapping of multiple receptor types would offer a multimodal perspective of the structural, functional and molecular organisation of the cerebral hemispheres and could serve as a reference for pharmacological and clinical studies of brain disorders (Zilles and Amunts 2010). The 'Jülich 3D Brain Atlas' (Amunts et al. 2020) atlas comprises cortical and subcortical cytoarchitectonic area maps, and accounts for variations among between individual brains. It is openly available (www.jubrain.fz-juelich.de) to provide for neuroimaging, modelling and simulation studies, and it can be connected to other brain atlases.

Wagstyl et al. (2020) presented the first whole-brain quantitative three-dimensional (3D) laminar atlas of the human cerebral cortex, derived from the 3D BigBrain histological atlas at 20- μm isotropic resolution, by using a convolutional neural network to segment the cortical layers in both cerebral hemispheres. The overall pattern of thickness was consistent with the data of Economo and Koskinas (1925; Economo 2009). Across sensory processing hierarchies, such as the visual, somatosensory, and auditory cortices, there was a gradient of cortical thickness increase, primarily driven by layers III, V, and VI. On the other hand, motor-frontal regions showed an inverse pattern, with decreases in overall and pyramidal layer thickness from motor to frontal association cortices. These data may provide a link between cellular morphology, cortical lamination and thickness, and, hopefully, morphofunctional correlations.

Nevertheless, the key to any functional outcome is the activity at the synapse. It is not merely helpful to understand the nano-scale organisation of the brain for insight into its function; it is a requisite (Südhof 2017). Today's imaging methods, including diffusion-tensor and diffusion-spectrum imaging (DTI and DSI, respectively), although they offer the promise of identifying at high resolution the fibre bundles in the white matter that proceed to and from cortical areas, do not reveal the synaptic terminations of axons in the grey matter of the cerebral hemispheres (Jones 2008). Moreover, axon growth and synaptogenesis occur along with gyrification, such that the laminar and regional cytoarchitectures are intimately linked to cortical connectomics and thalamocortical projections (Karten 2015).

The undeniable actuality is that synaptic connectivity in the cerebral hemispheres occurs in the cortical layers of the grey matter (Jones 2008). Tracking white matter axons alone, without reference to their exact neuronal origin, trajectory, and terminations, is of little use. In exploring the anatomical underpinnings of cognition, the way forward is our future ability to accurately determine where axons emanate and where they end in the human cerebral cortex. Important evidence derives from studies in monkeys that correlate histological tract tracing by autoradiography with the results from DTI and DSI analyses that offer the ability to resolve crossing fibres at the scale of single MRI voxels (Schmahmann and Pandya 2006; Schmahmann et al. 2007). Such comparisons indirectly cast light on the organisation of the human brain in health and disease.

As a technique that allows a correlation between structure and function, fMRI has limitations insofar as the measurements are not in real time, and spatial resolution only recently reached the mm level. Even the hypothetical development of a technique, that would conceivably and non-invasively image neural activity at a spatial resolution of 1 mm and at a temporal resolution of 1 msec, would still appear coarse relative to the size of the nerve cell body (5–100 μm) and the synaptic gap (20–40 nm) (Hougan and Altevogt 2008). As the necessity emerges to move from brain localisation to connectivity imaging, methods such as high-resolution two-photon imaging are used to visualise functionally-defined afferent inputs on cortical dendritic spines in vivo with single-synapse resolution (Chen et al. 2011). The relation of structure to function in synaptic cortical circuits is studied by combining

network anatomy with in vivo physiology. For example, a functional property of specific cortical neurons can be characterised by two-photon calcium imaging, and a portion of the local interconnections of such neurons can be traced with large-scale electron microscopy of serial thin sections (Bock et al. 2011). Thus, it is becoming possible to delve into hitherto intractable neurobiological problems through methodological advances that allow us to combine neuronal wiring with functional imaging (Briggman et al. 2011) through a high-speed reconstruction of neurite connectivity, while performing reliable analyses of large neuroanatomical datasets (Helmstaedter et al. 2011).

To sum up, despite all the extensive studies of the human brain, direct evidence and visualisation of anatomical connections, from origin to termination, is extremely limited, and our knowledge on connectional neuroanatomy largely derives from studies in experimental animals, such as rats, cats, and monkeys (Rushmore et al. 2020). The homological approach, in other words the comparative study of structural relationships in non-human species, remains the primary source of our knowledge, and a cornerstone of human cerebral anatomy. In the current trend of functional neuroimaging, the awareness of the strong reliance of human neuroanatomy on data gathered from other animal species is fundamental. In parallel with the rapid evolution of new techniques for studying the structural connectivity of the human brain, Rushmore et al. (2020) highlight the fact that, at present, it is the homologically-based atlases, in conjunction with diffusion-based MRI tractography, that offer a systematic framework to understand the circuit diagrams of the human brain.

Acknowledgment

The author wishes to thank the anonymous reviewers for their critical suggestions that led to an improved manuscript.

Funding

No Funding was received towards this work.

Competing interests

The author reports no competing interests.

References

- Allen JS, Bruss J, Damasio H (2006) Looking for the lunate sulcus: a magnetic resonance imaging study in modern humans. *Anat Rec* 288A: 867–876. <https://doi.org/10.1002/ar.a.20362>
- Amiez C, Petrides M (2018) Functional rostro-caudal gradient in the human posterior lateral frontal cortex. *Brain Struct Funct* 223: 1487–1499. <https://doi.org/10.1007/s00429-017-1567-z>
- Amunts K, Mohlberg H, Bludau S, Zilles K (2020) Jülich-Brain: a 3D probabilistic atlas of the human brain's cytoarchitecture. *Science* 369: 988–992. <https://doi.org/10.1126/science.abb4588>
- Amunts K, Zilles K (2015) Architectonic mapping of the human brain beyond Brodmann. *Neuron* 88: 1086–1107. <https://doi.org/10.1016/j.neuron.2015.12.001>
- Baillarger JGF (1840) Recherches sur la structure de la couche corticale des circonvolutions du cerveau. *Mém Acad R Méd* 1840; 8: 149–183
- Banovac I, Sedmak D, Džaja D, Jalšovec D, Jovanov Milošević N, Rašin MR, Petanjek Z (2019) Somato-dendritic morphology and axon origin site specify von Economo neurons as a subclass of modified pyramidal neurons in the human anterior cingulate cortex. *J Anat* 235: 651–669. <https://doi.org/10.1111/joa.13068>
- Berlin R (1858) Beiträge zur Strukturlehre der Grosshirnwindungen. A. E. Junge, Erlangen
- Bevan-Lewis W (1878) On the comparative structure of the cortex cerebri. *Brain* 1: 79–96. <https://doi.org/10.1093/brain/1.1.79>
- Bock DD, Allen Lee W-C, Kerlin AM, Andermann ML, Hood G, Wetzel AW, Yurgenson S, Soucy ER, Kim HS, Reid RC (2011) Network anatomy and *in vivo* physiology of visual cortical neurons. *Nature* 471: 177–182. <https://doi.org/10.1038/nature09802>
- Bonin G von (1953) Alfred Walter Campbell (1868–1937). In: Haymaker W, Baer KA (eds) *The founders of neurology*. Charles C Thomas, Springfield, IL, pp 16–18
- Briggman KL, Helmstaedter M, Denk W (2011) Wiring specificity in the direction-selectivity circuit of the retina. *Nature* 471: 183–188. <https://doi.org/10.1038/nature09818>
- Brodmann K (1907) Bemerkungen über die Fibrillogenie und ihre Beziehungen zur Myelogenie mit besonderer Berücksichtigung des Cortex cerebri. *Neurol Cbl* 26: 338–349
- Brodmann K (1908) Beiträge zur histologischen Lokalisation der Grosshirnrinde. VI. Mitteilung. Die Cortexgliederung des Menschen. *J Psychol Neurol (Leipz)* 10: 231–246
- Brodmann K (1909) Vergleichende Lokalisationslehre der Grosshirnrinde in ihren Prinzipien dargestellt auf Grund des Zellenbaues. Johann Ambrosius Barth, Leipzig
- Brodmann K (1914) Physiologie des Gehirns. In: Bruns P von (ed) *Neue Deutsche Chirurgie*, Bd. 11, I. Teil. Ferdinand Enke, Stuttgart, pp 85–426
- Campbell AW (1902) Histological features of the regions of the cortex in anthropoids, with special reference to the varieties of medullated fibres and their topographical relations in the cortex. *Lancet* 160: 527. [https://doi.org/10.1016/S0140-6736\(01\)54503-1](https://doi.org/10.1016/S0140-6736(01)54503-1)
- Campbell AW (1904a) Histological studies on cerebral localisation. *Proc R Soc Lond* 1904a; 72: 488–

492. <https://doi.org/10.1098/rspl.1903.0077>
- Campbell AW (1904b) Histological studies on the localisation of cerebral function. *J Ment Sci* 50: 651–662. <https://doi.org/10.1192/bjp.50.211.651>
- Campbell AW (1905a) Further histological studies on the localisation of cerebral function: the brains of *Felis*, *Canis*, and *Sus* compared with that of *Homo*. *Proc R Soc Lond* 74: 390–392. <https://doi.org/10.1098/rspl.1904.0131>
- Campbell AW (1905b) Histological studies on the localisation of cerebral function. At the University Press, Cambridge
- Campbell AW (1916) Histological studies on the localisation of cerebral function—the brain of the gorilla. *Rep Pathol Lab Lunacy Dept N S W Govt* 3: 20–35
- Campion GG, Elliot Smith G (1934) The neural basis of thought. Kegan Paul, Trench, Trubner and Company, London
- Chen X, Leischner U, Rochefort NL, Nelken I, Konnerth A (2011) Functional mapping of single spines in cortical neurons *in vivo*. *Nature* 475: 501–505. <https://doi.org/10.1038/nature10193>
- DeFelipe J, Jones EG (1988) Cajal on the cerebral cortex: an annotated translation of the complete writings. Oxford University Press, New York
- DeMyer W (1988) Neuroanatomy. Harwal Publishing Company, Malvern, PA
- Ding SL, Royall JJ, Sunkin SM, Ng L, Facer BA, Lesnar P, Guillozet-Bongaarts A, McMurray B, Szafer A, Dolbeare TA, Stevens A, Tirrell L, Benner T, Caldejon S, Dalley RA, Dee N, Lau C, Nyhus J, Reding M, Riley ZL, Sandman D, Shen E, van der Kouwe A, Varjabedian A, Wright M, Zöllei L, Dang C, Knowles JA, Koch C, Phillips JW, Sestan N, Wohnoutka P, Zielke HR, Hohmann JG, Jones AR, Bernard A, Hawrylycz MJ, Hof PR, Fischl B, Lein ES (2016) Comprehensive cellular-resolution atlas of the adult human brain. *J Comp Neurol* 524: 3127–3481. <https://doi.org/10.1002/cne.24080>
- Dinse J, Härtwich N, Waehnert MD, Tardif CL, Schäfer A, Geyer S, Preim B, Turner R, Bazinet P-L. (2015) A cytoarchitecture-driven myelin model reveals area-specific signatures in human primary and secondary areas using ultra-high resolution in-vivo brain MRI. *NeuroImage* 114: 71–87. <https://doi.org/10.1016/j.neuroimage.2015.04.023>
- Eadie MJ (1981) A. W. Campbell: Australia's first neurologist. *Clin Exp Neurol* 17: 27–35
- Economo C von (1926) Eine neue Art Spezialzellen des Lobus cinguli und Lobus insulae. *Z Gesamte Neurol Psychiatr (Berl)* 100: 706–712. <https://doi.org/10.1007/BF02970950>
- Economo C von (2009) Cellular structure of the human cerebral cortex (transl. and edited by L. C. Triarhou). Karger, Basel
- Economo C von, Koskinas GN (1925) Die Cytoarchitektonik der Hirnrinde des erwachsenen Menschen: Textband mit 162 zum Teil farbigen Textabbildungen. Julius Springer, Wien-Berlin
- Economo C von, Koskinas GN (2008) Atlas of Cytoarchitectonics of the adult human cerebral cortex (transl. and edited by L. C. Triarhou). Karger, Basel, 2008

- Elliot Smith G (1904a) The so-called “Affenspalte” in the human (Egyptian) brain. *Anat Anz (Jena)* 24: 74–83
- Elliot Smith G (1904b) The morphology of the occipital region of the cerebral hemisphere in man and the apes. *Anat Anz (Jena)* 24: 436–451
- Elliot Smith G (1907) A new topographical survey of the human cerebral cortex, being an account of the distribution of the anatomically distinct cortical areas and their relationship to the cerebral sulci. *J Anat Physiol (Lond)* 41: 237–254
- Elliot Smith G (1908) Localization of the human cerebral cortex. *Br Med J* 2: 836.
<https://doi.org/10.1136/bmj.2.2490.836>
- Elliot Smith G (1919a) Croonian lectures on the significance of the cerebral cortex: lecture I. *Br Med J* 1: 758. <https://doi.org/10.1136/bmj.1.3051.758>
- Elliot Smith G (1919b) Croonian lectures on the significance of the cerebral cortex: lectures II and III. *Br Med J* 1: 796–7. <https://doi.org/10.1136/bmj.1.3052.796>
- Elliot Smith G (1919c) Croonian lectures on the significance of the cerebral cortex: lecture IV. *Br Med J* 2: 11–2. <https://doi.org/10.1136/bmj.2.3053.11-a>
- Elliot Smith G (1927) Die Cytoarchitektonik der Hirnrinde des erwachsenen Menschen (Review). *J Anat (Lond)* 61: 264–266
- ffytche DH, Catani M (2005) Beyond localization: from hodology to function. *Phil Trans R Soc Lond B* 360: 767–779. <https://doi.org/10.1098/rstb.2005.1621>
- Flechsig PE (1894) *Gehirn und Seele*. Veit und Compagnie, Leipzig
- Foley PB, Storey CE (2010) History of neurology in Australia and New Zealand. *Handb Clin Neurol* 95: 781–800. [https://doi.org/10.1016/S0072-9752\(08\)02148-9](https://doi.org/10.1016/S0072-9752(08)02148-9)
- Ford E (1979) Campbell, Alfred Walter (1868–1937). In: Nairn B, Serle G (eds) *Australian dictionary of biography*, vol. 7. Melbourne University Press, Carlton, Victoria.
<http://adb.anu.edu.au/biography/campbell-alfred-walter-5481/text9317>. Accessed 3 June 2020
- Fulton JF (1937) A note on Francesco Gennari and the early history of cytoarchitectural studies of the cerebral cortex. *Bull Inst Hist Med* 5: 895–913
- Fulton JF (1938) Alfred Walter Campbell, M.D., Ch.M., 1868–1937. *Arch Neurol Psychiatry (Chic)* 40: 566–568. <https://doi.org/10.1001/archneurpsyc.1938.02270090160010>
- Garey LJ (2006) *Brodmann’s localisation in the cerebral cortex*. Springer Science, New York
- Gennari F (1782) *De peculiari structura cerebri nonnullisque ejus morbis*. Regio Typographeo, Parma
- Glasser MF, Van Essen DC (2011) Mapping human cortical areas *in vivo* based on myelin content as revealed by T1- and T2-weighted MRI. *J Neurosci* 31: 11597–616.
<https://doi.org/10.1523/JNEUROSCI.2180-11.2011>
- Grünbaum ASF, Sherrington CS (1902) Observations on the physiology of the cerebral cortex of some of the higher apes. (Preliminary communication). *Proc R Soc Lond* 69: 206–209.
<https://doi.org/10.1098/rspl.1901.0100>

- Grünbaum ASF, Sherrington CS (1904) Observations on the physiology of the cerebral cortex of the anthropoid apes. *Proc R Soc Lond* 72: 152–155. <https://doi.org/10.1098/r SPL.1903.0033>
- Hammarberg C (1890a) Atrophie und Sklerose des Kleinhirns. *Nord Med Arkiv* (Stockholm) 22(23): 1–39. <https://doi.org/10.1111/j.0954-6820.1890.tb00915.x>
- Hammarberg C (1890b) Atrophie et sclérose du cervelet. *Nord Med Arkiv* (Stockholm) 22(28): 3–5. <https://doi.org/10.1111/j.0954-6820.1890.tb00918.x>
- Hammarberg C (1893) Studier öfver idiotiens klinik och patologi jämte undersökningar af hjärnbarkens normala anatomi, med 7 planscher. Almqvist och Wiksells, Uppsala
- Hammarberg C (1895) Studien über Klinik und Pathologie der Idiotie nebst Untersuchungen über die normale Anatomie der Hirnrinde, mit Sieben Tafeln (transl. by W. Berger and edited by S. E. Henschen). E. Berling, Uppsala
- Hawrylycz MJ, Lein ES, Guillozet-Bongaarts AL, Shen EH, Ng L, Miller JA, van de Lagemaat LN, Smith KA, Ebbert A, Riley ZL, Abajian C, Beckmann CF, Bernard A, Bertagnolli D, Boe AF, Cartagena PM, Chakravarty MM, Chapin M, Chong J, Dalley RA, David Daly B, Dang C, Datta S, Dee N, Dolbeare TA, Faber V, Feng D, Fowler DR, Goldy J, Gregor BW, Haradon Z, Haynor DR, Hohmann JG, Horvath S, Howard RE, Jeromin A, Jochim JM, Kinnunen M, Lau C, Lazarz ET, Lee C, Lemon TA, Li L, Li Y, Morris JA, Overly CC, Parker PD, Parry SE, Reding M, Royall JJ, Schulkin J, Sequeira PA, Slaughterbeck CR, Smith SC, Sodt AJ, Sunkin SM, Swanson BE, Vawter MP, Williams D, Wohnoutka P, Zielke HR, Geschwind DH, Hof PR, Smith SM, Koch C, Grant SGN, Jones AR (2012) An anatomically comprehensive atlas of the adult human brain transcriptome. *Nature* 489: 391–399. <https://doi.org/10.1038/nature11405>
- Haymaker W, Baer KA (1953) *The founders of neurology*. Charles C Thomas, Springfield, IL
- Haymaker W, Schiller F (1970) *The founders of neurology*, 2nd edn. Charles C Thomas, Springfield, IL
- Helmstaedter M, Briggman KL, Denk W (2011) High-accuracy neurite reconstruction for high-throughput neuroanatomy. *Nat Neurosci* 14: 1081–1088. <https://doi.org/10.1038/nn.2868>
- Hof PR, Van der Gucht E. (2007) Structure of the cerebral cortex of the humpback whale, *Megaptera novaeangliae* (Cetacea, Mysticeti, Balaenopteridae). *Anat Rec* (Hoboken) 290: 1–31. <https://doi.org/10.1002/ar.20407>
- Hougan M, Altevogt B (2008) *From molecules to minds—challenges for the 21st century: workshop summary*. National Academies Press, Washington, DC
- Jones EG (2010) Cellular structure of the human cerebral cortex (review). *Brain* 133: 945–946. <https://doi.org/10.1093/brain/awn268>
- Kaes T (1907) *Die Grosshirnrinde des Menschen in ihren Massen und in ihrem Fasergehalt: ein gehirnanatomischer Atlas mit erläuterndem Text und schematischer Zeichnung*. Gustav Fischer, Jena

- Karten HJ (2015) Vertebrate brains and evolutionary connectomics: on the origins of the mammalian “neocortex”. *Phil Trans R Soc Lond B Biol Sci* 370: 20150060.
<https://doi.org/10.1098/rstb.2015.0060>
- Levertin A (1911) Carl Hammarberg. In: Hildebrand A (ed) *Svenskt porträttgalleri XIII: läkarekåren*. Hasse W. Tullbergs Förlag, Stockholm, p 177
- Lindberg BS (2013) Salomon Eberhard Henschen: en biografi. Universitetsbibliotek / Elanders Sverige AB, Uppsala. <http://urn.kb.se/resolve?urn=urn:nbn:se:uu:diva-208883>. Accessed 12 June 2020
- Loh KK, Procyk E, Neveu R, Lamberton F, Hopkins WD, Petrides M, Amiez C (2020) Cognitive control of orofacial motor and vocal responses in the ventrolateral and dorsomedial human frontal cortex. *Proc Natl Acad Sci USA* 117: 4994–5005. <https://doi.org/10.1073/pnas.1916459117>
- Lopez-Persem A, Verhagen L, Amiez C, Petrides M, Sallet J (2019) The human ventromedial prefrontal cortex: sulcal morphology and its influence on functional organization. *J Neurosci* 39: 3627–3639. <https://doi.org/10.1523/JNEUROSCI.2060-18.2019>
- Lorente de Nó R (1938) Architectonics and structure of the cerebral cortex. In: Fulton JF (ed) *Physiology of the nervous system*. Oxford University Press, New York, pp 291–327
- Macmillan M (2009) Evolution and the neurosciences down-under. *J Hist Neurosci* 18: 150–196.
<https://doi.org/10.1080/09647040701662377>
- Macmillan M (2014) Alfred Walter Campbell and the visual functions of the occipital cortex. *Cortex* 56: 157–81. <https://doi.org/10.1016/j.cortex.2012.10.007>
- Marshall LH, Magoun HW (1998) *Discoveries in the human brain: neuroscience prehistory, brain structure, and function*. Humana Press, Totowa, NJ
- Meynert T (1867/1868) Der Bau der Gross-Hirnrinde und seine örtlichen Verschiedenheiten, nebst einem pathologisch-anatomischen Corollarium. *Vierteljahresschr Psychiatr* 1: 77–93, 198–217; 2: 88–113
- Mott FW, Schuster E, Sherrington CS (1911) Motor localisation in the brain of the Gibbon, correlated with a histological examination. *Proc R Soc Lond B* 84: 67–74.
<https://doi.org/10.1098/rspb.1911.0047>
- Nieuwenhuys R (2013) The myeloarchitectonic studies on the human cerebral cortex of the Vogt-Vogt school, and their significance for the interpretation of functional neuroimaging data. In: Geyer S, Turner R (eds) *Microstructural parcellation of the human cerebral cortex*. Springer-Verlag, Berlin, pp 55–125. https://doi.org/10.1007/978-3-642-37824-9_3
- Pandya DN (1991) Friedrich Sanides (1914–1984). *Cortex* 27: 307–309.
[https://doi.org/10.1016/S0010-9452\(13\)80135-9](https://doi.org/10.1016/S0010-9452(13)80135-9)
- Pandya D, Petrides M, Seltzer B, Cipolloni PB (2015) *Cerebral cortex: architecture, connections, and the dual origin concept*. Oxford University Press, New York
- Pandya DN, Sanides F (1973) Architectonic parcellation of the temporal operculum in rhesus monkey

- and its projection pattern. *Z Anat Entwicklungsgesch* 139: 127–161
- Pekacka-Falkowska K, Owecki MK, Pekacka AM (2017) Maksymilian Rose (1883–1937). *J Neurol* 264: 2509–2510. <https://doi.org/10.1007/s00415-017-8592-y>
- Penfield W, Boldrey E (1937) Somatic motor and sensory representation in the cerebral cortex of man as studied by electrical stimulation. *Brain* 60: 389–443. doi: 10.1093/brain/60.4.389.
- Penfield W, Jasper H (1954) *Epilepsy and functional anatomy of the human brain*. Little, Brown and Company, Boston
- Penfield W, Paine K (1955) Results of surgical therapy for focal epileptic seizures. *Can Med Assoc J* 73: 515–553. PMID: 13260990
- Penfield W, Rasmussen TB (1950) *The cerebral cortex of man: a clinical study of localization of function*. MacMillan, New York
- Penfield W, Roberts L (1959) *Speech and brain mechanisms*. Princeton University Press, Princeton, NJ
- Petrides M (2019) *Atlas of the morphology of the human cerebral cortex on the average MNI brain*. Academic Press, London
- Raghanti MA, Spurlock LB, Treichler FR, Weigel SE, Stimmelmayer R, Butti C, Thewissen JG, Hof PR (2015) An analysis of von Economo neurons in the cerebral cortex of cetaceans, artiodactyls, and perissodactyls. *Brain Struct Funct* 220: 2303–2314. <https://doi.org/10.1007/s00429-014-0792-y>
- Ramón y Cajal S (1899a) Estudios sobre la corteza cerebral humana. I. Corteza visual. *Rev Trim Microgr (Madr)* 4: 1–63
- Ramón y Cajal S (1899b) Estudios sobre la corteza cerebral humana. II. Estructura de la corteza motriz del hombre y mamíferos superiores. *Rev Trim Microgr (Madr)* 4: 117–200
- Ramón y Cajal S (1899–1904) *Textura del sistema nervioso del hombre y de los vertebrados*, 3 vols. Nicolás Moya, Madrid
- Rasmussen TB (1977) Wilder Penfield: his legacy to neurology; surgical treatment of epilepsy. *Can Med Assoc J* 116: 1369–1370. PMID: 324598
- Rose M (1935) Cytoarchitektonik und Myeloarchitektonik der Grosshirnrinde. In: Bumke O, Foerster O (eds) *Handbuch der Neurologie*, Bd. 1: Allgemeine Neurologie I—Anatomie. Julius Springer, Berlin, pp 588–778
- Rushmore RJ, Bouix S, Kubicki M, Rathi Y, Yeterian EH, Makris N (2020) How human is human connectional neuroanatomy? *Front Neuroanat* 14: 18. <https://doi.org/10.3389/fnana.2020.00018>
- Sammet K (2006) Wilhelminian myelinated fibers—Theodor Kaes, myeloarchitectonics and the asylum Hamburg-Friedrichsberg 1890–1910. *J Hist Neurosci* 15: 56–72. <https://doi.org/10.1080/09647040500207770>
- Sanides F (1962) *Die Architektonik des menschlichen Stirnhirns*. Springer-Verlag, Berlin
- Sanides F (1964) The cyto-myeloarchitecture of the human frontal lobe and its relation to phylogenetic

- differentiation of the cerebral cortex. *J Hirnforsch* 47: 269–282
- Sanides F (1970) Functional architecture of motor and sensory cortices in primates in the light of a new concept of neocortex evolution. In: Noback CR, Montagna W (eds) *The primate brain: advances in primatology*. Appleton-Century-Crofts, New York, pp 137–208
- Sanides F (1972) Die Evolution des Säugetiergehirns. *Umsch Wiss Tech* 72(19): 613–620
- Schmahmann JD, Pandya DN (2006) *Fiber pathways of the brain*. Oxford University Press, New York
- Schmahmann JD, Pandya DN, Wang R, Dai G, D'Arceuil HE, de Crespigny AJ, Wedeen VJ (2007) Association fibre pathways of the brain: parallel observations from diffusion spectrum imaging and autoradiography. *Brain* 130: 630–653. <https://doi.org/10.1093/brain/awl359>
- Scholtens LH, de Reus MA, van den Heuvel MP (2015) Linking contemporary high resolution magnetic resonance imaging to the von Economo legacy: a study on the comparison of MRI cortical thickness and histological measurements of cortical structure. *Hum Brain Mapp* 36: 3038–3046. <https://doi.org/10.1002/hbm.22826>
- Scholtens LH, de Reus MA, de Lange SC, Schmidt R, van den Heuvel MP (2018) An MRI von Economo-Koskinas atlas. *NeuroImage* 170: 249–256. <https://doi.org/10.1016/j.neuroimage.2016.12.069>
- Schüle H (1886) *Klinische Psychiatrie: Specielle Pathologie und Therapie der Geisteskrankheiten, dritte Auflage*. F. C. W. Vogel, Leipzig
- Schwartz EL, Shaw A, Wolfson E (1989) A numerical solution to the generalized mapmaker's problem: flattening nonconvex polyhedral surfaces. *IEEE Trans Pattern Anal Mach Intell* 11: 1005–1008. <https://doi.org/10.1109/34.35506>
- Seeley WW, Merkle FT, Gaus SE, Craig AD, Allman JM, Hof PR (2012) Distinctive neurons of the anterior cingulate and frontoinsular cortex: a historical perspective. *Cereb Cortex* 22: 245–250. <https://doi.org/10.1093/cercor/bhr005>
- Shen EH, Overly CC, Jones AR (2012) The Allen Human Brain Atlas: comprehensive gene expression mapping of the human brain. *Trends Neurosci* 35: 711–714. <https://doi.org/10.1016/j.tins.2012.09.005>
- Sherrington CS, Grünbaum ASF (1901a) Motor representation in the cortex of the anthropoid brain. *Br Med J* 2: 1091–1093. <https://doi.org/10.1136/bmj.2.2128.1091>
- Sherrington CS, Grünbaum ASF (1901b) An address on localisation in the “motor” cerebral cortex. *Br Med J* 2: 1857–1859. <https://doi.org/10.1136/bmj.2.2139.1857>
- Sherrington CS, Grünbaum ASF (1902) A discussion on the motor cortex as exemplified in the anthropoid apes. *Br Med J* 2: 784–785. <https://doi.org/10.1136/bmj.2.2176.741>
- Sourander P, Öberg L (1969–1971) Carl Hammarberg, läkare (neurolog). *Svenskt Biografiskt Lexikon* 18: 145. <http://sok.riksarkivet.se/sbl/mobil/artikel/12520>. Accessed 2 June 2020
- Sprung-Much T, Petrides M (2018) Morphological patterns and spatial probability maps of two defining sulci of the posterior ventrolateral frontal cortex of the human brain: the sulcus

- diagonalis and the anterior ascending ramus of the lateral fissure. *Brain Struct Funct* 223: 4125–4152. <https://doi.org/10.1007/s00429-018-1733-y>
- Südhof TC (2017) Molecular neuroscience in the 21st century: a personal perspective. *Neuron* 96: 536–541. <https://doi.org/10.1016/j.neuron.2017.10.005>
- Talairach J, Tournoux P (1988) Co-planar stereotaxic atlas of the human brain; 3-dimensional proportional system: an approach to cerebral imaging (transl. by M. Rayport). Georg Thieme Verlag, Stuttgart
- Triarhou LC (2007a) The Economo-Koskinas atlas revisited: cytoarchitectonics and functional context. *Stereotact Funct Neurosurg* 85: 195–203. <https://doi.org/10.1159/000103258>
- Triarhou LC (2007b) A proposed number system for the 107 cortical areas of Economo and Koskinas, and Brodmann area correlations. *Stereotact Funct Neurosurg* 85: 204–215. <https://doi.org/10.1159/000103259>
- Triarhou LC (2012) Cytoarchitectonics of the human cerebral cortex: the 1926 presentation by Georg N. Koskinas (1885–1975) to the Athens Medical Society. In: Bright P (ed) *Neuroimaging—Cognitive and Clinical Neuroscience*. InTech Publishers, Rijeka/Vienna, pp 1–16. <https://doi.org/10.5772/24312>
- Triarhou LC (2013) The cytoarchitectonic map of Constantin von Economo and Georg N. Koskinas. In: Geyer S, Turner R (eds) *Microstructural parcellation of the human cerebral cortex: from Brodmann’s post-mortem map to in vivo mapping of high-field magnetic resonance imaging*. Springer-Verlag, Berlin, pp 33–53. https://doi.org/10.1007/978-3-642-37824-9_2
- Triarhou LC (2020) Pre-Brodmann pioneers of cortical cytoarchitectonics I: Theodor Meynert, Vladimir Betz, and William Bevan-Lewis. *Brain Struct Funct* 000: 000–000. <https://doi.org/10.1007/s00415-020-00000-0>
- Uylings HBM, Rajkowska G, Sanz-Arigita E, Amunts K, Zilles K (2005) Consequences of large interindividual variability for human brain atlases: converging macroscopical imaging and microscopical neuroanatomy. *Anat Embryol (Berl)* 210: 423–431. <https://doi.org/10.1007/s00429-005-0042-4>
- Vogt C, Vogt O (1919) Allgemeinere Ergebnisse unserer Hirnforschung. *J Psychol Neurol (Leipz)* 25: 279–461
- Vogt O (1903) Zur anatomischen Gliederung des Cortex cerebri. *J Psychol Neurol (Leipz)* 2: 160–180
- Vogt O (1906) Der Wert der myelogenetischen Felder der Grosshirnrinde (Cortex pallii). *Anat Anz (Jena)* 29: 273–287
- Vogt O (1910) Die myeloarchitektonische Felderung des menschlichen Stirnhirns. *J Psychol Neurol (Leipz)* 15: 221–238
- Vogt O (1911) Die Myeloarchitektonik des Isocortex parietalis. *J Psychol Neurol (Leipz)* 18: 379–390
- Wagstyl K, Larocque S, Cucurull G, Lepage C, Cohen JP, Bludau S, Palomero-Gallagher N, Lewis LB, Funck T, Spitzer H, Dickscheid T, Fletcher PC, Romero A, Zilles K, Amunts K, Bengio Y,

- Evans AC (2020) BigBrain 3D atlas of cortical layers: cortical and laminar thickness gradients diverge in sensory and motor cortices. *PLoS Biol* 18(4): e3000678.
<https://doi.org/10.1371/journal.pbio.3000678>
- Walker AE (1953) Sir Grafton Elliot Smith (1871–1937). In: Haymaker W, Baer KA (eds) *The founders of neurology*. Charles C Thomas, Springfield, IL, pp 89–92
- Watson KK, Jones TK, Allman JM (2006) Dendritic architecture of the von Economo neurons. *Neuroscience* 141: 1107–1112. <https://doi.org/10.1016/j.neuroscience.2006.04.084>
- Wilson JT (1937) Sir Grafton Elliot Smith's bibliography. *J Anat (Lond)* 71: 544–548
- Wilson JT (1938) Sir Grafton Elliot Smith, 1871–1937. *Obit Not Fell R Soc* 2: 322–33.
<https://doi.org/10.1098/rsbm.1938.0014>
- Woollard HH (1938) An outline of Elliot Smith's contributions to neurology. *J Anat (Lond)* 72: 280–294
- Zilles K, Amunts K (2010) Centenary of Brodmann's map—conception and fate. *Nat Rev Neurosci* 11: 139–145. <https://doi.org/10.1038/nrn2776>

Figure captions

Figure 1 *Left*: Carl Hammarberg, member of the ‘Östgöta nation’ student society at Uppsala University. Photo by Helène Edlund (1858–1941), Stockholm, 1888. Signature from an autograph letter to physician Carl Barthold Carlson (1863–1960), dated 1893. ALVIN Digital Collections and Digitised Cultural Heritage Platform, Uppsala University Library. *Middle*: Alfred Walter Campbell. Photo by Draycott Galleries, London, circa 1905. State Archives and Records Authority of New South Wales. *Right*: Sir Grafton Elliot Smith. Bromide print by Walter Stoneman (1876–1958), 1920. National Portrait Gallery, London. Signature from Wilson (1936).

Figure 2 *Upper left*: Title page of Carl Hammarberg’s doctoral thesis (Hammarberg 1893). *Lower left*: Salomon Henschen at the microscope, left, with his co-workers, circa 1890. Hammarberg sits at the short end of the table on the right (Lindberg 2013). *Right*: Lamina cytoarchitecture in the normal cerebral cortex of a 28 year-old male. Methylene blue, section thickness 20 µm. *A*, insula; *B*, anterior part of hippocampal gyrus; *C*, fascia dentata; *D*, middle part of hippocampal gyrus at the transition to Ammon’s horn (Hammarberg 1893).

Figure 3 Lamina cytoarchitecture in the normal cerebral cortex of a 28 year-old male. Methylene blue, section thickness 20 µm. *A*, cross-section of the cortex from the upper one-sixth of the precentral gyrus, showing giant cells in layer V; *B*, segment of the inferior frontal gyrus lying behind the ascending knee of the Sylvian fissure; *C*, segment of the inferior frontal gyrus lying in front of the ascending knee of the Sylvian fissure (showing the large pyramidal cells typical of layer III in Broca’s area); *D*, cross-section through the middle part of the superior temporal gyrus (Wernicke’s area); *E*, cross-section through the superior parietal gyrus; *F*, cross-section through the medial aspect of the superior occipital gyrus (Hammarberg 1893).

Figure 4 Macroscopic features in brains of individuals with intellectual disability (Hammarberg 1893). *Upper*: Medial and lateral facies of the left cerebral hemisphere. The cortex-clad ridge (*Wulst*) beneath the cingulate gyrus represents the free edge of the fibre tract that runs from the centre of the corpus callosum posteriorly to the occipital and temporal lobes. Under this ridge comes a membrane-like structure, which is attached with its lateral edge in the sulcus chorioidei; this structure merges forward into the clearly formed columns of the fornix. *Lower left*: Orbital surface of the right cerebral hemisphere, with the olfactory gyrus very well developed. *Lower right*: Anterior part of the inferior cerebral surface; the anterior part of the temporal gyri (apart from the superior temporal gyrus) is missing, exposing the amygdala.

Figure 5 Cortical cytoarchitecture in individuals with intellectual disability. *A*, cross-section through

the medial aspect of the precentral gyrus (group B2, moderate disability, case 7); *B*, cross-section through the central part of the precentral gyrus from the hemispheric convexity (group B1, severe disability, case 6); *C*, cross-section through the postcentral gyrus at the boundary with the precentral gyrus (group A, profound disability, case 4); *D*, cross-section through the medial hemispheric aspect of the precentral gyrus (group A, profound disability, case 1) (Hammarberg 1893).

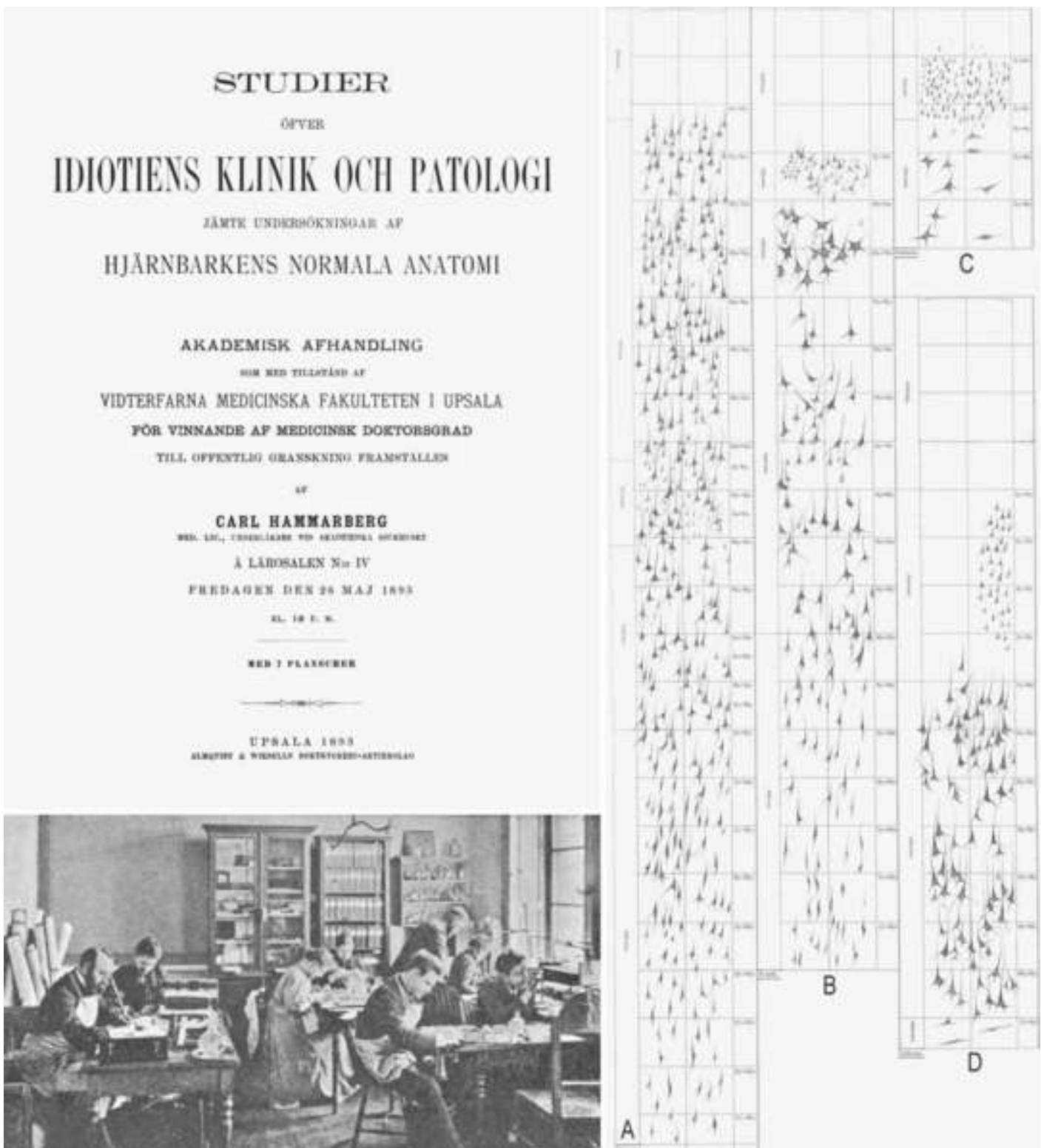
Figure 6 *Upper*: Cortical area maps ('orthogonal tracings') of the medial (*left*) and lateral facies (*right*, somewhat tilted to show the convexity) of the left cerebral hemisphere of an adult human, defined on the basis of nerve fibres and nerve cells by Campbell (1905b). *Lower*: Nerve fibre arrangement in the motor area (*far left*), drawn from a section through the precentral gyrus. Cell lamination in the precentral area (*centre left*), drawn from a section through the paracentral lobule. Fibre arrangement in the postcentral area (*centre right*), drawn from a transverse section of the postcentral gyrus; differences from the motor cortex include a dispersity in fibre wealth, particularly noticeable in the zonal layer and radiary zone. Cell lamination in the postcentral area (*far right*), drawn from a section through the paracentral lobule, immediately behind the upper extremity of the central sulcus; compared to the motor cortex, there is an absence of giant cells from the sixth layer. Numbers denote the layers of nerve cells. Layer 1, mostly composed of cortical grey matter, contained the arbours of numerous dendrites and the terminal axons form an intricate plexus – hence it was termed *plexiform layer* by Campbell. *Z*, zonal layer, dense and well-defined; *S*, supraradiary layer; *B*, line of Baillarger, its position obscured by surrounding fibres; *R*, radiary zone.

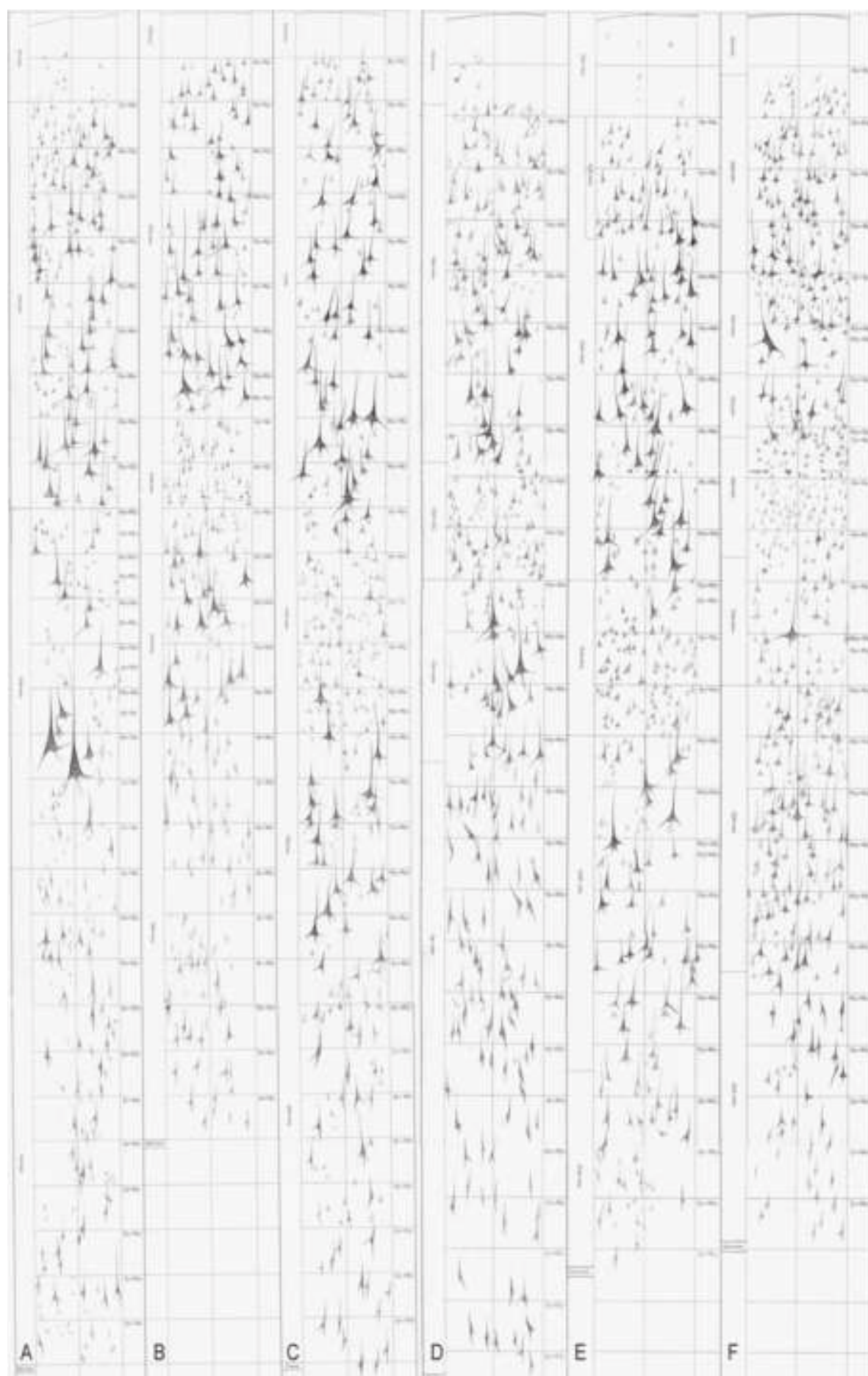
Figure 7 *Upper*: Cortical area maps of the medial facies (*left*) and convexity (*right*) of the human brain by Elliot Smith (1907b). *Lower left*: Detail of the human cerebral hemisphere to show parts of the insula, olfactory tubercle or the real boundaries of the piriform lobe and the transverse gyri of Heschl. *Lower right*: Elliot Smith at University College London (credit: Australian Neuroscience Society, <http://www.ans.org.au/images/grafon-smith.jpg>).

Figure 1

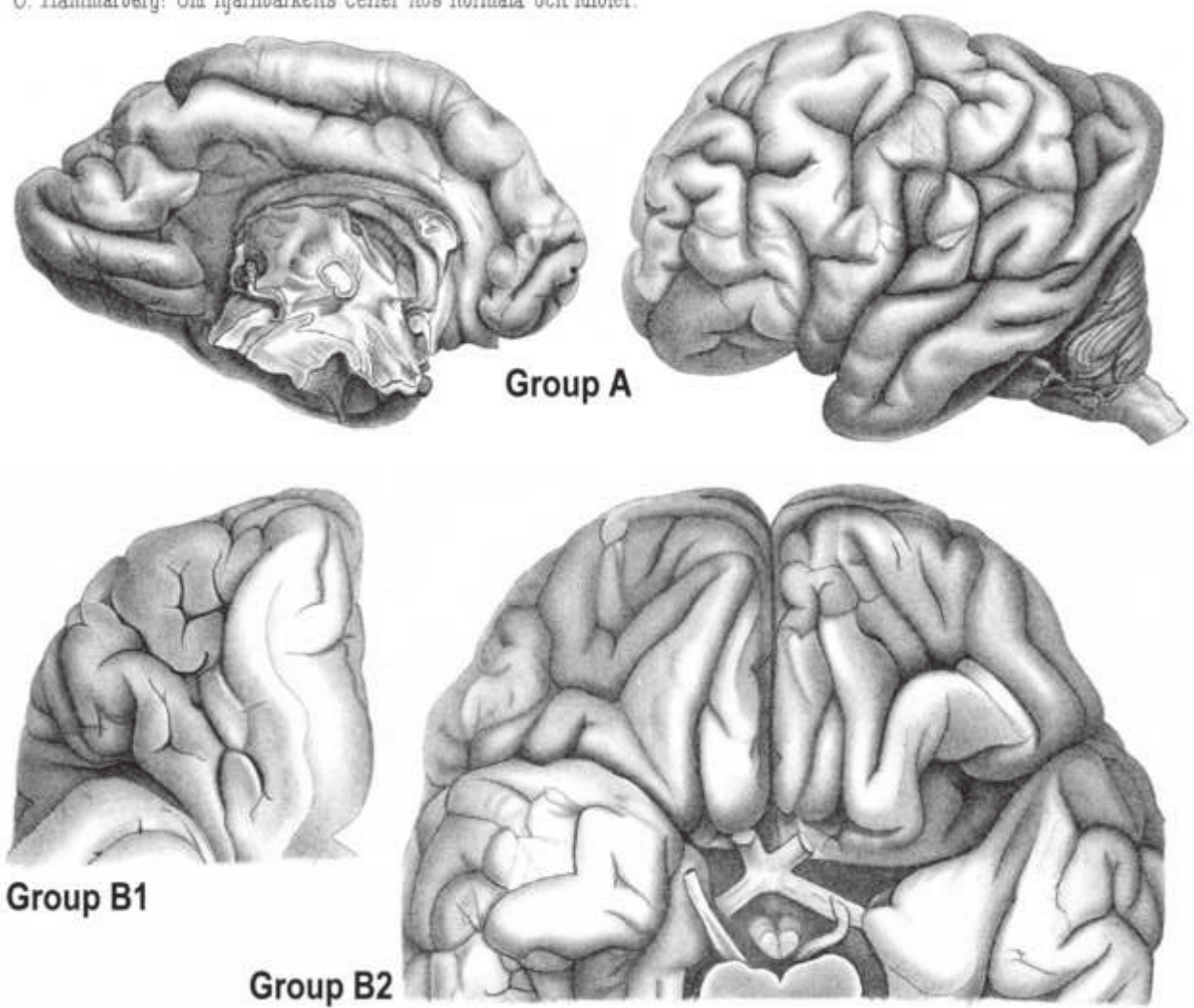
[Click here to access/download;Figure;Figure 1.jpg](#)







C. Hammarberg: Om hjärnbarkens celler hos normala och idioter.






Figure 6

[Click here to access/download;Figure;Figure 6.jpg](#)

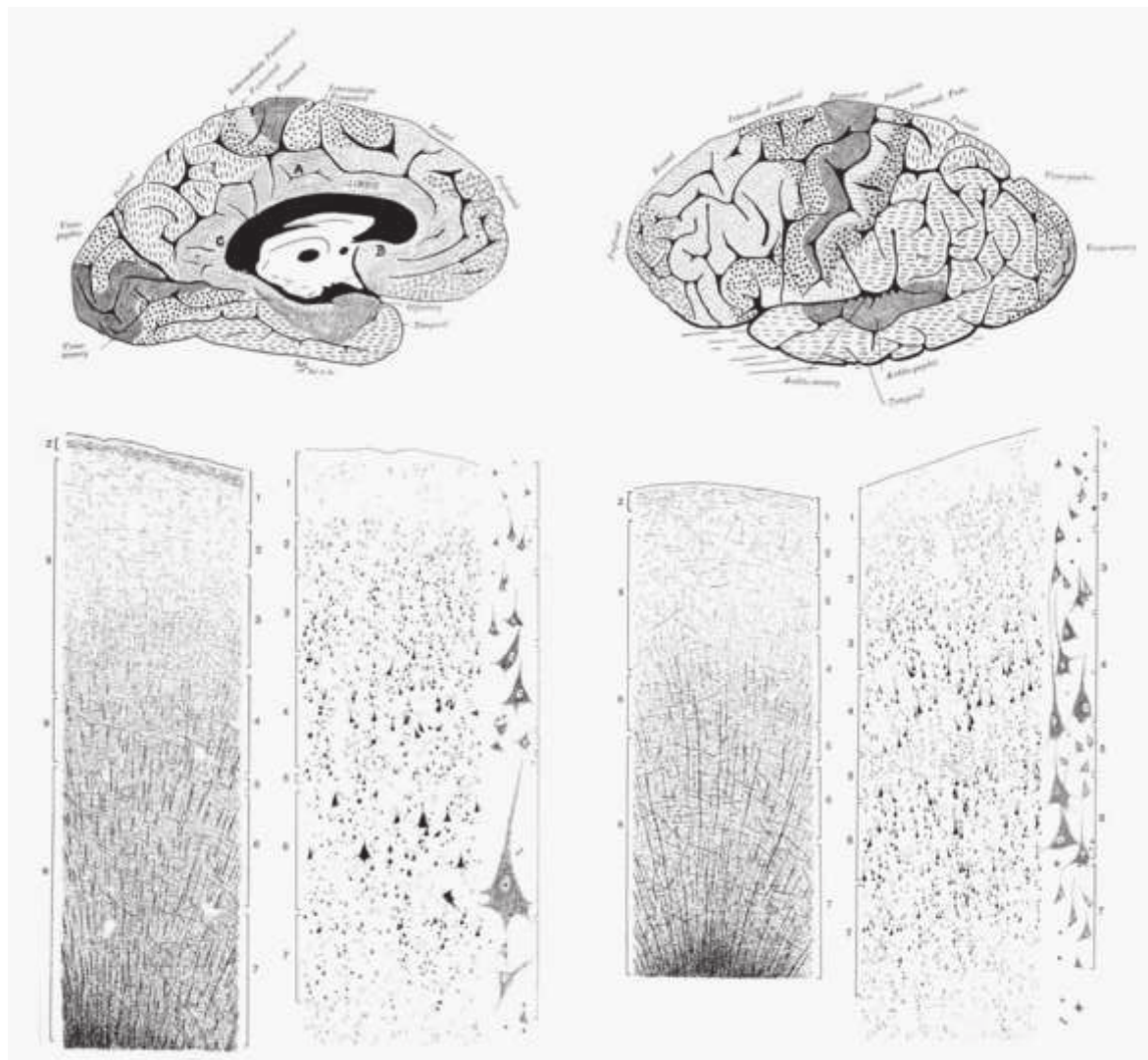


Figure 7

[Click here to access/download;Figure;Figure 7.jpg](#)

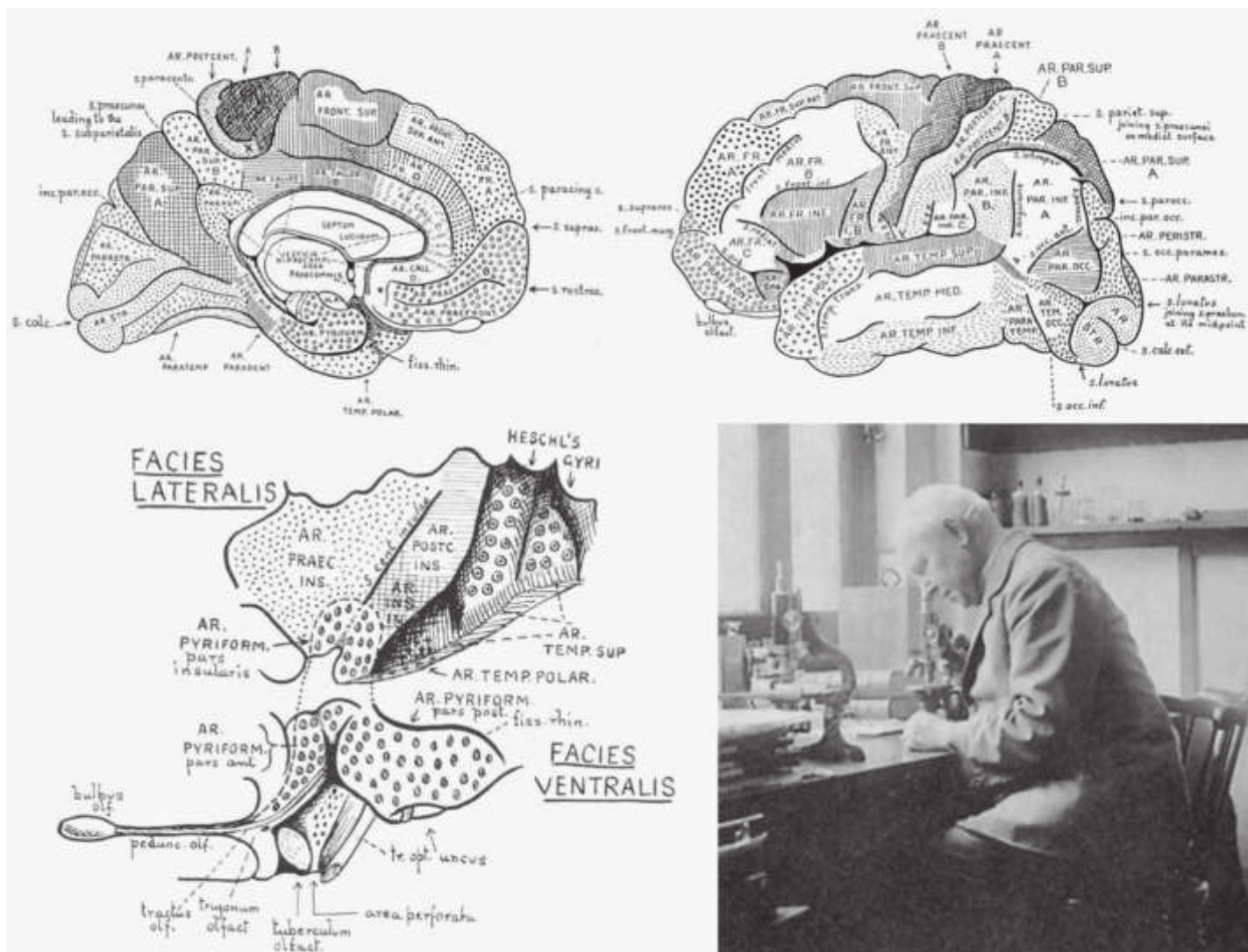


Table 1

Table 1 Timeline of discoveries by the scientists covered in the present and the accompanying paper, summarising their chronology, methods and species used.

Author	Dates of publications	Methods used	Sectioning	Fixation	Staining	Cortical lamination	Species examined
Theodor Meynert	1867/1868, 1868, 1872, 1877, 1878	Histology, microscopy	Fibre cleavage	Potassium dichromate	Carmine red	1. Molecular layer 2. External granular layer 3. Pyramidal layer 4. Internal granular layer 5. Spindle cell layer	Human control, neuropathological cases, ape, monkey, lion, bear, fox, cougar, wild cat, Viverrinae
Vladimir Betz	1873, 1874, 1875, 1881	Microscopy, comparative histology	Specially constructed knives and razors	Ethanol, ether, chloroform, iodine, potassium dichromate	Gerlach carmine red		Human control, neuropathological cases, dog, chimpanzee, baboon, rat, casts of non-human primates
William Bevan Lewis	1878, 1879, 1880, 1882	Macroscopy and optical microscopy	Freezing ('ether') microtome	Fresh, alcohol, picric acid, chrome salts	Osmic acid, aniline black	1. Plexiform layer 2. Small pyramids 3. Great pyramids 4. Inner small pyramids 5. Ganglion cell layer 6. Spindle cell layer	Human control, mental diseases, pig, sheep, cat, calf, ocelot, Barbary macaque, rodents
Carl Hammarberg	1893, 1895	Histology of cell bodies	20 µm thick sections	Alcohol-treated, paraffin-embedded	Nissl methylene blue		Human control, mental disability
Alfred Walter Campbell	1902, 1904, 1905, 1916	Cytoarchitectonics, myeloarchitectonics, topographical or provisional functional parcellation	Serial sections, 15 or 25 µm in thickness	Celloidin-embedded blocks	Wolters–Kulschitsky for myelin, thionine for cell bodies	1. Plexiform layer 2. Small pyramidal cells 3. Medium pyramidal cells 4. Large pyramidal cells 5. Stellate cells 6. Inner large pyramidal cells 7. Spindle cells	Human control, amputated patients, amyotrophic lateral sclerosis, tabes dorsalis, chimpanzee, orangutan, gorilla, dog, cat, pig
Grafton Elliot Smith	1907	Brain sections, magnifying lens	Scalpel, naked eye	Fresh	Unstained	Baillarger stripes, density of intracortical white matter	Monotremes, marsupials, human

Table 2

Table 2 Summary table of several laboratories with contributions to the cortical cytoarchitectonics of the human cerebral hemispheres.

Authors	Chronological range of publications	Number of brains studied (sample size)	Ages
Theodor Meynert	1867–1877	Undefined	Developing to aged
Vladimir Betz	1873–1881	5000 'specimens'	7 months of gestation to 6 postnatal weeks
William Bevan Lewis	1878–1882	Undefined	Mostly adult
Carl Hammarberg	1893–1895	12 (death from non-neurological causes), 9 (mental disability)	5 months of gestation to 50 years (control), 22 months to 26 years (mental disability)
Alfred Walter Campbell	1902–1916	>25	Mostly adult
Grafton Elliot Smith	1904–1908	>1000 'hemispheres'	Newborn to >20 years
Korbinian Brodmann	1907–1914	Unspecified	Adult
Constantin von Economo and Georg N. Koskinas	1925–1927	6 (death after short non-neurological illness)	30–40 years