



Prediction and probability of neonatal outcome in isolated congenital diaphragmatic hernia using multiple ultrasound parameters

R. RUANO*, E. TAKASHI*, M. M. DA SILVA†, J. A. D. B. CAMPOS‡, U. TANNURI†
and M. ZUGAIB*

*Department of Obstetrics and Gynecology, Faculdade de Medicina, Universidade de São Paulo, São Paulo, Brazil; †Department of Pediatric Surgery, Faculdade de Medicina, Universidade de São Paulo, São Paulo, Brazil; ‡Social Department, Faculdade de Odontologia, Universidade Estadual Paulista, Araraquara, Brazil

KEYWORDS: 3D ultrasonography; congenital diaphragmatic hernia; power Doppler; pulmonary hypoplasia; three-dimensional ultrasonography

ABSTRACT

Objectives To evaluate the accuracy and probabilities of different fetal ultrasound parameters to predict neonatal outcome in isolated congenital diaphragmatic hernia (CDH).

Methods Between January 2004 and December 2010, we evaluated prospectively 108 fetuses with isolated CDH (82 left-sided and 26 right-sided). The following parameters were evaluated: gestational age at diagnosis, side of the diaphragmatic defect, presence of polyhydramnios, presence of liver herniated into the fetal thorax (liver-up), lung-to-head ratio (LHR) and observed/expected LHR (o/e-LHR), observed/expected contralateral and total fetal lung volume (o/e-ContFLV and o/e-TotFLV) ratios, ultrasonographic fetal lung volume/fetal weight ratio (US-FLW), observed/expected contralateral and main pulmonary artery diameter (o/e-ContPA and o/e-MPA) ratios and the contralateral vascularization index (Cont-VI). The outcomes were neonatal death and severe postnatal pulmonary arterial hypertension (PAH).

Results Neonatal mortality was 64.8% (70/108). Severe PAH was diagnosed in 68 (63.0%) cases, of which 63 died neonatally (92.6%) ($P < 0.001$). Gestational age at diagnosis, side of the defect and polyhydramnios were not associated with poor outcome ($P > 0.05$). LHR, o/e-LHR, liver-up, o/e-ContFLV, o/e-TotFLV, US-FLW, o/e-ContPA, o/e-MPA and Cont-VI were associated with both neonatal death and severe postnatal PAH ($P < 0.001$). Receiver–operating characteristics curves indicated that measuring total lung volumes (o/e-TotFLV and US-FLW) was more accurate than was considering only

the contralateral lung sizes (LHR, o/e-LHR and o/e-ContFLV; $P < 0.05$), and Cont-VI was the most accurate ultrasound parameter to predict neonatal death and severe PAH ($P < 0.001$).

Conclusions Evaluating total lung volumes is more accurate than is measuring only the contralateral lung size. Evaluating pulmonary vascularization (Cont-VI) is the most accurate predictor of neonatal outcome. Estimating the probability of survival and severe PAH allows classification of cases according to prognosis. Copyright © 2011 ISUOG. Published by John Wiley & Sons, Ltd.

INTRODUCTION

Neonatal mortality and morbidity in cases with isolated congenital diaphragmatic hernia (CDH) depend on the severity of pulmonary hypoplasia and pulmonary arterial hypertension (PAH), and fetal tracheal occlusion has been proposed in order to prevent these complications and therefore to increase neonatal survival^{1–3}. However, prenatal prediction of those fetuses that will present with a severe form of CDH at birth is challenging, which makes it difficult to identify with any precision the best candidates for fetal intervention. Furthermore, neonatal mortality rates appear to vary between different centers all over the world, which may be related to differences in the standardization of perinatal management, in hidden mortality, in assessment and in the use of prenatal intervention^{4,5}. Standard classification of fetuses with isolated CDH according to prognosis is necessary in order to determine the best perinatal management and also to enable better comparison between centers.

Correspondence to: Dr R. Ruano, Universidade de São Paulo, Faculdade de Medicina, Obstetrics Department, Av. Dr. Enéias de Carvalho Aguiar, 255, 10º andar, Obstetrícia, São Paulo, Brazil, CEP 05403-900 (e-mail: rodrigorruano@usp.br)

Accepted: 24 August 2011

A European group suggested classifying fetuses with isolated CDH into extremely severe, severe, moderate and mild forms, based on the observed/expected lung-to-head ratio (LHR) and the presence of herniated liver in the fetal thorax^{6,7}. Several fetal parameters have been proposed in order to predict neonatal outcome in isolated CDH based on lung sizes, position of the liver and pulmonary vasculature status^{6,8–20}. However, as yet there is no consensus as to which parameter is most accurate and useful in predicting neonatal outcome in these cases.

In this study, therefore, we evaluated prospectively different ultrasound parameters in 108 fetuses with isolated CDH in order to analyze the accuracy and the probability of each parameter to predict postnatal survival and severe PAH, providing a basis for classifying the cases according to the severity of CDH. Our series underwent neither fetal surgery nor termination of pregnancy.

PATIENTS AND METHODS

Between January 2004 and December 2010, we conducted a prospective observational study in our tertiary Fetal Medicine Unit, evaluating 108 fetuses with isolated CDH (82 left-sided and 26 right-sided). Inclusion criteria were: (1) gestational age established by last menstrual period in accordance with first-/second-trimester ultrasonography; (2) confirmed ultrasound diagnosis of CDH; (3) normal fetal karyotype; (4) absence of other structural anomalies; (5) no fetal surgery. The protocol was approved by the local ethics committee. The pregnant patients were informed that the results of the study would not be used to modify their perinatal management. The perinatologists, ultrasonographers and surgeons in charge were unaware of the results of the lung volume measurements. Termination of pregnancy was not performed since it is not permitted in our country.

Fetal lung parameters

Using a Voluson 730 (GE Healthcare, Zipf, Austria) ultrasound machine we evaluated between 26 and 30 weeks the following fetal lung parameters: (1) side of the diaphragmatic defect (left or right); (2) presence of polyhydramnios (amniotic fluid index > 25 cm); (3) presence of fetal liver herniated into the fetal thorax ('liver-up'); (4) LHR; (5) observed/expected LHR (o/e-LHR); (6) observed/expected contralateral fetal lung volume (o/e-ContFLV) ratio; (7) observed/expected total fetal lung volume (o/e-TotFLV) ratio; (8) ultrasonographic fetal lung volume/fetal weight ratio (US-FLW); (9) observed/expected contralateral pulmonary artery diameter (o/e-ContPA) ratio; (10) observed/expected main pulmonary artery diameter (o/e-MPA) ratio; and (11) contralateral vascularization index (Cont-VI). In addition, the following data were evaluated: (12) gestational age at diagnosis; (13) gestational age at birth; and (14) newborn weight.

The LHR was measured using two-dimensional (2D) ultrasonography by multiplying the two longest

perpendicular diameters of the contralateral lung at the level of the four-chamber view of the heart and dividing this by the head circumference (measured in mm)^{21,22}. We calculated o/e-LHR by comparing the LHR with the expected value for gestational age on 2D ultrasound^{6,23}. We determined o/e-ContFLV and o/e-TotFLV by estimating the contralateral and total lung volumes, respectively, using Virtual Organ Computer-aided AnaLysis (VOCAL™) software (Sonoview software, GE Healthcare), rotating the three-dimensional (3D) image 30° degrees as described previously^{16,20}, and comparing them to the expected values for gestational age^{24,25}. US-FLW was the ratio between total fetal lung volume as estimated by 3D ultrasound and the estimated fetal weight using the Hadlock equation, which has been demonstrated not to vary throughout gestational age¹⁹. Fetal lung sizes were represented by LHR, o/e-LHR, o/e-ContFLV, o/e-TotFLV and US-FLW.

The o/e-ContPA and the o/e-MPA were evaluated by measuring the contralateral and the main pulmonary artery diameters on a cross-sectional image of the fetal chest at the level of the three vessels (main pulmonary artery, ascending aorta and superior vena cava) in the short-axis view of the fetal heart^{18,26}, and comparing them to the expected values for gestational age²⁷. Cont-VI was calculated using the 3D power Doppler histogram as reported previously¹⁷ and using the same power Doppler presets (angio mode, cent; smooth, 4/5; frequency, low; quality, 16; density, 6; enhance, 16; balance, G > 150; filter, 2; actual power, 2 dB; pulse repetition frequency, 0.9). The 3D volume of the fetal thorax was acquired and the contralateral lung volume was measured in the transverse plane using VOCAL™ software (rotation of 30° degrees). A 3D power Doppler histogram was used to determine the vascularization index (VI) from inbuilt computer algorithms which calculate the color voxel to total voxel ratio. This percentage of color flow Doppler within the lung is indicative of the vessels that are present as compared with the background non-vascular parenchyma. Since it has been demonstrated previously that fetal pulmonary VI does not vary throughout gestation¹⁷, an observed-to-expected ratio was unnecessary for this parameter. Fetal pulmonary vasculature was evaluated by the pulmonary artery diameters (o/e-ContPA and o/e-MPA) and Cont-VI.

Perinatal management

All fetuses with prenatal diagnosis of isolated CDH were followed in our Fetal Medicine Unit and were delivered in our Children's Hospital. All babies were treated following the same protocol²⁸. Briefly, the neonates were intubated in the delivery room and admitted immediately to the neonatal intensive care unit. Immediate ventilator support was initiated in all cases, with high-frequency oscillatory ventilation when necessary, followed by delayed CDH repair in all cases. The treatment protocol did not include extracorporeal membrane oxygenation (ECMO), either pre- or postoperatively, as this treatment modality is not available at our institution. Inhaled nitric oxide

(iNO) was administered in cases of persistent PAH verified by a pre- vs postductal saturation difference of >10%, confirmed by echocardiography. Hemodynamic support was achieved by volume expansion and administration of dobutamine (10–20 µg/kg/min) and norepinephrine (0.5–2 µg/kg/min) when necessary. Pre-operative respiratory and hemodynamic stabilization, required before delayed CDH repair was performed, was defined by the following criteria: (a) normal hemodynamic variables (mean blood pressure >40 mmHg with urine output >2 mL/kg/h) without need for inotropic agents; (b) absence of PAH after discontinuation of iNO; (c) successful weaning to conventional mechanical ventilation with moderate values of peak inspiratory pressure (15–20 cmH₂O) and adequate oxygenation, achieved with FiO₂ ≤40%.

Outcomes and statistical analysis

The primary outcome was neonatal survival to 28 days. The secondary outcome was postnatal diagnosis of severe PAH. Severe PAH was considered when the neonate presented with profound cyanosis associated with echocardiographic continuous right-to-left shunting through a persistent ductus arteriosus and a persistent difference in pre- to postductal saturation gradient >20%, despite the use of iNO²⁹.

Data were analyzed using Student's *t* and chi-square tests to evaluate the association of the ultrasound parameters with neonatal survival and with postnatal diagnosis of severe PAH. Correlations between variables were evaluated by Pearson test. Receiver–operating characteristics (ROC) curves were also calculated to evaluate the accuracy of each variable in the prediction of neonatal survival and postnatal diagnosis of severe PAH, by comparing the areas under the curves (AUCs). Best cut-offs (points with the highest sensitivity and lowest rate of false positivity) were then established. The accuracy of each ultrasound parameter to predict both outcomes was calculated using the best cut-off obtained from the ROC curve analysis using the following equation: accuracy = (number of true positives + number of true negatives)/total number of measurements. Statistical comparison between the accuracies of ultrasound parameters was performed using McNemar and Cochran's Q tests (SPSS for Windows version 17; Microsoft Corp., Chicago, IL, USA). Statistical comparisons between the AUCs of different ultrasound variables were also performed according to the DeLong *et al.* and Hanley & McNeil tests (MedCalc software version 11.6, Mariakerke, Belgium)^{30–32}. The probabilities for the events (neonatal survival and severe PAH) based on each ultrasound parameter were also calculated using regression. Based on the probabilities of neonatal survival and postnatal diagnosis of PAH, a prognostic classification of CDH was established (Statistica, version 9, StatSoft Inc., Tulsa, OK, USA). Multivariable studies were performed using logistic regression and factor analysis (SPSS for Windows version 17). Statistical differences were considered to be significant when *P* < 0.05.

RESULTS

The neonatal mortality rate in our series was 64.8% (70/108). All survivors were doing well at 6 months. Severe PAH was diagnosed postnatally in 68 (63.0%) cases, and this was statistically associated with neonatal death: 92.6% (63/68) newborns with severe PAH died while 15.0% (7/40) infants without severe PAH died (*P* < 0.001).

Table 1 presents the prenatal characteristics according to neonatal outcome. Liver herniation into the fetal thorax (liver-up), the ultrasonographic parameters representing fetal lung size (LHR, o/e-LHR, o/e-ContFLV, o/e-TotFLV and US-FLW), fetal pulmonary diameters (o/e-ContPA and o/e-MPA) and contralateral lung vascularization (Cont-VI) were statistically associated with either neonatal death or postnatal severe PAH (*P* < 0.05). Gestational age at diagnosis, polyhydramnios, side of defect, gestational age at birth and birth weight were related to neither neonatal survival nor postnatal diagnosis of severe PAH in this series.

With the exception of o/e-LHR and US-FLW, all fetal ultrasonographic lung parameters correlated statistically with each other (Table S1). The ROC curves used to determine the best cut-offs and accuracies for each ultrasound parameter in the prediction of postnatal death and severe PAH are presented in Figure 1, and the accuracies themselves are given in Tables S2 and S3. Considering the parameters representing fetal lung size, those evaluating total lung volumes had greater accuracy than did those evaluating only the contralateral lung, based on the AUCs and the comparison between accuracies (McNemar and Cochran's Q tests, *P* < 0.01). The o/e-TotFLV had the highest accuracy to predict both neonatal death and severe PAH (83.3% and 86.1%, respectively) when compared with LHR (73.1% and 78.7%, *P* < 0.01), o/e-LHR (75.9% and 72.2%; *P* = 0.07) and o/e-ContFLV (75.0% and 78.7%; *P* = 0.02), but o/e-TotFLV was not superior to US-FLW (80.6% and 75.9%; *P* = 0.59) and liver-up (79.6% and 74.1%, *P* = 0.41). However, Cont-VI was the best ultrasound parameter in predicting postnatal death and severe postnatal PAH (88.9% and 91.7%, respectively, *P* < 0.001), being more accurate than all other ultrasound parameters.

The relative risks (RR) of each parameter for the outcomes are also shown in Tables S2 and S3. Based on this information, for each ultrasound parameter it was possible to determine the risks for outcomes in isolated CDH. For example, fetuses with o/e-TotFLV <0.35 have an approximately four times higher risk of death and postnatal severe PAH than do those with o/e-TotFLV ≥0.35 (RR, 5.2 (95% CI, 2.5–11.0) and RR, 3.7 (95% CI, 2.2–6.4), respectively). The probabilities of each parameter to predict neonatal death or survival were calculated, leading to mathematical equations presented in Tables S2 and S3, respectively.

A further analysis was performed considering different combinations of parameters, including one parameter

Table 1 Prenatal findings of 108 fetuses with isolated congenital diaphragmatic hernia (CDH), according to neonatal outcome

Finding	All cases (n = 108)	Neonatal death			Severe PAH		
		Yes (n = 70)	No (n = 38)	P	Yes (n = 68)	No (n = 40)	P
GA at diagnosis (weeks)	20.6 ± 5.1	20.1 ± 5.2	20.7 ± 4.7	0.84	20.7 ± 5.2	20.3 ± 4.8	0.72
Laterality of CDH				0.13			0.09
Left-sided	82 (75.9)	50 (71.4)	32 (84.2)		48 (70.6)	34 (85.0)	
Right-sided	26 (24.1)	20 (28.6)	6 (15.8)		20 (29.4)	6 (15.0)	
Polyhydramnios	37 (34.3)	23 (32.5)	14 (36.8)	0.812	25 (36.8)	12 (30.0)	0.477
LHR	1.40 ± 0.88	0.97 ± 0.31	2.19 ± 1.06	< 0.001	1.0 ± 0.7	1.9 ± 0.9	< 0.001
o/e-LHR (%)	24.3 ± 8.5	20.5 ± 6.5	31.3 ± 7.2	< 0.001	21.5 ± 8.0	28.9 ± 7.4	< 0.001
Liver-up	76 (70.4)	62 (88.6)	14 (36.8)	< 0.001	58 (85.3)	18 (45.0)	< 0.001
o/e-ContFLV	0.52 ± 0.16	0.45 ± 0.10	0.67 ± 0.15	< 0.001	0.47 ± 0.13	0.61 ± 0.16	< 0.001
o/e-TotFLV	0.33 ± 0.13	0.26 ± 0.07	0.45 ± 0.12	< 0.001	0.28 ± 0.11	0.40 ± 0.12	< 0.001
US-FLW	0.011 ± 0.008	0.009 ± 0.001	0.014 ± 0.003	0.005	0.010 ± 0.002	0.013 ± 0.004	0.01
o/e-ContPA	0.71 ± 0.13	0.66 ± 0.13	0.79 ± 0.08	< 0.001	0.66 ± 0.13	0.78 ± 0.08	< 0.001
o/e-MPA	0.82 ± 0.18	0.75 ± 0.16	0.95 ± 0.11	< 0.001	0.75 ± 0.17	0.95 ± 0.11	< 0.001
Cont-VI	19.9 ± 11.9	13.4 ± 5.4	31.9 ± 11.3	< 0.001	13.4 ± 5.00	30.94 ± 12.12	< 0.001
GA at birth (weeks)	37.3 ± 1.9	37.2 ± 1.3	37.3 ± 1.7	0.93	37.3 ± 1.7	37.2 ± 1.2	0.86
Birth weight (g)	3016.2 ± 469.7	2995.7 ± 405.8	3067.7 ± 482.2	0.55	3084.1 ± 474.1	2966.9 ± 443.9	0.32

Data given as mean ± SD or n (%). ContFLV, contralateral fetal lung volume ratio; ContPA, contralateral pulmonary artery diameter ratio; Cont-VI, vascularization index of the contralateral lung; GA, gestational age; LHR, lung-to-head ratio; Liver-up, > 1/3 of liver herniated into the fetal thorax; MPA, main pulmonary artery diameter ratio; o/e, observed/expected; PAH, pulmonary arterial hypertension; TotFLV, total fetal lung volume; US-FLW, ultrasonographic fetal lung volume/fetal weight ratio.

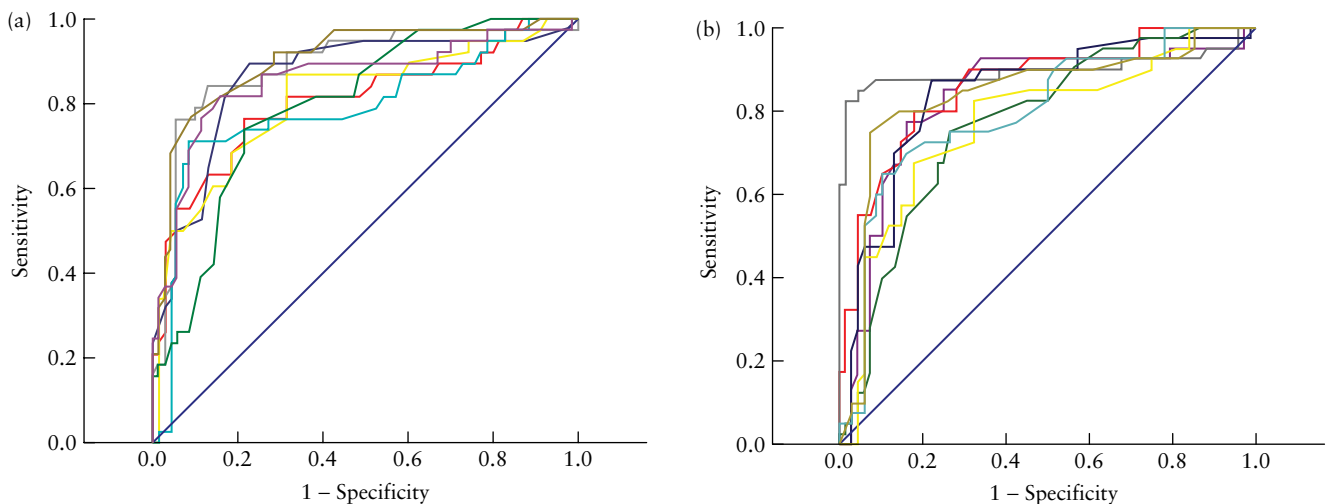


Figure 1 Receiver–operating characteristics curves for the prediction of neonatal death (a) and postnatal severe pulmonary arterial hypertension (b) using different lung parameters: —, LHR; —, o/e-LHR; —, o/e-TotFLV; —, o/e-ContFLV; —, US-FLW; —, o/e-MPA; —, o/e-ContPA; —, Cont-VI; —, Reference line. (LHR, lung-to-head ratio; ContFLV, contralateral fetal lung volume; ContPA, contralateral pulmonary artery diameter; Cont-VI, vascularization index of the contralateral lung; MPA, main pulmonary artery diameter; o/e, observed/expected; TotFLV, total fetal lung volume; US-FLW, ultrasonographic fetal lung volume/fetal weight).

that measures lung size (LHR, o/e-LHR, o/e-ContFLV, o/e-TotFLV or US-FLW) and the presence/absence of liver herniation, and one parameter that measures pulmonary vascularity (Cont-VI or o/e-MPA). ROC curves of the combined variables are shown in Figure 2 and results are presented in Tables S4 and S5. There was no statistically significant difference between these different combinations for the prediction of neonatal survival or postnatal diagnosis of severe PAH ($P > 0.05$).

Based on the probability estimations of neonatal survival and postnatal diagnosis of PAH using these ultrasound parameters (Tables S2–S5), isolated CDH

could be classified into four groups: extremely severe, severe, moderate and mild (Table 2). In our present series, the vast majority (almost 50%) of cases had severe CDH.

DISCUSSION

Many different methods have been proposed to estimate fetal lung size^{6,13,21,22,33–35}. The method used most widely is LHR, which is an uncomplicated means of measuring the contralateral lung size. However, some authors have suggested that LHR may vary throughout gestation^{34,36,37}, and so o/e-LHR was proposed, which

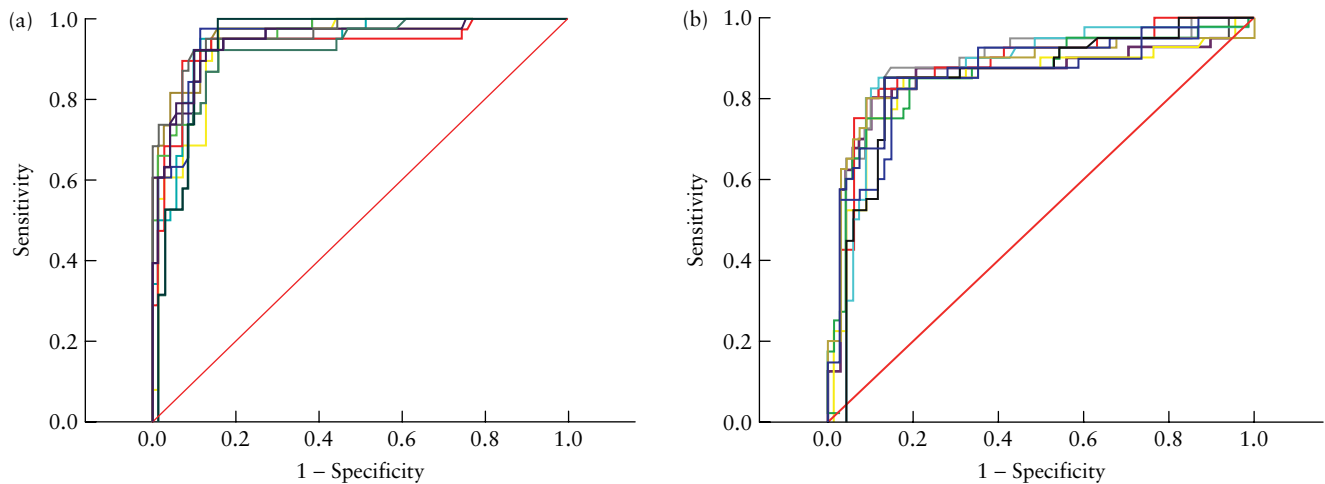


Figure 2 Receiver–operating characteristics curves for the prediction of neonatal death (a) and postnatal severe pulmonary arterial hypertension (b) using the combination of different lung parameters: —, LHR+Liver-up+Cont-VI; —, o/e-LHR+Liver-up+Cont-VI; —, o/e-ContFLV+Liver-up+Cont-VI; —, o/e-TotFLV+Liver-up+Cont-VI; —, US-FLW+Liver-up+Cont-VI; —, LHR+Liver-up+o/e-MPA; —, o/e-LHR+Liver-up+o/e-MPA; —, o/e-ContFLV+Liver-up+o/e-MPA; —, o/e-TotFLV+Liver-up+o/e-MPA; —, US-FLW+Liver-up+o/e-MPA; —, Reference line. (LHR, lung-to-head ratio; ContFLV, contralateral fetal lung volume; Cont-VI, vascularization index of the contralateral lung; Liver-up, > 1/3 of liver herniated into the fetal thorax; MPA, main pulmonary artery diameter; o/e, observed/expected; TotFLV, total fetal lung volume; US-FLW, ultrasonographic fetal lung volume/fetal weight).

Table 2 Classification and ultrasonographic parameters of 108 fetuses with isolated congenital diaphragmatic hernia (CDH), based on their probabilities of surviving and of having severe pulmonary arterial hypertension (PAH)*

Parameter	Prenatal classification of CDH			
	Extremely severe	Severe	Moderate	Mild
Probability of survival (%; mean (range))	5 (0–10)	15 (10–30)	50 (30–80)	90 (80–100)
Probability of severe PAH (%; mean (range))	> 70.0	60 (50–70)	45 (20–50)	< 20
Classification (<i>n</i> (%))	11 (10.2)	48 (44.4)	30 (27.8)	19 (17.6)
LHR	< 0.70	0.70–1.14	1.15–1.90	> 1.90
o/e-LHR (%)	< 15	15–26	27–45	> 45
o/e-ContFLV	< 0.48	0.48–0.51	0.52–0.60	> 0.60
o/e-TotFLV	< 0.29	0.29–0.31	0.32–0.39	> 0.39
US-FLW	< 0.009	0.009–0.010	0.011–0.013	> 0.013
o/e-ContPA	< 0.66	0.66–0.70	0.71–0.85	> 0.85
o/e-MPA	< 0.75	0.75–0.81	0.82–1.02	> 1.02
Cont-VI	< 15	15–18	19–28	> 28

Data given as range unless stated otherwise. *Probabilities estimated from equations in Tables S2–S5. ContFLV, contralateral fetal lung volume; ContPA, contralateral pulmonary artery diameter; Cont-VI, vascularization index of the contralateral lung; LHR, lung-to-head ratio; MPA, main pulmonary artery diameter; o/e, observed/expected; TotFLV, total fetal lung volume; US-FLW, ultrasonographic fetal lung volume/fetal weight.

is adjusted according to gestational age^{6,38}. These two methods use 2D ultrasound technology. In our present study, the gestational age at ultrasound examination did not vary considerably (from 26 to 30 weeks), so it is possible that LHR did not vary much within this narrow age range. Fetal lung volumes can be measured using magnetic resonance imaging (MRI) or 3D ultrasound^{10,13,14,20,35,39–42}. Since fetal lung volumes vary throughout gestation, they should be adjusted either to expected values according to gestational age or to estimated fetal weight^{19,20}. It has been demonstrated that the lung ipsilateral to the diaphragmatic defect is more hypoplastic than is the contralateral one, which suggests that evaluation of both lungs may better estimate the

degree of pulmonary hypoplasia in isolated CDH^{14–16,43}. We found that measuring total lung volumes (o/e-TotFLV and US-FLW) predicted neonatal outcome more accurately than did using the contralateral lung measurements (LHR, o/e-LHR and o/e-ContFLV).

Fetal pulmonary vascularity in isolated CDH can be evaluated by measuring pulmonary artery diameters on 2D ultrasound, studying pulmonary arterial flow using 2D color Doppler or estimating the vascular indices using 3D power Doppler ultrasonography^{18,26,44,45}. Our study confirmed that evaluation of fetal pulmonary vasculature is useful in the prediction of severe PAH and therefore of neonatal death. The better prediction of neonatal outcomes in isolated CDH by the VI compared with the

pulmonary arterial diameters may be explained by the fact that the VI evaluates the vascularity of an entire organ (pulmonary function) while the PA diameters may be more related to pulmonary vessel and lung size.

In this study, we established mathematical equations to calculate the probabilities of the events (neonatal survival/death and severe PAH) by using ultrasound parameters associated with neonatal outcome. Based on these equations, fetuses with isolated CDH were classified according to the prognosis into four groups: those with extremely severe, severe, moderate and mild CDH. The importance of classifying CDH according to severity is that this can be used to guide perinatal management. Fetuses with mild CDH have more than an 80% chance of survival and less than a 20% chance of presenting with severe postnatal PAH, while those with moderate CDH have an approximately 50% chance for each. In both of these cases, postnatal therapy in a specialized center is recommended, while fetal intervention is not. For severe CDH, with an approximately 15% chance of survival and higher than 60% chance of presenting with PAH, fetal tracheal occlusion has been proposed as a therapeutic option^{46,47}. Our initial study demonstrated a potential benefit for fetal tracheal occlusion in severe CDH by improving the survival rate from 5% in non-treated fetuses to 50% after fetal intervention⁴⁶, and these findings have been recently confirmed in a randomized trial⁴⁸. Another therapeutic option for severe CDH is the use of ECMO. However, the benefits of ECMO in such cases need to be evaluated.

This classification also allows comparison of neonatal mortality rates between different centers by matching for severity of the CDH. For example, in our present series, the mortality rate was extremely high (64.8%) when compared with other centers^{6,49,50}. However, a large proportion (54.6%) of cases in our series had severe or extremely severe CDH. This can be explained by the fact that in our series there were no terminations of pregnancy or fetal interventions. Furthermore, this series represents cases diagnosed prenatally, many of which were referred to our center due to their severity because we offer fetal therapy for severe CDH (on a referral bias).

In our study, fetuses with right and left CDH were analyzed together since the aim of the present study was to evaluate whether right-sided CDH had worse prognosis than left-sided defect. However, our results demonstrated that right-sided CDH was not associated statistically with poor neonatal outcome, which is not in accordance with other studies^{47,51}. In our opinion, the herniated liver, reduced lung sizes and decreased vascularity are factors related directly to the neonatal outcomes in isolated CDH independent of the side of the defect. Perhaps previous studies did not consider this fact and the right-sided CDH was considered to have poor prognosis, but in reality these cases had liver herniated into fetal thorax, reduced lung sizes and decreased pulmonary vascularity.

In conclusion, neonatal outcome in fetuses with isolated CDH can be predicted by evaluating the lung size, confirming a herniated liver and analyzing the pulmonary

vasculature. Measuring the total lung volumes (o/e-TotFLV) more accurately predicts neonatal outcome than does measuring only the contralateral lung size (LHR, o/e-LHR and o/e-ContFLV). The prediction of neonatal outcome is more accurate by evaluating the pulmonary vasculature using the VI on 3D power Doppler ultrasound, since it is related more to the postnatal diagnosis of severe PAH, which may be the main cause of death in newborns with isolated CDH. The present study provides mathematical equations to calculate the probabilities of survival/death and severe PAH, which allows classification of affected fetuses according to severity of CDH. This suggested classification may guide the perinatal management of fetuses with isolated CDH and may allow a better comparison between results in different centers.

ACKNOWLEDGMENT

This study was funded by the FAPESP (Fundação de Amparo à Pesquisa do Estado de São Paulo).

REFERENCES

1. Cannie MM, Jani JC, De Keyzer F, Allegaert K, Dymarkowski S, Deprest J. Evidence and patterns in lung response after fetal tracheal occlusion: clinical controlled study. *Radiology* 2009; **252**: 526–533.
2. Deprest J, Gratacos E, Nicolaidis KH. Fetoscopic tracheal occlusion (FETO) for severe congenital diaphragmatic hernia: evolution of a technique and preliminary results. *Ultrasound Obstet Gynecol* 2004; **24**: 121–126.
3. Deprest JA, Evrard VA, Verbeken EK, Perales AJ, Delaere PR, Lerut TE, Flageole H. Tracheal side effects of endoscopic balloon tracheal occlusion in the fetal lamb model. *Eur J Obstet Gynecol Reprod Biol* 2000; **92**: 119–126.
4. Doné E, Gucciardo L, Van Mieghem T, Jani J, Cannie M, Van Schoubroeck D, Devlieger R, Catte LD, Klaritsch P, Mayer S, Beck V, Debeer A, Gratacos E, Nicolaidis K, Deprest J. Prenatal diagnosis, prediction of outcome and in utero therapy of isolated congenital diaphragmatic hernia. *Prenat Diagn* 2008; **28**: 581–591.
5. Deprest JA, Hyett JA, Flake AW, Nicolaidis K, Gratacos E. Current controversies in prenatal diagnosis 4: Should fetal surgery be done in all cases of severe diaphragmatic hernia? *Prenat Diagn* 2009; **29**: 15–19.
6. Jani J, Nicolaidis KH, Keller RL, Benachi A, Peralta CF, Favre R, Moreno O, Tibboel D, Lipitz S, Eggink A, Vaast P, Allegaert K, Harrison M, Deprest J; Antenatal-CDH-Registry Group. Observed to expected lung area to head circumference ratio in the prediction of survival in fetuses with isolated diaphragmatic hernia. *Ultrasound Obstet Gynecol* 2007; **30**: 67–71.
7. Deprest JA, Flemmer AW, Gratacos E, Nicolaidis K. Antenatal prediction of lung volume and in-utero treatment by fetal endoscopic tracheal occlusion in severe isolated congenital diaphragmatic hernia. *Semin Fetal Neonatal Med* 2009; **14**: 8–13.
8. Balassy C, Kasprian G, Brugger PC, Weber M, Csapo B, Herold C, Prayer D. Assessment of lung development in isolated congenital diaphragmatic hernia using signal intensity ratios on fetal MR imaging. *Eur Radiol* 2010; **20**: 829–837.
9. Cannie M, Jani J, Chaffiotte C, Vaast P, Deruelle P, Houfflin-Debarge V, Dymarkowski S, Deprest J. Quantification of intrathoracic liver herniation by magnetic resonance imaging and prediction of postnatal survival in fetuses with congenital

- diaphragmatic hernia. *Ultrasound Obstet Gynecol* 2008; **32**: 627–632.
10. Cannie M, Jani J, Meerschaert J, Allegaert K, Done' E, Marchal G, Deprest J, Dymarkowski S. Prenatal prediction of survival in isolated diaphragmatic hernia using observed to expected total fetal lung volume determined by magnetic resonance imaging based on either gestational age or fetal body volume. *Ultrasound Obstet Gynecol* 2008; **32**: 633–639.
 11. Cannie M, Jani JC, De Keyzer F, Devlieger R, Van Schoubroeck D, Witters I, Marchal G, Dymarkowski S, Deprest JA. Fetal body volume: use at MR imaging to quantify relative lung volume in fetuses suspected of having pulmonary hypoplasia. *Radiology* 2006; **241**: 847–853.
 12. Jani J, Cannie M, Sonigo P, Robert Y, Moreno O, Benachi A, Vaast P, Gratacos E, Nicolaides KH, Deprest J. Value of prenatal magnetic resonance imaging in the prediction of postnatal outcome in fetuses with diaphragmatic hernia. *Ultrasound Obstet Gynecol* 2008; **32**: 793–799.
 13. Mahieu-Caputo D, Sonigo P, Dommergues M, Fournet JC, Thalabard JC, Abarca C, Benachi A, Brunelle F, Dumez Y. Fetal lung volume measurement by magnetic resonance imaging in congenital diaphragmatic hernia. *BJOG* 2001; **108**: 863–868.
 14. Ruano R, Aubry MC, Barthe B, Dumez Y, Benachi A. Three-dimensional ultrasonographic measurements of the fetal lungs for prediction of perinatal outcome in isolated congenital diaphragmatic hernia. *J Obstet Gynaecol Res* 2009; **35**: 1031–1041.
 15. Ruano R, Aubry MC, Barthe B, Dumez Y, Zugaib M, Benachi A. Ipsilateral lung volumes assessed by three-dimensional ultrasonography in fetuses with isolated congenital diaphragmatic hernia. *Fetal Diagn Ther* 2008; **24**: 389–394.
 16. Ruano R, Aubry MC, Barthe B, Dumez Y, Zugaib M, Benachi A. Three-dimensional sonographic measurement of contralateral lung volume in fetuses with isolated congenital diaphragmatic hernia. *J Clin Ultrasound* 2008; **36**: 273–278.
 17. Ruano R, Aubry MC, Barthe B, Mitanchez D, Dumez Y, Benachi A. Quantitative analysis of fetal pulmonary vasculature by 3-dimensional power Doppler ultrasonography in isolated congenital diaphragmatic hernia. *Am J Obstet Gynecol* 2006; **195**: 1720–1728.
 18. Ruano R, Aubry MC, Barthe B, Mitanchez D, Dumez Y, Benachi A. Predicting perinatal outcome in isolated congenital diaphragmatic hernia using fetal pulmonary artery diameters. *J Pediatr Surg* 2008; **43**: 606–611.
 19. Ruano R, Aubry MC, Dumez Y, Zugaib M, Benachi A. Predicting neonatal deaths and pulmonary hypoplasia in isolated congenital diaphragmatic hernia using the sonographic fetal lung volume-body weight ratio. *AJR Am J Roentgenol* 2008; **190**: 1216–1219.
 20. Ruano R, Benachi A, Joubin L, Aubry MC, Thalabard JC, Dumez Y, Dommergues M. Three-dimensional ultrasonographic assessment of fetal lung volume as prognostic factor in isolated congenital diaphragmatic hernia. *BJOG* 2004; **111**: 423–429.
 21. Lipshutz GS, Albanese CT, Feldstein VA, Jennings RW, Housley HT, Beech R, Farrell JA, Harrison MR. Prospective analysis of lung-to-head ratio predicts survival for patients with prenatally diagnosed congenital diaphragmatic hernia. *J Pediatr Surg* 1997; **32**: 1634–1636.
 22. Metkus AP, Filly RA, Stringer MD, Harrison MR, Adzick NS. Sonographic predictors of survival in fetal diaphragmatic hernia. *J Pediatr Surg* 1996; **31**: 148–151; discussion 51–52.
 23. Jani J, Peralta CF, Benachi A, Deprest J, Nicolaides KH. Assessment of lung area in fetuses with congenital diaphragmatic hernia. *Ultrasound Obstet Gynecol* 2007; **30**: 72–76.
 24. Ruano R, Joubin L, Aubry MC, Thalabard JC, Dommergues M, Dumez Y, Benachi A. A nomogram of fetal lung volumes estimated by 3-dimensional ultrasonography using the rotational technique (virtual organ computer-aided analysis). *J Ultrasound Med* 2006; **25**: 701–709.
 25. Ruano R, Martinovic J, Dommergues M, Aubry MC, Dumez Y, Benachi A. Accuracy of fetal lung volume assessed by three-dimensional sonography. *Ultrasound Obstet Gynecol* 2005; **26**: 725–730.
 26. Sokol J, Bohn D, Lacro RV, Ryan G, Stephens D, Rabinovitch M, Smallhorn J, Hornberger LK. Fetal pulmonary artery diameters and their association with lung hypoplasia and postnatal outcome in congenital diaphragmatic hernia. *Am J Obstet Gynecol* 2002; **186**: 1085–1090.
 27. Ruano R, de Fatima Yukie Maeda M, Niigaki JI, Zugaib M. Pulmonary artery diameters in healthy fetuses from 19 to 40 weeks' gestation. *J Ultrasound Med* 2007; **26**: 309–316.
 28. Mitanchez D. [Antenatal treatment of congenital diaphragmatic hernia: an update]. *Arch Pediatr* 2008; **15**: 1320–1325.
 29. Roofthoof MT, Bergman KA, Waterbolk TW, Ebels T, Bartelds B, Berger RM. Persistent pulmonary hypertension of the newborn with transposition of the great arteries. *Ann Thorac Surg* 2007; **83**: 1446–1450.
 30. DeLong ER, DeLong DM, Clarke-Pearson DL. Comparing the areas under two or more correlated receiver operating characteristic curves: a nonparametric approach. *Biometrics* 1988; **44**: 837–845.
 31. Hanley JA, McNeil BJ. A method of comparing the areas under receiver operating characteristic curves derived from the same cases. *Radiology* 1983; **148**: 839–843.
 32. McNeil BJ, Hanley JA, Funkenstein HH, Wallman J. Paired receiver operating characteristic curves and the effect of history on radiographic interpretation. CT of the head as a case study. *Radiology* 1983; **149**: 75–77.
 33. Jani J, Peralta CF, Van Schoubroeck D, Deprest J, Nicolaides KH. Relationship between lung-to-head ratio and lung volume in normal fetuses and fetuses with diaphragmatic hernia. *Ultrasound Obstet Gynecol* 2006; **27**: 545–550.
 34. Odibo AO, Biron-Shental T, Tomlinson TM, Shim TL, Wanat K. Predictive value of lung-head ratio in congenital diaphragmatic hernia: a study by Yang, et al. *Am J Obstet Gynecol* 2007; **197**: 110–111.
 35. Paek BW, Coakley FV, Lu Y, Filly RA, Lopoo JB, Qayyum A, Harrison MR, Albanese CT. *Radiology* 2001; **220**: 63–67.
 36. Arkovitz MS, Russo M, Devine P, Budhorick N, Stolar CJ. Fetal lung-head ratio is not related to outcome for antenatal diagnosed congenital diaphragmatic hernia. *J Pediatr Surg* 2007; **42**: 107–110.
 37. Bretelle F, Mazouni C, D'Ercole C, Chaumoitre K, Chau C, Desbrieres R. Fetal lung-head ratio measurement in the evaluation of congenital diaphragmatic hernia. *J Pediatr Surg* 2007; **42**: 1312–1313.
 38. Al-Assiri A, Wiseman N, Bunge M. Prenatal diagnosis of intrathoracic stomach (gastric herniation). *J Pediatr Surg* 2005; **40**: E15–E17.
 39. Ahn HY, Shin JC, Kim YH, Ko HS, Park IY, Kim SJ, Rha JG, Kim SP. Prenatal diagnosis of congenital diaphragmatic hernia in a fetus with 46,XY/46,X,-Y,+der(Y)t(Y; 1)(q12; q12) mosaicism: a case report. *J Korean Med Sci* 2005; **20**: 895–898.
 40. Jani J, Cannie M, Done E, Van Mieghem T, Van Schoubroeck D, Gucciardo L, Dymarkowski S, Deprest JA. Relationship between lung area at ultrasound examination and lung volume assessment with magnetic resonance imaging in isolated congenital diaphragmatic hernia. *Ultrasound Obstet Gynecol* 2007; **30**: 855–860.
 41. Jani JC, Cannie M, Peralta CF, Deprest JA, Nicolaides KH, Dymarkowski S. Lung volumes in fetuses with congenital diaphragmatic hernia: comparison of 3D US and MR imaging assessments. *Radiology* 2007; **244**: 575–582.
 42. Ruano R, Joubin L, Sonigo P, Benachi A, Aubry MC, Thalabard JC, Brunelle F, Dumez Y, Dommergues M. Fetal lung volume estimated by 3-dimensional ultrasonography and magnetic resonance imaging in cases with isolated congenital diaphragmatic hernia. *J Ultrasound Med* 2004; **23**: 353–358.

43. Peralta CF, Jani J, Cos T, Nicolaides KH, Deprest J. Left and right lung volumes in fetuses with diaphragmatic hernia. *Ultrasound Obstet Gynecol* 2006; 27: 551–554.
44. Moreno-Alvarez O, Hernandez-Andrade E, Oros D, Jani J, Deprest J, Gratacos E. Association between intrapulmonary arterial Doppler parameters and degree of lung growth as measured by lung-to-head ratio in fetuses with congenital diaphragmatic hernia. *Ultrasound Obstet Gynecol* 2008; 31: 164–170.
45. Mahieu-Caputo D, Aubry MC, El Sayed M, Joubin L, Thalabard JC, Dommergues M. Evaluation of fetal pulmonary vasculature by power Doppler imaging in congenital diaphragmatic hernia. *J Ultrasound Med* 2004; 23: 1011–1017.
46. Ruano R, Duarte SA, Pimenta EJ, Takashi E, da Silva MM, Tannuri U, Zugaib M. Comparison between fetal endoscopic tracheal occlusion using a 1.0-mm fetoscope and prenatal expectant management in severe congenital diaphragmatic hernia. *Fetal Diagn Ther* 2011; 29: 64–70.
47. Jani JC, Nicolaides KH, Gratacós E, Valencia CM, Doné E, Martínez JM, Gucciardo L, Cruz R, Deprest JA. Severe diaphragmatic hernia treated by fetal endoscopic tracheal occlusion. *Ultrasound Obstet Gynecol* 2009; 34: 304–310.
48. Ruano R, Yoshisaki CT, da Silva MM, Ceccon MEJ, Grasi MS, Tannuri U, Zugaib M. A randomized controlled trial of fetal endoscopic tracheal occlusion versus postnatal management of severe isolated congenital diaphragmatic hernia. *Ultrasound Obstet Gynecol* 2012; 39: 20–27.
49. Hedrick HL. Management of prenatally diagnosed congenital diaphragmatic hernia. *Semin Fetal Neonatal Med* 2010; 15: 21–27.
50. Hedrick HL, Danzer E, Merchant A, Bebbington MW, Zhao H, Flake AW, Johnson MP, Liechty KW, Howell LJ, Wilson RD, Adzick NS. Liver position and lung-to-head ratio for prediction of extracorporeal membrane oxygenation and survival in isolated left congenital diaphragmatic hernia. *Am J Obstet Gynecol* 2007; 197: 422.e1–4.
51. Hedrick HL, Crombleholme TM, Flake AW, Nance ML, von Allmen D, Howell LJ, Johnson MP, Wilson RD, Adzick NS. Right congenital diaphragmatic hernia: prenatal assessment and outcome. *J Pediatr Surg* 2004; 39: 319–323.

SUPPORTING INFORMATION ON THE INTERNET

The following supporting information may be found in the online version of this article:



Table S1 Correlations between ultrasonographic parameters in 108 fetuses with isolated CDH

Table S2 Prediction of neonatal death using multiple ultrasound parameters in 108 fetuses with CDH

Table S3 Prediction of severe PAH using multiple ultrasound parameters in 108 fetuses with CDH

Table S4 Prediction of neonatal death using the combination of multiple ultrasound parameters in 108 fetuses with CDH

Table S5 Prediction of severe pulmonary arterial hypertension using the combination of multiple ultrasound parameters in 108 fetuses with CDH