European Heart Journal (2002) **23,** 124–132
doi:10.1053/euhj.2001.2707, available online at http://www.idealibrary.com on IDEAL®

Predictors and outcomes of stent thrombosis

An intravascular ultrasound registry

N. G. Uren, S. P. Schwarzacher, J. A. Metz, D. P. Lee, Y. Honda, A. C. Yeung, P. J. Fitzgerald and P. G. Yock, on behalf of the POST Registry investigators

Division of Cardiovascular Medicine, Stanford University School of Medicine, Stanford, California, U.S.A.

Aims To investigate whether intravascular ultrasound provides additional information regarding the prediction of stent thrombosis, a retrospective multicentre registry was designed to enrol patients with stent thrombosis following stent deployment under ultrasound guidance.

Methods and Results A total of 53 patients were enrolled (mean age 61 ± 9 years) with stable angina (43%), unstable angina (36%), and post-infarct angina (21%) who underwent intracoronary stenting. The majority had balloon angioplasty alone prior to stenting (94%) with 6% also undergoing rotational atherectomy. The indication for stenting was elective (53%), suboptimal result (32%) and bailout (15%). There were 1·6 ± 0·8 stents/artery with 87% undergoing high-pressure dilatation (≥14 atmospheres). The minimum stent area was 7·7 ± 2·8 mm^2 with a mean stent expansion of 81·5 ± 21·9%. Overall, 94% of cases demonstrated one abnormal ultrasound finding (stent under-expansion, malapposition, inflow/outflow disease, dissection, or thrombus). Angiography demonstrated an abnormality in only 32% of cases (chi-square = 30·0, P<0·001). Stent thrombosis occurred at 132 ± 125 h after deployment. Myocardial infarction occurred in 67% and there was an overall mortality of 15%.

Conclusion On comparison with angiography, the vast majority of stents associated with subsequent thrombosis have at least one abnormal feature by intravascular ultrasound at the time of stent deployment.
(Eur Heart J 2002; 23: 124–132, doi:10.1053/euhj.2001.2707)

Key Words: Intravascular ultrasound, intracoronary stents, thrombosis.

See page 97, doi:10.1053/euhj.2001.2810 for the Editorial comment on this article

Introduction

Although the incidence of stent thrombosis has diminished with improvement in stent design, deployment, and adjunctive pharmacology, it continues to occur in up to 1·9% of cases with a high associated morbidity and mortality[1–5]. At the current world-wide level of intracoronary stenting with this incidence, stent thrombosis may occur in up to 12 000 patients per year. There are several clinical, lesion-related, stent-related and technique-dependent predictors of stent thrombosis which have come from retrospective analysis of single centre stent experience in recent years. However, there are no current multicentre trial data available to allow confident prediction of this event in any individual patient. The initial use of intravascular ultrasound to deploy the Palmaz–Schatz stent and newer generation stents has contributed to improved stent deployment through appropriate balloon sizing and the use of high-pressure dilatation to achieve full stent expansion, complete apposition to the vessel wall, and full lesion coverage[1]. However, it is not certain whether the qualitative information derived from ultrasound analysis of a deployed stent will provide additional features predictive of subsequent stent thrombosis. Thus, this retrospective registry was designed to collect clinical, angiographic and ultrasound data on patients undergoing stent deployment who went on to sustain a stent thrombosis, with additional data on the specific treatment and outcomes of this event.

Revision submitted 27 March 2001, accepted 28 March 2001, and published online 2 October 2001.

Correspondence: Neal Uren MD MRCP FESC, Department of Cardiology, Royal Infirmary, 1 Lauriston Place, Edinburgh EH3 9YW, U.K.

0195-668X/02/020124+09 $35.00/0

Methods

Study design

The Predictors and Outcomes of Stent Thrombosis (POST) Registry was designed to identify the intravascular ultrasound predictors of acute (<24 h) and subacute (24 h to 4 weeks) stent thrombosis. This multicentre, retrospective registry enrolled cases from 1991 to 1996 from North America, Europe and Japan (see Appendix). After enrolment, cases of stent thrombosis were identified where intravascular ultrasound was used during deployment and analysis was based on a clinical registry compiled from case report forms, intravascular ultrasound imaging tapes and angiograms at deployment.

Inclusion criteria

Inclusion criteria for the registry were intentionally broad to maximize enrolment. All clinical presentations including elective or emergency stent deployment were included. Single and multiple stents of all stent types were enrolled. Pre-stent treatment with any transcatheter therapy was allowed. The major criterion was that an intravascular ultrasound examination was performed post-deployment and that images were of sufficient quality to be interpreted by the core laboratory. A total of nine participating centres from North America, seven from Europe and two from Japan contributed cases to the study. A total of 53 cases of stent thrombosis fulfilled the inclusion criteria and were enrolled in the registry.

Case report forms were designed to include three sections: (i) clinical details, (ii) procedure details, and (iii) outcome and treatment of stent thrombosis. In addition, details of the daily course of antiplatelet and antithrombotic therapy were documented on a separate clinical report form. From these data, the clinical details of the initial interventional case was determined and analysed.

Intravascular ultrasound analysis

Intravascular ultrasound image analysis was undertaken at the Quantitative Coronary Ultrasound laboratory at Stanford University, California. Several quantitative and qualitative criteria were determined with respect to the deployed stent(s) and reference vessels proximal and distal to the stent using the TapeMeasure 2.1.0 analysis program (Indec Systems, Mountain View, CA, U.S.A.) by at least two independent observers. The final intravascular ultrasound run at the end of the procedure was selected as the imaging sequence for analysis. Vessel, lumen and plaque area were drawn by planimetry proximal and distal to the stent in the most normal frame within 5 mm of the stent edges. Stent area was determined by planimetry at the distal and proximal stent edges as well as at the minimum stent cross-sectional area. Stent under-expansion was defined as minimum stent area <80% of mean proximal and distal reference lumen areas. Stent deployment was also assessed according to the MUSIC criteria, namely, complete apposition and expansion (minimum stent area [MSA] >90% average of proximal/distal segments or MSA >100% of lowest reference segment or MSA >90% proximal segment, revised to 80%, 90%, 80% respectively if MSA >9 mm^2)[6].

The definition chosen for significant inflow disease was that the proximal reference lumen area was less than the distal reference lumen area in the presence of $\geq$40% plaque area in either segment. Outflow disease was defined as the presence of plaque $\geq$40% vessel area. The presence of calcium and the plaque morphology (fibrous, fibro-fatty or fibro-calcific) in the reference segments was also documented. Residual dissection or edge tears were defined as a visible flap outside stent edges with blood speckle behind the intimal flap or at mid-stent articulation for the Palmaz–Schatz design when present. Malapposition was identified by recognition of a relatively echo-free space between the struts and intima with evidence of blood speckle. Plaque protrusion was defined as visible tissue on the luminal side of the stent struts, but lacking any of the identifying characteristics of thrombus. Thrombus was defined as the presence of tissue within but adherent to the stent with an ultrasound intensity less than half of the adventitial signal. When present, a scintillating appearance, a lobular irregular edge, microchannels and/or movement in an undulating manner separate from the artery confirmed the presence of thrombus.

In order to compare the data from the POST registry with comparable control data, qualitative and quantitative ultrasound variables from one registry of intravascular ultrasound-guided stenting and two prospective studies of intravascular ultrasound-guided against angiography-guided stenting were used. Four variables — percent stent expansion, malapposition, edge tears/dissection, and thrombus — from POST were compared with the equivalent ultrasound parameters from three other studies. These were (1) STRUT (Stent Treatment Region assessed by Ultrasound Tomography)[7], which was a multicentre registry of intravascular ultrasound-guided stenting in clinical practice, (2) CRUISE (Can Routine Ultrasound Influence Stent Expansion)[8], which was a prospective randomized multicentre trial of intravascular ultrasound-guided vs angiography-guided stenting with clinical follow-up, and (3) AVID (Angiography Versus Intravascular ultrasound Directed stent placement)[9], which was a randomised trial similar to CRUISE. These three studies were selected by the POST investigators for comparison as the ultrasound analysis was also performed by the same ultrasound core lab (Center for Research in Cardiovascular Interventions, Stanford University Hospital, CA, U.S.A.).

Table 1 Population demographics

	Number	Percentage
Extent of disease		
1 vessel	19	36%
2 vessel	19	36%
3 vessel	15	28%
Clinical presentation		
Stable angina	23	43%
Unstable angina	19	36%
Post-MI angina	11	21%
Stent indication		
Elective	29	53%
Suboptimal result	17	32%
Bailout	7	15%

Table 2 Lesion and stent characteristics

	Number	Percentage
ACC/AHA lesion class		
A	2	4%
B1	17	32%
B2	15	28%
C	19	36%
Artery		
LAD	26	49%
CFX	10	19%
RCA	13	24%
Saphenous vein graft	4	8%
Lesion segment		
Proximal	32	60%
Mid	16	30%
Distal	3	6%
2 segments	2	4%
Number of stents		
One	32	60%
Two	12	23%
Three or more	9	17%
High pressure deployment ($\geq$14 atm)	46	87%
Stent type		
Palmaz–Schatz	40	76%
Palmaz–Schatz+other	5	9%
Other stent	8	15%

ACC/AHA=American College of Cardiology/American Heart Association; LAD=left anterior descending artery; CFX=left circumflex artery; RCA=right coronary artery.

Coronary angiography analysis

Angiographic image analysis was performed at the Quantitative Coronary Angiography laboratory at Stanford University Hospital. The angiographic runs selected were a composite of the views taken at the end of the procedure and analysed by an independent observer (D.L.) blinded to the intravascular ultrasound images during the case. Whether or not a residual diameter stenosis of 0% or less was achieved was determined by visual assessment. At angiography, inflow/outflow disease was defined as a diameter stenosis >50% immediately proximal or distal to the stent edges and other definitions used were standard. Filling defects and all dissections visible angiographically were described.

Statistical analysis

Comparable dichotomous qualitative data for ultrasound and angiography were analysed using McNemar's test. Individual ultrasound variables were compared with existing data using the chi-square method with Yates' correction where appropriate. Comparison of continuous variables in the acute and subacute stent thrombosis groups was done using an unpaired Student's t test. A P value of less than 5% was considered statistically significant.

Results

Patient and lesion demographics

The clinical characteristics of the patients enrolled in the study and the coronary artery lesion undergoing intervention and subsequent analysis are described in Tables 1 and 2. The mean age of patients was 61 ± 9 years and the left ventricular ejection function was 55 ± 16%. The majority of patients in the study had an unstable coronary syndrome and just under two-thirds of patients had complex lesions of AHA/ACC class B2 and C. Ninety percent of stents were deployed in the proximal or mid segments of the vessel with the remainder deployed in distal arteries or across two segments. The majority of patients had a single stent deployment with the maximum number deployed being four. The mean number of stents per artery was 1·6 with a median of 1. Six percent of patients had high-speed rotational atherectomy prior to stenting with the remaining 94% having balloon angioplasty alone.

Post-procedure antithrombotic and antiplatelet therapy in the registry reflects the fact that patients were enrolled over a period of 5 years with an evolving protocol of antithrombotic management after stent deployment. All but three patients had oral aspirin following stent deployment, with 40% having aspirin alone as therapy (n=21, 6 of whom also had warfarin). The remaining 54% (n=29) received ticlopidine and aspirin for at least 4 weeks following stenting.

Stent deployment by intravascular ultrasound

Intravascular ultrasound measurements are given in Table 3. By ultrasound, average percent expansion was 82% of average reference lumen area, 91% of distal reference lumen area, and 76% of proximal reference lumen area. Given that the mean minimum stent area

Table 3 Intravascular ultrasound assessment

	Mean ± SD	Range
Distal reference segment		
Vessel area (mm^2)	16·1 ± 7·8	6·5–52·4
Minimum diameter (mm)	4·1 ± 1·1	2·5–7·7
Maximum diameter (mm)	4·7 ± 1·1	3·0–8·6
Lumen area (mm^2)	9·2 ± 4·7	2·7–33·4
Minimum diameter (mm)	3·0 ± 0·7	1·7–6·1
Maximum diameter (mm)	3·6 ± 0·8	1·9–6·9
Plaque area (mm^2)	6·8 ± 4·3	0–19·0
Distal stent edge		
Stent area (mm^2)	8·8 ± 3·5	2·8–19·5
Minimum diameter (mm)	3·0 ± 0·6	1·5–4·7
Maximum diameter (mm)	3·6 ± 0·7	2·1–5·4
Minimum stent area		
Stent area (mm^2)	7·7 ± 2·8	2·8–17·4
Minimum diameter (mm)	2·7 ± 0·5	1·5–4·5
Maximum diameter (mm)	3·4 ± 0·6	2·1–5·1
Lumen ratio	0·81 ± 0·08	0·57–0·93
Proximal stent edge		
Stent area (mm^2)	9·8 ± 3·6	5·0–25·7
Minimum diameter (mm)	3·1 ± 0·6	2·4–5·4
Maximum diameter (mm)	3·8 ± 0·7	2·7–5·9
Proximal reference segment		
Vessel area (mm^2)	17·7 ± 5·6	14·4–32·2
Minimum diameter (mm)	4·3 ± 0·8	1·8–6·0
Maximum diameter (mm)	5·0 ± 0·8	2·9–6·6
Lumen area (mm^2)	10·4 ± 5·5	3·7–37·8
Minimum diameter (mm)	3·2 ± 0·8	1·8–6·4
Maximum diameter (mm)	3·9 ± 0·9	2·3–7·4
Plaque area (mm^2)	7·6 ± 4·7	0·13–25·2

was 7·7 ± 2·8 mm^2, mean stent expansion did not meet any of the expansion criteria of the MUSIC study[6]. With respect to these criteria, 31 stents achieved none (58%), seven stents achieved one (13%), nine stents achieved two (17%), and six stents achieved all three (11%). The minimum stent area was found in the proximal, mid (articulation) or distal stent segments in 20%, 17% and 63% of stents, respectively. In the proximal and distal reference segments, the percent plaque area was 42·6% (range 13·4–78·2%) and 40·9% (range 0–83·0%), respectively.

Table 4 Reference segment plaque morphology

	Proximal segment	Distal segment
Fibrofatty	20 (38%)	25 (47%)
Fibrous	12 (23%)	11 (21%)
Fibrofatty+fibrous	4 (8%)	4 (8%)
Fibrofatty+calcium <180°	1 (2%)	1 (2%)
Fibrous+calcium <180°	5 (9%)	5 (9%)
Calcium ≥180°	3 (6%)	3 (6%)
Normal	6 (11%)	4 (8%)
No reference segment	2 (4%)	0

Plaque morphology in the reference segments up to 5 mm proximal and distal to the stent were described qualitatively (Table 4). The segment was described as normal where ≤15% of vessel area was intimal thickening, given the mean age of patients in the study. A total of 11% of proximal segments and 8% of distal segments fell within this definition. Calcium was described in 18% of proximal or distal reference segments with a minority of deposits greater than 180° in extent. The concordance between proximal and distal plaque type with respect to fibro-fatty plaque, fibrous plaque or plaque with >180° calcium present was 65%.

Comparison of intravascular ultrasound and angiography after final stent deployment

With intravascular ultrasound, under-expansion less than 80% of mean reference area was found in 49% of cases (n=26) compared to 11% (n=6) where angiography identified a residual diameter stenosis >0%. Malapposition was also seen in 49% of cases by intravascular ultrasound (Fig. 1). Inflow/outflow disease on intravascular ultrasound examination occurred in 30% of cases (n=16; 7 inflow, 3 outflow, and 6 inflow/

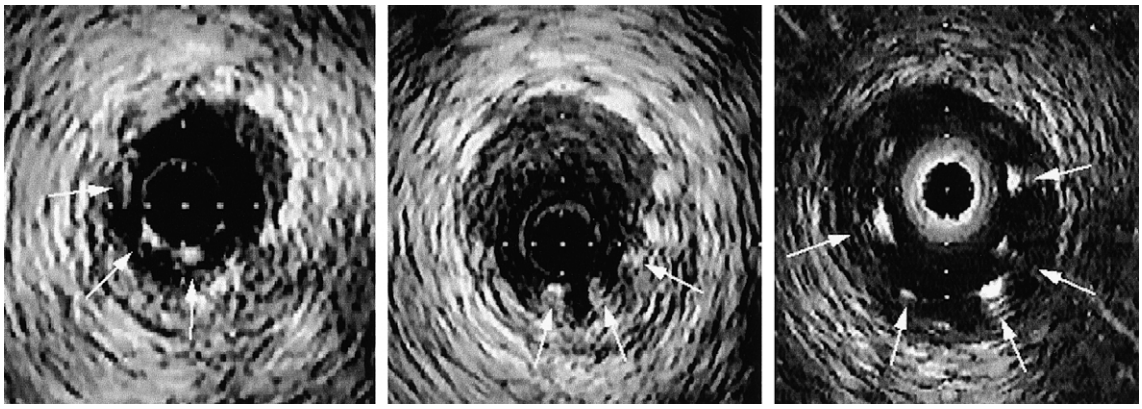

Figure 1 **Three examples of stent malapposition to a mild degree (left panel), to a moderate degree (middle panel) and to a severe degree (right panel), not appreciable by angiography.**

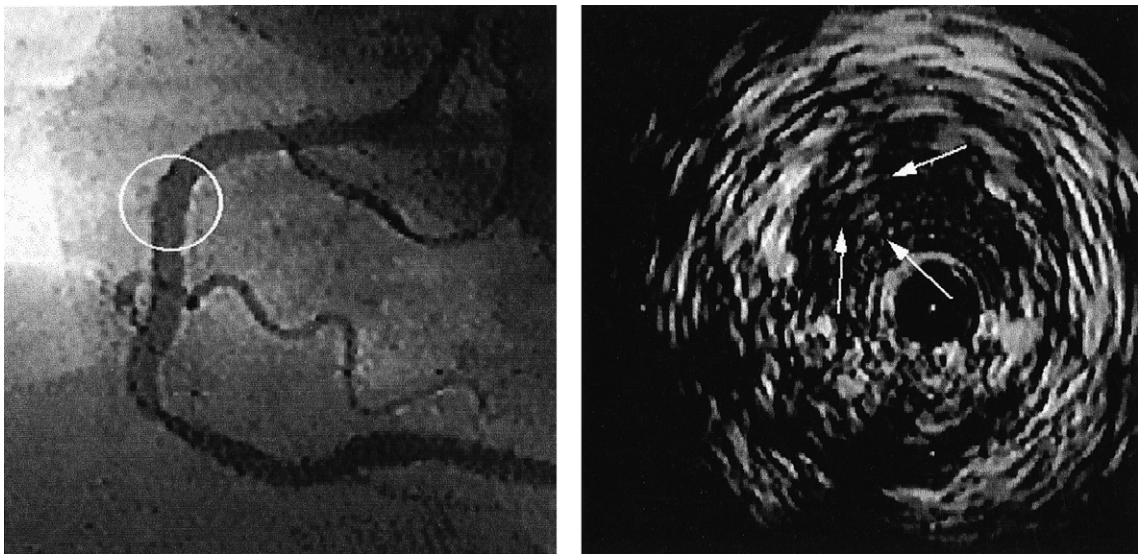

Figure 2 **An example of in-stent thrombus at 11 o'clock in a proximal right coronary artery stent in a patient with a completely normal final angiogram.**

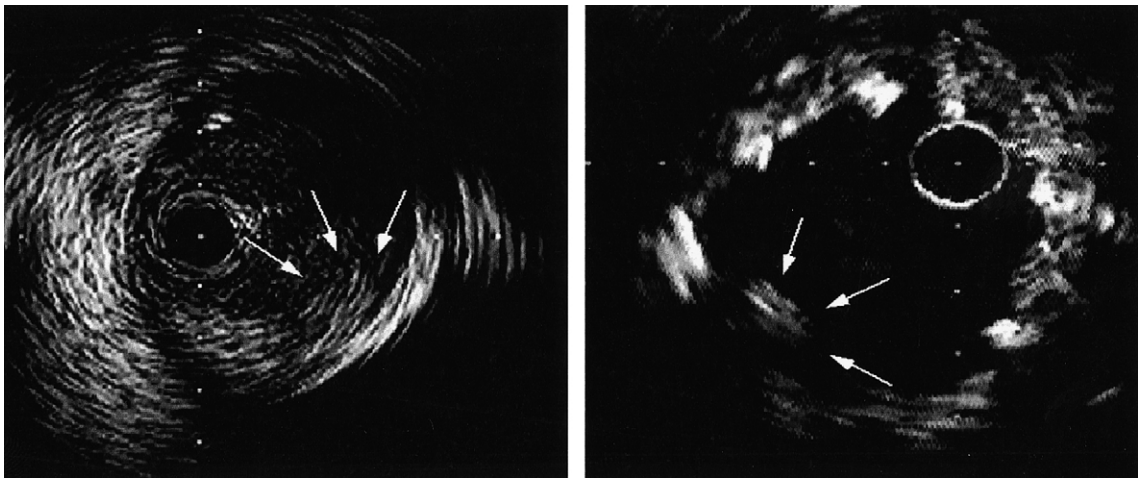

Figure 3 **An example of an edge tear or marginal dissection just distal to the stent (left panel). In the right panel, an intimal flap or dissection is seen at 7 o'clock in a proximal stent edge with adjacent visible struts.**

outflow) compared to 15% of cases (n=8; 2 inflow, 6 outflow) by angiography. With intravascular ultrasound, in-stent thrombus was seen in 23% of cases (n=12) (Fig. 2) compared to a filling defect at angiography in 13% (n=7). Intravascular ultrasound demonstrated edge tears in six and dissections in eight cases (a total of 26%) (Fig. 3) compared to obvious dissection in 2% (n=1) of angiograms. Another abnormal ultrasound parameter, plaque protrusion (defined as plaque border inside the stent struts), was seen in 19% of cases (n=10). An additional angiographic parameter, less than TIMI 3 flow was seen in 6% of cases (n=3). Two abnormal ultrasound parameters occurred in 38% of cases (n=20) with three or more in 30% (n=16). By comparison, two abnormal angiographic parameters occurred in 21% of these cases, with only one case demonstrating three abnormalities. In total, an abnormal intravascular ultrasound appearance was seen in 94% of cases (50 patients) subsequently sustaining a stent thrombosis compared to 32% (17 patients) of angiograms (chi-square=30·0, $P<0{\cdot}001$).

Comparison of POST with other intravascular ultrasound-guided stent trials

Percent stent expansion was similar in POST to that in STRUT, CRUISE and AVID, but the incidence of malapposition, edge tears/dissection and intra-stent thrombus was significantly higher in the POST registry compared to these other three studies (Fig. 4). A direct statistical comparison was made between absolute parameters in POST (n=53) and the STRUT (n=111)

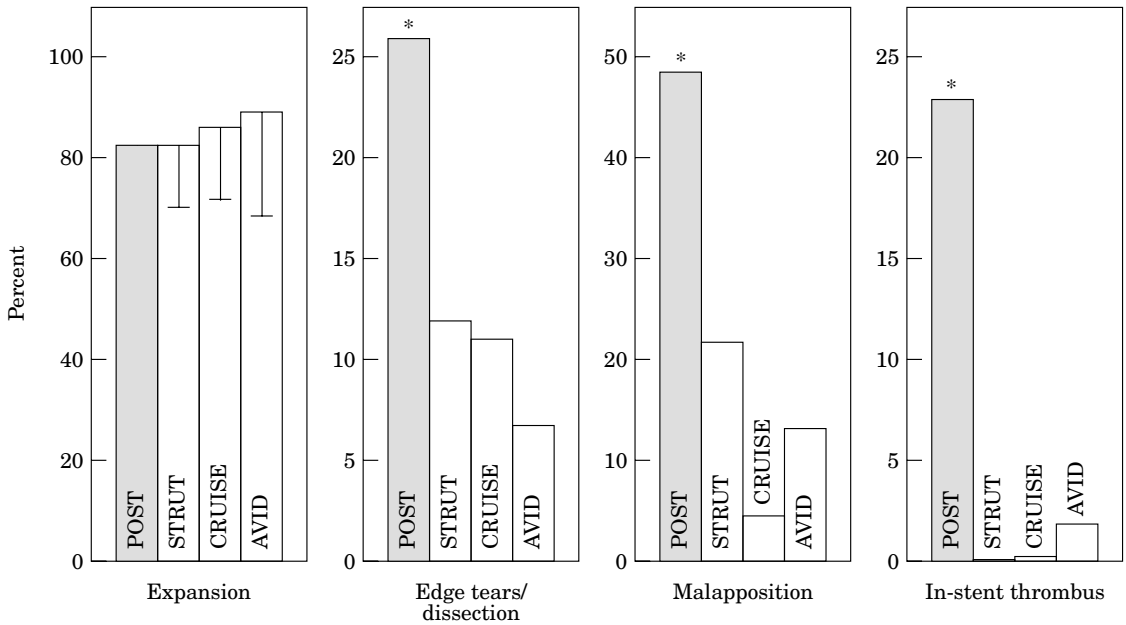

Figure 4 **A direct comparison of POST with existing ultrasound-guided stent deployment registries (STRUT) and ultrasound-guided stent deployment studies (CRUISE, AVID) with respect to percent stent expansion, edge tear/dissection, malapposition, and thrombus (*P<0·05 vs STRUT, CRUISE, and AVID).**

Table 5 Comparison of acute and subacute stent thrombosis

	Acute thrombosis	Subacute thrombosis	*P* value
Left ventricular function	62 ± 11%	51 ± 17%	0·04
Stents/artery	2·0 ± 1·3	1·5 ± 0·8	ns
Minimum stent area (mm^2)	7·38 ± 2·82	7·86 ± 2·80	ns
Proximal reference lumen area (mm^2)	9·77 ± 2·60	10·7 ± 6·0	ns
Distal reference lumen area (mm^2)	7·95 ± 3·2	9·64 ± 5·0	ns
Percent $expansion_{proximal}$	73·7 ± 27·7%	76·7 ± 22·5%	ns
Percent $expansion_{average}$	80·9 ± 18·1%	81·7 ± 23·0%	ns
Percent $expansion_{distal}$	106 ± 24%	87 ± 27%	0·02
Proximal reference intimal area (mm^2)	9·89 ± 6·66	7·78 ± 4·20	ns
Distal reference intimal area (mm^2)	6·27 ± 3·1	7·05 ± 4·55	ns

registry. No difference in stent under-expansion (<80% reference) was seen, but malapposition (chi-square= 11·72, P<0·001), edge tears or dissection (chi-square= 5·60, P<0·05), and thrombus (chi-square=26·75, P<0·0001) were significantly more common in POST than in STRUT.

Comparison of acute with subacute stent thrombosis

Subgroup analysis was done comparing acute stent thrombosis (within the first 24 h) with the remaining subacute cases. Overall, the average time to thrombosis was 132 h (range 0–600) or approximately 6 days after stenting. Eleven patients (21%) had acute thrombosis at a mean of 12 ± 6 h, and the remaining 42 patients had a subacute thrombosis at a mean of 164 ± 121 h (into the 7th day). In the acute group, the clinical presentation was unstable/post-infarction angina in 63%, compared to 55% in the subacute group. There was no significant difference in the stent number per artery or the minimum stent area although left ventricular function was better in the acute group (Table 5). Percent stent expansion was no different between groups when measured with respect to proximal reference area or to average reference area, but stents were better expanded with respect to the distal reference in acute thrombosis compared to the subacute thrombosis group. Under-expansion <80% of average reference area was similar, 36% acute vs 50% subacute, although with respect to the distal vessel, under-expansion <90% of distal vessel was seen in 18% acute vs 64% in the subacute group (chi-square=5·73, P=0·017). Malapposition was 64% in acute thrombosis vs 45% in subacute thrombosis although this did not achieve statistical significance. No significant difference in inflow/outflow disease or jailed side branches was noted. An increased number of edge tears/dissection was seen in the subacute thrombosis group, 47% vs 27% and

in intra-stent thrombus 24% vs 9% compared to the acute stent thrombosis group, although both failed to achieve statistical significance mainly due to sample size.

Treatment and outcome of stent thrombosis

A total of 85% of patients underwent emergency coronary intervention: 36% had balloon angioplasty alone, 20% had angioplasty plus additional therapy (thrombolysis, abciximab or both) and 29% received a further stent, some of these also receiving intracoronary thrombolysis. Six percent had an emergency CABG and 9% had no revascularization. Two-thirds of the patients suffered a myocardial infarction by enzyme criteria and there was an overall mortality of 15%.

Discussion

The POST registry is the largest retrospective collection to date of patients sustaining a stent thrombosis who underwent an intravascular ultrasound study after stent deployment. The registry was not controlled for stent deployment without intravascular ultrasound guidance or for the ultrasound appearance of stents deployed without subsequent stent thrombosis, and thus comparison was made with existing studies. In POST, many stents sustaining acute and subacute thrombosis were under-expanded, which is consistent with previous data on stent expansion from other multicentre ultrasound registries of stent deployment[7–9], suggesting that stent expansion itself is not a predictor of subacute thrombosis. Edge tears and dissection were found to a greater extent in the STRUT registry[7], and to a greater extent than in the prospective studies CRUISE[8], and AVID[9]. However, almost one half of patients sustaining stent thrombosis had malapposition, which is considerably higher than in these other series[7–9]. Also, up to a quarter had in-stent thrombus seen at ultrasound. These data from POST confirm the importance of morphologic variables documented by intravascular ultrasound even where stents may be relatively well-expanded by existing standards.

Stent thrombosis has become a less frequent event with the advent of high-pressure dilatation and anti-platelet therapy[4,10,11]. Initial use of ultrasound during traditional stent deployment showed that 80% of stents were under-expanded (<70% of balloon cross-sectional area) and led to the hypothesis that stent thrombosis might be decreased as a result of optimal stent placement with high-pressure balloon dilatation under ultrasound guidance without the need for anticoagulation[12,13].

To examine clinical predictors of subacute stent thrombosis, a study of 19 cases from 1001 consecutive patients from 1993–5 was reported[14]. Following high-pressure dilatation to achieve less than 20% residual diameter stenosis, intravascular ultrasound was used in 72% to guide final deployment. Patients with an unsuccessful angiographic outcome were treated with warfarin; otherwise, a combination of aspirin/ticlopidine or aspirin alone was used. Indications for stenting, site and complexity of the lesion were no different between the groups. Slow flow at angiography, but not residual dissection post intervention, was a strong predictor of thrombosis. With intravascular ultrasound, a smaller minimum stent area was seen in the stent thrombosis group, $5{\cdot}9 \pm 1{\cdot}7$ vs $7{\cdot}8 \pm 2{\cdot}5$ mm^2 (c.f. $7{\cdot}7 \pm 2{\cdot}8$ mm^2 in the POST registry). These data confirmed that bailout stenting, a factor predicting stent thrombosis in earlier studies[15,16], only carries a high risk for subsequent thrombosis if the underlying angiographic problem is not fully corrected. In another review of 10 thrombosis cases in 215 intravascular ultrasound-guided stents, stent thrombosis occurred in smaller reference vessels, $2{\cdot}7 \pm 0{\cdot}5$ vs $3{\cdot}2 \pm 0{\cdot}6$ mm (c.f. $3{\cdot}2 \pm 0{\cdot}8$ mm in POST). The only independent predictors of risk were initial stent lumen area, $4{\cdot}80 \pm 1{\cdot}33$ mm^2 vs $6{\cdot}86 \pm 2{\cdot}08$ mm^2, and final stent percent plaque area, $70{\cdot}1 \pm 6{\cdot}1\%$ vs $58{\cdot}4 \pm 9{\cdot}8\%$[17]. In contrast to POST, morphologic variables were not examined in this retrospective study

In the ISAR (Intracoronary Stenting and Antithrombotic Regimen) trial, a composite risk assessment for adverse outcome was devised from a list of 18 clinical, lesion-related, and procedural variables (stent length, residual dissection, residual thrombus and stent overlap) in 517 patients[18]. Stent thrombosis occurred in 5·9% of high-risk ($\geq$4 criteria), 2·7% of intermediate risk (3 criteria), and 0% of low risk ($\leq$2 criteria) patients. In contrast to the low- and intermediate-risk groups, in high-risk patients, the stent thrombosis rate was 11·5% with anticoagulant therapy and 0% with anti-platelet therapy ($P<0{\cdot}001$). A wider review of stent outcomes was described by the same group in 2894 procedures from 1992–7 in whom 80% received aspirin/ticlopidine with a documented stent thrombosis rate of 2·3%[19]. Residual dissection after stenting by angiography and the use of ticlopidine after day 3 were the two major influences on stent thrombosis. Although the stent thrombosis rate in standard interventional practice is low, an increased risk of late thrombosis (in up to 9% of stents) following intracoronary stenting and intracoronary irradiation indicates the potential value of intravascular ultrasound in guiding successful intervention in higher risk situations[20].

Limitations

The POST registry is retrospective and does not have a comparable control group of ultrasound-guided stent deployment cases without thrombosis. At present, stent thrombosis is a rare event and prospective comparative data will only come from analysis of the large multicentre ultrasound-guided stent deployment trials. Despite the selection bias of POST, the observations remain valid and can still be compared with other stent registries where intravascular ultrasound was used to

guide deployment and where significant differences were observed with respect to POST.

It is still a limitation of ultrasound to diagnose thrombus with complete specificity. However, several qualitative criteria such as a scintillating lobulated appearance, microchannels and fluctuation in a direction opposite to the vessel wall were used. The definitions applied in this study to inflow or outflow disease by ultrasound or angiography are arbitrary but are consistent with the historical observation that successful stenting should be performed from normal or near-normal segments from proximal to distal artery[1].

The POST registry came from a period of evolution of antiplatelet therapy. However, the majority of patients still received aspirin and ticopidine with only three of 53 patients receiving no aspirin. Although this may be considered an additional risk factor for stent thrombosis, the discrepancy between angiography-guided and ultrasound-guided stent abnormalities still remains when excluding these patients from analysis.

Clinical implications

Intravascular ultrasound is significantly more sensitive in defining suboptimal stent deployment leading to thrombosis compared to angiography. Although retrospective, the POST registry suggests that stent malapposition, in-stent thrombus and edge tears/dissection are important determinants of stent thrombosis. It is not a cost-effective strategy to perform intravascular ultrasound in every stent deployment to identify risk of subsequent thrombosis given the low rate in current interventional practice. However, in cases where the clinical consequences of stent occlusion are great or where problems with antiplatelet therapy are anticipated, intravascular ultrasound is a useful adjunct to angiography in fully defining the optimal deployment of intracoronary stents and in the identification of patients at risk of stent thrombosis.

We thank Mr Rob Elton, Medical Statistics, University of Edinburgh, U.K., for statistical advice. NGU was a British Heart Foundation International Fellow.

References

[1] Colombo A, Hall P, Nakamura S *et al*. Intravascular stenting without anticoagulation accomplished with intravascular ultrasound guidance. Circulation 1995; 91: 1891–3.
[2] Karrillon GJ, Morice MC, Beneviste E *et al*. Intracoronary stent implantation without ultrasound guidance and with replacement of conventional anticoagulation by antiplatelet therapy: 30 day clinical outcome of the French multicenter registry. Circulation 1996; 94: 1519–27.
[3] Hall P, Nakamura S, Maiello L *et al*. A randomized comparison of combined ticlopidine and aspirin therapy versus aspirin therapy alone after successful intravascular ultrasound-guided stent implantation. Circulation 1996; 93: 215–22.
[4] Schömig A, Neumann F-J, Kastrati A *et al*. A randomized comparison of antiplatelet and anticoagulant therapy after the placement of coronary-artery stents. N Engl J Med 1996; 334: 1084–9.
[5] Serruys PW, van Hout B, Bonnier H *et al*., for the Benestent Study Group. Randomised comparison of implantation of heparin-coated stents with balloon angioplasty in selected patients with coronary artery disease (Benestent II). Lancet 1998; 352: 673–81.
[6] de Jaegere P, Mudra H, Figulla H *et al*. for the MUSIC Study Investigators. Intravascular ultrasound-guided optimized stent deployment. Immediate and 6 months clinical and angiographic results from the Multicenter Ultrasound Stenting in Coronaries Study (MUSIC study). Eur Heart J 1998; 19: 1214–23.
[7] Metz JA, Mooney MR, Walter PD *et al*. Significance of edge tears in coronary stenting: initial observations from the STRUT registry (Abstr). Circulation 1995; 92 (Suppl): I-546.
[8] Fitzgerald PJ, Oshima A, Hayase M *et al*. Final results of the Can Routine Ultrasound Influence Stent Expansion (CRUISE) study? Circulation 2000; 102: 523–30.
[9] Russo RJ, Attubato MS, Davidson CJ *et al*. Angiography versus intravascular ultrasound-directed stent placement: final results from AVID (Abstr). Circulation 1999; 100 (Suppl I): I-234.
[10] Barragan P, Sainsous J, Silvestri M *et al*. Ticlopidine and subcutaneous heparin as an alternative regimen following coronary stenting. Cathet Cardiovasc Diag 1994; 32: 133–8.
[11] Morice MC, Zemour G, Beneviste E *et al*. Intracoronary stenting without coumadin: one month results of a French multicenter study. Cathet Cardiovasc Diag 1995; 35: 1–7.
[12] Nakamura S, Colombo A, Gaglione S *et al*. Intracoronary ultrasound observations during stent implantation. Circulation 1994; 89: 2026–34.
[13] Goldberg Sl, Colombo A, Nakamura S, Almagor Y, Maiello L, Tobis JM. The benefit of intracoronary ultrasound in the deployment of Palmaz–Schatz stents. J Am Coll Cardiol 1994; 24: 996–1003.
[14] Moussa I, di Mario C, Reimers B, Akiyama T, Tobis J, Colombo A. Subacute stent thrombosis in the era of intravascular ultrasound-guided coronary stenting without anticoagulation: frequency, predictors, and clinical outcome. J Am Coll Cardiol 1997; 29: 6–12.
[15] Nath FC, Muller DWM, Ellis SG *et al*. Thrombosis of flexible coil coronary stent: frequency, predictors and clinical outcome. J Am Coll Cardiol 1993; 21: 622–7.
[16] Agrawal LS, Ho D, Liu M, Iser S *et al*. Predictors of thrombotic complications after placement of the flexible coil stent. Am J Cardiol 1994; 73: 1216–21.
[17] Werner GS, Gastmann O, Ferrari M *et al*. Risk factors for acute and subacute stent thrombosis after high-pressure stent implantation: a study by intracoronary ultrasound. Am Heart J 1998; 135: 300–9.
[18] Schühlen H, Hadamitzky M, Walter H, Ulm K, Schömig A. Major benefit from antiplatelet therapy for patients at high risk for adverse cardiac events after coronary Palmaz–Schatz stent placement: analysis of a prospective risk stratification protocol in the Intracoronary Stenting and Antithrombotic Regimen (ISAR) trial. Circulation 1997; 95: 2015–21.
[19] Schühlen H, Kastrati A, Dirschinger J *et al*. Intracoronary stenting and risk for major adverse cardiac events during the first month. Circulation 1998; 98: 104–11.
[20] Costa MA, Sabaté M, van der Giessen WJ *et al*. Late coronary occlusion after intracoronary brachytherapy. Circulation 1999; 100: 789–92.

Appendix

The list of contributing centres and individuals is as follows (case number in parentheses):

North America
Abbott Northwestern, Minneapolis, MN. Michael Mooney MD (1)

Emory University Hospital, Atlanta, GA. Nicolas Chronos MRCP (1)
Georgetown University, Washington, DC. Neal Weissman MD (1)
Northwestern University, Chicago, IL. Charles Davidson MD (2)
Laurel Cardiology, Vancouver, Canada. Ian Penn MD (1)
Mayo Clinic, Rochester, MN. Stuart Higano MD (3)
Scripps Clinic, La Jolla, CA. Robert Russo MD (5)
Stanford University, Stanford, CA. Paul Yock MD (4)
Washington Hospital Center, Washington, DC. Gary Mintz MD (5)

Europe
Centro Cuore Columbus, Milano, Italy. Carlo di Mario MD (12)
Essen University, Essen, Germany. Gunter Görge MD (2)
Georg-August University, Göttingen, Germany. Gerald Werner MD (7)
Hospital Gregorio Marañon, Madrid, Spain. Javier Botas MD (1)
Ludwig Maximillian Universität, München, Germany. Harald Mudra MD (2)
Medizinische Hochschule, Hannover, Germany. Dirk Hausmann MD (2)
Western General Hospital, Edinburgh, U.K. David Northridge MRCP (1)

Japan
National Toyohashi Higashi Hospital, Toyohashi. Takahiko Suzuki MD (2)
Ogaki Municipal Hospital, Ogaki. Takahito Sone MD (1)