

Predictors of Recurrence of Hepatocellular Carcinoma after Transarterial Chemoembolization: Role of Hepatocyte Growth Factor

Amr Mohamed Zaghoul¹, Ahmed Sedky², Ali Hussein Mohammed³, Samer A. El-Sawy⁴, Ahmed Abd El Rady Ahmed⁵, Emad Eldin Nabil⁶

¹Tropical Medicine and Gastroenterology Department, Sohag University, Sohag, Egypt

²Department of Clinical Pathology, Sohag University, Sohag, Egypt

³Department of Internal Medicine, Sohag University, Sohag, Egypt

⁴Biochemistry Department, Sohag University, Sohag, Egypt

⁵Interventional Radiology Department, Alazhar University (Assuit Branch), Assuit, Egypt

⁶Department of Oncology, Sohag University, Sohag, Egypt

Email: amrmoh_80@yahoo.com

How to cite this paper: Zaghoul, A.M., Sedky, A., Mohammed, A.H., El-Sawy, S.A., El Rady Ahmed, A.A. and Nabil, E.E. (2020) Predictors of Recurrence of Hepatocellular Carcinoma after Transarterial Chemoembolization: Role of Hepatocyte Growth Factor. *Open Journal of Gastroenterology*, 10, 151-165.

<https://doi.org/10.4236/ojgas.2020.106016>

Received: May 2, 2020

Accepted: June 12, 2020

Published: June 15, 2020

Copyright © 2020 by author(s) and

Scientific Research Publishing Inc.

This work is licensed under the Creative

Commons Attribution International

License (CC BY 4.0).

<http://creativecommons.org/licenses/by/4.0/>



Open Access

Abstract

Background: Hepatocellular carcinoma is the third leading cause of tumor related mortality and develops mostly in patients with chronic liver disease and liver cirrhosis. Human hepatocyte growth factor (HGF) is produced in various organs of the body and is characterized as a multifunctional factor with various biologic activities. **Aim:** Our aim was to investigate the predictive factors of recurrence specially the role of HGF in patients with HCC treated with TACE. **Patients and Methods:** one hundred HCC patients treated by TACE who achieved complete response were included and divided into two groups according to disease free survival (DFS) status at 1 year: the non-early recurrence (NER) group (1) and the early recurrence (ER) group (2). Univariate binary logistic regression analysis for the possible risk factors of recurrence showed that AFP, multinodularity and HGF level were significant. **Conclusion:** high AFP, multinodularity and high HGF were inter-related possible risk factors for 1-year recurrence of HCC in patients with initial remission following TACE.

Keywords

Hepatocellular Carcinoma, Hepatocyte Growth Factor, Prediction of HCC Recurrence

1. Introduction

Hepatocellular carcinoma is the third leading cause of tumor related mortality after tumors of the lung and the stomach [1] and the prevalence is high in sub-Saharan Africa and Southeast Asia. It develops mostly in patients with chronic liver disease and liver cirrhosis [2]. Multiple treatment options are available but the choice depends on the stage and the patient liver function [3].

Surgical treatment either resection or transplantation remains the mainstay of potentially curative therapy but the prognosis remains poor due to advanced stage of the tumor at time of diagnosis and the recurrence rate at 5 years after resection is about 80% [4].

Transarterial chemoembolization (TACE) is the best therapeutic option in about 60% to 70% of patients with advanced stage of the disease [5], when curative options such as radiofrequency and surgery are unsuccessful or unfeasible TACE could be another option [6]. The long term outcomes of patients treated with TACE are not entirely satisfactory due to high recurrence rates [7].

Several risk factors of recurrence of HCC after TACE have been reported such as number of focal lesions, size of the lesion, tumor markers and liver function [8].

Human hepatocyte growth factor (HGF) is produced in various organs of the body and is characterized as a multifunctional factor with various biologic activities [9], several reports have examined the relationship between HGF and liver diseases and several have sought a factor that would assist in predicting the development of chronic hepatitis (CH), and the facilitation of the occurrence of HCC [10].

HGF exerts its actions through tyrosine phosphorylation of its receptor, cMET, which is a proto-oncogene product. HGF (also known as the scattering factor) activates the MET signaling pathway, thereby increasing the invasive and metastatic potential of the cells and allowing the survival of cancer cells in the blood stream and facilitating cancer progression [11].

In HCC, the mRNA levels of HGF and the MET receptor are markedly increased compared with those in normal liver. A high serum HGF concentration is associated with a poor prognosis for overall survival after hepatic resection, and the serum level of HGF represents the degree of the carcinogenic state in the livers of patients with C-viral chronic hepatitis and cirrhosis [11].

However, the predictive factors for recurrence after complete response (CR) after TACE have not yet been elucidated. Here, we investigated the predictive factors of recurrence specially the role of HGF in patients with HCC treated with TACE.

2. Patients and Methods

Study Design

The present study was a retrospective cohort study performed at a single centre. The medical records of 250 patients treated with TACE as a first treatment

according to BCLC Staging (stage B) between June 2017 and June 2018 at Sohag Digestive Diseases center (Sohag, Egypt) were reviewed.

The inclusion criteria for TACE were BCLC B HCC patients with Child's A or B cirrhosis, patent portal vein and patients willing for therapy and follow up. Some patients of BCLC A who were unsuitable for ablative therapy or surgery were also included.

The exclusion criteria for TACE were: 1) previous intervention; 2) main portal vein thrombosis; 3) hepatic encephalopathy; 4) uncontrolled Ascites; 5) recent attack of gastrointestinal bleeding within past month. Of these, 125 patients achieved complete response 1 month post TACE as documented by triphasic CT liver and subsequently observed over a 1-year period.

Twenty five patients were excluded as they were lost to follow up. So, only 100 patients (72 males, 28 females) were included in final statistics. These patients were divided into two groups according to disease free survival (DFS) status at 1 year: the non early recurrence (NER) group (1) (no recurrence within 1 year after initial TACE; n = 55) and the early recurrence (ER) group (2) (recurrence within 1 year after initial TACE; n = 45) and The study was approved by the local ethics committee of Sohag Digestive Diseases Centre (Sohag, Egypt) in May 2017 according to the principles of the Declaration of Helsinki 1964 and written informed consent was obtained from all patients before treatment.

Diagnosis of HCC

The diagnosis of HCC was confirmed in patients with chronic liver disease and cirrhosis with typical vascular pattern on dynamic imaging modalities (*i.e.* Triphasic CT) which showed contrast hyperenhancement in the arterial phase (wash in) and hypoenhancement in the portal venous and/or delayed phase (wash out) without need to liver biopsy. Complete response (CR) was defined as the disappearance of any intratumoral arterial enhancement in all target lesions or compact lipiodol uptake 1 month after procedure according to modified Response Evaluation Criteria in Solid Tumors [7]. The recurrence is determined when a new lesion appeared or when an enhanced part was seen at the margin of the original lesion.

The Procedure of TACE

Definition: Is a dual therapeutic approach involving concomitant hepatic artery embolization and infusion of concentrated dose of chemotherapeutic drugs.

This procedure has several goals:

Prolongation of contact time between the cytotoxic agent and the tumor allows greater concentration of the chemotherapeutic drug in the tumor. (Experimental studies have shown that embolization can triple the local concentration of Adriamycin.)

Embolization induced ischemia that can enhance the effect of chemotherapy and finally, embolization reduces general side effects of cytotoxic drug [12].

Since TACE was introduced as a palliative treatment in patients with unresectable HCC, it has become one of the most common forms of interventional therapy [13].

TACE Technique

Preprocedural preparation:

The patient would be fasting for 6 hours and the groin shaved;

Undergo vigorous intravenous hydration (500 mL 5% dextrose in normal saline solution before chemoembolization then continued at 100 mL/h) for at least 24 hours;

Preprocedural medications include a prophylactic antibiotic and a non-steroidal anti-inflammatory drug (NSAID).

Angiographic procedure:

Selective hepatic angiography through transfemoral Seldinger technique was conducted with a digital angiographic unit (Siemens Artis Zee).

A 5F valved sheath (introducer 11 cm long sheath) was inserted into the femoral artery with the patient under local anesthesia, (10 ml of 2% lidocaine HCl).

Celiac and superior mesenteric arteriography was performed with Copra II catheter. (Simon II catheter sometimes used).

The catheter was advanced into the common hepatic artery distal to the origin of gastroduodenal artery, by using a 0.035 inch gliding guide wire (Glide wire Terumo). The catheter must be advanced as selective as possible very close to the tumor (micro catheter used in many cases).

Selective hepatic angiography data were recorded with a digital subtraction technique. Then we inject 1 ml lidocaine mixed with 10 cc saline.

The patients were injected by a mixture of Lipiodol and cytotoxic drugs. (The mixture of injected material consists of Lipiodol and Doxorubicin) was prepared as follows: 50 mg powder of the Adriablastin (adriamycin hydrochloride) dissolved in a 10 ml saline. The dissolved Adriablastin is mixed with 7 ml iodized oil Lipiodol. The remaining 3 ml iodized oil Lipiodol injected later.

The homogeneous manually shaken emulsion of Lipiodol and chemotherapeutic agent were injected through the catheter into the tumor vascular bed under screen, until the Lipiodol is densely accumulated into the tumor, sometimes this is followed by occlusion of the tumor vascular bed by PVA particles (When we depicted that there is dominant supply to the tumor with almost no side branches).

After complete response was achieved patients were evaluated every 3 months by Triphasic CT for 1 year for assessment of recurrence.

Assessment of Serum HGF Level

Ten milliliters of venous blood was taken from each participant under aseptic conditions and by using sterile disposable gloves and then we divide the samples as follow:

- 1) 1.8 ml collected in 0.2 sodium citrate for prothrombin time (PT), prothrombin concentration (PC) and international normalized ratio (INR) which was assayed by Thrombol-S kit using Sysmex CA-1500 fully automated coagulometer (Siemens Healthcare GmbH, Laboratory Diagnostic, Marburg, Germany).

- 2) We collected the rest of sample in a plain tube which was left to clot then

the serum was separated and divided into three aliquots:

a) The first one was used for assessment of serum creatinine, serum bilirubin, and albumin which were assayed on the same day using Cobas C311 Chemistry Analyser System (Roche Diagnostic GmbH, Indianapolis, IN, USA).

The second and the third aliquots were stored at -20°C until the time of assay.

b) The second aliquot was used for assessment of alphafetoprotein and serological testing for anti-HCV and HBsAg which were done using architect i1000 system (Abbott Laboratories, Diagnostic Division Abbott Park, IL).

c) The third aliquot was used for assessment of hepatocyte growth factor by quantitative sandwich ELISA technique using HGF ELISA kit catalog No. DHG00. R&D Systems Inc., Minneapolis, Minnesota, USA (using ELISA Thermo Fisher, Scientific Multiscan EX Microplate Reader, OY, FI-O1621, Vantaa, Finland).

Predictive Factors

The baseline characteristics of 100 patients treated with TACE were evaluated. We analyzed the clinical and biological factors that may predict early recurrence of the disease: age, gender, viral markers (hepatitis B virus surface antigen and hepatitis C virus antibody), Child-Pugh score, serum AFP, HGF serum level, size and number of tumors).

Statistical Analysis:

- Statistical package for social sciences (IBM-SPSS), version 25 (IBM-Corporation, Chicago, USA; August 2017) was used for statistical data analysis.
- Data was expressed as mean, standard deviation (SD), number and percentage. Mean and standard deviation were used as descriptive value for quantitative data.
- Student t test was used to compare the means between two groups, and one-way analysis of variance (ANOVA) test was used to compare means of more than two groups. Mann-Whitney and Kruskal-Wallis tests were used instead of student t test and ANOVA for non parametric data to compare medians rather than means between two or more groups, respectively.
- Pearson Chi-square test was used to compare percentages of qualitative variables.
- Receiver Operating Characteristics curve (ROC curve) analysis was done to assess the predictive value of HGF as a screening test and to calculate the most suitable cut-off values which provide the highest possible accuracy (highest sensitivity and specificity at the same time).
- Univariate binary logistic regression analysis was done to assess the possible risk factors for and those with significant univariate regression were included in multivariate binary logistic regression analysis model to estimate if any of them could be considered as an independent risk factor.
- For all these tests, the level of significance (p-value) was explained as:
 - ✧ No significance $p > 0.05$;
 - ✧ Significance $p < 0.05$;
 - ✧ High significance $p < 0.001$.

3. Results

Comparison between the two groups: group (1) non early recurrence (NER) and group (2) early recurrence (ER), showed no significant difference in terms of age, sex, size of the tumor, aetiology of liver cirrhosis and liver function but AFP level, number of the lesions (multinodularity) and HGF level were significantly higher in the ER group compared with the other group (p value < 0.001, 0.001, 0.001) (**Table 1**).

Regarding HGF level there was a highly significant difference between the cases and the control group and the cut-off value of HGF was 1568.4 pg/ml as shown in **Figure 1**.

There was a highly significant difference between in HGF level between the two groups as shown in **Figure 2** and the cut-off value was 3960.4 pg/ml with a sensitivity of 97%, and a specificity of 100%.

Univariate binary logistic regression analysis for the possible risk factors of recurrence showed that AFP, multinodularity and HGF level were significant as shown in **Table 2** (p value < 0.001, 0.001, 0.001).

Multivariate regression analysis showed that all of the AFP, multinodularity and HGF were inter-related and none of them could be considered as an independent risk factor as shown in **Table 3**.

Table 1. Demographic features and laboratory data of the participants studied.

		Group (1)	Group (2)	Chi square*/ t test ** MWT^	p value
Sex	Male	39 (70.9%)	33 (73.3%)	0.072*	<0.788 (NS)
	Female	16 (29.1%)	12 (26.7%)		
Age	Mean ± SD	53.6 ± 7.12	54.2 ± 6.96	0.424**	0.673 (NS)
Aetiology	HBV	7 (12.7%)	6 (13.3%)	0.053*	0.974 (NS)
	HCV	46 (83.6%)	37 (82.2%)		
	NBNC	2 (3.6%)	2 (4.4%)		
Albumin	Mean ± SD	3.75 ± 0.66	3.99 ± 0.55	2.150**	0.059 (NS)
T. bilirubin	Mean ± SD	1.06 ± 0.42	0.92 ± 0.42	1.693**	0.094 (NS)
PC	Mean ± SD	80.5 ± 11.3	80.2 ± 11.2	0.164**	0.870 (NS)
Child-Pugh	A	26 (47.3%)	27 (60%)	3.962*	0.205 (NS)
	B	29 (52.7%)	18 (40%)		
	Mean ± SD	37.2 ± 39.6	305 ± 203	39.5^	<0.001 (HS)
AFP	Median	28	234		
	Range	5 - 220	44 - 970		
HGF level	Mean ± SD	3194 ± 982	5134 ± 986	9.806*	<0.001 (HS)
Size	Mean ± SD	8.59 ± 4.55	10.34 ± 4.75	1.870**	0.064 (NS)
Multi-nodularity		6 (10.9%)	43 (95.6%)	70.962*	<0.001 (HS)

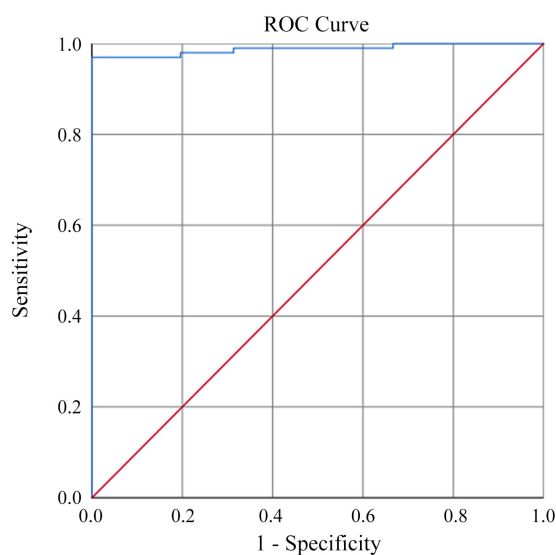
HBV: Hepatitis B Virus; HCV: Hepatitis C Virus; NBNC: Non B Non C; T.bilirubin: Total bilirubin; PC: Prothrombin concentration; MWT: Mann Whitney test.

Table 2. Univariate binary logistic regression analysis for the possible risk factors of group (2) compared to group (1).

Item	p value	Odds ratio	CI of Odds
Male sex	0.788	1.128	0.468 - 2.721
Age	0.669	1.012	0.957 - 1.071
Aetiology	0.893	0.857	0.091 - 8.075
Albumin	0.062	1.894	0.968 - 3.708
Total bilirubin	0.096	0.436	0.164 - 1.160
Prothrombin concentration	0.868	0.997	0.962 - 1.033
Child score	0.206	1.673	0.754 - 3.714
AFP	<0.001	1.035	1.022 - 1.049
Size	0.066	1.084	0.995 - 1.181
Multinodularity	<0.001	175.583	33.657 - 915.979
HGF	<0.001	1.002	1.002 - 1.003

Table 3. Multivariate binary logistic regression analysis for the possible risk factors of group (2) compared to group (1).

Item	p value
AFP	0.932
Multinodularity	0.932
HGF	0.935

**Figure 1.** ROC curve statistics for the predictive value of HGF to differentiate cases from controls.

ROC analysis shows that HGF can differentiate cases (groups 1 and 2 collectively) from controls, with a highly significant difference. Using coordinate points of the above ROC curve, the most relevant level cut-off value of HGF to differentiate cases from controls was 1568.4, with a sensitivity of 97%, and a specificity of 100%.

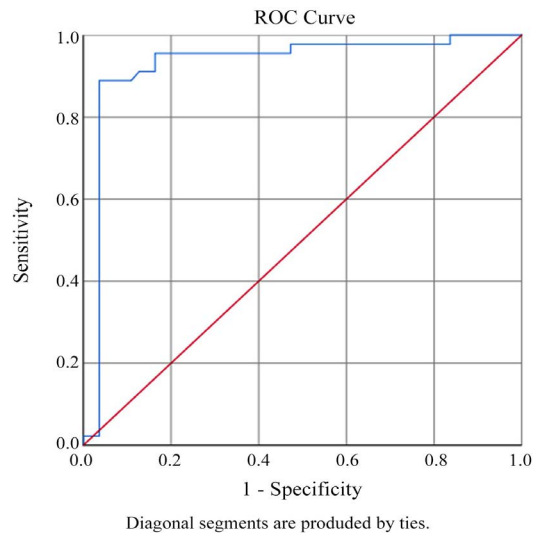


Figure 2. ROC curve statistics for the predictive value of HGF to differentiate group (2) from group (1).

ROC analysis shows that HGF can differentiate group (2) from group (1), with a highly significant difference. Using coordinate points of the above ROC curve, the most relevant level cut-off value of HGF to differentiate group (2) from group (1) was 3960.4, with a sensitivity of 88.9%, and a specificity of 96.4%.

- Triphasic CT images of **Case (1)** showed enhanced hepatic mass involving segment 8 in arterial phase (a) and wash out in delayed phase (b). Digital subtraction angiography of the hepatic mass lesion was showed (c) and the angiography during Chemoembolization (d). Disappearance of tumor vascularity and Lipiodol uptake as showed (e). The one month post TACE follow up showed no residual viable tumor tissue (f).
- Triphasic CT images of **Case (2)** showed hepatic mass involving Lt hepatic lobe segment 3 in arterial phases (a). Angiographic blush of hepatic mass lesion was showed (b) and (c). Follow up CT scan at the same level one month after TACE, showing marked response to treatment. (d) CT scan at the same level six months after TACE, showing reduced size with no residual enhancing tumor tissue. (e) CT scan at the same level one year after TACE, showing vanishing of the focal lesion with no residual enhancing tumor tissue (f).
- Triphasic CT images of **Case (3)** showed hypovascular mass lesion involving the right lobe (a) and the selective hepatic anigography showing displacement of the hepatic vessels by the hypovascular tumor (b). The procedure using microcatheter was shown (c) but Follow up CT showing poor response to chemoembolization (d).

4. Discussion

HCC is one of the most common cancers worldwide, and is associated with a high mortality rate. TACE is the most commonly used treatment modality when

curative treatment is not indicated, we evaluated the predictive factors of early recurrence within 1 year in patients treated with TACE as a first therapy.

Multinodularity, elevated AFP and high HGF level were predictive factors of early recurrence. In respect to multinodularity, it is hypothesized that TACE cannot target undetected satellite lesions outside the zone of TACE induced necrosis. Consistent with the present study, Lee *et al.* [14] found that recurrence following initial remission by TACE has been more often reported in patients with multinodular HCC. By contrast Matsuda *et al.* [15] found that tumor multinodularity was not associated with 1-year HCC recurrence. This discrepancy may be explained in part by the different baseline characteristics of the patients with HCC between studies.

Triphasic CT can not detect microscopic remnant tumors during the early phase after TACE (4) Thus, HCC patients with multinodular lesions should be closely monitored even if they are in remission radiologically after TACE.

HCC with high AFP shows a poorer grade of differentiation than does HCC with lower AFP level [16]. Serum AFP has roles in immune system inhibition by altering the ratio of CD4+ and CD8+ T lymphocytes subsets and inducing lymphocyte death. Hypofunction of the immune system is an important factor for cancer cell growth, recurrence and metastasis. Although 10% to 30% of HCC cases are negative for AFP expression, studies have suggested that AFP is a significant predictor of HCC recurrence [17].

In our study, the serum HGF levels were 239 - 1260, 456 - 37,543, and 2654 - 38,790 in the control, group (A), and group (B), respectively. HGF was highly significantly elevated in the group (B) [Mean \pm SD 4196 \pm 5719 pg/ml] compared with that of the group (A) [5800 \pm 5095 pg/ml] ($p < 0.001$).

Several researchers have confirmed similar results of increased HGF levels in patients with HCC compared with normal control participants such as the studies of Shiota *et al.* [18].

The sensitivity and specificity of HGF have been shown to vary with the different cut-off values used. According to our results, at a cut-off 1568.4 pg/ml (1.5684 ng/ml), with a sensitivity of 97%, and a specificity of 100%, and area under the curve (AUC) was 0.988. Yamagamim *et al.* [19] found in their study that the cut-off value of HGF for suspecting HCC in their cirrhotic patients was above 0.6 ng/ml and they concluded from their study that HGF may be a critical marker for emergence of HCC in their patients, they detected the HGF after only two days of storage of their samples, which is why their values were low and more specific (19). In our study, our samples were stored till the end of collection; this explains the higher cut-off value.

We conclude from this study that both HGF and AFP can be additional useful factors as noninvasive biomarkers for the early detection of HCC in cirrhotic patients and this agree with that was found by S. El Deen and El Haddad [20].

The use of HGF as an additional biomarker for early detection of HCC may be of value in cases with normal AFP and in other cases with persistent elevation in

AFP that is associated with regeneration as a consequence of liver necroinflammation.

HGF is also involved in cancer invasion and metastasis as it is the most potent growth factor for hepatocytes and its receptor, the N-methyl-N'-nitroso-guanidine human osteosarcoma transforming gene transmembrane tyrosine kinase (c-Met) is implicated in HCC carcinogenesis and progression through activation of multiple signaling pathways that direct cell growth, proliferation survival, and motility [21].

Aberrant Met/HGF activation has been observed in many tumor types, can occur by multiple mechanisms, and promotes cellular proliferation and metastasis via growth factor receptors and other oncogenic receptor pathways.

On the contrary Karabulut *et al.* [22] found that HGF had diagnostic value but of no prognostic value in HCC patients.

The mechanism whereby stromal cells over-produce HGF for accelerating tumor malignancy has been investigated, and HGF-inducers (such as autacoids and cytokines) have been identified. Growing evidence indicates that NK4 inhibits tumor growth, invasion and metastasis in rodents bearing various types of malignant tumors and the discovery of NK4 as an HGF antagonist has promoted research in cancer biology, pathology and therapy [23].

Another mechanism by which HGF can promote tumor growth was highlighted by the studies which suggested that HGF increase the expression of VEGF, thereby initiating angiogenesis in a paracrine manner [24], HGF is a heparin-binding glycoprotein of mesenchymal origin that acts as a potent mitogen and motogen leading to organogenesis and tissue regeneration [25].

In conclusion, we have found that high AFP, multinodularity and high HGF were inter-related possible risk factors for 1-year recurrence of HCC in patients with initial remission following TACE. So, these parameters may be used to predict recurrence of HCC post TACE.

However, we should acknowledge that the present study has some limitations. This study included only patients candidate for TACE, several radiologists suggested that MRI should be used over CT for detection of viable tumor residuals after lipiodol based TACE. The 1-year follow up of recurrence may be short and need to be prolonged. So we recommend further studies to include patient candidates for locoregional therapy or surgery, the use of MRI for better follow up and extended duration of follow up more than 1 year.

Further studies with high sample sizes are needed to determine the potential clinical significance of these predictors and should include patients with early stages of the disease who are candidate for curative treatment modalities with longer period of follow up.

Conflicts of Interest

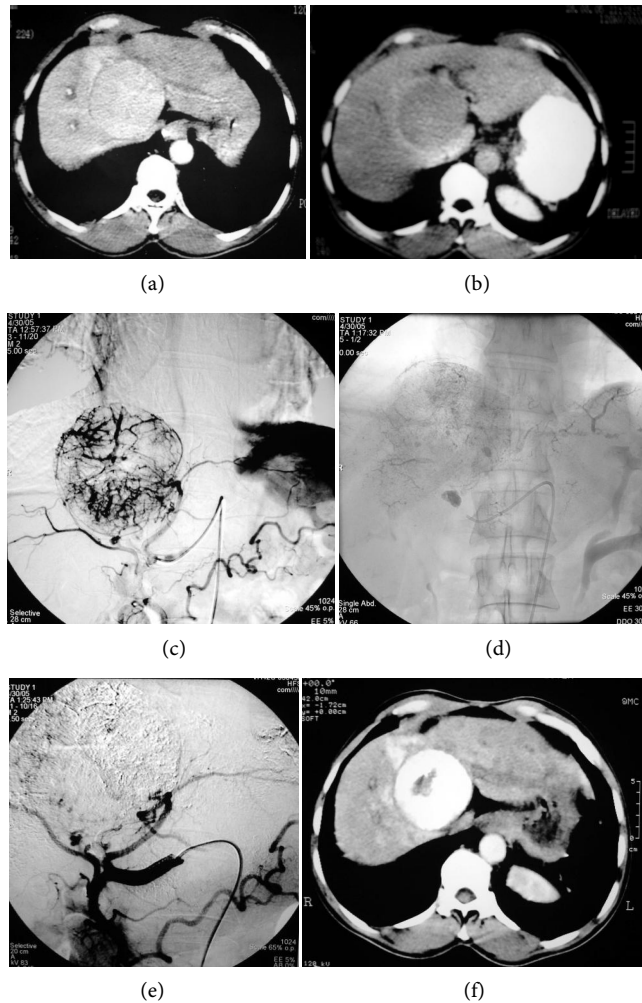
The authors declare no conflicts of interest regarding the publication of this paper.

References

- [1] Ferlay, J., Shin, H.R., Bray, F., Forman, D., Mathers, C. and Parkin, D.M. (2010) Estimates of Worldwide Burden of Cancer in 2008: GLOBOCAN 2008. *International Journal of Cancer*, **127**, 2893-2917. <https://doi.org/10.1002/ijc.25516>
- [2] Simonetti, R.G., Cammà, C., Fiorello, F., Politi, F., D'Amico, G. and Pagliaro, L. (1991) Hepatocellular Carcinoma. A Worldwide Problem and the Major Risk Factors. *Digestive Diseases and Sciences*, **36**, 962-972. <https://doi.org/10.1007/BF01297149>
- [3] Bruix, J. and Sherman, M. (2011) Management of Hepatocellular Carcinoma: An Update. *Hepatology*, **53**, 1020-1022. <https://doi.org/10.1002/hep.24199>
- [4] Park, W., Chung, Y.H., Kim, J.A., Jin, Y.J., Lee, D., Shim, J.H., Lee, D., Kim, K.M., Lim, Y.S., Lee, H.C., et al. (2013) Recurrences of Hepatocellular Carcinoma Following Complete Remission by Transarterial Chemoembolization or Radiofrequency Therapy: Focused on the Recurrence Patterns. *Hepatology Research*, **43**, 1304-1312. <https://doi.org/10.1111/hepr.12083>
- [5] Kohles, N., Nagel, D., Jüngst, D., Durner, J., Stieber, P. and Holdenrieder, S. (2012) Prognostic Relevance of Oncological Serum Biomarkers in Liver Cancer Patients Undergoing Transarterial Chemoembolization Therapy. *Tumor Biology*, **33**, 33-40. <https://doi.org/10.1007/s13277-011-0237-7>
- [6] Hsu, K.F., Chu, C.H., Chan, D.C., et al. (2012) Superselective Transarterial Chemoembolization vs Hepatic Resection for Resectable Early-Stage Hepatocellular Carcinoma in Patients with Child-Pugh Class a Liver Function. *European Journal of Radiology*, **81**, 466-471. <https://doi.org/10.1016/j.ejrad.2010.12.058>
- [7] Lencioni, R. and Llovet, J.M. (2010) Modified RECIST (mRECIST) Assessment for Hepatocellular Carcinoma. *Seminars in Liver Disease*, **30**, 52-60. <https://doi.org/10.1055/s-0030-1247132>
- [8] Ueno, S., Tanabe, G., Nuruki, K., et al. (2002) Prognostic Performance of the New Classification of Primary Liver Cancer of Japan (4th Edition) for Patients with Hepatocellular Carcinoma: A Validation Analysis. *Hepatology Research*, **24**, 395-403. [https://doi.org/10.1016/S1386-6346\(02\)00144-4](https://doi.org/10.1016/S1386-6346(02)00144-4)
- [9] Higashio, K., Shima, N., Goto, M., et al. (1990) Identity of a Tumorcytotoxic Factor from Human Fibroblasts and Hepatocytegrowth Factor. *Biochemical and Biophysical Research Communications*, **170**, 397-404. [https://doi.org/10.1016/0006-291X\(90\)91287-3](https://doi.org/10.1016/0006-291X(90)91287-3)
- [10] Tsubouchi, H., Niitani, Y., Hirono, S., et al. (1991) Levels of the Human Hepatocyte Growth Factor in Serum of Patients with Various Liver Diseases Determined by an Enzyme-Linked Immunosorbent Assay. *Hepatology*, **13**, 1-5. <https://doi.org/10.1002/hep.1840130102>
- [11] Nagai, T., Arao, T., Furuta, K., Sakai, K., Kudo, K., Kaneda, H., et al. (2011) Sorafenib Inhibits the Hepatocyte Growth Factor-Mediated Epithelial Mesenchymal Transition in Hepatocellular Carcinoma. *Molecular Cancer Therapeutics*, **10**, 169-177. <https://doi.org/10.1158/1535-7163.MCT-10-0544>
- [12] Ferrucci, J. and Mathieu, D. (2004) Advances in Hepatobiliary Radiology. The CV Mosby Company, St. Louis, Vol. 12, 295-305.
- [13] Achenbach, T., Seifert, J.K., Pitton, M.B., et al. (2002) Chemoembolization for Primary Liver Cancer. *European Journal of Surgical Oncology*, **28**, 37-41. <https://doi.org/10.1053/ejso.2001.1181>

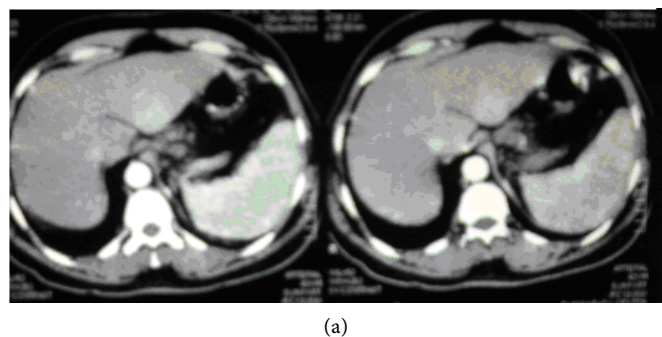
- [14] Lee, J.K., Chung, Y.H., Song, B.C., Shin, J.W., Choi, W.B., Yang, S.H., *et al.* (2002) Recurrences of Hepatocellular Carcinoma Following Initial Remission by Transcatheter Arterial Chemoembolization. *Journal of Gastroenterology and Hepatology*, **17**, 52-58. <https://doi.org/10.1046/j.1440-1746.2002.02664.x>
- [15] Matsuda, M., Omata, F., Fuwa, S., Saida, Y., Suzuki, S., Uemura, M., Ishii, N., Iizuka, Y., Fukuda, K. and Fujita, Y. (2013) Prognosis of Patients with Hepatocellular Carcinoma Treated Solely with Transcatheter Arterial Chemoembolization: Risk Factors for One-Year Recurrence and Two-Year Mortality (Preliminary Data). *Internal Medicine*, **52**, 847-853. <https://doi.org/10.2169/internalmedicine.52.9356>
- [16] Okuda, H., Nakanishi, T., Takatsu, K., *et al.* (2001) Comparison of Clinicopathological Features of Patients with Hepatocellular Carcinoma Seropositive for Alpha-Fetoprotein Alone and Those Seropositive for Des-Gamma-Carboxy Prothrombin Alone. *Journal of Gastroenterology and Hepatology*, **16**, 1290-1296. <https://doi.org/10.1046/j.1440-1746.2001.02610.x>
- [17] Evdokimova, V.N., Liu, Y., Potter, D.M. and Butterfield, L.H. (2007) AFP-Specific CD4+ Helper T-Cell Responses in Healthy Donors and HCC Patients. *Journal of Immunotherapy*, **30**, 425-437. <https://doi.org/10.1097/CJL.0b013e31802fd8e2>
- [18] Shiota, G., Okano, J., Kawasaki, H., Kawamoto, T. and Nakamura, T. (1995) Serum Hepatocyte Growth Factor in Liver Diseases: Clinical Implications. *Hepatology*, **21**, 106-112. <https://doi.org/10.1002/hep.1840210119>
- [19] Yamagamim, H., Moriyama, M., Matsumura, H., Aoki, H., Shimizu, T., Saito, T., *et al.* (2002) Serum Concentrations of Human Hepatocyte Growth Factor Is a Useful Indicator for Predicting the Occurrence of Hepatocellular Carcinomas in C-Viral Chronic Liver Diseases. *Cancer*, **95**, 824-834. <https://doi.org/10.1002/cncr.10732>
- [20] El Deen, S.H. and El-Haddad, H. (2015) Significance of Hepatocyte Growth Factor Concentrations in Serum of Patients with Liver Cirrhosis and Patients with Hepatocellular Carcinoma. *The Egyptian Journal of Internal Medicine*, **27**, 92-102. <https://doi.org/10.4103/1110-7782.165437>
- [21] Hamed, M.A. and Ali, S.A. (2013) Non-Viral Factors Contributing to Hepatocellular Carcinoma. *World Journal of Hepatology*, **5**, 311-322. <https://doi.org/10.4254/wjh.v5.i6.311>
- [22] Karabulut, S., Tas, F., Akyüz, F., Ormeci, A.C., Serilmez, M., Soydinç, H.O., *et al.* (2014) Clinical Significance of Serum Hepatocyte Growth Factor (HGF) Levels in Hepatocellular Carcinoma. *Tumor Biology*, **35**, 2327-2333. <https://doi.org/10.1007/s13277-013-1308-8>
- [23] Matsumoto, K. and Nakamura, T. (2006) Hepatocyte Growth Factor and the Met System as a Mediator of Tumor-Stromal Interactions. *International Journal of Cancer*, **119**, 477-483. <https://doi.org/10.1002/ijc.21808>
- [24] Van Belle, E., Witzensichler, B., Chen, D., Silver, M., Chang, L., Schwall, R. and Isner, J.M. (1998) Potentiated Angiogenic Effect of Scatter Factor/Hepatocyte Growth Factor via Induction of Vascular Endothelial Growth Factor: The Case for Paracrine Amplification of Angiogenesis. *Circulation*, **97**, 381-390. <https://doi.org/10.1161/01.CIR.97.4.381>
- [25] Birchmeier, C. and Gherardi, E. (1998) Developmental Roles of HGF/SF and Its Receptor, the c-Met Tyrosine Kinase. *Trends in Cell Biology*, **8**, 404-410. [https://doi.org/10.1016/S0962-8924\(98\)01359-2](https://doi.org/10.1016/S0962-8924(98)01359-2)

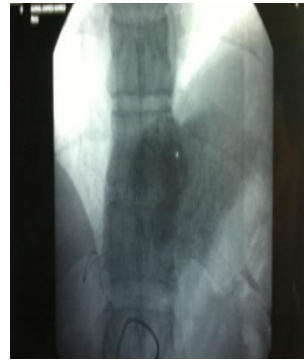Appendix 1: Case (1)



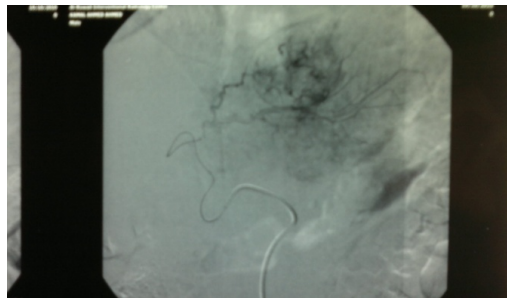
Case (1). Triphasic CT scan of the liver showing hepatic mass involving segment 8 in arterial (a) and delayed phases (b). (c) Digital subtraction angiography showing hepatic mass lesion (d) Angiography during chemoembolization. (e) Digital subtraction angiography post TACE showing disappearance of tumor vascularity and Lipiodol uptake. (f) CT scan at the same level one month after the last TACE, showing marked response with no residual viable tumor tissue.

Appendix 2: Case (2)

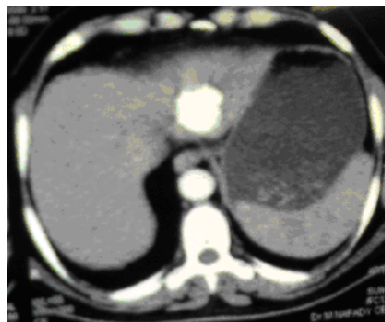




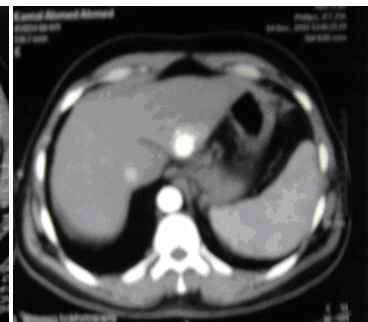
(b)



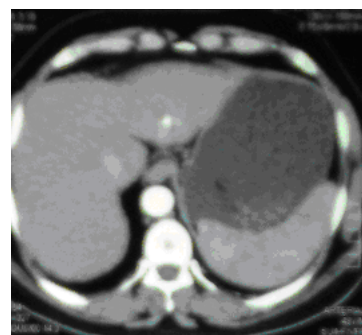
(c)



(d)

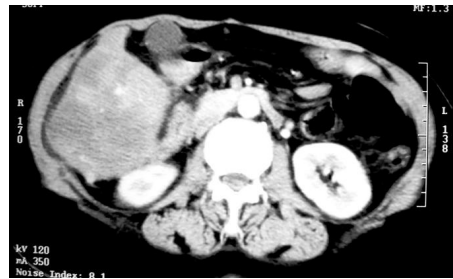

(e)

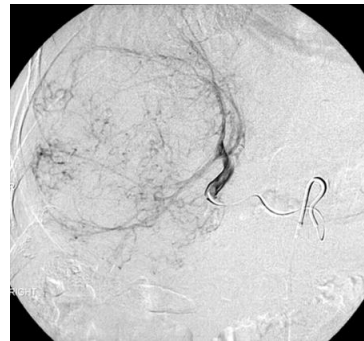

(f)

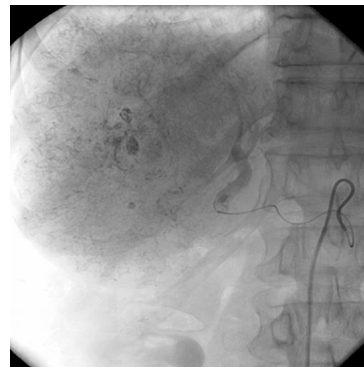
Case (2). (a) Triphasic CT scan of the liver showing hepatic mass involving Lt hepatic lobe segment 3 in arterial phases. (b) and (c): Digital subtraction angiography showing angiographic blush of hepatic mass lesion. CT scan at the same level one month after TACE, showing marked response to treatment. (d) CT scan at the same level six months after TACE, showing reduced size with no residual enhancing tumor tissue. (e) CT scan at the same level one year after TACE, showing vanishing of the focal lesion with no residual enhancing tumor tissue (f).

Appendix 3: Case (3)

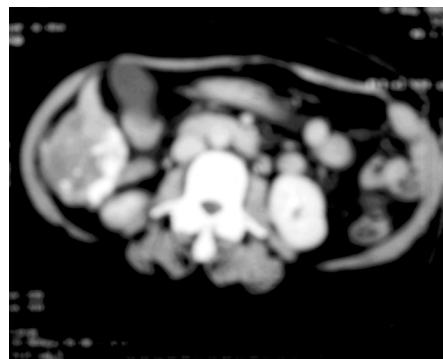
(a)



(b)



(c)



(d)

Case (3). (a) Arterial phase Triphasic CT scan of the liver showing hypovascular mass lesion involving the right lobe. (b) Selective hepatic arteriography showing displacement of the hepatic vessels by the hypovascular tumor. (c) The procedure using microcatheter. (d) Follow up CT showing poor response to chemoembolization.