



Published in final edited form as:

Psychiatry Res. 2001 November 30; 108(2): 65–78.

Prefrontal cortex, negative symptoms, and schizophrenia: an MRI study

Cynthia G. Wible^{a,b,c,d}, Jane Anderson^{a,b,c,d}, Martha E. Shenton^{a,b,c,d}, Ashley Kricun^{a,b,c,d}, Yoshio Hirayasu^{a,b,c,d}, Shin Tanaka^{a,b,c,d}, James J. Levitt^{a,b,c,d}, Brian F. O'Donnell^{a,b,c,d}, Ron Kikinis^{e,f}, Ferenc A. Jolesz^{e,f}, and Robert W. McCarley^{a,b,c,d,*}

^aDepartment of Psychiatry, Harvard Medical School, Boston, MA, USA

^bBrockton Veterans Affairs Medical Center, Brockton, MA, USA

^cMassachusetts Mental Health Center, Boston, MA, USA

^dMcLean Hospital, Belmont, MA, USA

^eDepartment of Radiology, Harvard Medical School, Boston, MA, USA

^fMRI Division, Surgical Planning Laboratory, Brigham and Women's Hospital, Boston, MA, USA

Abstract

The present study measured prefrontal cortical gray and white matter volume in chronic, male schizophrenic subjects who were characterized by a higher proportion of mixed or negative symptoms than previous patients that we have evaluated. Seventeen chronic male schizophrenic subjects and 17 male control subjects were matched on age and handedness. Regions of interest (ROI) were measured using high-resolution magnetic resonance (MR) acquisitions consisting of contiguous 1.5-mm slices of the entire brain. No significant differences were found between schizophrenic and control subjects in mean values for prefrontal gray matter volume in either hemisphere. However, right prefrontal white matter was significantly reduced in the schizophrenic group. In addition, right prefrontal gray matter volume was significantly correlated with right hippocampal volume in the schizophrenic, but not in the control group. Furthermore, an analysis in which the current data were combined with those from a previous study showed that schizophrenic subjects with high negative symptom scores had significantly smaller bilateral white matter volumes than those with low negative symptom scores. White matter was significantly reduced in the right hemisphere in this group of schizophrenic subjects. Prefrontal volumes were also associated with negative symptom severity and with volumes of medial–temporal lobe regions — two results that were also found previously in schizophrenic subjects with mostly positive symptoms. These results underscore the importance of temporal–prefrontal pathways in the symptomatology of schizophrenia, and they suggest an association between prefrontal abnormalities and negative symptoms.

Keywords

White matter; Temporal lobe; Hippocampus; Orbitofrontal cortex

* Corresponding author. Psychiatry Service, 116A, Brockton VA Medical Center, 940 Belmont Street, Brockton, MA 02401, USA. Tel: +1-508-583-4500, ext. 2479; fax: +1-508-586-0894. robert_mccarley@hms.harvard.edu (R.W. McCarley).

1. Introduction

Frontal lobe abnormalities have been hypothesized to contribute to the schizophrenic syndrome. Frontal functions such as attention, working memory, eye movement, judgment and insight are thought to be impaired in schizophrenic patients (Mesulam, 1981; Damasio and Van Hoesen, 1983; Mesulam, 1990; Goldman-Rakic and Friedman, 1991; Anderson et al., 1994; Paus, 1995; Petit et al., 1995). Both structural and physiological frontal abnormalities have been reported in schizophrenic patients, but the findings have often been contradictory. Magnetic resonance imaging (MRI) studies have found reduced volume in the frontal lobe. However, this finding has not been consistently replicated. Table 1 contains a summary of prefrontal MRI findings in schizophrenia; also see recent reviews of MR studies of schizophrenia for a more detailed discussion of frontal findings (Shenton et al., 1997, 2001; McCarley et al., 1999). Inconsistent findings across studies could be attributed to the diverse methodologies used, including differences in factors such as MR image resolution, segmentation procedures, subject matching variables, and the symptom profiles of the patient group.

The present study measured prefrontal gray and white matter in closely matched groups of schizophrenic subjects and normal control subjects using quantitative volumetric techniques and high resolution MRI scans. The study was designed to be similar in MRI methods to a previous study of prefrontal cortex volume in chronic schizophrenics (Wible et al., 1995) in which no volume differences were found between groups. However, the schizophrenic subjects for the present study were chosen from outpatient community residences and therefore consisted of a higher proportion of subjects showing negative symptoms (either the mixed or negative symptom rating) relative to the previous study, which drew on an acutely hospitalized sample.

Temporal lobe structures such as the amygdala, hippocampus, entorhinal cortex, parahippocampal gyrus, and superior temporal gyrus have been shown to be abnormal in schizophrenic subjects, especially on the left side (Shenton et al., 1992, 1997; McCarley et al., 1999). These temporal lobe structures are highly interconnected with the prefrontal cortex (Goldman-Rakic et al., 1984; Pandya and Yeterian, 1990; Wible et al., 1995), and in a previous study we observed volume correlations between prefrontal and temporal regions in schizophrenic subjects that were not present in control subjects. Such volume correlations are suggestive of a functional system that is pathological in the schizophrenic brain, and we predicted that these correlations would also be found in the current subject group.

Several negative symptoms of the schizophrenic syndrome are similar to those symptoms present after frontal lobe damage (e.g. attentional deficits, lack of insight into behavior). Clinical measures of negative, but not positive symptoms were correlated with prefrontal volume measures in the schizophrenic group of the previous study. We predicted that these same clinical correlations would be present in the current study.

2. Methods

2.1. Subjects

MR scans were obtained from 17 schizophrenic and 17 right-handed male control subjects. Schizophrenic subjects were recruited from the Brockton Veterans Affairs Medical Center; one was hospitalized at the time of recruitment, 16 were in VA community residences, and all were receiving neuroleptic medication. Control subjects were recruited through newspaper advertisements. Patient diagnoses were made in accord with the Diagnostic and Statistical Manual of Mental Disorders (DSM-III-R), on the basis of chart review, and from information obtained from administration of the Schedule for Affective Disorders and Schizophrenia

(Spitzer and Endicott, 1978). Subjects were admitted to the study if they were between the ages of 20 and 55 years with no history of electroconvulsive shock treatment, neurologic illness, or steroid use, and no lifetime history of drug/alcohol addiction or abuse (DSM-III-R) within the last 5 years. Control subjects were also excluded if they had a history of psychiatric illness in themselves or in their first-degree relatives.

The schizophrenic and control subjects were matched (as a group) on age and handedness, and there were no statistically significant differences between the two groups in height, weight, head circumference, or scores on the WAIS-R information subscale (Wechsler, 1981). There was a difference in socioeconomic status of the family of origin. See Table 2 for the means and standard deviations (S.D.) of subject characteristics, including the mean chlorpromazine (CPZ) equivalents. All subjects signed written informed consent prior to study participation. No subjects were in common with the previous prefrontal study (Wible et al., 1995).

2.2. Clinical evaluations

Three instruments were used to assess symptoms: The Scale for the Assessment of Positive Symptoms (Andreasen, 1984); the Scale for the Assessment of Negative Symptoms (Andreasen, 1981); and the Thought Disorder Index (Johnston and Holzman, 1979). In the Andreasen classification, 11 of the patients were characterized as having mixed symptoms, four had mainly positive symptoms, and two had mainly negative symptoms.

It should be noted that negative symptoms in this study were measured using the SANS scale, not the Schedule for the Deficit Syndrome. The Deficit Syndrome Scale differs from the SANS scale in that the presence or absence of negative symptoms is considered independently of psychotic symptoms and that the symptoms must be enduring features (Kirkpatrick et al., 1989).

2.3. MRI methodology

All MR scans were acquired at the Brigham and Women's Hospital with a 1.5-T General Electric SIGNA System (GE Medical Systems, Milwaukee, WI). The MR methodology is described in detail elsewhere (Shenton et al., 1992), and hence will be only briefly described here. For the measurement of prefrontal gray and white matter regions of interest (ROI), a three-dimensional Fourier transform spoiled gradient-recalled acquisition in steady state (3DFT SPGR) was acquired throughout the entire brain and reformatted into 124 contiguous 1.5-mm coronal slices. The SPGR images were obtained using the following parameters: echo time (TE) = 5 ms, repetition time (TR) = 35 ms, one repetition, nutation angle = 45°, field of view = 24 cm, acquisition matrix = 256 × 256 × 124, voxel dimensions = 0.9375 × 0.9375 × 1.5 mm.

For the measurement of the intracranial contents, 108 (54 for each echo) contiguous double-echo spin-echo 3-mm axial slices were obtained throughout the extent of the brain. Imaging parameters were: TE = 30 ms, TR = 3000 ms, field of view = 24 cm, acquisition matrix = 256 × 256, voxel dimensions = 0.9375 × 0.9375 × 3 mm. No gross abnormalities were found in the scans when they were evaluated by a clinical neuroradiologist.

2.4. Image processing

The image-processing stages were different for the whole brain vs. the individual region of interest (ROI) measurements. The image processing for the ROI measurements on the SPGR scans proceeded in several stages. (1) The SPGR images were filtered to reduce noise (Gerig et al., 1990). (2) The SPGR images were segmented using the iterative expectation-maximization (EM) algorithm. This algorithm combines the statistical classification of tissue classes with the automatic identification of intensity inhomogeneities in the images. The EM

segmenter alternates two computational stages. In one stage, the spatial intensity inhomogeneities in the images are estimated, and then in a second stage, this estimate is used to improve the accuracy of the tissue classification. An initial semi-automated segmentation (the algorithm used for segmentation in our previous articles) was used as a starting point or as input to the EM segmenter, and then the algorithm improved the segmentation in several iterations of the two steps (Wells et al., 1996). The segmentations computed using this algorithm were more consistent in estimating tissue classes than the semi-automated segmentation procedures when the segmentation was compared among five raters (Wells et al., 1996). In previous articles (Wible et al., 1995), the measurement of the gray/white matter volume in a cortical region required slice by slice editing of the boundary on each slice. The segmentations obtained using the EM segmenter required much less editing. (3) The results of the segmentation were then superimposed on the original SPGR image and edited using an image-editing program, slice by slice, on the computer workstation to exclude extraneous tissue from the gray/white matter segmentation, and to assign the left and right lobes to separate tissue classes. The slice editor contained algorithms to perform manual drawing of ROI, connectivity, island removal, erosion and dilation of tissue classes, a color editor to assign colors to different ROI, and a magnifier to magnify the image to a user-chosen level of magnification. The current version of this image editor (Gering et al., 1999) is described on our web pages at <http://splweb.bwh.harvard.edu:8000/pages/papers/slicer/index.html>. (5) A dividing cubes algorithm was used to reconstruct the segmentation to allow for a three-dimensional view of each tissue class (Cline et al., 1988, 1990). The voxels for each tissue class were summed to compute the volume for each slice and the cumulative volume.

The image-processing procedures for the measurement of intracranial content (used to compute the relative volume measurements) were described in detail, in a previous study (Shenton et al., 1992). The 3-mm double-echo axial scans were used for this measurement, and the image processing required some of the same algorithms as those used in measurement of the specific prefrontal ROI, including a preprocessing filter, and algorithms for segmentation, connectivity, three-dimensional reconstruction and visualization, and an algorithm for calculating volume.

2.5. Specific brain regions of interest

The gray and white matter of the prefrontal cortex was measured using the same landmarks as in our previous study (Wible et al., 1995). The posterior boundary of the gray matter coincided with the separation of frontal and temporal lobe areas as illustrated in Fig. 1A,B. The most posterior slice on which we measured prefrontal gray matter is shown in Fig. 1A in relationship to the ventricles. Fig. 1B shows a three-dimensional reconstruction of the white matter in relationship to the ventricles and the most posterior gray matter slice. Reliability for the gray and white matter volumes is discussed below.

2.6. Reliability of image-processing techniques

2.6.1. Intra-rater reliability for the frontal lobe volumetric measures—The 34 cases were first segmented by CGW. Intra-rater reliability was assessed using the same four pre-selected representative slices throughout the frontal lobe for 10 cases. The intraclass correlation was $r_1 = 0.80$.

2.6.2. Inter-rater reliability for the volumetric measures—Inter-rater reliability for two additional raters was also obtained for the same 10 cases and was $r_1 = 0.84$.

2.7. Statistical analyses

Left and right volumes of prefrontal gray and white matter were analyzed using a multivariate analysis of variance (MANOVA) with the variables group (schizophrenic vs. control), tissue class (white or gray matter), and side (right or left). An analysis of covariance (ANCOVA)

was also used, and the factors analyzed in the MANOVA were covaried with age. Analyses were computed separately for absolute volumes, and for relative volumes — the latter corrected for head size by dividing the absolute volume by the volume of the intracranial contents and multiplying by 100.

Volumetric data were available for several temporal lobe structures for the subjects used in this study (Anderson et al., submitted). The hypothesis guiding the examination of the relationship between volumes of prefrontal and temporal ROI in patients with left-lateralized temporal lobe abnormalities was that prefrontal–temporal correlations would be significant in schizophrenic, but not control subjects.

Univariate correlation coefficients were also computed, for comparison, for right temporal lobe structures and right prefrontal gray and white matter. Correlations were also performed, for schizophrenic patients only, between clinical measures and prefrontal left and right, gray and white matter, to assess the degree of association between symptomatology and prefrontal volume measurements.

2.8. Analyses combining current data with previously published prefrontal data

The patient groups from the previous (Wible et al., 1995) and current studies were combined and redivided into groups based on symptom profiles. This was done to examine the relationship between frontal volumes and negative symptoms. The *Z*-score for each (relative) prefrontal volume measure was computed for each patient by using the mean and S.D. of the corresponding control group for that patient. *Z*-scores were used because we were combining patients from different studies with different control groups. The subjects thus had to be matched to their corresponding control groups, and this necessitated the use of *Z*-scores. The patient group was then ranked by the total SANS score and divided into two equal groups of patients, one group with the lower SANS scores and the other with the higher SANS scores. The dividing SANS score was 10. Note that the SANS score for one patient from the previous study was not available. These *Z*-score measures were then subjected to analyses.

3. Results

3.1. Prefrontal volume measures

In the present sample, control and schizophrenic subjects had similar mean values for gray, but not white matter volume (see Table 3). The results derived from relative measures showed the same pattern of statistical significance as those derived from absolute measures. For brevity, only the results of the relative measures will be reported in the text (relative and absolute volumes, as well as mean number of slices used, are reported in Table 3). The MANOVA showed a three-way interaction between group, tissue, and side ($F = 7.30$, d.f. = 1,32, $P = 0.01$). There were no two-way interactions. Follow up *t*-tests showed significant differences between groups in right prefrontal white matter ($t = -2.85$, d.f. = 1,32, $P = 0.008$). An ANCOVA was done with the same factors using subject age as a covariate; this analysis showed a pattern of significance similar to that described above.

3.2. Prefrontal–temporal univariate Pearson product-moment correlations

Note that correlations are reported only if values were consistently significant using both absolute and relative volume measures. Volumes of right prefrontal gray matter and right posterior amygdala–hippocampal complex showed high positive correlations for schizophrenic subjects ($r = 0.73$, $P = 0.001$ abs. vol.; $r = 0.68$, $P = 0.004$ rel. vol.). This correlation was not significant in the control group (vol.; $r = 0.48$, $P = 0.118$ abs. vol.; $r = 0.43$, $P = 0.17$ rel. vol.).

3.3. Prefrontal ROI-clinical correlations

The correlation of total SANS scores and left frontal gray matter volume was significant in schizophrenic subjects ($r = -0.50$, $P = 0.043$ abs. vol.; $r = -0.52$, $P = 0.033$ rel. vol.). The correlations between SANS score and white matter volumes did not reach significance in the current sample ($r = -0.29$, $P = 0.26$ abs. vol., left hemisphere; $r = -0.07$, $P = 0.78$ abs. vol., right hemisphere). Thought Disorder Index scores did not correlate with any measure of prefrontal cortex volume.

3.4. Analyses of combined data from the current study and a previously published study

The same analysis described above for the current subject sample was performed on the combined data from current and previously published prefrontal volumes of schizophrenic and control groups. The previous study used the same general scanning parameters and the image editor was also the same as used in the current study. The segmentation algorithms differed between the two studies; however, the final editing of the segmentation was done by hand in both studies. No significant differences were found between combined groups (combined schizophrenia, $n = 31$, and combined control, $n = 32$) for any of the prefrontal measures (right or left gray or white matter).

The relative prefrontal volume measures for the combined schizophrenic group were transformed into Z -scores and the combined group was split into halves according to SANS scores (see Section 2). The low SANS group had a total SANS score (S.D.) of 7.2 (1.9), with a range of 4–10. The high SANS group had a total SANS score (S.D.) of 13.5 (2.6), with a range of 10–18.

A repeated measures ANOVA using schizophrenic group's Z scores was computed separately for each tissue type (gray and white matter) using the factors SANS group (high or low total SANS score) and side (right or left). Gray matter volumes showed no significant differences between SANS groups. White matter volumes were significantly different between SANS groups ($F = 4.12$; d.f. = 1,29; $P = 0.052$ for absolute volumes; $F = 5.88$; d.f. = 1,29; $P = 0.022$ for relative volumes). The higher SANS score group had reduced white matter compared with the lower SANS group (see Fig. 2).

The SANS group by side interaction was not significant. Significant correlations were found between Z -scores for left white matter and SANS scores of the combined schizophrenic group ($r = -0.50$, $P = 0.005$ abs. vol.; $r = -0.49$, $P = 0.005$ rel. vol.). Significant correlations were also found between Z -scores for total prefrontal volume (gray and white matter combined) and total SANS scores ($r = -0.43$, $P = 0.019$ abs. vol.; $r = -0.38$, $P = 0.04$ rel. vol.).

4. Discussion

The present study used high resolution MRI in conjunction with semi-automated image-processing procedures to measure whole prefrontal cortical gray and prefrontal white matter volume in schizophrenic and control subjects. No significant differences were found between the two groups in either right or left gray matter volume; however, right white matter volume was significantly reduced in the schizophrenic group when compared with control subjects. These results are similar to those of Breier et al. (1992), whose methodology has comparable image resolution to that used in the present study. The Breier et al. study also did not find gray matter volume reductions in schizophrenic subjects, but did report white matter volume reduction on both sides of the brain. Buchanan et al. (1993) also reported white matter abnormalities in schizophrenic subjects.

White matter abnormalities were not found in our previous sample of positive symptom schizophrenic subjects. The different findings are likely to be a result of the different symptom

profiles of the previous (positive symptom) and current (negative symptom) groups. In the current study, 11 of the 17 patients had predominately mixed symptoms, four had mainly positive symptoms, and two had mainly negative symptoms. In the previous study, symptom profiles were very different. Eleven of the 14 patients were assessed as having mainly positive symptoms, three patients were characterized as having mixed symptoms, and none of the patients had predominately negative symptoms (Wible et al., 1995).

Schizophrenic subjects from our previous and current studies were combined and split into two groups based on SANS total score. This combined analysis showed that the Z-scores for bilateral white matter volumes were significantly smaller in schizophrenic patients from the higher SANS group (see Fig. 2). In other words, the higher the SANS score, the smaller the prefrontal white matter volumes. Although much of the methodology stayed constant between the current and previous studies, caution must be taken in interpreting results from combined studies that were performed at different times with differing methodologies. Sanfilipo et al. (2000) also found an association between white matter volume and negative symptoms in schizophrenic subjects. They reported that the white matter reduction was most severe in the orbitofrontal region. Gur et al. (2000) reported an association, in women schizophrenic subjects only, between decreased orbital (gray matter) volumes and negative symptoms. In the current sample, we also found a significant correlation between total SANS scores and left frontal gray matter volume in schizophrenic subjects. Together these findings suggest a relationship between prefrontal abnormalities and negative symptoms.

The lack of gray matter or total volume findings is also in agreement with several other studies that have reported no volumetric differences in this area between schizophrenic and control subjects (see Table 1). However, a reduction in white matter volume is likely to signify degeneration or cell death either in the frontal lobe or in regions that project to the frontal lobe. Thus, this finding of white matter reduction is not inconsistent with or contradictory to the reports of gray matter volume reductions that have been reported in several studies (see Table 1). A white matter volume reduction followed by changes in gray matter would suggest different primary pathological loci or processes than would either a finding of only gray matter loss or a finding of both gray and white matter loss combined. These issues need to be resolved in future research.

Temporal lobe pathology has been demonstrated in schizophrenic subjects using both MRI and post-mortem histological studies (for reviews, see Shenton et al., 1997; Wible et al., 1997; McCarley et al., 1999). Correlations were found between volumes of right hippocampal and right prefrontal gray matter volumes in schizophrenic, but not control subjects. These findings are again similar to those of the Breier et al. (1992) study, which found a significant correlation between the right hippocampal–amygdala complex and right prefrontal white matter in schizophrenic subjects. The previous study from our laboratory found a relationship between anterior portions of the hippocampal–amygdala complex, parahippocampal gyrus, and superior temporal gyrus and prefrontal white and gray volume on the left side in schizophrenic subjects. Again, the differences in correlations may be due to the different symptom profiles of the previous and current patient groups.

The volume correlations found between temporal and prefrontal regions in schizophrenic patients, but not control subjects, may indicate volume reductions in tightly anatomically and functionally linked temporal–prefrontal regions such as hippocampal, superior temporal, cingulate, orbital and inferior frontal regions. A detailed discussion of these ideas and the neuroanatomical relationships can be found in Wible et al. (1997).

As in the previous study, here we hypothesize that a use-dependent and/or developmental pathological process that affects temporal lobe structures may also be affecting prefrontal

cortical areas in a parallel manner, resulting in stronger than normal relationships between volumes in these areas (Wible et al., 1997).

The lack of detection of gray matter volumetric abnormalities in the current study should be interpreted with caution in light of the sensitivity of MR findings. Abnormalities in cellular orientation, connectivity, receptor distribution and sensitivity, and neurotransmitter distribution, among other factors, are not detectable by MRI and have been previously reported (Benes et al., 1986, 1991). However, a histological study reporting abnormalities in prefrontal areas did not find a *significant difference* between schizophrenic and control subjects in the cortical thickness of area 9 of the prefrontal cortex because the differences were not large enough to reach significance (Selemon et al, 1995).

The results of this study point to abnormal temporal-prefrontal pathways, a finding for which there is converging evidence from many studies. The findings also suggest that there may be differences in brain pathology or primary brain pathology in accordance with specific schizophrenic symptoms, and that negative symptoms may be associated with prefrontal abnormalities.

Acknowledgments

This research was supported by the National Institute of Mental Health through a National Research Service Award MH 16259 (JA), a K02 award, MH 01110 (MES), and MH 40799 and MH 52807 (RWM) and Department of Veterans Affairs Merit (MES, RWM) and Middleton (RWM) awards.

References

- Anderson TJ, Jenkins IH, Brooks DJ, Hawken MB, Frackowiak RSJ, Kennard C. Cortical control of saccades and fixation in man. A PET study. *Brain* 1994;117:1073–1084. [PubMed: 7953589]
- Anderson JE, Wible CG, McCarley RW, Jakab M, Kasai K, Shenton ME. An MRI Study of Temporal Lobe Abnormalities and Negative Symptoms in Chronic Schizophrenia. Submitted to Schizophrenia Research.
- Andreasen, N. Scale for the Assessment of Negative Symptoms (SANS). University of Iowa; Iowa City: 1981.
- Andreasen, N. Scale for the Assessment of Positive Symptoms (SAPS). University of Iowa; Iowa City: 1984.
- Andreasen N, Nasrallah HA, Dunn V, Olson SC, Grove WM, Ehrhardt JC, Coffman JA, Crossett JH. Structural abnormalities in the frontal system in schizophrenia. A magnetic resonance imaging study. *Archives of General Psychiatry* 1986;43:136–144. [PubMed: 3947208]
- Andreasen NC, Ehrhardt JC, Swayze VW, Alliger RJ, Yuh RT, Cohen G, Ziebell S. Magnetic resonance imaging of the brain in schizophrenia. The pathophysiologic significance of structural abnormalities. *Archives of General Psychiatry* 1990;47:35–44. [PubMed: 2294854]
- Andreasen NC, Flashman L, Flaum M, Arndt S, Swayze VW II, O'Leary DS, Ehrhardt JC, Yuh WT. Regional brain abnormalities in Schizophrenia measured with magnetic resonance imaging. *Journal of the American Medical Association* 1994;272:1763–1769. [PubMed: 7966925]
- Baare WF, Hulshoff Pol HE, Hijman R, Mali WP, Viergever MA, Kahn RS. Volumetric analysis of frontal lobe regions in schizophrenia: relation to cognitive function and symptomatology. *Biological Psychiatry* 1999;45:1597–1605. [PubMed: 10376121]
- Benes FM, Davidson J, Bird ED. Quantitative cytoarchitectural studies of the cerebral cortex of schizophrenics. *Archives of General Psychiatry* 1986;43:31–35. [PubMed: 3942472]
- Benes FM, McSparren J, Bird ED, SanGiovanni JP, Vincent SL. Deficits in small interneurons in prefrontal and cingulate cortices of schizophrenic and schizoaffective patients. *Archives of General Psychiatry* 1991;48:996–1001. [PubMed: 1747023]

- Bilder RM, Wu H, Bogerts B, Degreef G, Ashtari M, Alvir JMJ, Snyder PJ, Lieberman JA. Absence of regional hemispheric volume asymmetries in first-episode schizophrenia. *American Journal of Psychiatry* 1994;151:1437–1447. [PubMed: 8092337]
- Blackwood DH, Young AH, McQueen JK, Martin MJ, Roxborough HM, Muir WJ, St Clair DM, Kean DM. Magnetic resonance imaging in schizophrenia: altered brain morphology associated with P300 abnormalities and eye tracking dysfunction. *Biological Psychiatry* 1991;30:753–769. [PubMed: 1751619]
- Bornstein RA, Schwarzkopf SB, Olson SC, Nasrallah HA. Third ventricle enlargement and neuropsychological deficit in schizophrenia. *Biological Psychiatry* 1992;31:954–961. [PubMed: 1637933]
- Breier A, Buchanan RW, Elkashef A, Munson RC, Kirkpatrick B, Gellad F. Brain morphology and schizophrenia. A magnetic resonance imaging study of limbic, prefrontal cortex, and caudate structures (see comments). *Archives of General Psychiatry* 1992;49:921–926. [PubMed: 1449382]
- Buchanan RW, Breier A, Kirkpatrick B, Elkashef A, Munson RC, Gellad F, Carpenter WR. Structural abnormalities in deficit and nondeficit schizophrenia (see comments). *American Journal of Psychiatry* 1993;150:59–65. [PubMed: 8417581]
- Buchanan RW, Valdar K, Barta PE, Pearlson GD. Structural evaluations of the prefrontal cortex in schizophrenia. *American Journal of Psychiatry* 1998;155:1049–1055. [PubMed: 9699693]
- Cline HE, Lorensen WE, Ludke S, Crawford CR, Teeter BC. Two algorithms for the three-dimensional reconstruction of tomograms. *Medical Physics* 1988;15:320–327. [PubMed: 3043154]
- Cline HE, Lorensen WE, Kikinis R, Jolesz F. Three-dimensional segmentation of MR images of the head using probability and connectivity. *Journal of Computer Assisted Tomography* 1990;14:1037–1045. [PubMed: 2229557]
- Corey-Bloom J, Jernigan T, Archibald S, Harris MJ, Jeste DV. Quantitative magnetic resonance imaging of the brain in late-life schizophrenia. *American Journal of Psychiatry* 1995;152:447–449. [PubMed: 7864275]
- Damasio, AR.; Van Hoesen, GW. Emotional disturbances associated with focal lesions of the limbic frontal lobe. In: Heilman, K.; Satz, P., editors. *Neuropsychology of Human Emotion*. Guilford; New York: 1983. p. 85
- DeLisi LE, Hoff AL, Schwartz JE, Shields GW, Halthore SN, Gupta SM, Henn FA, Anand AK. Brain morphology in first episode schizophrenic-like psychotic patients: a quantitative magnetic resonance imaging study. *Biological Psychiatry* 1991;29:159–175. [PubMed: 1995085] *Biological Psychiatry* 1991 Mar 1;29(5):519. published erratum appears in.
- DeMyer MK, Gilmore RL, Hendrie HC, DeMyer WE, Augustyn GT, Jackson RK. Magnetic resonance brain images in schizophrenic and normal subjects: influence of diagnosis and education. *Schizophrenia Bulletin* 1988;14:21–37. [PubMed: 3387916]
- Egan MF, Duncan CC, Suddath RL, Kirsh DG, Mirsky AF, Wyatt RJ. Event related potential abnormalities correlate with structural brain alterations and clinical features in patients with chronic schizophrenia. *Schizophrenia Research* 1994;11:259–271. [PubMed: 7910755]
- Gerig, G.; Kikinis, R.; Kubler, O. Significant Improvement of MR Image Data Quality Using Anisotropic Diffusion Filtering. *Communication Technology Laboratory, Image Science Division; Zurich, Switzerland: 1990.*
- Gering, D.; Nabavi, A.; Kikinis, R.; Grimson, WEL.; Hata, N.; Everett, P.; Jolesz, F.; Wells, W, III. An integrated visualization system for surgical planning and guidance using image fusion and interventional imaging. *Proceedings of the Medical Image Computing and Computer-Assisted Intervention (MICCAI); Cambridge, England. 1999 Sept. p. 809-819.*
- Goldman-Rakic, PS.; Friedman, H. The circuitry of working memory revealed by anatomy and metabolic imaging. In: Levin, HS.; Eisenberg, HM.; Benton, AL., editors. *Frontal Lobe Function and Dysfunction*. Oxford University Press; New York: 1991. p. 72-91.
- Goldman-Rakic PS, Selemon LD, Schwartz ML. Dual pathways connecting the dorsolateral prefrontal cortex with the hippocampal formation and parahippocampal cortex in the rhesus monkey. *Neuroscience* 1984;12:719–743. [PubMed: 6472617]

- Goldstein JM, Goodman JM, Seidman LJ, Kennedy DN, Makris N, Lee H, Tourville J, Caviness VS, Faraone VS, Tsuang MT. Cortical abnormalities in schizophrenia identified by structural magnetic resonance imaging. *Archives of General Psychiatry* 1999;56:537–547. [PubMed: 10359468]
- Gur RE, Cowell P, Turetsky BI, Gallacher F, Cannon T, Bilker W, Gur R. A follow-up magnetic resonance imaging study of schizophrenia. Relationship of neuroanatomical changes to clinical and neurobehavioral measures. *Archives of General Psychiatry* 1998;55:145–152. [PubMed: 9477928]
- Gur RE, Cowell PE, Latshaw A, Turetsky BI, Grossman RI, Arnold SE, Bilker WB, Gur RC. Reduced dorsal and orbital prefrontal gray matter volumes in schizophrenia. *Archives of General Psychiatry* 2000;57:761–768. [PubMed: 10920464]
- Harvey I, Ron MA, Du Boulay G, Wicks D, Lewis SW, Murray RM. Reduction of cortical volume in schizophrenia on magnetic resonance imaging. *Psychosomatic Medicine* 1993;23:591–604.
- Jernigan TL, Zisook S, Heaton RK, Moranville JT, Hesselink JR, Braff DL. Magnetic resonance imaging abnormalities in lenticular nuclei and cerebral cortex in schizophrenia. *Archives of General Psychiatry* 1991;48:881–890. [PubMed: 1929757]
- Johnston, MH.; Holzman, PS. *Assessing Schizophrenic Thinking*. Jossey-Bass Inc Publishers; San Francisco, CA: 1979.
- Kawasaki Y, Maeda Y, Urata K, Higashima M, Yamaguchi N, Suzuki M, Takashima T, Ide Y. A quantitative magnetic resonance imaging study of patients with schizophrenia. *European Archives of Psychiatric Clinical Neuroscience* 1993;242:268–272.
- Kelsoe JR, Cadet JL, Pickar D, Weinberger DR. Quantitative neuroanatomy in schizophrenia. A controlled magnetic resonance imaging study. *Archives of General Psychiatry* 1988;45:533–541. [PubMed: 3377640]
- Kirkpatrick B, Buchanan RW, McKenney PD, Alphas LD, Carpenter WT Jr. The Schedule for the Deficit Syndrome: an instrument for research in schizophrenia. *Psychiatry Research* 1989;30:119–123. [PubMed: 2616682]
- Lawrie SM, Whalley H, Kestelman JN, Abukmeil SS, Byrne M, Hodges A, Rimmington JE, Best JJ, Owens DG, Johnstone EC. Magnetic resonance imaging of brain in people at high risk of developing schizophrenia (see comments). *Lancet* 1999;353:30–33. [PubMed: 10023948]
- Marsh L, Harris D, Lim KO, Hoff AL, Minn K, Csernansky JG, DeMent S, Faustman WO, Sullivan EV, Pfefferbaum A. Structural magnetic resonance imaging abnormalities in men with severe chronic schizophrenia and an early age at clinical onset. *Archives of General Psychiatry* 1997;54:1104–1112. [PubMed: 9400346]
- McCarley RW, Niznikiewicz MA, Salisbury DF, Nestor PG, O'Donnell BF, Hirayasu Y, Grunze H, Greene RW, Shenton ME. Cognitive dysfunction in schizophrenia: unifying basic research and clinical aspects. *European Archives of Psychiatry & Clinical Neuroscience* 1999;249(Suppl 4):69–82. [PubMed: 10654112]
- Mesulam MM. Schizophrenia and the brain (editorial; comment). *New England Journal of Medicine* 1990;322:842–845. [PubMed: 2308617]
- Mesulam MM. A cortical network for directed attention and unilateral neglect. *Annals of Neurology* 1981;10:309–325. [PubMed: 7032417]
- Nasrallah HA, Schwarzkopf SB, Olson SC, Coffman JA. Gender differences in schizophrenia on MRI brain scans. *Schizophrenia Bulletin* 1990;16:205–210. [PubMed: 2374881]
- Nopoulos P, Torres I, Flaum M, Andreasen NC, Ehrhardt JC, Yuh WTC. Brain morphology in first-episode schizophrenia. *American Journal of Psychiatry* 1995;152:1721–1723. [PubMed: 8526236]
- Ohnuma T, Kimura M, Takahashi T, Iwamoto N, Arai H. A magnetic resonance imaging study in first-episode disorganized-type patients with schizophrenia. *Psychiatry Clinical Neuroscience* 1997;51:9–15.
- Pandya DN, Yeterian EH. Prefrontal cortex in relation to other cortical areas in rhesus monkey: architecture and connections. *Progress in Brain Research* 1990;85:63–94. [PubMed: 2094916]
- Paus T. Location and function of the human frontal eye-field: a selective review. *Neuropsychologia* 1995;34:475–483. [PubMed: 8736560]
- Petit L, Tzourio N, Orssaud C, Pietrzyk U, Berthoz A, Mazoyer B. Functional neuroanatomy of the human visual fixation system. *European Journal of Neuroscience* 1995;7:169–174. [PubMed: 7711932]

- Raine A, Lencz T, Reynolds GP, Harrison G, Sheard C, Medley I, Reynolds LM, Cooper JE. An evaluation of structural and functional prefrontal deficits in schizophrenia: MRI and neuropsychological measures. *Psychiatry Research* 1992;45:123–137. [PubMed: 1362615]
- Rossi A, Stratta P, D'Albenzio L, Tartaro A, Schiavza G, DiMichele V, Bolino F, Casacchia M. Reduced temporal lobe areas in schizophrenia: preliminary evidences from a controlled multiplanar magnetic resonance imaging study. *Biological Psychiatry* 1990;27:61–68. [PubMed: 2297553]
- Rossi A, Stratta P, Gallucci M, Passariello R, Casacchia M. Standardized magnetic resonance image intensity study in schizophrenia. *Psychiatry Research* 1988;25:223–231. [PubMed: 3174904]
- Sanfilippo M, Lafargue T, Rusinek H, Arena L, Loneragan C, Lautin A, Feiner D, Rotrosen J, Wolkin A. Volumetric measure of the frontal and temporal lobe regions in schizophrenia: relationship to negative symptoms. *Archives of General Psychiatry* 2000;57:471–480. [PubMed: 10807487]
- Schlaepfer TE, Harris GJ, Tien AY, Peng LW, Federman EB, Chase GA, Barta PE, Pearlson GD. Decreased regional cortical gray matter volume in schizophrenia. *American Journal of Psychiatry* 1994;151:842–848. [PubMed: 8184992]
- Selemon LD, Rajkowska G, Goldman-Rakic PS. Abnormally high neuronal density in the schizophrenic cortex. A morphometric analysis of prefrontal area 9 and occipital area 17. *Archives of General Psychiatry* 1995;52:805–818. discussion 819–820. [PubMed: 7575100]
- Shenton ME, Kikinis R, Jolesz FA, Pollak SA, LeMay M, Wible CG, Hokama H, Martin J, Metcalf D, Coleman M. Abnormalities of the left temporal lobe and thought disorder in schizophrenia. A quantitative magnetic resonance imaging study. *New England Journal of Medicine* 1992;327:604–612. [PubMed: 1640954]
- Shenton, ME.; Wible, CG.; McCarley, RW. A review of magnetic resonance imaging studies of brain abnormalities in schizophrenia. In: Krishnan, K.; Doraiswamy, P., editors. *Brain Imaging in Clinical Psychiatry*. Marcel Dekker, Inc; New York: 1997.
- Shenton ME, Dickey CC, Frumin M, McCarley RW. A review of MRI findings in schizophrenia. *Schizophrenia Research* 2001;49:1–52. [PubMed: 11343862]
- Smith RC, Baumgartner R, Calderon M. Magnetic resonance imaging studies of the brains of schizophrenic patients. *Psychiatry Research* 1987;20:33–46. [PubMed: 3562689]
- Spitzer, RL.; Endicott, J. Biometrics Research Division. New York State Psychiatric Institute; New York: 1978. Schedule for Affective Disorders and Schizophrenia — Lifetime Version.
- Staal WG, Hulshoff Pol HE, Schnack HG, Hoogendoorn ML, Jellema K, Kahn RS. Structural brain abnormalities in patients with schizophrenia and their healthy siblings. *American Journal of Psychiatry* 2000;157:416–421. [PubMed: 10698818]
- Stratta P, Rossi A, Gallucci M, Amicarelli I, Passariello R, Casacchia M. Hemispheric asymmetries and schizophrenia: a preliminary magnetic resonance imaging study. *Biological Psychiatry* 1989;25:275–284. [PubMed: 2914152]
- Suddath RL, Casanova MF, Goldberg TE, Daniel DG, Kelsoe JR, Weinberger DR. Temporal lobe pathology in schizophrenia: a quantitative magnetic resonance imaging study. *American Journal of Psychiatry* 1989;146:464–472. [PubMed: 2929746]
- Sullivan EV, Mathalon DA, Lim KO, Marsh L, Pfefferbaum A. Patterns of regional cortical dysmorphology distinguishing schizophrenia and chronic alcoholism. *Biological Psychiatry* 1998;43:118–131. [PubMed: 9474444]
- Szeszko PR, Bilder RM, Lencz T, Pollack S, Alvir JM, Ashtari M, Wu H, Lieberman JA. Investigation of frontal lobe subregions in first-episode schizophrenia. *Psychiatry Research: Neuroimaging* 1999;90:1–15.
- Turetsky BI, Cowell PE, Gur RC, Grossman RI, Shtasel DL, Gur RE. Frontal and temporal lobe brain volumes in schizophrenia. *Archives of General Psychiatry* 1995;52:1061–1070. [PubMed: 7492258]
- Uematsu M, Kaiya H. Midsagittal cortical pathomorphology of schizophrenia: a magnetic resonance imaging study. *Psychiatry Research* 1989;30:11–20. [PubMed: 2574474]
- Vita A, Dieci M, Giobbio GM, Caputo A, Ghiringhelli L, Comazzi M, Garbarini M, Mendini AP, Morganti C, Tenconi F. Language and thought disorder in schizophrenia: brain morphological correlates. *Schizophrenia Research* 1995;15:243–251. [PubMed: 7632621]
- Wells WM, Grimson W, Kikinis R. Adaptive segmentation of MRI data. *IEEE Transactions on Medical Imaging* 1996;15:429–443. [PubMed: 18215925]

- Wechsler, D. Wechsler Adult Intelligence Scale — Revised. Harcourt Brace Jovanovich Inc; New York: 1981.
- Wible CG, Shenton ME, Hokama H, Kikinis R, Jolesz FA, Metcalf D, McCarley RW. Prefrontal cortex and schizophrenia. A quantitative magnetic resonance imaging study. *Archives of General Psychiatry* 1995;52:279–288. [PubMed: 7702444]
- Wible, CG.; Shenton, ME.; McCarley, RW. Functional neuroanatomy of the limbic system and planum temporale. In: Krishnan, RR.; Doraiswamy, PM., editors. *Brain Imaging in Clinical Psychiatry*. Marcel Dekker; 1997. p. 63-101.
- Woods BT, Yurgelun-Todd D, Goldstein JM, Seidman LJ, Tsuang M. MRI brain abnormalities in chronic schizophrenia: One process or more? *Biological Psychiatry* 1996;40:585–596. [PubMed: 8886291]
- Woodruff PW, Wright IC, Shuriquie N, Russouw H, Rushe T, Howard RJ, Graves M, Bullmore ET, Murray RM. Structural brain abnormalities in male schizophrenics reflect frontotemporal dissociation. *Psychosomatic Medicine* 1997;27:1257–1266.
- Zipursky RB, Lim KO, Sullivan EV, Brown BW, Pfefferbaum A. Widespread cerebral gray matter volume deficits in schizophrenia. *Archives of General Psychiatry* 1992;49:195–205. [PubMed: 1567274]
- Zipursky RB, Marsh L, Lim KO, DeMent S, Shear PK, Sullivan EV, Murphy GM, Csernansky JG, Pfefferbaum A. Volumetric MRI assessment of temporal lobe structures in schizophrenia. *Biological Psychiatry* 1994;35:501–516. [PubMed: 8038294]

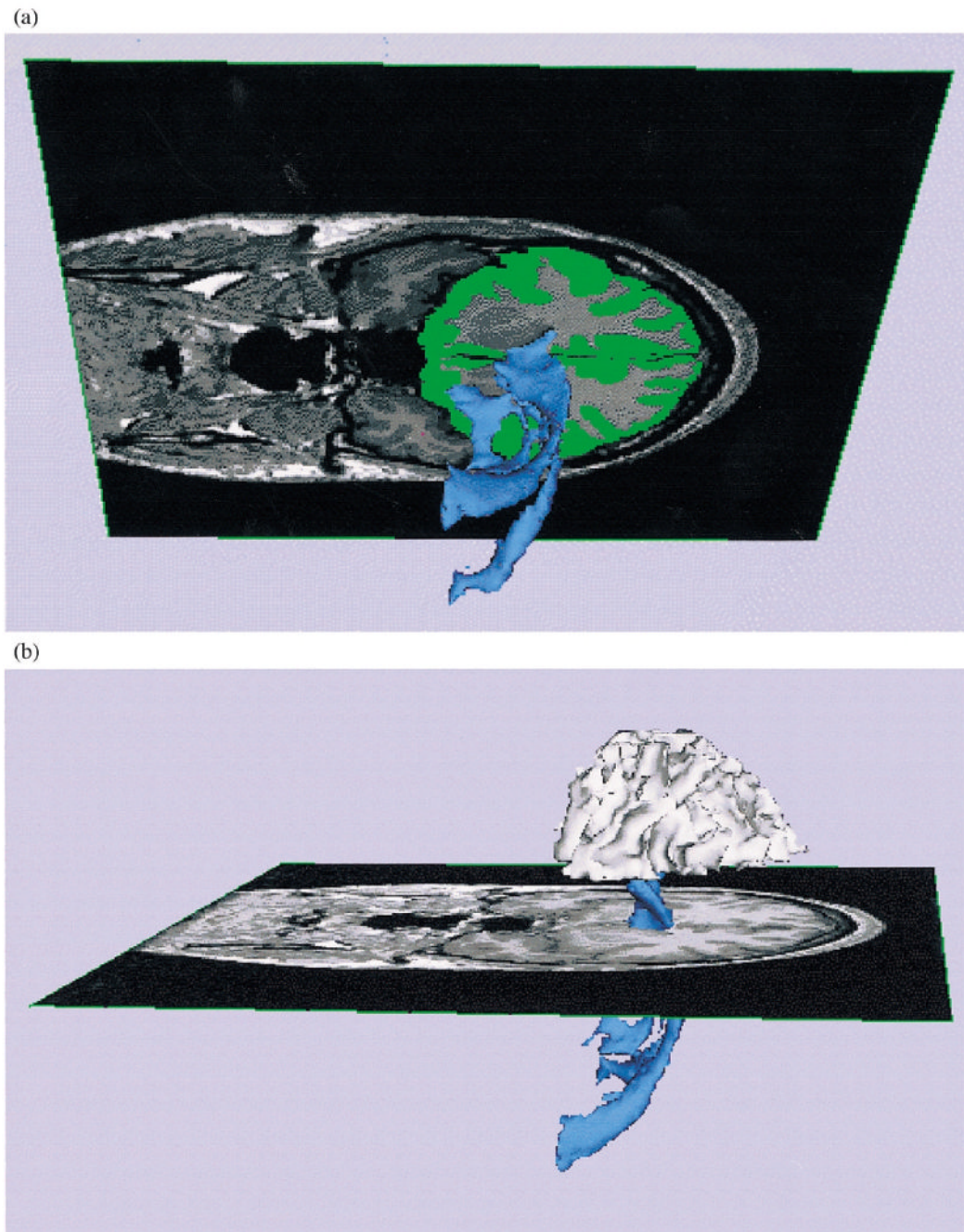


Fig. 1.

The most posterior slice in which prefrontal gray matter was measured in relationship to the ventricles and the white matter. Panel 1A: left lateral view of the most posterior slice in which gray matter was measured, shown in relationship to the ventricles with segmented prefrontal gray matter shown in green overlay on the MRI slice. Panel 1B: left lateral view of a three-dimensional reconstruction of the prefrontal white matter in relationship to the ventricles and to the slice shown in Panels A and B.

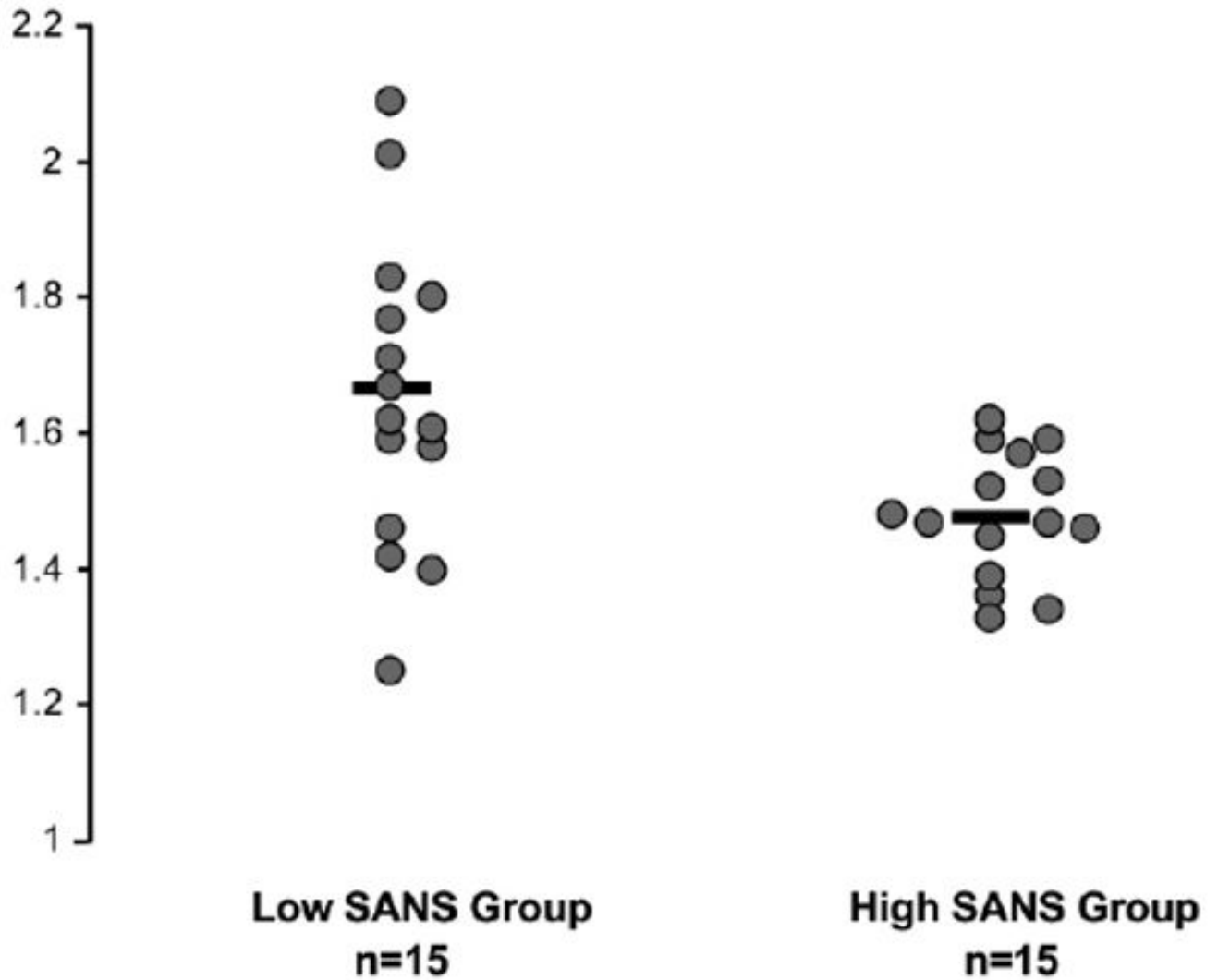


Fig. 2. Relative volumes of average left and right (combined) prefrontal white matter for schizophrenic subjects with high and low SANS scores. The subject data shown are from a combination of the current study and our previous study of prefrontal volume in schizophrenia. The low and high SANS groups were determined by ranking all schizophrenic subjects and doing a median split to obtain two groups.

Table 1

A summary table of MRI studies of prefrontal cortex in schizophrenia

Reference	Slice thickness (number)	CN, SZ
<i>Studies showing differences in frontal lobe area or volume between schizophrenic and control subjects</i>		
Andreasen et al., 1986	10 mm	49, 38
DeMyer et al., 1988	10 mm (2 slices)	24, 24
Rossi et al., 1988	10 mm, 5 mm	12, 12
Stratta et al., 1989	10 mm (8 axial), 5 mm (1 midsag.)	20, 20
Jernigan et al., 1991	5 mm, 2.5 gap	24, 42
Breier et al., 1992	3 mm	29, 44
Raine et al., 1992	10 mm (12 coronal) (1 midsag., 1 axial)	19 + 18, 17
Zipursky et al., 1992	5 mm, 2.5 gap (7 slices)	20, 22
Buchanan et al., 1993	3 mm	30, 41
Harvey et al., 1993	5 mm (20 slices)	34, 48
Andreasen et al., 1994	1.5 mm	90, 52
Bilder et al., 1994	3.1 mm	51, 70
Schlaepfer et al., 1994	5 mm	60 + 27, 46
Zipursky et al., 1994	3 mm (22 slices)	20, 22
Nopoulos et al., 1995	1.5 mm	24, 24
Woods et al., 1996	5 mm	19, 19
Marsh et al., 1997	3 mm (22 slices)	52, 56
Woodruff et al., 1997	5 mm	43, 42
Ohnuma et al., 1997	4 mm	10, 10
Gur et al., 1998	5 mm	17, 40
Buchanan et al., 1998	1.5 mm	24, 18
Sullivan et al., 1998	5 mm (2.5 mm gap)	73, 71 + 62
Goldstein et al., 1999	3.1 mm	26, 29
Staal et al., 2000	1.6 mm	32 + 16, 16
Szeszko et al., 1999	3.1 mm	26, 19
Sanfilipo et al., 2000	2.8 mm	29, 53
Gur et al., 2000	1 mm	81, 70
<i>Studies showing no differences in frontal lobes</i>		
Smith et al., 1987	8 mm, 12 mm	21, 29
Kelsoe et al., 1988	10 mm (1 midsag)	14, 24
Uematsu and Kaiya, 1989	10 mm (8 slices)	17, 49
Suddath et al., 1989	10 mm (12 slices)	17, 17
Rossi et al., 1990	8 mm (7–8 slices)	13, 17
Nasrallah et al., 1990	3 mm, 5 mm	35, 56
Andreasen et al., 1990	10 mm	47, 54
Blackwood et al., 1991	12 mm (10 slices)	33, 28

Reference	Slice thickness (number)	CN, SZ
DeLisi et al., 1991	5 mm, 2 mm gap	20, 45
Bornstein et al., 1992	5 mm, 5 mm gap	52, 72
Kawasaki et al., 1993	5 mm	10, 20
Egan et al., 1994	10 mm (12 slices)	16, 16
Vita et al., 1995	5 mm, 2 mm gap	15, 19
Turetsky et al., 1995	5 mm	77, 71
Vita et al., 1995	5 mm (2 mm gap)	15, 19
Corey-Bloom et al., 1995	5 mm, 2.5 mm gap	28, 30
Wible et al., 1995	1.5 mm (36 slices)	15, 14
Baare et al., 1999	1.2 mm	14, 14
Lawrie et al., 1999	1.8 mm	30, 20 + 100 high risk

The table shows the reference, the resolution of the MRI methods in terms of number of slices used to assess the prefrontal cortex, and the number of control (CN) and schizophrenic (SZ) subjects.

Table 2

Subject characteristics (mean and standard deviation) and probability level of a one-way ANOVA test for the variables when appropriate

	Schizophrenic	Control	Significance (one-way ANOVA)
Number of subjects	17	17	
Age at test (years)	44	40	$F = 0.004$, d.f. = 1,31, $P = 0.950$
Handedness	0.80	0.78	$F = 0.006$, d.f. = 1,28, $P = 0.939$
Parental SES	3.18	2.35	$F = 5.07$, d.f. = 1,32, $P = 0.031^*$
WAIS-R information	11.75	10.53	$F = 2.07$, d.f. = 1,31, $P = 0.161$
Duration (years since onset)	20		
Total SANS score (S.D.)	11 (4)		
Range of SANS scores	4–18		
Total SAPS score (S.D.)	8 (4)		
Range of SAPS score	1–15		

* Signifies that the probability level was significant.

Table 3

Means and standard deviations of prefrontal left and right, gray and white volumes for schizophrenic and control subjects

	Absolute volume	Relative volume	Number of slices
<i>Left frontal gray matter</i>			
Schizophrenia	68.9 (8.1)	4.5 (0.44)	36
Control	73.8 (12.0)	4.7 (0.65)	37
<i>Left frontal white matter</i>			
Schizophrenia	22.6 (2.2)	1.5 (0.12)	24
Control	24.2 (4.2)	1.5 (0.18)	24
<i>Right frontal gray matter</i>			
Schizophrenia	68.1 (8.6)	4.5 (0.51)	35
Control	72.7 (12.2)	4.6 (0.68)	35
<i>Right frontal white matter</i>			
Schizophrenia	22.2 (2.0)	1.5 (0.15)	24
Control	26.0 (4.5)	1.7 (0.24)	24

Also shown is the mean number of MRI slices used to assess each measure.