

---

# Prehospital Ultrasound by Paramedics: Results of Field Trial

William Heegaard, MD, MPH, David Hildebrandt, NREMT-P, RN, David Spear, MD, Kevin Chason, DO, Bret Nelson, MD, RDMS, and Jeffrey Ho, MD

---

## Abstract

**Objectives:** The objective was to determine if 9-1-1 paramedics trained in ultrasound (US) could adequately perform and interpret the Focused Assessment Sonography in Trauma (FAST) and the abdominal aortic (AA) exams in the prehospital care environment.

**Methods:** Paramedics at two emergency medical services (EMS) agencies received a 6-hour training program in US with ongoing refresher education. Paramedics collected US in the field using a prospective convenience methodology. All US were performed in the ambulance without scene delay. US exams were reviewed in a blinded fashion by an emergency sonographer physician overreader (PO).

**Results:** A total of 104 patients had an US performed between January 1, 2008, and January 1, 2009. Twenty AA exams were performed and all were interpreted as negative by the paramedics and the PO. Paramedics were unable to obtain adequate images in 7.7% (8/104) of the patients. Eighty-four patients had the FAST exam performed. Six exams (6/84, 7.1%) were read as positive for free intraperitoneal/pericardial fluid by both the paramedics and the PO. FAST and AA US exam interpretation by the paramedics had a 100% proportion of agreement with the PO.

**Conclusions:** This pilot study shows that with close supervision, paramedics can adequately obtain and interpret prehospital FAST and AA US images under protocol. These results support a growing body of literature that indicates US may be feasible and useful in the prehospital setting.

ACADEMIC EMERGENCY MEDICINE 2010; 17:624-630 © 2010 by the Society for Academic Emergency Medicine

**Keywords:** prehospital ultrasound, paramedic ultrasound, trauma care, and ultrasound

---

**P**oint-of-care (POC) ultrasound (US) has significantly increased in use over the past 20 years.<sup>1-3</sup> Multiple studies have shown the efficacy and

From the Department of Emergency Medicine, Hennepin County Medical Center (WH, DH, JH), Minneapolis, MN; the Department of Emergency Medicine, Parkland Hospital (DS), Dallas, TX; and the Department of Emergency Medicine, Mount Sinai School of Medicine (KC, BN), New York, NY.

Received November 14, 2009; revision received January 14, 2010; accepted January 23, 2010.

Preliminary data from this study were presented at the 2009 National Association of EMS Physicians annual meeting in Jacksonville, FL; and the 2009 World Interactive Network Focused on Critical Ultrasound meeting in Sydney, Australia.

SonoSite Corporation provided all MicroMaxx ultrasound machines free of charge. SonoSite Corporation provided an unrestricted grant for this study. Other sources of financial support came from the Hennepin County Medical Center Department of Emergency Medicine, the Hennepin County Medical Center Emergency Medical Services, and the Edina Fire Department, Edina, MN.

Address for correspondence and reprints: William Heegaard, MD, MPH; e-mail: william.heegaard@hcmcd.org.

efficiency of POC US. Some studies have demonstrated improved morbidity and mortality outcomes.<sup>3-5</sup> The use of POC US in the prehospital setting is a relatively new application of this medical technology. Small studies have shown utility in military, ground, and helicopter emergency medical services (EMS) in both Europe and the United States.<sup>5-17</sup> These studies have largely concentrated on US use for trauma evaluation and involve the application of the Focused Assessment Sonography for Trauma (FAST) or an extended FAST examination. Prehospital US use has been more fully described in Germany, France, and Italy than in the United States.<sup>18,19</sup> The largest prehospital US study to date was performed by Walcher and colleagues in Germany.<sup>5</sup> The goal of their study was to examine if prehospital US could improve final destination decisions and time to definitive diagnosis with a high degree of accuracy. However, despite this study being well designed, their study used physicians performing prehospital US exams at the EMS scene and did not involve paramedics performing US in the back of a moving ambulance.

In this article, we report the results of a pilot study examining paramedic-performed prehospital US, carried out in the ambulances, in two EMS services. This

study did not address emergency department use of prehospital findings or clinical outcomes. Our objective was to determine if 9-1-1 paramedics trained in emergency US principles could perform the FAST and the abdominal aortic (AA) exams under real field conditions. We discuss the role of prehospital US in assisting with prehospital clinical decision-making.

## METHODS

### Study Design

This was a prospective, observational study on the use of US in the prehospital setting. This study was approved by the Human Subjects Research Committee of Hennepin County Medical Center (HCMC). Waiver of informed consent was requested and approved for this study.

### Study Setting and Population

The field study was performed at two locations: Hennepin County EMS in Minneapolis, Minnesota, with an annual 9-1-1 run volume of 48,000, and Edina Fire and Rescue in Edina, Minnesota, with an annual 9-1-1 run volume of 4,000. Both services operate full-time advanced life support paramedic ambulance services in their respective communities. Forty paramedics volunteered to be trained.

### Study Protocol

Paramedics were trained through lecture, written pre/post examinations, and objective structured clinical examination (OSCE) format. Many of the FAST and AA examination questions were adapted from a previous study on US knowledge retention.<sup>20</sup> The 6-hour training program and results of written test scores and OSCE examinations were previously presented<sup>21</sup> (see Table 1 for training format).

Each participating paramedic received two 1-hour refresher courses given during the 1-year study period. This was done in groups with up to 15 paramedics participating at a time. These refresher courses occurred at approximately 3 and 8 months into the study period. In addition, all participating paramedics could contact the study physicians for specific US assistance or training at any time during the study. Furthermore, we had online training videos of the FAST and AA US exams that the paramedics could review at any time.

Five SonoSite (Bothell, WA) MicroMaxx US machines (three at HCMC EMS and two at Edina Fire) with P17

phased probes were used in the study. Study paramedics were encouraged to use the US machines to obtain FAST or AA US examination of any patient presenting after significant trauma or with abdominal pain, respectively. Specific inclusion and exclusion protocols were developed for enrollment of prehospital US patients. Figures 1A and 1B illustrate the FAST and AA exam protocols, respectively. For AA US exams, the paramedic needed to obtain at least one 6-second video clip (either cross-sectional short axis or longitudinal long axis) and one static view with measurements to be considered adequate. The abdominal aorta 6-second clip had to include a study with the infrarenal aorta present. For FAST exams, 6-second video clips of each window (Morison's, perisplenic, pelvic, and cardiac subcostal or parasternal long axis) needed to be obtained to be considered adequate. Regarding the FAST exam, we required that the paramedics obtain a 6-second clip that showed the diaphragm, the lower hepatic tip, and Morison's pouch in the right upper quadrant and the entire perisplenic view including tip and diaphragm in the left upper quadrant.

If any of the four views on the FAST or two views on the AA US were deemed inadequate, the whole exam was considered inadequate. Inadequate views were not excluded from our analysis. Times for FAST US exams were calculated from the US machines. For each US exam, start and stop times were time stamped automatically.

All US exams were performed either in the ambulance at the scene if no delay of care could be ensured or while en route to the hospital. Paramedics were directed not to delay standard treatment or transport to accomplish the US exam. This was a condition of our IRB approval. All US views were recorded using 6-second video clips. Measurement of the aorta was obtained from a single static view. These studies were then overread by one independent, blinded, emergency physician overreader (PO). The PO was a US and fellowship director with over 15 years of experience in US at a major teaching hospital. Positive US scans were confirmed by operative or computed tomography (CT) findings. The PO is not an author of this manuscript.

### Data Analysis

All data were entered into an Excel spreadsheet (Microsoft Corp., Redmond, WA). Data were then exported to STATA 10 (StataCorp., College Station, TX) for analysis. Data were described using descriptive statistics. A decision was made to report the results of the paramedic's interpretation of the US exam in relation to the PO's interpretation as a proportion of agreement rather than specificity and sensitivity.

## RESULTS

At Hennepin County EMS, 25 of 116 paramedics were trained in US, and 15 completed the full study. At Edina Fire, 15 of 32 paramedics were trained, and 10 completed the study. Paramedic study attrition rates for both sites are summarized in Figure 2. The mean number of US studies per paramedic was 4.6, with a median of 3.

Table 1  
Training Format of Paramedic US Course for Current Study

Physics and image orientation	60 minutes
FAST exam	40 minutes
Case review of each quadrant	20 minutes
Abdominal aorta	40 minutes
Case reviews of AAA	20 minutes
Practical training	180 minutes
Student-to-instructor ratio	4:1

AAA = abdominal aortic aneurysm; FAST = Focused Assessment Sonography in Trauma; US = ultrasound.

**A****Prehospital FAST Protocol**

1. When a patient presents with torso or abdominal trauma, the paramedic shall perform a prehospital FAST exam in the following order:
  - Morison's/Perihepatic View
  - Pelvic View
  - Perisplenic View
  - Cardiac View
2. If the patient presents with penetrating trauma to the chest or near the chest or the patient is in PEA or a near arrest state, the paramedic shall first capture the cardiac view and then proceed to the remaining views in the order listed above.
3. To capture the images paramedics shall perform patient scans in the back of the ambulance at the scene with no delay in care, or during ambulance transport.
4. All paramedics shall record 6-second clips of all views. All FAST views must be completed. If full imaging was not possible, record as many views as possible.
5. The paramedic shall record the amount of time it takes to complete the scan. The time of the complete exam in seconds shall be recorded on the data sheet.
6. If and when a positive (free abdominal fluid identified or pericardial fluid) view is identified, paramedics shall note the time of the first positive view and record it on the data sheet. This will simulate the time that the medics would notify Medical Control of a positive exam.
7. Upon arrival at the hospital, the prehospital data sheet will be completed in its entirety.

**B****Abdominal Aorta Ultrasound Protocol****Indications:**

Patient who is age 50 years or older and presents with:

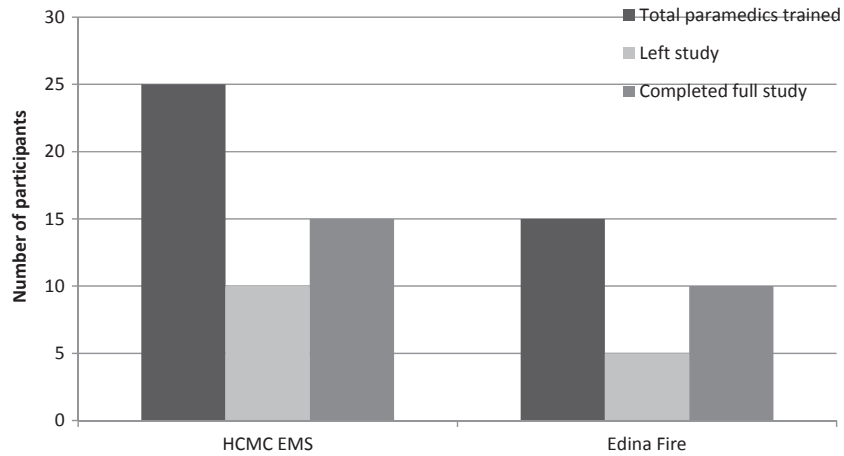
1. Severe abdominal pain, especially pain that radiates to the groin/back/flank and/or
2. Has hypotension (syncope, near syncope, appears ill) and/or
3. A high clinical suspicion for AAA.

The paramedic shall perform an abdominal aortic ultrasound to assess for AAA.

**Procedure:**

1. Paramedic shall locate the proximal aortic views. Both the transverse and longitudinal views should be attempted to be obtained and measured. Obtain video clips.
2. Paramedic shall then locate the distal aorta. The distal aorta is located 2 cm above the umbilicus. Keep in mind that the vast majority of AAA's are located in the distal aorta.
3. If the patient is critical and time does not allow, distal views should be obtained first. In all cases, unless time does not allow and/or the patient is too critical, the size of the aorta should be measured in proximal or distal view and a still image of this measurement captured using a transverse or longitudinal view. To capture the images paramedics shall perform patient scans in the back of the ambulance prior to leaving without delay of transport, or have the scan performed en route.
4. Paramedics shall record 6 second clips of all views with a minimum of one video capture of an aortic view and one measured static view.
5. Time it takes to complete aortic US exam will be recorded in seconds on each case.
6. If and when a positive view is identified, an aorta that measures 3 cm or more, paramedics shall note the time of the first positive view and record it on the data sheet. This will simulate the time that the medics would notify Medical Control of a positive exam.
7. Upon arrival at the hospital, the prehospital data sheet will be completed in its entirety.

**Figure 1.** (A) Prehospital FAST paramedic US protocol. (B) Prehospital AA paramedic US Protocol. AAA = abdominal aortic aneurysm; PEA =; pFAST = Focused Assessment Sonography in Trauma; PEA = pulseless electrical activity; US = ultrasound.



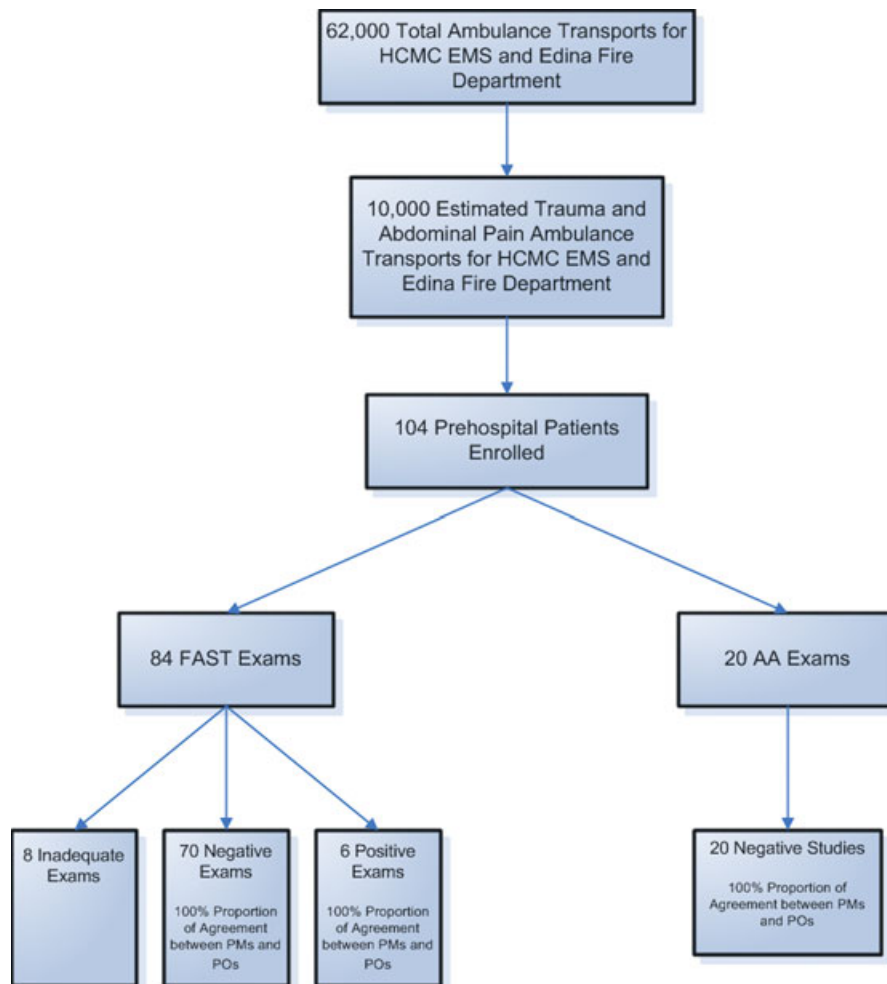
**Figure 2.** Paramedic attrition rates by study location.

A total of 104 patients had a prehospital US performed from January 1, 2008, to January 1, 2009 (Figure 3). Paramedics were unable to obtain adequate images in 7.7% (8/104) of the studies, all of which were FAST exams.

Twenty AA exams were performed, and all were interpreted as negative by the paramedics and the

blinded PO (Figure 3). All AA US performed by the paramedics were deemed adequate by the PO.

Eighty-four patients had prehospital FAST exams. Of the 76 adequate FAST exams, the mean time to perform the fast exam was 156 seconds (2.6 minutes) with the median time being 138 seconds (range = 76 to 357



**Figure 3.** Flow diagram of patients included in US study. AA = abdominal aortic; FAST = Focused Assessment Sonography in Trauma; HCMC = Hennepin County Medical Center; PM = paramedic; PO = physician overreader; US = ultrasound.

seconds). Six prehospital FAST exams (6/84, 7.1%) were read as positive for free intraperitoneal or pericardial fluid by both the paramedic and the PO. In one case, a positive US was identified by both the paramedic and the PO as not clinically significant. The positive finding was seen on the bladder view only. Among adequate prehospital US exams, FAST and AA exam interpretation by the paramedics had a 100% proportion of agreement with the PO's interpretation.

Positive prehospital USs were confirmed by positive operative or CT findings. One case, which was mentioned earlier, had a positive US read by both the paramedics and the PO; however, the patient was eventually discharged from the emergency department (ED). The attending emergency physician (EP) felt that the finding was physiologic. The patient was observed in the ED for over 4 hours with serial examinations. No CT scan was performed, and the patient was discharged from the ED. Table 2 summarizes the clinical course and findings of the patients with positive prehospital US exams.

## DISCUSSION

The largest prehospital US study to date was performed by Walcher and colleagues in Germany.<sup>5</sup> A total of 202 patients were entered into the study. The prehospital FAST exam performed by EPs and paramedics in the field had 93% sensitivity and 99% specificity for detecting intraperitoneal blood and was performed in less than 3 minutes. Significant improvement in time to diagnosis of potential life threat and time to operating room intervention was found in patients with hemoperitoneum. Prehospital US findings resulted in a 20%

change in final hospital destination by prehospital personnel.<sup>5</sup>

The data from our study show that prehospital US can be successfully introduced into a U.S. EMS system with quality and accuracy if trained paramedics are carefully supervised by US-trained EPs. We also show that accurate USs can be performed while patients are being transported, thus adding no additional time to their prehospital care.

This pilot study had a very different intent than Walcher et al.'s German prehospital study.<sup>5</sup> Our hypothesis was that paramedic level personnel could perform US with high quality and accuracy while working in the back of a moving ambulance. Because Germany uses physicians as their primary prehospital providers, examining outcomes such as effect on time to diagnosis and hospital diversion is appropriate in that EMS system. However, given that the EMS system in North America has been built on using nonphysicians as the prehospital care provider, we felt a pilot study looking at paramedic accuracy was an important contribution to the American prehospital US literature. Furthermore, it was a condition of our IRB waiver of consent approval that no direct clinical decisions would be made in the field from this pilot study of prehospital US imaging.

To our knowledge, no studies in the United States have examined US utility in ground EMS systems using paramedics. No prehospital study has reported on 6-second video recordings of each component of the FAST exam obtained in the field for overview by a PO. Previous studies have always relied on single, nonvideo images for overreading. We believe that it is crucial to

Table 2  
Findings for Positive US Exams

Case	Age, yr	Injury	Paramedic US Finding	CT/OR Finding	Outcome
1	22	High-speed MVC	Grossly positive, positive RUQ and Morison's view	CT of abdomen shows renal artery disruption, splenic laceration with free intraperitoneal fluid	Renal artery stent, nonoperative management of splenic laceration: survived
2	29	Direct blunt trauma	Grossly positive, pelvis, spleen and positive Morison's view	Splenic lacerations with active extravasation with free intraperitoneal fluid	Grade 3/4 splenic laceration, eventually received splenectomy: survived
3	33	Moderate-speed MVC	Positive pelvis view	Patient had serial exams and multiple x-rays performed in ED. Watched for over 5 hours. Patient stable and discharged from ED. No CT performed.	Discharged from ED: survived
4	20	GSW to abdomen	Grossly positive, RUQ/Morison's and pelvis view	Directly to OR for right nephrectomy and liver laceration repair	Right nephrectomy: survived
5	41	Stab wound to chest	Grossly positive, subcostal view for pericardial effusion	Directly to the OR for RV repair. Had pericardial tamponade diagnosed by paramedics	Thoracotomy: survived
6	74	Fall and abdominal pain	Positive subcostal view for pericardial effusion	CT showed pericardial effusion. Patient had a history of cancer and found to have malignant pericardial effusion	Admitted for inpatient care. Pericardiocentesis performed: died of cancer

CT = computed tomography; GSW = gunshot wound; MVC = motor vehicle crash; OR = operating room; RUQ = right upper quadrant; RV = right ventricle; US = ultrasound.

have video clips included so that adequate image review and quality assurance are possible.

In this study, paramedics were unable to obtain adequate images in 7.7% of the patients. This is similar to the study by Walcher et al. where US was performed by prehospital physicians. Walcher et al.<sup>5</sup> reported a 7% inadequate image collection. Sixty-two percent of the inadequate examinations noted in our study had at least one adequate view of the Morison's pouch, perisplenic, or pelvic view. However, if one US view was deemed inadequate by our PO, the entire exam was considered an inadequate study.

The durability of portable US in the prehospital setting has been evaluated by several authors.<sup>5-7,13</sup> Most portable US machines are lightweight, have a laptop configuration, and produce excellent image quality. A crucial element for prehospital portable US is combining light weight and excellent image quality with a more rugged external and probe casing. Multiple portable US manufactures appear to have achieved these goals. Recently one manufacturer has created the first dedicated prehospital US machine (NanoMaxx by SonoSite Corporation).

The SonoSite MicroMaxx performed well in this study in a moving ambulance under real clinical settings. The P-17 probe used in this study is a versatile US probe with a broad frequency range. Using an all purpose US probe was ideal in this study for the variable and dynamic prehospital conditions that were encountered.

Prehospital US has been successfully implemented and is being consistently utilized throughout much of Europe, specifically in Germany, France, Italy, and some Scandinavian countries.<sup>18</sup> Prehospital US in the United States is still in the early development stage. Numerous studies have shown that US can be accomplished in the air medical setting despite tight quarters with equipment constraints and may have clinical utility.<sup>5-8,13,15,22</sup>

Future prehospital studies should consider video clip recordings to clearly demonstrate the quality and accuracy of obtained scans. Single hard copies are inadequate to perform appropriate quality assurance. Advances in US machine technology have now made it easy to collect compressed video recording.

The opportunity to improve patient care outcomes in the areas of trauma care, critical medical conditions, and cardiac resuscitation will likely accelerate the use of prehospital US in the future. Similar to many large metropolitan areas, our metro area has specialized hospitals with expertise in trauma care, cardiac care, and 24-hour invasive radiologic interventions for acute life-threatening diseases such as acute symptomatic AA aneurysms. Prehospital US has the potential to improve EMS delivery of patients to the right hospital in the right timeframe for acute emergencies.

The horizon for prehospital US is enlarging. How, where, and to what extent prehospital US is developed in America is still an open question. Our study did not attempt to answer these questions, but rather acts as a hypothesis-generating study to promote further research in this important area. Hypotheses that come directly from our study include: 1) What is the most

efficacious and cost effective method to teach paramedics US? 2) What exam types should we train paramedics to perform? and 3) What clinical impact can prehospital US have for improving patient care?

## LIMITATIONS

---

This study was not randomized and consisted of a convenience sample. This inherently introduces selection bias. The goal of this study was not to determine if prehospital US could affect clinical outcomes, but rather determine if paramedics from busy EMS systems could perform US in the back of an ambulance with a high degree of accuracy. Because of the limited number of US machines available at any one time, and our study protocol, we collected 104 US cases. Because the number of patients included in this study was relatively small, we have labeled this report as a pilot study. Larger numbers of positive study subjects using a randomized protocol will be needed to determine if the use of prehospital US in the United States can decrease time to diagnosis and improve patient outcomes.

The paramedics were not blinded to this study. Since the paramedics knew they were being evaluated, they may have been more motivated to enhance their performance of the criteria being studied. Our relatively low percentage of positive scans (7.1%) compared to the report by Walcher et al. of 14% is likely because our protocol excluded patients who the paramedics felt were too unstable, and the performance of the US might interfere with other patient care duties.

Another potential bias of our study was the study selection criteria used for paramedics to participate in the study. Paramedics volunteered to be a part of this training, education, and data-gathering experience using US equipment. Because it was not required and involved additional training and work using new technology, this may have attracted more highly motivated personnel that were interested in and adept at using higher technology devices in their professional practice. It is not known if less-motivated paramedics, or those with lesser ability to adapt to new technology, would demonstrate similar success rates.

Because no standard exists for training paramedics in US, we cannot assume that our training program was adequate. However, we developed our training course by extrapolation of the well-established American College of Emergency Physicians US training guidelines.<sup>1</sup> Further research needs to be performed to validate our suggested paramedic FAST and AA US training template.

## CONCLUSIONS

---

Prehospital ultrasound has the potential to improve patient outcomes by improving time to diagnosis and early delivery of critically ill patients who are amenable to time-dependent lifesaving interventions. It also has the promising ability to assist in making appropriate destination decisions for the patient. Our study shows that paramedics can perform the FAST and abdominal aortic ultrasound exams in the prehospital environment with a high degree of accuracy.

## References

1. American College of Emergency Physicians. Policy Statement: emergency ultrasound guidelines. *Ann Emerg Med.* 2009; 53:550–70.
2. Mayron R, Gaudio FE, Plummer D, Asinger R, El-sperger J. Echocardiography performed by emergency physicians: impact on diagnosis and therapy. *Ann Emerg Med.* 1988; 17:150–4.
3. Melniker LA, Leibner E, McKenney MG, Lopez P, Briggs WM, Mancuso CA. Randomized controlled clinical trial of point-of-care, limited ultrasonography for trauma in the emergency department: the first sonography outcomes assessment program trial. *Ann Emerg Med.* 2006; 48:227–35.
4. Plummer D, Brunette D, Asinger R, Ruiz E. Emergency department echocardiography improves outcome in penetrating cardiac injury. *Ann Emerg Med.* 1992; 21:709–12.
5. Walcher F, Weinlich M, Conrad G, et al. Prehospital ultrasound imaging improves management of abdominal trauma. *Br J Surg.* 2006; 93:238–42.
6. Heegaard W, Plummer D, Dries D, et al. Ultrasound for the air medical clinician. *Air Med J.* 2004; 23:20–3.
7. Price DD, Wilson SR, Murphy TG. Trauma ultrasound feasibility during helicopter transport. *Air Med J.* 2000; 19:144–6.
8. Polk JD, Fallon WF Jr, Kovach B, Mancuso C, Stephens M, Malangoni MA. The “Airmedical F.A.S.T.” for trauma patients—the initial report of a novel application for sonography. *Aviat Space Environ Med.* 2001; 72:432–6.
9. Breitzkreutz R, Walcher F, Seeger FH. Focused echocardiographic evaluation in resuscitation management: concept of an advanced life support-conformed algorithm. *Crit Care Med.* 2007; 35(5 Suppl):S150–61.
10. Ward DI. Prehospital point-of-care ultrasound use by the military [abstract]. *Emerg Med Australas.* 2007; 19:282.
11. Lu LH, Choi WM, Wu HR, Liu HC, Chiu WT, Tsai SH. Blunt cardiac rupture with prehospital pulseless electrical activity: a rare successful experience. *J Trauma.* 2005; 59:1489–91.
12. Do JR, McManus J, Harrison B. Use of ultrasonography to avoid an unnecessary procedure in the prehospital combat environment: a case report. *Prehosp Emerg Care.* 2006; 10:502–6.
13. Polk JD, Fallon WF Jr. The use of focused assessment with sonography for trauma (FAST) by a prehospital air medical team in the trauma arrest patient. *Prehosp Emerg Care.* 2000; 4:82–4.
14. Byhahn C, Bingold TM, Zwissler B, Maier M, Walcher F. Prehospital ultrasound detects pericardial tamponade in a pregnant victim of stabbing assault. *Resuscitation.* 2008; 76:146–8.
15. Walcher F, Kortum S, Kirschning T, Weihgold N, Marzi I. Optimized management of polytraumatized patients by prehospital ultrasound [German]. *Unfallchirurg.* 2002; 105:986–94.
16. Lapostolle F, Petrovic T, Lenoir G, et al. Usefulness of hand-held ultrasound devices in out-of-hospital diagnosis performed by emergency physicians. *Am J Emerg Med.* 2006; 24:237–42.
17. Ma OJ, Norvell JG, Subramanian S. Ultrasound applications in mass casualties and extreme environments. *Crit Care Med.* 2007; 35(5 Suppl):S275–9.
18. Walcher F, Petrovic T, Heegaard W, et al. Prehospital ultrasound: perspectives from four countries. In: MA J, Mateer J, Blaivas M, eds. *Emergency Ultrasound.* New York, NY: McGraw Hill, 2008.
19. Nelson BP, Chason K. Use of ultrasound by emergency medical services: a review. *Int J Emerg Med.* 2008; 1:253–9.
20. Noble VE, Nelson BP, Sutingco AN, Marill KA, Cranmer H. Assessment of knowledge retention and the value of proctored ultrasound exams after the introduction of an emergency ultrasound curriculum [abstract]. *BMC Med Educ.* 2007; 7:40.
21. Heegaard W, Hildebrandt D, Ho J, Spear D. Paramedic prehospital ultrasound training evaluation [abstract]. *Acad Emerg Med.* 2008; 15:S46.
22. Plummer D, Heegaard W, Dries D, Reardon R, Pip-pert G, Frascione RJ. Ultrasound in HEMS: its role in differentiating shock states. *Air Med J.* 2003; 22:33–6.