

Circulation

JOURNAL OF THE AMERICAN HEART ASSOCIATION



**Preserved Endothelium-Dependent Vasodilation in Coronary Segments
Previously Treated With Balloon Angioplasty and Intracoronary Irradiation**
Manel Sabaté, I. Patrick Kay, Willem J. van der Giessen, Angel Cequier, Jurgen M. R.
Ligthart, Joan Antoni Gómez-Hospital, Stéphane G. Carlier, Veronique L. M. A.
Coen, Johannes P. A. Marijnissen, Alexander J. Wardeh, Peter C. Levendag and
Patrick W. Serruys

Circulation 1999;100:1623-1629

Circulation is published by the American Heart Association, 7272 Greenville Avenue, Dallas, TX
72514

Copyright © 1999 American Heart Association. All rights reserved. Print ISSN: 0009-7322. Online
ISSN: 1524-4539

The online version of this article, along with updated information and services, is
located on the World Wide Web at:

<http://circ.ahajournals.org/cgi/content/full/100/15/1623>

Subscriptions: Information about subscribing to *Circulation* is online at
<http://circ.ahajournals.org/subscriptions/>

Permissions: Permissions & Rights Desk, Lippincott Williams & Wilkins, 351 West Camden
Street, Baltimore, MD 21202-2436. Phone 410-5280-4050. Fax: 410-528-8550. Email:
journalpermissions@lww.com

Reprints: Information about reprints can be found online at
<http://www.lww.com/static/html/reprints.html>

Preserved Endothelium-Dependent Vasodilation in Coronary Segments Previously Treated With Balloon Angioplasty and Intracoronary Irradiation

Manel Sabaté, MD; I. Patrick Kay, MBChB; Willem J. van der Giessen, MD, PhD; Angel Cequier, MD, PhD; Jurgen M.R. Ligthart, BSc; Joan Antoni Gómez-Hospital, MD; Stéphane G. Carlier, MD; Veronique L.M.A. Coen, MD; Johannes P.A. Marijnissen, PhD; Alexander J. Wardeh, MD; Peter C. Levendag, MD, PhD; Patrick W. Serruys, MD, PhD

Background—Abnormal endothelium-dependent coronary vasomotion has been reported after balloon angioplasty (BA), as well as after intracoronary radiation. However, the long-term effect on coronary vasomotion is not known. The aim of this study was to evaluate the long-term vasomotion of coronary segments treated with BA and brachytherapy.

Methods and Results—Patients with single de novo lesions treated either with BA followed by intracoronary β -irradiation (according to the Beta Energy Restenosis Trial-1.5) or with BA alone were eligible. Of these groups, those patients in stable condition who returned for 6-month angiographic follow-up formed the study population (n=19, irradiated group and n=11, control group). Endothelium-dependent coronary vasomotion was assessed by selective infusion of serial doses of acetylcholine (ACh) proximally to the treated area. Mean luminal diameter was calculated by quantitative coronary angiography both in the treated area and in distal segments. Endothelial dysfunction was defined as a vasoconstriction after the maximal dose of ACh (10^{-6} mol/L). Seventeen irradiated segments (89.5%) demonstrated normal endothelial function. In contrast, 10 distal nonirradiated segments (53%) and 5 control segments (45%) demonstrated endothelium-dependent vasoconstriction ($-19\pm 17\%$ and $-9.0\pm 5\%$, respectively). Mean percentage of change in mean luminal diameter after ACh was significantly higher in irradiated segments ($P=0.01$).

Conclusions—Endothelium-dependent vasomotion of coronary segments treated with BA followed by β -radiation is restored in the majority of stable patients at 6-month follow-up. This functional response appeared to be better than those documented both in the distal segments and in segments treated with BA alone. (*Circulation*. 1999;100:1623-1629.)

Key Words: balloon ■ angioplasty ■ radioisotopes ■ endothelium ■ acetylcholine

Abnormal endothelium-dependent coronary vasomotion has been reported both immediately after and up to 6 months after coronary balloon angioplasty (BA).¹⁻⁴ The preservation of endothelial function is of the utmost importance to maintain the delicate balance between inhibition and promotion of vascular growth, vasoconstriction, and vasodilation, as well as antithrombotic and hemostatic mechanisms.⁵ Intracoronary radiation appears to be a promising new technique to prevent restenosis after BA.⁶⁻⁸ Experimental studies have demonstrated an impairment of endothelial function in the short term after high-dose intracoronary γ -irradiation, which was restored at follow-up.⁹ However, the effect of brachytherapy after balloon-induced injury on vasomotor function in patients remains unknown. The aim of the present study was to assess the long-term effect of intracor-

onary radiation therapy after successful BA on coronary vasomotion.

Methods

Patient Selection

Two groups of patients were compared: patients with single de novo lesions successfully treated with BA followed by intracoronary β -irradiation (n=23) and patients with single de novo lesions successfully treated only with BA (n=16). Patients receiving radiation were included in the Beta Energy Restenosis Trial (BERT-1.5). Patients in the control group were individuals treated with BA alone and matched for age, sex, and vessel size. Those patients in stable condition who returned for 6-month angiographic follow-up formed the study population (n=19, irradiated group and n=11, control group). BERT-1.5 was a prospective multicenter feasibility study. The isotope selected was pure β -emitting $^{90}\text{Sr}/^{90}\text{Y}$, and patients were randomized to receive 12, 14, or 16 Gy at 2 mm from the source. The

Received April 13, 1999; revision received June 21, 1999; accepted June 28, 1999.

From the Thoraxcenter, Heartcenter, Rotterdam, Dijkzigt Academisch Ziekenhuis Rotterdam, The Netherlands (M.S., I.P.K., W.J.v.d.G., J.M.R.L., S.G.C., A.J.W., P.W.S.); Daniel den Hoed Cancer Center, Rotterdam, The Netherlands (V.L.M.A.C., J.P.A.M., P.C.L.); and Hospital de Bellvitge, Universitat de Barcelona, Barcelona, Spain (A.C., J.A.G.-H.).

Correspondence to P.W. Serruys, MD, PhD, Professor of Interventional Cardiology, Head of Department of Interventional Cardiology, Bd 412, Heartcenter, Academisch Ziekenhuis Rotterdam, Erasmus University, PO Box 1738, Dr Molewaterplein 40, 3000 DR Rotterdam, Netherlands. E-mail serruys@card.azr.nl

© 1999 American Heart Association, Inc.

Circulation is available at <http://www.circulationaha.org>

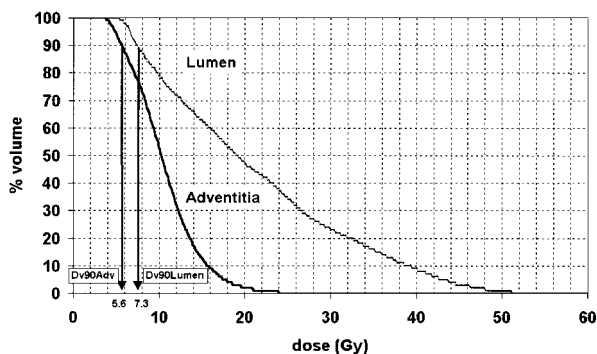


Figure 1. Dose-volume histogram showing cumulative dose received at level of luminal surface and adventitia layer. Minimal dose received by 90% of lumen (D_{v90} Lumen) and adventitia (D_{v90} Adv) was calculated.

inclusion and exclusion criteria of this trial have been reported previously.¹⁰

Radiation Delivery System

The Beta-Cath System (Novoste Corp) was used to deliver localized β -radiation to a coronary artery at the site of coronary intervention. The device consists of 3 components: (1) the transfer device, which stores the radiation source train and allows the positioning of these sources within the catheter; (2) the delivery catheter, which is a 5F multilumen, over-the-wire, noncentered catheter that uses saline solution to send and return the radiation source train; and (3) the radiation source train, which consists of a series of 12 independent 2.5-mm-long cylindrical seeds that contain the radioisotope $^{90}\text{Sr}/^{90}\text{Y}$ sources and is bordered by 2 gold radiopaque markers at the distal and proximal parts of the 30-mm source train.¹¹

Dose Calculation

The actual dose received by the luminal surface was retrospectively calculated by means of dose-volume histograms.¹² This method is based on quantitative intravascular ultrasound (IVUS) under the assumption that the radiation source is positioned at the same place as the IVUS catheter. The method of selection of the area of interest on IVUS has been reported previously.¹³ The IVUS system used was a sheath-based IVUS catheter (ClearView, CVIS, Boston Scientific Corporation) incorporating a 30-MHz single-element transducer rotating at 1800 rpm (Ultrasound, CVIS). Image acquisition and digitization were performed by means of an ECG-gated pullback at a step size of 0.2 mm/step.^{14,15} Volumetric analysis of the irradiated area was performed by a semiautomatic contour detection program developed at our institution.¹⁶ The feasibility and intraobserver and interobserver variabilities of this system have been reported previously.¹⁷⁻¹⁹ The distance between the center of the catheter and both the lumen-intima and media-adventitia interfaces was calculated in 24 pie slices (15° each) in all cross sections corresponding to the irradiated area (30-mm length of the train source). Considering the prescribed dose and the accurate geometric data obtained from the IVUS, the cumulative curve of the dose-volume histogram for a predefined volume (ie, intima or adventitia) can be obtained (Figure 1). From this curve, for example, the minimal dose received by 90% of either the intimal volume (D_{v90} lumen) or the adventitial volume (D_{v90} Adv) was calculated.

Endothelial Function Study

Long-acting vasoactive drugs were discontinued ≥ 48 hours before the study. A percutaneous femoral artery approach and 8F guiding catheter were used in all cases. Endothelium-dependent and -independent coronary vasomotion were studied as described previously in detail²⁰: after the administration of 10 000 IU of heparin, a 3F infusion catheter (Transit, Cordis) was advanced over a guidewire

and placed proximally to the irradiated segment. To avoid wire-induced coronary spasm, the wire was removed. The irradiated segment was identified on the basis of the anatomic landmarks visible on the angiogram performed at the time of the placement of the radiation source. To ensure that the segments were fully bathed by the infusion of acetylcholine chloride (ACh), the tip of the infusion catheter was placed 2 to 3 mm proximal to the proximal border of the irradiated area. To determine the baseline vasomotion, an initial infusion of saline solution for 1 minute through the infusion catheter was performed and a baseline angiogram taken. This was followed by infusion of serial doses of intracoronary ACh, with final estimated intracoronary concentrations of 10^{-8} to 10^{-6} mol/L, to assess endothelium-dependent coronary vasomotion. The duration of each infusion was 2.5 minutes, followed immediately by angiography. All angiograms were taken with identical views and radiographic characteristics. All infusions were delivered at a rate of 2 mL/min by use of a precision pump injector (Mark V, Medrad, Europe BV). The final blood concentrations of ACh were estimated with the assumption that blood flow in the coronary artery was 80 mL/min.²¹ Finally, to evaluate endothelium-independent vasomotion, a nitroglycerin (NTG) bolus (2 mg) was administered through the guiding catheter, after which an angiogram identical to those performed previously was done.²⁰ Throughout each infusion, the heart rate, systemic arterial pressure, and ECG were monitored continuously. Because ACh causes endothelium-dependent vessel relaxation in experimental models and in humans,^{22,23} a paradoxical vasoconstriction after the infusion of this substance is an indicator of endothelial dysfunction.²⁰

The study was approved by the Medical Ethics Committee of our institution, and written informed consent was obtained from all patients in accordance with the guidelines established by the Committee for the Protection of Human Subjects.

Quantitative Coronary Angiography

Quantitative coronary angiography was performed after the infusion of saline solution, at the end of each ACh infusion, and after NTG bolus. Angiograms were performed in the 2 orthogonal projections that best showed the artery of interest, without overlapping of side branches and with less foreshortening. Offline analysis was performed by means of the CAAS II system (Pie Medical BV). Calibration of the system was based on dimensions of the catheters not filled with contrast medium. The intraobserver and interobserver variabilities of this method of analysis have been reported previously.²⁴⁻²⁶ Mean luminal diameter was determined after the infusion of each substance in the irradiated area, in a 15- to 20-mm-long segment distal to the irradiated area and in a contralateral nontreated artery that served as a control. Mean luminal diameter was averaged for the 2 projections, and the percentage of change relative to baseline was noted. All quantitative measurements were performed by the same investigator (M.S.). Intraobserver variability was assessed by reanalysis of the quantitative coronary angiography of a series of 15 studies (150 repeated measures in total) ≥ 3 months apart. Intraobserver differences (mean \pm 2 SD) in mean luminal diameter were as follows: $0.7 \pm 2.7\%$ for baseline values, $0.8 \pm 2.9\%$ after maximal dose of ACh, and $0.7 \pm 2.6\%$ after NTG. The intraclass correlation coefficient (R^2) for repeated measures was 0.97 for baseline values, 0.96 for maximal-dose ACh values, and 0.98 for NTG values. We considered endothelial dysfunction a vasoconstriction of the segment studied after the maximal dose of ACh beyond the variability of the method of analysis ($>3\%$).

Statistical Analysis

Data are presented as mean \pm SD or proportions. To compare continuous variables, 2-tailed Student's *t* test, ANOVA for repeated measurements, and linear regression analysis were performed when appropriate. A value of $P < 0.05$ was considered statistically significant.

TABLE 1. Baseline Characteristics

	Irradiation Group (n=19)	Control Group (n=11)
Age, y	55±8	58±5
Male sex, n (%)	14 (74)	10 (91)
Treated artery, n (%)		
Left anterior descending	10 (53)	10 (91)
Left circumflex	6 (31)	1 (9)
Right coronary	3 (16)	0 (0)
Coronary risk factors, n (%)		
Systemic hypertension	9 (47)	5 (45)
Diabetes mellitus	2 (10)	1 (9)
Smoking	14 (74)	7 (63)
Hypercholesterolemia	11 (58)	6 (54)
Family history	11 (58)	5 (45)
Minimal luminal diameter, mm	1.7±0.6	1.6±0.3
Diameter stenosis, %	39±17	34±7

Continuous data are presented as mean±SD.

Results

Baseline Characteristics

Baseline characteristics of both irradiated and control patients are presented in Table 1. Angiographic restenosis (diameter stenosis >50%) was observed within the irradiated area in 3 patients (16%). Fourteen patients (74%) remained asymptomatic, whereas 5 (26%) presented with angina pectoris Canadian Cardiovascular Society (CCS) class 1 (n=1), 2 (n=1), or 3 (n=3). None of the patients in the control group showed angiographic restenosis, and only 2 presented with angina pectoris CCS class 1. No differences were observed between groups regarding age, sex, coronary risk factors, or minimal luminal diameter and diameter stenosis in the diagnostic angiogram performed at the time of the functional study. The left anterior descending coronary artery was assessed more often in the control group.

Coronary Vasomotion Study

No significant changes in mean aortic pressure and heart rate were observed during the ACh infusion in either group. Mean luminal diameters after infusion of each substance in irradiated and distal nonirradiated segments and in the control group are presented in Table 2. Seventeen irradiated segments (89.5%) demonstrated normal endothelium-dependent coronary vasomotion (16 segments with a vasodilatory response [5.0±3% of change in mean luminal diameter after ACh] and 1 with no change in mean luminal diameter [-0.1% of change after ACh infusion]). On the other hand, endothelial dysfunction was demonstrated in 2 irradiated segments (10.5%): 1 with angiographic restenosis and angina pectoris CCS class 3 and the other with angina pectoris CCS class 1 without restenosis (-5.2% and -7.8% of vasoconstriction after maximal dose of ACh, respectively). In contrast, 10 (53%) of the distal nonirradiated segments demonstrated endothelial dysfunction (-19.5±17% of vasoconstriction after maximal dose of ACh). No significant de novo stenosis was observed at

TABLE 2. Coronary Vasomotor Response (Mean Luminal Diameter)

	Irradiated Segment (n=19)	Distal Segment (n=19)	Control Group (n=11)
Baseline	2.46±0.4	2.20±0.4	2.38±0.3
ACh 10 ⁻⁸	2.49±0.4	2.19±0.5	2.35±0.3
ACh 10 ⁻⁷	2.52±0.4	2.13±0.5	2.33±0.5
ACh 10 ⁻⁶	2.55±0.5*	2.07±0.7	2.31±0.3
NTG	2.62±0.4†	2.33±0.6‡	2.58±0.5‡

Data are presented as mean±SD (in mm).

*P=0.03, †P=0.0004, ‡P=0.01 with respect to baseline values.

distal segments. No significant correlation was demonstrated between the degree of stenosis at follow-up and the vasomotor response. Five patients in the control group (45%) showed endothelial dysfunction in the treated area (-9.0±5% of vasoconstriction at ACh 10⁻⁶ mol/L). Mean percentages of change in mean luminal diameter after infusion of the different substances between the irradiated and control patients and between irradiated and distal nonirradiated segments are presented in Figures 2 and 3. Mean percentage change in diameter after ACh was 3.8±7.1% in the irradiated segments compared with -3.2±7% and -6.6±10% in the control group and in the distal nonirradiated segments, respectively (P=0.01). No significant differences in percentage of change in mean luminal diameter either in irradiated or in distal segments were observed between the 3 coronary vessels after either ACh or NTG. Examples of coronary segments with vasodilation of the irradiated area and vasoconstriction of the distal nonirradiated segment after ACh infusion are depicted in Figures 4 and 5. All of the segments experienced vasodilation after NTG, which is indicative of normal smooth muscle vasomotion (Figures 2 and 3).

Radiation Dose Calculation

Mean prescribed radiation dose was 14±1.9 Gy at 2 mm to the source. However, when dose-volume histograms were applied, the calculated minimal dose received by 90% of the

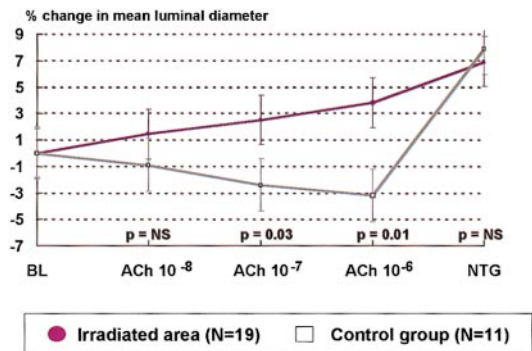


Figure 2. Percentage of change in mean luminal diameter after infusion of each substance in irradiated segments and in control group. Irradiated segments showed, on average, an increase in mean luminal diameter after infusion of ACh, which is indicative of normal endothelial function, whereas control group demonstrated on average vasoconstriction, which is indicative of endothelial dysfunction. Endothelium-independent coronary vasomotion was preserved in both groups. BL indicates baseline.

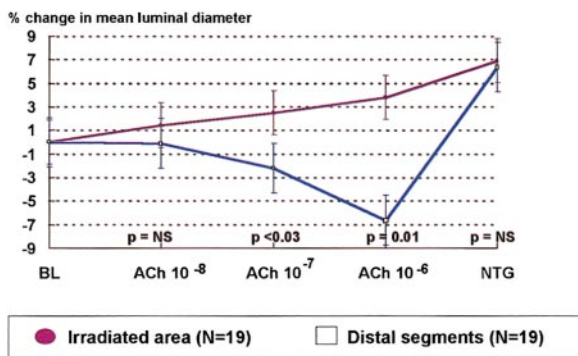


Figure 3. Percentage of change in mean luminal diameter after infusion of each substance in irradiated and in distal nonirradiated segments. Irradiated segments showed, on average, an increase in mean luminal diameter after infusion of ACh, which is indicative of normal endothelial function, whereas distal nonirradiated segments demonstrated, on average, vasoconstriction, which is indicative of endothelial dysfunction. Endothelium-independent coronary vasomotion was preserved in both groups. BL indicates baseline.

luminal surface was 8.2 ± 3.8 Gy, whereas D_{v90} Adv was 5.2 ± 1.9 Gy. Only 6 patients (31.5%) received on average >10 Gy at luminal surface, and only 2 patients (10.5%) received on average >8 Gy at the adventitial layer. No significant correlation was found between endothelium-dependent coronary vasomotion and the calculated D_{v90} lumen ($r = -0.03$; $P = \text{NS}$). Similarly, no significant correlation was observed between the coronary vasomotor response to NTG and D_{v90} Adv ($r = 0.03$; $P = \text{NS}$).

Discussion

This study demonstrates for the first time that the endothelium-dependent vasomotor function of coronary segments treated with BA followed by β -radiation is restored in the majority of stable patients at 6-month follow-up. This functional response observed in irradiated segments appeared to be better than that documented both in distal nonirradiated segments and in segments treated only with BA.

An impairment of endothelial function has been reported at up to 3 to 6 months after BA.⁴ It has been demonstrated that soon after balloon-induced injury, there is a release of von Willebrand factor²⁷ and endothelin²⁸ as markers of endothelial injury. Experimental studies have demonstrated that the endothelium regenerates at follow-up. However, the endothelium appeared to still be dysfunctional,^{29,30} which may cause the release of endothelium-dependent contracting factors and the alteration of endothelial muscarinic receptors.^{31–33}

Endothelial dysfunction in distal nontreated segments is a common finding in atherosclerotic coronary arteries after percutaneous interventions.³ An alteration of autoregulation due to chronic hypoperfusion may be implicated in the distal abnormal responsiveness to ACh.² Furthermore, the presence of coronary risk factors may have a deleterious effect on distal coronary vasomotion.^{34,35}

In contrast, most of the irradiated segments exhibited normal endothelium-dependent vasomotion, and all of them presented a normal response to NTG. Wiedermann et al⁹ demonstrated restoration of endothelial function after high-dose (20 Gy) γ -radiation in a non-balloon-injured animal

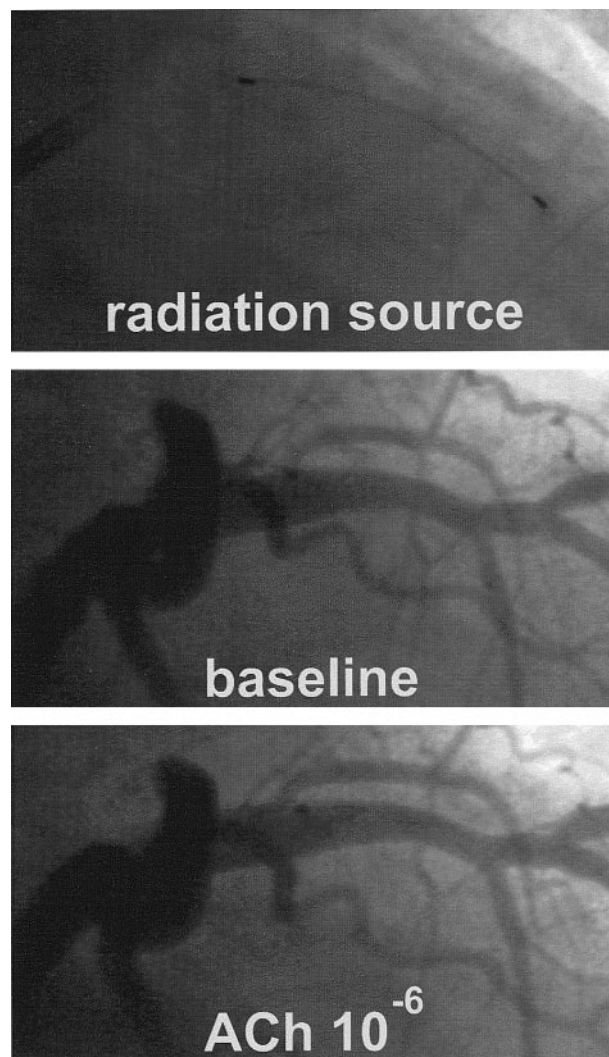


Figure 4. Coronary angiogram showing mild vasodilation in irradiated segment at 6-month follow-up.

model. However, a diffuse fibrosis of the smooth muscle layer, probably responsible for the loss of response to NTG, was detected on histological analysis.⁹ Our findings confirmed these experimental observations in terms of endothelium-dependent coronary vasomotion. The lack of paradoxical vasoconstriction may be explained by an alteration of the muscular media, which may demonstrate an impairment in response to endothelium-dependent vasoregulatory signals. However, vasodilation rather than lack of constriction was the vasomotor response demonstrated in all but 1 of the irradiated segments with normal endothelial function. The vasomotor response to NTG remained unaltered and comparable between groups, which suggests an absence of radiation-induced impairment of the medial layer. In an experimental model, endothelial cells as well as vascular smooth muscle cells were inhibited in a dose-dependent manner. However, at a moderate range of β -particle delivery (0.4 to 6 Gy), but not at a high dose (10 Gy), endothelial cells appeared to be more radioresistant than vascular smooth muscle cells.³⁶ The relatively low dose of radiation received by the treated segments may account for this normal functional behavior. In fact, none

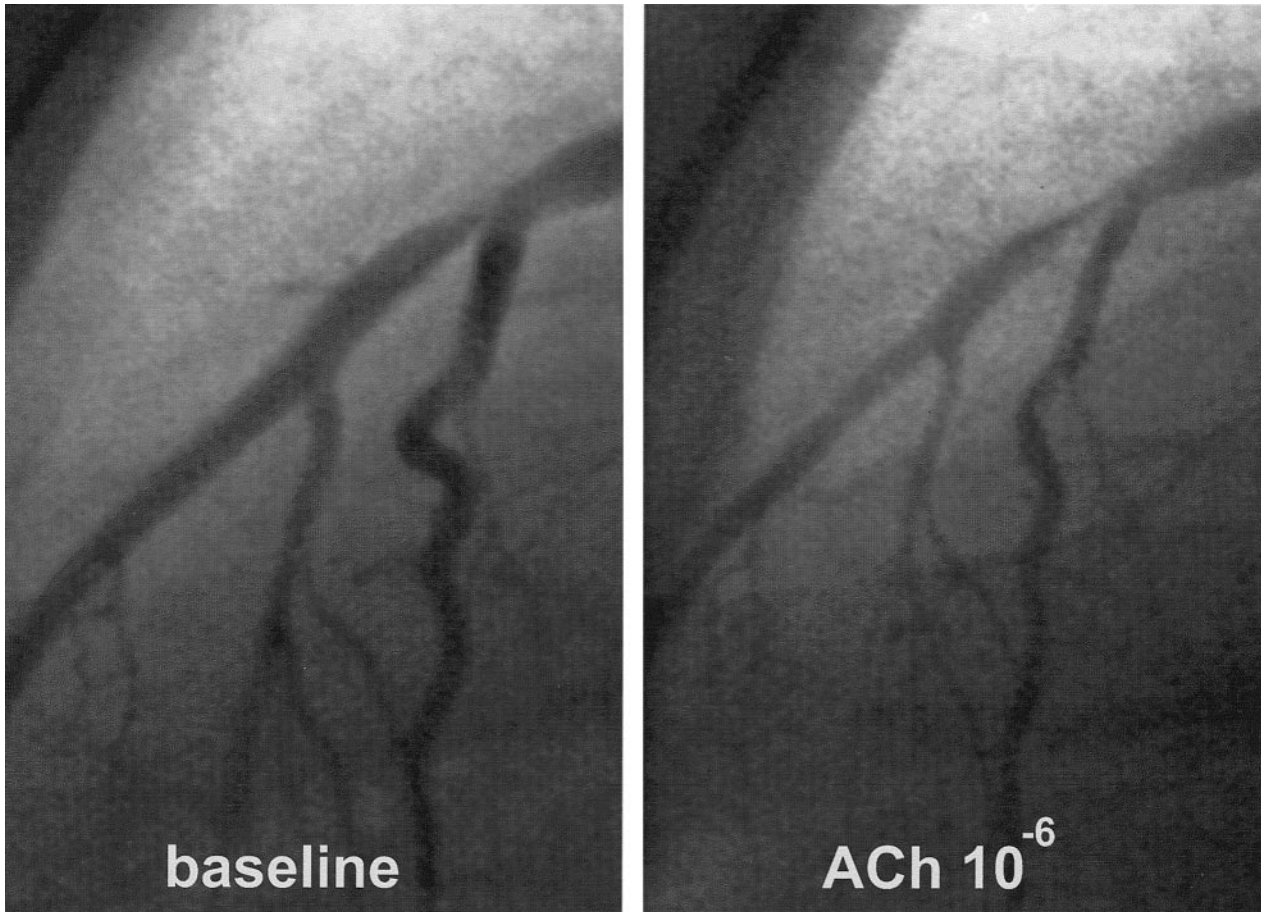


Figure 5. Coronary angiogram showing moderate vasoconstriction of distal nontreated coronary segment after infusion of maximal dose of ACh, which is indicative of endothelial dysfunction.

of the patients actually received on average >10 Gy at the level of the adventitia, as assessed by dose-volume histograms.

On the other hand, an experimental model of porcine coronary arteries subjected to balloon overstretch injury and either placebo or radiation with 18 Gy³⁷ demonstrated that expression of enzyme-inducible nitric oxide synthase (iNOS), responsible for NO production, was enhanced, whereas expression of the cytokine transforming growth factor- β_1 (TGF- β_1) was suppressed in the irradiated group. iNOS is potentially responsible for inhibition of neointimal hyperplasia and stimulation of reendothelialization, whereas TGF- β_1 would enhance intimal hyperplasia and fibrosis by negatively modulating the expression of iNOS.³⁷ Moreover, it has been demonstrated in experimental models that radiation causes dose- and time-dependent impairment of endothelium-dependent relaxation³⁸ and that low-dose radiation would induce an anti-inflammatory reaction through specific dose-dependent modulation of the NO pathway.³⁹ It remains to be seen whether this chain reaction after radiation would result in a late reduction in the restenosis rate. However, restoration of endothelial function may play an important role in this regard.

Study Limitations

Because the use of ACh in unstable patients is not exempt of risk of coronary occlusion, only stable patients were evaluated.

This study assessed patients receiving β -radiation by means of a noncentering device. The actual dose received by the treated segment was rather low; thus, the effect of a higher dose or of different devices that allow a more homogeneous dose distribution remains to be evaluated.

We assessed the vasomotion of the 3 coronary arteries in the irradiated group, which have a potentially different degree of vasoreactivity to ACh. However, the 3 arteries demonstrated comparable vasomotor responses to ACh and NTG both at the irradiated and the distal segments, which overcomes this potential limitation.

We assumed that coronary vasomotion immediately after treatment is markedly impaired, as demonstrated in experimental models and in humans.^{1-4,9} Taking into account the risk of coronary occlusion in such situation, it was considered unethical to determine endothelium-dependent vasomotion immediately after the coronary intervention. Thus, the degree of recovery of coronary vasomotion could not be evaluated.

We also assumed that the IVUS and delivery catheters were lying in the same position in the treated coronary

segment. The size of the IVUS catheter is smaller (2.9F, ≈ 1 mm) than the brachytherapy device (5F), which is thus to some extent more centered in the lumen. Although the catheters should be on the shortest 3D path in the lumen, coronary arteries have a complex curved geometry in space and can be partially deformed by the catheters. Thus, catheters with different rigidity may occupy different positions. The development of new systems that incorporate the IVUS imaging element on the delivery catheter might resolve this drawback.

During irradiation, the position of the delivery catheter inside the lumen is not fixed and may vary during the cardiac cycle because of ventricular contractions, which may lead to some degree of inhomogeneity not assumed by data derived from the static end-diastolic IVUS images.

Acknowledgments

Dr Sabaté is the recipient of the 1997 BEAI200043 grant from the Generalitat de Catalunya for research in endothelial function after brachytherapy. Dr Kay is supported by The National Heart Foundation of New Zealand. The authors are indebted to the personnel of the catheterization laboratory for their help during the study protocol. The Wenckebach prize was awarded to P.W. Serruys by the Dutch Heart Foundation for brachytherapy research in the catheterization laboratory.

References

- Fischell TA, Nellessen U, Johnson DE, Ginsburg R. Endothelium-dependent arterial vasoconstriction following balloon angioplasty. *Circulation*. 1989;79:899-910.
- Fischell TA, Bausback KN, McDonald TV. Evidence for altered epicardial coronary artery autoregulation as a cause of distal coronary vasoconstriction after successful percutaneous transluminal coronary angioplasty. *J Clin Invest*. 1990;86:575-584.
- el-Tamimi H, Davies GJ, Crea F, Maseri A. Response of human coronary arteries after injury by coronary angioplasty. *J Am Coll Cardiol*. 1993;21:1152-1157.
- Vassanelli C, Menegatti G, Zanolla L, Molinari J, Zanotto G, Zardini P. Coronary vasoconstriction in response to acetylcholine after balloon angioplasty: possible role of endothelial dysfunction. *Coron Artery Dis*. 1994;5:979-986.
- Maxwell AJ, Cooke JP. Regulation of vasomotor tone. In: Topol EJ, ed. *Comprehensive Cardiovascular Medicine*. Philadelphia, Pa: Lippincott-Raven; 1998:2919-2946.
- Wiedermann JG, Marboe C, Amols H, Schwartz A, Weinberger J. Intracoronary irradiation markedly reduces restenosis after balloon angioplasty in a porcine model. *J Am Coll Cardiol*. 1994;23:1491-1498.
- Waksman R, Robinson KA, Crocker IR, Wang C, Gravanis MB, Cipolla GD, Hillstead RA, King SB III. Intracoronary low-dose β -irradiation inhibits neointima formation after coronary artery balloon injury in the swine restenosis model. *Circulation*. 1995;92:3025-3031.
- Verin V, Popowski Y, Urban P, Belenger J, Redard M, Costa M, Widmer MC, Rouzaud M, Nouet P, Grob E, Schwager M, Kurtz JM, Rutishauser W. Intra-arterial beta irradiation prevents neointimal hyperplasia in a hypercholesterolemic rabbit restenosis model. *Circulation*. 1995;92:2284-2290.
- Wiedermann JG, Leavy JA, Amols H, Schwartz A, Homma S, Marboe C, Weinberger J. Effects of high-dose intracoronary irradiation on vasomotor function and smooth muscle histopathology. *Am J Physiol*. 1994;267:H125-H132.
- King SB III, Williams DO, Chougule P, Klein JL, Waksman R, Hillstead R, Macdonald J, Anderberg K, Crocker IR. Endovascular beta-radiation to reduce restenosis after coronary balloon angioplasty: results of the Beta Energy Restenosis Trial (BERT). *Circulation*. 1998;97:2025-2030.
- Hillstead RA, Johnson CR, Weldon TD. The Beta-Cath™ system. In: Waksman R, Serruys PW, eds. *Handbook of Vascular Brachytherapy*. London, UK: Martin Dunitz Ltd; 1998:41-51.
- Carlier SG, Marijnissen JPA, Coen VLMA, van der Giessen WJ, Sabaté M, Ligthart JMR, den Boer A, Céspedes IE, Li W, van der Steen AF, Levendag PC, Serruys PW. Guidance of intracoronary radiation therapy based on dose-volume histograms derived from quantitative intravascular ultrasound. *IEEE Trans Med Imaging*. 1998;17:772-778.
- Sabaté M, Serruys PW, van der Giessen WJ, Ligthart JMR, Coen VLMA, Kay IP, Gijzel AL, Wardeh AJ, den Boer A, Levendag PC. Geometric vascular remodeling after balloon angioplasty and β -radiation therapy: a three-dimensional intravascular ultrasound study. *Circulation*. 1999;100:1182-1188.
- Bruining N, von Birgelen C, de Feyter PJ, Ligthart J, Li W, Serruys PW, Roelandt JRTC. ECG-gated versus non-gated three-dimensional intracoronary ultrasound analysis: implications for volumetric measurements. *Cathet Cardiovasc Diagn*. 1998;43:254-260.
- Bruining N, von Birgelen C, Di Mario C, Prati F, Li W, Den Houd W, Patijn M, de Feyter PJ, Serruys PW, Roelandt JRTC. Dynamic three-dimensional reconstruction of ICUS images based on an ECG-gated pullback device. *Comput Cardiol*. 1995:633-636.
- Li W, von Birgelen C, Di Mario C, Boersma E, Gussenhoven EJ, van der Putten N, Bom N. Semi-automated contour detection for volumetric quantification of intracoronary ultrasound. *Comput Cardiol*. 1994:277-280.
- von Birgelen C, de Vrey EA, Mintz GS, Nicosia A, Bruining N, Li W, Slager CJ, Roelandt JRTC, Serruys PW, de Feyter PJ. ECG-gated three-dimensional intravascular ultrasound: feasibility and reproducibility of the automated analysis of coronary lumen and atherosclerotic plaque dimensions in humans. *Circulation*. 1997;96:2944-2952.
- von Birgelen C, Di Mario C, Li W, Schuurbiens JCH, Slager CJ, de Feyter PJ, Roelandt JRTC, Serruys PW. Morphometric analysis in three-dimensional intracoronary ultrasound: an in vitro and in vivo study performed with a novel system for the contour detection of lumen and plaque. *Am Heart J*. 1996;132:516-527.
- von Birgelen C, Mintz GS, Nicosia A, Foley DP, van der Giessen WJ, Bruining N, Arian SG, Roelandt JRTC, de Feyter PJ, Serruys PW. Electrocardiogram-gated intravascular ultrasound image acquisition after coronary stent deployment facilitates on-line three-dimensional reconstruction and automated lumen quantification. *J Am Coll Cardiol*. 1997;30:436-443.
- Ludmer PL, Selwyn AP, Shook TL, Wayne RR, Mudge GH, Alexander RW, Ganz P. Paradoxical vasoconstriction induced by acetylcholine in atherosclerotic coronary arteries. *N Engl J Med*. 1986;315:1046-1051.
- Ganz W, Tamura K, Markus HS, Donoso R, Yoshida S, Swan HJC. Measurement of coronary sinus blood flow by continuous thermodilution in man. *Circulation*. 1971;44:181-195.
- Furchgott RF, Zawadzki JV. The obligatory role of endothelial cells in the relaxation of arterial smooth muscle by acetylcholine. *Nature*. 1980;288:373-376.
- Hodgson JM, Marshall JJ. Direct vasoconstriction and endothelium-dependent vasodilation: mechanisms of acetylcholine effects on coronary flow and arterial diameter in patients with nonstenotic coronary arteries. *Circulation*. 1989;79:1043-1051.
- Haase J, Escaned J, Van Swijndregt EM, Ozaki Y, Gronenschild E, Slager CJ, Serruys PW. Experimental validation of geometric and densitometric coronary measurements on the new generation Cardiovascular Angiography Analysis System (CAAS II). *Cathet Cardiovasc Diagn*. 1993;30:104-114.
- Di Mario C, Hermans WR, Rensing BJ, Serruys PW. Calibration using angiographic catheters as scaling devices: importance of filming the catheters not filled with contrast medium. *Am J Cardiol*. 1992;69:1377-1378.
- Serruys PW, Foley DP, de Feyter PJ. *Quantitative Coronary Angiography in Clinical Practice*. Dordrecht, Netherlands: Kluwer Academic Publishers; 1994.
- Blann A, Midgley H, Burrows G, Maxwell S, Utting S, Davies M, Waite M, McCollum C. Free radicals, antioxidants, and endothelial cell damage after percutaneous transluminal coronary angioplasty. *Coron Artery Dis*. 1993;4:905-910.
- Kruger D, Giannitsis E, Sheikhzadeh A, Stierle U. Cardiac release and kinetics of endothelin after uncomplicated percutaneous transluminal coronary angioplasty. *Am J Cardiol*. 1998;81:1421-1426.
- Yamamoto Y, Tomoike H, Egashira K, Kobayashi T, Kawasaki T, Nakamura M. Pathogenesis of coronary artery spasm in miniature swine with regional intimal thickening after balloon denudation. *Circ Res*. 1987;60:113-121.

30. Cox RH, Haas KS, Moisey DM, Tulenko TN. Effects of endothelium regeneration on canine coronary artery function. *Am J Physiol.* 1989;257:H1681–H1692.
31. De Meyer GRY, Bult H, van Hoydonck AE, Jordaens FH, Buysens N, Herman AG. Neointima formation impairs endothelial muscarinic receptors while enhancing prostacyclin-mediated responses in the rabbit carotid artery. *Circ Res.* 1991;68:1669–1680.
32. Shimokawa H, Flavahan NA, Vanhoutte PM. Natural course of the impairment of endothelium-dependent relaxations after balloon endothelium removal in porcine coronary arteries: possible dysfunction of a pertussis toxin-sensitive G protein. *Circ Res.* 1989;65:740–753.
33. Katusic ZS, Shepherd JT, Vanhoutte PM. Endothelium-dependent contraction to stretch in canine basilar arteries. *Am J Physiol.* 1987;252:H671–H673.
34. Frielingsdorf J, Kaufmann P, Suter T, Hug R, Hess OM. Percutaneous transluminal coronary angioplasty reverses vasoconstriction of stenotic coronary arteries in hypertensive patients. *Circulation.* 1998;98:1192–1197.
35. Sakai A, Hirayama A, Adachi T, Nanto S, Hori M, Inoue M, Kamada T, Kodama K. Is the presence of hyperlipidemia associated with impairment of endothelium-dependent neointimal relaxation after percutaneous transluminal coronary angioplasty? *Heart Vessels.* 1996;11:255–261.
36. Fareh J, Martel R, Kermani P, Leclerc G. Cellular effects of β -particle delivery on vascular smooth muscle cells and endothelial cells: a dose-response study. *Circulation.* 1999;99:1477–1484.
37. Vodovotz Y, Waksman R. Potential roles for nitric oxide and transforming growth factor- β_1 in endovascular brachytherapy. In: Waksman R, ed. *Vascular Brachytherapy*. Armonk, NY: Futura Publishing Co; 1999: 139–146.
38. Qi F, Sugihara T, Hattori Y, Yamamoto Y, Kanno M, Abe K. Functional and morphological damage of endothelium in rabbit ear artery following irradiation with cobalt-60. *Br J Pharmacol.* 1998;123:653–660.
39. Hildebrandt G, Seed MP, Freemantle CN, Alam CA, Colville-Nash PR, Trott KR. Mechanisms of the anti-inflammatory activity of low-dose radiation therapy. *Int J Radiat Biol.* 1998;74:367–378.