

# Primary Malignant Laryngeal Melanoma

— Report of a Case with Review of Literature —

Hoguen Kim and Chan Il Park

*Department of Pathology, Yonsei University College of Medicine*

A case of primary malignant melanoma of the larynx is reported. The patient, a 41-year-old Korean man, presented with dyspnea and blood tinged sputum. Physical examination showed blackish necrotic mass involving right side of the larynx. The mass proved to be malignant melanoma containing many melanin pigments. A description of the lesion and a review of literature are given.

**Key Words:** Melanoma, Larynx

Primary malignant melanoma of the larynx is well documented but extremely uncommon. The rarity is reflected partly on the fact that 99% of primary laryngeal malignancy are epidermoid carcinomas. Only seven cases are now available after Goldmann et al (1972) who collected 18 cases of primary malignant melanoma reported before that time (Conley and Pack, 1974; Shah et al, 1977; Lorenz, 1979).

We report the following as an additional case of malignant melanoma arising in the larynx with review of primary laryngeal melanomas reported in the world literature.

## CASE REPORT

A 41-year-old man was admitted to the ENT department because of dyspnea and blood tinged sputum of one month duration. He had

been in relatively good health until three months before when hoarseness and vague throat discomfort had developed. Physical examination revealed a blackish necrotic mass involving the right side of the larynx. Extensive physical examination of the whole body including the eyes showed no abnormal mass or pigmentation. On laryngogram a 4cm sized mass was demonstrated on the right supraglottic area which extended to the right glottis and subglottis (Fig. 1). A lymphoscintigram revealed a disturbance in the passage of the neck lymphatics. Under the impression of laryngeal malignancy, conservative tracheostomy and biopsy were done.

On microscopic examination, submucosal infiltration of anaplastic cells in cords or small nests was found (Fig. 2). The tumor cells had large nuclei, prominent nucleoli and amphophilic and somewhat glassy cytoplasm (Fig. 3), frequently containing Fontana-Masson positive pigment granules (Fig. 4). The intervening

Received December 13, 1982

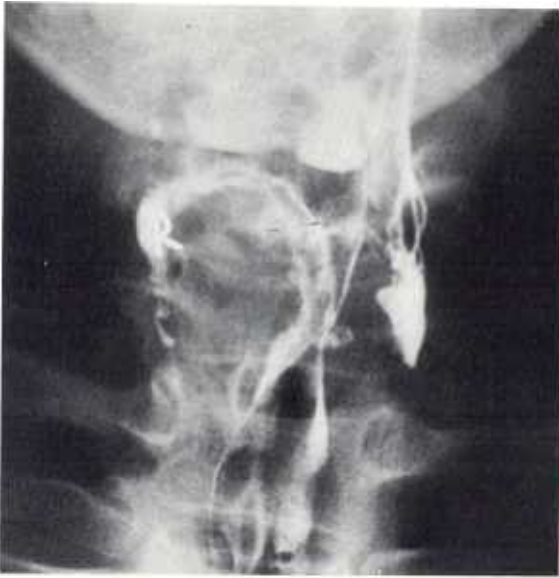

Fig. 1. Laryngogram showing huge mass on the right supraglottic area which extends to the right glottis and subglottis

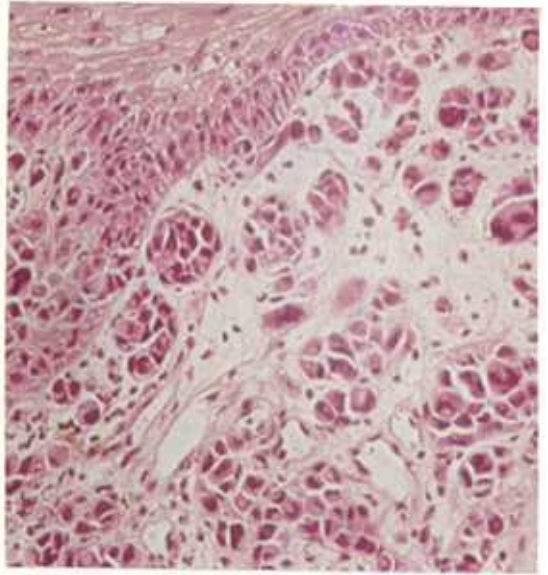


Fig. 2. Microphotograph of the tumor showing clusters of tumor cells closely contact to the mucosa, some invading the mucosa (H&E, x200)

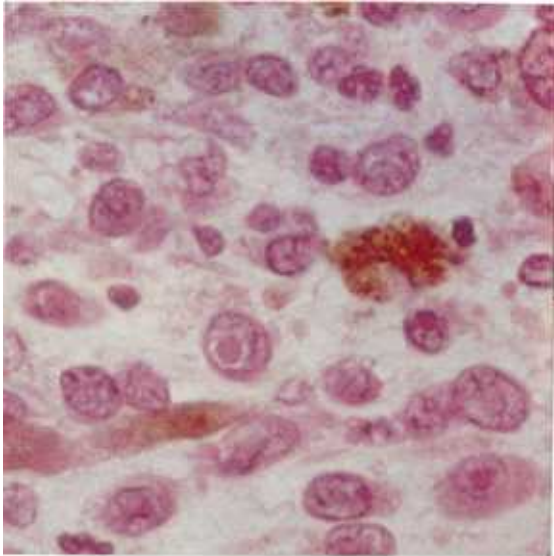


Fig. 3. Microphotograph showing details of the tumor cell and dark brown pigments within and around the tumor cells (H&E, x1000)

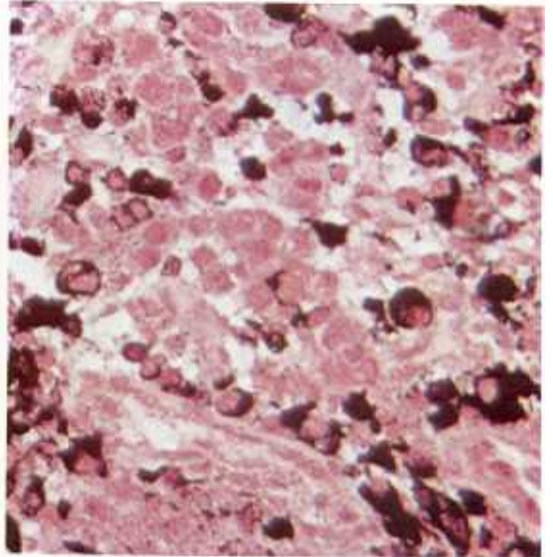


Fig. 4. Microphotograph of a section stained with Fontana Masson technique showing intracellular melanin pigments stained black (Fontana Masson, x400)

stroma was relatively vascular. The tumor cell clusters were in close contact to the mucosa in several areas, some undoubtedly invading the

mucosa (Fig. 2). Melanotic premalignant lesion such as laryngeal melanosis or nevus was not found.

Table 1. Primary malignant laryngeal melanoma reported in the literature

AUTHOR	CASE NUMBER	AGE & SEX	SITE	GROSS FINDING	MICROSCOPIC FINDING	INITIAL COMPLAINT	TREATMENT	FOLLOW-UP
Hilterman, 1908	1	—	Epiglottis	—	—	—	—	—
Havens and Parkhill, 1941	2	48/M	Arytenoid	nodular	melanotic	Irritation on throat	None	WM
Ash and Raum, 1949	3	37/M	Epiglottis	—	amelanotic	—	—	—
Curtiss and Kosinski, 1955	4	57/M	Arytenoid	thickened	amelanotic	Hoarseness	RT	6 years
De Juan, 1955	5	—	Epiglottis	—	(melanotic)	—	TL+ND	—
Moore and Martin, 1955	6	—	Ventricle and False Cord	polypoid	(melanotic)	Hoarseness	TL	14months(-)
	7	—	Ventricle and False Cord	polypoid	(melanotic)	Hoarseness	TL	21months(-)
Cromonesi, 1956	8	—	True Cord	—	(melanotic)	—	TL+RT	—
Welsh and Welsh, 1961	9	41/F	Vocal Cord	polypoid	melanotic	Hoarseness	None	WM
Pantazopoulos, 1964	10	63/M	False Cord	nodular	amelanotic	Hoarseness	PL+RT	17months(+)
Nsamba, 1966	11	57/M	Ventricle and False Cord	fungating	amelanotic	Irritation on throat	TL	4months(+)
Cartlin, 1967	12	86/F	Epiglottis	—	(melanotic)	—	TL	5years(+)
	13	68/M	Extrinsic Larynx	—	—	—	TL	31months
Cady et al, 1968	14	—	Intrinsic Larynx	polypoid	(melanotic)	—	TL+ND	—
Müller, 1968	15	68/—	False Cord	—	melanotic	Hoarseness	Chemo-therapy	56months
El-Barbary et al, 1968	16	40/M	Vocal Cord	polypoid	melanotic	Hoarseness	RT	11months
	17	60/M	Vocal Cord	sessile	melanotic	Hoarseness	RT	4months(+)

Vuori and	18	70/M	Epiglottis and Pyriiform Fossa	ulcerative	melanotic	Pain on the neck	PL	14months
Hormina, 1969								
Shanon et al, 1970	19	60/M	Epiglottis	nodular	melanotic	Vague discom fort	TL+RT	57months
Conley and Pack, 1974	20 21	- -	Epiglottis Supraglottic	- -	- -	- -	- -	- -
Shah et al, 1977	22-25	-	-	-	-	-	-	-
Lorenz, 1979	26	71/M	Epiglottis	polypoid	(melanotic)	Dysphagia	PL+RT	28months
Kim and Park, 1981	27	41/M	Transglottic	polypoid	melanotic	Hoarseness	RT	5months(-)

(melanotic): presumed to be melanotic by gross finding

WM : widespread metastasis at the time of examination

RT : radiation therapy

TL : total laryngectomy

ND : node dissection

PL : partial laryngectomy

(+) : the patient was alive at the time of report without recurrence or metastasis

(-) : The patient was alive at the time of report with recurrence and/or metastasis

With the diagnosis of primary laryngeal melanoma, irradiation therapy was initiated. The mass was mostly but not completely diminished in size after a dose of 2,000 rad was delivered over a period of two weeks. The patient was discharged because he refused further treatment. Four months thereafter the patient visited once with a huge mass in the same location, which had the appearance previously described, but he did not return for further follow-up.

### COMMENT

Melanoma is known to affect the larynx either as a primary or as a metastatic tumor. Several cases presumed to be secondary laryngeal melanomas have been reported (Fisher and Odess, 1951; Loughhead, 1952; Shaheen, 1960; Chamberlain, 1966; Lorenz, 1979), but they are much rarer than the primary cases. Including the present case, all primary laryngeal melanomas recorded in the world literature were summarized in table 1.

Clinically there is greater preponderance in males and they occur at an older age (mean of 58years). The most common initial complaint is hoarseness of several months' duration. Irritation of throat, pain in the neck, vague discomfort and dysphagia are symptoms in a few patients. Of twenty one cases in which the distinct locations of tumor were presented, seventeen were grouped into supraglottic and the remaining four into glottic tumors. In contrast to the epidermoid carcinoma of the larynx (Sessions, 1976), laryngeal melanoma arises more commonly in the supraglottic area.

Grossly most of the tumors show nodular or polypoid configuration and a dark brown color.

Histologically most of the cases contain melanin pigmentation but several cases of

amelanotic melanoma have also been reported (Ash and Raum, 1949; Curtiss and Kosinski, 1955; Pantazopoulos, 1964; Nsamba, 1966).

It is relatively infrequent that primary laryngeal melanoma accompanies a melanotic premalignant lesion, such as laryngeal melanosis or nevus. The presence of junctional changes has been noted only by Ash and Raum (1949) and Curtiss and Kosinski (1955). Two cases of accompanied laryngeal melanosis have been described by Catlin (1967) and Cady *et al* (1968).

The histogenesis of primary laryngeal melanoma is still obscure, however, Goldman *et al* (1972) proposed the cytologic basis for the development of this neoplasm by demonstration of melanocytes in the laryngeal mucosa.

The prognosis is extremely poor. Only two out of sixteen cases survived from the tumor beyond five years (Curtiss and Kosinski, 1955; Catlin, 1967) and eight cases were dead within five years mostly due to widespread metastasis.

## REFERENCES

- Ash JE, Raum M: *An atlas of otolaryngeal pathology. Armed Forces Institute of Pathology, Washington, D.C., 1949*
- Cady B, Rippey JH, Frazell EL: *Non-epidermoid cancer of the larynx. Ann Surg 167:116-120, 1968.*
- Catlin D: *Mucosal melanomas of the head and neck. Am J Roentgenol 99:809-816, 1967*
- Chamberlain D: *Malignant melanoma, metastatic to the larynx. Arch Otolaryngol 83:231-232, 1966*
- Conley J, Pack GT: *Melanoma of the mucous membrane of the head and neck. Arch Otolaryngol 99:315-319, 1974*
- Cremonesi G: *Su un eccezionale report o di sarcoma melanotico primitivo della larynge. Minerva Otorinolaringo 6:333-340, 1956*
- Curtiss C, Kosinski AA: *Primary melanoma of the larynx, report of a case and review of the literature. Cancer 8:961-963, 1955*
- De Juan: *Melanosarcoma laryngeo y otras consideraciones. Acta Otoino-Laring Ibero-Am 7: 296-308, 1955*
- El-Barbary A, Fouad HA, El-Sayed A: *Malignant melanoma involving the larynx. Report of two cases. Ann Otol 77:338-343, 1968*
- Fisher GE, Odess JS: *Metastatic malignant melanoma of the larynx. Arch Otolaryngol 54:639-642, 1951*
- Goldman JL, Lawson W, Zak FG, Roffman JD: *The presence of melanocytes in the human larynx. The Laryngoscope 82:824-835, 1972*
- Havens FZ, Parkhill EM: *Tumors of the larynx other than squamous cell epithelioma. Arch Otolaryngol 34:1113-1122, 1941*
- Hilterman: *Cited by Welsb and Welsb, 1908*
- Lorenz E: *Das maligne melanom des kehlkopfes. HNO 27:275-277, 1979*
- Loughhead JR: *Malignant melanoma of the larynx. Ann Otol 61:154-158, 1952*
- Moore ES, Martin H: *Melanoma of the upper respiratory tract and oral cavity. Cancer 8:1167-1176, 1955*
- Müller E: *Melanoblastome in kehlkopf and mittelchr. HNO 16:133-136, 1968*
- Nsamba C: *A case of malignant melanoma of the larynx. J Laryngol 80:1178-1181, 1966*
- Pantazopoulos PE: *Primary malignant melanoma of the larynx. The Laryngoscope 74:95-102, 1964*
- Sessions DG: *Surgical pathology of cancer of the larynx and hypopharynx. The Laryngoscope 86: 814-839, 1976*
- Shah JP, Andrew GH, Elliot WS: *Mucosal melanoma of the head and neck. Am J Surg 134:531-535, 1977*
- Shaheen OH: *A case of metastatic amelanotic melanoma of the larynx. J Laryngol 74:182-187, 1960*
- Shannon E, Covo J, and Loeventhal M: *Melanoma of the epiglottis. A case treated by supraglottic laryngectomy. Arch Otolaryngol 91:304-305, 1970.*
- Vuori EE, Hormia M: *Primary laryngeal melanoma of the larynx and pharynx. J Laryngol 83:281-287, 1969*
- Welsh LW, Welsh JJ: *Malignant melanoma of the larynx. The Laryngoscope 71:185-191, 1961*