

Primary malignant mediastinal germ cell tumors: A single institutional experience

Subhasis Mishra, Saroj Kumar Das Majumdar, Mukund Sable¹, Dillip Kumar Parida

Abstract

Background: Primary mediastinal malignant germ cell tumour (PMMGCT) is rare with unsatisfactory prognosis and pose difficulty in management due to lack of guidelines. **Methods:** All cases of PMMGCT diagnosed and treated between years 2014 to 2018 were retrospectively evaluated for clinicopathological features, multimodality treatment and follow up. **Results:** Among a total of five PMMGCT cases, three were seminomatous and two were non seminomatous tumour [Yolk-sac tumour (n-1) and Mixed tumour (n-1)]. Four of these cases were non - metastatic with locally advancement and another one presented with metastasis to supraclavicular lymph node. All patients received platinum based induction chemotherapy. Post-induction chemotherapy, two cases of non seminomatous tumours underwent surgery. Among the three seminoma cases, one patient showed complete metabolic response; one with metastasis succumbed to the disease and the in-operable case of seminoma received local radiotherapy. **Conclusion:** PMMGCT needs a multi-disciplinary approach for appropriate diagnosis and management. Clinicopathological features like tumour site, extension, histopathological type, tumour stage and serum tumour marker are necessary for prognostication and decision making of further treatment plan.

Key words: Extragenadal germ cell tumor, mediastinum, multimodality management, seminoma, yolk-sac tumor

Introduction

Extragenadal germ cell tumors (GCTs) are mainly midline in location, with mediastinum being the most common site.^[1] Primary mediastinal malignant GCT (PMMGCT) is a rare cancer contributing <5% of all GCTs and <4% of all mediastinal tumors.^[2] Although the histomorphological features of mediastinal GCTs are similar to those of gonadal GCTs, the biological behavior, clinical presentation, and prognosis vary.^[3] Primary mediastinal GCT (PMGCT) is considered as a separate unique entity with different multimodality approach in the management of patients. A combined management with multi-agent chemotherapy (CT), surgery, and radiotherapy (RT) is an integral part of the treatment. However, due to rarity of this tumor subset, there is a lack of consensus regarding its treatment strategies.

In this study, we retrospectively reviewed our experience with PMMGCT for their clinicopathological features and multimodality management approach.

Materials and Methods

A retrospective analysis of patients presenting and diagnosed at a tertiary care center of eastern part of India during the time period spanning from January 2014 to December 2018 was done. During this time period, five patients had presented with PMMGCT. All these cases were diagnosed by histopathological examination of the primary tumor mass. Patients having primary GCTs at gonadal or other extragonadal sites (nonmediastinal) were excluded from the study. Similarly, patients with mature teratoma (nonmalignant GCT) of mediastinum were also not included in the study. Clinicopathological details such as age, sex, site, serum tumor marker level (alpha-fetoprotein [AFP], beta-human chorionic gonadotropin [B-hCG], and lactate dehydrogenase [LDH]), histopathological details, and CT, RT, and surgical details were obtained from the archival of hospital records.

Results

All the five cases of PMMGCTs were male, and the age of

presentation ranged from 18 to 34 years (mean: 25.2 years). All tumors were from the anterior mediastinal location. Pretreatment image-guided biopsy was available in all cases, and postsurgery histopathological details were available in two patients. Among these cases, three cases had seminoma, one had yolk-sac tumor, whereas the other patient had mixed GCT (comprising seminoma, yolk sac, and embryonal carcinoma). Four patients presented in locally advanced and inoperable stage, whereas one patient had distant metastasis at the time of presentation.

All patients received CT in the initial setting with bleomycin, etoposide, and cisplatin (BEP) or etoposide, ifosfamide, and cisplatin (VIP) regimen. Among the two patients who underwent surgery, one patient with yolk-sac tumor showed complete pathological response in the postoperative specimen. The follow-up period ranged from 5 to 22 months (median: 11.5 months). One patient had complete metabolic response on positron emission tomography scan after receiving six cycles of CT [Figures 1 and 2], whereas one patient had stable disease with inoperable status after induction CT and then received local RT. Two out of five patients died due to the disease. One patient with upfront metastasis succumbed to the disease after receiving one cycle of CT, and another patient developed local and distance recurrence after 6 months of surgery, for which he had received palliative CT and died after 18 months of follow-up. The treatment details and response thereof are summarized in Table 1.

Discussion

GCTs most commonly arise in the gonads, namely testis and ovary. They originate from germ cells at different stages of development. A diagnosis of primary extragonadal GCT is established when the GCT is found at sites other than gonadal tissue, i.e., pineal gland, retroperitoneum, mediastinum, and sacral region. It is hypothesized that extragonadal GCT may have been originated due to abnormal migration and differentiation of primordial germ cells during early embryogenesis. Another metastatic dissemination hypothesis suggests the dissemination

Access this article online

Quick Response Code:



Website: www.sajc.org

DOI: 10.4103/sajc.sajc_47_19

Departments of Radiotherapy and ¹Pathology, All India Institute of Medical Sciences, Bhubaneswar, Odisha, India

Correspondence to: Dr. Mukund Sable, E-mail: mukundnsable@gmail.com

This is an open access journal, and articles are distributed under the terms of the Creative Commons Attribution-NonCommercial-ShareAlike 4.0 License, which allows others to remix, tweak, and build upon the work non-commercially, as long as appropriate credit is given and the new creations are licensed under the identical terms.

For reprints contact: reprints@medknow.com

How to cite this article: Mishra S, Das Majumdar SK, Sable M, Parida DK. Primary malignant mediastinal germ cell tumors: A single institutional experience. South Asian J Cancer 2020;9:27-9.

Table 1: Details of patients showing mode of presentation, treatment, and response

Sex	Age (years)	Histopathology	Metastasis	Serum AFP	Treatment	Recurrence	Status
Male	34	Seminoma	No	1.18	6×VIP-RT	No	On 5-month follow-up
Male	18	Yolk sac	No	>4000	3×VIP-surgery-1×VIP (pCR after Sx)	No	On 5-month follow-up
Male	25	Seminoma	Supraclav node with SVCO	1.2	1×EP	-	Died after 1 cycle of CT
Male	27	Seminoma	No	0.8	3×BEP-2×EP	No	On 22-month follow-up
Male	22	Mixed (seminoma, embryonal carcinoma, yolk sac)	No	27,593	6 × VIP-surgery	After 6 months of surgery - pleural and hepatic metastasis - received 3 × TIP	Died (18 months of follow-up)

SVCO=Superior vena cava obstruction, RT=Radiotherapy, CT=Chemotherapy, pCR=Pathological complete response, AFP=Alpha-feto protein, BEP=Bleomycin, etoposide, and cisplatin, VIP=Etoposide, ifosfamide, and cisplatin, EP=Etoposide, cisplatin, TIP=Paclitaxel, ifosfamide, cisplatin

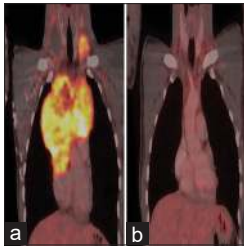


Figure 1: Comparative positron emission tomography-computed tomography scan images in coronal section of a patient showing prechemotherapy disease extent (a) and complete metabolic response after completing chemotherapy (b)

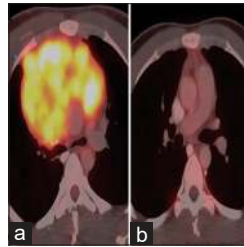

Figure 2: Comparative positron emission tomography-computed tomography scan images in axial section of the patient showing prechemotherapy disease extent (a) and complete metabolic response after completing chemotherapy (b)

of primary gonadal tumor to the extragonadal location, where the primary disease has subsided and hence remains undetected. PMGCTs constitute approximately 10%–15% of all mediastinal tumors, whereas PMMGCTs constitute only 1%–4% of the mediastinal tumors.^[4] Liu *et al.* reported that mediastinal seminomas accounted for approximately 33% of all PMMGCTs followed by immature teratoma (25.9%), yolk-sac tumor (20.4%), and mixed tumors (9%).^[5] There is a paucity of data of PMMGCT in Indian patients in the form of case reports and short case series.^[6,7] In our series, seminomas constitute 3/5 of all malignant GCTs, whereas the nonseminomatous group comprises yolk-sac tumor (1/5) and mixed tumor (1/5).

PMMGCTs mostly present with the chief complaints of cough, breathlessness, chest pain, and neck and upper-chest swelling according to the location and extension of the primary tumor mass. Among our five patients, three had the presenting complaint as facial puffiness and neck swelling, whereas two patients had nonproductive cough. Diagnosis is established by histopathological evaluation from the mediastinal mass. Serological markers, i.e., serum AFP, B-hCG, and LDH, carry a diagnostic, prognostic, and predictive significance. All the three patients of seminoma had normal serum AFP level, whereas AFP value was significantly increased in both yolk-sac and mixed GCTs. Serum LDH is a nonspecific marker in the majority of cases. In operable cases of PMMGCT, histopathological examination of the resected specimen gives the definitive pathological subtyping of the tumor. However, in inoperable cases, biopsy via mediastinoscopy and thoracoscopy is preferred over percutaneous fine-needle aspiration in view of needle tract dissemination and inability to diagnose mixed tumor on cytomorphology.

Patients with nonseminoma tumors have a 5-year overall survival rate of only 45%, compared with almost 90% rate of long-term cure for patients with seminoma.^[8] Therapeutic approach for PMMGCTs plays a vital role in patient's response and survival. Seminomas have a favorable prognosis and fare better compared to their nonseminomatous counterparts. Management of mediastinal GCT requires a multimodal treatment approach involving surgery, CT, and RT. Tumor location, extension, serum tumor markers, and histopathological type guide the treatment approach. Platinum-based CT regimen is the standard practice for all GCTs. BEP has been the traditional CT regimen used in gonadal GCTs. However, in mediastinal GCTs, bleomycin use has been associated with decreased pulmonary function and increased perioperative pulmonary complications. Hence, since the last two decades, VIP regimen has been the preferred choice for induction CT over BEP regimen, and it should be advised in patients of operable MMGCT, as used in our cases.^[9] Post CT evaluation of serum tumor marker is important to decide further management. Cases with normalization of the markers require surgery. There is ambiguity on the management of cases with persistent elevated marker levels; the opinion is divided regarding surgery or salvage CT.^[10,11] Patients with complete radiological response with normalization of tumor markers can be spared from surgery and kept under observation, as observed in one of our patients. Adjuvant CT can be planned in patients showing pathological residual disease. RT has a definite role in seminomatous tumors and in some cases of inoperable nonmetastatic nonseminomatous tumors.^[12]

Conclusion

PMMGCTs need a multidisciplinary approach for appropriate diagnosis and management. Tumor site, extension, histopathological type, stage, and tumor marker play an important role in prognostication and further selection of treatment plan and response.

Financial support and sponsorship

Nil.

Conflicts of interest

There are no conflicts of interest.

References

- Ganjoo KN, Rieger KM, Kesler KA, Sharma M, Heilman DK, Einhorn LH. Results of modern therapy for patients with mediastinal nonseminomatous germ cell tumors. *Cancer* 2000;88:1051-6.
- Schmoll HJ. Extragonadal germ cell tumors. *Ann Oncol* 2002;13 Suppl 4:265-72.
- Nichols CR. Mediastinal germ cell tumors. Clinical features and biologic correlates. *Chest* 1991;99:472-9.

4. Takeda S, Miyoshi S, Ohta M, Minami M, Masaoka A, Matsuda H. Primary germ cell tumors in the mediastinum: A 50-year experience at a single Japanese institution. *Cancer* 2003;97:367-76.
5. Liu Y, Wang Z, Peng ZM, Yu Y. Management of the primary malignant mediastinal germ cell tumors: Experience with 54 patients. *Diagn Pathol* 2014;9:33.
6. Deb M, Mohanty S, Ananthamurthy A, Garg I, Das K. Atypical extragonadal germ cell tumors. *J Indian Assoc Pediatr Surg* 2012;17:9-15.
7. Karanth SS, Vaid AK, Batra S, Sharma D. Mediastinal germ cell tumour causing superior vena cava tumour thrombosis. *BMJ Case Rep* 2015;2015. pii: bcr2014208356.
8. Sakurai H, Asamura H, Suzuki K, Watanabe S, Tsuchiya R. Management of primary malignant germ cell tumor of the mediastinum. *Jpn J Clin Oncol* 2004;34:386-92.
9. Ranganath P, Kesler KA, Einhorn LH. Perioperative morbidity and mortality associated with bleomycin in primary mediastinal nonseminomatous germ cell tumor. *J Clin Oncol* 2016;34:4445-6.
10. Kesler KA, Rieger KM, Hammoud ZT, Kruter LE, Perkins SM, Turrentine MW, *et al.* A 25-year single institution experience with surgery for primary mediastinal nonseminomatous germ cell tumors. *Ann Thorac Surg* 2008;85:371-8.
11. Wright CD, Kesler KA, Nichols CR, Mahomed Y, Einhorn LH, Miller ME, *et al.* Primary mediastinal nonseminomatous germ cell tumors. Results of a multimodality approach. *J Thorac Cardiovasc Surg* 1990;99:210-7.
12. Wang J, Bi N, Wang X, Hui Z, Liang J, Lv J, *et al.* Role of radiotherapy in treating patients with primary malignant mediastinal non-seminomatous germ cell tumor: A 21-year experience at a single institution. *Thorac Cancer* 2015;6:399-406.