

## PRIMARY TORSION AND IDIOPATHIC SEGMENTAL INFARCTION OF OMENTUM

M.R.K. MOTAMEDI, M.D., F.A.C.S., M.R. ZAFARGHANDI, M.D.,  
AND M.H.S. MODAGHEGH, M.D.

*From the Department of Surgery, Shohada Medical Center, Shahid Beheshti University of Medical  
Sciences, Tehran, Islamic Republic of Iran.*

### ABSTRACT

Torsion and infarction of the greater omentum are two rare clinical situations which present as an acute abdomen. Nevertheless, knowledge concerning these two problems can help the surgeon in proper diagnosis and treatment. Since the first report on primary torsion by Eitel in 1899, a few hundred more have been reported and some collective reviews published to date. In this study we will present a complete review concerning the history, classification, pathophysiology, clinical manifestations and treatment of these disorders. In addition, we will report seven cases, four of whom developed primary torsion and the other three idiopathic segmental infarction of the omentum.

*MJIRI, Vol. 10, No. 4, 271-278, 1997.*

### INTRODUCTION

Vascular accidents of the omentum including torsion, infarction and hemorrhage are all rare causes of the acute abdomen. They are usually misdiagnosed in the majority of cases as acute appendicitis, followed by acute cholecystitis. Other differential diagnoses are perforated peptic ulcer, appendicular abscess, pancreatitis, torsion of ovarian cyst and diverticulitis.<sup>24,31</sup> Therefore it is important that responsible physicians be aware of this entity. Since all these patients require surgical exploration regardless of clinical diagnosis, a precise preoperative diagnosis is only of academic interest.<sup>24</sup> In one series of 165 reported cases, only one case was correctly diagnosed preoperatively and from then on no similar cases have been reported.<sup>25</sup>

In addition to torsion of the greater omentum, a few isolated instances of torsion of the gastrocolic or gastrohepatic ligaments have been reported.<sup>7,16</sup> Von Klimko described the presence of so-called third omentum undergoing torsion.<sup>34</sup> Complete torsion of the omentum and torsion of accessory

omentum has also been recorded.<sup>24</sup> It is recommended that in all negative exploratory laparotomies the greater omentum be evaluated routinely to avoid missing an instance of infarcted omentum.

### HISTORICAL REVIEW

Omental torsion was first described in the literature by de-Marchetti in 1858 and primary torsion of the omentum by Eitel in 1899.<sup>13,24</sup> In a case report by Eberts, spontaneous hemorrhage had occurred from the greater omentum of a young man (1920).<sup>12</sup> Schomberg in 1929 described three cases of what he termed "acute hemorrhagic epiploitis",<sup>32</sup> in all of whom there were areas of infarction of the omentum and no evidence of torsion or omental disease. Johnson in 1932 reported a case of what he called "primary omental thrombosis" which was associated with heart disease.<sup>23</sup> In 1940 Pines and Rabinovich described six cases under the title of "idiopathic segmental infarction".<sup>29</sup> Eliason and

## Omental Torsion and Infarction

**Table I: Anton's classification.**

- A: Primary (idiopathic, cryptogenic, pure intra-abdominal)
- B: Secondary:
  - 1- Hernial: (external, in sac)
  - 2- Abdominal:
    - a: Intrinsic (cysts and tumors)
    - b: Extrinsic (associated with pathology of abdominal and pelvic organs and peritoneum).

**Table II. Leitner's classification.**

- A: Omental infarction (with or without gangrene) due to torsion.
  - 1- Primary (idiopathic)
  - 2- Secondary
- B: Omental infarction (with or without gangrene) due to thrombosis.

**Table III. The ideal classification of omental accidents.**

- Omental vascular accidents:
  - A= Hemorrhage (into the cyst or freely into the peritoneal cavity)
    - 1. Spontaneous
    - 2. Secondary to blood dyscrasias
  - B= Infarction: due to
    - 1. Torsion:
      - a- Primary (without a causative factor)
      - b- Secondary (due to adhesion or entrapment by intra-abdominal or pelvic lesions)
    - 2. Thrombosis:
      - a- Idiopathic (without predisposing factors)
      - b- Secondary (due to generalized vascular or cardiac problems)

Johnson reported the sole case of spontaneous detorsion in 1939.<sup>14</sup> Anton et al. in 1949 published an excellent review in which they discussed the embryology, anatomy, physiology and pathology of the omentum.<sup>3</sup> They listed 104 references and proposed an etiologic classification for various types of omental torsion (Table I).<sup>3</sup> At the same time, Caron had found 70 cases of primary omental torsion reported until 1946.<sup>8</sup> Leitner et al. in 1952 published a comprehensive review article of 100 previously reported cases in addition to his own six cases and proposed an inclusive classification for vascular disturbances of the omentum (Table II).<sup>24</sup> A review of literature by Bernatz in 1956 revealed 100 cases of symptomatic torsion.<sup>5</sup>

Mainzer and Simoes provided another comprehensive review of 165 reported cases in 1964.<sup>25</sup> In 1968 Epstein and Lempake found 88 cases of primary idiopathic segmental infarction of the greater omentum in the literature, to which Hedayati and co-workers and Delaurentis and associates added two and ten more cases, respectively, up to 1971.<sup>13,20,22</sup>

Now we have about 150 published cases of segmental infarction of the omentum.<sup>10</sup> Brown and Noone collected data of 180 reported cases and published it in association with 4 new cases.<sup>7</sup> These entities may occur more often than is suspected because surgeons rarely mention the appearance of the omentum in their operative notes.<sup>21</sup>

### CLASSIFICATION

Acute omental accidents can be divided into 1) infarction or 2), hemorrhage. Hemorrhage is extremely rare and may occur into a cyst or tumor or freely into the peritoneal cavity. It may be spontaneous in origin or as a result of blood dyscrasias. Omental infarction most commonly is due to torsion but may be a result of vascular accidents (thrombosis).

Omental torsion in turn is classified as primary (without a causative factor) and secondary (due to adhesion or entrapment by intraabdominal or pelvic lesions). Infarctions

**Table IV. Clinical findings of 180 cases according to Brown's review (1971).**

<p>A= Preoperative diagnosis:</p> <ul style="list-style-type: none"> <li>- Acute appendicitis= 83%</li> <li>- Acute cholecystitis= 15%</li> </ul> <p>B= male to female ratio= 1-1.5/1</p> <p>C= Age (range 3-75 years):</p> <ul style="list-style-type: none"> <li>-under 12 years= 15%</li> <li>-26-50 years= 53%</li> <li>-over 50 years= 50%</li> </ul> <p>D= Symptoms:</p> <ul style="list-style-type: none"> <li>-Location of pain:                             <ul style="list-style-type: none"> <li>RLQ= 79%</li> <li>RUQ= 13%</li> <li>Left side= 8%</li> </ul> </li> <li>-Nausea= 47%</li> <li>-Vomiting= 30%</li> <li>-Anorexia= 4%</li> </ul> <p>E= Signs:</p> <ul style="list-style-type: none"> <li>-Temp: Less than 100°F= 50%</li> <li style="padding-left: 20px;">between 100°-101°F= 41%</li> <li style="padding-left: 20px;">greater than 101°F= 9%</li> <li>-Palpable mass= 22%</li> </ul>	<p>F= Laboratories:</p> <ul style="list-style-type: none"> <li>-Leukocytosis (&gt;12000 WBC/mm<sup>3</sup>):                             <ul style="list-style-type: none"> <li>Adults= 56%</li> <li>Children= 84%</li> </ul> </li> <li>-Neutrophil response (&gt;80%)                             <ul style="list-style-type: none"> <li>Adults= 22%</li> <li>Children= 21%</li> </ul> </li> </ul> <p>G= Operative findings:</p> <ul style="list-style-type: none"> <li>-Free abdominal fluid= 77% (usually serosanguinous but rarely turbid)</li> <li>-The size of the infarcted segment, Range= 2.5×2.5 to 27.5×20cm, (mean 8×8cm)</li> <li>-Involvement of the entire greater omentum= only 3 cases</li> <li>-Torsion of the accessory omentum= 9 cases</li> </ul>
--	--

due to vascular accidents may also be idiopathic (without predisposing factors) or secondary to generalized vascular or cardiac problems (Table III). Of these various types, our interest is in the two rarest problems, primary omental torsion and idiopathic segmental infarction. We will discuss the pathophysiology, etiologic factors, clinical presentation and treatment of these two problems in this study.

### **PATHOPHYSIOLOGY**

The definitive cause is obscure, but some possible etiologic factors may be involved in the pathogenesis of both torsion and infarction. Some anatomic considerations are helpful in better understanding the etiology.

A- Omental veins are longer than omental arteries, and have very thin walls.<sup>24</sup>

B- The right side of the omentum is redundant and more prone to torsion.

C- It is claimed that the right side of the omentum has a poor circulation which is collateral in nature, due to its differentiation from the lesser omentum embryologically, and therefore it is more prone to ischemia and gangrene.<sup>15</sup>

For primary torsion, among the many predisposing

factors, anatomic variations of the omentum such as malformations of the pedicle, tongue-like projections along the free edge, bifid, trifid or maldeveloped omentum, presence of accessory omentum and variations in size and deposition of fat in various parts of the omentum are mentioned.<sup>18</sup>

Obesity, especially in younger patients, sudden straining, trauma and exertion have also been blamed for precipitating or initiating torsion. Occurrence of venous redundancy and vascular abnormalities that may produce venous congestion or segmental thrombosis may also initiate torsion.<sup>18,24,26</sup>

The torsion is usually in a clockwise direction around a narrow pedicle which may lead to arterial occlusion and ultimately infarction and gangrene.<sup>1,3</sup>

Idiopathic segmental infarction seems to initiate from venous thrombosis due to stretching or trauma resulting in rupture or intimal tear.<sup>24</sup> It has variously been attributed to:

1- Postprandial stress on thin-walled omental veins, producing hemorrhage and thrombosis,<sup>3,24,33</sup>

2- Thrombosis following endothelial injury to omental veins by physical exertion or gravity,<sup>29</sup>

3- Embryologic and anatomic variations of the omentum,<sup>15</sup>

4- Gravitational stress of obesity, causing rupture of

## Omental Torsion and Infarction

Table V.

Case No.	Sex	Age (yr)	Diagnosis	Symptoms	Duration of symptoms	Signs	Mass	WBC /mm <sup>3</sup>	Preoperative impression
1	M	14	torsion	RLQ pain	1 day	T= 38 PR= 100 tenderness & rebound tenderness & guarding	----	10,600	acute appendicitis
2	M	29	torsion	RUQ pain	36 hrs	tachycardia mild fever tenderness & rebound tenderness & guarding	----	14,500	acute abdomen
3	M	10	torsion	RLQ pain	4 days	T= 38 PR= 90 tenderness & rebound tenderness	----	12,700	acute appendicitis
4	M	45	torsion	paraumbilical pain & anorexia	8 hrs	T= 37 PR= 100 tenderness & rebound tenderness & guarding	†	10,000	phlegmon
5	F	65	infarction	RLQ pain	2 days	T= 37.9 PR= 96 tenderness & rebound tenderness & guarding	----	7,900	acute appendicitis
6	F	70	infarction	RUQ pain	4 days	T= 37.3 PR= 100 tenderness & rebound tenderness +ve Murphy's sign	----	11,300	acute cholecystitis
7	M	40	infarction	periumbilical pain & anorexia	2 days	T= 37.5 PR= 80 tenderness & rebound tenderness	----	10,500	acute abdomen

omental veins,<sup>20</sup> and

5- Disproportionate overgrowth of omental fat leading to ischemia and necrosis.<sup>2,11</sup>

Some believe that this problem occurs in the fat-gaining middle-aged group, and they postulate that the omentum might outgrow its blood supply and undergo infarction as a rapidly growing sarcoma does.<sup>31</sup> Blood extravasation and serosanguinous fluid collections may lead to chemical peritonitis.<sup>1</sup>

### CLINICAL MANIFESTATIONS

There is no characteristic sign or symptom, but pain is the main complaint.<sup>1</sup> It starts suddenly, initially somewhat generalized and ultimately localized, more often in the right lower quadrant and to some extent in the right upper quadrant, peri- or paraumbilical area, right loin and rarely in the left side of the abdomen.<sup>24</sup>

The pain is constant and occasionally remitting. It may subside or diminish when the patient lies down. The pain is not progressive which is in contrast to appendicitis. Nausea and vomiting may be present but anorexia is rare. Constipation and diarrhea are also reported. The condition may affect

all age groups including children but most commonly involves middle-aged men.<sup>6</sup>

Significant findings on physical examination are fever, localized tenderness and rebound tenderness mainly in the right lower quadrant associated with guarding and occasionally a palpable, tender, mobile mass on the right side (Table IV).<sup>1,24</sup>

Relief of symptoms has been reported as a result of spontaneous detorsion or autoamputation.<sup>1,14,17,18</sup>

Intestinal obstruction may be a late presentation of untreated patients as a result of adhesion following fibrosis of the involved omental segment.<sup>1,7</sup>

### LABORATORY EVALUATION

Leukocytosis is frequent. A neutrophil response greater than 80% and eosinophilia has been reported.<sup>24</sup> Abdominal plain film may reveal a "sentinel loop" near the inflamed omental portion. CT scan and ultrasonography may aid in preoperative diagnosis.<sup>4,27,30</sup> Recently laparoscopic intervention has been used in diagnosis and treatment of this problem.<sup>19</sup>

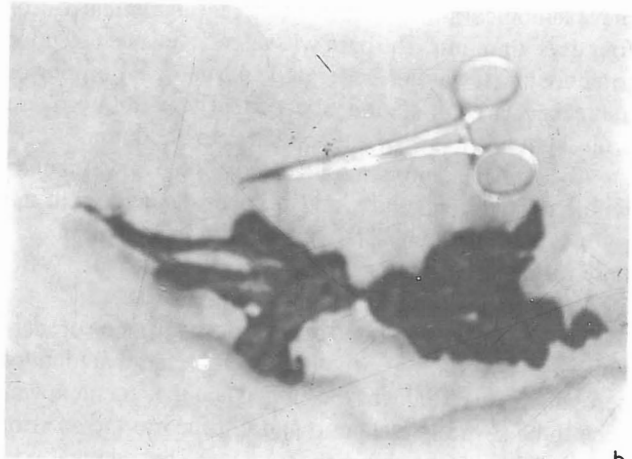
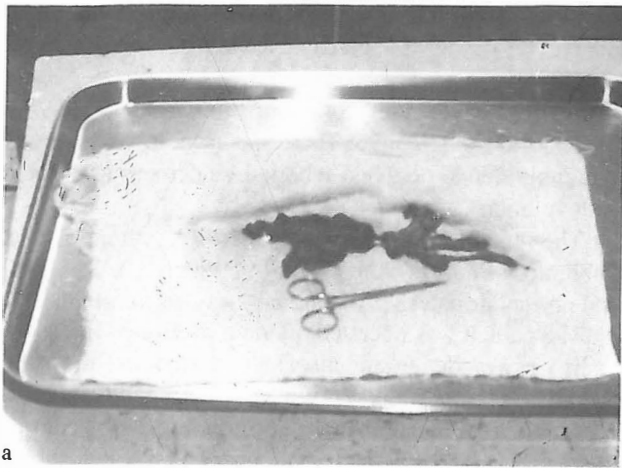


Fig. 1, a. The resected specimen, b. Close-up view.

## TREATMENT

All cases ultimately come to laparotomy. The abdominal cavity often contains excessive amounts of serosanguinous fluid, but is otherwise normal. These findings must direct the surgeon toward the problem. Careful examination of the omentum may reveal torsion or infarction in a portion of the omentum.

The treatment of choice is resection of the involved segment.<sup>24</sup> This is possible even through an appendectomy incision. Of historical significance is the fact that one case of surgical detorsion has been reported without deleterious results.<sup>1</sup>

Spontaneous detorsion is an expected possibility.<sup>14,28</sup> This may be a cause of chronic abdominal pain with obscure origin.<sup>9</sup> According to this phenomenon, nonsurgical treatment has also been proposed.<sup>30</sup>

## CASE REPORTS

### PRIMARY TORSION

#### Case I

A 14 year old boy was admitted to hospital with a history of abdominal pain of one days' duration. The pain started gradually in the lower abdomen which increased in severity and localized in the right lower quadrant 10 hours later. The pain was not associated with nausea, vomiting or anorexia, but was aggravated with motion. There was no history of previous illness or operation. On examination he was a well developed, normal weight and otherwise healthy boy with slight fever (38°C), pulse rate 100/min, respiratory rate 20/min, and blood pressure 100/70. Abdominal examination revealed right-sided voluntary guarding with tenderness and rebound tenderness in the right lower quadrant. Bowel sounds were hypoactive, and there was no abdominal distension. No mass was palpable. The remainder of the physi-

cal examination was unremarkable.

Laboratory tests were WBC 10,600/mm<sup>3</sup>, Hb 11.4g/dL, Hct 36.4%, Plt 331×10<sup>3</sup>/mm<sup>3</sup>, Na<sup>+</sup>= 136 mEq/L, K<sup>+</sup>= 4.0 mEq/L.

The urinalysis was unremarkable.

The patient underwent operation via a McBurney incision with the impression of acute appendicitis. The appendix was grossly normal. On further exploration, a 3×12 cm mass of omental origin was found with loose adhesion to the anterior abdominal wall just above the incision. The adhesion was separated with blunt dissection and the twisted omental segment resected.

The infarcted segment was twisted 3 times in a clockwise direction on a narrow pedicle. Appendectomy was also performed.

#### Case II

A 29 year old man was admitted to hospital with a history of abdominal pain, mainly in the paraumbilical area and right upper quadrant of the abdomen of 36 hours' duration. The pain was aggravated by time. The history was negative for nausea, vomiting or anorexia. He had had no previous operation or illness. On physical exam he had tachycardia, mild fever and right-sided abdominal tenderness and rebound tenderness. The rest of the examination was normal. Laboratory studies showed only leukocytosis (WBC 14,500). The patient was operated on with the impression of acute cholecystitis or appendicitis through a midline abdominal incision. The gallbladder and appendix were grossly normal. A segment of the greater omentum measuring about 9×7×1.5cm was twisted on the base of a narrow pedicle. The segment was gangrenous and removed. The patient had an uneventful hospital course and was discharged on the third postoperative day.

#### Case III

A 10 year old boy was admitted to hospital with a history

## Omental Torsion and Infarction

of paraumbilical and right lower quadrant abdominal pain of four days' duration. The pain was aggravated one day prior to admission. It was not associated with nausea, vomiting or anorexia. On examination, the patient was mildly obese with slight fever (38°C) and a pulse rate of 90/min.

Abdominal examination revealed normal bowel sounds with moderate tenderness and rebound tenderness in the right lower quadrant. The rest of the examination was unremarkable.

12,700/mm<sup>3</sup>, PMN 74%, Lym 25% and Eos 1%.

The patient was operated on with the impression of acute appendicitis via a McBurney incision. A large amount of serosanguinous fluid was evacuated and the omentum was seen to be severely ischemic and attached to the anterior abdominal wall just above the incision. This omental portion was twisted around a very narrow pedicle. The direction of torsion was not clear. A portion of omentum measuring about 4×10 cm was resected (Fig. 1). There was no other abdominal pathology. The appendix was mildly inflamed and appendectomy was performed.

### Case IV

A 45 year old man was admitted due to right paraumbilical abdominal pain. The pain had begun eight hours before admission in the same region and increased gradually. The pain increased in the supine position and was associated with anorexia but not nausea or vomiting. On physical examination he was normothermic and normotensive with mild tachycardia (PR=100). General examination was unremarkable. Abdominal examination revealed normal bowel sounds, but tenderness, rebound tenderness and guarding slightly above the point of McBurney, and an ill-defined mass at the point of maximum tenderness.

Laboratory findings were mild leukocytosis (WBC 10,000/mm<sup>3</sup>), and pyuria (WBC 10-12/hpf). The rest of the examination was normal. The patient was operated on with impression of acute appendicitis through a McBurney incision. Appendix was normal appearing and retrocecal in position. On further exploration an infarcted segment of the omentum measuring about 7×5 cm was found which was twisted several times around its vertical axis. The segment was resected and appendectomy performed.

The patient was discharged on the fourth postoperative day after an uneventful hospital course.

## IDIOPATHIC INFARCTION

### Case V

A 65 year old lady was admitted to hospital with a history of remitting right lower quadrant abdominal pain of two days' duration.

The pain increased in severity and became constant one day later. She had no other gastrointestinal complaints such

as nausea, vomiting, change in bowel habits or anorexia. Her past history was indicative of asthma but was otherwise normal.

On physical examination, vital signs were T= 37.9°C, BP= 130/85, and PR= 96. There was right lower quadrant abdominal tenderness and rebound tenderness associated with voluntary guarding.

The remainder of the examination was unremarkable. Laboratory findings were WBC 7,900/mm<sup>3</sup>, Hb 15.3 g/dL and normal urinalysis. Abdominal x-ray was normal.

The patient was operated on via a McBurney incision. There was a moderate amount of serosanguinous fluid in the abdomen. The appendix was mildly inflamed and removed. A portion of the omentum measuring about 12×4×1 cm was found to be gangrenous and firm without torsion, which was resected. The patient was discharged from the hospital on the fifth postoperative day.

### Case VI

A 70 year old lady was admitted to hospital with a four day history of mild right upper quadrant abdominal pain which had intensified since two days prior to admission. The pain was associated with low grade fever but no other symptoms (such as nausea, vomiting, anorexia or jaundice). The pain was aggravated with motion. She had diet-controlled diabetes mellitus.

There was no previous history of abdominal pain. On physical examination she was mildly obese, T 37.3°C, PR 100/min and BP 135/75 mmHg. There was right upper quadrant tenderness with mild rebound tenderness and a positive Murphy's sign.

Laboratory findings were FBS=90 mg/dL, WBC 11,300/mm<sup>3</sup>, Hb=16 g/dL. The patient was operated on with an impression of acute cholecystitis via a right subcostal incision. Operative findings were an excess amount of serosanguinous fluid and an infarcted segment of omentum measuring about 4×5 cm without torsion.

The gallbladder was normal. The rest of the exploration was unremarkable. The infarcted segment was resected. The patient did well postoperatively and was discharged on the fourth day.

### CASE VII

A 40 year old man was admitted due to right periumbilical abdominal pain. The pain had begun two days before admission and later became generalized. The pain was aggravated in the supine position and associated with anorexia but not nausea or vomiting. He gave a history of blunt abdominal trauma two weeks sooner. The patient was a cigarette smoker and had a left atrophic kidney located in the pelvis. On physical examination vital signs were T= 37.5°C, PR= 80/min, BP= 110/80. General examination except for the abdomen was unremarkable. Abdominal examination revealed generalized abdominal tenderness

and rebound tenderness without guarding. Bowel sounds were present.

Laboratory examinations revealed only mild leukocytosis (WBC 10,500). The patient was operated on for acute abdomen through a low midline incision. Appendix was normal appearing and retrocecal in position and the abdomen contained a significant amount of serosanguinous fluid. The problem was an infarcted portion of the omentum situated distally on the right side without torsion. The involved segment was resected and appendectomy performed.

The patient was discharged on the fifth postoperative day after an uneventful hospital course.

## RESULTS

During four years (1990-1994) we have had these seven presented cases, five of which were male and two female. All cases of primary torsion were male while two of three cases of idiopathic infarction were female.

The mean age in the torsion group (24.5 yrs) was remarkably younger than the infarction group (58.3 yrs).

The most frequent presenting symptom was abdominal pain (paraumbilical or at the right side of the abdomen) and the most common preoperative impression was acute appendicitis.

The duration of symptoms varied from eight hours to four days. A previous history of abdominal pain was not frequent. A history of previous blunt abdominal trauma was obtained in only one case.

Motion in one case and supine position in two others were found to be aggravating factors.

Anorexia was experienced in only one case and nausea and vomiting were totally absent in all patients. Four cases had low grade fever but all cases had mild tachycardia.

Abdominal mass was a physical finding only in one case. All patients, with the exception of one case, had leukocytosis ranging from 10,000-14,500/mm<sup>3</sup>.

In all cases the torsion or the infarction affected only a portion of the greater omentum, not its entirety.

A summary of the clinical data of all cases is shown in Table V.

## REFERENCES

1. Adams JT: Primary torsion of the omentum. *Am J Surg* 126: 102, 1973.
2. Alecce AA, Sullivan SG, Ashworth W: Spontaneous idiopathic segmental infarction of the omentum. *Am Surg* 142: 316, 1955.
3. Anton JJ, Jennings JE, Spiegel MB: Primary omental torsion. *Am J Surg* 68: 303, 1945.
4. Balthazar EJ, Lefkowitz RA: Left-sided omental infarction with associated omental abscess. *Radiology* 17(3): 739-81, 1993.
5. Bernatz PE: Usual conditions simulating acute appendicitis. *Proc Mayo Clin* 31: 53, 1956.
6. Brodribb AJM: Primary idiopathic omental torsion: a report of 2 cases. *Br J Surg* 61: 305, 1974.
7. Brown HJ, Noone RB: Primary omental torsion. *OSMA Jour* 64: 177, 1971.
8. Caron W: Primary torsion of the omentum. *Laval Med* 12: 481, 1964.
9. Choen S, Nambiar R: Primary torsion of the greater omentum. *Surgery* 156(2): 171-2, 1990.
10. Coppo B, et al: Idiopathic segmental infarction of the greater omentum. *J Chir Paris* 128(4): 204-6, 1991.
11. Delaurentis DA, Kim DK, Hartshorn JWS: Idiopathic segmental infarction of the greater omentum. *Arch Surg* 102: 474, 1971.
12. Eberts EM: Case of spontaneous hemorrhage from the great omentum. *Canad MAJ* 10: 461, 1920.
13. Eitel GG: Rare omental torsion. *New York Med Rec* 55: 715, 1899.
14. Eliason EL, Johnson J: Primary acute epiploitis. *Surg* 6: 68, 1939.
15. Epstein LI, Lempke RE: Primary idiopathic segmental infarction of the greater omentum: case report and collective review of the literature. *Ann Surg* 167: 437, 1968.
16. Etherington WE: Torsion of the greater omentum; report of four cases. *Brit J Surg* 33: 142, 1945.
17. Fusco EM: Surgical lesions of the greater omentum. *Virginia M Monthly* 73: 371, 1946.
18. Grover NK, et al: Acute abdomen caused by primary torsion of the greater omentum. *Int Surg* 57: 587, 1972.
19. Giuly J, Francois GF, Gaujoux J, Reynaud B: Idiopathic segmental infarction of the great omentum: value of celioscopy: *Clinique Fallien* 130(1): 1-4, 1993.
20. Harris FI, Diller T, Marcus SA: Hemorrhagic infarction of the greater omentum simulating acute appendicitis: a report of two cases. *Surg* 23: 206, 1948.
21. Hassantash SA: Primary segmental infarction of the greater omentum. *Med J Isl Rep Iran* 6: 67, 1992.
22. Hedayati H, Sconzo FT, Yossundarakul C, et al.: Primary idiopathic segmental infarction of the greater omentum. *Am J Gastroenterol* 55: 168, 1971.
23. Johnson AH: The great omentum and omental thrombosis. *Northwest Med* 31: 285, 1932.
24. Leitner MJ, Jordan CG, Spinner MH, Reese EC: Torsion, infarction and hemorrhage of the omentum as a cause of acute abdominal distress. *Ann Surg* 135: 103, 1952.
25. Mainzer RA, Simoes A: Primary idiopathic torsion of the omentum. *Arch Surg* 88: 974, 1964.
26. Malek F, Riley EJ: Primary torsion and segmental infarction of greater omentum. *Am Surg* 10: 549, 1970.
27. Myllyla V, Leskinen M, Paakko E, Kiviniemi H, Kairaluoma MV: CT appearance of omental torsion. *Diagnostic* 161(6): 559-60, 1994.

## Omental Torsion and Infarction

28. Nihei Z, Kojima K, Uehara K, Sawai S, Kakihana M, Hirayama R, Mishima Y: Omental bleeding with spontaneously derotated torsion. *Surgery* 21(6): 700-2, 1991.
29. Pines B, Rabinovich J: Idiopathic segmental infarction of the greater omentum. *Surg Gynec Obst* 71: 80, 1940.
30. Puyleart JB: Right-sided segmental infarction of the omentum. *Radiol* 185(1): 169-72, 1992.
31. Schnur PL, et al: Segmental infarction of the greater omentum. *Mayo Clin Proc* 47: 451, 1972.
32. Schomberg H: Acute hemorrhagic epiploitis with the picture of acute appendicitis. *Beitr Z Klin Chair* 146: 89, 1929.
33. Totten HP: Primary idiopathic segmental infarction of the greater omentum. *Am J Surg* 56: 676, 1942.
34. Von Klimko D: Torsion of the third omentum. *Arch F Klin Chir* 155: 685, 1929.