



## Review

# Proceedings of the Third International Symposium on Retinopathy of Prematurity: An update on ROP from the lab to the nursery (November 2003, Anaheim, California)

Gerard A. Lutty,<sup>1</sup> Tailoi Chan-Ling,<sup>2</sup> Dale L. Phelps,<sup>3,4</sup> Anthony P. Adamis,<sup>5</sup> Kenneth I. Berns,<sup>6,7</sup> Candy K. Chan,<sup>8</sup> Cynthia H. Cole,<sup>9</sup> Patricia A. D'Amore,<sup>10,11</sup> Arup Das,<sup>12</sup> Wen-Tao Deng,<sup>13</sup> Velma Dobson,<sup>14</sup> John T. Flynn,<sup>15</sup> Martin Friedlander,<sup>16</sup> Anne Fulton,<sup>11,17</sup> William V. Good,<sup>18</sup> Maria B. Grant,<sup>19</sup> Ronald Hansen,<sup>11,17</sup> William W. Hauswirth,<sup>13</sup> Robert J. Hardy,<sup>20</sup> David R. Hinton,<sup>21,22,23</sup> Suzanne Hughes,<sup>2</sup> D. Scott McLeod,<sup>1</sup> Earl A. Palmer,<sup>24</sup> Arnall Patz,<sup>1</sup> John S. Penn,<sup>25</sup> Brian J. Raisler,<sup>26</sup> Michael X. Repka,<sup>1,27</sup> Magali Saint-Geniez,<sup>10,11</sup> Lynn C. Shaw,<sup>19</sup> David T. Shima,<sup>5</sup> Bradley T. Smith,<sup>28</sup> Lois E. H. Smith,<sup>17</sup> Sjakon G. Tahija,<sup>29</sup> William Tasman,<sup>28</sup> Michael T. Trese<sup>30</sup>

<sup>1</sup>Wilmer Ophthalmological Institute and <sup>27</sup>Department of Pediatrics, Johns Hopkins School of Medicine, Baltimore, MD; <sup>2</sup>Department of Anatomy, Institute for Biomedical Research, University of Sydney, Sydney, Australia; Departments of <sup>3</sup>Pediatrics and <sup>4</sup>Ophthalmology, University of Rochester School of Medicine and Dentistry, Rochester, NY; <sup>5</sup>Eyetech Research Center, Lexington, MA; <sup>6</sup>Powell Gene Therapy Center and Departments of <sup>7</sup>Molecular Genetics and Microbiology, <sup>13</sup>Ophthalmology, and <sup>19</sup>Pharmacology and Therapeutics, University of Florida, Gainesville, FL; <sup>8</sup>Department of Surgery, University of California, San Francisco, CA; <sup>9</sup>Department of Neonatology, Beth Israel Deaconess Medical Center, Boston, MA; <sup>10</sup>The Schepens Eye Research Institute, <sup>11</sup>Harvard Medical School, and <sup>17</sup>Department of Ophthalmology, Children's Hospital, Boston, MA; <sup>12</sup>Department of Surgery, University of New Mexico School of Medicine, Albuquerque, NM; <sup>14</sup>Department of Ophthalmology and Vision Science, University of Arizona, Tucson, AZ; <sup>15</sup>Department of Ophthalmology, Columbia University College of Medicine, New York, NY; <sup>16</sup>Department of Cell Biology, The Scripps Research Institute, La Jolla, CA; <sup>18</sup>Smith-Kettlewell Eye Institute, San Francisco, CA; <sup>20</sup>School of Public Health, University of Texas at Houston, Houston, TX; Departments of <sup>21</sup>Pathology, <sup>22</sup>Ophthalmology, and <sup>23</sup>Neurosurgery, Keck School of Medicine, University of Southern California, Los Angeles, CA; <sup>24</sup>Oregon Health & Science University, Casey Eye Institute, Portland, OR; <sup>25</sup>Department of Ophthalmology and Visual Sciences, Vanderbilt University School of Medicine, Nashville, TN; <sup>26</sup>Ocular Angiogenesis Laboratory, University of Kentucky, Lexington, KY; <sup>28</sup>Wills Eye Hospital, Philadelphia, PA; <sup>29</sup>Klinik Mata Nusantara, Jakarta, Indonesia; <sup>30</sup>William Beaumont Hospital, Eye Research Institute, Oakland University, Rochester, MI

The Third International Symposium on Retinopathy of Prematurity (ROP) was convened with the aim of cross fertilizing the horizons of basic and clinical scientists with an interest in the pathogenesis and management of infants with ROP. Ten speakers in the clinical sciences and ten speakers in the basic sciences were recruited on the basis of their research to provide state of the art talks. The meeting was held November 9, 2003 immediately prior to the American Academy of Ophthalmology meeting; scholarships were provided for outreach to developing countries and young investigators. This review contains the summaries of the 20 platform presentations prepared by the authors and the abstracts of presented posters. Each author was asked to encapsulate the current state of understanding, identify areas of controversy, and make recommendations for future research. The basic science presentations included insights into the development of the human retinal vasculature, animal models for ROP, growth factors that affect normal development and ROP, and promising new therapeutic approaches to treating ROP like VEGF targeting, inhibition of proteases, stem cells, ribozymes to silence genes, and gene therapy to deliver antiangiogenic agents. The clinical presentations included new insights into oxygen management, updates on the CRYO-ROP and ETROP studies, visual function in childhood following ROP, the neural retina in ROP, screening for ROP, management of stage 3 and 4 ROP, ROP in the third world, and the complications of ROP in adult life. The meeting resulted in a penetrating exchange between clinicians and basic scientists, which provided great insights for conference attendees. The effect of preterm delivery on the normal cross-talk of neuroretinal and retinal vascular development is a fertile ground for discovering new understanding of the processes involved both in normal development and in retinal neovascular disorders. The meeting also suggested promising potential therapeutic interventions on the horizon for ROP.

---

Correspondence to: Gerard A. Lutty, Wilmer Ophthalmological Institute, 170 Woods Research Building, Johns Hopkins Hospital, 600 North Wolfe Street, Baltimore, MD, 21287; Phone: (410) 955-6750; FAX: (410) 955-3447; email: [glutty@jhmi.edu](mailto:glutty@jhmi.edu)

## INTRODUCTION

### Contributors: Tailoi Chan-Ling, Gerard Lutty, Dale Phelps

It only takes a spark to get the fire going and soon all those around can warm up in its glowing. That is how it was with this meeting, it started with the simple idea that there

exists a need to bring together many of the foremost clinical and experimental experts in Retinopathy of Prematurity (ROP) to review and discuss the research frontiers in this field. We wanted to create an opportunity where clinicians who are faced with the day to day care of these infants, could enlighten the scientists about the disease process and highlight unresolved questions. We also hoped that basic bench scientists could update the clinicians on the current understanding of the processes by which retinal vessels form, during normal development and in neovascularization, and to elucidate the latest therapies that are on the horizon.

We discussed this vision with Dr. Arnall Patz and his encouragement to take this idea forward gave us the courage to make this idea a reality. Dr. Patz took on the role of Honorary Chair of our Organizing Committee facilitating the smooth running of every aspect of this meeting with his gentle guiding hand. Drs. John Flynn, Earl Palmer, Bill Tasman and Jan McCole added further energy to our organizing committee. However, any scientific meeting is only a success if the scientific program is outstanding. We are indebted to our distinguished faculty who accepted our invitation with enthusiasm and delivered superb elucidation of their assigned topics. Discussion during the oral and poster sessions was animated, candid and penetrating, resulting in the exchange between clinicians and basic scientists we had hoped for when planning this meeting.

The publication of the proceedings from the symposium will enable our colleagues who were not able to attend the symposium to benefit from the insights gained at this meeting. The one day symposium consisted of two basic science sessions and two clinical science sessions. Each speaker has provided a short summary of their presentation. The session co-chairs have provided a capstone/commentary at the beginning of each of the four sessions highlighting the importance of different topic areas, identified areas of controversy, and have made specific recommendations for future research. The abstracts from the poster presentations are included in Appendix 1. We wish to thank all the participants of "The 3<sup>rd</sup> International Symposium on Retinopathy of Prematurity: An update on ROP from the Lab to the Nursery" who made this possible.

#### SESSION 1A: EVOLVING BASIC SCIENCE

##### **Contributors: Tailoi Chan-Ling, Maria Grant**

While we have made significant progress in our understanding of the mechanisms and molecular cues underlying formation of retinal blood vessels via angiogenesis, the cellular and molecular cues driving formation of the primordial vessels via vasculogenesis requires further elucidation (Session 1B). The large animal models of kitten and dog mimic closely the dual role of vasculogenesis and angiogenesis. These models are similar to what is observed in the formation of human retinal vasculature and closely mimic the cellular and vascular changes observed in acute human ROP. The costs of these larger animal models, the difficulty of access, and the lack of species-specific antibodies make them less desirable to use than rodent models (Session 1C).

Mouse models have the additional benefit of transgenic and knockouts. The mouse and rat models of oxygen-induced retinopathy (OIR) demonstrate preretinal neovascularization and have been a major advance to the field. However, there exists significant strain variability in the angiogenic response and care must be observed in the selection of genetic background when conducting studies on the angiogenic response in rodents (Session 1D). Further, it appears from rodent models that the ratio of vascular endothelial growth factor (VEGF)/pigment epithelial derived growth factor (PEDF) determines OIR susceptibility. This ratio could potentially become a useful measure if studies substantiate that this ratio applies across all the retinopathies and species.

Recent studies from D'Amore's lab (Session 1E) have shown that pericytes and astrocytes express VEGF, that VEGF expression by pericytes is maintained in adulthood, and that it plays a role in endothelial signalling (Session 1E). The complex role played by various isoforms of VEGF is beginning to be unravelled. The most effective intervention for ROP should minimize the vaso-obliteration/delayed vascularization typified by phase I of ROP and promote vasculogenesis. Increasing ocular levels of PlGF-1, which specifically activates vascular endothelial growth factor receptors 1 (VEGFR-1), has been shown to protect against vaso-obliteration in the mouse OIR model (Session 1F). Increasing serum insulin-like growth factor 1 (IGF-1) levels towards those observed in utero may also represent a novel approach to promoting normal vasculogenesis. However, as pointed out by Smith (Session 1F), even if proven effective, the timing of IGF-1 administration will require careful determination, as incorrectly-timed administration could result in a worsening of outcome.

#### SESSION 1B: CELL-CELL INTERACTIONS IN THE FORMATION OF THE HUMAN RETINAL VASCULATURE

##### **Contributors: Tailoi Chan-Ling, Suzanne Hughes**

The retina is an extension of the central nervous system. As such, it consists of 3 main cellular elements: the neurons, macroglia (including astrocytes and Müller cells), and the vasculature (including vascular endothelial cells, pericytes, and smooth muscle cells). Immune and phagocytic cells including retinal microglia, macrophages, and perivascular cells complete the cellular milieu. During the formation of the human retinal vasculature, these cellular elements interact in complex ways resulting in the formation and then the remodeling of the vasculature to produce a vascular tree that is well matched to the metabolic needs of the tissue.

Vessels can be formed by two mechanisms, either vasculogenesis in which vessels are formed from vascular precursor cells (VPCs) that differentiate and aggregate to form primitive endothelial tubes or by angiogenesis in which vessels are formed via budding from existing vessels. Formation of the human retinal vasculature involves both of these processes.

The first event in human retinal vascularization, apparent before 12 weeks gestation (WG), is the migration of large numbers of ADPase<sup>+</sup>/Nissl stained VPCs from the optic disc [1].

These VPCs are also CD39<sup>+</sup> (ecto-ADPase) and vascular endothelial growth factor receptor 2 (VEGFR-2) positive [1]. They proliferate and differentiate to form a primordial vascular bed centered on the optic disc. Thus, vasculogenesis is responsible for the formation of the primordial vessels of the inner (superficial) plexus in the central human retina. Angiogenesis is responsible for formation of the remaining retinal vessels, including increasing vascular density in the central retina, vessel formation in the peripheral retina of the inner plexus, and the formation of the outer (deep) plexus and the radial peri-papillary capillaries [2]. The fact that the human retinal vasculature is formed via two distinct mechanisms has important implications for the understanding of neovascularization of the human retina.

Formation of the outer plexus begins around the incipient fovea between 25 and 26 WG [2], coincident with the peak period of eye opening and the first appearance of the visually evoked potential, indicative of a functional visual pathway and photoreceptor activity [3]. The timing and topography of angiogenesis in the human retina supports the “physiological hypoxia” model of retinal vascular formation, in which angiogenesis is induced by a transient but physiological level of hypoxia as a result of the increased metabolic activity of retinal neurons as they differentiate and become functional [4-6]. This tissue hypoxia results in upregulation of hypoxia-inducible factor (HIF) 1, resulting in the upregulation of VEGF<sub>165</sub> expression [7], by both astrocytes in the inner retina and Müller cells in the outer retina [8]. The new blood vessels bring oxygen and other metabolic requirements, leading to downregulation of VEGF<sub>165</sub> by neuroglia.

In contrast, formation of retinal vessels via vasculogenesis appears independent of metabolic demand and hypoxia-induced VEGF<sub>165</sub> expression [2]. Evidence for this conclusion includes three observations. (1) Substantial vascularization in the human retina occurs prior to detection of VEGF<sub>165</sub> mRNA. At 18 WG, the inner plexus covers approximately 54% of the retinal area, however, VEGF<sub>165</sub> mRNA was not detected in the human retina by *in situ* hybridization until 20 WG [9]. (2) Vasculogenesis is well established by 14 to 15 WG, before the differentiation of most retinal neurons [10]. (3) The topography of formation of the primordial vessels by vasculogenesis is centered around the optic disc whereas neuronal maturation is centered around the fovea. The existence of a second pathway with distinct inhibitory and stimulatory signals could provide alternative pathways for intervention.

In the human fetal retina, Pax-2 expression is restricted to cells of the astrocytic lineage [11]. Pax-2 is a member of the Pax family of transcription factors. Each member of the Pax family is expressed in a spatially and temporally restricted manner, which suggests that these proteins contribute to the control of tissue morphogenesis and pattern formation. Pax-2+/GFAP- astrocyte precursor cells (APCs) are first evident at the optic nerve head at 12 WG, preceding the appearance of Pax-2+/GFAP+ astrocytes. These immature astrocytes are seen immediately peripheral to the leading edge of vessel formation (approximately 20-40  $\mu$ m) and at 18 WG loosely ensheath the newly formed vessels. With maturation, Pax2+/GFAP+

astrocytes extend towards the periphery, reaching the edge of the retina around 26 WG [11]. The positioning of the astrocytes and APCs just ahead of the leading edge of vessel formation places them in an ideal position to mediate the angiogenic response to “physiological hypoxia”, via upregulation of VEGF<sub>165</sub> expression [9]. Earlier workers [12-14] have suggested that the spindle shaped, presumed mesenchymal precursor cells were in fact APCs and not vascular precursors. Our results show that APCs and VPCs differ in their timing, topography, and antigenic expression. They thus represent two distinct populations, supporting the conclusion that formation of the primordial human retinal vasculature takes place via vasculogenesis.

Retinal vessels have blood-retinal barrier (BRB) properties as soon as they become patent. Astrocytes have been shown to be responsible for inducing the blood-brain barrier properties in vascular endothelial cells [15] and thus are thought to induce the blood-retinal barrier in the inner plexus. The processes of the Müller cells (the radial glia of the retina) ensheath the vessels of the outer plexus and are also capable of induction of the BRB [16].

During normal human retinal vascularization, significant overproduction of vascular segments occurs and the excess segments regress with maturation of the vasculature. Our earlier work has shown that endothelial cell apoptosis and macrophages do not initiate vessel retraction, but rather contribute to the removal of excess vascular endothelial cells throughout the immature retinal vasculature. Further, our observations suggest that vessel retraction is mediated by endothelial cell migration and that endothelial cells derived from retracting vascular segments are re-deployed in the formation of new vessels [17]. Mural cells (pericytes and smooth muscle cells) are an intrinsic part of blood vessel walls with broad functional activities including blood flow regulation and have been implicated in vessel stabilization [18]. These cells are derived from a mural precursor cell which gives rise to pericytes on capillaries and smooth muscle cells on larger vessels [19]. Immature mural cells, the ensheathing mural precursor cells, in cats, rats and mice, envelop newly formed vessels and have recently been shown to express VEGF<sub>165</sub> [20]. The presence of these immature mural cells does not prevent vessel regression during normal development [19] and hyperoxia-induced vessel regression [21]. As mature vasculatures with mature mural cells are considered stable, this suggests that mural cell maturation may be necessary for resistance to VEGF<sub>165</sub> withdrawal-induced vessel regression. Macrophages are also part of the cellular milieu during formation of retinal vessels [22]. Although their function is unclear they are capable of expressing VEGF<sub>165</sub> in the mouse model of hyperoxia-induced retinopathy [23] and in age-related macular degeneration [24].

The endothelium in turn influences the development of astrocytes and mural cells. Retinal endothelial cells express PDGFB which induces recruitment and proliferation of mural cells [25]. It has also been shown that vascular endothelial cells can induce astrocyte differentiation [26,27]. In addition, contact between mesenchymal precursor cells and vascular endothelial cells leads to mural cell differentiation *in vitro* [28].

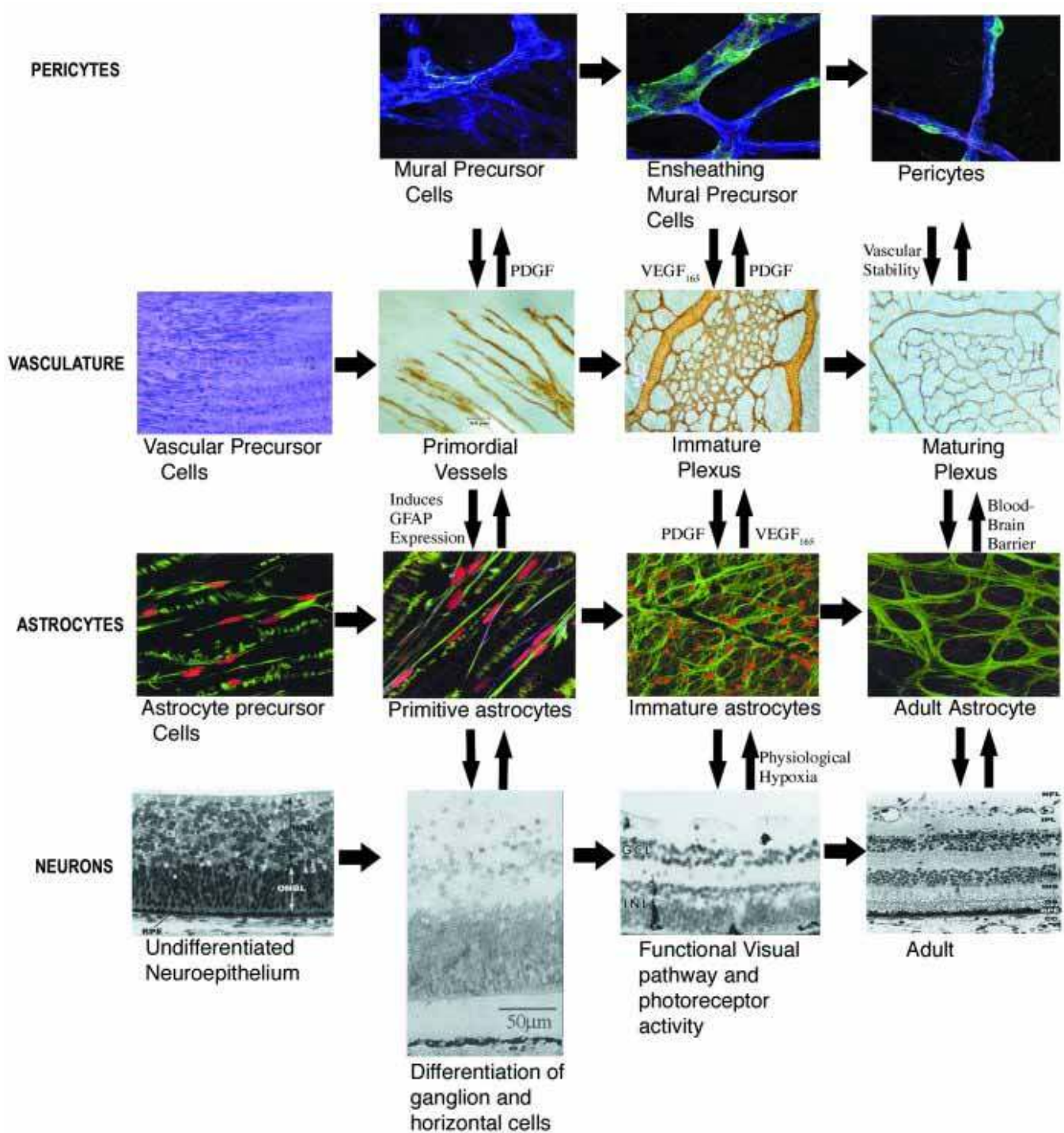


Figure 1. Cell-cell interactions in developing retina. Schematic representation of the complex cell-cell interactions during formation of human retinal vasculature showing how neurons, astrocytes, and pericytes all play a role in influencing the formation of blood vessels. For each class of cells and the vasculature, maturation along the differentiation pathway is shown from left to right. The proposed molecular intercellular signals where known are shown with their functional interactions. All data shown are from human retina with the exception of pericytes which are from rat retina.

Taken together, these studies show that the formation and maturation of the human retinal vasculature is (1) concurrent with neuronal, astrocyte and mural cell differentiation and maturation, as represented schematically in Figure 1, and (2) the result of complex cellular interactions in which the vasculature both takes its developmental cues from, and also influences its cellular environment. During normal development, the retinal vasculature is remodeled resulting in a vascular pattern that is well matched to the metabolic demands of the tissue. Thus, the overriding drive of the retina, to meet its ever changing metabolic needs, results in the reactivation of angiogenic signals, where vascular perfusion has been compromised resulting in retinal neovascularization.

#### SESSION 1C: LARGE ANIMAL MODELS OF ROP

##### Contributors: Gerard Luty, D. Scott McLeod

Two large laboratory animals have been used for experimental models of ROP, the cat and dog. In both species, the neonatal animals were exposed to high oxygen for short periods, modeling the vaso-obliterative stage of ROP. When the animals are returned to room air, the retinas are hypoxic and angiogenesis occurs.

*Cat model:* The cat was used first by Norman Ashton et al. [28] in 1954. He evaluated the effects of different levels of oxygen and duration of exposure and found that the longer the exposure and the greater the concentration of oxygen, the more severe the retinopathy. Arnall Patz at first used the cat model that Ashton had developed as he explored the effects of hyperoxia on the developing retinal vasculature in several species [29]. He later, in collaboration with Robert Flower, was able to view the effects of hyperoxia on the cat retinal vasculature in situ [30,31]. Dale Phelps also used the cat model in her pioneering studies on the effects of vitamin E on the oxygen induced vaso-obliteration [32] and later in her studies of oxygen withdrawal protocols which led to the STOP-ROP clinical trial [33]. More recently, Tailoi Chan-Ling et al. [6] have utilized the kitten model to elucidate the vascular and cellular changes that underlie the various stages of the human disease [6,8,34-36] and have also used the cat model to demonstrate the concept of "physiological hypoxia," which Patz [37] and Ashton [28] had hypothesized earlier from their experimental studies of ROP in cat.

Phelps and Chan-Ling expose 0- to 3-day-old kittens to 80% oxygen for 80-96 h [33,34]. This results in obliteration of more than 80% of the retinal vasculature. The longer the exposure to this concentration of oxygen, the more severe the vaso-obliteration and vasoproliferation will be [38] and by 10 days after return to room air, significant preretinal vascular membranes are evident [34]. Tailoi Chan-Ling has demonstrated astrocyte death during the hypoxia after reintroduction to room air and that recovery of the blood-retinal barrier in the kitten model of ROP is coincident with ensheathment of the retinal blood vessels by astrocytes [35]. The reforming, retinal vasculature was described by Chan-Ling et al. [34] as a rosette-like vasculature and she demonstrated that it leaked profusely using horse radish peroxidase as a vascular tracer. By day 14, tufts of neovascularization appear throughout the

fundus and large networks can exist around or near the optic nerve head. Ashton demonstrated that the small tufts were glomeruloid-like neovascular formations, which appeared similar to angioblastic masses with few canalized lumens [28]. These tufts are called "popcorn" formations by some clinicians. Eventually the neovascularization matures and spreads through vitreous across the surface of the retina. The Phelps and Chan-Ling labs have both demonstrated that VEGF upregulation is associated with the vasoproliferative phase of OIR in the cat [38,39]. Importantly, Chan-Ling et al. [36] have shown that it is possible with supplemental oxygen to revascularize a kitten retina with minimal astrocyte degeneration and breakdown of the blood retinal barrier. This results in a vascular tree showing lobular topography and morphology seen during normal development, lending support to the importance of tight oxygen administration to produce optimized vascular formation.

*The dog model:* The canine model of OIR was first used by Arnall Patz in 1954 [40]. Robert Flower used this model in the 1970s and investigated the effects of prostaglandin inhibitors on severity of retinopathy [41]. Scott McLeod and I have carefully documented each stage in the disease process more recently using adenosine diphosphatase (ADPase) enzyme histochemistry and used the model to evaluate antiangiogenic therapies.

One reason that we prefer this model is that the initial retinal blood vessel assemblage in the neonatal dog occurs primarily by a process of vasculogenesis [42,43], a term referring to de novo formation of vasculature from mesenchymal precursors or angioblasts. We have recently described this same process using ADPase enzyme histochemistry in the fetal human retina (Session 1B). During development, the inner Müller cell processes form a network of interconnecting extracellular spaces, which furnish a scaffold for angioblast attachment and organization during blood vessel assemblage and provide unimpeded growth anteriorly [43]. In the dog, astrocyte migration, as assessed with glial fibrillary acidic protein (GFAP) immunolabeling, lags behind formation of the primary retinal blood vessels [44]; while in cat [45], GFAP<sup>+</sup> astrocytes precede the formation of a patent vasculature by a small margin.

Sustained breathing of 100% oxygen for four days produces a progressive constriction of the developing retinal vasculature that eventually results in vaso-obliteration, or the irreversible closure of many capillary channels and subsequent death of capillaries from optic nerve head to the edge of the forming vasculature. In cross sections, pericytes can be seen on collagenous tubes, suggesting they survive hyperoxia while endothelial cells die. The end product of vaso-obliteration in the neonatal dog model of ROP is a 77% reduction in capillary density and a 60% decrease in luminal diameter of remaining viable retinal capillaries (Figure 2A,B). There are often surviving islands of ADPase positive endothelial cells. In contrast, the choriocapillaris appears unaffected morphologically by prolonged oxygen breathing [46].

In the dog, revascularization following hyperoxic insult involves a period of marked vasoproliferation that peaks some-

where between three to ten days after return to room air [44]. In addition to the marked increase in endothelial cell proliferation, there is proliferation of perivascular cells, presumably astrocytes. Hyperoxic insult, followed by return to room air, not only stimulates a marked increase in proliferation of vasoformative cells and apparent accessory glia, but also results in a loss of extracellular spaces, which were prevalent in the inner retina during the course of normal development. The diminution of spaces in the peripheral avascular retina after return to room air and the occupancy of these spaces by cells not normally found in advance of forming blood vessels is likely to impede vascular growth anteriorly. As many as six layers of capillaries form in the nerve fiber layer during the vasoproliferative stage. Marked vasoproliferation in the abnormal confines of this congested perivascular milieu probably contributes to the prolific capillary overgrowth at the anterior edge of reforming vasculature and to the invasion of vessels into the vitreous cavity. The initial formations are immature, angioblastic masses with very few formed lumens, similar to what Ashton observed in the cat [47]. When these formations mature, they develop a 1:1 ratio of endothelial cells:pericytes in these blood vessels [47]. Enzyme histochemistry demonstrated high alpha glycerophosphate dehydroge-

nase activity, a marker for angioblasts and immature endothelial cells, in poorly differentiated neovascular formations and low activity in formations with mature pericytes and endothelial cells.

Fifteen days after exposure to hyperoxia, fluorescein angiography and fundusoscopic examination can be performed on the dogs. From this time in the disease process, ADPase flat-embedded retinas demonstrate dilated and tortuous retinal vessels, pigmentary changes, incomplete vascularization of peripheral retina, vitreous hemorrhage, and large intravitreal neovascular formations (Figure 2C,D) [48]. The small neovascular formations seem to fuse with time, and this syncytium creates large mats of neovascularization that often follows the vascular arcades (Figure 2E,F). Full thickness eyewall sections at 22 days and later demonstrated tractional retinal folds, tented intravitreal vascularized membranes and vitreous synchysis. GFAP immunohistochemical analysis revealed inner retinal astrogliosis at the edge of the reforming vasculature. End stage OIR in the neonatal dog shares many features with the chronic human disease. The tented membranes and tractional retinal folds persist at least until 45 days of age, the longest time we have to date.

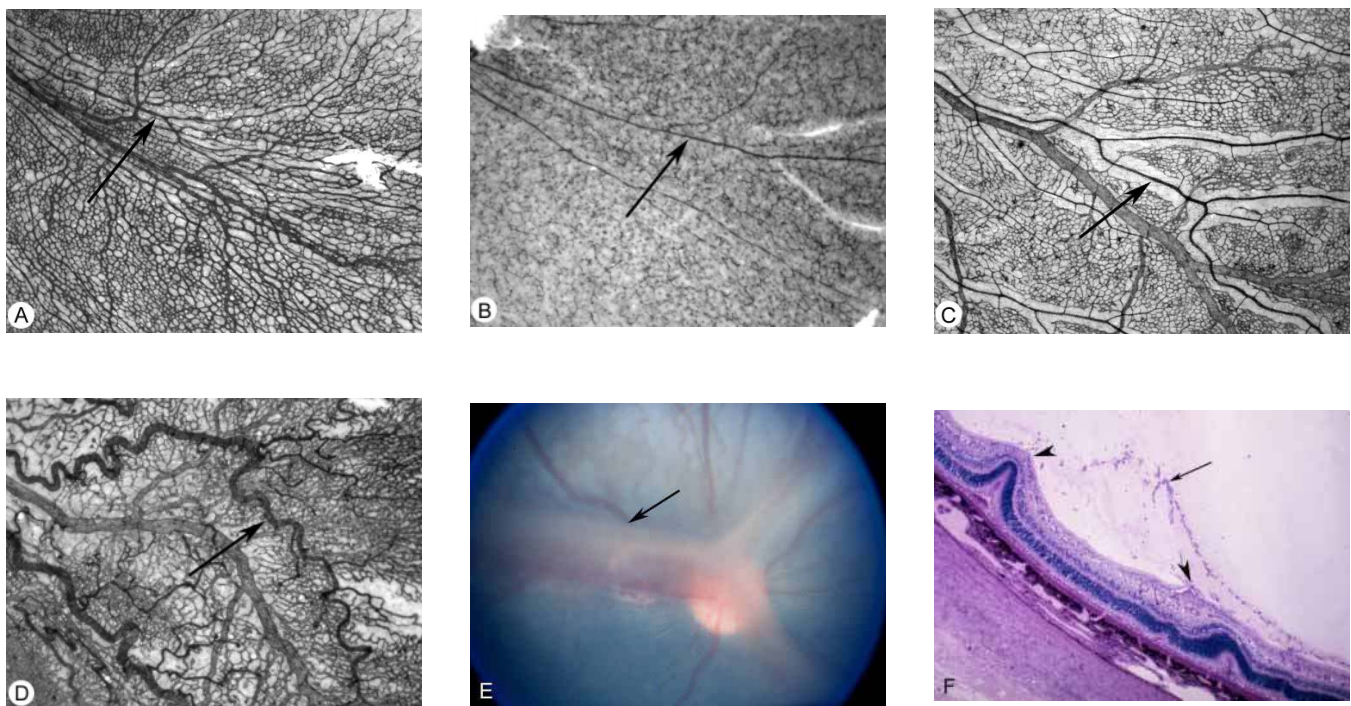


Figure 2. Canine model of oxygen-induced retinopathy. **A:** ADPase whole mount showing the temporal arcade of a 5-day-old normal air control dog (the arrow indicates an artery). Note the density and chicken wire mesh appearance of the developing capillaries. **B:** ADPase whole mount showing the temporal arcade of a 5-day-old dog sacrificed after 4 days of 100% oxygen exposure (the arrow indicates an artery). Note the obliteration of the capillaries and the extreme constriction of the major vessels. **C:** ADPase whole mount showing the temporal arcade of a 21-day-old normal air control dog (the arrow indicates an artery). Capillary-free zones have formed along the arteries and remodelling of the capillary bed has occurred. The secondary capillary bed has also formed. **D:** ADPase whole mount showing the temporal arcade of a 21-day-old oxygen-treated dog after return to room air for 16 days. The arteries are extremely tortuous (arrow) and an overgrowth of the capillaries is apparent. **E:** Fundus photograph of a 45-day-old oxygen-treated dog. Preretinal membranes extend along the major arcades and over the optic nerve head (arrow). **F:** Histological section from the animal shown in Panel E, shows tractional retinal folds (arrowheads) associated with the preretinal membrane (arrow).

In both cat and dog, VEGF has been implicated as a stimulus for the angiogenic process when the animals are returned to room air and the retina is hypoxic. We have also demonstrated a close association between adenosine, the development of the retinal vasculature, and the angiogenic process in the dog OIR model [49]. Adenosine A2a receptors are associated with angioblasts and endothelial cells in intraretinal and intravitreal neovascularization [44]. The source of the adenosine appears to be the enzyme 5' nucleotidase in the inner Müller cell processes [50].

The usefulness of the canine model is exemplified in a study that examined the effects of neutralizing KDR (VEGF receptor 2) on vasculogenesis and angiogenesis in OIR [51]. The binding of a humanized chimeric neutralizing antibody in dog retina and choroid was done with immunohistochemistry. KDR immunoreactivity was only weakly associated with developing retinal vessels and not observed in angioblasts throughout normal postnatal development. Immunoreactivity was very strong in reforming retinal vessels and intravitreal neovascularization in oxygen-treated animals. To examine the effects of blocking KDR, 6-day-old air control and oxygen-treated animals were surgically implanted with Elvax pellets containing control IgG or anti-KDR. Anti-KDR had no effect on vessel morphology or growth in air control animals at 22 days of age using ADPase histochemistry. In oxygen-treated animals, anti-KDR significantly inhibited revascularization of the retina and formation of intravitreal neovascularization compared to control IgG pellet eyes. Therefore, blocking KDR affected proliferation of endothelial cells in the formation of intravitreal neovascularization and revascularization of retina in OIR but did not have an effect on normal development of the primary retinal vessels, which occurs by vasculogenesis and not by proliferation of endothelial cells. The study suggests that blocking KDR might be beneficial for treating pathologic angiogenesis in adult tissue but caution must be used in preventing revascularization of the retina in OIR.

**Benefits of large animal models of ROP:** Both the dog and cat models of OIR have robust neovascularization with pathological features similar to human ROP. The neovascularization is prolonged in both species lasting at least 45 days in dog and longer in cat. The dog neovascular formations are not only long lived but also eventually cause tractional retinal folds in retina like human ROP. The vitreous cavity in both species is large enough that bioerodable polymers with antiangiogenic agents could be evaluated. Therefore, these models can be used for preclinical evaluation of therapeutic antiangiogenic agents. The optimal therapy probably should target only preretinal neovascularization.

**Question by John Flynn:** Why is cat and dog oxygen-induced retinopathy so severe compared to rodents?

**Response:** The vaso-obliviation is more severe in the large animals, so perhaps that results in greater neovascularization, which persists longer. The dog has some very mature neovascular formations (1:1 ratio of pericytes to endothelial cells) that may contribute to the longevity. Alternatively, there may be a balance of angiogenic and antiangiogenic factors in

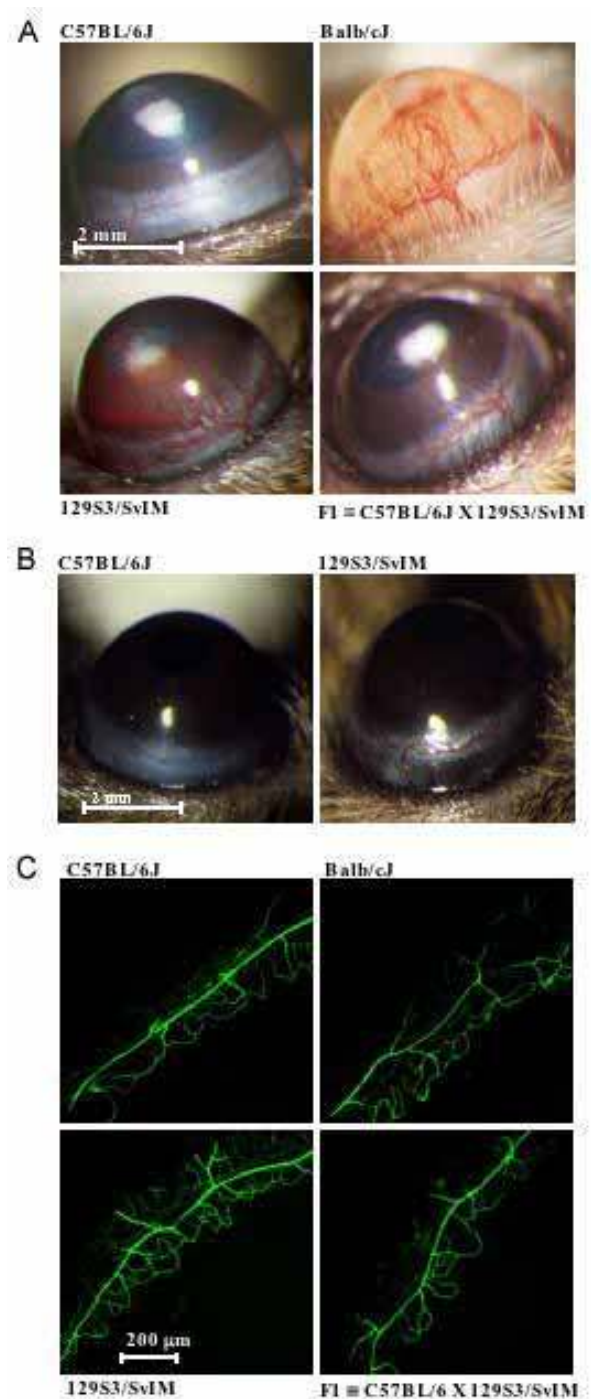


Figure 3. Strain-dependent corneal angiogenesis. **A:** Corneas were photographed 7 days after implantation of a hydron polymer pellet containing 75 ng of basic fibroblast growth factor (bFGF) into a central corneal micropocket. **B:** Resting limbal vasculature was strain dependent. Photographs of the limbal vessels were taken in normal, unoperated, adult eyes. **C:** Limbal vessel density differences between mouse strains were further evaluated by fluorescence microscopy after labeling with endothelial-specific fluorescein conjugated *Griffonia simplicifolia* lectin. Republished with permission of The Association for Research in Vision & Ophthalmology from Chan CK, Pham LN, Chinn C, Spee C, Ryan SJ, Akhurst RJ, Hinton DR. Mouse strain-dependent heterogeneity of resting limbal vasculature. *Invest Ophthalmol Vis Sci* 2004; 45:441-7.

the rodents that favors regression of NV not persistence or maintenance of the neovascular formations.

#### SESSION 1D: GENOMIC VARIATION AND SUSCEPTIBILITY IN RODENT MODELS OF OXYGEN-INDUCED RETINOPATHY

**Contributors: John Penn, Candy K. Chan, David R. Hinton**

From their use in the very first investigations of the pathogenesis of the condition, rodent models have remained the mainstay of ROP research. They were integral to the studies of Patz [52], Ashton [28], and Gyllenstein and Hellstrom [53] who first defined the correlation between oxygen therapy and ROP pathology, and they continue to play important roles in the current studies that further refine our thinking. Widely used rat and mouse models of ROP have been developed [54,55], and each has its clear advantages. We will leave it to the reader to examine the published methods by which the animals are induced to produce ROP-like pathology and techniques with which the pathology is measured. Briefly, the critical pathologic feature of the widely adopted rodent models of Penn and Smith [54,55] is preretinal neovascularization (NV). The preretinal vessels are stained and quantified in transverse retinal sections or in whole-mount retinal preparations. In animal models, the term OIR is most often used to distinguish the condition from human ROP. This general approach was used in most of the studies described below.

In addition to their important role in ROP research, rat and mouse models of OIR have been employed by investigators in other disciplines to define the molecular and cellular basis of angiogenesis for application to tumor growth, non-ocular diabetic complications, wound healing, and heart disease, among others. In addition, rodent models of OIR are the cornerstones of pre-clinical efficacy trials for angiostatic agents under development for any number of ocular and non-ocular conditions. The prominent role of rodents in these endeavors relies on a number of beneficial features of OIR models including: rodents have relatively large litter sizes, they are inexpensive to purchase and maintain, the models have been extensively characterized, and they have proven reliable in producing NV under appropriate conditions.

Another advantageous feature of rodents lies in the ease of defining and comparing genetic differences among various inbred strains or differences between isolated colonies of the same strain. Segregation of genomic content yields rodents with different gene expression profiles and different susceptibilities to disease. This allows for the identification of gene products that influence angiogenesis susceptibility, providing candidate therapeutic targets. The rationale of the target can be confirmed by further manipulating gene expression using transgenic technology, a process that is particularly facile in mice.

This experimental strategy was foreshadowed by a few anecdotal findings. The first of these (Penn, unpublished observations) was not a comparison of strains, per se, but was a comparison of the pathologic response of one rat strain obtained from four different vendors. Pregnant Sprague-Dawley

rats were obtained from Charles River, Hilltop, Harlan, and Zivic. The litters were exposed to the 50/10% variable oxygen paradigm developed by Penn et al. [56]. This exercise yielded a greater than two fold difference in susceptibility to retinopathy as measured by the area of retinal NV. Charles River rats produced 3.0 mm<sup>2</sup> NV area, while rats obtained from Zivic produced only 1.2 mm<sup>2</sup>. Rats from the other two suppliers yielded intermediate levels of pathology. At the time, we postulated that a genomic drift in these isolated and inbred colonies of rats had produced this difference in susceptibility.

In 2002, Holmes et al. [57] conducted a similar experiment. Their results supported the difference in susceptibility to OIR of rats from two different vendors, in this case Charles River and Harlan. However, the difference did not hold for retinopathy produced by metabolic acidosis [58]. The data showed a 62% increase in the susceptibility of Charles River over that of Harlan-bred animals in the induction of NV by oxygen. Their induction of NV by metabolic acidosis yielded a statistically insignificant difference of only 14%. This suggests that the OIR susceptibility differences between strains are potentially dependent on the mechanism by which the angiogenesis is initiated, further implying that upstream events in the angiogenesis cascade warrant special attention.

The most systematic comparison of strains to date comes from D'Amato et al. [59]. The authors used the corneal micro-pocket assay to evaluate the growth of blood vessels from the limbal area into the normally avascular cornea under the influence of basic fibroblast growth factor (bFGF), an angiogenic protein. D'Amato compared 25 strains of mice for susceptibility to corneal NV. When 80 ng of bFGF was implanted in the corneal pocket, C57BL/6J mice fell near the middle of the susceptibility profile, while 129/SvImJ strains were significantly more susceptible and other strains were less than half as susceptible. Evaluation of F1 and F2 hybrid animals, created by crossing strains of low and high angiogenic potential, suggested that angiogenic potential is genetically determined and that multiple genes are involved. When the corneal pocket assay was modified, using VEGF as the angiogenic agent instead of bFGF, they found that variability in VEGF responsiveness also varied among mouse strains and that it correlated with results found for bFGF [60]. Subsequently, D'Amato et al. [59-61] mapped quantitative trait loci (QTL) associated with bFGF and VEGF responsiveness in recombinant inbred mouse strains and found that these regions contain a number of genes known to be involved in angiogenesis [60,61]. It is hoped that further work evaluating these genetic regions will identify functional polymorphisms in genes contributing to the angiogenic response.

Recently, Chan et al. [62] similarly reported that there was a wide range in bFGF-induced angiogenic responses among inbred mouse strains using the corneal micropocket assay (Figure 3). They considered the possibility that these responses may, in part, be due to differences in the resting limbic vasculature from which the angiogenic corneal vessels are derived. Interestingly, they found that there was a similar wide range in resting limbic vessel vascular density suggest-



ing the possibility that genetic factors controlling the development of the limbic vasculature may also play a role in their angiogenic response (Figure 3) [62].

In 2002, Ma [63] conducted an experiment comparing Brown Norway and Sprague-Dawley rat strains using a constant oxygen exposure paradigm like that developed by Smith et al. [55] for mice. The avascular area at the time of removal of the rats from oxygen was eight fold greater in the more susceptible Brown Norway rats than in the Sprague-Dawley rats. This avascular retina provides the impetus for subsequent NV. Consequently, after the post-exposure room air period, the Brown Norway rats exhibited a three fold greater degree of NV. Ma extended the study to look at retinal factors that had the potential to produce this difference in susceptibility. He focused on VEGF and PEDF, calculating ratios of the retinal levels of these two factors at various times during the after exposure period for the two strains of rats. VEGF, an endogenous endothelial cell-specific mitogen, is widely recognized as the driving force behind retinal NV in ROP, while PEDF is the most potent endogenous inhibitor of angiogenesis identified to date. Ma's findings are best summarized by focusing on the P16 time (4 days post-exposure to hyperoxia). Here, the ratio of VEGF to PEDF was ten fold greater in the more susceptible Brown Norway rats, a circumstance that would presumably be permissible for NV.

Recently, Berkowitz et al. confirmed the work of Ma, demonstrating that Sprague-Dawley and Brown Norway rats differed significantly in their susceptibilities to constant OIR, with the latter strain showing a seven fold greater degree of NV (Berkowitz, personal communication to John Penn). In addition, Berkowitz employed variable oxygen exposures and these treatments, surprisingly, yielded no difference in susceptibility. The VEGF to PEDF ratios were not measured, but based upon Ma's work, correlation of this ratio to OIR susceptibility in these sets of conditions is warranted.

Hinton's group has presented preliminary data evaluating mouse strain-related differences in susceptibility to OIR [64]. They found that both preretinal and intraretinal NV varied among inbred mouse strains with 129S3/SvIM mice showing significantly more NV than the C57BL/6J strain. They are currently using this model to evaluate the level of mRNA and protein expression for several pro-angiogenic and anti-angiogenic genes at various times in both of these strains. Preliminary results suggest that the ratio of VEGF/PEDF is higher in the more angiogenic 129S3/SvIM strain.

Collectively, these studies present an intriguing mix of findings. Particularly interesting is the tight correlation between the VEGF to PEDF ratio and OIR susceptibility. The work of Ma and Hinton points to a prominent role for these factors and emphasizes the need to assay them in the combinations of treatment or strain (vendor comparison, metabolic acidosis compared to OIR comparison and variable compared to constant OIR comparison) used by other investigators. Certainly other factors besides VEGF and PEDF participate in the regulation of ROP angiogenesis, but if these various sets of experimental conditions all yield the appropriate pattern of VEGF:PEDF ratios, a compelling argument can be made for the controlling influence of these two factors (Figure 4). The next critical question will become whether the ratio is predictive for disease severity.

Systematic studies designed to correlate gene expression and pathology susceptibility are still in their infancy, yet their value to the study of ROP is already evidenced by these investigations. With today's advances in gene microarray technology, comparison of the complete genomes of rats and mice exposed to various experimental conditions is possible. This certainly will yield a myriad of new targets for investigation, and initially this will complicate the process of defining the most influential factors. Ultimately, however, it will lead us to novel therapeutic targets that may provide relief for infants at risk for ROP.

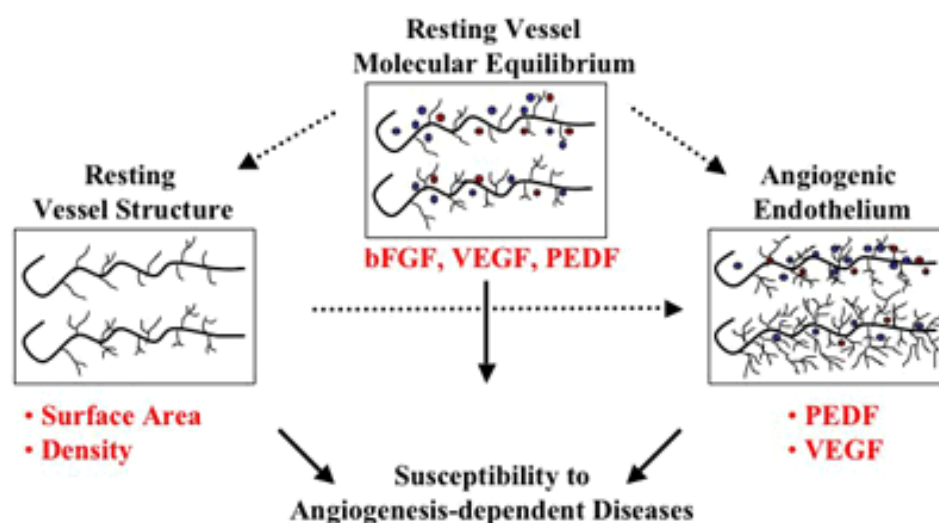


Figure 4. Mechanisms of strain-dependent angiogenesis. Schematic diagram illustrating mechanisms of strain-dependent angiogenesis. The molecular equilibrium between pro-angiogenic and anti-angiogenic growth factors may play a role in establishing mouse strain-dependent differences in resting vascular density and surface area, and the extent of responses to angiogenic stimuli. We speculate that such differences may also be predictive of susceptibility to angiogenesis-dependent diseases. The growth factors of interest are basic fibroblast growth factor (bFGF), vascular endothelial growth factor (VEGF), pigment epithelium derived growth factor (PEDF).

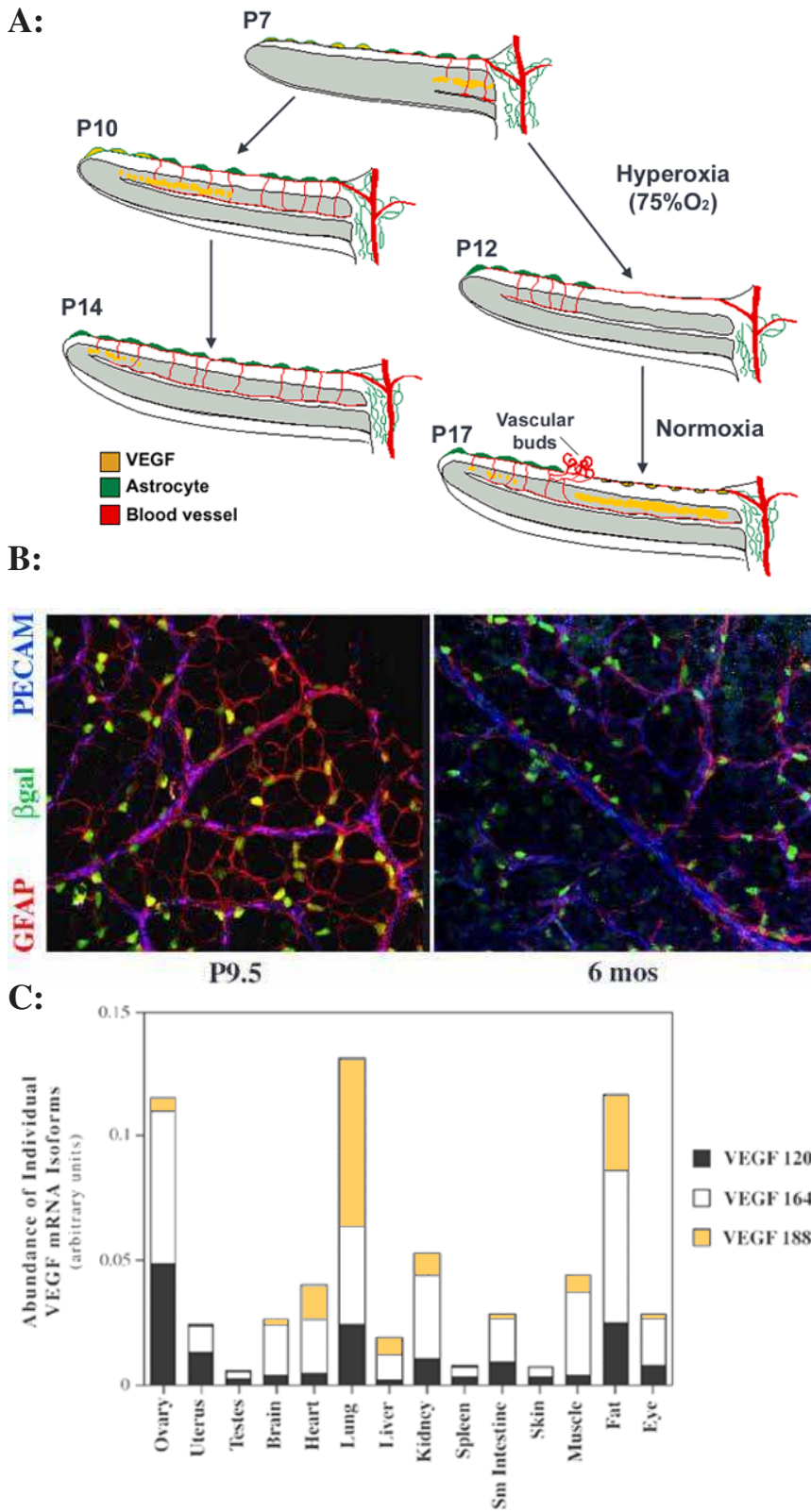


Figure 5. VEGF and its isoforms in retinal development, oxygen-induced retinopathy, and adult retinal vasculature. **A:** Mouse model of retinal vascularization and ROP (adapted from Stone et al. [8]). During normal retinal development (left side of panel A), maturation of the neural retina induces a “physiologic hypoxia” anterior to the growing vessel tips. Astrocytes spreading from the optic nerve to the periphery respond to the hypoxia by expressing vascular endothelial growth factor (VEGF), which in turn promotes the formation of the superficial vascular network. Subsequently, a second wave of neuronal activation induces VEGF secretion in the inner nuclear layer, leading to the formation of the deep vascular layers of the retina. Once the tissue is vascularized, VEGF expression decreases and the new vessels are remodeled and stabilized. Under hyperoxic conditions (drawings to the right), VEGF expression is downregulated before the completion of the normal vascular development, leading to the obliteration of the central retinal vessels. Once returned to normoxia, the unperfused tissue becomes highly hypoxic, inducing a strong and uncontrolled secretion of VEGF and the formation of vascular buds invading the vitreous, characteristic of the pathological neovascularization. **B:** Localization of VEGF in developing and adult retinal vasculature. Retinas from P9.5 and 6 months old VEGF-lacZ<sup>±</sup> mice were co-stained for  $\beta$ gal expression in combination with astrocytes and endothelial cell-associated proteins (GFAP and PECAM, respectively). Numerous  $\beta$ gal-positive nuclei, reflecting VEGF expression, can be observed in both developing and mature retina.  $\beta$ gal-positive nuclei are not all co-localized with GFAP staining, some are characteristically associated with the vessels in a pattern characteristic of pericytes, indicating pericytes producing VEGF. **C:** Quantification of VEGF mRNA isoforms levels in adult mouse organs using RNase protection assay. The height of the columns represent the levels of total VEGF mRNA, and the relative levels of different VEGF isoforms are indicated in the divisions.

Both level of total VEGF mRNA and relative VEGF isoforms expression varies among tissues. **A:** Republished with permission of the University of the Basque Country Press from Saint-Geniez M, D’Amore PA. Development and pathology of the hyaloid, choroidal and retinal vasculature. *Int J Dev Biol* 2004; 48:1045-58. **B:** Republished with permission of Elsevier from Darland DC, Massingham LJ, Smith SR, Piek E, Saint-Geniez M, D’Amore PA. Pericyte production of cell-associated VEGF is differentiation-dependent and is associated with endothelial survival. *Dev Biol* 2003; 264:275-88. **C:** Republished with permission of Wiley-Liss, Inc., a subsidiary of John Wiley and Sons, Inc., from Ng YS, Rohan R, Sunday ME, Demello DE, D’Amore PA. Differential expression of VEGF isoforms in mouse during development and in the adult. *Dev Dyn* 2001; 220:112-21.

## SESSION 1E: REVISITING THE ROLE OF VEGF IN ROP

### Contributors: Magali Saint-Geniez, Patricia D'Amore

A role for VEGF in the pathogenesis of ROP has been clearly established. In the human [11], cat [45], rat [65] and mouse retina [66], astrocytes migrate into the developing retina in front of the forming vasculature. A "physiologic hypoxia" develops, due to the increased metabolic demands of the differentiating neural retina, leading to upregulation of astrocyte VEGF production [6,39]. The gradient of VEGF produced mediates continued vascularization of the ganglion cell layer. Synthesis of VEGF by the Müller cells, also stimulated by a local oxygen deficit, induces the sprouting of the vasculature downward into the inner nuclear layer. Once metabolic demands are met, hypoxia subsides and VEGF expression declines (Figure 5A).

It is hypothesized that when premature infants are placed in high oxygen, the "physiologic hypoxia" signal is overridden and astrocyte VEGF synthesis is suppressed [67]. The lack of VEGF leads to the regression of immature vessels (vaso-obliteration), which during their development are dependent on exogenous VEGF for their continued survival. Once the infant is returned to room air, nonperfused retina becomes ischemic and the hypoxic environment upregulated VEGF synthesis in astrocytes and other neural cells. The "global" nature of the VEGF production by a significant area of nonperfused retina, compared to the local release by a limited number of astrocytes, leads to uncontrolled, abnormal vessel growth (Figure 5A).

Thus, the dogma has developed that VEGF expression virtually ceases once the retina is vascularized and normoxic. Recent observations from our lab reveal that there is constitutive VEGF expression in the adult retina by both astrocytes and some pericytes [20]. Using VEGF lacZ mice [68], we have shown that VEGF expression is maintained in adult retina. Confocal analysis of adult retina revealed the presence of numerous  $\beta$ gal-positive nuclei characteristically associated with the vessels. Presumably, the pericytes were positive (Figure 5B), since pericyte differentiation is associated with an induction of VEGF [20]. This expression of VEGF in adult tissue is not specific to the retina alone. In fact, a survey of adult murine tissues for the expression of VEGF reveals that virtually all adult tissues examined to date express VEGF, albeit at different levels (Figure 5C) [69]. The relative expression of the different VEGF isoforms varies among different tissues and organs. For example, while most tissues have relatively little VEGF<sub>188</sub>, in lung and heart more than 50% of the VEGF was VEGF<sub>188</sub> (Figure 5C). Evidence of the functional significance for the differential isoform expression has been supplied by mice that express single VEGF isoforms. Thus, mice that express only VEGF<sub>120</sub> (and lack VEGF<sub>164</sub> and VEGF<sub>188</sub>) develop to term (at reduced Mendelian ratios) and die within hours after birth from defects in cardiac and pulmonary development [70,71]. Similarly, mice expressing only VEGF<sub>120</sub> had impaired retinal vascularization and patterning; mice expressing only VEGF<sub>188</sub> displayed normal development of venous circulation but defective arterial development [72]. As VEGF

isoforms do not share the same function in regulating vascular formation and remodeling, they could also contribute differentially in the progression of pathological neovascularization. Recently, Ishida et al. [73] confirmed this hypothesis showing that VEGF<sub>164</sub> inhibition can suppress pathological neovascularization without affecting physiological angiogenesis in the rat model of ROP.

The constitutive expression of VEGF in adult tissues leads to the question of what role VEGF plays in a tissue, in the absence of active angiogenesis. We have speculated that VEGF in the adult plays a role in stabilization of the microvasculature. These functions have been addressed to some extent in experimental models. Acute withdrawal of VEGF from newly formed vessels, such as occurs in the ROP model [67] or in experimental tumors systems [74], leads to the regression of the nascent vessels. VEGF is also suspected to play a role in the differentiation of the endothelium; addition of VEGF to endothelial monolayers leads to the formation of fenestrations, a microvascular specialization [75].

The role played by VEGF in stable, mature vessels has not been elucidated. Observations from our lab and others of highly specific expression patterns of VEGF [69] and its receptors [76] in combination with evidence that VEGFR-2 is constitutively activated in the retina (Saint Geniez and D'Amore, unpublished data) [77] strongly indicate that the VEGF produced by pericytes in the adult retinal microvasculature is signaling to the endothelium. A variety of studies are currently underway to block VEGFR-2 signaling and should allow us to determine if, in fact, this signaling is biologically relevant in terms of vessel survival and stabilization.

## SESSION 1F: CAN WE PREVENT ROP THROUGH MANIPULATION OF VEGF AND IGF-1?

### Contributors: Lois Smith

ROP is a major cause of blindness in children despite current treatment of stage 3 ROP. As neonatal care in developing countries improves, the incidence of ROP increases. Preventive therapy would be of great benefit.

ROP was first described by Terry in the 1940s and associated shortly thereafter with excessive oxygen use [78]. Supplemental oxygen is now monitored carefully. Even with controlled oxygen use, the number of infants with ROP has increased further [79] due to the increased survival of very low birth weight infants [80].

*Pathogenesis: Two phases of ROP:* Infants born prematurely have incompletely vascularized retinas, with a peripheral avascular zone. The normal retinal vascular growth, which would occur in utero ceases, and there is loss of some of the developed vessels, this represents phase I of ROP. With maturation of the infant, the nonvascularized retina becomes increasingly metabolically active and increasingly hypoxic. Retinal neovascularization characterizes Phase II of ROP. It is hypoxia-induced and typically begins at 32-34 weeks post-menstrual age. Mice, rats, cats, and dogs, though born full term, have eyes that are incompletely vascularized at birth and resemble the retinal vascular development of premature infants. Exposure of these neonatal animals to hyperoxia causes

loss of vessels and cessation of normal retinal blood vessel development; this mimics phase I of ROP [28,46,55,81]. Upon return to room air, the nonperfused portions of the retina become hypoxic, which in turn causes retinal neovascularization, similar to phase II of ROP and other retinopathies.

*VEGF and phase II of ROP:* Phase II of ROP is driven by hypoxia. VEGF is a hypoxia-inducible cytokine. In the mouse and kitten models of ROP, there is a temporal relationship between VEGF and proliferative retinopathy; retinal hypoxia stimulates an increase in the expression of VEGF before the development of neovascularization [39,55,82]. Inhibition of VEGF decreases the neovascular response [83,84] indicating that VEGF is a critical factor in retinal neovascularization. The central role of VEGF in ocular neovascularization has also been demonstrated by other investigators in other animal models [38,39,85-87] and correspond to clinical observations. VEGF is elevated in the vitreous of patients with retinal neovascularization [88,89]. VEGF was found in the retina of a patient with ROP in a pattern similar to that observed in mouse studies [85].

*VEGF and phase I of ROP:* Normal blood vessel growth is also VEGF dependent. In phase I, hyperoxia suppresses normal VEGF driven vessel growth. Blood vessels grow from the optic nerve to the periphery. As neural retina develops anterior to the vasculature there is increased oxygen demand, which creates localized physiologic hypoxia, an increase in VEGF, and blood vessels grow toward the stimulus [8,90]. As the hypoxia is relieved by oxygen from the newly formed vessels, VEGF mRNA expression is suppressed, moving the wave forward.

Supplemental oxygen interferes with normal VEGF-driven vascular development [6]. Furthermore, hyperoxia-induced vaso-obliteration is caused by apoptosis of vascular endothelial cells. Vaso-obliteration can be partially prevented by administration of exogenous VEGF, or in particular by administration of placental growth factor (PlGF-1), the ligand specific to VEGFR-1 [67,90,91]. Thus VEGFR-1 is required for vessel survival. This indicates that VEGF acting through VEGFR-1 is required for maintenance of the immature retinal vasculature and explains, at least in part, the effect of hyperoxia on normal vessel development in ROP.

Although hyperoxia alone can cause cessation of vascular growth and vaso-obliteration in animal models, it is clear that clinical ROP is multifactorial. Despite controlled use of supplemental oxygen, the disease persists as ever more immature infants are saved, suggesting that other factors related to prematurity itself are also at work.

*Growth hormone and insulin-like growth factor in phase II of ROP:* Prematurity is the most significant risk factor for ROP. Because growth hormone has been implicated in proliferative diabetic retinopathy, we considered growth hormone (GH) and IGF-1 the mediator of many of GH's mitogenic effects, as potential candidates in ROP.

Proliferative retinopathy, the second phase of ROP [92], is substantially reduced in transgenic mice expressing a growth hormone receptor antagonist, in normal mice treated with a

somatostatin analog that decreases growth hormone release, or in mice treated with an IGF-1 receptor antagonist.

IGF-1 may not act through VEGF under physiological conditions [92,93]. However, it appears that IGF-1 can act permissively to facilitate maximum VEGF stimulation of new vessel growth as VEGF alone may not be sufficient for promoting vigorous retinal angiogenesis.

*IGF-1 and phase I of ROP:* Similar to the role of VEGF in both phases of ROP, IGF-1 is critical to phase I [94]. The extent of phase II of ROP is determined by the extent of phase I. IGF-1 levels fall from in utero levels after birth, due to the loss of IGF-1 provided by the placenta and the amniotic fluid. We hypothesized that IGF-1 is critical to normal retinal vascular development and that a lack of IGF-1 in the early neonatal period is associated with lack of vascular growth and subsequent proliferative ROP. In IGF-1 knockout mice retinal blood vessels grow more slowly than in those of normal mice, a pattern very similar to that seen in premature babies with ROP. We found that IGF-1 controls maximum VEGF activation of the Akt endothelial cell survival pathway. These observations were confirmed in patients with ROP [94,95].

In 84 premature infants, the mean IGF-1 level was significantly and proportionately lower in post-menstrual-age-matched babies with each stage of ROP than without ROP. These findings suggest the intriguing possibility that replacement of IGF-1 to uterine levels might have an impact on the development of ROP and facilitate normal retinal vascular development. If phase I is aborted the destructive second phase of vasoproliferation will not occur.

*A rationale for the evolution of ROP:* A rationale for the evolution of ROP has emerged based on the understanding of the roles of VEGF and IGF-1 in both phases of the disease. Blood vessel growth is dependant on both IGF-1 and VEGF. In very preterm infants, with the absence of IGF-1 normally provided by the placenta and amniotic fluid, blood vessel growth may be retarded since IGF-1 is required for optimal VEGF signaling of endothelial cells. When premature infants are given supplemental oxygen, VEGF itself is suppressed. Thus both prematurity and oxygen are factors in suppression of normal vessel growth during phase I of ROP. As parts of the eye mature without a vascular supply, they become oxygen starved, sending signals to increase VEGF. We postulate that as the infant's organ systems mature, IGF-1 levels rise and suddenly allow the elevated levels of VEGF to promote neovascular proliferation of blood vessels that can cause blindness.

*Clinical implications:* The discovery of the possible interactions of VEGF and IGF-1 in the development of ROP furthers our understanding of the pathogenesis of the disease (Figure 6). These studies suggest a number of ways to intervene medically in the disease process but also emphasize that timing is critical to any intervention, since the two phases of the disease require different approaches. Inhibition of either VEGF or IGF-1 soon after birth could detrimentally alter normal blood vessel growth and precipitate the disease whereas inhibition at the second neovascular phase might prevent destructive neovascularization (Figure 6).

Similarly, replacement of IGF-1 early might promote normal blood vessel growth while late supplementation with IGF-1 in the neovascular phase of ROP could exacerbate the neovascular disease. In the fragile neonate, the choice of any intervention must be made very carefully to promote normal physiological development of both blood vessels and other tissue. In particular, the finding that the low serum levels of IGF-1 in premature babies may give a new avenue for treatment suggests that correcting the serum IGF-1 levels towards those found in utero might have a beneficial effect on the disease by facilitating normal vascular development.

It is also encouraging to find an intervention in the mouse model of ROP that can prevent vessel loss without precipitating new vessel growth. Since VEGFR-1 appears to control vessel survival without instigating proliferation, the use of a specific agonist to VEGFR-1, PlGF-1, might be used early in the disease to prevent vessel loss without promoting proliferative disease. Further studies on disease mechanism and development of strategies to allow normal retinal and brain development may lead to a significant reduction in the incidence of ROP.

#### SESSION 2A: CLINICAL STUDIES

##### Contributors: Dale Phelps, Earl Palmer

This series of presentations brought out many aspects of ROP that have emerged in the recent years as a result of carefully controlled intervention trials, systematic observational studies of large cohorts, and focused studies of the physiology of the retina and its vessels as affected by ROP.

The natural history data and controlled trial results from Multicenter Trial of Cryotherapy for Retinopathy of Prematurity (the CRYO-ROP Study) provide circumstantial evidence that peripheral production of growth factors in the avascular retina is probably the most immediate disturbance leading to deterioration of the retinopathy. Destruction of that peripheral retina and the putative source of the growth factors permits regression (healing) of the ROP in a great many cases. The visual acuity following ROP has been studied now with grating and recognition acuity testing through 10 years following birth. Dr. Dobson describes these findings and shows that the premature infant develops vision within the normal range over the early years, even having had mild or moderate ROP. However, the acuity of the infants who have had threshold ROP are below the normal developmental range, even when the eyes have been successfully protected from retinal detachments. The additional finding that the peripheral retina has poor function (Goldman peripheral fields) at 10 years following neonatal threshold ROP, even when the ROP regresses spontaneously with no cryotherapy (control eyes) was unexpected. The detailed studies of the development of photoreceptor function described by Dr. Fulton (Session 2D) provides greater detail and insights into the functional problems encountered by photoreceptors in the growing former preterm infants. Using these functional assessments, children who had even mild or moderate ROP continue to have measurable deficits in rod sensitivity, although it does appear to be proportional to the severity of the original ROP.

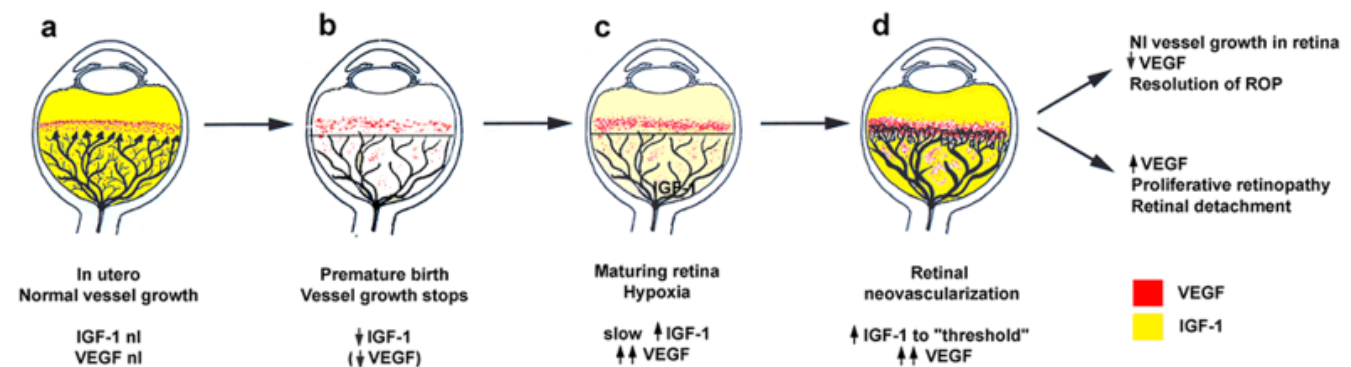


Figure 6. Schematic representation of IGF-I & VEGF control of blood vessel development in ROP. **A:** In utero, vascular endothelial growth factor (VEGF) is found at the growing front of vessels. insulin-like growth factor 1 (IGF-1) is sufficient to allow vessel growth. **B:** With premature birth, IGF-1 is not maintained at in utero levels and vascular growth ceases, despite the presence of VEGF at the growing front of vessels. Both endothelial cell survival (Akt) and proliferation (mitogen-activated protein kinase) pathways are compromised. With low IGF-1 and cessation of vessel growth, a demarcation line forms at the vascular front. High oxygen exposure (as occurs in animal models and in some premature infants) may also suppress VEGF, further contributing to inhibition of vessel growth. **C:** As the premature infant matures, the developing but nonvascularized retina becomes hypoxic. VEGF increases in retina and vitreous. With maturation, the IGF-1 level slowly increases. **D:** When the IGF-1 level reaches a threshold at 34 weeks gestation, with high VEGF levels in the vitreous, endothelial cell survival and proliferation driven by VEGF may proceed. Neovascularization ensues at the demarcation line, growing into the vitreous. If VEGF vitreal levels fall, normal retinal vessel growth can proceed. With normal vascular growth and blood flow, oxygen suppresses VEGF expression, so it will no longer be overproduced. If hypoxia (and elevated levels of VEGF) persists, further neovascularization and fibrosis leading to retinal detachment can occur. Republished with permission of the National Academy of Sciences, U.S.A. from Hellstrom A, Perruzzi C, Ju M, Engstrom E, Hard AL, Liu JL, Albertsson-Wikland K, Carlsson B, Niklasson A, Sjobell L, LeRoith D, Senger DR, Smith LE. Low IGF-I suppresses VEGF-survival signaling in retinal endothelial cells: direct correlation with clinical retinopathy of prematurity. Proc Natl Acad Sci U S A 2001; 98:5804-8. Copyright 2001 National Academy of Sciences, U.S.A.

Oxygen and ROP remain linked by the clear demonstration that, like in the animal models of oxygen induced retinopathy, prolonged administration of oxygen so that arterial levels are elevated will clearly increase the chance of vision loss from ROP. The discouraging lack of systematic data about what oxygen saturations (pulse oximetry) are safest for both the retina and the developing brain are carefully brought out by Dr. Cole (Session 2F), and there seems to be ample room for improvement in our knowledge. It is encouraging to learn that the plans to get such data are finally moving forward on an international level. In contrast to these planned studies on the use of oxygen in the early days and weeks after birth, Dr. Phelps (Session 2E) presented the data from the STOP-ROP study where enrolled infants already had prethreshold ROP and were then randomized to treatment with conventional or increased oxygen as measured by oximetry. While the treatment was theoretically plausible and supported by animal studies, the effects were small, and not statistically significant except in the subgroup identified post hoc who did not have "plus disease" at the time of randomization. Even in this subgroup, the effect size was small and not much different than the rates of adverse pulmonary events from the elevated oxygen levels, leaving us without the new therapeutic intervention we had hoped for.

Despite all we have learned, we are left with many questions, and a few of our favorites are: Why does the pace of ROP move with postmenstrual age instead of weeks after birth? Just what is "plus disease"? Why does the peripheral retina not work after threshold ROP, even when it regressed?

## SESSION 2B: LESSONS LEARNED FROM THE CRYO-ROP STUDY

### Contributors: Earl Palmer

We stand in the early years of a new millennium, and it is fitting to assess what we have learned in the latter half of the previous millennium. In 1988, the initial report from the CRYO-ROP Study offered the first proof cryotherapy significantly reduces unfavorable fundus outcomes from ROP. In 1990, we reported significant visual acuity benefit from cryotherapy, as well. Subsequent publications detailed the small changes that occurred over time in the group of eyes that received cryotherapy, as compared to the control eyes. As with many well-designed multicenter, randomized clinical trials, much additional information emerged during the course of the trial, beyond the primary aim of the study. The CRYO-ROP study produced abundant new and reliable data concerning the incidence and early course of ROP, in various subgroups and according to severity categories.

*Brief ROP history:* ROP was first recognized in the 1940s. The role of oxygen was demonstrated in the 1950s, but in the 1960s, the belief that the disease was under control proved false, and during the 1970s clinicians began to appreciate that we needed to learn more about this disease. Substantial progress was made in the clinical recognition of ROP, and by 1984, the international classification of ROP (ICROP) had been developed and published [96]. During the meetings of that committee, discussions were held about the advisability of

cryotherapy. The data were inconclusive, but discussions led to a planning committee to design a clinical trial of cryotherapy.

*The Multicenter Trial of Cryotherapy for Retinopathy of Prematurity:* The CRYO-ROP study required detailed development of a multi-center infrastructure to determine the risks and benefits of cryotherapy for ROP, to examine the natural course of the disorder, and to determine its incidence. Outcomes of comparably treated and untreated eyes would be studied; by including a prospective natural history cohort with the new ICROP, the disease would be better characterized.

Starting in January 1985, infants born were tracked if they weighed less than 1251 g at birth; 9,751 infants were registered in 23 participating clinical centers. The cohort of prospectively examined infants who survived for examinations numbered 4,099. Examinations began at age 4-6 weeks, and continued every 1-2 weeks, until retinopathy either involuted or threshold status for randomization into the clinical trial was attained. Two hundred and ninety-one infants with ROP at threshold were randomized in the trial. Of these, 79 were "late entry" and not part of the natural history cohort (infants who reached the threshold for randomization and were then transferred into a study center) [97].

To place the CRYO-ROP study into perspective, this was the first conclusive intervention trial for ROP, and it included a predetermined sample size to answer the primary question. The cohort was representative of preterm infants, including approximately 15% of the premature infants born in the United States during that time frame [98].

Cryotherapy was chosen (as the method for ablating the entire area of nonvascularized peripheral retina), because an indirect-ophthalmoscope delivery system for laser had not yet been developed that was suitable for use in infants. The optimal dosage and timing of cryotherapy were not studied. The threshold for randomization was predicted to represent a 50% risk-severity category, for retinal detachment, and this prediction proved to be surprisingly accurate.

The CRYO-ROP infrastructure included 302 investigators, located at 77 hospitals in 23 geographic centers around the United States. This included ophthalmologists, neonatologists, study center coordinators, ophthalmic photographers, and the Data Coordinating Center at the University of Texas, Houston. Many procedures had to be developed. ICROP had to be refined for research use since plus disease was described in the ICROP publication only with an example photograph, but was not specifically presented as a minimum-standard severity to qualify as plus disease. Therefore, the CRYO-ROP investigators spent considerable time and effort reviewing fundus photographs, in order to come up with a photograph the group felt represented the minimum degree of dilatation and tortuosity to qualify as plus disease. This was published with the preliminary results of the CRYO-ROP study in 1988 [99], and has also been used as the standard for three subsequently-launched multicenter ROP trials sponsored by the NIH (STOP-ROP, LIGHT-ROP, and ETROP).

The executive committee of the CRYO-ROP study conducted detailed training sessions in the ICROP and in the use of the data forms. Inter-observer consistency was specifically

trained by paired examinations, and agreement among centers was tested by extensive site visiting. The essential elements of the ICROP were preserved; namely, the definitions of stages, zones, and the use of the clock-hour convention for recording the extent of ROP. The ICROP was ambiguous on the precise definition of zone III, and the CRYO-ROP study settled on the convention that zones II and III would be mutually exclusive. Thus, it would be impossible by definition, for any ROP on the temporal side of the eye to be classified as zone III, unless the two nasal sectors in the same eye had fully developed vessels without ROP (a convention also used in the STOP-ROP, LIGHT-ROP, and ETROP studies).

Objective outcome evaluation was assured by use of naïve graders of fundus photos, using a system of grading that had to be developed for this purpose. Visual acuity assessment was carried out at age one year, under the direction of Dr. Velma Dobson, using the Teller grating acuity cards. The exact procedures used to assess visual acuity had to be changed as the children grew and developed.

*Results:* By age ten, the majority of treated threshold eyes have acuity better than 20/200, as compared to only 38% of untreated eyes. Likewise, the posterior retina was free of folding or detachment in 73% of treated eyes compared to a bare majority of control eyes [100]. Color vision, contrast sensitivity and visual fields were also improved in treated eyes, and the latter findings were particularly interesting. A physical and functional price for the benefit of cryotherapy is the reduction of peripheral visual field by about 5% (compared to sighted control eyes), but in fact, ROP itself actually reduced the visual fields nearly as much as did ablation of the nonvascularized peripheral retina [101].

The current incidence of ROP was determined, and about two-thirds of all infants weighing less than 1251 g at birth developed ROP to some degree. Overall, 6% of these infants developed threshold ROP and were eligible for the randomized clinical trial. This was highly correlated with the degree of prematurity, with 16% of those born weighing less than 750 g reaching threshold for cryotherapy, but only 2% of those with birth-weights of 1.0-1.25 kg.

A closer look at the timing of events in the natural course of ROP showed that prethreshold ROP occurred between 32.4 and 41.5 postmenstrual (postconceptional) weeks in 90% of the infants, for a median of 36.1 weeks. Threshold occurred at a median age of 36.9 weeks. Involution of ROP started at the mean postmenstrual age of 38.6 weeks, and 90% of eyes began to involute between 34 and 46 weeks [102].

Among the outcomes for all eyes in the natural history cohort (excluding those threshold eyes that were randomized to be treated), 3.1% had a final outcome of retinal fold or detachment by age 5.5 years. Such unfavorable outcomes were generally associated with zone II, stage 3 ROP with plus disease or with zone I ROP. There were only 12 children in the CRYO-ROP study who had zone I threshold disease fairly symmetrically, in both eyes. For them, fundus outcomes were unfavorable 75% of the time in the eye that received cryotherapy, as compared with 92% of control eyes. Zone I ROP was uncommon in CRYO-ROP and the investigators learned about

and debated its unusual appearance, particularly the more subtle signs of stage 3 disease.

An analysis of risk factors showed significant associations with five ROP variables: stage, extent, zone, plus disease, and rate of progression of ROP. These were reasonably predictable, but it was very satisfying to be able to mathematically describe the magnitude of these effects for the first time in terms of odds ratios. For risk factors associated with the infant (as opposed to the eyes), it was already well known that gestational age and birth weight were significant, but it was interesting to see evidence that the need for transfer to another hospital following birth was associated with increased ROP severity. While multiple gestation was not significant in predicting outcome once an eye reached threshold severity, it was a predictive factor in the development of ROP per se, and the likelihood of progressing to threshold severity. A surprise finding was that African-Americans seem to be relatively resistant to bad outcomes from ROP, despite a similar rate of early ROP [97]. Hardy combined all of these risk factors to compute a global risk for a given eye in a given baby. This risk algorithm, related to adverse fundus outcome at three months, was used in the ETROP study [103].

*Current status of the CRYO-ROP study:* More than 50 significant outcome articles have been published since the primary results appeared in 1988. Final examinations of the randomized patients were completed at 15 years of age in 2003; the final manuscript examined the occurrence of retinal detachments between age ten and fifteen years [104].

## SESSION 2C: VISUAL FUNCTION IN THE DEVELOPING CHILD FOLLOWING ROP

### **Contributors: Velma Dobson (on behalf of the CRYO-ROP Cooperative Group)**

The CRYO-ROP study is a multicenter study that consisted of two arms: (1) a natural history study of children with birth weights <1251 g who had eye examinations in one of the 23 participating centers by 4-6 weeks after birth and (2) a randomized, controlled trial of cryotherapy for eyes that developed threshold (severe) ROP. The natural history study enrolled over 4,000 infants who were born between January 1986, and November 1987, representing approximately 15% of the infants with birth weight <1251 g children who were born in the US during this period. Two-thirds of these infants developed ROP.

As part of the natural history study, monocular grating visual acuity was measured with the Teller acuity card procedure [105] in 735 infants at 1 year, 945 children at 2 years, 1,108 children at 3 1/2 years, and 1,173 children at 4 1/2 years [106]. Results were compared with normative grating acuity data reported for full-term infants and young children [107,108]. In the group of children who did not develop ROP (data obtained from 214 to 380 per test age), mean grating acuity was near the bottom of the normal range at each age. Similar results were found for the group of children who developed only mild (less than prethreshold) ROP (298 to 499 per test age). Mean acuity scores for the group of children who developed moderate (prethreshold) ROP (65 to 100 per

test age) were at the bottom of the normal range at each age. Approximately half of the eyes with threshold ROP that were randomized to serve as a control (158 to 194 per test age) were blind, and the remaining eyes showed mean visual acuity well below the normal range at all ages (Figure 7).

Monocular recognition acuity was measured in 959 of the children at age 5 1/2 years [109] using the Early Treatment Diabetic Retinopathy Study (ETDRS) letter charts [110]. Visual acuity outcome was correlated with severity of acute phase ROP. Over half of eyes with ROP in zone I or with ROP in zone II, stage 3 in 7-12 sectors, and plus disease had a visual acuity of 20/200 or worse. In contrast, over 80% of eyes with stage 1 or 2 ROP in zone II or with ROP in zone III had a visual acuity of 20/40 or better at 5 1/2 years.

Two hundred ninety-one infants participated in the randomized trial of cryotherapy for threshold ROP. Of these 291 infants (218 of whom also participated in the natural history study), 240 had developed threshold ROP in both eyes and had one eye randomized to undergo cryotherapy and the other

eye served as a control. The remaining 51 infants developed threshold ROP in only one eye and that eye was randomized to cryotherapy or to serve as control. Monocular visual acuity was tested in 68% of the 260 surviving infants at age 1 year [98], 92% of the 256 survivors at age 3 1/2 years [111], 92% of the 255 survivors at 5 1/2 years [112], and 97% of 255 survivors at 10 years [100]. As with the children in the natural history study, testing was conducted with Teller acuity cards at 1, 3 1/2, and 5 1/2 years, with the crowded HOTV letter test at 3 1/2 years, and with the ETDRS letter charts at 5 1/2 and 10 years. Unfavorable visual acuity outcome was grating acuity more than one octave below the normal range for age (an octave is a halving or doubling of grating spatial frequency; e.g., from 4 to 2 cycles/degree) or letter acuity of 20/200 or worse. Across all test ages, results indicated an unfavorable outcome in approximately 60% of control eyes and approximately 45% of cryotherapy treated eyes, which was a significant reduction in unfavorable outcomes in the treated eyes. Results at 10 years using the letter charts showed that approximately 25% of both treated and control eyes had acuity of 20/40 or better [100]. More treated than control eyes had visual acuity worse than 20/40 but better than 20/200, while more control than treated eyes had visual acuity of 20/200 or worse, suggesting that eyes saved from blindness by cryotherapy may not develop normal visual acuity.

Because cryotherapy ablates the avascular peripheral retina, Goldmann perimetry was conducted at the 10-year examination to determine whether study participants showed visual field deficits [101]. Visual field extent was measured along eight meridians using the V4e and III4e stimuli and showed a significant reduction in both treated and control eyes, compared to results from approximately 100 CRYO-ROP study participants who did not develop ROP. To determine whether the reduction in mean measured visual field extent in treated and control eyes was attributable solely to data from blind eyes (which have a measured visual field extent of zero), we examined results from 78 patients, each of whom had one sighted treated eye and one sighted control eye. Measured visual field extent was still significantly reduced in both treated and control eyes, in comparison to eyes in the no-ROP group. In addition, measured visual field extent was slightly (approximately 5%) smaller in sighted treated eyes than in sighted control eyes.

In summary, data from the CRYO-ROP study indicate that the development of visual acuity is related to severity of acute-phase ROP. Eyes with the most severe acute-phase ROP show the worst acuity scores at all ages between 1 and 5 1/2 years. Results from the randomized trial indicate that peripheral retinal ablation using cryotherapy in eyes with severe (threshold) ROP results in a benefit to visual acuity development, with only a minimal effect on visual field extent. Nevertheless, approximately 45% of eyes treated with cryotherapy show significant deficits in visual acuity development [98,100,111,112]; visual field deficits are seen in both treated and control eyes of children who had severe acute-phase ROP [101]. These results suggest that, despite the benefit of cryotherapy in the

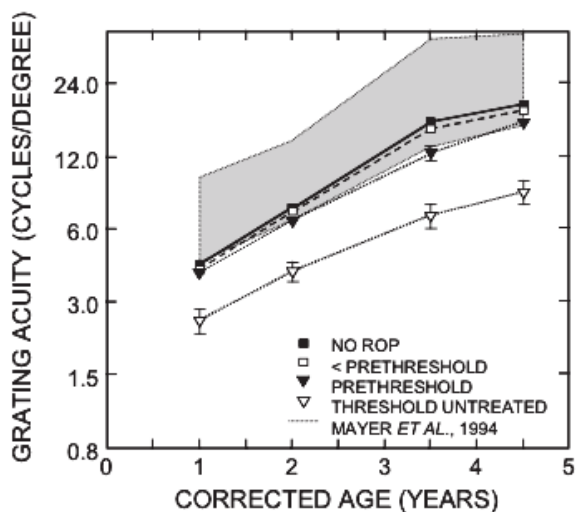


Figure 7. Acuity development in eyes with quantifiable grating acuity in the CRYO-ROP study. The shaded area represents the 95% prediction limits for healthy full-term children with no ocular abnormalities reported by Mayer et al. [108]. Not represented in this graph are eyes with vision too poor to be quantifiable with the Teller acuity card procedure (less than 3% of eyes in the no-ROP, less than prethreshold, and prethreshold groups, and approximately 50% of eyes in the threshold untreated group). Numbers of eyes in each group at the four test ages, respectively, are: no-ROP (213, 276, 344, 380), less than prethreshold (295, 384, 468, 496), prethreshold (64, 92, 96, 98), and threshold untreated (78, 89, 94, 98). Bars represent the standard error of the mean. Republished with permission of The Association for Research in Vision & Ophthalmology from Dobson V, Quinn GE, Summers CG, Saunders RA, Phelps DL, Tung B, Palmer EA. Effect of acute-phase retinopathy of prematurity on grating acuity development in the very low birth weight infant. The Cryotherapy for Retinopathy of Prematurity Cooperative Group. Invest Ophthalmol Vis Sci 1994; 35:4236-44.



treatment of severe ROP, there is a need for methods of preventing the development of severe ROP, and a need for improved treatments for eyes that do develop severe ROP.

SESSION 2D: PHOTORECEPTORS AND NEURAL RETINA IN ROP

**Contributors: Anne Fulton, Ronald Hansen**

Abnormal blood vessels are the hallmark of ROP. Active ROP and important developments in the oxygen greedy rods are concurrent. At preterm ages, the developing rod cells begin redistribution over the growing retinal surface area. The rod outer segments grow longer causing demands for energy and oxygen to escalate. The rhodopsin content of the retina increases (Figure 8A).

We present two types of experiments on the rods of infants and children. We use psychophysical procedures to

sample retinal function in selected, small retinal areas, and ERG responses to full field stimuli to evaluate function of all rods in the whole retina. Our subjects are former preterms categorized according to severity of ROP: none, mild, moderate, and severe [113].

As background for the psychophysical experiments, we note that the human eye grows considerably after the preterm ages when those at risk for ROP are born. By term, the diameter of the eye is about that of a US dime. At post-term ages, when we measure rod cell function, the globe is still growing. An adult's globe is about the size of a US quarter. As the eye grows, retinal surface area increases. The immature rods redistribute over the retinal surface to pave an expanding peripheral area with a fixed number of rod cells. Redistribution of rod cells leads to definition of an anatomic ring with a high number of rod cells per unit area [114,115]. The rod ring is

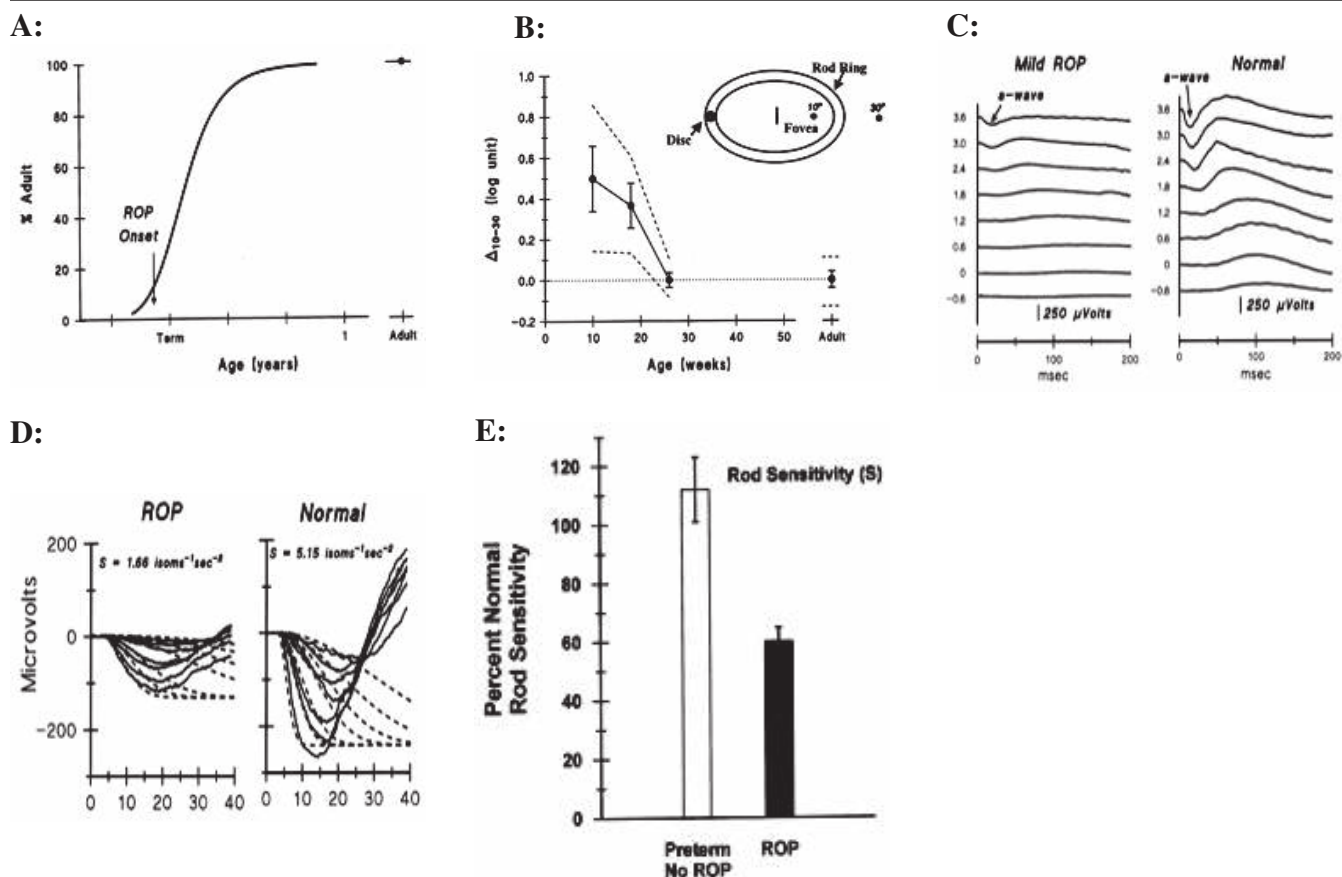


Figure 8. Visual function and ROP. **A:** The growth curve summarizes the developmental increase in human rhodopsin. ROP has its onset just as the curve begins to increase rapidly. **B:** The mean and prediction limits for D 10-30 in normal infants; the adult value of zero is reached by age 6 months. **C:** Sample ERG records from 10-week-old infants. The vertical scale is in log scotopic troland seconds. The downward deflections in the records are the a-waves (arrow). The difference between records from the infant with mild ROP and the normal subject are conspicuous. **D:** The a-waves are displayed on an expanded time scale. The dashed lines represent the Lamb & Pugh model fitted to the ERG a-waves. S (rod cell sensitivity) is lower in ROP subjects. **E:** The mean values of S for “No ROP” and “ROP” subjects are shown as percent of normal for age. The means differ significantly (re-plotted from Fulton et al, 2001). **A:** Republished with permission of The Association for Research in Vision & Ophthalmology from Fulton AB, Dodge J, Hansen RM, Williams TP. The rhodopsin content of human eyes. Invest Ophthalmol Vis Sci 1999; 40:1878-83. **B:** Republished with permission of The Association for Research in Vision & Ophthalmology from Hansen RM, Fulton AB. The course of maturation of rod-mediated visual thresholds in infants. Invest Ophthalmol Vis Sci 1999; 40:1883-6. **C,D:** Republished with permission of the American Medical Association from Fulton AB, Hansen RM, Petersen RA, Vanderveen DK. The rod photoreceptors in retinopathy of prematurity: an electroretinographic study. Arch Ophthalmol 2001; 119:499-505. Copyright ©2001 American Medical Association. All rights reserved.

concentric with the fovea and at the eccentricity of the disc (Figure 8B). The developmental elongation of the rods central to the ring lags behind that of more peripheral rods [114]. Short outer segments predict lower quantum catch, lower sensitivity, and higher visual threshold.

We devised a preferential looking based psychophysical procedure suitable for testing, the immature rods central ( $10^\circ$  eccentric) and peripheral ( $30^\circ$  eccentric) to the rod ring, in young infants [116]. We selected test conditions such that in a dark-adapted adult, the thresholds at  $10^\circ$  and  $30^\circ$  are identical. By definition, the difference between these thresholds (“ $\Delta 10-30$ ”) is zero in adults, but in normal infants, “ $\Delta 10-30$ ” is not zero. A longitudinal study following a within subject design showed “ $\Delta 10-30$ ” at 10 weeks post-term is on average 0.5 log units, and decreases systematically to the adult zero by 26 weeks (6 months) as thresholds at both  $10^\circ$  and  $30^\circ$  reach adult values [117]. Additional evidence [118] demonstrates rod cell origins of this visual function, in accord with the anatomic data. The course of development is prolonged in some ROP subjects, even if ROP is mild [119]. Elevated “ $\Delta 10-30$ ” thresholds persist in late childhood in some ROP subjects [120]. At these older ages, the rod outer segments would have been turned over and renewed thousands of times. Thus, ROP injury must not be directed to the outer segment but perhaps to the inner segment which manufactures the outer segment discs.

Now we turn to the ERG studies of rod photoreceptor responses to full field stimuli (Figure 8C). The rod outer segments are a stack of discs surrounded by the outer segment membrane. Rhodopsin is in the discs, along with the other proteins in the transduction cascade. Photon capture activates rhodopsin, which diffuses in the membrane to activate the G-protein, which diffuses to activate PDE, which leads to closure of the cG-gated channels in the membrane.

Each of these biochemical steps can be described precisely by a mathematical equation, which can be summarized in one grand equation, the Lamb and Pugh model [121-123]. In development, the main parameters of the model are nicely scaled by rhodopsin content [124,125]. In this equation the parameter  $S$  summarizes kinetics from photon capture through closure of channels in the outer segment membrane.  $S$  represents rod cell sensitivity.  $S$  is calculated from ERG waves (Figure 8D).

Sensitivity ( $S$ ) for the No ROP group is indistinguishable from normal (Figure 8E). Rod cell sensitivity is significantly lower in those with a history of ROP. Analysis of variance for data stratified by severity of ROP indicates rod cell sensitivity varies significantly with severity of ROP [126]. As we continue to fill experimental cells, we will find out if this holds for a larger sample.

We conclude that the rods are affected by ROP, even if ROP was mild. Rod cell dysfunction predicts some visual deficits in ROP. The developmental course of  $\Delta 10-30$  implicates the rods in the ROP disease process. Can ERG testing of rod cell function at preterm ages, before ROP appears, forecast ROP? We can find out! If rod cell function forecasts ROP, then timely intervention might prevent ROP.

## SESSION 2E: EFFECTS OF OXYGEN ON ESTABLISHED ROP

### Contributors: Dale Phelps

The clinician-scientist brings a synthesis of experience, basic science, theory, epidemiology, and previous clinical research to a clinical trial to determine the safety and efficacy of a promising intervention. Beyond the strict outcomes of that trial, secondary analyses reveal new insights and generate new hypotheses to be tested.

The STOP-ROP study [127] is best understood on the backdrop of normal human retinal vascular development, described elsewhere in these proceedings, and the course of ROP from its first visible neovascularization 4-11 weeks after birth [97] through involution or progression to severe disease requiring surgery to reduce the risk of retinal detachment (Figure 9). The current favored hypothesis of its mechanism is that following injury to the primitive growing vessels soon after birth, the retinal vessels begin to re-grow (neovascularization; NV) and sometimes escape the retina, growing into the vitreous [96,128]. The retinal vessels most often grow successfully (80%) and as the retina becomes fully vascularized, involution of preretinal and intraretinal NV occurs yielding a good outcome. If “plus disease” develops with its dilation and tortuosity of the vessels in the posterior pole of the eye (Figure 10), the risk of progression to retinal detachments becomes about 50% [98]. If the avascular retina is the source of growth factors driving the neovascularization and plus disease, its ablation would be expected to halt the progress of the disease. Indeed, surgical ablation (cryotherapy or laser therapy) of the avascular retina appears to downregulate the process with disappearance of the plus disease and return of the eye to a quiet state, but there is no further vascularization of the now scarred and non-functional peripheral retina [98]. In the STOP-ROP hypothesis, we extended the concept: if hypoxia of the neuroretina was causing the growth factor release, perhaps raising the diffusion gradi-

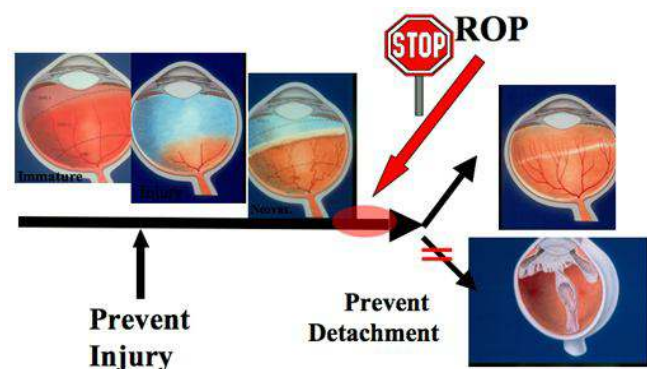


Figure 9. Rationale for the STOP-ROP study. Artist's concept of the sequential appearance of the growing preterm human retina as it develops ROP. From left to right, the normal immature retina, initial injury of the developing vessels, neovascularization with plus disease, involution (top) or retinal detachment (lower). The red arrow and circle indicates the hypothesized time/site of action of oxygen in the STOP-ROP study.

ent of oxygen from the choroid could allow downregulation of the growth factor production (without turning it completely off) and permit orderly new vascularization.

In the STOP-ROP study [127], infants who developed prethreshold ROP [99] were enrolled from 30 centers and randomized to maintain pulse oximetry of 89-94% oxygen saturation (conventional treatment [C]; n=325) compared to 96-99% saturation (supplemental treatment [S]; n=324; Figure 11). The randomization balanced the groups well and the treatment was administered consistently. We found that 48% of the C group went on to meet surgery criteria compared to 41% of the S group (p=0.06). The total magnitude of the difference (which was not statistically significant, but in the expected direction) was not large and, at 3-6 months past their due dates, these preterm infants had essentially the same rates of poor eye outcomes (retinal detachment, retinal fold, obstruction of the visual axis) in both groups (4.4% for the C group and 4.1% for the S group). There were increased pulmonary side effects in the S group, so with its small potential benefit, this treatment is not widely used now. However, in a secondary analysis, some tantalizing biology emerged.

For the STOP-ROP trial, the prethreshold ROP entry criteria was: stage 3 ROP in zone II; plus disease in zone II with stage 2; zone II without enough stage 3 to meet threshold-for-surgery criteria; or any ROP in zone I, even with no plus disease [99]. Examination of the enrolled infants showed that 2/3 of the enrollees did not have plus disease as a component of the reason for their having prethreshold ROP. This was equally balanced in the C and S groups. The birth weights and gestational ages of these two subgroups were similar and, therefore, the outcomes were examined according to whether they

had plus disease or not at study entry. If plus disease was present at the time of randomization, 55% of the infants went on to meet the surgery criteria, clearly a marker of severe disease; however, supplemental oxygen had no differential effect on eyes that already had plus disease (57% going on to threshold in the S group compared to 52% in the C group). In contrast, the outcomes were significantly different among the eyes that did not have plus disease at the time of randomization. Eyes of infants in the C group progressed to threshold 46% of the time while those in the S group progressed only

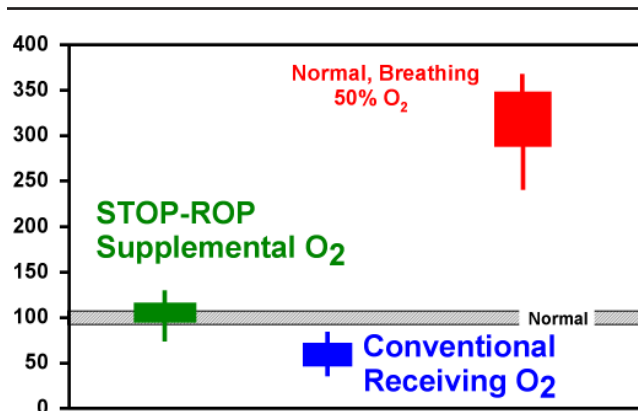


Figure 11. Predicted arterial PaO<sub>2</sub>. Relative arterial oxygen levels in human infants with normal lungs breathing 50% oxygen (animal models of ROP breathing 80-100% oxygen are even higher), and the levels among premature infants receiving oxygen where attempts are made to minimize the amount of oxygen given. Infant's in the supplemental group in STOP-ROP had somewhat higher levels, as labeled.

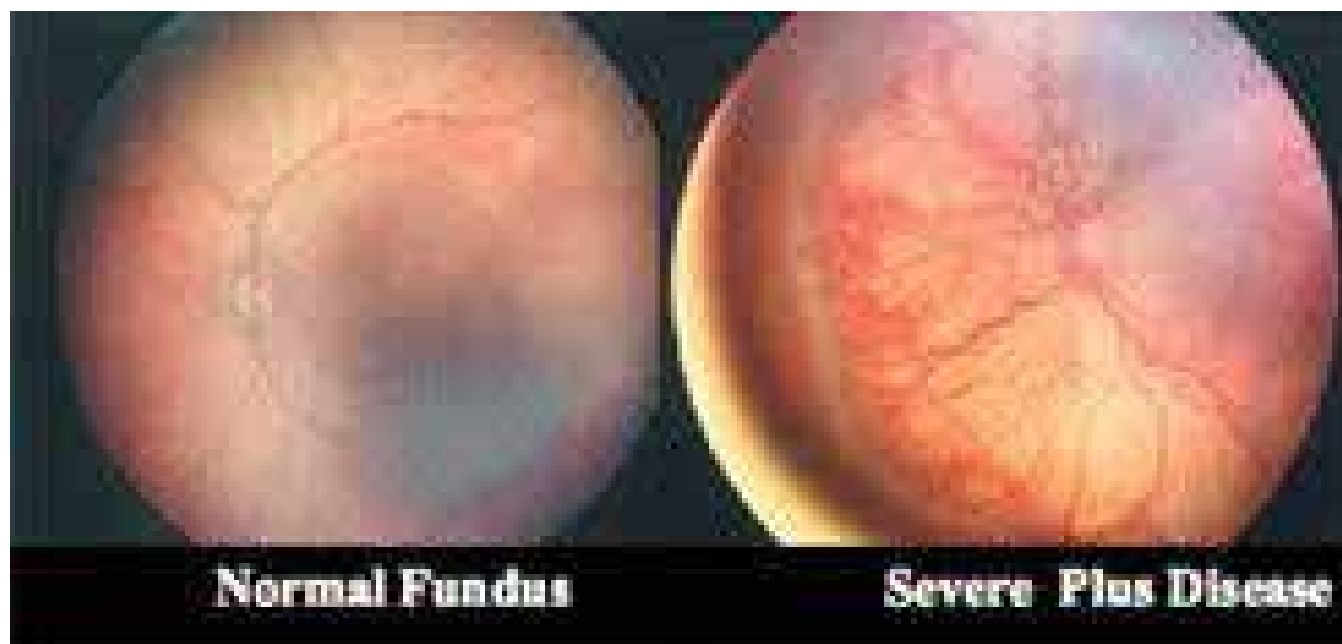

Figure 10. Fundus photography of plus disease in ROP. Photographs of the posterior pole of human infants demonstrating the normal vascular pattern (left), and venous dilation and arteriolar tortuosity of "plus disease" (right). RetCam photos courtesy of Massie Labs (now Clarity Medical Systems, Inc.), Pleasanton, CA.

32% of the time ( $p=0.004$ ) [127]. This suggests that systemic oxygenation status does effect rates of progression in human ROP if administered before plus disease occurs. This has been replicated in the mouse and kitten models, where the neovascularization and VEGF expression were both reduced when oxygenation status was increased [36,39,90]. It also suggests that when plus disease develops, there is a major change in the pathophysiologic process that is occurring, and it is likely to lie in the complex mix of proangiogenic and antiangiogenic mechanisms ongoing in the retina. We do not yet understand what happens in ROP to result in plus disease, but progression to early retinal detachments rarely ever occurs without the retina developing plus disease first.

The STOP-ROP trial disappointed clinicians and bench scientists who sought a gentle intervention (supplemental oxygen) allowing infants with ROP to complete spontaneous involution and healing of prethreshold ROP. However, it also suggested that the key finding of “plus disease” is a greater turning point in the control of ROP than was previously suspected, and that it should be further investigated in order to understand this developmental retinopathy.

#### SESSION 2F: CAN EARLY OXYGEN RESTRICTION PREVENT ROP AND IS IT SAFE?

##### Contributors: Cynthia Cole

Oxygen is the one of the most common neonatal therapies [129]. Unfortunately, very premature infants are particularly sensitive to its toxic effects [130-133]. The optimum range of oxygen saturation in the first few weeks is unknown and no randomized trial has addressed this question [134,135]. Thus, oxygenation management of Extremely Low Gestational Age Neonates (ELGANs; under 28 weeks gestation) is a major dilemma and challenge.

The intense interest in oxygenation of ELGANs is driven by concerns that current practices in many nurseries target oxygen saturation ( $SpO_2$ ) ranges above 90% and that higher  $SpO_2$  ranges appear to contribute to oxygen-related morbidities, such as severe ROP and chronic lung disease (CLD). ROP and CLD are both associated with subsequent neurodevelopmental impairment. CLD is also associated with poor growth and long-term respiratory morbidity. These concerns are further intensified by findings from recent cohort studies which suggest that lower  $SpO_2$  policies (less than 90% saturation) and strict oxygenation management are associated with less ophthalmic and pulmonary morbidity without adverse effect on mortality, neurodevelopment, and growth [136-139].

Proponents who favor higher  $SpO_2$  targeted ranges (over 90%) are concerned that the lower saturation approach of oxygen therapy may be “insufficient oxygen” and that this would lead to poor growth, neurodevelopmental impairment, and possibly increased mortality. Additional concerns are that restrictive oxygen therapy would increase patent ductus arteriosus, raise pulmonary vascular resistance, and increase apnea and bradycardia. Numerous newborn animal studies clearly demonstrate evidence of OIR [55,140-144]. Ashton et al. [28,141] showed that exposure of newborn kittens to lower oxygen

concentrations (10-15%) for 10 days resulted in mild neovascularization. Phelps et al. [145] showed that continuous exposure to lower oxygen (13% or 17% from birth through 3 weeks) facilitated or even accelerated growth of retinal vessels in kittens. In contrast, breathing 21%, 30%, and 40% oxygen increasingly impaired retinal vessel development up to complete vessel ablation when reared breathing 80% oxygen. McColm et al. [146] reported the effect of oxygen fluctuations around different mean oxygen levels (17%, 21%, 24%) on retinal vessel development in rat pups. Rats raised in a 17% variable oxygen environment developed less severe vascular abnormalities than those raised in variable oxygen environment around a higher mean of 21% and 24%. Research by McColm et al. [146] provides additional evidence that exposure of immature retinas to lower oxygen, even with oxygen lability, reduces abnormal vessel development and that small increases in oxygen with oxygen lability contributes to abnormal retinal development. Analyses of oxygen fluctuations around different mean oxygen concentrations (17%, 21%, 24%) on the rat pups' lungs and central nervous system is pending (personal communication, J. McColm and N. McIntosh).

*Human studies:* The first multicenter, randomized clinical trial involving neonates demonstrated that restricted prolonged oxygen therapy reduced the risk of cicatricial retrolental fibroplasia (RLF, as ROP was initially known) by two thirds compared to unrestricted prolonged oxygen therapy [147-149]. Two separate meta-analyses of the early RLF trials [37,78,149-152] reaffirmed that restricted oxygen was associated with reduction, though not complete elimination, of both overall RLF and severe RLF. Inappropriate extrapolation of results from the RLF trials of the 1950s led to the belief that RLF could be reduced if oxygen concentrations did not exceed 40% [147]. Widespread restriction of oxygen therapy to no more than 40% for premature infants was associated with a dramatic reduction in blindness due to RLF. Unfortunately, the uncritical acceptance and untested restriction of oxygen therapy in the manner practiced after the RLF trials also resulted in increased mortality and cerebral palsy [153,154]. For every infant whose sight was saved, it is estimated that 16 died and many others developed spastic diplegia [155,156].

Four recent cohort studies suggest that lower rather than higher oxygen saturation alarm limits or policies in very premature infants may reduce severe ROP and chronic lung disease and improve growth without increasing adverse outcome [136-139]. Tin et al. reported that lower  $SpO_2$  alarm limits correlated with improved outcomes in infants born less than 28 weeks gestation [136]. Alarm limits for  $SpO_2$  in four intensive care units ranged from 70-90% to 88-98%. Babies in the unit with  $SpO_2$  alarm limits of 70-90% had less ROP surgery than babies in the NICU with  $SpO_2$  alarm limits of 88-98% (6.2% compared to 27.2%; 80% relative risk reduction [RRR];  $p<0.01$ ). Survivors from the NICU with  $SpO_2$  alarm limits of 70-90% (compared to survivors from the NICU with  $SpO_2$  alarm limits of 88-98%) were ventilated fewer days (13.9 compared to 31.4 days), fewer needed oxygen at 36 weeks postmenstrual age (18% compared to 46%; 61% RRR), and fewer were below the third centile for weight at discharge (17%

compared to 45%; 62% RRR;  $p < 0.01$  in all). Survival (52% compared to 53%) and cerebral palsy (15% compared to 17%) at one year were similar. In a preliminary analysis of 2 and 10 year outcomes of this same cohort who received care in nurseries with “low” (70-90%) or “high” (88-98%) targeted SpO<sub>2</sub> alarm limits, Tin et al. [157] recently presented that there was no difference in survival with or without disability.

Anderson [137] reported that units with functional SpO<sub>2</sub> upper limits of 92% and less compared to over 92% had less Grade III/IV ROP (2.4% compared to 5.5%;  $p < 0.001$ ) and less ROP surgery (1.3% compared to 3.3%; 61% RRR;  $p < 0.037$ ). Sun [138] studied 1544 infants weighing under 1 kg in units with upper limit SpO<sub>2</sub> of 95% or less compared to over 95%. Units with the lower targets had less stage 3 ROP (10% compared to 29%;  $p < 0.001$ ), surgery (4% compared to 12%; 67% RRR;  $p < 0.001$ ), chronic lung disease (27% compared to 53%; 49% RRR;  $p < 0.001$ ) and similar mortality (17% compared to 24%).

Chow et al. [139] reported the four year experience of a new strict oxygenation management policy which emphasized avoidance of extreme swings in oxygen saturation, new SpO<sub>2</sub> target ranges of 83-85% to 93% for infants up to 32 weeks and sick infants. Compared to historic controls before (1997) and after (1999-2001) implementation of the new protocol, ROP stage 3-4 decreased from 12.5% to 2.5% ( $p = 0.01$ ) and threshold from 4.4% to 1.3% in infants with birth weight under 1500 g. Although numbers for other outcomes were small, there was no increase in bronchopulmonary dysplasia, intracranial hemorrhage, cerebral palsy, hearing loss, or mortality. Survival tended to improve after the protocol change (81% to 90% for infants under 1.5 kg; 48% to 75% for infants between 0.5 and 0.75 kg).

Schulze et al. [158] reported in ventilated preterm infants ( $n = 20$ ; 25-33 weeks gestation, age 11-96 h) that a fractional SpO<sub>2</sub> range of 89-92% compared to 93-96% permitted less oxygen exposure without causing compensatory increase in cardiac output or compromising tissue oxygen delivery or oxygen consumption. They concluded that “lower” SpO<sub>2</sub> allowed for less oxygen exposure without deleterious cardiovascular effects or compromise in systemic oxygen delivery.

Skinner et al. [159] studied hemodynamic effects of the SpO<sub>2</sub> ranges 84-88%, 95-97%, and 96-100% (10-15 min) in 18 infants with respiratory failure (mean gestational age 31 weeks, range 28-36 weeks; age 9 to 76 h). Increasing the saturation from 84-88% to 95-97%, did not significantly change pulmonary artery pressure. Studies during acute hyaline membrane disease failed to show a convincing link between pulmonary arterial pressure and arterial oxygenation [160,161]. This is in contrast to studies of babies with established bronchopulmonary dysplasia (BPD) that demonstrated increasing SpO<sub>2</sub> is a potent pulmonary vasodilator [162,163].

Bard et al. [164] found that a decrease in SpO<sub>2</sub> from 95% to 90% in preterm infants at a mean age of about 62 h did not effect pulmonary circulatory hemodynamics, or ductus arteriosus.

Conclusion: Despite accumulating evidence that restricted oxygen management may be beneficial in reducing oxygen-

related morbidities such as severe ROP and chronic lung disease, the safety and efficacy of this goal has not been demonstrated in a clinical trial. Even if a lower SpO<sub>2</sub> range decreases rates of ROP, it is not known if this potential benefit may be offset by possible increased rates of adverse outcomes such as mortality and neurodevelopmental delay or later learning disorders. Lack of definitive evidence as to what SpO<sub>2</sub> range maximizes benefit and minimizes harm in premature infants provides the ethical and scientific imperative to study untested, current practices. A pragmatic, randomized, masked, clinical trial is needed to define an optimum target SpO<sub>2</sub> range.

### SESSION 3A: ROP - A LIFETIME DISEASE

#### Contributors: Michael Repka, John Flynn

Numerous problems associated with ROP continue to confront physicians. In the developed and developing world alike there is great difficulty ensuring adequate availability of eye examinations for ROP and facilities with experienced treating physicians. Results of the Early Treatment Study which found a benefit of early treatment will only serve to increase those demands as these results are translated into clinical practice necessitating more frequent examinations. Screening for ROP may be eased in the future by the implementation of new imaging technologies. Advanced ROP (stages 4 and 5) remains difficult to treat successfully, but good visual outcomes have been found in uncontrolled series after lens-sparing vitrectomy for stage 4A. Beyond childhood, serious ROP confronts patients with retinal detachment, early cataract formation, and myopia, aspects of the disease which need to be taught to all ophthalmologists.

### SESSION 3B: MANAGEMENT OF ATYPICAL STAGE 3 AND STAGE 4 ROP

#### Contributors: Michael Trese

As smaller and smaller babies are kept alive, an increased incidence of posterior ROP has been observed. With this posterior disease, the appearance of neovascularization changes from the typical neovascularization extending into the vitreous cavity, anterior to the retinal ridge, to more flat neovascularization without ridge tissue. This appearance now has become more familiar to the ophthalmologist, and with that the treatment pattern has changed.

*Treatment of atypical posterior stage 3 ROP:* All would agree that treatment should be to the avascular retina and should include the avascular retina that is beneath the frond of flat neovascularization that lies along the retinal surface. The treatment is also extended anterior to the area of, but not including, the shunt vessels. These vessels have been referred to as “naked” shunt vessels as they are not enclosed in ridge tissue. By including this area of avascular retina, the chance of progression to retinal detachment is reduced. The treatment pattern however does produce small amounts of punctate hemorrhage in the area of the flat neovascularization. This aggressive posterior disease, however, can still lead to retinal detachment, even with appropriate treatment pattern and treatment timing. Recent evidence for the need for this timing has been contributed by the Early Treatment Retinopathy of Pre-

maturity Study. When such detachments occur, we aim to detect them early for further intervention.

*Treatment of stage 4 retinal detachment:* We seek to detect these retinal detachments at the 4A stage. With the advent of lens-sparing vitrectomy for stage 4A ROP, we have found that we are often able to halt the progression to stage 5 ROP and to achieve retinal reattachment in a high percentage of eyes ranging from 86 to 90+% [165-167]. In addition, we have found that by operating on eyes before the center of the macula detaches, our visual results can also improve, with measured acuity ranging from 20/20 to 20/200, as reported by Prenner et al. [168]. The circumstance of timing of lens-sparing vitrectomy is based on the natural history observations of the CRYO-ROP study, which showed that in eyes with a postmenstrual (PMA) age consistent with active disease (up to 50 weeks PMA) that progression to stage 5 in eyes with 12 ROP sectors (the 3 ROP zones with a clock superimposed) of retinal detachment were as high as 92%. In addition, unfavorable outcomes were present in eyes that had as little as 1 to 3 sectors of retinal detachment at an active period. Therefore early intervention with vitrectomy for stage 4A certainly seems appropriate.

The risks of vitrectomy include infection, endophthalmitis, and damage to the lens or retina, which could render the child blind. If retinal tears are present and unable to be repaired, blindness is also likely. The risk, however, is much less than the risk of the eyes progressing to stage 5 disease. I think in most centers now vitrectomy for stage 4A is an accepted procedure.

### SESSION 3C: ROP: LATE COMPLICATIONS IN THE BABY BOOMER GENERATION (1946-1964)

**Contributors: Bradley Smith, William Tasman**

Prior to the 1940s, ROP was an unknown disease, in part because severe prematurity was usually fatal. The period between the 1940s and the introduction of ROP treatment in the 1980s resulted in a cohort of baby boomers with ROP that escaped initial treatment. While the disease continues to affect infants of especially low birth weight and gestational age [169] effective treatment is now available with cryotherapy or laser [100,170,171]. Complications of more severe stages of ROP include myopia, early development of cataracts, iris neovascularization, glaucoma, retinal pigmentation, retinal folds, dragging of the retina, lattice-like degeneration, retinal tears, and, rhegmatogenous and exudative retinal detachments [172-177]. This report presents a review of older children and adults with ROP born during a time when neither a generally accepted form of treatment nor the definitive international classification of ROP (ICROP) was available [96,99].

*Participants and methods:* The study population included all referral patients aged 45 years or older from the authors' practice who were diagnosed with ROP as infants. After approval by the Institutional Review Board, charts were reviewed for birth weight, gestational age, present age, gender, posterior segment pathology, prior surgery, refractive error, phakic status, glaucoma and best-corrected visual acuity as measured with the Snellen charts.

*Findings:* Forty-seven patients were identified with 86 eyes (8 were enucleated). The mean current age was 49.9 years with a range of 45 to 56 years. Birth weights (known in 36 patients) ranged from 680 to 2438 g with a mean of 1251 g; the mean gestational age (known in 32 patients) was 28.2 weeks with a range of 20 to 36 weeks recorded. Thirty-three patients (70.2%) were female and 14 were male (29.8%) suggesting that females may have had a greater tendency to survive than did males as previously reported [178]. In a recent database review of Jefferson Hospital's neonatal intensive care nursery, however, babies 1250 g or less born between June 1995 and August 2003 had a 24.1% prevalence of stage 3 ROP for each gender.

*Posterior segment:* Seventy-six of the 86 eyes (88.4%) had posterior segment pathology due to ROP. The remaining 10 eyes demonstrated other forms of regressed ROP. Retinal dragging was the most common posterior segment pathology occurring in 29 of the 86 eyes (33.7%).

*Retinal detachments:* Retinal detachments occurred in 22 eyes (25.6%): five exudative and 17 rhegmatogenous. The exact date of retinal detachment onset was known for 11 eyes. The average age of onset for all retinal detachments was 35 years of age with a range of 14 to 51 years. Three eyes with exudative detachments were successfully reattached using cryotherapy, scleral buckling, and vitrectomy with buckling. Two eyes treated with scleral buckling alone failed to reattach. Twelve eyes with rhegmatogenous retinal detachments were successfully buckled and two were reattached after vitrectomy with scleral buckling. Vitrectomy was unsuccessful in one eye as was scleral buckling in two others. In all, 17 of the 22 eyes with retinal detachments (77.3%) were reattached. Two of the failures were exudative detachments and three were rhegmatogenous.

Nine eyes (10.5%) had retinal pigmentation and 8 (9.3%) had lattice-like degeneration. Retinal tears occurred in seven eyes (8.1%) and were treated with cryotherapy (five eyes) and laser (two eyes). Six eyes (7.0%) had retinal folds and five eyes (5.8%) had posterior vitreous detachments. The prevalence of macular holes, epiretinal membranes, chorioretinal scars, and retinal pigment epithelium changes was 2.3% each. Lacquer cracks occurred in one eye, as did a macular star (1.2%).

*Acuity and refractive errors:* The best-corrected visual acuity (BCVA) was 20/30 or better in 23 of the 84 eyes that could be tested (27.4%; Table 1). Eighteen eyes (21.4%) had a BCVA between 20/30 and 20/200 while 43 eyes (51.2%) were 20/200 or worse.

The refractive error was known for 43 of the 86 eyes (Table 2). Thirty-nine of 43 eyes (90.7%) showed some degree of myopia ranging from -0.50 to -22.00 D with a mean of -5.71 D. Fourteen eyes (32.6%) were highly myopic ( $\leq -6.00$  D), 19 (44.2%) were moderately myopic ( $> -6.00$  D but  $\leq -2.00$ ), and six (14.0%) were mildly myopic ( $> -2.00$  but  $< \text{zero}$ ). Four eyes (9.3%) were either emmetropic or hyperopic. Only ten refractions were known for the 20 eyes that received a scleral buckle. The range for this subgroup was from -0.50 to -6.25 D with a mean of -3.63 D.

**Lens status:** Fourteen of the 86 eyes (16.3%) had a clear natural lens while the remaining 72 eyes (83.7%) had a cataract, implant, or were aphakic. Stated another way, 35 patients (74.5%) had cataract surgery on one or both eyes while only 12 (25.5%) retained their natural lenses. Nuclear sclerosis was the most common type of cataract occurring in 13 of the 29 phakic eyes (44.8%) who had not undergone cataract extraction.

**Cornea and glaucoma:** Band keratopathy developed in five eyes (5.8%) and two eyes (2.3%) had opaque corneas. The remaining 79 eyes (91.9%) had clear corneas. Fourteen of the 86 eyes (16.3%) had some form of glaucoma. Six (7.0%) had narrow angles treated with laser peripheral iridotomy. Open-angle glaucoma occurred in five eyes (5.8%). Three eyes (3.5%) were diagnosed with neovascular glaucoma. One was treated with panretinal photocoagulation (PRP), one with a shunt tube, and one with a shunt tube in addition to PRP.

**Discussion:** Eight eyes (9.3%) of the patients in this study were enucleated (indications for enucleation were not known), but these eyes probably represent the terminal consequences of ROP. The remaining 86 eyes available for review all had regressed ROP, and 88.4% had some residual posterior segment pathology. As in previous studies, these findings highlight the need for lifelong follow up of patients who have been diagnosed with ROP [176].

Interestingly, the average age at onset for retinal detachment in this group was 35 years. Twenty of the 22 eyes with a retinal detachment were treated with a scleral buckling procedure for a success rate of 80%, similar to other published series treating late retinal detachments in ROP [176-178]. Two of the unsuccessful cases were exudative retinal detachments.

Previous studies have also demonstrated a correlation between the severity of early acute ROP and the development of myopia [113,173,179,180]. The acute early stage of ROP for each patient in this present study is not known, but was likely to have been severe in order for them to be referred to the retinal practice. Despite regression of disease, 90.7% of the eyes (where refractive information was available) were found to be myopic at the time of review. Twenty-four of 37 eyes (64.9%) were found to have persistence of or progression of myopia at six months of age. Our study also demonstrates a high incidence of myopia in adults with ROP. The refraction was known for half the eyes with a buckle. Eyes with a scleral buckle had a mean of -3.63 D for this group of myopia compared to -5.71 D for the entire study cohort suggests the rate and degree of myopia for most was due to causes other than scleral buckling alone, although a buckle may induce higher myopia.

Glaucoma is another recognized threat to vision in infants with ROP, even with the retina attached [172]. Smith et al. [181] reported three cases of acute-angle closure glaucoma occurring in patients with ROP, and all were treated successfully using miotics and either surgical or laser iridotomy. These outcomes suggest pupillary block as the mechanism. Six of our patients had narrow angles warranting peripheral iridotomies. In this review there was no correlation with posterior segment disease such as retrolental membranes in eight of the 14 cases of glaucoma. Three eyes developed neovascular glaucoma. This was presumed to occur due to stimulation of angiogenic factors from avascular retina leading to neovascularization of the anterior segment. Two eyes were treated with panretinal photocoagulation in an effort to halt the process of neovascularization.

BCVA is the most important measure of outcome. Unfortunately, 51.2% of the eyes in this retrospective review had a BCVA of 20/200 or less. However, good BCVA is still possible despite ROP as demonstrated by Ferrone et al. [182] in his series of patients with marked posterior segment changes secondary to ROP; we had similar results. For example, 13 of 27 eyes (48.1%) with retinal dragging and known BCVA had a visual acuity of 20/60 or better (Table 3). Eyes with only retinal pigmentary change and no other ROP findings were the most likely to achieve good visual function. In contrast only one of six eyes (16.7%) with retinal folds had a BCVA of

**TABLE 1. BEST-CORRECTED VISUAL ACUITY**

BCVA	Number out of 84 known visual acuities
>=20/30	23 (27.4%)
<20/30 and >=20/60	12 (14.3%)
<20/60 and >=20/100	6 (7.1%)
<20/100 and >=20/400	12 (14.3%)
Count fingers	11 (13.1%)
Hand motion	9 (10.7%)
Light perception	4 (4.8%)
No light perception	7 (8.3%)

Best-corrected visual acuity in 84 of 86 ROP eyes.

**TABLE 2. REFRACTIVE ERROR IN ROP**

Spherical equivalent of refractive error	Number out of 43 known refractions
<=-6.00	14 (32.6%)
>-6.00 and <=-2.00	19 (44.2%)
>-2.00 and <= 0	6 (14.0%)
>0	4 (9.3%)

Refractive error in 43 ROP eyes.

**TABLE 3. POSTERIOR SEGMENT PATHOLOGY BY VISUAL ACUITY**

BCVA	Dragging (27 of 29 VAs known)	Retinal detachment (22 eyes)	Retinal tear (7 eyes)	Retinal pigment (9 eyes)	Retinal fold (6 eyes)
>=20/30	9	5	2	3	0
<20/30 and >=20/60	4	5	1	2	1
<20/60 and >=20/100	4	0	0	1	0
<20/100 and >=20/400	3	4 (3 ERD)	2	1	0
Count fingers	2	2 (1 ERD)	2	0	2
Hand motion	3	2	0	1	1
Light perception	2	3 (1 ERD)	0	0	1
No light perception	0	1	0	1	1

The relationships observed between best-corrected visual acuity (BCVA) and ocular pathologies like retinal traction or dragging. Counts for exudative retinal detachments (ERD) are also given.

20/60 or better; this group of eyes had the poorest visual prognosis.

**Summary:** ROP can be a devastating eye disease in premature infants. Developments in treatment such as cryotherapy and laser photocoagulation have reduced vision-threatening complications, but life-long follow up of these patients is required.

**SESSION 3D: ROP IN THIRD WORLD AND MIDDLE DEVELOPED COUNTRIES**

**Contributors: Sjakon Tahija**

Indonesia's population was 206 million, growing at a rate of 1.49% annually, and the gross income per capita in 2002 was US\$710 according to the BPS-Statistics Indonesia. Infant mortality in 2002 was reported by the WHO in 1997 to be between 26 to 39.4 deaths/1000 live births. These statistics would probably categorize Indonesia as being a middle developed country.

Problems in health care in Indonesia are similar to other under or middle developed countries, with limited government resources allocated to areas with the greatest needs. Most likely the problems in management of ROP in Indonesia would also reflect similar situations in other third world and middle developed countries.

The main causes of blindness according to a 1997-1998 Indonesian Department of Health survey of eight provinces are presented in Table 4. When the incidence of population effected by a disease is less than 0.5%, there is usually no special government program. This is why there is a cataract eradication program in Indonesia but none for the other eye diseases.

According to the World Health Organization between 1995-1999, 8% of infants in Indonesia had low birth weights, however there are no data on premature births nationally.

In Indonesia it appears that there are two causes of ROP in neonatal intensive care wards. The first cause of ROP is the relatively recent success in saving low birth weight (LBW) and very low birth weight (VLBW) infants, which has not been matched by an increased awareness to screen for and treat ROP. This is a new problem because previously these infants did not survive. Despite economic problems in Indonesia, there have been very significant advances in private health care, fueled by the demand created by a growing middle class. In most areas of Indonesia, babies with a birth weight of

1500 g or lower do not survive, however, in a few private hospitals it is common for babies with a birth weight of 1000 g to survive, and at times babies with a birth weight of 800 g are being saved. This success in saving LBW and VLBW infants was not followed by awareness in preventing ROP. Consultation to ophthalmologists was usually only done after the baby had stage V ROP. To prevent vision loss from ROP it was necessary to improve awareness of (1) neonatologists usually through personal communication, (2) ophthalmologists by giving courses and training in examining neonates, and (3) the general public by using television and other mass media tools. A high profile legal case against a hospital and neonatologist by the parents of a stage V ROP infant who was not screened in time to be offered peripheral retinal ablation has ironically provided the help needed to draw attention to the need for timely screening in ROP.

The second cause of ROP is the use of high and unmonitored concentrations of oxygen in neonates which are at risk due to septicemia or other reasons. These infants would not normally be classified as high risk for ROP; however, the high concentrations of oxygen used in treatment can cause ROP in neonates who would normally be at low risk. These neonates are usually in government facilities where the main attention is to save their lives. In one case, a child with a birth weight of 2500 g developed ROP. The solution to this problem would appear to be making available instruments to measure oxygen concentration in these neonates.

Our goals are (1) to increase awareness regarding risk factors leading to ROP, (2) to have all neonates at risk of ROP examined by an ophthalmologist, (3) for babies needing treatment to be referred on a timely basis to a hospital with either indirect laser or cryotherapy facilities available, and (4) to provide oxygen monitoring devices to neonatal intensive care wards.

Although in a developing country like Indonesia, ROP is not a serious problem from a public health perspective, it is a great tragedy both for the children affected and their families. It is even more tragic that many of these cases of blindness due to ROP are caused by ignorance of the healthcare providers. Hopefully with better education and some funding for equipment, such as indirect ophthalmoscopes and oxygen monitoring devices, these cases of unnecessary blindness can be avoided in the future.

**SESSION 3E: SCREENING FOR ROP IN THE UNITED STATES?**

**Contributors: John Flynn**

The title of this paper is punctuated with a question mark. Why? It is because I believe this word, "screening," to be a misnomer. The characteristics of a screening procedure [183] and a successful screening program are listed in Table 5 and Table 6.

We ophthalmologists are responsible for performing a diagnostic examination of the premature infant's at-risk eyes. On the basis of that examination, we must make a diagnosis of the presence or absence of ROP, and form a prognosis should ROP be present. Finally, and most importantly, on the basis of

**TABLE 4. BLINDNESS IN INDONESIA**

Blindness etiology	Prevalence	Persons affected
Cataract	0.78%	1,600,000
Glaucoma	0.3%	600,000
Retina	0.1%	200,000
Cornea	0.1%	200,000
Refractive disorders	0.1%	200,000

The main causes of blindness reported by an Indonesian Department of Health survey of eight provinces in 1997-8. Percentages listed are based on the survey result with the number affected extrapolated to the total population.



**TABLE 5. CHARACTERISTICS OF A SCREENING PROCEDURE**

Application of test or procedure to asymptomatic subjects

Classify them by risk of disease

Screening does not diagnose disease

Performed by nonprofessional

Important characteristics of a procedure to be used in a screening program as described by Hennekens et al. [183].

**TABLE 6. CHARACTERISTICS OF A SUCCESSFUL SCREENING PROGRAM**

Disease is appropriate for screening

Disease has a high prevalence in target population

Serious consequences if undetected

Screening is sensitive/specific

Effective treatment is available

Cost effective/ethical

Essential characteristics in applying a screening procedure to a full screening program that is cost effective and prevents morbidity as described by Hennekens et al. [183].

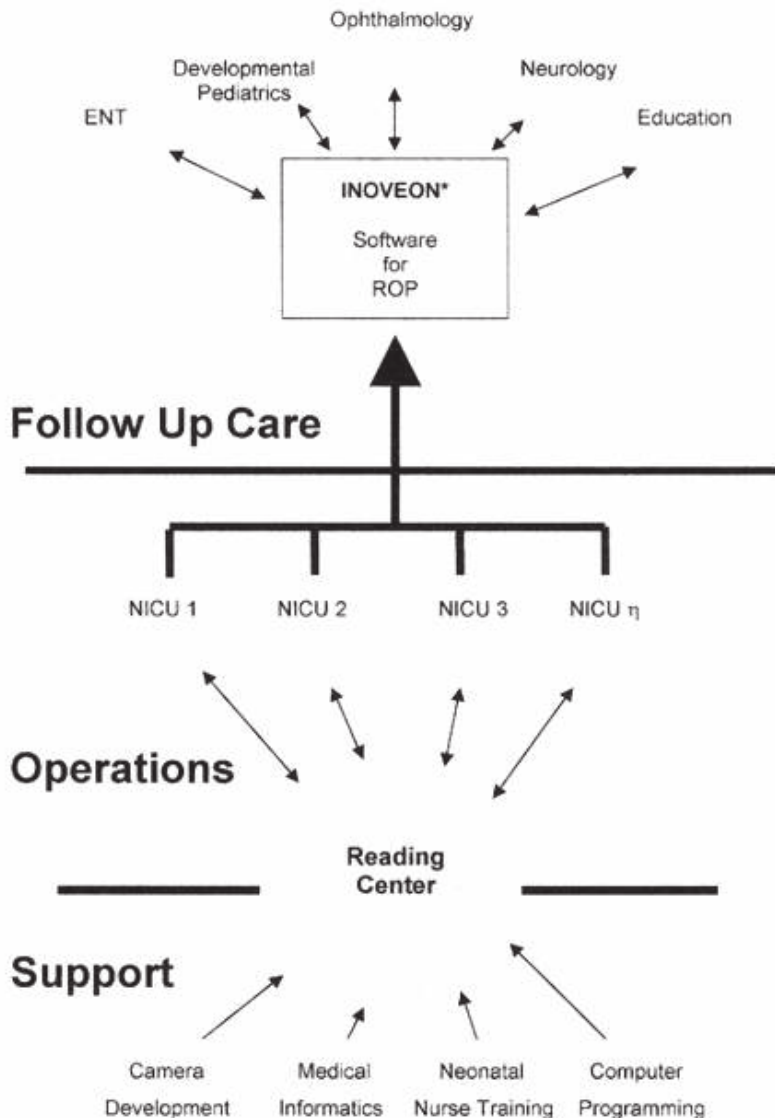


Figure 12. System for screening, diagnosis, and treatment of ROP in the future. Model for ROP management in the future that includes support, operations, and follow up. This proposed system will vastly improve the efficiency of care for the ROP patient and the caregivers.

that examination, we must determine a treatment plan. If ROP is not present then it becomes our obligation to determine when follow up examinations should occur to exclude with reasonable probability ROP as a threat to the premature infant's vision. Is that screening? Most assuredly it is not. If one finds this hard to accept, ask any experienced medical malpractice trial lawyer. Is this a trivial misnomer? Not in the least, for it denigrates the skills we bring to the child's examination. Most likely should it continue to be called "screening" unchecked we will find our colleagues in the third party payor world eager to take us at our valuation of ourselves and reward us accordingly. I have a better name for what we do: Retinopathy of Prematurity Examination and Diagnosis or "ROPED" for those who find acronyms congenial.

Next let us look for the current guidelines for "Screening" (*verbum horribilis*) in the United States [102,184]. These two works, although proffered only as guidelines, may take

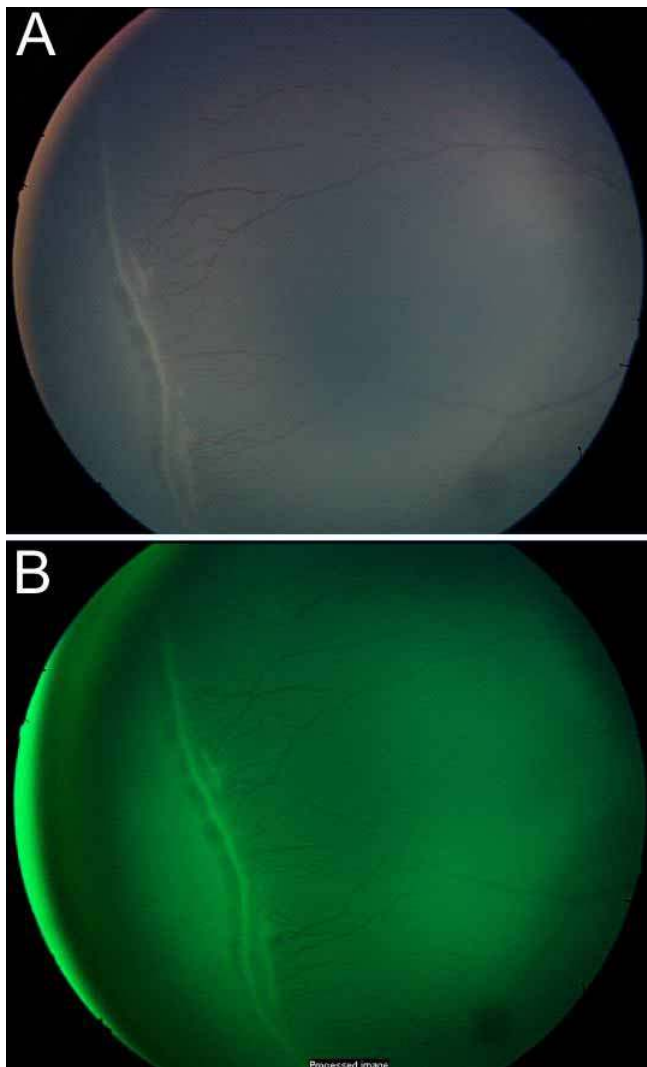


Figure 13. Digital fundus photographs of ROP. **A:** Original digital fundus photograph of ROP. **B:** The original image was enhanced by increasing contrast, subtracting the red and a little blue for better appreciation of the ridge and retinal blood vessels.

on an almost biblical significance, especially in the hands of tort lawyers, in malpractice actions against physicians who may have experienced an unfavorable result in treating an infant with ROP. Most assuredly they are not dogma. They merely represent a mixture of evidence drawn from a large pool of examinations and the intuition/wisdom of clinicians experienced with the disease. All the more reason to word such documents extremely carefully, stressing their limits, and what they do not represent, as much as what they do. Parsimony of verbiage and accuracy in the use of language should be their hallmark. They furnish, at best, a rough road map of a very difficult biological terrain and without providing navigation for the journey itself.

This leaves unanswered, as all guidelines must by their very nature, the nagging question, "Who is uncovered?" Several groups suggest themselves: infants of gestational age or birth weight just above the boundary set in the guidelines. After all how much different is a 33 week premature or 1255 g infant from one just under those boundaries? Others that come to mind are infants outside the guidelines with severe pulmonary/cardiac disease, severe intracranial hemorrhage, infants who have undergone major surgical procedures, are the product of artificial insemination, genetic disease, or blood loss. These are handled today very much on an ad hoc basis. Can we do better? In what follows I would like to make the case that not only can we, but we must.

Modern neonatology is among the most advanced medical specialties. A victim of its own success, that success is being exported over the globe to developing nations and already developed nations. Smaller and gestationally younger infants are being saved in numbers never before experienced. The result is predictable and is being witnessed in nurseries every day. Where good neonatology is in place more 400-500 g, 23-25 week infants are surviving. Ophthalmologists are diagnosing zone I and rush disease ROP [97,185] more frequently than ever before. Resources and manpower necessary to continue such tight surveillance are limited. The safety net is frayed, even in this country for reasons we do not need to discuss. We must, for these two very practical reasons, think anew and act anew. We cannot escape this wave of premature infants alive and vulnerable to this scourge of blindness.

What can we do? Consider that in a year a well-trained pediatric ophthalmologist is responsible for the care of 100 premature infants of <1250 g birth weight and/or 28 weeks gestational age in a level 3 nursery. She performs an average of 5 exams on each infant or a total of 500 exams annually. This is all she can spare from her busy practice and takes her in excess of a half day/week. Of these infants, 40-50 will have ROP, 10 will have stage 3, and 3-5 will require laser therapy. She is obviously performing her professional duty well within the current guidelines and is stretched to the limit to do so.

Now consider another scenario. At her office computer she examines the high quality digital images of the 100 infant's retinas taken by a well trained neonatal nurse. She determines that 60 need only be seen in her office following discharge for routine examinations. For 40, she wants the nurse to take a second image in 1-2 weeks. She satisfies herself that 30 need

only routine office follow up, 10 need her examination and diagnostic skills, and 5 require her superb laser technique. With the time saved, she can extend her highest quality to perhaps ten nurseries considerably extending the radius of her expertise. In so doing, she works closely with the ophthalmologists, neonatologists, and neonatal nurses to bring these units up to the level of her own, thereby providing the best service possible for these infants.

Can we make it better? What if we were to perfect the software, the network links, the camera (a huge problem at present), and the service and support necessary to maintain such a system? What would it look like? Figure 12 is a schematic showing the potential of such a system to accomplish our sought after goal. Do not be fooled by the seeming simplicity of the network. The devil, as always, resides in the details. We at Columbia are focused on three aspects today: the necessary training and testing of reading center personnel, camera development, and the development and testing of the informatics infrastructure necessary to make the network operate seamlessly.

What sort of product might we be looking at? Figure 13, Figure 14, and Figure 15 are examples of the type of high quality digital images we might be examining. With enhance-

ment, mainly increasing the contrast, subtracting the red fully and a little blue, we can enhance the vascular architecture without resorting to fluorescein angiography, although this may once again become the useful research tool it once was in the past [186,187].

As physicians and ophthalmologists, we are faced with a worldwide problem of the scourge of this blinding disease, ROP, not because of any medical error as in the epidemic of the 1940s and 1950s, but because of the spread of the scientific knowledge underlying the success of the worldwide application of the principles of modern neonatology. We cannot turn our back on this challenge. We must think anew and act anew; we cannot escape the inexorable consequences of medical progress.

SESSION 3F: RESULTS OF THE EARLY TREATMENT FOR RETINOPATHY OF PREMATURITY STUDY

**Contributors: William Good, Robert Hardy (on behalf of the Early Treatment for Retinopathy of Prematurity Cooperative Group)**

ROP is one of the most widely and thoroughly studied diseases in pediatric ophthalmology, yet it continues to be a major disability occurring in preterm infants [188,189], and is

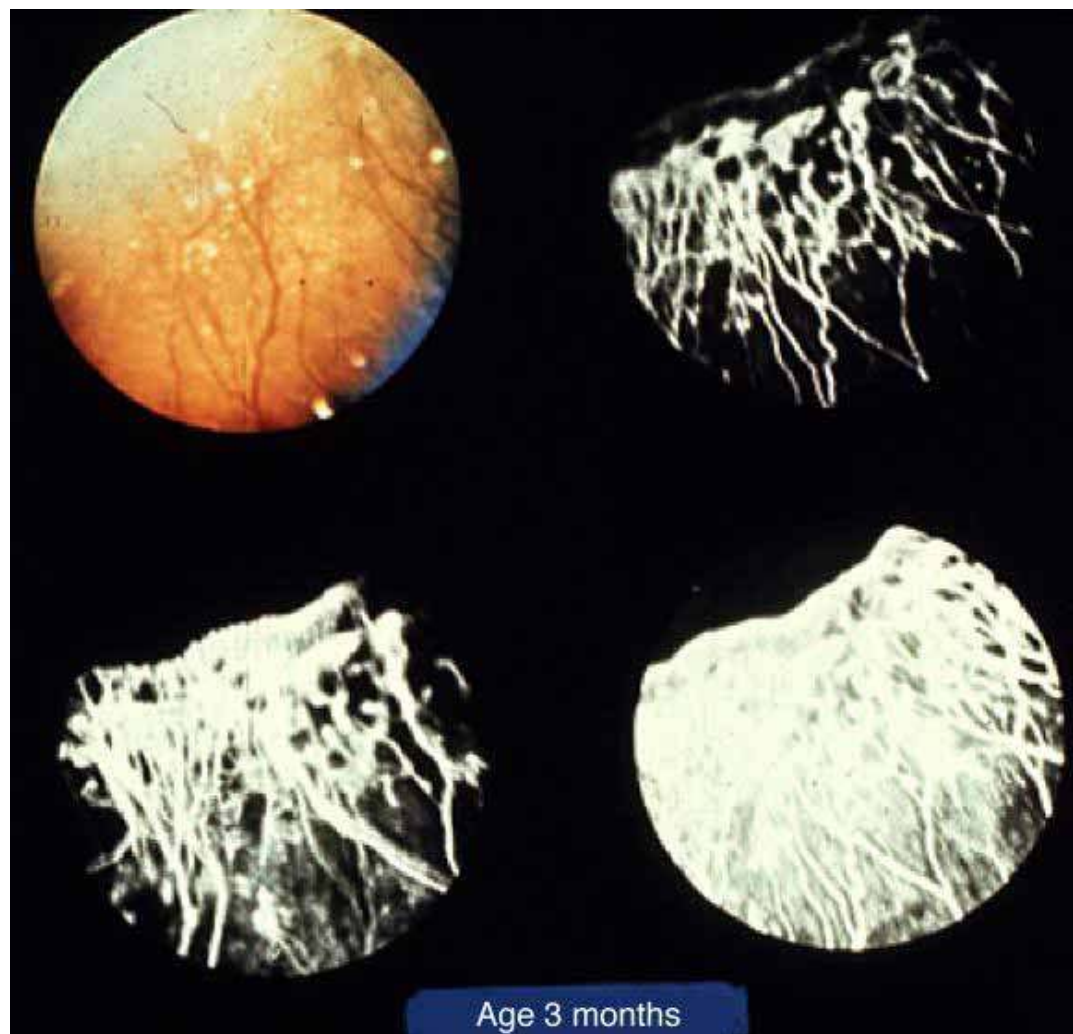


Figure 14. Digital fluorescein angiogram of ROP. Fundus photograph (top left) and series of images from a fluorescein angiogram of an ROP subject with stage 3 ROP.

one of the most common causes of severe visual impairment in childhood [190]. Peripheral retinal ablation was shown to be effective in reducing the incidence of retinal detachment and blindness in the CRYO-ROP study [99]. Retinal ablation in the CRYO-ROP study occurred when a prerequisite amount and severity of ROP was reached (i.e., the threshold for treatment of ROP). In the Early Treatment for Retinopathy of Prematurity study (ETROP), we measured whether earlier treatment of high-risk prethreshold ROP using ablation of the avascular retina results in improved grating visual acuity and retinal structural outcomes compared with conventional treatment.

**Methods:** Study protocols were approved by the review boards of all participating institutions, and parents provided written informed consent prior to infants' enrollment in the study and again at randomization. Infants with birth weights less than 1251 g and birth dates between October 1, 2000, and September 30, 2002, were screened at 26 participating centers. Infants who survived at least 28 days underwent serial eye examinations, with the first screening examination occurring by 42 days after birth. If an infant developed ROP, par-

ents were asked to consent to data collection and a possibly increased frequency of examinations. Study-certified ophthalmologists conducted serial examinations to measure the rate of progression of ROP, development of prethreshold ROP, and development of threshold ROP. Infants with retinal vessels ending in zone I but no ROP or with zone II, stage 2 ROP received follow-up at least once per week. Infants with zone II, stage 1 ROP were examined at least every 2 weeks. If at least one eye reached prethreshold ROP, the infant's demographic and ROP information was entered into the RM-ROP2 risk model to determine the likelihood of progression to an unfavorable outcome in the absence of treatment [103]. Prethreshold was defined as any ROP in zone I, but less than threshold; or zone II stage 2 or 3 with plus disease (but fewer than 5 contiguous or 8 cumulative clock hours of stage 3); or zone II, any amount of stage 3 without plus disease.

If the risk of progression to an unfavorable outcome in the absence of treatment was calculated to be 15% or higher and a second examination by a masked study-certified ophthalmologist confirmed findings consistent with this risk, consent for the randomized trial was obtained and randomization occurred. Eyes that had a risk of 15% or higher were termed high-risk prethreshold. Eyes with less than a 15% risk were termed low-risk prethreshold and received follow-up examinations every 2 to 4 days for at least 2 weeks, until the ROP regressed or the risk progressed to 15% or higher.

Infants with bilateral high-risk prethreshold ROP (n=317) had one eye randomized to early treatment with the fellow eye managed conventionally (control eye). In asymmetric cases (n=84), the eye with high-risk prethreshold ROP was randomized to early treatment or conventional management. High risk was determined using a model based on the CRYO-ROP natural history cohort [103]. At a corrected age of 9 months, masked testers using the Teller acuity card procedure assessed visual acuity. At corrected ages of 6 and 9 months, eyes were examined for structural outcome. Outcomes for the 2 treatment groups of eyes were compared using  $\chi^2$  analysis, combining data for bilateral and asymmetric cases.

**Results:** Results from the 366 infants with follow up are shown in Table 7 and Table 8. Grating acuity results showed a reduction in unfavorable visual acuity outcomes with earlier treatment, from 19.5% to 14.5% (p=0.01). Unfavorable structural outcomes were reduced from 15.6% to 9.1% (p<0.001) at 9 months.

**Conclusion:** The results of this study show that it is possible to identify characteristics of ROP that predict which eyes are most likely to benefit from early peripheral retinal ablation. Based on study data, a clinical algorithm was developed to identify eyes with prethreshold ROP that were at highest risk for retinal detachment and blindness while minimizing treatment of prethreshold eyes likely to show spontaneous regression of ROP. The use of this algorithm circumvents the need for computer-based calculation of low risk or high risk, as was used in this study. Details of this analysis are published [185]. The clinical algorithm shows that in most circumstances, peripheral retinal ablation should be considered for any eye with "type 1 ROP": Zone I, any stage ROP with plus disease;

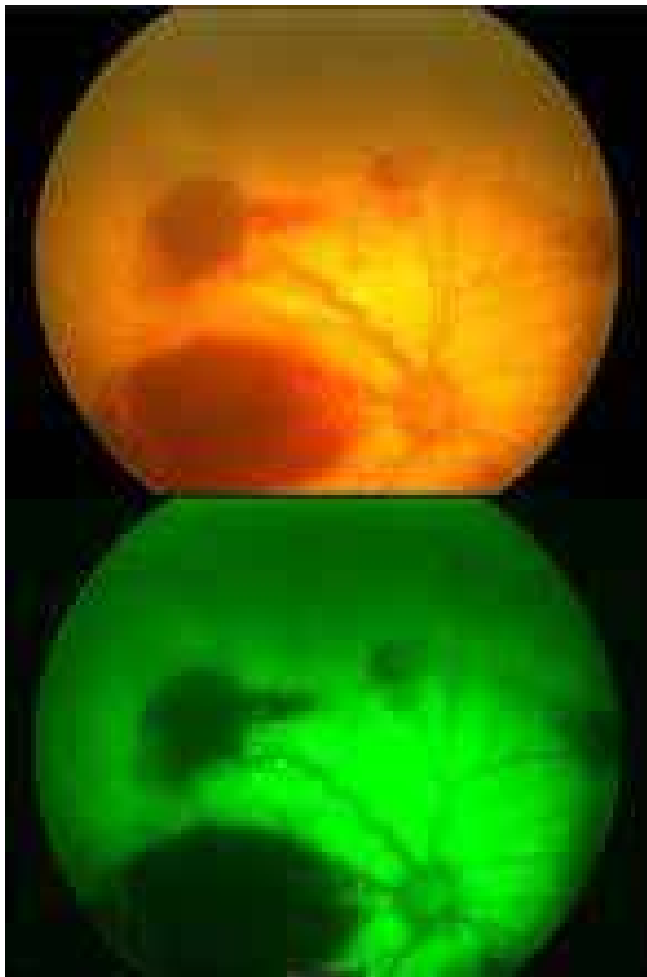


Figure 15. Digital fundus photographs of ROP. Digital fundus photograph (top) of a subject with hemorrhages and severe, zone I disease. The image was enhanced in the bottom photograph by subtracting out the red and blue.

Zone I, stage 3 ROP with or without plus disease; or Zone II, stage 2 or 3 ROP with plus disease.

Plus disease, in this instance, requires at least two quadrants of dilation and tortuosity of the posterior retinal blood vessels and, hence, the presence of significant disease. The algorithm does not take into account all of the other known risk factors (e.g., extent of stage 3 or birth weight), and therefore clinical judgment is required in applying this initial step to the management of ROP. The clinical algorithm also indicates that continued serial examinations as opposed to peripheral retinal ablation should be considered for any eye with "type 2 ROP": Zone I, stage 1 or 2 ROP without plus disease or Zone II, stage 3 ROP without plus disease.

Treatment should be considered for an eye with type 2 ROP when progression to type 1 status or threshold ROP occurs. Even with the addition of early treatment for selected eyes with prethreshold ROP, some eyes will still progress to an unfavorable visual and/or structural outcome. Thus, additional research is needed to identify better methods for the prevention and treatment of severe ROP.

SESSION 4A: FUTURE THERAPIES

Contributors: Gerard Luty, John Penn

Tony Adamis described VEGF as the Swiss Army knife of angiogenesis because this vasoactive factor has so many biological activities including angiogenesis, induction of fenestrations, and inflammatory cell chemoattractant. The VEGF aptamer currently in clinical trials for age-related macular degeneration (AMD) neutralizes only VEGF<sub>164</sub> and the different isoforms of VEGF have different biological activities.

TABLE 7. NINE MONTH GRATING ACUITY OUTCOME FOR RANDOMIZED PATIENTS

	Eyes treated at high-risk prethreshold		Conventionally managed eyes		χ-sq	p
	N	% UF	N	% UF		
Bilateral	287	15.7	287	20.9	7.26	0.007
Asymmetric	43	7.0	36	8.3	0.05	0.82
Total	330	14.5	323	19.5	6.60	0.01

The Grating Acuity assessed with Teller acuity cards was judged as favorable or unfavorable (UF) in each eye at 9 months corrected age. The table shows the number of infants (N) categorized into those who had high risk prethreshold ROP in both eyes (bilateral) or only in one eye (asymmetric). The χ<sup>2</sup> test (χ-sq) for the infants with bilateral ROP was based on pairs for eyes with discordant outcomes (23 infants had an eye treated early with a favorable outcome and an eye managed conventionally with an unfavorable outcome; 8 infants had an eye treated early with a unfavorable outcome and an eye managed conventionally with an favorable outcome). Early treatment significantly improved grating visual acuity outcomes.

Republished with permission of the American Medical Association from Early Treatment For Retinopathy Of Prematurity Cooperative Group. Revised indications for the treatment of retinopathy of prematurity: results of the early treatment for retinopathy of prematurity randomized trial. Arch Ophthalmol 2003; 121:1684-94. Copyright ©2003 American Medical Association. All rights reserved.

Because the aptamer blocks formation of NV but not retinal vascular development, he concludes that VEGF<sub>164</sub> stimulates formation of neovascularization but not normal development of the retinal vasculature. Furthermore, VEGF<sub>164</sub> knockout mice do not get neovascularization in the mouse model of OIR. In this model, the vaso-occlusive process is modulated by leukocytes who have the VEGF receptor FLT-1.

Marty Friedlander has demonstrated that one type of stem cell, hemangioblasts, will home to retina and its developing vasculature. Maria Grant has demonstrated that hemangioblasts will participate in the formation of retinal and choroidal neovascularization. Friedlander suggested that this could be a method to delivery genes for therapy to sites of neovascularization. Friedlander has demonstrated that hemangioblasts injected into vitreous of neonatal mice organize on the astrocyte template and contribute to formation of the retinal vasculature. This appears to be accomplished by R-cadherin related homing, which he suggested might be a useful target in blocking neovascularization in retina. One questioner asked if cord blood could be used a source of autologous hemangioblasts? Although cord blood contains hemangioblasts, Friedlander said it had not been determined if these hemangioblasts could be expanded and live long enough to aid in therapy. Other questions concern how to target them only to sites in the eye and if these cells from marrow actually participate in the normal development of the retinal vasculature.

TABLE 8. NINE MONTH STRUCTURAL OUTCOME FOR RANDOMIZED PATIENTS

	Eyes treated at high-risk prethreshold		Conventionally managed eyes		χ-sq	p
	N	% UF	N	% UF		
Bilateral	289	10.4	290	17.2	11.7	<0.001
Asymmetric	42	0.0	36	2.8	1.2	0.28
Total	331	9.1	326	15.6	12.6	<0.001

The analysis was based on the structural outcome of these eyes observed by the examining ophthalmologist at the 9 month examination and each was classified as favorable or unfavorable (UF). Twenty-four eyes with partial retinal detachment not including the macula (stage 4A) had vitrectomy or a scleral buckle procedure prior to the 9 month examination and are included in this table as having an UF outcome. Stage 4B or 5 eyes were considered UF in this study a priori. There were 292 patients with bilateral ROP and 43 with asymmetric ROP. The structural outcome could not be determined for five of the bilateral eyes, and one of those with asymmetric ROP. The χ<sup>2</sup> test (χ-sq) for the infants with bilateral ROP was based on discordant pairs (25 infants had an eye treated early with a favorable outcome and an eye managed conventionally with an UF outcome; 6 infants had an eye treated early with a UF outcome and an eye managed conventionally with a favorable outcome), and showed a significantly improved outcome for the early treated eyes (p<0.001).

Republished with permission of the American Medical Association from Early Treatment For Retinopathy Of Prematurity Cooperative Group. Revised indications for the treatment of retinopathy of prematurity: results of the early treatment for retinopathy of prematurity randomized trial. Arch Ophthalmol 2003; 121:1684-94. Copyright ©2003 American Medical Association. All rights reserved.

Arup Das has demonstrated that antiprotease strategies can be used to control the formation of intravitreal neovascularization in the mouse model of OIR. BB-94 (inhibits matrix metalloproteinases [MMPs]), B-428, and A6 (inhibits urokinase) significantly inhibit the formation of NV but do not affect normal development of the retinal vasculature in mouse. Soluble TEK or TIE-2 receptor inhibits formation of NV and reduces the production of MMPs.

Maria Grant has developed ribozymes that target receptors important in binding angiogenic growth factors. Ribozymes are tRNA like molecules that enzymatically destroy specific mRNAs. They can be targeted to mRNAs for growth factor receptors. She has successfully made ribozymes that target adenosine receptors, VEGF receptors, and IGF-1 receptors. The ribozymes against the adenosine A<sub>2B</sub> receptor and the IGF-1 receptor inhibit neovascularization in the mouse model of ROP. Although ribozymes are usually delivered to cells with a viral vector, Dr. Grant has shown that they can transfect cells in retina when delivered as naked DNA.

Bill Hauswirth has developed many vectors for gene therapy of retinal degenerations and retinal neovascularization. He has designed vectors with adeno-associated virus (AAV) that have the endostatin, pigment epithelial derived factor, and angiostatin genes that successfully transfect retinal cells and inhibit angiogenesis in the mouse model of ROP. Transfection works well in developing tissues but it has been difficult to target endothelial cells. He is using different promoters to attempt to target endothelial cells. Although it is dubious that viral vectors that exist today could be used in premature babies, future technologies may make this possible.

This session has suggested a panoply of therapeutic agents and strategies for controlling the proliferative stage of ROP. The targets included VEGF and IGF-1, their receptors, and proteases. Delivery could be accomplished by hemangioblasts that home to neovascularization or molecular vectors that could degrade growth factor receptors or cause overexpression of endogenous antiangiogenic agents. Dr. Arnall Patz, to whom this meeting is dedicated, offers some closing thoughts and optimism that these new ideas may become viable therapies.

#### SESSION 4B: ANTI-VEGF STRATEGIES: BIOLOGICAL SPECIFICITY IS ENCODED IN THE VEGF ISOFORMS AND THEIR RECEPTORS

**Contributors: Anthony Adamis, David Shima**

Our appreciation for the biology of VEGF has matured over the last 20 years to the point where VEGF can now be considered a “middle aged” growth factor. VEGF was first identified and partially purified in 1983 by Don Senger in Harold Dvorak’s laboratory [191]. In its infancy, VEGF was known as vascular permeability factor (VPF), based on its potent effects on vascular permeability. In 1989, Leung et al. [192] at Genentech, and Keck et al. [193] at Monsanto cloned and characterized VPF’s cDNA. It was also demonstrated that VPF was an endothelial cell mitogen that promoted angiogenesis in vivo. VPF was rechristened VEGF, and the latter term has seen widespread adoption.

With these two new ascribed bioactivities, VEGF was viewed as a potentially important angiogenic factor and consequently was studied in several ophthalmic models. VEGF was shown to be produced in ocular tissues [194] and VEGF levels were demonstrated to rise synchronously and in proportion to the degree of pathological neovascularization in the nonhuman primate eyes [86]. Similar correlations with pathological neovascularization were seen in fluids sampled from human eyes at the time of surgery [88,89]. In an adult nonhuman primate model, VEGF was shown to be necessary [87] and sufficient [195] for triggering pathological iris neovascularization. In the context of OIR, it was demonstrated that VEGF blockade resulted in suppressed pathological retinal neovascularization [84]. VEGF was also shown to be necessary and sufficient for corneal [196] and choroidal neovascularization [197]. Taken together, these observations generated excitement about the potential for using anti-VEGF strategies in the prevention and treatment of pathological neovascularization in human ophthalmic diseases.

As VEGF was studied in laboratories worldwide, it became apparent that its biological functions were even more varied and significant than originally believed. Consequently, our knowledge of VEGF biology has grown significantly as the molecule has entered “middle age.” In the last decade, the important role VEGF plays in both vasculogenesis (the de novo formation of blood vessels) and angiogenesis (the sprouting of new vessels from existing ones) has been documented [198,199]. In addition to these bioactivities, it is now known that VEGF is a critical survival factor for endothelial cells [67], provides spatial guidance for vascular sprouts [200], and is instrumental in the formation and maintenance of fenestrae (cellular structures found in certain highly specialized normal tissues such as the choriocapillaris) [201]. VEGF is also a potent inflammatory cell chemoattractant [202] and a neuroprotection factor [203]. Due to its ability to perform these many functions, VEGF has been termed the “Swiss army knife” of vasoactive factors.

How can one growth factor be responsible for selectively eliciting such disparate biological responses, as seems to be the case? The answer may reside in the various VEGF isoforms and receptors. VEGF (VEGF-A) exists as a single gene with multiple alternatively spliced transcripts that encode for at least five distinct protein isoforms, ranging in length from 121 to 206 amino acids [204,205]. Alternative splicing results in isoforms with varying affinities for heparin, affecting VEGF tissue distribution following secretion. The domains that promote binding to charged heparin-like moieties are encoded in exons 6 and 7. The smallest VEGF isoform (VEGF<sub>121</sub> in humans, VEGF<sub>120</sub> in rodents) does not bind heparin to any significant degree and is able to diffuse freely. The larger isoforms, VEGF<sub>164</sub> and VEGF<sub>188</sub>, bind heparin-like moieties with increasing affinity and tend to concentrate on the cell surface and basement membranes.

Using genetically altered mice that expressed a single VEGF isoform, Shima’s laboratory evaluated the role of the heparin-binding properties of different VEGF isoforms on the

branching morphology of blood vessels in the brain [200,206]. Compared to wild-type mice, mice expressing only VEGF<sub>120</sub>, a non-heparin binding isoform, had fewer branches at the capillary level in the CNS. In contrast, when mice that were engineered to express only VEGF<sub>188</sub>, a heparin-binding isoform, capillary hyper-branching was observed.

VEGF is required for both physiological and pathological blood vessel growth, although these vessels differ both anatomically and physiologically. This paradox was demonstrated in the neonatal models of OIR. These models expose neonatal animals to a hyperoxic environment, followed by an environment of relative hypoxia, to produce pathological retinal neovascularization characterized by tufts of new vessels that break through the internal limiting membrane. The models also exhibit physiological neovascularization when the ischemic retinal parenchyma is revascularized upon exposure to room air. As rodent eye development progresses postnatally, formation of the normal and pathological retinal vasculature can be followed relatively easily in this species. The roles of specific VEGF isoforms were evaluated using the above models and a technique which detects the presence of leukocytes in the retinal vasculature [73]. Normal retinal vessel development in animals exposed to room air alone was studied in parallel. It was observed that many leukocytes are present at the leading edge of pathological, but not physiological, neovascularization. When absolute VEGF protein levels also were measured, a modest increase in the overall VEGF levels during both normal retinal development and proliferative retinopathy was found. A more striking change was demonstrated in the relative expression of different isoforms. While VEGF<sub>120</sub> and VEGF<sub>164</sub> were expressed similarly during physiological neovascularization, the expression of VEGF<sub>164</sub> predominated during pathological neovascularization [73]. This is consistent with previous work in which it was demonstrated that VEGF<sub>164</sub> is pro-inflammatory when injected into the vitreous, triggering the sticking of leukocytes throughout the retinal microvasculature [207].

To confirm that VEGF<sub>164</sub> is preferentially involved in the model of pathological neovascularization, we used an anti-VEGF aptamer now in development for the treatment of age-related macular degeneration and diabetic macular edema [208]. Aptamers, a new class of therapeutics, maintain a highly specific three-dimensional conformation that allows binding to a molecular target in a manner similar to the binding of antibody to antigen. The aptamer (pegaptanib; Macugen™; OSI Eyetech Pharmaceuticals, Lexington, MA) binds very specifically to VEGF<sub>164</sub> (VEGF<sub>165</sub> in humans) and neutralizes the isoform's ability to bind to its cognate receptors VEGFR-1 and VEGFR-2. We compared the effects of administration of pegaptanib with administration of a soluble fusion protein of VEGFR-1/Fc that blocks the activity of all VEGF isoforms in the proliferative retinopathy model [73]. Blocking VEGF<sub>165</sub> with pegaptanib was as effective as blocking all the isoforms in preventing pathological neovascularization. When we treated rodents that were undergoing physiological revascularization of the retinal parenchyma that occurs in this model (i.e., in which vessels do not penetrate the internal lim-

iting membrane), pegaptanib had no effect. In contrast, pan-isoform blockade with VEGFR-1/Fc inhibited physiological vessel growth. These data suggested that targeting VEGF<sub>164</sub> selectively inhibits the pathological vessels but spares the normal vessels during the revascularization phase.

Additional data in isoform-specific knockout mice supported the conclusion that VEGF<sub>164</sub> plays a key role in pathological neovascularization. When withdrawn from a hyperoxic environment, neonatal mice lacking VEGF<sub>164</sub> expression (but retaining expression of the VEGF<sub>120</sub> and VEGF<sub>188</sub>) did not develop pathological neovascularization while the wild-type mice developed proliferative retinopathy [73]. On examination of the retinas of the VEGF<sub>164</sub> null mice, no tufts breaking through the internal limiting membrane were observed and physiological retinal vascular development occurred quite normally. Therefore, experiments with VEGF<sub>164</sub> knockout mice and those using aptamers to block VEGF<sub>164</sub> resulted in the same conclusion; VEGF<sub>164</sub> is the predominant isoform responsible for pathological but not physiological neovascularization.

While these findings show that variations in isoform expression are important determinants of VEGF biological activity, the distribution and activity of VEGF receptors also have been shown to confer specificity. Among the various VEGF receptors, the major endothelial cell receptors are VEGFR-1 (also known as Flt-1) and VEGFR-2 (also known as KDR in the human with Flk-1 being the murine homolog). Interestingly, while knocking out either KDR or Flt-1 was lethal, inactivation of just the receptor signal transducing domain for Flt-1 allowed for normal development and angiogenesis [209]. It has been suggested that, at least on endothelial cells, soluble Flt-1 may serve as a competitor for VEGF binding to VEGFR-2, thereby controlling VEGF levels in the microenvironment.

The specific roles of VEGF receptors in retinal development in neonatal mice and the OIR model was further explored by Lois Smith's group. The VEGFR-1-specific ligand, human placental growth factor-1 (PlGF-1), and the VEGFR-2-specific ligand VEGF-E, were used to delineate the specific functions of the two VEGF receptors [91]. VEGFR-1 (Flt-1) was found to be preferentially expressed in retinal vessels early in development and its expression greatly increased during normal retinal vascularization. VEGFR-2 was detected primarily outside the vasculature in the neural retina (this is consistent with a growing body of evidence supporting the importance of VEGF in neuroprotection) and its levels did not change during normal vascularization. PlGF-1 was able to block hyperoxia-induced vaso-obliteration, whereas VEGF-E had no effect on blood vessel survival. These studies support the notion that variability in the expression and location of VEGF receptors, in addition to the previously described variability in VEGF isoforms, are important determinants of VEGF biology.

The role of leukocytes in vaso-obliteration and vascular remodeling has been a subject of recent interest. Using rodent models, we identified a temporal association between the arrival of leukocytes and a reduction in vascular density during oxygen-induced vaso-obliteration [210]. When leukocytes are inhibited by specifically deleting the CD18 receptor (a cell

adhesion receptor found on certain leukocytes for binding to vasculature) in mice, vaso-obliteration can be reduced. Similarly, rats treated with antibodies that blocked CD18 had significantly less vaso-obliteration than did wild-type animals or those treated with control antibodies. Perhaps there is a way to combine these findings into a unified hypothesis of the role for VEGF in vaso-obliteration, as certain leukocyte cell populations possess functional VEGFR-1 and migrate in response to VEGF<sub>164</sub> via VEGFR-1. The migration of leukocytes is less robust in response to VEGF<sub>120</sub>. Blocking VEGFR-1 eliminates the migration of leukocytes in response to VEGF. We hypothesize that VEGFR-1 prevents vaso-obliteration via a mechanism that involves leukocyte sourced VEGF, as VEGF is known to be made in many leukocyte populations. Those same leukocytes (and their VEGF) can then aid and abet the pathological neovascularization process.

In conclusion, since the bioactivities of VEGF span numerous critical functions, pan-VEGF blockade is more likely to produce unwanted biological effects. The selective targeting of specific VEGF isoforms and/or receptors may therefore be important in the future treatment of pathological neovascularization.

#### SESSION 4C: "STEMMING" VISION LOSS WITH STEM CELLS

##### Contributors: Martin Friedlander

Neovascular eye diseases are the most common causes of vision loss in industrialized nations and represent significant unsolved medical needs today. While most of these diseases involve abnormal new blood vessel growth inside the eye, there are also diseases involving periorbital/ocular proliferation of blood vessels. Hemangiomas are benign, local growths of proliferating endothelial cells that can expand quite rapidly and locally invade tissues and vital organs in the head and neck region of young children. Since the natural history of these tumors involves proliferative, plateau, and involitional phases, studying these tumors can teach us about factors that regulate the normal and abnormal growth of the vasculature. At the other end of the aging spectrum is age-related macular degeneration; this is the leading cause of vision loss in elderly Americans, affecting 15 to 20 million people in this country. Approximately 10-15% of these patients have new blood vessels growing under the retina secondary to the disease. Finally, the leading cause of visual loss of Americans under the age of 55 is diabetes; 16-18% of Americans are diabetic and virtually every one of them will have some form of retinopathy from the disease after 20 years. I mention diabetes because it is a member of a broader class of diseases called the ischemic retinopathies, which of course, includes ROP. In all, we are talking about millions of individuals in this country that suffer visual loss secondary to the growth of abnormal new blood vessels. As mentioned at this symposium, ROP can be thought of as an ischemic retinopathy. Again, it is important to remember that patients with ischemic retinopathies are usually ischemic; the reason children with ROP are making new blood vessels is because there is inadequate oxygenation at the retinal periphery due to developmental arrest secondary to high

oxygen which we need to give these children because their lungs are immature when they come out of the maternal "incubator."

The paradigm of the current therapeutic approach is what I call "slash and burn;" we sacrifice peripheral retina in an attempt to match supply to demand thereby protecting central vision. All of us in the clinics have taken lasers and cryoprobes to the eyes of these patients in an attempt to decrease metabolic demand in the retina by destroying tissue. Lasers are destructive treatments. The other obvious consideration is that tissues in patients with "ischemic retinopathies" are ischemic and rather than destroying the aberrant vessels, we probably should think of ways to normalize and maintain them. I would like to propose a new therapeutic paradigm: rather than inhibiting neovascularization and preventing growth of new blood vessels we should think about encouraging these immature vessels to mature and let them do what the body is trying to do, to bring an adequate blood supply.

Based on recent work from our laboratory and preliminary basic work by many others, we have found that adult bone marrow contains a population of cells that will target to sites of neovascularization in the eye and exert profound vasculo- and neurotrophic rescue effects [211,212]. From presentations at this symposium, it is apparent that ROP is not simply a disease of abnormal proliferation and ischemic nonperfusion but something that profoundly affects the neural components of the retina, too.

So what is the stem cell [213-220]? Our colleagues in hematology and stem cell biology define them as pluripotent cells capable of differentiating into a variety of cell types. They possess the ability to indefinitely self renew, can generate multiple cell types in tissues in which they reside, and can undergo transdifferentiation events. Many of our colleagues in ophthalmology and vision science have made interesting and exciting contributions to this field [221-225]. There are several kinds of stem cells: corneal limbal stem cells; neuroretinal stem cells, which under appropriate conditions can be stimulated to become the adult cells useful for arresting a certain number of pathologies; retinal and iris pigment epithelial cells which under certain conditions have been shown to differentiate into neuronal cells; and, finally, there is the class of cells called hematopoietic stem cells (HSC). It is the hematopoietic stem cells that I will focus on.

HSC reside in our bone marrow and core blood and can differentiate into what we call lineage-positive or lineage-negative cells. By lineage, we refer to their ability to become the formed elements of blood. Thus, lineage-positive HSC contain cells that, under appropriate circumstances, can differentiate into blood cells such as monocytes, neutrophils, platelets, and red blood cells. The cells we are more interested in are the lineage-negative cells, which include a fraction of cells called endothelial progenitor cells (EPC) [226]. These cells can become mature endothelial cells. They reside in the bone marrow and under appropriate conditions can be mobilized into peripheral circulation by a variety of compounds. We know they participate in postnatal angiogenesis in a variety of sites in the body, but their precise phenotypic characterization re-



mains elusive. There are two ways of looking at these stem cells. One is that they are indigenous bone marrow-derived stem cells, which under appropriate circumstances are mobilized from the bone marrow, spill into circulation, and target sites of neovascularization where they can participate in vascular pathology. Our colleagues in other fields have taken advantage of this phenomenon and use them to target sites of vascular collateralization. For example, in cardiology we know that there is a population of these cells which can be mobilized from the bone marrow to target ischemic hearts and peripheral vessels where they can help collateralize ischemic tissue. In fact, these circulating EPC can be used as surrogate markers for determining ones ability to recover from ischemic damage to the heart [227]. Our colleagues in neurology have demonstrated there are a number of these cells which, under appropriate circumstances, can be targeted to and differentiate into neural stem precursor cells, suggesting that these cells have potential to treat a variety of neurodegenerative diseases. Finally, recent data from several people including Maria Grant in Gainesville, Scott Cousin in Miami and Karl Csaky from the NEI, have demonstrated in mouse models of neovascular eye disease that bone marrow mobilized EPCs can participate in the abnormal development of choroidal and retinal neovascular membranes [228,229]. This suggests that in certain neovascular eye diseases, we may want to think about blocking the targeting of these bone marrow mobilized stem cells to sites of abnormal angiogenesis in the retina [230]. This, however, is not what I will be talking about. Instead, I would like to focus on the potential use of these cells in a form of cell-based therapy that targets drugs or trophic molecules to sites of retinal vascular and neuronal degenerative disease.

Mononuclear cells are obtained from the bone marrow of adult mice transgenic for green fluorescent protein (GFP) so that all of the cells obtained are expressing GFP behind the actin promoter. We then use magnetic beads loaded with antibodies to a variety of lineage markers to separate the lineage-positive from the lineage-negative fraction; it is the latter, negative fraction that is enriched for endothelial progenitive cells. These cells can then be injected directly into the vitreous of newborn mice and assessed by scanning laser confocal microscopy for their location and physiological effects. One of the models we use in the laboratory is the newborn mouse; the mouse is born without a retinal vasculature and in this regard is somewhat analogous to the beginning of the 3<sup>rd</sup> trimester human retina. When you stain these newborn mouse retinas with a marker of the vascular extracellular matrix, collagen IV, you note some collagen IV positive structures around the optic nerve, and within 24 h after birth you can see a network of vessels forming. By a week postnatally, these vessels have nearly reached the retinal periphery. At postnatal day 8 (P8), these vessels branch and dive deep so that if you now look at a cross section of the retina, you see a superficial retinal vascular layer and a parallel, deep layer of vessels 40  $\mu$ m from the superficial. By three weeks, a third, intermediate layer has formed. The vessels know how to do this because it turns out when the mouse is born there is already a preformed astrocytic template as evidenced by looking at GFAP-GFP

transgenic mice. At birth these mice contain a template of astrocytes over which the endothelial cells will migrate and form the vasculature. How specific is this interaction between migrating endothelial cells and the underlying astrocytes? It turns out if you take a transgenic mouse in which all the astrocytes are green and inject endothelial progenitor cells from adult bone marrow of GFP transgenic mice into that mouse's eye at P3 or P4 you see that the injected stem cells actually target and adhere to the astrocytes. This is very much analogous to what happens with endogenous vascular endothelial cells. Two weeks later you can find green cells on both the superficial and deep retinal vascular layers. Some of these cells have formed patent blood vessels as evidenced by the presence of previously injected rhodamine dextran. Thus, injecting endothelial progenitor cells from adult mouse bone marrow into neonatal mouse eyes will result in the targeting of these cells to astrocytes and their incorporation into, or close association with, developing vasculature [212].

Once we established that these cells can selectively target activated retinal astrocytes and participate in retinal angiogenesis we decided to use them as a form of cell based therapy to see if we could deliver an angiostatic agent to sites of abnormal angiogenesis. To do this, we turned to a molecule we have been working on in the laboratory in collaboration with Paul Schimmel's lab at Scripps for the past few years. Let me briefly review this published work for you [231,232]. It turns out that the fragments of various tRNA synthetases are potent angiogenic or angiostatic agents; T2TrpRS is a small carboxy-terminal fragment of tryptophan tRNA synthetase and is a very potent angiostatic agent. We took that cDNA fragment encoding the protein and engineered the coding region for a signal sequence in front of the T2 fragment. If this plasmid is transfected into lineage-negative HSC and these cells are then injected into neonatal mouse retinas, we find that within a week or two after injection we can detect the synthesis of T2TrpRS as evidenced by western blot analysis with an antibody specific for the T2TrpRS. We also found that the presence of the T2TrpRS correlated with a complete inhibition of the forming deep retinal vascular layer. HSC transfected with control plasmids had no such inhibitory effect. Thus, we have demonstrated, as a proof of concept, that we can use EPCs as magic bombs to deliver angiostatic agents to the back of the eye [212].

Can we use these EPCs to exert some sort of trophic and/or rescue effect on vasculature or neurons that are destined to degenerate under a variety of circumstances? For example, in diseases like ROP or diabetes, if we could somehow stabilize developing neovasculature and make it form new functional blood vessels, rather than ones which leak fluid or cause traction detachments, we might be able to relieve ischemia and avoid a lot of complications of these terrible diseases. To investigate that, we turned to a mouse model of retinal degeneration called the rd/rd mouse. This mouse, shortly after birth, undergoes a profound degeneration of the outer nuclear layer such that by one month postnatally there are no photoreceptors in the outer nuclear layer; there is also a profound atrophy of the inner nuclear layer. Additionally, the deep and interme-

diate vascular layers undergo a profound degeneration such that by one month postnatally there are only a few remaining superficial network vessels and little else. If you examine these mouse retinas with a confocal microscope z-series, what you see is both the intermediate and deep vascular complexes become markedly atrophic. If you inject lineage-negative HSC into one eye of an animal, we observe that at 2 months postnatally you have essentially normal looking intermediate and deep vascular layers. In contrast, a contralateral eye injected with control cells has typical, profound degeneration. If you look in cross section, not only are the vessels gone but in the control eye the inner nuclear layer is markedly atrophic and the outer nuclear layer is completely gone. In the rescued eye, we not only rescued the blood vessels but we also rescued the inner nuclear layer and, to some extent, the outer nuclear layer. When you look as long as 6 months after injection in the rescued eye treated with the EPC-containing lineage-negative HSC population, we observe a reasonably normal intermediate layer, and an atrophic, but partially present, deep vascular layer. We have done electrophysiology on these animals in collaboration with John Heckenlively and Steve Nusinowitz from UCLA; while these are not normal ERGs, there is some electrical activity in response to light stimulation in these rescued eyes. We observe the same rescue effects when we take human adult bone marrow and inject lineage-negative HSC into SCID mice with the rd/rd genotype. Interestingly, we again see a similar sort of neurotrophic rescue effect whereas in the control eyes, there is no outer nuclear layer and an atrophic inner nuclear layer [211].

Thus, we have demonstrated that bone marrow derived lineage-negative HSC utilize an established astrocytic template in both developing and injury-induced mouse vasculature. These HSC, when they are transduced *ex vivo* with a transgene encoding an angiostatic protein like T2TrpRS, can profoundly inhibit new blood vessel formation without affecting already established blood vessels. Incorporation of endothelial progenitor cells into the vasculature, can stabilize degenerating vessels in mice with retinal degeneration and can also exert a profound neurotrophic affect. I will not go into detail here, but if you do microarray analysis to compare rescued and non-rescued eyes, what we find is a tremendous increase in expression of genes encoding anti-apoptotic proteins including transcription factors and heat shock proteins. We think that this is probably the mechanism by which these EPCs are facilitating rescue.

The potentially exciting fantasy here, as it pertains to treating ischemic retinopathies such as ROP, is whether we can use these EPCs to rescue and mature otherwise degenerating vessels. Can we use these cells to stabilize an ischemic retina and increase its resistance to degeneration? Can we deliver factors (e.g., neurotrophic) to enhance this effect? The model or treatment protocol might be to do an autologous cord blood or bone marrow transplant into the eye of a child recently diagnosed with ROP. Based on the studies I have already discussed, we might expect these cells to target sites where blood vessels are forming and if these cells are indeed more resis-

tant to ischemic damage perhaps we would not see the kind of proliferation or vascular leakage we see in some of these ischemic retinopathies. To address this potential treatment opportunity, we have been using the mouse OIR model in collaboration with Lois Smith's group at Harvard. Using live, real-time multiphoton confocal microscopy, we have been able to observe that these lineage-negative HSC do target to sites of blood vessels in the mouse model of OIR. This is very preliminary data and we can not yet determine if the rescue effect will also be observed. We have, however, looked at the effect of these cells in another model of ischemic retinopathy (obtained from John Heckenlively at UCLA) in which intraretinal microvascular abnormalities are observed when the very low density lipoprotein receptor (VLDLR) is knocked out. If you do rhodamine dextran injection, these vessels leak from the intraretinal microvascular abnormalities that resemble angiomatous proliferations not dissimilar from those abnormalities we observe in humans with chorio-retinal angiomatous proliferation (CRAP), a special type of age related macular degeneration. If you inject these lineage-negative HSC into mice with CRAP or OIR, GFP positive EPCs in green appear to target sites of neovascularization and incorporate into blood vessels. Preliminary results from our lab suggest that we may be able to reverse the VLDLR knockout phenotype by injecting normal EPCs into this mouse.

In summary, these bone marrow-derived endothelial progenitor cells use an established template in mice and can promote angiogenesis. They can incorporate into vasculature, stabilize degenerating vessels, and stabilize degenerating neuronal cell layers, although not to the same extent. We observed a significant induction of anti-apoptotic genes which may mediate the vascular and neuronal rescue. When similar populations of cells are taken from human bone marrow and injected into mice, identical targeting and rescue activities are observed. Based on these observations, we suggest a new paradigm for treating ischemic and degenerative retinopathies involving the use of autologous bone marrow stem cell grafts; this would avoid many of the problems we see in association with other forms of gene therapy including lack of an immune response to injected viral particles. We are currently using such a cell based approach to deliver a variety of anti-angiogenic and neurotrophic factors to sites of neovascularization and/or degeneration in the retina. What we would really like to do, of course, is to see if we could reconstruct, rather than destroy, abnormal blood vessels that are the retina's response to ischemia in diseases such as ROP and diabetic retinopathy.

#### SESSION 4D: INHIBITION OF RETINAL NEOVASCULARIZATION: ANTI-PROTEINASE STRATEGY

##### **Contributors: Arup Das**

I want to thank the organizers of this symposium, especially Jerry Luty for inviting me to present at this session. It is an honor for me to be part of this great event saluting Dr. Arnall Patz who has been a pioneer in the field of ROP research. I am going to discuss the role of proteinases in retinal

neovascularization (NV) and the anti-proteinase strategy as an anti-angiogenic armament in the fight against new vessels in the retina.

A crucial event during angiogenesis is the invasion and migration of endothelial cells through the capillary basement membrane and into the adjacent extracellular matrix (ECM). This invasive process is tightly coupled to the production and activity of specific extracellular proteinases including the serine proteinase urokinase plasminogen activator (uPA) and specific members of the MMP family [233]. Our lab is actively involved in investigating this pathway in the angiogenesis cascade in retina.

*Role of proteinases in retinal neovascularization:* We investigated the role of proteinases in retinal neovascularization. We examined by zymography the expression of these enzymes in human epiretinal neovascular membranes, obtained surgically from proliferative diabetic retinopathy patients [234]. Similar neovascular epiretinal membranes also grow in eyes with ROP. Zymography shows both the high 54 kDa and low 33 kDa molecular weight forms of urokinase are present at significantly higher levels in diabetic membranes than in normal donor retinas. Quantification of zymograms showed a 6 fold increase in the high molecular weight form and a 4 fold increase in the low molecular weight form of uPA. Both the pro- and active forms of MMP-2 and MMP-9 enzymes were elevated in the human diabetic epiretinal neovascular membranes [234].

To examine the role of proteinases in animal models, we used the ROP mouse model [235]. We examined by zymography the level of proteinases in the retinas of the oxygen-treated animals compared to room-air control animals. uPA, MMP-2, and MMP-9 are all significantly elevated in the retinas of animals with retinal NV. This was further confirmed by RT-PCR analysis showing that mRNAs of these proteinases are also elevated [235].

To further investigate the role of the uPA/uPA receptor (uPAR) system during retinal NV, we examined retinas of mice with active neovascularization by RT-PCR analysis. Expression of uPAR mRNA was detected in experimental mice on day 17 during the active angiogenic period. This was in contrast to control mice which demonstrated undetectable uPAR mRNA. The mRNA of uPAR was significantly upregulated during retinal angiogenesis [236]. To identify the cell types responsible for the expression of uPAR in the retina, we performed immunohistochemistry on adjacent sections of retinas using antibodies for uPAR and with the endothelial cell marker CD31. The expression of uPAR was restricted to endothelial cells within the superficial layer of the retina and the neovascular tufts on the surface of the inner limiting membrane [236].

A balanced interplay of proteinases and proteinase inhibitors (tissue inhibitor of MMP or TIMP), has been implicated during angiogenesis. Interestingly, message and protein of one of the subtypes of the endogenous inhibitor, TIMP-2, remained low and significantly less in animals with retinal NV than in control animals [237]. There was no significant change in TIMP-3 message levels in retinal tissues, and TIMP-1 mes-

sage and protein were undetectable. Thus there is suggestion of a temporal role for MMP-2, MMP-9, MT1-MMP, and TIMP-2 during retinal angiogenesis in response to hypoxia [237].

In a different study, we also found that the action of angiopoietins is mediated through proteinases. RT-PCR analysis of retinas from the ROP model for Ang-2 shows that Ang-2 is significantly increased in ROP compared to control retinas, with the greatest increase on day 17 (the time of maximal angiogenic response) [238]. Also, we found that stimulation of cultured retinal endothelial cells with Ang-1 and Ang-2 activates the expression of the proteinase MMP-9 at the protein and mRNA level [238]. If the Ang-2 expression is inhibited, there is inhibition of expression of MMP-9. How do we summarize this data? The mature vessel, if destabilized, can either go in the direction of angiogenesis in the presence of VEGF or regress in the absence of VEGF. During destabilization, Ang-2 upregulates the expression of MMP-9; this upregulation of proteinases in endothelial cells by Ang-2 may be an early response necessary for cell migration during angiogenesis.

*Anti-proteinase approach to retinal neovascularization:* Now that we know that proteinases are upregulated during retinal NV, we wanted to find out whether the anti-proteinase strategy can suppress retinal neovascularization. We first tried a synthetic broad-spectrum MMP inhibitor, BB-94 (British Biotech, Oxford, UK) [235]. Intraperitoneal injection (IP) of this MMP inhibitor suppresses the growth of human ovarian carcinoma xenografts and murine melanoma metastases. IP injections of the BB-94 drug were given to the murine ROP model on day 12, 14, and 16. At 1 mg/kg dose, there was 72% reduction of retinal NV [235]. No obvious toxic effects, inflammation, or abnormal development was noted at this dose. However, at a higher dose of 15 mg/kg, there was 90% reduction but the dose was toxic.

We then investigated the effect of a uPA inhibitor on retinal NV in the ROP model. B-428 (4-substituted benzothioephene-2-carboxamidine; Eisai Research Institute, Andover, MA) has been shown to effectively block tumor growth in an animal model of mammary adenocarcinoma and prostate cancer. IP injections of this uPA inhibitor were given to the ROP model on days 12-16 at different doses. There was about 43-58% inhibition of retinal NV, and the response was dose-dependent [239]. There was no side effect on normal development of the retinal vasculature or neural tissue.

Recently, we investigated the effect of another urokinase inhibitor, A6 (Angstrom Pharmaceuticals, San Diego, CA), on retinal NV in the ROP model [236]. A6 is an 8-amino acid novel peptide derived from the non-receptor binding region of urokinase that inhibits the interaction of uPA with its receptor, uPAR. A6 showed a dose-dependent inhibition on the basic fibroblast growth factor-stimulated migration of human microvascular endothelial cells (HMVECs). As the uPA/uPAR system is involved in cell migration only, there was no effect of A6 on proliferation of endothelial cells. A6 has been shown to inhibit tumor growth and metastasis in breast cancer and glioblastoma models. There was significant tumor reduction by treatment with both A6 and Cisplatin. These data suggest

that the combination of an angiogenesis inhibitor that targets endothelial cells with a cytotoxic agent may be a useful therapeutic approach.

We used the A6 peptide in the mouse ROP model. Different doses of A6 were injected IP from day 12 to day 16. A6 was found to be effective in suppressing retinal NV by up to 63%, and the response was dose-dependent [236]. We investigated the role of uPAR in facilitating the formation of new vessels by comparing the extent of oxygen-induced retinal NV in normal mice and in uPAR<sup>-/-</sup> knockout mice. There was almost 73% reduction of retinal NV in the uPAR<sup>-/-</sup> knockout mice compared with normal mice [236]. The inhibition by A6 is very close to the reduction observed in the uPAR knockout mice. The loss of uPAR activity and its effect on vascularization appeared to be limited to abnormal neovascularization, but not to the normal development of the retinal vasculature. Whole mount preparation stained for ADPase activity showed the same vascular pattern overall in the uPAR knockout mice and in normal mice. RT-PCR analysis of retinas showed that there was a 2.3 fold decrease in the level of uPAR mRNA in the A6 treated animals [236].

Using an anti-angiopoietin approach with the Tek delta Fc (Amgen Washington, Seattle, WA), a fusion protein consisting of the extracellular domain of the murine Tek receptor fused to the Fc portion of the murine IgG, yielded interesting data in terms of Ang-2 and its relation to proteinases. An 87% inhibition of retinal NV was achieved at the high dose of 80 mg/kg [238]. What was most interesting when we did RT-PCR analysis for MMP-9 of retinas from animals treated with Tek delta Fc, MMP-9 was found to be significantly decreased by 80% by inhibition of Ang-2 activity [238]. Thus, our speculation is that Ang-2 probably upregulates the proteinase MMP-9, which then destabilizes the vessel for angiogenesis.

Conclusions: (1) Proteinases are upregulated during retinal neovascularization. (2) Proteinase inhibitors including MMP inhibitors and uPA inhibitors can suppress retinal angiogenesis. (3) A6, an inhibitor of the uPA/uPAR interaction, significantly inhibits retinal NV in a ROP model and is a promising, novel drug. (4) Anti-proteinase strategy may be used in the treatment of retinal NV in ROP.

#### SESSION 4E: RIBOZYME-MEDIATED GENE SILENCING IN THE MOUSE MODEL OF OIR

**Contributors: Lynn Shaw, Maria Grant**

*Gene Silencing:* Historically, two general methods exist to assay the function of specific components of complex physiological pathways. The first is the use of transgenic knockout animals in which the gene coding for a specific intermediate in the pathway has been inactivated. The second is the use of conventional drugs that act as either antagonists or agonists to a specific component of the pathway. The production of knockout animals is expensive, labor-intensive and can result in embryonic lethality; while conventional drugs have the potential disadvantage of unwanted side effects due to direct interaction with other components of the same or different pathways that can make the interpretation of any results problematic. Here we detail the use of a molecular approach to block the

expression of a specific gene product in order to perturb a pathway. There are several molecular-based methods for this type of gene silencing. One method is the use of antisense oligonucleotides, either DNA or RNA based, that bind the mRNA to block protein expression. We will not go into antisense technology since there are excellent reviews covering this subject [240-242]. Another method is a reasonably new technique called RNA interference (RNAi). This method involves a small interfering RNA (siRNA) that anneals to a target mRNA and signals the cleavage of the target through the action of an enzyme complex inherent to the organism called the RNA-induced silencing complex (RISC). The development of this method for gene silencing is ongoing and is discussed in a number of relevant papers [243-245]. The third method uses a class of catalytic RNAs called ribozymes to cleave the target mRNA and reduce protein expression.

There are several classes of ribozymes and one useful way of segregating them is based on their requirements for a protein subunit. Group I introns require a single protein subunit, *in vivo*, for splicing [246]. The one known exception to this is the mitochondrial intron found in the large ribosomal RNA subunit of *Tetrahymena* [247-250]. Group II introns require a complex composed of several small nuclear RNAs (snRNA) and proteins called the spliceosome for the removal of the intron [251]. RNase P, which cleaves the 5'-precursor from immature tRNAs, also requires a single protein subunit [252,253]. For each of these types of ribozymes the protein serves a structural role while the RNA, either the introns or the tRNA, is the sole catalytic component. The class of ribozymes that require no protein subunit consists of hammerhead and hairpin ribozymes [254-256]. These ribozymes are small, approximately 30 to 90 nucleotides, and require magnesium for structure (hairpin and hammerhead) and cleavage (hammerhead) [257]. We shall limit our discussion of ribozymes to the hammerheads since we are using these types of ribozymes to specifically cleave the mRNAs of components of the neovascularization pathway in the mouse model of OIR [55].

A number of cell surface receptors have been implicated in angiogenesis. The adenosine A<sub>2B</sub> receptor, the insulin-like growth factor-1 receptor (IGF-1R) and the VEGFR-1 and VEGFR-2 are the targets of the ribozymes we have developed and describe here. These receptors are expressed preferentially on proliferating endothelial cells and these are the cells we desire to influence when blocking angiogenesis.

*Hammerhead ribozymes design and development:* Figure 16 shows the structure of a typical hammerhead ribozyme that we use in our studies. The ribozyme is 34 nucleotides in length and is annealed to a 13 nucleotide target. Annealing of the target to the ribozymes targeting arms creates stems I and III. The ribozyme in Figure 16 is a 6-4-6-ribozyme where 6-4-6 refers to the number of base pairs that are present in stems I-III representing ribozymes that have targeting arms that form 6 base pair stems. The length of the targeting arms affects the efficiency of the binding of the target and ribozyme. Longer targeting arms may adversely affect the overall rate of cleavage by improving binding to the target and slowing disassociation of the ribozyme from the cleavage products and re-

ducing overall catalytic turnover. Shorter targeting arms, while increasing the release of the ribozyme after cleavage may also decrease specificity for the target. The 6-4-6-ribozyme design has proven to be a reasonable compromise. Bases highlighted in yellow in Figure 16A comprise the required bases of the catalytic core of the ribozyme. Substitution of any one of these bases eliminates catalytic activity. As indicated in Figure 16A, a substitution of an A for the indicated G produces an inactive version of the ribozyme and allows the study of the antisense effects of these molecules. While this version will still anneal to the target it is catalytically inactive. Therefore, any reduction in expression or function of the target will be due to antisense inhibition.

The only sequence requirement for the target of a hammerhead ribozyme is a NUX (shown in red in Figure 16A), where N is any base and X cannot be a G. Cleavage occurs just downstream of the X [258]. Shimayama et al. [259] demonstrated that the most efficient target site is a GUC and we have found that a GUC followed by a pyrimidine rather than a purine increases cleavage efficiency [260-262]. The accessibility of the target site within the mRNA is the most important aspect of target selection; Fritz et al. [263] detail the methods required for the selection of target sites. Target accessibility can be determined by examining the secondary structure and thermodynamic stability of the target mRNA using the Mfold program [264,265]. In addition, once potential targets are se-

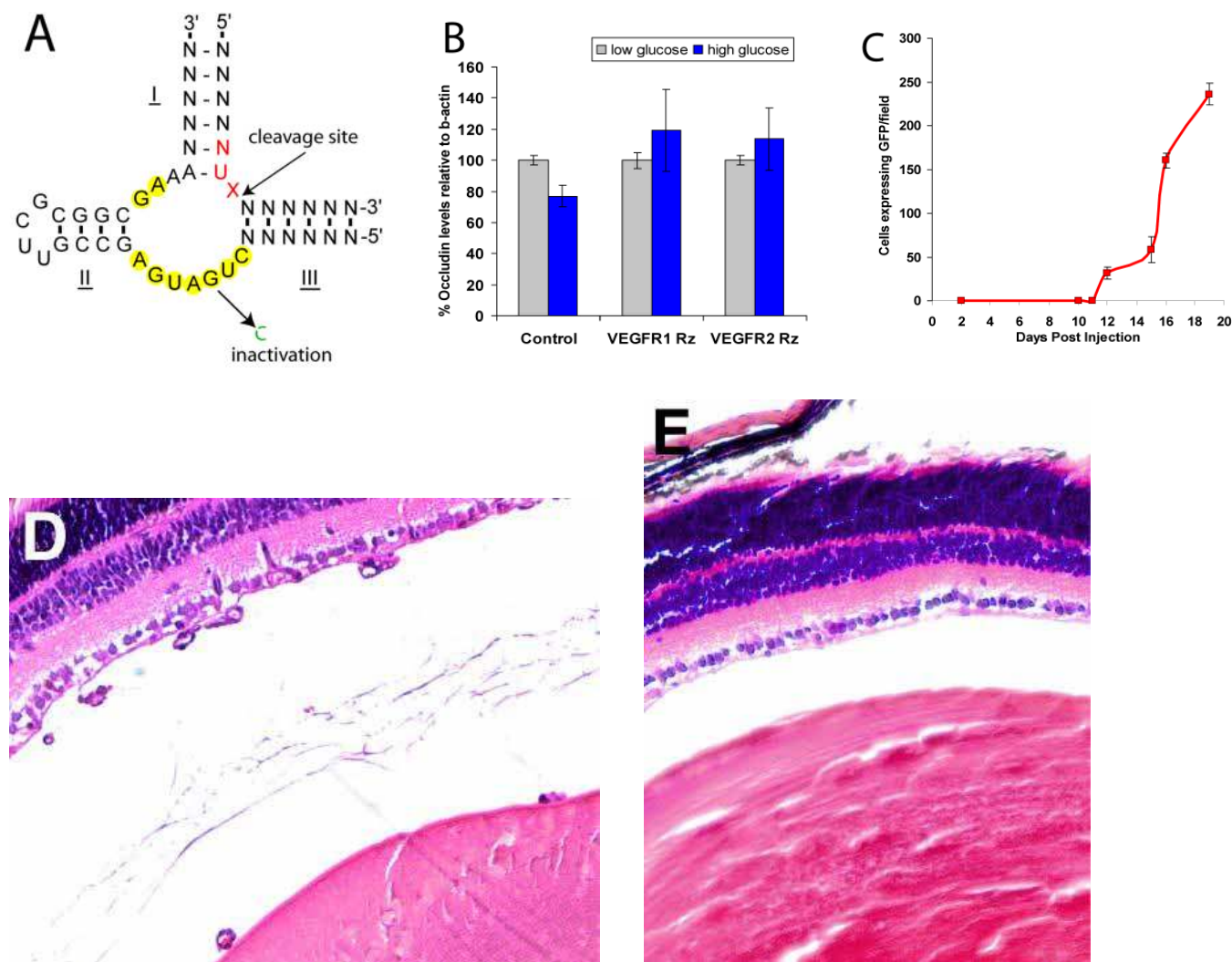


Figure 16. Targeted ribozyme expression vectors in an OIR mouse model. **A:** Structure of a generic hammerhead ribozyme annealed to its target. Cleavage occurs just downstream of the target NUX site where N is any base and X is not a G. Bases highlighted in yellow show the catalytic core. **B:** HRECs transfected with plasmids expressing ribozymes targeting vascular endothelial growth factor receptors 1 and 2 (VEGFR-1, VEGFR-2) prevent reduction in occludin levels in high glucose (25 mM). **C:** Intraocular injection of 1  $\mu$ g of plasmid expressing green fluorescent protein (GFP) into the oxygen-induced retinopathy (OIR) mouse model on postnatal day 1 results in increasing GFP expression on postnatal day 12 through 19. **D:** Cross section of control retina from mouse from the OIR model showing preretinal neovascularization. **E:** Cross section of retina from mouse from the OIR model after intraocular injection on postnatal day 1 with a plasmid expressing IGF-1R ribozyme. Note lack of preretinal neovascularization.

lected, then the corresponding ribozyme, with targeting arms, must also be examined, in silico, to look for any secondary structures that would interfere with target annealing [263]. In vitro methods also exist for the determination of accessible sites on mRNA, but these are time consuming and, ultimately, may not be any more effective than target evaluation in silico [263,266]. Another important consideration when choosing target sites is their uniqueness. It is important that the ribozyme only cleave the single target for which it is designed. Therefore, all target sites must be compared against known sequences by performing a BLAST search against GenBank.

The focus of our work involves designing ribozymes against wildtype targets. We want to affect expression from both alleles. Numerous potential NUX targets exist and we search for the best possible target. In contrast, for the reduction of expression of a single mutant allele, the selection of a target site is usually limited to the mutant site itself. Unfortunately, this means that most mutation sites will not allow for the design of a sufficiently active ribozyme. While there are potential solutions for this problem, it is probably best not to use ribozymes to affect a mutant allele. The reduction in expression from a mutant allele might best be accomplished with RNAi technology that allows for a wider selection of target sites than does ribozyme technology.

Once the ribozyme and target site have been selected, the corresponding RNA oligonucleotides are purchased (Dharmacon, Boulder, CO) and in vitro multiple turnover kinetic analysis is performed to evaluate whether the ribozyme has enough catalytic activity to pursue it further [263]. Hammerhead ribozyme cleavage is treated as pseudo-first order kinetics and we determine three kinetic parameters for each ribozyme ( $V_{max}$ ,  $K_m$ ,  $K_{cat}$ ) [255,267]. Multiple-turnover reactions are performed under two different conditions: 1 mM  $MgCl_2$  at 25 °C with pH 7.4 or 20 mM  $MgCl_2$  at 37 °C with pH 7.4. We have produced ribozymes that vary widely in the values of their kinetic parameters, but generally, ribozymes with a  $K_{cat} > 1.0 \text{ min}^{-1}$  at 20 mM  $MgCl_2$  at 37 °C with pH 7.4 will be cloned for further testing in cells and in vivo. Many expression vectors are available, but we clone our ribozymes into AAV vectors because of the potential of packaging these vectors into AAV. However, we have found sufficient expression of the ribozymes from the plasmids for simple transfection experiments and for intraocular injections into the OIR mouse model [263].

*Expression of ribozymes in human retinal endothelial cells:* Plasmids expressing ribozymes are used to transfect primary cultures of human retinal endothelial cells (HRECs). A number of transfection protocols and reagents are available, and currently we are using the Lipofectamine 2000 reagent (Invitrogen, Carlsbad, CA), as its utilization results in 100% transfection efficiency in HRECs with almost 100% cell viability following transfection. To determine if the ribozymes are actually cleaving the desired target, analysis of ribozyme activity is performed 72 h after transfection of HRECs. RT-PCR, or real time RT-PCR, is performed on total RNA or mRNA to assay levels of the target RNA. Western analysis is performed to determine if the ribozymes have reduced expres-

sion of the protein product. Generally, significant reduction of both the RNA and protein has been found, and we have observed a significant level of reduction in RNA and protein levels from the antisense binding of the ribozyme to the target RNA in HRECs. Functional analysis, such as cell migration assays, can also be performed on the transfected cells.

One of the main justifications for using ribozymes is to assay for the affect of the reduction in expression of a specific component of a pathway on other components of that pathway. Since ribozymes can be designed to only cleave the desired target, any affects on the pathway can be directly attributed to the reduction in expression of the target protein. One example of this can be found in tight junctions. Tight junctions form between endothelial cells in order to prevent leakage of vascular fluid. In proliferative retinopathies, tight junction integrity is lost and leakage occurs resulting in hemorrhage and detachment. Occludin is a transmembrane protein integral in the formation of tight junctions. In diabetics, under conditions of high serum glucose, occludin levels are reduced and tight junction integrity is lost. In order to examine the role of VEGF on this process we produced two ribozymes, one targeted against VEGFR-1 and the second targeted against VEGFR-2. Our initial results on transfected HRECs demonstrate that both ribozymes prevent occludin loss under high glucose conditions suggesting that VEGF reduces tight junction integrity through both receptor subtypes (Figure 16B).

*Intraocular injection of ribozymes into the OIR mouse model:* The ultimate test of a ribozyme is its ability to function in an in vivo model. We tested our ribozymes in the OIR mouse model [55]. The short time course of this model is ideal for quickly assessing the effects of ribozymes on retinal neovascularization, but it is important to determine the expression pattern of the ribozymes within this model to make certain that sufficient expression is occurring during the hypoxic stimulation of neovascularization. In addition, it is important to determine the level of ribozyme expression during normal vasculature development of the eye. To examine this issue, we injected plasmids intraocularly that expressed GFP rather than a ribozyme in order to visually monitor expression levels in our plasmids. Plasmid was injected intraocularly on postnatal day 1 and the mice then proceeded through the 17 day OIR model with mice being sacrificed at various times (days 2 through 19). Retinas were flat mounted and the number of GFP positive cells per high-power field per retina was determined. Our results show that expression of GFP is visually observed on postnatal day 12 and increases through postnatal day 19 (Figure 16C). Because ocular development is largely completed by day 12, expression of ribozymes from our plasmids should not interfere with the normal development of the retinal vasculature, and should occur at sufficient levels during hypoxia-stimulated neovascularization (days 12 through 17). Thus, we are not influencing the vaso-obliteration phase of the model but we are affecting the vasoproliferative phase.

Using the OIR mouse model, we examined the affect on neovascularization of reducing the expression of the adenosine  $A_{2B}$  and the IGF-1 receptors. Intraocular injection of the

plasmid expressing the adenosine A<sub>2B</sub> receptor ribozyme reduced preretinal neovascularization by approximately 53% while injections with plasmid expressing the IGF-1R reduced preretinal neovascularization by approximately 65%. Cross sections of the eyes also demonstrate no unusual structural changes in eyes injected with ribozyme-expressing plasmids, supporting the idea that plasmid expression occurred primarily following vascular development and during the onset of neovascularization. Figure 16D,E shows typical cross sections of retinas that have undergone the OIR model with and without the injection of a plasmid expressing the IGF-1R ribozyme. These results demonstrate the validity of using ribozymes to manipulate a complex physiological pathway like angiogenesis.

#### SESSION 4F: AAV MEDIATED GENE THERAPY REDUCES RETINAL NEOVASCULARIZATION IN THE ROP MOUSE

**Contributors: William Hauswirth, Kenneth Burns, Wentao Deng, Brian J. Raisler**

In the retina, proper control of angiogenesis, the formation of new blood vessels from existing vasculature, is essential to preservation of vision. Pathologic neovascularization of retinal and choroidal vessels is central to several prevalent ocular diseases including ROP, proliferative diabetic retinopathy (PDR) and AMD. PDR and AMD are the leading causes of blindness in developed countries and ROP is the leading cause of infant blindness. It is the balance between endogenous vascular growth factors, such as VEGF [268], and inhibitors of angiogenesis, such as PEDF [269], that are vital for regulation of retinal vascularization. When this balance is upset, as happens during and after the hyperoxic treatment of premature infants, pathologic angiogenesis often occurs that ultimately results in vision loss.

Although a variety of treatments currently exist for patients with choroidal or retinal neovascularization, all cause collateral retinal damage and/or provide only a temporary solution. Clearly the need exists for therapies that require minimal surgical manipulation, preserve existing vision, and provide long-term amelioration for the various forms of neovascularization. Several potent and well-tolerated *in vivo* inhibitors of neovascularization have been identified, including PEDF [270], angiostatin [271] or endostatin [272]. Their effectiveness as anti-neovascular agents has been primarily validated through protein injection studies in animal models [273,274], although viral vector delivered cDNA studies have also recently appeared [275-285].

*Results and discussion:* In order to fairly assess the utility of gene-based anti-angiogenic therapies it was important to first determine the optimal promoter construct and intraocular site of vector administration to use. Our initial assumption was that the promoter yielding the highest level of vector encoded ocular protein would be the most effective for animal testing. We assayed by ELISA the amount of ocular protein encoded by each vector in adult mice using each of five different promoters within AAV vectors administered either to the subretinal or intravitreal space. The promoters were se-

lected based on their ability to restrict expression to different subsets of retinal cells. Chicken  $\beta$ -actin (CBA) is a ubiquitous strong promoter composed of a cytomegalovirus (CMV) immediate early enhancer (381 bp) and a CBA promoter-exon1-intron1 element (1352 bp). The cis-retinaldehyde binding protein promoter (2265 bp) is a retinal pigment epithelium specific promoter when administered subretinally in an AAV vector (A. Timmers and W. Hauswirth, unpublished data). The mouse rod opsin promoter [286] (372 bp) is photoreceptor specific. Platelet derived growth factor promoter (1600 bp) is specific to retinal ganglion cells when delivered intravitreally in AAV vectors (A. Timmers and W. Hauswirth, unpublished data), and the CMV promoter (620 bp) like CBA is also relatively ubiquitous in the retina but expresses at lower levels than CBA [287].

Vectors containing the CBA promoter, injected either subretinally or intravitreally, yielded the most consistently robust levels of secreted passenger gene expression. By reference to available protein therapy data, we estimate that measured intraocular levels of vector expressed PEDF and Angiostatin were well above therapeutic thresholds for inhibiting retinal neovascularization. The intraocular level of each encoded protein was unaffected by the site of vector administration, perhaps because all three candidate proteins are either naturally secreted or engineered to be secreted. Given the potential for retinal damage attendant with subretinal injections, intravitreal administration is concluded to be the preferable route of vector administration. Previous work has shown that AAV vectors with the CBA promoter express preferentially and efficiently in retinal ganglion cells when injected into the mouse vitreous space [277]. For purposes of maximizing protein expression in the retina, we therefore conclude that CBA promoter containing AAV vectors delivered intravitreally are best suited for therapeutic evaluation in a retinal NV setting. Finally, we note that passenger gene expression after intravitreal vector administration was sustained for at least 21 months in the mouse eye.

Retinal neovascularization was induced by a modification of the previously described neonatal ischemic mouse protocol that employs shifts in oxygen tension [55]. Each AAV vector (0.5  $\mu$ l,  $5 \times 10^9$  vector genomes) was administered at postnatal day 1 (P1) and retinas analyzed at P17, the age of maximal retinal neovascularization. Visualization of complete retinal vessel beds by whole mount FITC dextrin angiography [280] demonstrated that uninjected eyes and eyes injected with AAV-CBA-GFP did not significantly differ from uninjected eyes; all showed extensive areas of neovascularization in the retinal periphery with significant areas of central avascularity. In contrast, eyes treated with any of the three candidate cDNA vectors exhibited marked reduction in peripheral neovascularization and relatively normal central perfusion.

In order to more quantitatively measure the effects of each vector on retinal neovascularization, direct counting of endothelial cells in the preretinal vasculature was carried out as previously described [280]. We enucleated and fixed both vector-treated and control eyes from P17 pups for paraffin em-

bedded sectioning. Samples of eyes of each animal remained paired throughout the procedure to allow direct comparison of vector treated eyes with their untreated contralateral control eyes. Serial sections (5  $\mu$ m) were made through the entire eye, and every 30<sup>th</sup> section was placed on a single slide and hematoxylin and eosin stained. These representative sections provide a reliable method for quantitatively assessing, in an unbiased manner, the total level of retinal neovascularization in each eye. Individuals masked to the identity of the treatment groups quantified neovascularization by enumerating all endothelial cell nuclei found in the vitreous space above the inner limiting membrane. Comparisons were made between one eye of each animal injected with therapeutic vector and the contralateral uninjected eye serving as an internal control. Care was taken to exclude persistent hyaloid vessels from the analysis by omitting both retinal vascular endothelial cells not in direct contact with the anterior face of the retina and all vascular endothelial cells within 1.5 optic nerve diameters of the optic nerve head.

Eyes injected with vectors containing either the PEDF, Kingle domains 1-3 of Angiostatin, or Endostatin cDNAs at P1 had 70-80% fewer aberrant retinal vascular endothelial cells at P17 compared to contralateral untreated eyes (n=10-11; p<0.001 for all comparisons; Figure 17). Vehicle-injected eyes and eyes injected with AAV-CBA-GFP did not significantly differ from uninjected eyes in this assay (data not shown).

It was somewhat surprising that an apparently therapeutic endpoint could be elicited by AAV vectors during the 17 days of the experiment because ocular expression in adult mice requires 3-4 weeks to plateau at super therapeutic threshold

levels (data not shown). To experimentally confirm that intraocular protein levels of each were above estimated therapeutic thresholds, the amount of each vector expressed protein was determined by ELISA from ocular extracts collected daily between P1 and P17. In all cases, encoded protein levels rose above threshold levels within 1 to 3 days after vector injection and remained there until the end of the experiment at P17. Therefore, unlike adult mice in which measurable AAV vector passenger gene expression in the retina requires several weeks to reach its sustained maximal level, such early ocular vector administration resulted in therapeutic levels of gene expression within days. The fact that many retinal cells in a P1 mouse retina are still dividing may provide an explanation for the difference between adult and neonatal expression because AAV vectors express their passenger genes much more rapidly in dividing cells [288].

In summary, these experiments support the idea that intraocular expression of secretable, anti-angiogenic proteins using AAV vectors provides a viable way to manage retinal neovascularization. Additionally, this therapeutic approach may be applicable to human ROP, assuming the duration of therapy can be controlled.

#### SESSION 4G: ROP IS STILL A CHALLENGE FOR CLINICIANS AND RESEARCHERS

##### Contributors: Arnall Patz

It was a privilege to serve as Honorary Chairman for this highly productive symposium on ROP. The organizing co-chairs, Jerry Luty, Tailoi Chan-Ling, and Dale Phelps provided leadership and inspiration to all of the participants. I also want to congratulate the rest of the organizing committee which included John Flynn, Jan McColm, Earl Palmer, and William Tasman for their key role. I especially wanted to recognize Jerry Luty for his assistance in soliciting financial support for the meeting and for contributing significantly to and editing my final remarks.

As Chairman of the Development Committee, I want to recognize the special contributors to the symposium. The leadership of Alcon and Allergan provided important support along with Eyetech Pharmaceuticals, Iridex, Biospherix, Mead Johnson Nutritionals, and Massie Labs. I also want to thank the Bernadotte Foundation for Children's Eye Care, whose funding made it possible for many international scholars to attend. We also greatly appreciate the special support from the National Eye Institute (NEI). On behalf of all the organizers and participants in the symposium, I want to especially thank the American Academy of Ophthalmology staff for scheduling the meeting the day prior to the start of the Retina Sub-Specialty meetings and their cooperation throughout the meeting. The participants I have spoken with were very appreciative of this meeting serving as a timely and very useful addition to the previous International Symposia on ROP.

It has been 50 years since the pioneering study of Everett Kinsey and our initial observations on retrolental fibroplasia. Cynthia Cole et al. [289] recently pointed out that "neonatal care providers do not understand how best to use oxygen in the most vulnerable premature infants despite more than 50

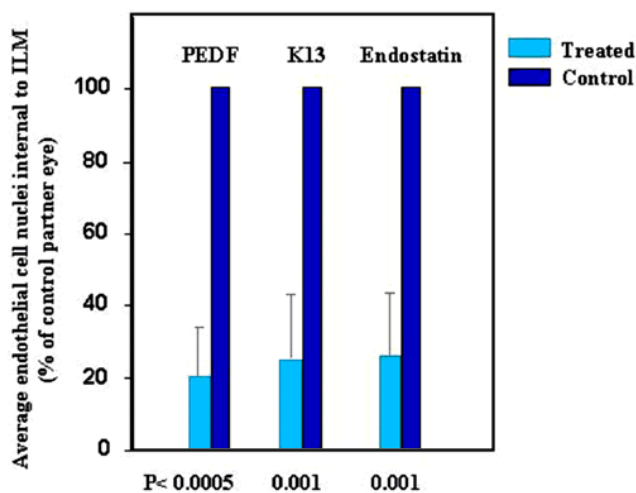


Figure 17. Effect of anti-angiogenic cDNA vectors in the mouse ROP model. Effect of anti-neovascular cDNA containing AAV vectors on reducing retinal neovascularization in the ROP mouse. Angiogenic retinal vascular endothelial cells counts at P17 normalized to the control eye at 100% are shown for pigment epithelium derived growth factor (PEDF), Kringle domains 1-3 of angiostatin (K13) and endostatin cDNAs in intravitreally injected AAV vectors. The p values for comparison of the control and partner treated eyes are shown at the bottom.



years of oxygen therapy in neonatal medicine.” A Danish study this year states that the apparent progress in the fight against ROP over many years seems to have come to a halt [290].

A recent study in Korea found a 20.7% incidence of ROP in their study population and that a gestational age of  $\leq 28$  weeks and a birth weight of  $\leq 1000$  g were the most significant risk factors [291]. Additionally, an English study reported a similar finding for the latter half of the last decade in their population [292]. Therefore, the ability to save younger premature infants and questions about the correct level of oxygen to maintain these extremely small infants may be factors in ROP remaining one of the major causes of blindness globally, as mentioned in Dr. Miller’s comments and demonstrated in Dr. Tahia’s report on management of ROP in Indonesia.

The American Printing House for the Blind has recently collected data concerning the incidence of ROP in twenty states as part of their program called “Babies Count: The National Registry for Children with Visual Impairments Birth to 3 Years.” Their goal is to determine the cause of visual impairment in children from all states in the United States, and its associated territories, within the near future. Current data from the 20 states suggests that 16% of the 2,152 visually impaired children surveyed to date have ROP.

From the exciting work presented at this symposium and the reports on the incidence of ROP in the US and abroad, it is apparent that research on ROP must continue. It is important that basic scientific studies as presented in this symposium continue so we can better understand how retinal vessels develop and are injured in hyperoxia. Furthermore, the mouse model of OIR has become the gold standard for research on retinal angiogenesis, so our understanding of retinal angiogenesis and how to control it will be advanced by the study of the proliferative stage of ROP in models of ROP. This should help us target pathologic events in ROP and develop new therapies. It is equally important that clinical trials continue to improve care of children and management of their retinopathy. Finally, it is important that basic scientists and clinicians share their ideas and discoveries at forums like this symposium, so that the rise in incidence of ROP can be addressed and hopefully reversed.

#### ACKNOWLEDGEMENTS

The support of the following sponsors of the symposium is gratefully acknowledged: The National Eye Institute, Alcon Pharmaceuticals, Eyetech Pharmaceuticals, Allergan Pharmaceuticals, Iridex, Biospherix, Mead Johnson Nutritionals, and Massie Research Laboratories, Inc. The Bernadotte Foundation of Children’s Eye Care provided funding making it possible for many international scholars to attend this symposium. Drs. Arnall Patz and John Flynn provided invaluable assistance in securing this sponsorship. The organization of this meeting was provided by the University of Rochester Medical Center, Office of Continuing Professional Education.

In the time since this meeting occurred, the ROP clinical and research community has suffered the loss of William Silverman, MD, who published one of the key textbooks on this disease.

#### REFERENCES

1. Chan-Ling T, McLeod DS, Hughes S, Baxter L, Chu Y, Hasegawa T, Luttly GA. Astrocyte-endothelial cell relationships during human retinal vascular development. *Invest Ophthalmol Vis Sci* 2004; 45:2020-32.
2. Hughes S, Yang H, Chan-Ling T. Vascularization of the human fetal retina: roles of vasculogenesis and angiogenesis. *Invest Ophthalmol Vis Sci* 2000; 41:1217-28.
3. Dreher B, Robinson SR. Development of the retinofugal pathway in birds and mammals: evidence for a common ‘timetable’. *Brain Behav Evol* 1988; 31:369-90.
4. Chan-Ling T, Stone J. Retinopathy of prematurity: origins in the architecture of the retina. *Prog Retin Eye Res* 1993; 12:155-78.
5. Chan-Ling T. Glial, neuronal and vascular interactions in the mammalian retina. *Prog Retin Eye Res* 1994; 13:357-89.
6. Chan-Ling T, Gock B, Stone J. The effect of oxygen on vasoformative cell division. Evidence that ‘physiological hypoxia’ is the stimulus for normal retinal vasculogenesis. *Invest Ophthalmol Vis Sci* 1995; 36:1201-14.
7. Semenza GL. Transcriptional regulation by hypoxia-inducible factor 1: molecular mechanisms of oxygen homeostasis. *Trends Cardiovasc Med* 1996; 6:151-7.
8. Stone J, Itin A, Alon T, Pe’er J, Gnessin H, Chan-Ling T, Keshet E. Development of retinal vasculature is mediated by hypoxia-induced vascular endothelial growth factor (VEGF) expression by neuroglia. *J Neurosci* 1995; 15:4738-47.
9. Provis JM, Leech J, Diaz CM, Penfold PL, Stone J, Keshet E. Development of the human retinal vasculature: cellular relations and VEGF expression. *Exp Eye Res* 1997; 65:555-68.
10. Provis JM, van Driel D, Billson FA, Russell P. Development of the human retina: patterns of cell distribution and redistribution in the ganglion cell layer. *J Comp Neurol* 1985; 233:429-51.
11. Chu Y, Hughes S, Chan-Ling T. Differentiation and migration of astrocyte precursor cells and astrocytes in human fetal retina: relevance to optic nerve coloboma. *FASEB J* 2001; 15:2013-5.
12. Gariano RF, Sage EH, Kaplan HJ, Hendrickson AE. Development of astrocytes and their relation to blood vessels in fetal monkey retina. *Invest Ophthalmol Vis Sci* 1996; 37:2367-75.
13. Fruttiger M. Development of the mouse retinal vasculature: angiogenesis versus vasculogenesis. *Invest Ophthalmol Vis Sci* 2002; 43:522-7.
14. Dorrell MI, Aguilar E, Friedlander M. Retinal vascular development is mediated by endothelial filopodia, a preexisting astrocytic template and specific R-cadherin adhesion. *Invest Ophthalmol Vis Sci* 2002; 43:3500-10.
15. Tao-Cheng JH, Brightman MW. Development of membrane interactions between brain endothelial cells and astrocytes in vitro. *Int J Dev Neurosci* 1988; 6:25-37.
16. Tout S, Chan-Ling T, Hollander H, Stone J. The role of Muller cells in the formation of the blood-retinal barrier. *Neuroscience* 1993; 55:291-301.
17. Hughes S, Chan-Ling T. Roles of endothelial cell migration and apoptosis in vascular remodeling during development of the central nervous system. *Microcirculation* 2000; 7:317-33.
18. Benjamin LE, Hemo I, Keshet E. A plasticity window for blood vessel remodeling is defined by pericyte coverage of the preformed endothelial network and is regulated by PDGF-B and VEGF. *Development* 1998; 125:1591-8.
19. Hughes S, Chan-Ling T. Characterization of smooth muscle cell and pericyte differentiation in the rat retina in vivo. *Invest Ophthalmol Vis Sci* 2004; 45:2795-806.
20. Darland DC, Massingham LJ, Smith SR, Piek E, Saint-Geniez M, D’Amore PA. Pericyte production of cell-associated VEGF

- is differentiation-dependent and is associated with endothelial survival. *Dev Biol* 2003; 264:275-88.
21. Chan-Ling T, Page MP, Gardiner T, Baxter L, Rosinova E, Hughes S. Desmin ensheathment ratio as an indicator of vessel stability: evidence in normal development and in retinopathy of prematurity. *Am J Pathol* 2004; 165:1301-13.
  22. Penfold PL, Provis JM, Madigan MC, van Driel D, Billson FA. Angiogenesis in normal human retinal development: the involvement of astrocytes and macrophages. *Graefes Arch Clin Exp Ophthalmol* 1990; 228:255-63.
  23. Naug HL, Browning J, Gole GA, Gobe G. Vitreal macrophages express vascular endothelial growth factor in oxygen-induced retinopathy. *Clin Experiment Ophthalmol* 2000; 28:48-52.
  24. Ambati J, Ambati BK, Yoo SH, Ianchulev S, Adamis AP. Age-related macular degeneration: etiology, pathogenesis, and therapeutic strategies. *Surv Ophthalmol* 2003; 48:257-93.
  25. Hellstrom M, Kalen M, Lindahl P, Abramsson A, Betsholtz C. Role of PDGF-B and PDGFR-beta in recruitment of vascular smooth muscle cells and pericytes during embryonic blood vessel formation in the mouse. *Development* 1999; 126:3047-55.
  26. Mi H, Haerberle H, Barres BA. Induction of astrocyte differentiation by endothelial cells. *J Neurosci* 2001; 21:1538-47.
  27. Hirschi KK, Rohovsky SA, D'Amore PA. PDGF, TGF-beta, and heterotypic cell-cell interactions mediate endothelial cell-induced recruitment of 10T1/2 cells and their differentiation to a smooth muscle fate. *J Cell Biol* 1998; 141:805-14. Erratum in: *J Cell Biol* 1998; 141:1287.
  28. Ashton N, Ward B, Serpell G. Effect of oxygen on developing retinal vessels with particular reference to the problem of retrolental fibroplasia. *Br J Ophthalmol* 1954; 38:397-432.
  29. Patz A. Retrolental fibroplasia; experimental studies. *Trans Am Acad Ophthalmol Otolaryngol* 1955; 59:25-34; discussion 40-1.
  30. Flower RW, Patz A, Speiser P. New method for studying immature retinal vessels in vivo. *Invest Ophthalmol* 1968; 7:366-70.
  31. Patz A. The role of oxygen in retrolental fibroplasia. *Trans Am Ophthalmol Soc* 1968; 66:940-85.
  32. Phelps DL, Rosenbaum AL. The role of tocopherol in oxygen-induced retinopathy: kitten model. *Pediatrics* 1977; 59 Suppl:998-1005.
  33. Phelps DL. Reduced severity of oxygen-induced retinopathy in kittens recovered in 28% oxygen. *Pediatr Res* 1988; 24:106-9.
  34. Chan-Ling T, Tout S, Hollander H, Stone J. Vascular changes and their mechanisms in the feline model of retinopathy of prematurity. *Invest Ophthalmol Vis Sci* 1992; 33:2128-47.
  35. Chan-Ling T, Stone J. Degeneration of astrocytes in feline retinopathy of prematurity causes failure of the blood-retinal barrier. *Invest Ophthalmol Vis Sci* 1992; 33:2148-59.
  36. Tailoi CL, Gock B, Stone J. Supplemental oxygen therapy. Basis for noninvasive treatment of retinopathy of prematurity. *Invest Ophthalmol Vis Sci* 1995; 36:1215-30.
  37. Patz A. Oxygen studies in retrolental fibroplasia. IV. Clinical and experimental observations. *Am J Ophthalmol* 1954; 38:291-308.
  38. Donahue ML, Phelps DL, Watkins RH, LoMonaco MB, Horowitz S. Retinal vascular endothelial growth factor (VEGF) mRNA expression is altered in relation to neovascularization in oxygen induced retinopathy. *Curr Eye Res* 1996; 15:175-84.
  39. Stone J, Chan-Ling T, Pe'er J, Itin A, Gnessin H, Keshet E. Roles of vascular endothelial growth factor and astrocyte degeneration in the genesis of retinopathy of prematurity. *Invest Ophthalmol Vis Sci* 1996; 37:290-9.
  40. Patz A. Clinical and experimental studies on role of oxygen in retrolental fibroplasia. *Trans Am Acad Ophthalmol Otolaryngol* 1954; 58:45-50.
  41. Flower RW, Blake DA. Retrolental fibroplasia: evidence for a role of the prostaglandin cascade in the pathogenesis of oxygen-induced retinopathy in the newborn beagle. *Pediatr Res* 1981; 15:1293-302.
  42. Flower RW, McLeod DS, Luty GA, Goldberg B, Wajer SD. Postnatal retinal vascular development of the puppy. *Invest Ophthalmol Vis Sci* 1985; 26:957-68.
  43. McLeod DS, Luty GA, Wajer SD, Flower RW. Visualization of a developing vasculature. *Microvasc Res* 1987; 33:257-69.
  44. Taomoto M, McLeod DS, Merges C, Luty GA. Localization of adenosine A2a receptor in retinal development and oxygen-induced retinopathy. *Invest Ophthalmol Vis Sci* 2000; 41:230-43.
  45. Ling TL, Stone J. The development of astrocytes in the cat retina: evidence of migration from the optic nerve. *Brain Res Dev Brain Res* 1988; 44:73-85.
  46. McLeod DS, Brownstein R, Luty GA. Vaso-oblivation in the canine model of oxygen-induced retinopathy. *Invest Ophthalmol Vis Sci* 1996; 37:300-11.
  47. McLeod DS, Crone SN, Luty GA. Vasoproliferation in the neonatal dog model of oxygen-induced retinopathy. *Invest Ophthalmol Vis Sci* 1996; 37:1322-33.
  48. McLeod DS, D'Anna SA, Luty GA. Clinical and histopathologic features of canine oxygen-induced proliferative retinopathy. *Invest Ophthalmol Vis Sci* 1998; 39:1918-32.
  49. Luty GA, McLeod DS. Retinal vascular development and oxygen-induced retinopathy: a role for adenosine. *Prog Retin Eye Res* 2003; 22:95-111.
  50. Luty GA, Merges C, McLeod DS. 5' nucleotidase and adenosine during retinal vasculogenesis and oxygen-induced retinopathy. *Invest Ophthalmol Vis Sci* 2000; 41:218-29.
  51. McLeod DS, Taomoto M, Cao J, Zhu Z, Witte L, Luty GA. Localization of VEGF receptor-2 (KDR/Flk-1) and effects of blocking it in oxygen-induced retinopathy. *Invest Ophthalmol Vis Sci* 2002; 43:474-82.
  52. Patz A, Eastham AB. Oxygen studies in retrolental fibroplasia. VI. The effect of concentration and duration of exposure to oxygen on the immature mouse eye. *Am J Ophthalmol* 1957; 44:110-8.
  53. Gyllensten LJ, Hellstrom BE. Experimental approach to the pathogenesis of retrolental fibroplasia. I. Changes of the eye induced by exposure of newborn mice to concentrated oxygen. *Acta Paediatr Suppl* 1954; 43:131-48.
  54. Penn JS, Tolman BL, Lowery LA. Variable oxygen exposure causes preretinal neovascularization in the newborn rat. *Invest Ophthalmol Vis Sci* 1993; 34:576-85.
  55. Smith LE, Wesolowski E, McLellan A, Kostyk SK, D'Amato R, Sullivan R, D'Amore PA. Oxygen-induced retinopathy in the mouse. *Invest Ophthalmol Vis Sci* 1994; 35:101-11.
  56. Penn JS, Henry MM, Tolman BL. Exposure to alternating hypoxia and hyperoxia causes severe proliferative retinopathy in the newborn rat. *Pediatr Res* 1994; 36:724-31. Erratum in: *Pediatr Res* 1995; 37:353.
  57. Kitzmann A, Leske D, Chen Y, Kendall A, Lanier W, Holmes J. Incidence and severity of neovascularization in oxygen- and metabolic acidosis-induced retinopathy depend on rat source. *Curr Eye Res* 2002; 25:215-20.
  58. Holmes JM, Zhang S, Leske DA, Lanier WL. Metabolic acidosis-induced retinopathy in the neonatal rat. *Invest Ophthalmol Vis Sci* 1999; 40:804-9.
  59. Rohan RM, Fernandez A, Udagawa T, Yuan J, D'Amato RJ. Genetic heterogeneity of angiogenesis in mice. *FASEB J* 2000; 14:871-6.

60. Rogers MS, Rohan RM, Birsner AE, D'Amato RJ. Genetic loci that control vascular endothelial growth factor-induced angiogenesis. *FASEB J* 2003; 17:2112-4.
61. Rogers MS, Rohan RM, Birsner AE, D'Amato RJ. Genetic loci that control the angiogenic response to basic fibroblast growth factor. *FASEB J* 2004; 18:1050-9.
62. Chan CK, Pham LN, Chinn C, Spee C, Ryan SJ, Akhurst RJ, Hinton DR. Mouse strain-dependent heterogeneity of resting limbal vasculature. *Invest Ophthalmol Vis Sci* 2004; 45:441-7.
63. Gao G, Li Y, Fant J, Crosson CE, Becerra SP, Ma JX. Difference in ischemic regulation of vascular endothelial growth factor and pigment epithelium—derived factor in brown norway and sprague dawley rats contributing to different susceptibilities to retinal neovascularization. *Diabetes* 2002; 51:1218-25.
64. Chan CK, Pham LN, Zhou J, Spee C, Ryan SJ, Hinton DR. Early regulation of strain-dependent retinal angiogenesis. *ARVO Annual Meeting*; 2003 May 4-9; Fort Lauderdale (FL).
65. Ling TL, Mitrofanis J, Stone J. Origin of retinal astrocytes in the rat: evidence of migration from the optic nerve. *J Comp Neurol* 1989; 286:345-52.
66. Huxlin KR, Sefton AJ, Furby JH. The origin and development of retinal astrocytes in the mouse. *J Neurocytol* 1992; 21:530-44.
67. Alon T, Hemo I, Itin A, Pe'er J, Stone J, Keshet E. Vascular endothelial growth factor acts as a survival factor for newly formed retinal vessels and has implications for retinopathy of prematurity. *Nat Med* 1995; 1:1024-8.
68. Miquelot L, Gertsenstein M, Harpal K, Rossant J, Nagy A. Multiple developmental roles of VEGF suggested by a LacZ-tagged allele. *Dev Biol* 1999; 212:307-22.
69. Ng YS, Rohan R, Sunday ME, Demello DE, D'Amore PA. Differential expression of VEGF isoforms in mouse during development and in the adult. *Dev Dyn* 2001; 220:112-21.
70. Carmeliet P, Ng YS, Nuyens D, Theilmeier G, Brusselmans K, Cornelissen I, Ehler E, Kakkav VV, Stalmans I, Mattot V, Perriard JC, Dewerchin M, Flameng W, Nagy A, Lupu F, Moons L, Collen D, D'Amore PA, Shima DT. Impaired myocardial angiogenesis and ischemic cardiomyopathy in mice lacking the vascular endothelial growth factor isoforms VEGF164 and VEGF188. *Nat Med* 1999; 5:495-502.
71. Galambos C, Ng YS, Ali A, Noguchi A, Lovejoy S, D'Amore PA, DeMello DE. Defective pulmonary development in the absence of heparin-binding vascular endothelial growth factor isoforms. *Am J Respir Cell Mol Biol* 2002; 27:194-203.
72. Stalmans I, Ng YS, Rohan R, Fruttiger M, Bouche A, Yuce A, Fujisawa H, Hermans B, Shani M, Jansen S, Hicklin D, Anderson DJ, Gardiner T, Hammes HP, Moons L, Dewerchin M, Collen D, Carmeliet P, D'Amore PA. Arteriolar and venular patterning in retinas of mice selectively expressing VEGF isoforms. *J Clin Invest* 2002; 109:327-36.
73. Ishida S, Usui T, Yamashiro K, Kaji Y, Amano S, Ogura Y, Hida T, Oguchi Y, Ambati J, Miller JW, Gragoudas ES, Ng YS, D'Amore PA, Shima DT, Adamis AP. VEGF164-mediated inflammation is required for pathological, but not physiological, ischemia-induced retinal neovascularization. *J Exp Med* 2003; 198:483-9.
74. Benjamin LE, Golijanin D, Itin A, Pode D, Keshet E. Selective ablation of immature blood vessels in established human tumors follows vascular endothelial growth factor withdrawal. *J Clin Invest* 1999; 103:159-65.
75. Esser S, Wolburg K, Wolburg H, Breier G, Kurzchalia T, Risau W. Vascular endothelial growth factor induces endothelial fenestrations in vitro. *J Cell Biol* 1998; 140:947-59.
76. Witmer AN, Dai J, Weich HA, Vrensen GF, Schlingemann RO. Expression of vascular endothelial growth factor receptors 1, 2, and 3 in quiescent endothelia. *J Histochem Cytochem* 2002; 50:767-77.
77. Saint-Geniez M, D'Amore PA. Development and pathology of the hyaloid, choroidal and retinal vasculature. *Int J Dev Biol* 2004; 48:1045-58.
78. Patz A, Hoek LE, De La Cruz E. Studies on the effect of high oxygen administration in retrolental fibroplasia. I. Nursery observations. *Am J Ophthalmol* 1952; 35:1248-53.
79. Phelps DL. Retinopathy of prematurity: an estimate of vision loss in the United States—1979. *Pediatrics* 1981; 67:924-5.
80. Flynn JT. Acute proliferative retrolental fibroplasia: multivariate risk analysis. *Trans Am Ophthalmol Soc* 1983; 81:549-91.
81. Penn JS, Tolman BL, Henry MM. Oxygen-induced retinopathy in the rat: relationship of retinal nonperfusion to subsequent neovascularization. *Invest Ophthalmol Vis Sci* 1994; 35:3429-35.
82. Pierce EA, Avery RL, Foley ED, Aiello LP, Smith LE. Vascular endothelial growth factor/vascular permeability factor expression in a mouse model of retinal neovascularization. *Proc Natl Acad Sci U S A* 1995; 92:905-9.
83. Robinson GS, Pierce EA, Rook SL, Foley E, Webb R, Smith LE. Oligodeoxynucleotides inhibit retinal neovascularization in a murine model of proliferative retinopathy. *Proc Natl Acad Sci U S A* 1996; 93:4851-6.
84. Aiello LP, Pierce EA, Foley ED, Takagi H, Chen H, Riddle L, Ferrara N, King GL, Smith LE. Suppression of retinal neovascularization in vivo by inhibition of vascular endothelial growth factor (VEGF) using soluble VEGF-receptor chimeric proteins. *Proc Natl Acad Sci U S A* 1995; 92:10457-61.
85. Young TL, Anthony DC, Pierce E, Foley E, Smith LE. Histopathology and vascular endothelial growth factor in untreated and diode laser-treated retinopathy of prematurity. *J AAPOS* 1997; 1:105-10.
86. Miller JW, Adamis AP, Shima DT, D'Amore PA, Moulton RS, O'Reilly MS, Folkman J, Dvorak HF, Brown LF, Berse B, Yeo T-K, Yeo K-T. Vascular endothelial growth factor/vascular permeability factor is temporally and spatially correlated with ocular angiogenesis in a primate model. *Am J Pathol* 1994; 145:574-84.
87. Adamis AP, Shima DT, Tolentino MJ, Gragoudas ES, Ferrara N, Folkman J, D'Amore PA, Miller JW. Inhibition of vascular endothelial growth factor prevents retinal ischemia-associated iris neovascularization in a nonhuman primate. *Arch Ophthalmol* 1996; 114:66-71.
88. Aiello LP, Avery RL, Arrigg PG, Keyt BA, Jampel HD, Shah ST, Pasquale LR, Thieme H, Iwamoto MA, Park JE, Nguyen HV, Aiello LM, Ferrara N, King GL. Vascular endothelial growth factor in ocular fluid of patients with diabetic retinopathy and other retinal disorders. *N Engl J Med* 1994; 331:1480-7.
89. Adamis AP, Miller JW, Bernal MT, D'Amico DJ, Folkman J, Yeo TK, Yeo KT. Increased vascular endothelial growth factor levels in the vitreous of eyes with proliferative diabetic retinopathy. *Am J Ophthalmol* 1994; 118:445-50.
90. Pierce EA, Foley ED, Smith LE. Regulation of vascular endothelial growth factor by oxygen in a model of retinopathy of prematurity. *Arch Ophthalmol* 1996; 114:1219-28. Erratum in: *Arch Ophthalmol* 1997; 115:427.
91. Shih SC, Ju M, Liu N, Smith LE. Selective stimulation of VEGFR-1 prevents oxygen-induced retinal vascular degeneration in retinopathy of prematurity. *J Clin Invest* 2003; 112:50-7.
92. Smith LE, Kopchick JJ, Chen W, Knapp J, Kinose F, Daley D, Foley E, Smith RG, Schaeffer JM. Essential role of growth hor-

- mone in ischemia-induced retinal neovascularization. *Science* 1997; 276:1706-9.
93. Smith LE, Shen W, Perruzzi C, Soker S, Kinose F, Xu X, Robinson G, Driver S, Bischoff J, Zhang B, Schaeffer JM, Senger DR. Regulation of vascular endothelial growth factor-dependent retinal neovascularization by insulin-like growth factor-1 receptor. *Nat Med* 1999; 5:1390-5.
  94. Hellstrom A, Perruzzi C, Ju M, Engstrom E, Hard AL, Liu JL, Albertsson-Wikland K, Carlsson B, Niklasson A, Sjodell L, LeRoith D, Senger DR, Smith LE. Low IGF-I suppresses VEGF-survival signaling in retinal endothelial cells: direct correlation with clinical retinopathy of prematurity. *Proc Natl Acad Sci U S A* 2001; 98:5804-8.
  95. Hellstrom A, Engstrom E, Hard AL, Albertsson-Wikland K, Carlsson B, Niklasson A, Lofqvist C, Svensson E, Holm S, Ewald U, Holmstrom G, Smith LE. Postnatal serum insulin-like growth factor I deficiency is associated with retinopathy of prematurity and other complications of premature birth. *Pediatrics* 2003; 112:1016-20.
  96. An international classification of retinopathy of prematurity. The Committee for the Classification of Retinopathy of Prematurity. *Arch Ophthalmol* 1984; 102:1130-4.
  97. Palmer EA, Flynn JT, Hardy RJ, Phelps DL, Phillips CL, Schaffer DB, Tung B. Incidence and early course of retinopathy of prematurity. The Cryotherapy for Retinopathy of Prematurity Cooperative Group. *Ophthalmology* 1991; 98:1628-40.
  98. Multicenter trial of cryotherapy for retinopathy of prematurity. One-year outcome—structure and function. Cryotherapy for Retinopathy of Prematurity Cooperative Group. *Arch Ophthalmol* 1990; 108:1408-16.
  99. Multicenter trial of cryotherapy for retinopathy of prematurity. Preliminary results. Cryotherapy for Retinopathy of Prematurity Cooperative Group. *Arch Ophthalmol* 1988; 106:471-9.
  100. Cryotherapy for Retinopathy of Prematurity Cooperative Group. Multicenter Trial of Cryotherapy for Retinopathy of Prematurity: ophthalmological outcomes at 10 years. *Arch Ophthalmol* 2001; 119:1110-8.
  101. Cryotherapy for Retinopathy of Prematurity Cooperative Group. Effect of retinal ablative therapy for threshold retinopathy of prematurity: results of Goldmann perimetry at the age of 10 years. *Arch Ophthalmol* 2001; 119:1120-5.
  102. Reynolds JD, Dobson V, Quinn GE, Fielder AR, Palmer EA, Saunders RA, Hardy RJ, Phelps DL, Baker JD, Trese MT, Schaffer D, Tung B, CRYO-ROP and LIGHT-ROP Cooperative Study Groups. Evidence-based screening criteria for retinopathy of prematurity: natural history data from the CRYO-ROP and LIGHT-ROP studies. *Arch Ophthalmol* 2002; 120:1470-6.
  103. Hardy RJ, Palmer EA, Dobson V, Summers CG, Phelps DL, Quinn GE, Good WV, Tung B. Cryotherapy for Retinopathy of Prematurity Cooperative Group. Risk analysis of prethreshold retinopathy of prematurity. *Arch Ophthalmol* 2003; 121:1697-701.
  104. Palmer EA, Hardy RJ, Dobson V, Phelps DL, Quinn GE, Summers CG, Krom CP, Tung B. Cryotherapy for Retinopathy of Prematurity Cooperative Group. 15-year outcomes following threshold retinopathy of prematurity: final results from the multicenter trial of cryotherapy for retinopathy of prematurity. *Arch Ophthalmol* 2005; 123:311-8.
  105. Teller DY, McDonald MA, Preston K, Sebris SL, Dobson V. Assessment of visual acuity in infants and children: the acuity card procedure. *Dev Med Child Neurol* 1986; 28:779-89.
  106. Dobson V, Quinn GE, Summers CG, Saunders RA, Phelps DL, Tung B, Palmer EA. Effect of acute-phase retinopathy of prematurity on grating acuity development in the very low birth weight infant. The Cryotherapy for Retinopathy of Prematurity Cooperative Group. *Invest Ophthalmol Vis Sci* 1994; 35:4236-44.
  107. Salomao SR, Ventura DF. Large sample population age norms for visual acuities obtained with Vistech-Teller Acuity Cards. *Invest Ophthalmol Vis Sci* 1995; 36:657-70.
  108. Mayer DL, Beiser AS, Warner AF, Pratt EM, Raye KN, Lang JM. Monocular acuity norms for the Teller Acuity Cards between ages one month and four years. *Invest Ophthalmol Vis Sci* 1995; 36:671-85.
  109. Cryotherapy for Retinopathy of Prematurity Cooperative Group. Multicenter trial of cryotherapy for retinopathy of prematurity: natural history ROP: ocular outcome at 5(1/2) years in premature infants with birth weights less than 1251 g. *Arch Ophthalmol* 2002; 120:595-9.
  110. Ferris FL 3rd, Kassoff A, Bresnick GH, Bailey I. New visual acuity charts for clinical research. *Am J Ophthalmol* 1982; 94:91-6.
  111. Multicenter trial of cryotherapy for retinopathy of prematurity. 3 1/2-year outcome—structure and function. Cryotherapy for Retinopathy of Prematurity Cooperative Group. *Arch Ophthalmol* 1993; 111:339-44.
  112. Multicenter trial of cryotherapy for retinopathy of prematurity. Snellen visual acuity and structural outcome at 5 1/2 years after randomization. Cryotherapy for Retinopathy of Prematurity Cooperative Group. *Arch Ophthalmol* 1996; 114:417-24.
  113. Quinn GE, Dobson V, Kivlin J, Kaufman LM, Repka MX, Reynolds JD, Gordon RA, Hardy RJ, Tung B, Stone RA. Prevalence of myopia between 3 months and 5 1/2 years in preterm infants with and without retinopathy of prematurity. Cryotherapy for Retinopathy of Prematurity Cooperative Group. *Ophthalmology* 1998; 105:1292-300.
  114. Dorn EM, Hendrickson L, Hendrickson AE. The appearance of rod opsin during monkey retinal development. *Invest Ophthalmol Vis Sci* 1995; 36:2634-51.
  115. Hendrickson A, Drucker D. The development of parafoveal and mid-peripheral human retina. *Behav Brain Res* 1992; 49:21-31.
  116. Fulton AB, Hansen RM, Dorn E, Hendrickson AE. Development of primate rod structure and function. In: Vital-Durand F, Atkinson J, Braddick OJ, editors. *Infant Vision*. Oxford: Oxford University Press; 1996. p. 33-49.
  117. Hansen RM, Fulton AB. The course of maturation of rod-mediated visual thresholds in infants. *Invest Ophthalmol Vis Sci* 1999; 40:1883-6.
  118. Hansen RM, Fulton AB. Rod-mediated increment threshold functions in infants. *Invest Ophthalmol Vis Sci* 2000; 41:4347-52.
  119. Jolesz M, Vanderveen D, Hansen RM, Fulton A. Development of rod mediated visual thresholds in infants with a history of mild retinopathy of prematurity. ARVO Annual Meeting; 2002 May 5-10; Fort Lauderdale (FL).
  120. Reisner DS, Hansen RM, Findl O, Petersen RA, Fulton AB. Dark-adapted thresholds in children with histories of mild retinopathy of prematurity. *Invest Ophthalmol Vis Sci* 1997; 38:1175-83.
  121. Lamb TD, Pugh EN Jr. A quantitative account of the activation steps involved in phototransduction in amphibian photoreceptors. *J Physiol* 1992; 449:719-58.
  122. Pugh EN Jr, Lamb TD. Amplification and kinetics of the activation steps in phototransduction. *Biochim Biophys Acta* 1993; 1141:111-49.
  123. Pugh EN Jr, Lamb TD. Phototransduction in vertebrate rods and cones: molecular mechanisms of amplification, recovery

- and light adaptation. In: Stavenga DG, de Grip WJ, Pugh EN Jr, editors. Handbook of biological physics. Vol 3. Molecular mechanisms of visual transduction. New York: Elsevier; 2000. p. 183-255.
124. Fulton AB, Hansen RM, Findl O. The development of the rod photoresponse from dark-adapted rats. *Invest Ophthalmol Vis Sci* 1995; 36:1038-45.
  125. Fulton AB, Hansen RM. The development of scotopic sensitivity. *Invest Ophthalmol Vis Sci* 2000; 41:1588-96.
  126. Fulton AB, Hansen RM, Petersen RA, Vanderveen DK. The rod photoreceptors in retinopathy of prematurity: an electroretinographic study. *Arch Ophthalmol* 2001; 119:499-505.
  127. The STOP-ROP, Multicenter Study Group. Supplemental Therapeutic Oxygen for Prethreshold Retinopathy Of Prematurity (STOP-ROP), a randomized, controlled trial. I: primary outcomes. *Pediatrics* 2000; 105:295-310.
  128. Foos RY. Retinopathy of prematurity. Pathologic correlation of clinical stages. *Retina* 1987; 7:260-76.
  129. Tin W. Oxygen therapy: 50 years of uncertainty. *Pediatrics* 2002; 110:615-6.
  130. Saugstad OD. The oxygen radical disease in neonatology. *Indian J Pediatr* 1989 Sep-Oct; 56:585-93.
  131. Saugstad OD. Oxygen toxicity in the neonatal period. *Acta Paediatr Scand* 1990; 79:881-92.
  132. Balentine JD. Pathology of oxygen toxicity. New York: Academic Press; 1982.
  133. Weinberger B, Laskin DL, Heck DE, Laskin JD. Oxygen toxicity in premature infants. *Toxicol Appl Pharmacol* 2002; 181:60-7.
  134. Tin W, Walker S, Lacamp C. Oxygen monitoring in preterm babies: too high, too low? *Paediatr Respir Rev* 2003; 4:9-14.
  135. Tin W, Wariyar U. Giving small babies oxygen: 50 years of uncertainty. *Semin Neonatol* 2002; 7:361-7.
  136. Tin W, Milligan DW, Pennefather P, Hey E. Pulse oximetry, severe retinopathy, and outcome at one year in babies of less than 28 weeks gestation. *Arch Dis Child Fetal Neonatal Ed* 2001; 84:F106-10.
  137. Anderson CG, Benitz WE, Madan A. Retinopathy of prematurity and pulse oximetry: a national survey of recent practices. *J Perinatol* 2004; 24:164-8.
  138. Sun SC. Relation of target SpO<sub>2</sub> levels and clinical outcome in ELBW infants on supplemental oxygen. *Pediatr Res* 2002; 51:350A.
  139. Chow LC, Wright KW, Sola A, CSMC Oxygen Administration Study Group. Can changes in clinical practice decrease the incidence of severe retinopathy of prematurity in very low birth weight infants? *Pediatrics* 2003; 111:339-45.
  140. Ashton N, Ward B, Serpell G. Role of oxygen in the genesis of retrolental fibroplasia; a preliminary report. *Br J Ophthalmol* 1953; 37:513-20.
  141. Ashton N, Cook C. Direct observation of the effect of oxygen on developing vessels: preliminary report. *Br J Ophthalmol* 1954; 38:433-40.
  142. Ashton N. Oxygen and the growth and development of retinal vessels. In vivo and in vitro studies. The XX Francis I. Proctor Lecture. *Am J Ophthalmol* 1966; 62:412-35.
  143. Penn JS, Thum LA. Oxygen-induced retinopathy in the rat. *Basic Life Sci* 1988; 49:1025-8.
  144. Madan A, Penn JS. Animal models of oxygen-induced retinopathy. *Front Biosci* 2003; 8:d1030-43.
  145. Phelps DL. Oxygen and developmental retinal capillary remodeling in the kitten. *Invest Ophthalmol Vis Sci* 1990; 31:2194-200.
  146. McColm JR, Cunningham S, Wade J, Sedowofia K, Gellen B, Sharma T, McIntosh N, Fleck BW. Hypoxic oxygen fluctuations produce less severe retinopathy than hyperoxic fluctuations in a rat model of retinopathy of prematurity. *Pediatr Res* 2004; 55:107-13.
  147. Silverman WA, Flynn JT, editors. Contemporary Issues in Fetal and Neonatal Medicine. Retinopathy of prematurity. Boston: Blackwell Scientific; 1985.
  148. Silverman WA. A cautionary tale about supplemental oxygen: the albatross of neonatal medicine. *Pediatrics* 2004; 113:394-6.
  149. Kinsey VE. Retrolental fibroplasia; cooperative study of retrolental fibroplasia and the use of oxygen. *AMA Arch Ophthalmol* 1956; 56:481-543.
  150. Lanman JT, Guy LP, Dancis J. Retrolental fibroplasia and oxygen therapy. *J Am Med Assoc* 1954; 155:223-6.
  151. Duc G, Sinclair JC. Oxygen administration. In: Sinclair JC, Bracken MB, editors. Effective care of the newborn infant. New York: Oxford University Press; 1992. p. 178-99.
  152. Askie LM, Henderson-Smart DJ. Restricted versus liberal oxygen exposure for preventing morbidity and mortality in preterm or low birth weight infants. *Cochrane Database Syst Rev* 2001; (4):CD001077.
  153. Avery ME. Recent increase in mortality from hyaline membrane disease. *J Pediatr* 1960; 57:553-9.
  154. McDonald AD. The aetiology of spastic diplegia. A synthesis of epidemiological and pathological evidence. *Dev Med Child Neurol* 1964; 11:277-85.
  155. Cross KW. Cost of preventing retrolental fibroplasia? *Lancet* 1973; 2:954-6.
  156. Bolton DP, Cross KW. Further observations on cost of preventing retrolental fibroplasia. *Lancet* 1974; 1:445-8.
  157. Tin W. Ten year neurodevelopmental outcome of premature infants <28 weeks with early oxygen restriction. Hot Topics in Neonatology Meeting. 2003 December 8-9. Washington, DC.
  158. Schulze A, Whyte RK, Way RC, Sinclair JC. Effect of the arterial oxygenation level on cardiac output, oxygen extraction, and oxygen consumption in low birth weight infants receiving mechanical ventilation. *J Pediatr* 1995; 126:777-84.
  159. Skinner JR, Hunter S, Poets CF, Milligan DW, Southall D, Hey EN. Haemodynamic effects of altering arterial oxygen saturation in preterm infants with respiratory failure. *Arch Dis Child Fetal Neonatal Ed* 1999; 80:F81-7.
  160. Skinner JR, Boys RJ, Hunter S, Hey EN. Pulmonary and systemic arterial pressure in hyaline membrane disease. *Arch Dis Child* 1992; 67:366-73.
  161. Evans NJ, Archer LN. Doppler assessment of pulmonary artery pressure during recovery from hyaline membrane disease. *Arch Dis Child* 1991; 66:802-4.
  162. Abman SH, Wolfe RR, Accurso FJ, Koops BL, Bowman CM, Wiggins JW Jr. Pulmonary vascular response to oxygen in infants with severe bronchopulmonary dysplasia. *Pediatrics* 1985; 75:80-4.
  163. Halliday HL, Dumpit FM, Brady JP. Effects of inspired oxygen on echocardiographic assessment of pulmonary vascular resistance and myocardial contractility in bronchopulmonary dysplasia. *Pediatrics* 1980; 65:536-40.
  164. Bard H, Belanger S, Fouron JC. Comparison of effects of 95% and 90% oxygen saturations in respiratory distress syndrome. *Arch Dis Child Fetal Neonatal Ed* 1996; 75:F94-6.
  165. Capone A Jr, Trese MT. Lens-sparing vitreous surgery for tractional stage 4A retinopathy of prematurity retinal detachments. *Ophthalmology* 2001; 108:2068-70.
  166. Moshfeghi AA, Banach MJ, Salam GA, Ferrone PJ. Lens-spar-

- ing vitrectomy for progressive tractional retinal detachments associated with stage 4A retinopathy of prematurity. *Arch Ophthalmol* 2004; 122:1816-8.
167. Hubbard GB 3rd, Cherwick DH, Burian G. Lens-sparing vitrectomy for stage 4 retinopathy of prematurity. *Ophthalmology* 2004; 111:2274-7.
  168. Prenner JL, Capone A Jr, Trese MT. Visual outcomes after lens-sparing vitrectomy for stage 4A retinopathy of prematurity. *Ophthalmology* 2004; 111:2271-3.
  169. Campbell PB, Bull MJ, Ellis FD, Bryson CQ, Lemons JA, Schreiner RL. Incidence of retinopathy of prematurity in a tertiary newborn intensive care unit. *Arch Ophthalmol* 1983; 101:1686-8.
  170. The natural ocular outcome of premature birth and retinopathy. Status at 1 year. Cryotherapy for Retinopathy of Prematurity Cooperative Group. *Arch Ophthalmol* 1994; 112:903-12.
  171. Tasman W. Late complications of retrolental fibroplasia. *Ophthalmology* 1979; 86:1724-40.
  172. Hartnett ME, Gilbert MM, Hirose T, Richardson TM, Katsumi O. Glaucoma as a cause of poor vision in severe retinopathy of prematurity. *Graefes Arch Clin Exp Ophthalmol* 1993; 231:433-8.
  173. Choi MY, Park IK, Yu YS. Long term refractive outcome in eyes of preterm infants with and without retinopathy of prematurity: comparison of keratometric value, axial length, anterior chamber depth, and lens thickness. *Br J Ophthalmol* 2000; 84:138-43.
  174. Knight-Nanan DM, Algawi K, Bowell R, O'Keefe M. Advanced cicatricial retinopathy of prematurity—outcome and complications. *Br J Ophthalmol* 1996; 80:343-5.
  175. Maly E. Frequency and natural history of retinopathy of prematurity (ROP). A prospective study in a Swedish city 1986-1990. *Acta Ophthalmol Suppl* 1993; 210:52-5.
  176. Kaiser RS, Trese MT, Williams GA, Cox MS Jr. Adult retinopathy of prematurity: outcomes of rhegmatogenous retinal detachments and retinal tears. *Ophthalmology* 2001; 108:1647-53.
  177. Sneed SR, Pulido JS, Blodi CF, Clarkson JG, Flynn HW Jr, Mieler WF. Surgical management of late-onset retinal detachments associated with regressed retinopathy of prematurity. *Ophthalmology* 1990; 97:179-83.
  178. Greven C, Tasman W. Scleral buckling in stages 4B and 5 retinopathy of prematurity. *Ophthalmology* 1990; 97:817-20.
  179. Nissenkorn I, Yassar Y, Mashkowski D, Sherf I, Ben-Sira I. Myopia in premature babies with and without retinopathy of prematurity. *Br J Ophthalmol* 1983; 67:170-3.
  180. Knight-Nanan DM, O'Keefe M. Refractive outcome in eyes with retinopathy of prematurity treated with cryotherapy or diode laser: 3 year follow up. *Br J Ophthalmol* 1996; 80:998-1001.
  181. Smith J, Shivitz I. Angle-closure glaucoma in adults with cicatricial retinopathy of prematurity. *Arch Ophthalmol* 1984; 102:371-2.
  182. Ferrone PJ, Trese MT, Williams GA, Cox MS. Good visual acuity in an adult population with marked posterior segment changes secondary to retinopathy of prematurity. *Retina* 1998; 18:335-8.
  183. Hennekens CH, Buring JE. Screening. In: Mayrent SL, editor. *Epidemiology in medicine*. Boston: Little, Brown; 1987. p. 327-47.
  184. American Academy of Pediatrics. Section on Ophthalmology. Screening examination of premature infants for retinopathy of prematurity. *Pediatrics* 2001; 108:809-11.
  185. Early Treatment For Retinopathy Of Prematurity Cooperative Group. Revised indications for the treatment of retinopathy of prematurity: results of the early treatment for retinopathy of prematurity randomized trial. *Arch Ophthalmol* 2003; 121:1684-94.
  186. Cantolino SJ, O'Grady GE, Herrera JA, Israel C, Justice J Jr, Flynn JT. Ophthalmoscopic monitoring of oxygen therapy in premature infants. Fluorescein angiography in acute retrolental fibroplasia. *Am J Ophthalmol* 1971; 72:322-31.
  187. Flynn JT. Acute proliferative retrolental fibroplasia: evolution of the lesion. *Albrecht Von Graefes Arch Klin Exp Ophthalmol* 1975; 195:101-11.
  188. Schmidt B, Davis P, Moddemann D, Ohlsson A, Roberts RS, Saigal S, Solimano A, Vincer M, Wright LL, Trial of Indomethacin Prophylaxis in Preterms Investigators. Long-term effects of indomethacin prophylaxis in extremely-low-birth-weight infants. *N Engl J Med* 2001; 344:1966-72.
  189. Vohr BR, Wright LL, Dusick AM, Mele L, Verter J, Steichen JJ, Simon NP, Wilson DC, Broyles S, Bauer CR, Delaney-Black V, Yolton KA, Fleisher BE, Papile LA, Kaplan MD. Neurodevelopmental and functional outcomes of extremely low birth weight infants in the National Institute of Child Health and Human Development Neonatal Research Network, 1993-1994. *Pediatrics* 2000; 105:1216-26.
  190. Steinkuller PG, Du L, Gilbert C, Foster A, Collins ML, Coats DK. Childhood blindness. *J AAPOS* 1999; 3:26-32.
  191. Senger DR, Galli SJ, Dvorak AM, Perruzzi CA, Harvey VS, Dvorak HF. Tumor cells secrete a vascular permeability factor that promotes accumulation of ascites fluid. *Science* 1983; 219:983-5.
  192. Leung DW, Cachianes G, Kuang WJ, Goeddel DV, Ferrara N. Vascular endothelial growth factor is a secreted angiogenic mitogen. *Science* 1989; 246:1306-9.
  193. Keck PJ, Hauser SD, Krivi G, Sanzo K, Warren T, Feder J, Connolly DT. Vascular permeability factor, an endothelial cell mitogen related to PDGF. *Science* 1989; 246:1309-12.
  194. Adamis AP, Shima DT, Yeo KT, Yeo TK, Brown LF, Berse B, D'Amore PA, Folkman J. Synthesis and secretion of vascular permeability factor/vascular endothelial growth factor by human retinal pigment epithelial cells. *Biochem Biophys Res Commun* 1993; 193:631-8.
  195. Tolentino MJ, Miller JW, Gragoudas ES, Chatzistefanou K, Ferrara N, Adamis AP. Vascular endothelial growth factor is sufficient to produce iris neovascularization and neovascular glaucoma in a nonhuman primate. *Arch Ophthalmol* 1996; 114:964-70.
  196. Amano S, Rohan R, Kuroki M, Tolentino M, Adamis AP. Requirement for vascular endothelial growth factor in wound- and inflammation-related corneal neovascularization. *Invest Ophthalmol Vis Sci* 1998; 39:18-22.
  197. Krzystolik MG, Afshari MA, Adamis AP, Gaudreault J, Gragoudas ES, Michaud NA, Li W, Connolly E, O'Neill CA, Miller JW. Prevention of experimental choroidal neovascularization with intravitreal anti-vascular endothelial growth factor antibody fragment. *Arch Ophthalmol* 2002; 120:338-46.
  198. Ferrara N, Carver-Moore K, Chen H, Dowd M, Lu L, O'Shea KS, Powell-Braxton L, Hillan KJ, Moore MW. Heterozygous embryonic lethality induced by targeted inactivation of the VEGF gene. *Nature* 1996; 380:439-42.
  199. Carmeliet P, Ferreira V, Breier G, Pollefeyt S, Kieckens L, Gertsenstein M, Fahrig M, Vandenhoeck A, Harpal K, Eberhardt C, Declercq C, Pawling J, Moons L, Collen D, Risau W, Nagy A. Abnormal blood vessel development and lethality in embryos lacking a single VEGF allele. *Nature* 1996; 380:435-9.

200. Ruhrberg C, Gerhardt H, Golding M, Watson R, Ioannidou S, Fujisawa H, Betsholtz C, Shima DT. Spatially restricted patterning cues provided by heparin-binding VEGF-A control blood vessel branching morphogenesis. *Genes Dev* 2002; 16:2684-98.
201. Roberts WG, Palade GE. Increased microvascular permeability and endothelial fenestration induced by vascular endothelial growth factor. *J Cell Sci* 1995; 108:2369-79.
202. Clauss M, Gerlach M, Gerlach H, Brett J, Wang F, Familletti PC, Pan YC, Olander JV, Connolly DT, Stern D. Vascular permeability factor: a tumor-derived polypeptide that induces endothelial cell and monocyte procoagulant activity, and promotes monocyte migration. *J Exp Med* 1990; 172:1535-45.
203. Oosthuysen B, Moons L, Storkebaum E, Beck H, Nuyens D, Brusselmans K, Van Dorpe J, Hellings P, Gorselink M, Heymans S, Theilmeier G, Dewerchin M, Laudénbach V, Vermeylen P, Raat H, Acker T, Vleminckx V, Van Den Bosch L, Cashman N, Fujisawa H, Drost MR, Sciot R, Bruyninckx F, Hicklin DJ, Ince C, Gressens P, Lupu F, Plate KH, Robberecht W, Herbert JM, Collen D, Carmeliet P. Deletion of the hypoxia-response element in the vascular endothelial growth factor promoter causes motor neuron degeneration. *Nat Genet* 2001; 28:131-8.
204. Tischer E, Mitchell R, Hartman T, Silva M, Gospodarowicz D, Fiddes JC, Abraham JA. The human gene for vascular endothelial growth factor. Multiple protein forms are encoded through alternative exon splicing. *J Biol Chem* 1991; 266:11947-54.
205. Shima DT, Kuroki M, Deutsch U, Ng YS, Adamis AP, D'Amore PA. The mouse gene for vascular endothelial growth factor. Genomic structure, definition of the transcriptional unit, and characterization of transcriptional and post-transcriptional regulatory sequences. *J Biol Chem* 1996; 271:3877-83.
206. Gerhardt H, Golding M, Fruttiger M, Ruhrberg C, Lundkvist A, Abramsson A, Jeltsch M, Mitchell C, Alitalo K, Shima D, Betsholtz C. VEGF guides angiogenic sprouting utilizing endothelial tip cell filopodia. *J Cell Biol* 2003; 161:1163-77.
207. Miyamoto K, Khosrof S, Bursell SE, Moromizato Y, Aiello LP, Ogura Y, Adamis AP. Vascular endothelial growth factor (VEGF)-induced retinal vascular permeability is mediated by intercellular adhesion molecule-1 (ICAM-1). *Am J Pathol* 2000; 156:1733-9.
208. Eyetech Study Group. Anti-vascular endothelial growth factor therapy for subfoveal choroidal neovascularization secondary to age-related macular degeneration: phase II study results. *Ophthalmology* 2003; 110:979-86.
209. Hiratsuka S, Minowa O, Kuno J, Noda T, Shibuya M. Flt-1 lacking the tyrosine kinase domain is sufficient for normal development and angiogenesis in mice. *Proc Natl Acad Sci U S A* 1998; 95:9349-54.
210. Ishida S, Yamashiro K, Usui T, Kaji Y, Ogura Y, Hida T, Honda Y, Oguchi Y, Adamis AP. Leukocytes mediate retinal vascular remodeling during development and vaso-obliteration in disease. *Nat Med* 2003; 9:781-8.
211. Otani A, Dorrell MI, Kinder K, Moreno SK, Nusinowitz S, Banin E, Heckenlively J, Friedlander M. Rescue of retinal degeneration by intravitreally injected adult bone marrow-derived lineage-negative hematopoietic stem cells. *J Clin Invest* 2004; 114:765-74.
212. Otani A, Kinder K, Ewalt K, Otero FJ, Schimmel P, Friedlander M. Bone marrow-derived stem cells target retinal astrocytes and can promote or inhibit retinal angiogenesis. *Nat Med* 2002; 8:1004-10.
213. Ivanova NB, Dimos JT, Schaniel C, Hackney JA, Moore KA, Lemischka IR. A stem cell molecular signature. *Science* 2002; 298:601-4.
214. Ramalho-Santos M, Yoon S, Matsuzaki Y, Mulligan RC, Melton DA. "Stemness": transcriptional profiling of embryonic and adult stem cells. *Science* 2002; 298:597-600.
215. Raff M. Adult stem cell plasticity: fact or artifact? *Annu Rev Cell Dev Biol* 2003; 19:1-22.
216. Wagers AJ, Weissman IL. Plasticity of adult stem cells. *Cell* 2004; 116:639-48.
217. Korbiling M, Estrov Z. Adult stem cells for tissue repair - a new therapeutic concept? *N Engl J Med* 2003; 349:570-82.
218. Anderson DJ, Gage FH, Weissman IL. Can stem cells cross lineage boundaries? *Nat Med* 2001; 7:393-5.
219. McKay RD. Stem cell biology and neurodegenerative disease. *Philos Trans R Soc Lond B Biol Sci* 2004; 359:851-6.
220. Rafii S, Lyden D. Therapeutic stem and progenitor cell transplantation for organ vascularization and regeneration. *Nat Med* 2003; 9:702-12.
221. Reh TA, Fischer AJ. Stem cells in the vertebrate retina. *Brain Behav Evol* 2001; 58:296-305.
222. Tropepe V, Coles BL, Chiasson BJ, Horsford DJ, Elia AJ, McInnes RR, van der Kooy D. Retinal stem cells in the adult mammalian eye. *Science* 2000; 287:2032-6.
223. Ahmad I, Das AV, James J, Bhattacharya S, Zhao X. Neural stem cells in the mammalian eye: types and regulation. *Semin Cell Dev Biol* 2004; 15:53-62.
224. Klassen H, Sakaguchi DS, Young MJ. Stem cells and retinal repair. *Prog Retin Eye Res* 2004; 23:149-81.
225. LeCouter J, Moritz DR, Li B, Phillips GL, Liang XH, Gerber HP, Hillan KJ, Ferrara N. Angiogenesis-independent endothelial protection of liver: role of VEGFR-1. *Science* 2003; 299:890-3.
226. Asahara T, Murohara T, Sullivan A, Silver M, van der Zee R, Li T, Witzenbichler B, Schattman G, Isner JM. Isolation of putative progenitor endothelial cells for angiogenesis. *Science* 1997; 275:964-7.
227. Rosenzweig A. Endothelial progenitor cells. *N Engl J Med* 2003; 348:581-2.
228. Grant MB, May WS, Caballero S, Brown GA, Guthrie SM, Mames RN, Byrne BJ, Vaught T, Spoerri PE, Peck AB, Scott EW. Adult hematopoietic stem cells provide functional hemangioblast activity during retinal neovascularization. *Nat Med* 2002; 8:607-12.
229. Csaky KG, Baffi JZ, Byrnes GA, Wolfe JD, Hilmer SC, Flippin J, Cousins SW. Recruitment of marrow-derived endothelial cells to experimental choroidal neovascularization by local expression of vascular endothelial growth factor. *Exp Eye Res* 2004; 78:1107-16.
230. Dorrell MI, Otani A, Aguilar E, Moreno SK, Friedlander M. Adult bone marrow-derived stem cells use R-cadherin to target sites of neovascularization in the developing retina. *Blood* 2004; 103:3420-7.
231. Wakasugi K, Slike BM, Hood J, Otani A, Ewalt KL, Friedlander M, Cheresch DA, Schimmel P. A human aminoacyl-tRNA synthetase as a regulator of angiogenesis. *Proc Natl Acad Sci U S A* 2002; 99:173-7.
232. Otani A, Slike BM, Dorrell MI, Hood J, Kinder K, Ewalt KL, Cheresch D, Schimmel P, Friedlander M. A fragment of human TrpRS as a potent antagonist of ocular angiogenesis. *Proc Natl Acad Sci U S A* 2002; 99:178-83.
233. Pepper MS. Role of the matrix metalloproteinase and plasminogen activator-plasmin systems in angiogenesis. *Arterioscler Thromb Vasc Biol* 2001; 21:1104-17.
234. Das A, McGuire PG, Eriqat C, Ober RR, DeJuan E Jr, Williams

- GA, McLamore A, Biswas J, Johnson DW. Human diabetic neovascular membranes contain high levels of urokinase and metalloproteinase enzymes. *Invest Ophthalmol Vis Sci* 1999; 40:809-13.
235. Das A, McLamore A, Song W, McGuire PG. Retinal neovascularization is suppressed with a matrix metalloproteinase inhibitor. *Arch Ophthalmol* 1999; 117:498-503.
236. McGuire PG, Jones TR, Talarico N, Warren E, Das A. The urokinase/urokinase receptor system in retinal neovascularization: inhibition by A6 suggests a new therapeutic target. *Invest Ophthalmol Vis Sci* 2003; 44:2736-42.
237. Majka S, McGuire P, Colombo S, Das A. The balance between proteinases and inhibitors in a murine model of proliferative retinopathy. *Invest Ophthalmol Vis Sci* 2001; 42:210-5.
238. Das A, Fanslow W, Cerretti D, Warren E, Talarico N, McGuire P. Angiopoietin/Tek interactions regulate mmp-9 expression and retinal neovascularization. *Lab Invest* 2003; 83:1637-45.
239. Das A, McGuire PG, Xu L. Retinal neovascularization is suppressed with an inhibitor of proteinase enzymes. *Invest Ophthalmol Vis Sci* 1999; 40:S704.
240. Rossi JJ. Therapeutic applications of catalytic antisense RNAs (ribozymes). *Ciba Found Symp* 1997; 209:195-204.
241. Murakami A. Making sense of antisense. *Trends Mol Med* 2001; 7:430-1.
242. Erickson RP. Use of antisense to study gene expression. *Introduction. Methods* 1999; 18:241-3.
243. McManus MT, Sharp PA. Gene silencing in mammals by small interfering RNAs. *Nat Rev Genet* 2002; 3:737-47.
244. Denli AM, Hannon GJ. RNAi: an ever-growing puzzle. *Trends Biochem Sci* 2003; 28:196-201.
245. Hannon GJ. RNA interference. *Nature* 2002; 418:244-51.
246. Burke JM, Belfort M, Cech TR, Davies RW, Schweyen RJ, Shub DA, Szostak JW, Tabak HF. Structural conventions for group I introns. *Nucleic Acids Res* 1987; 15:7217-21.
247. Zaug AJ, Cech TR. In vitro splicing of the ribosomal RNA precursor in nuclei of *Tetrahymena*. *Cell* 1980; 19:331-8.
248. Cech TR, Zaug AJ, Grabowski PJ. In vitro splicing of the ribosomal RNA precursor of *Tetrahymena*: involvement of a guanosine nucleotide in the excision of the intervening sequence. *Cell* 1981; 27:487-96.
249. Cech TR, Brehm SL. Replication of the extrachromosomal ribosomal RNA genes of *Tetrahymena thermophila*. *Nucleic Acids Res* 1981; 9:3531-43.
250. Cech TR. Alkaline gel electrophoresis of deoxyribonucleic acid photoreacted with trimethylpsoralen: rapid and sensitive detection of interstrand cross-links. *Biochemistry* 1981; 20:1431-7.
251. Guo H, Zimmerly S, Perlman PS, Lambowitz AM. Group II intron endonucleases use both RNA and protein subunits for recognition of specific sequences in double-stranded DNA. *EMBO J* 1997; 16:6835-48.
252. Stark BC, Kole R, Bowman EJ, Altman S. Ribonuclease P: an enzyme with an essential RNA component. *Proc Natl Acad Sci U S A* 1978; 75:3717-21.
253. Altman S, Kirsebom L, Talbot S. Recent studies of ribonuclease P. *FASEB J* 1993; 7:7-14.
254. Ruffner DE, Dahm SC, Uhlenbeck OC. Studies on the hammerhead RNA self-cleaving domain. *Gene* 1989; 82:31-41.
255. Fedor MJ, Uhlenbeck OC. Kinetics of intermolecular cleavage by hammerhead ribozymes. *Biochemistry* 1992; 31:12042-54.
256. Chowrira BM, Burke JM. Binding and cleavage of nucleic acids by the "hairpin" ribozyme. *Biochemistry* 1991; 30:8518-22.
257. Dahm SC, Uhlenbeck OC. Role of divalent metal ions in the hammerhead RNA cleavage reaction. *Biochemistry* 1991; 30:9464-9.
258. Zoumadakis M, Tabler M. Comparative analysis of cleavage rates after systematic permutation of the NUX consensus target motif for hammerhead ribozymes. *Nucleic Acids Res* 1995; 23:1192-6.
259. Shimayama T, Nishikawa S, Taira K. Generality of the NUX rule: kinetic analysis of the results of systematic mutations in the trinucleotide at the cleavage site of hammerhead ribozymes. *Biochemistry* 1995; 34:3649-54.
260. Shaw LC, Skold A, Wong F, Petters R, Hauswirth WW, Lewin AS. An allele-specific hammerhead ribozyme gene therapy for a porcine model of autosomal dominant retinitis pigmentosa. *Mol Vis* 2001; 7:6-13.
261. Shaw LC, Afzal A, Lewin AS, Timmers AM, Spoerri PE, Grant MB. Decreased expression of the insulin-like growth factor 1 receptor by ribozyme cleavage. *Invest Ophthalmol Vis Sci* 2003; 44:4105-13.
262. Afzal A, Shaw LC, Caballero S, Spoerri PE, Lewin AS, Zeng D, Belardinelli L, Grant MB. Reduction in preretinal neovascularization by ribozymes that cleave the A2B adenosine receptor mRNA. *Circ Res* 2003; 93:500-6.
263. Fritz JJ, Lewin A, Hauswirth W, Agarwal A, Grant M, Shaw L. Development of hammerhead ribozymes to modulate endogenous gene expression for functional studies. *Methods* 2002; 28:276-85.
264. Zucker M, Mathews DH, Turner DH. Algorithms and thermodynamics for RNA secondary structure prediction: a practical guide. In: Barciszewski J, Clark BFC, editors. *NATO Advanced Research Workshop on RNA: Biochemistry, and Biotechnology*. Boston: Kluwer Academic; 1999. p. 11-43.
265. Mathews DH, Sabina J, Zuker M, Turner DH. Expanded sequence dependence of thermodynamic parameters improves prediction of RNA secondary structure. *J Mol Biol* 1999; 288:911-40.
266. Scherr M, LeBon J, Castanotto D, Cunliffe HE, Meltzer PS, Ganser A, Riggs AD, Rossi JJ. Detection of antisense and ribozyme accessible sites on native mRNAs: application to NCOA3 mRNA. *Mol Ther* 2001; 4:454-60.
267. Stage-Zimmermann TK, Uhlenbeck OC. Hammerhead ribozyme kinetics. *RNA* 1998; 4:875-89.
268. Shweiki D, Itin A, Soffer D, Keshet E. Vascular endothelial growth factor induced by hypoxia may mediate hypoxia-initiated angiogenesis. *Nature* 1992; 359:843-5.
269. Dawson DW, Volpert OV, Gillis P, Crawford SE, Xu H, Benedict W, Bouck NP. Pigment epithelium-derived factor: a potent inhibitor of angiogenesis. *Science* 1999; 285:245-8.
270. Tombran-Tink J, Barnstable CJ. PEDF: a multifaceted neurotrophic factor. *Nat Rev Neurosci* 2003; 4:628-36.
271. O'Reilly MS, Holmgren L, Shing Y, Chen C, Rosenthal RA, Moses M, Lane WS, Cao Y, Sage EH, Folkman J. Angiostatin: a novel angiogenesis inhibitor that mediates the suppression of metastases by a Lewis lung carcinoma. *Cell* 1994; 79:315-28.
272. O'Reilly MS, Boehm T, Shing Y, Fukai N, Vasios G, Lane WS, Flynn E, Birkhead JR, Olsen BR, Folkman J. Endostatin: an endogenous inhibitor of angiogenesis and tumor growth. *Cell* 1997; 88:277-85.
273. Stellmach V, Crawford SE, Zhou W, Bouck N. Prevention of ischemia-induced retinopathy by the natural ocular antiangiogenic agent pigment epithelium-derived factor. *Proc Natl Acad Sci U S A* 2001; 98:2593-7.
274. Meneses PI, Hajjar KA, Berns KI, Duvoisin RM. Recombinant angiostatin prevents retinal neovascularization in a murine proliferative retinopathy model. *Gene Ther* 2001; 8:646-8.



275. Mori K, Ando A, Gehlbach P, Nesbitt D, Takahashi K, Goldstein D, Penn M, Chen CT, Mori K, Melia M, Phipps S, Moffat D, Brazzell K, Liau G, Dixon KH, Campochiaro PA. Inhibition of choroidal neovascularization by intravenous injection of adenoviral vectors expressing secreted endostatin. *Am J Pathol* 2001; 159:313-20.
276. Mori K, Duh E, Gehlbach P, Ando A, Takahashi K, Pearlman J, Mori K, Yang HS, Zack DJ, Etyreddy D, Brough DE, Wei LL, Campochiaro PA. Pigment epithelium-derived factor inhibits retinal and choroidal neovascularization. *J Cell Physiol* 2001; 188:253-63.
277. Mori K, Gehlbach P, Yamamoto S, Duh E, Zack DJ, Li Q, Berns KI, Raisler BJ, Hauswirth WW, Campochiaro PA. AAV-mediated gene transfer of pigment epithelium-derived factor inhibits choroidal neovascularization. *Invest Ophthalmol Vis Sci* 2002; 43:1994-2000.
278. Mori K, Gehlbach P, Ando A, McVey D, Wei L, Campochiaro PA. Regression of ocular neovascularization in response to increased expression of pigment epithelium-derived factor. *Invest Ophthalmol Vis Sci* 2002; 43:2428-34.
279. Mori K, Gehlbach P, Ando A, Wahlin K, Gunther V, McVey D, Wei L, Campochiaro PA. Intraocular adenoviral vector-mediated gene transfer in proliferative retinopathies. *Invest Ophthalmol Vis Sci* 2002; 43:1610-5.
280. Raisler BJ, Berns KI, Grant MB, Beliaev D, Hauswirth WW. Adeno-associated virus type-2 expression of pigmented epithelium-derived factor or Kringle 1-3 of angiostatin reduce retinal neovascularization. *Proc Natl Acad Sci U S A* 2002; 99:8909-14.
281. Auricchio A, Behling KC, Maguire AM, O'Connor EM, Bennett J, Wilson JM, Tolentino MJ. Inhibition of retinal neovascularization by intraocular viral-mediated delivery of anti-angiogenic agents. *Mol Ther* 2002; 6:490-4.
282. Bainbridge JW, Mistry A, De Alwis M, Paleolog E, Baker A, Thrasher AJ, Ali RR. Inhibition of retinal neovascularisation by gene transfer of soluble VEGF receptor sFlt-1. *Gene Ther* 2002; 9:320-6.
283. Lai CC, Wu WC, Chen SL, Xiao X, Tsai TC, Huan SJ, Chen TL, Tsai RJ, Tsao YP. Suppression of choroidal neovascularization by adeno-associated virus vector expressing angiostatin. *Invest Ophthalmol Vis Sci* 2001; 42:2401-7.
284. Lai YK, Shen WY, Brankov M, Lai CM, Constable IJ, Rakoczy PE. Potential long-term inhibition of ocular neovascularisation by recombinant adeno-associated virus-mediated secretion gene therapy. *Gene Ther* 2002; 9:804-13.
285. Rasmussen H, Chu KW, Campochiaro P, Gehlbach PL, Haller JA, Handa JT, Nguyen QD, Sung JU. Clinical protocol. An open-label, phase I, single administration, dose-escalation study of ADGVPEDF.11D (ADPEDF) in neovascular age-related macular degeneration (AMD). *Hum Gene Ther* 2001; 12:2029-32.
286. Flannery JG, Zolotukhin S, Vaquero MI, LaVail MM, Muzyczka N, Hauswirth WW. Efficient photoreceptor-targeted gene expression in vivo by recombinant adeno-associated virus. *Proc Natl Acad Sci U S A* 1997; 94:6916-21.
287. Bennett J, Duan D, Engelhardt JF, Maguire AM. Real-time, noninvasive in vivo assessment of adeno-associated virus-mediated retinal transduction. *Invest Ophthalmol Vis Sci* 1997; 38:2857-63.
288. Muzyczka N. Use of AAV as a general transduction vector for mammalian cells. In: Muzyczka N, editor. *Viral expression vectors. Current topics in microbiology and immunology*. Vol 158. Berlin: Springer Verlag; 1992. p. 97-129.
289. Cole CH, Wright KW, Tarnow-Mordi W, Phelps DL, Pulse Oximetry Saturation Trial for Prevention of Retinopathy of Prematurity Planning Study Group. Resolving our uncertainty about oxygen therapy. *Pediatrics* 2003; 112:1415-9.
290. Fledelius HC, Gote H, Greisen G, Jensen H. Surveillance for retinopathy of prematurity in a Copenhagen high-risk sample 1999-2001. Has progress reached a plateau? *Acta Ophthalmol Scand* 2004; 82:32-7.
291. Kim TI, Sohn J, Pi SY, Yoon YH. Postnatal risk factors of retinopathy of prematurity. *Paediatr Perinat Epidemiol* 2004; 18:130-4.
292. Hameed B, Shyamanur K, Kotecha S, Manktelow BN, Woodruff G, Draper ES, Field D. Trends in the incidence of severe retinopathy of prematurity in a geographically defined population over a 10-year period. *Pediatrics* 2004; 113:1653-7.

The appendix is available in the online version of this article at <http://www.molvis.org/molvis/v12/a63/>.

The print version of this article was created on 23 May 2006. This reflects all typographical corrections and errata to the article through that date. Details of any changes may be found in the online version of the article.  $\alpha$