

Progressive ECG changes in arrhythmogenic right ventricular disease

Evidence for an evolving disease

S. Abou Jaoude, J. F. Leclercq and P. Coumel

From the Cardiology Department, Lariboisière Hospital, Paris, France

Electrocardiography results were used to assess diagnosis and evolution of arrhythmogenic right ventricular disease. The initial ECG presentation and long-term changes were analysed in 74 consecutive patients with symptomatic ventricular tachycardia and arrhythmogenic right ventricular disease.

On first available tracings, a left axis deviation of the QRS was found in 18 patients. The QRS length in V_1 was ≥ 110 ms in 39 patients, an epsilon wave was present in 17, and a complete right bundle branch block in four patients. The T wave was negative in V_1 – V_3 in 37 patients (50%).

In 36 patients, long-term electrocardiographic follow-up of 9.5 ± 3.2 years was available. During this period, ECG changes were observed in 20 patients (56%): negative T waves in 11 patients, a new left axis deviation in three, QRS enlargement in 13 (including eight right bundle branch block), right atrial hypertrophy in three, and paroxysmal or established atrial fibrillation in three.

On studying all 110 ECG tracings (74 initial recordings + 36 follow-up ECGs), we found a strong correlation between

QRS or T wave changes and the length of follow-up after the first symptom; mean time interval between first ventricular tachycardia and ECG recording was significantly longer in patients with negative T waves in the right precordial leads, QRS enlargement, or left axis deviation, than in patients without such abnormalities. ECG abnormalities were more frequent at 10 year and 5 year follow-up than on initial tracings. A normal ECG was found in 40% of patients during the first year of follow-up, 8% at 5 years, and never later than the 6th year.

In conclusion, electrocardiographic diagnosis of arrhythmogenic right ventricular disease may be difficult in the initial stage of the disease, since a normal ECG is found in up to 40% of patients. During the follow-up, progressive and characteristic ECG changes will occur. Arrhythmogenic right ventricular disease can be excluded if the ECG is found to be normal 6 years or later after a first ventricular tachycardia attack.

(*Eur Heart J* 1996; 17: 1717–1722)

Key Words: Right ventricular dysplasia, ECG, evolution.

Introduction

Diagnosis of arrhythmogenic right ventricular disease is usually based on clinical, electrocardiographic, and morphological arguments. Recently, major and minor criteria for a positive diagnosis have been proposed^[1].

ECG recording can contribute significantly to a positive diagnosis by showing characteristics of the ventricular arrhythmia. Features of ventricular tachycardia in arrhythmogenic right ventricular disease have

been extensively studied, and are now well known^[2,3]. During sinus rhythm, many electrocardiographic abnormalities may be present and some investigators have shown that ECG findings can be highly sensitive and specific^[4,5]. Conversely, less notice has been taken of ECG changes during the progression of arrhythmogenic right ventricular disease; the diagnostic value of the ECG at different stages of the disease, particularly after the first symptoms, is unclear.

To assess the diagnostic value of electrocardiography at different stages of this disease as well as the development of new ECG findings, we analysed the initial electrocardiographic presentation and long-term ECG changes in a population with arrhythmogenic right ventricular disease.

Manuscript submitted 9 January 1996, and accepted 14 February 1996.

Correspondence. Service de cardiologie, Hôpital Lariboisière, 2, rue Ambroise Paré, 75475 Paris Cedex 10, France.

Patients and methods

Patients

The study population includes 74 consecutive patients with arrhythmogenic right ventricular disease (63 men and 11 women). Spontaneous ventricular tachycardia was documented in all patients: sustained ventricular tachycardia was present in 59 and non-sustained ventricular tachycardia in 15. The date of the first ventricular tachycardia was noted in each patient and considered as initial time to follow-up. Mean age at the first ventricular tachycardia attack was 37.2 ± 13.5 (range 11 to 68 years). Right ventricular angiography was performed in all cases, and a diagnosis of arrhythmogenic right ventricular disease was made when criteria proposed by Daubert *et al.*^[6] were met. Thus, localized akinesia was found in 61 patients and a more diffuse disease in the other 13.

Electrocardiographic recording

The initial 12-lead ECG was studied in all patients. QRS duration and axis were calculated; presence of an epsilon wave, incomplete or complete right bundle branch block, or right atrial hypertrophy were sought. Repolarization abnormalities were analysed. A significant ECG follow-up was available in 36 patients; first and last recordings were compared in each patient; changes in rhythm, P wave, QRS axis and duration, or T wave polarity were noted; time interval from the first ventricular tachycardia attack was calculated for each ECG recording. Finally, all the 110 tracings (74 initial recordings+36 follow-up ECGs) were analysed, looking for a possible relationship between various ECG findings and length of follow-up after the first ventricular tachycardia.

Results

Patients

Demographic and clinical data of the study group are shown in Table 1. Male predominance, high prevalence of familial forms, and low incidence of heart failure are the main characteristics of this population.

Ventricular tachycardia

Table 2 displays the characteristics of the first ventricular tachycardia. A left bundle branch block pattern and the occurrence of ventricular tachycardia in adrenergic-related situations are the most frequent.

Initial ECG

The first available ECG tracing was recorded 1.8 years (± 3.2) after the first ventricular tachycardia attack. All

Table 1 Clinical characteristics of the study population

n	74
Sex	
M (n)	63 (85%)
F (n)	11 (15%)
Age at first VT (years)	37.2 ± 13.5 range 11–68
Family history (n)	16 (22%)
Overt ARVD (n)	6
Sudden death (n)	5
Sudden death and overt ARVD (n)	5
Right heart failure at last follow-up (n)	10 (14%)

VT=ventricular tachycardia; ARVD=arrhythmogenic right ventricular disease.

Table 2 Characteristics of the first VT

VT (n)	74 (100%)
Sustained (n)	59 (80%)
Non-sustained (n)	15 (20%)
Configuration	
LBBB pattern (n)	70 (95%)
RBBB pattern (n)	4 (5%)
Frontal axis	
0–90° (n)	7 (10%)
$\leq 0^\circ$ (n)	33 (45%)
$\geq 90^\circ$ (n)	21 (28%)
Undetermined (n)	13
Effort related arrhythmia (n)	51 (69%)

VT=ventricular tachycardia; LBBB/RBBB=left and right bundle branch block.

patients were in sinus rhythm; mean frontal plane QRS axis was of $30^\circ \pm 35$. Right axis deviation ($\geq 90^\circ$) was found in seven patients (10%) while left axis deviation ($\leq 0^\circ$) was noted in 18 others (24%). A normal QRS axis was observed in 47 patients (64%). In the two remaining patients, QRS axis was perpendicular to the frontal plane. Complete right bundle branch block was present in four patients (5%) and incomplete right bundle branch block was noted in 11 others. No left bundle branch block was observed. Prolongation of the QRS duration ≥ 110 ms in lead V_1 was present in 39 patients (53%) and an epsilon wave was found in 17 (23%). The T wave was positive in all precordial leads in 18 patients and was found negative only in V_1 in 19. Inverted T waves in leads V_1 – V_3 ($\pm V_4$ – V_6) were present in 37 patients (50%). In three patients, T waves were also negative in D_2 , D_3 and VF. Right atrial hypertrophy was observed in only one patient. A normal ECG recording was found in 22 patients (30%) on the first available tracing.

ECG changes

Long-term electrocardiographic follow-up of 9.5 years (± 3.2) was available in 36 of the 74 patients. During

this period, no ECG changes could be observed in 16 patients (44%). In the 20 others (56%), the following modifications were noted: new complete right bundle branch block in eight patients (right bundle branch block appeared immediately after ventricular tachycardia fulguration in two patients); new left axis deviation in three patients; prolongation of QRS duration ≥ 110 ms in 13 patients (including the eight with right bundle branch block); increasing epsilon wave amplitude in one patient. In two others, the epsilon wave appeared immediately after ventricular tachycardia fulguration; negative T wave in right precordial leads in 11 patients; development of right atrial hypertrophy in three patients; appearance of atrial fibrillation in three patients (established in two, paroxysmal in the third).

Correlation between ECG findings and length of follow-up after the first ventricular tachycardia

On studying all the 110 recordings, we found that in patients with prolonged QRS duration (≥ 110 ms), the mean time interval between the first ventricular tachycardia and the ECG recording was 7.1 ± 5.9 years, significantly longer than in patients with QRS duration < 110 ms: 2.9 ± 3.2 years ($P < 0.01$). Length of ECG follow-up after the first ventricular tachycardia was 8.7 ± 8.8 years in patients with left axis deviation, and 4.2 ± 5.3 years in patients without left axis deviation ($P < 0.01$). Similar results were found concerning repolarization abnormalities; indeed, in patients with T wave inversion in V_1 , V_2 and V_3 , the mean time interval between the first ventricular tachycardia and the ECG recording was significantly longer than in patients without negative T waves: 8.3 ± 7.5 years vs 2.2 ± 2.5 ($P < 0.001$).

Prevalence of various ECG findings during follow-up

ECG abnormalities were found more frequently at 5- and 10-year follow-up than on initial recordings. On studying tracings recorded in the year following the first ventricular tachycardia, no abnormality could be observed in 40% of patients. Inverted T waves in the right precordial leads were found in 37% of patients, prolongation of the QRS duration ≥ 110 ms in 35% and left axis deviation in 14%, while at 10 years after the first ventricular tachycardia, those abnormalities were present in 98%, 65% and 37%, respectively. Table 3 shows prevalence of various ECG findings at 1, 5 and 10 year follow-up. None of the 31 ECGs obtained later than the 6th year after the first ventricular tachycardia was normal.

Discussion

Since the first description of arrhythmogenic right ventricular disease by Fontaine *et al.*^[7,8], many ECG

Table 3 Prevalence of various ECG findings during follow-up

	Time interval from the first VT		
	<1 year	5 years	10 years
Negative T wave V_1 - V_3	37%	78%	98%
QRS ≥ 110 ms	35%	59%	65%
Left axis deviation	14%	30%	37%
Epsilon wave	19%	27%	34%
Complete RBBB	4.6%	13%	20%
Normal ECG	40%	8%	0%*

*All ECGs recorded later than the 6th year were abnormal.

abnormalities have been reported in this disease. Although patients are usually in stable sinus rhythm, the incidence of spontaneous or inducible atrial tachyarrhythmias is increased^[9,10]. In the present population, atrial fibrillation was found in only three patients at follow-up. Atrial arrhythmia may be favoured by atrial enlargement, right atrial involvement, or both^[10,11]. However, electrocardiographic right atrial hypertrophy remains a rare finding: one patient out of 20, and two out of 22 in the series of Metzger *et al.*^[12] and Canu *et al.*^[13] respectively, and four out of 74 in our study group.

QRS wave abnormalities are more frequent findings. Changes such as axis deviation, localized QRS prolongation, complete and incomplete right bundle branch block, or epsilon wave can be observed. Localized QRS prolongation in right precordial leads seems to be an interesting finding. Indeed, Fontaine *et al.*^[14,15] showed that in patients with arrhythmogenic right ventricular disease, the QRS wave in lead V_1 is significantly larger than in lead D_1 ; thus, 55% sensitivity and 100% specificity were observed for a QRS duration > 110 ms in lead V_1 . This finding was restudied recently by Stefan *et al.*^[5] who noted 93% sensitivity and 100% specificity for a QRS duration ratio in $V_2/V_4 > 1.1$ or a ratio of the sum of right (V_1 - V_3) and left (V_4 - V_6) QRS duration > 1.1 . This conduction delay often reflects the presence of a parietal block in the right ventricle^[16], which is better explored by the right precordial leads, and by the signal averaged ECG.

The main ECG finding in patients with arrhythmogenic right ventricular disease is repolarization abnormalities^[3,17]. T wave inversion is usually seen in V_1 - V_3 , sometimes in V_1 through V_6 , or less frequently in D_2 , D_3 and VF . Although mechanisms of these changes are not completely understood, many explanations have been proposed: a possibility of T wave changes secondary to parietal right ventricular conduction defects has been suggested by Fontaine *et al.*^[18] as well as repolarization abnormalities secondary to prolonged episodes of ventricular tachycardia. Nava *et al.* studied T wave changes in 24 cases of arrhythmogenic right ventricular disease and showed that extension of T wave negativity on precordial leads has a direct relationship with

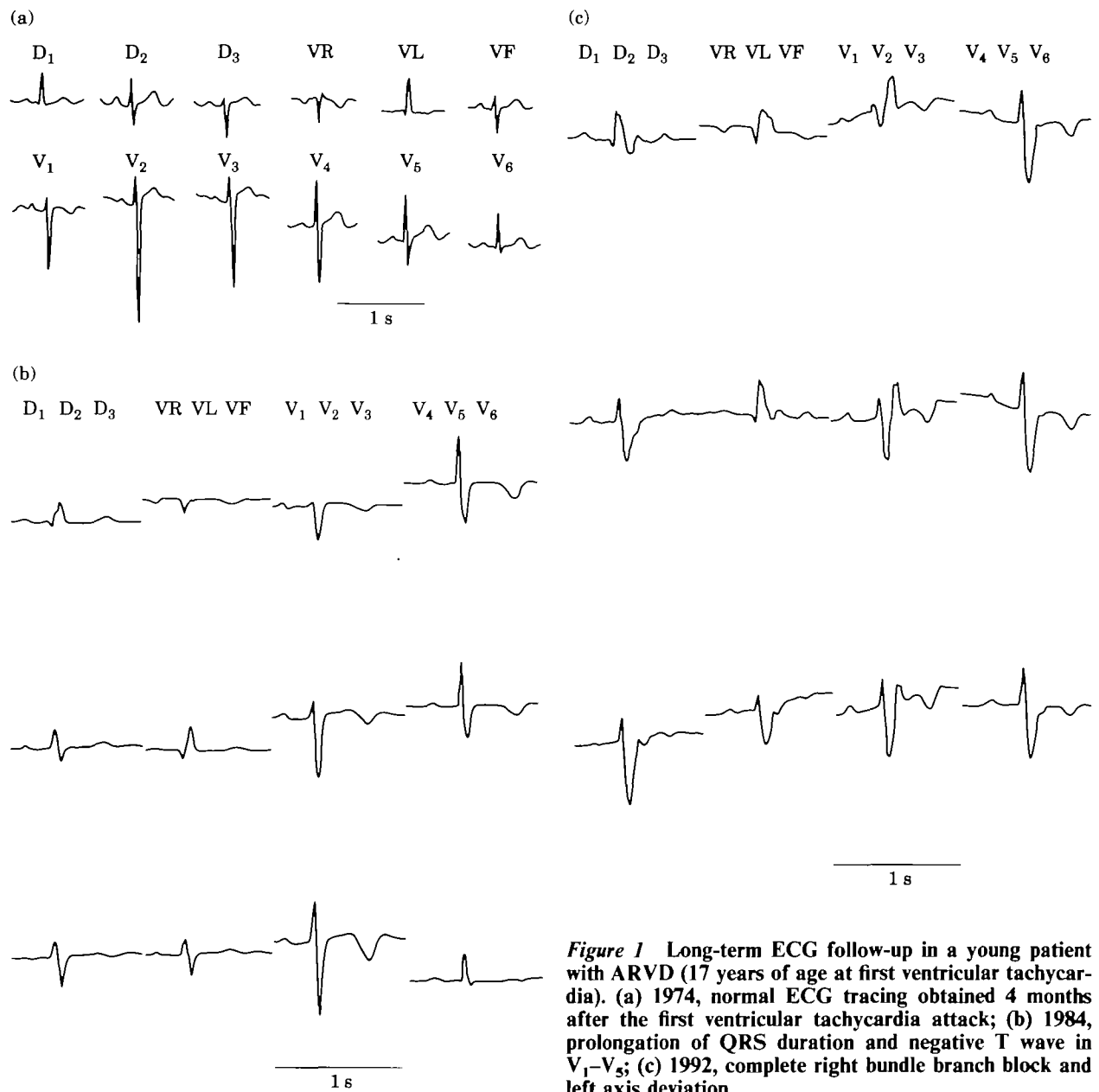


Figure 1 Long-term ECG follow-up in a young patient with ARVD (17 years of age at first ventricular tachycardia). (a) 1974, normal ECG tracing obtained 4 months after the first ventricular tachycardia attack; (b) 1984, prolongation of QRS duration and negative T wave in V₁-V₅; (c) 1992, complete right bundle branch block and left axis deviation.

right ventricular enlargement. They concluded that repolarization changes are probably caused by dislocation of the left ventricular backwards secondary to right ventricular dilatation^[19].

While T wave changes are considered by most investigators to be the most frequent ECG abnormality in arrhythmogenic right ventricular disease, their incidence is very differently estimated in the literature: they were observed in 55%, 66%, 75%, 86% and 100% in the series of Pinamonti *et al.*^[20], Fontaine *et al.*^[18], Metzger *et al.*^[12], Marcus *et al.*^[13] and Canu *et al.*^[13], respectively. In our patients, they were found in only 50% of cases on the first available ECG. One possible explanation for this incidence variability between series could be the fact that ECG recordings were performed at variable time

intervals after the onset of the first symptom. Indeed, in the present study, we found that patients with T wave inversions in right precordial leads, had significantly longer time intervals between the first ventricular tachycardia and the ECG recording, than patients who did not show such abnormalities. A negative T wave in V₁, V₂ and V₃ was observed more frequently when ECG tracings were performed many years after the first ventricular tachycardia, than on initial recordings: prevalence was of 50% at first available recording and 98% 10 years after the first ventricular tachycardia.

This is also true concerning other ECG abnormalities found in our patients: the time interval between the onset of the ventricular tachycardia and the ECG recording was significantly longer in patients with

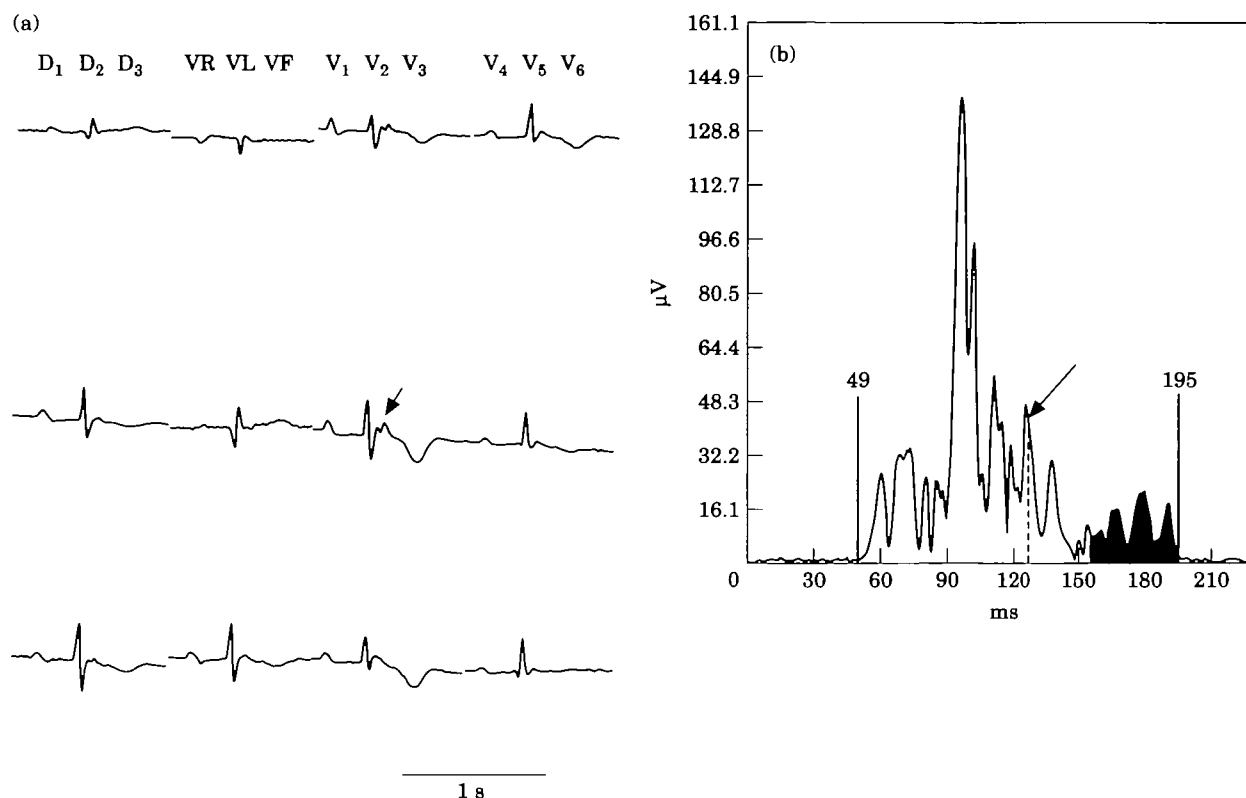


Figure 2 (a) 12-lead ECG obtained 9 years after the first ventricular tachycardia attack in a 52-year-old woman; sinus rhythm, negative T wave in precordial leads and epsilon wave in V_1 , V_2 . (b) Same patient. Signal averaged ECG shows the presence of late potentials. Filtered QRS duration=146 ms, length of low amplitude signal below $40 \mu\text{V}$ (LAS 40)=68.5 ms, root mean square of the last 40 ms (RMS 40)=11.7 μV . (Bidirectional filters between 40 and 300 Hz).

prolonged QRS duration (≥ 110 ms) or left axis deviation, than in patients with a narrow QRS or no left axis deviation respectively. A normal ECG tracing was observed in 40% of patients at 1 year after the first ventricular tachycardia, 8% at 5 years, and never later than the 6th year.

ECG modifications over time were also observed by other investigators. Blomstrom-Lundquist *et al.*^[21] obtained 8.8 years of electrocardiographic follow-up in 15 patients with arrhythmogenic right ventricular disease. ECG changes such as new T wave inversion, new right bundle branch block, or QRS prolongation, occurred in 11 patients. Conversely, Metzger *et al.*^[12] found no significant ECG changes on follow-up in 14 patients, but no analysis of a possible relationship between electrocardiographic abnormalities and the onset of the arrhythmia has been performed.

Our data confirm that in arrhythmogenic right ventricular disease ECG findings evolve; over time, inversion of T waves in precordial leads, prolongation of QRS duration and left axis deviation will progressively appear; the ECG pattern becomes more characteristic of the disease, to allow an easier diagnosis. Thus, the diagnostic value of the ECG in arrhythmogenic right ventricular disease depends on the disease stage: normal tracings on the initial recording do not rule out the

diagnosis, since it can be found in up to 40% of patients. However, arrhythmogenic right ventricular disease becomes very unlikely when the ECG is still normal 6 years or later after the first ventricular tachycardia. The ECG is also useful in managing patients with apparently idiopathic ventricular arrhythmias originating from the right ventricle. In those patients, serial ECG recordings must be obtained, and normal tracing at long-term follow-up is needed to exclude arrhythmogenic right ventricular disease.

The hypothesis that the evolving ECG in arrhythmogenic right ventricular disease reflects a change in the pathological process is reinforced by many other studies, which showed the presence of evolutionary clinical, radiological, echocardiographic and angiographic findings in this disease. Indeed, Marcus *et al.*^[22] and Blomstrom-Lundquist *et al.*^[21], have observed congestive heart failure in about 20% of cases during the follow-up period. In addition, heart size increase on chest X-ray was observed in 40% of patients over 8.8 years. Nava *et al.*^[23] reported two members of a family with arrhythmogenic right ventricular disease who did not present any abnormalities when examined at 11 years of age, but had overt disease 4 years later. Moreover, appearance of parietal akinesia or dyskinesia, worsening of right ventricular function, and progressive

right ventricular dilatation, evaluated by echocardiography or angiography, have been observed by many investigators^[20,12,24].

It seems obvious from our observations as well as from those in the literature, that arrhythmogenic right ventricular disease is an evolving disease. Electrocardiographic signs are important for its diagnosis and their absence in the initial stage of the disease made diagnosis sometimes difficult or impossible. However, at 6 years, the vast majority of patients have an abnormal ECG. A long-term electrocardiographic follow-up is therefore needed to exclude arrhythmogenic right ventricular disease in patients with apparently idiopathic ventricular arrhythmias originating from the right ventricle.

References

- [1] McKenna WJ, Thiene G, Nava A *et al.* Diagnosis of arrhythmogenic right ventricular dysplasia/cardiomyopathy. *Br Heart J* 1994; 71: 215–8.
- [2] Leclercq JF, Gatta F, Maisonblanche P *et al.* Caracteristiques et pronostic des troubles du rythmes ventriculaires de la dysplasie arythmogene du ventricule droit. *Arch Mal Coeur* 1988; 81: 1335–41.
- [3] Marcus FI, Fontaine G, Guiraudon G *et al.* Right ventricular dysplasia: a report of 24 cases. *Circulation* 1982; 65: 384–99.
- [4] Fontaine G. Arrhythmogenic right ventricular dysplasia. *Curr Opin Cardiol* 1995; 10: 16–20.
- [5] Stefan P, Gert-Hinrich R. Right and left precordial QRS duration in arrhythmogenic right ventricular dysplasia (Abstr). *J Am Coll Cardiol* 1995; 25: 111A.
- [6] Daubert C, Descaves C, Fulgor J, Bourdonner C, Laurent M, Gouffalt J. Critical analysis of cineangiographic criteria for diagnosis of arrhythmogenic right ventricular dysplasia. *Am Heart J* 1988; 115: 448–59.
- [7] Fontaine G, Guiraudon G, Frank R *et al.* Stimulation studies and epicardial mapping in ventricular tachycardia: study of mechanisms and selection for surgery. In: Kulbertus HE, ed. *Reentrant arrhythmias*. Lancaster. MTP Publishing; 1977: 344–50.
- [8] Frank R, Fontaine GH, Vedel J *et al.* Electrocardiologie de quatre cas de dysplasie ventriculaire droite arythmogene. *Arch Mal Coeur* 1978; 71: 963–72.
- [9] Brembilla-Perrot B, Terrier de La Chaise A, Beurrier D, Louis P, Suty-Selton C, Thiel B. Incidence du declenchement des tachyarythmies supraventriculaires dans la dysplasie du ventricule droit. *Arch Mal Coeur* 1993; 86: 203–7.
- [10] Tonet J, Castro-Miranda R, Iwa T, Poulain F, Frank R, Fontaine G. Frequency of supra ventricular tachyarrhythmias in arrhythmogenic right ventricular dysplasia. *Am J Cardiol* 1991; 67: 1153.
- [11] Proclemer A, Cuzzato AL, Morocutti G, Rocco M, Feruglio GA. Aritmie atriali parossistiche in cardiomiopatia aritmogena del ventricolo destro a carattere familiare: ruolo dell'interessamento dell'atrio destro. *G Ital Cardiol* 1992; 22: 1315–26.
- [12] Metzger J, de Chillou C, Cheriex E, Rogriguez LM, Smeets J, Wellens H. Value of the 12-lead electrocardiogram in arrhythmogenic right ventricular dysplasia, and absence of correlation with echocardiographic findings. *Am J Cardiol* 1993; 72: 964–7.
- [13] Canu G, Atallah G, Claudel JP *et al.* Pronostic et evolution a long terme de la dysplasie arythmogene du ventricule droit. *Arch Mal Coeur* 1993; 86: 41–8.
- [14] Fontaine G, Tsezana R, Lazarus A, Lascault G, Tonet J, Frank R. Electrocardiographic features of arrhythmogenic right ventricular dysplasia (Abstr). *Circulation* 1993; 88 (pt 2): 643.
- [15] Fontaine G, Umemura J, Di Donna P, Tsezana R, Cannat JJ, Frank R. La duree des complexes QRS dans la dysplasie ventriculaire droite arythmogene. Un nouveau marqueur diagnostique non invasif. *Ann Cardiol Angeiol* 1993; 42: 399–405.
- [16] Fontaine G, Frank R, Guiraudon G *et al.* Signification des troubles de conduction intraventriculaires dans la dysplasie ventriculaire droite arythmogene. *Arch Mal Coeur* 1988; 81: 1335–41.
- [17] Rossi PA. Arrhythmogenic right ventricular dysplasia — clinical features. *Eur Heart J* 1989; 10 (Suppl D): 7–9.
- [18] Fontaine G, Tsezana R, Lazarus A, Lascault G, Tonet J, Frank R. Troubles de la repolarisation et de la conduction intraventriculaire dans la dysplasie ventriculaire droite arythmogene. *Ann Cardiol Angeiol* 1994; 43: 5–10.
- [19] Nava A, Canciani B, Buja G *et al.* Electrocardiographic study of negative T wave on precordial leads in arrhythmogenic right ventricular dysplasia: relationship with right ventricular volumes. *J Electrocardiol* 1988; 21: 239–45.
- [20] Pinamonti B, Sinagra G, Salvi A *et al.* Left ventricular involvement in right ventricular dysplasia. *Am Heart J* 1992; 123: 711–24.
- [21] Blomstrom-Lundquist C, Sabel KG, Olsson SB. A long-term follow-up of 15 patients with arrhythmogenic right ventricular dysplasia. *Br Heart J* 1987; 58: 477–88.
- [22] Marcus FI, Fontaine GH, Frank R, Gallagher JJ, Reiter MJ. Long-term follow-up in patients with arrhythmogenic right ventricular dysplasia. *Eur Heart J* 1989; 10 (Suppl D): 68–73.
- [23] Nava A, Thiene G, Canciani B *et al.* Familial occurrence of right ventricular dysplasia: a study involving nine families. *J Am Coll Cardiol* 1988; 12: 1222–8.
- [24] Pinamonti B, Di Lenarda A, Sinagra G, Silvestri F, Bussani R, Camerini F, and the Heart Muscle Disease Study Group Trieste, Italy. Long-term evolution of right ventricular dysplasia-cardiomyopathy. *Am Heart J* 1995; 129: 412–5