

Progressive supranuclear palsy: clinicopathological concepts and diagnostic challenges

David R Williams, Andrew J Lees

Lancet Neurol 2009; 8: 270–79

Faculty of Medicine (Neurosciences), Monash University, Melbourne, Australia (D R Williams FRACP); Reta Lila Weston Institute of Neurological Studies, University College London, London, UK (A J Lees FRCP, D R Williams); and Queen Square Brain Bank for Neurological Disorders, University College London, London, UK (A J Lees)

Correspondence to:

David R Williams, Faculty of Medicine (Neurosciences), Monash University, Alfred Hospital Campus, Commercial Road, Melbourne 3004, Australia
david.williams@med.monash.edu

Progressive supranuclear palsy (PSP) is a clinical syndrome comprising supranuclear palsy, postural instability, and mild dementia. Neuropathologically, PSP is defined by the accumulation of neurofibrillary tangles. Since the first description of PSP in 1963, several distinct clinical syndromes have been described that are associated with PSP; this discovery challenges the traditional clinicopathological definition and complicates diagnosis in the absence of a reliable, disease-specific biomarker. We review the emerging nosology in this field and contrast the clinical and pathological characteristics of the different disease subgroups. These new insights emphasise that the pathological events and processes that lead to the accumulation of phosphorylated tau protein in the brain are best considered as dynamic processes that can develop at different rates, leading to different clinical phenomena. Moreover, for patients for whom the diagnosis is unclear, clinicians must continue to describe accurately the clinical picture of each individual, rather than label them with inaccurate diagnostic categories, such as atypical parkinsonism or PSP mimics. In this way, the development of the clinical features can be informative in assigning less common nosological categories that give clues to the underlying pathology and an understanding of the expected clinical course.

Introduction

In 1963, J Clifford Richardson described an “unusual syndrome” of postural instability, supranuclear gaze palsy, mild dementia, and progressive axial rigidity and bulbar palsy.¹ His collaborators, Jerzy Olszewski and John Steele, identified consistent pathological findings that were eventually used to establish this unusual syndrome as a new nosological condition: progressive supranuclear palsy (PSP).¹ Pathologically, PSP is defined by the accumulation of tau protein and neuropil threads, mainly in the pallidum, subthalamic nucleus, red nucleus, substantia nigra, pontine tegmentum, striatum, oculomotor nucleus, medulla, and dentate nucleus.^{2,3} Similar histopathological findings, however, can be seen in patients with postencephalitic parkinsonism (PEP) and the atypical

parkinsonian syndromes of Guam and Guadeloupe,^{4,7} thus complicating the pathological diagnosis of PSP. The most specific features of PSP pathology are star-shaped astrocytic tufts and neurofibrillary tangles that can be seen with light microscopy and that immunostain strongly with antibodies to tau. These features support the role of tau dysfunction in the pathogenesis of the disorder and the classification of PSP by neuropathologists as a primary tauopathy.^{8,9} Despite advances in our understanding of the disease process, there are no reliable diagnostic biomarkers for PSP, and accurate diagnosis depends on clinical acumen.

Although the classic PSP syndrome presents with clear clinical signs in its later stages, several clinical variants have recently been identified that are less distinctive, and many patients with PSP are initially thought to have Parkinson's disease (PD) or multiple system atrophy.¹⁰ We refer to the classic clinical picture of PSP as Richardson's syndrome (also known as Steele–Richardson–Olszewski syndrome) to distinguish it from the other clinical variants that fall under pathologically defined PSP.¹¹ These clinicopathological variants can be separated by differences in their severity, regions of pathology, and clinical features, and are linked by the accumulation of neurofibrillary tangles and similar natural histories that lead to death, usually within 6–12 years of diagnosis (figure 1). No accepted guidelines for the clinical diagnosis of these variants have been compiled, and the variants are often labelled as “atypical PSP”. We have termed the commonest of these variants PSP-parkinsonism (PSP-P) and have shown that the associated tau pathology is less severe and presents in a more restricted distribution than the tau pathology seen in patients with Richardson's syndrome (classic PSP).¹⁰ Some patients present with early gait disturbance, micrographia, and hypophonia, with eventual gait freezing. This variant has been labelled PSP-pure akinesia with gait freezing (PAGF).¹² Patients with PAGF have severe atrophy and neuronal loss only in the globus pallidus, substantia nigra, and subthalamic nucleus.^{12,13}

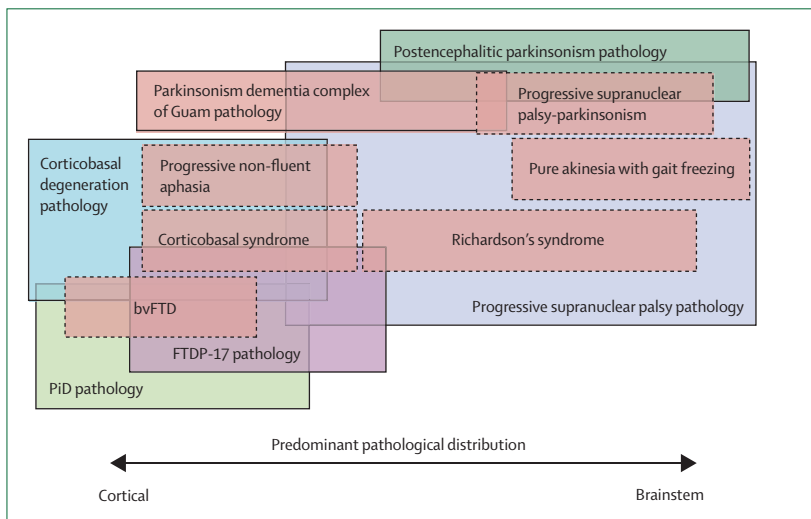


Figure 1: Distribution of tau pathology in clinical and pathological nosological syndromes of progressive supranuclear palsy

Dashed boxes—clinical syndromes. Solid boxes—pathologically defined diseases. PiD=Pick's disease.

FTDP-17=frontotemporal dementia with parkinsonism-17. bvFTD=behavioural variant of frontotemporal dementia.^{3,6,45,60,65}

Other groups of patients present with progressive, asymmetric dystonia, apraxia, and cortical sensory loss (PSP-corticobasal syndrome [PSP-CBS]) or apraxia of speech (PSP-progressive non-fluent aphasia [PSP-PNFA]) and have more severe cortical tau pathology than the patients with PSP-P.^{14,15}

Here, we review recent advances in the understanding of the pathological heterogeneity of PSP subtypes and highlight the similarities and differences between PSP and other tauopathies. Our aim is to integrate these findings into the emerging picture of the range of clinical subtypes of PSP and to discuss the implications for the diagnosis of this complex and devastating disorder.

Pathology

Pathological heterogeneity

The operational diagnostic criteria for the pathological diagnosis of PSP are derived from the first detailed studies made by Olszewski and Steele in 1964.¹ Although they found “no pathological evidence of frontal, cortical, or white matter involvement of consequence”, more recent reports that have used up-to-date staining techniques have shown cortical tau pathology to be a common finding in PSP.¹⁹ The pathological heterogeneity of PSP has recently been examined in detail in two post-mortem series, in which the extent of tau pathology was used as a surrogate marker for pathological severity in patients with Richardson’s syndrome and PSP-P.^{16,17} The patients with PSP-P had less severe tau pathology than those with

Richardson’s syndrome, although the pattern of distribution between both groups was similar: the subthalamic nucleus and substantia nigra were the regions that were most severely affected (figure 2).^{16–18} The regions where the differences in severity were greatest were the cerebral cortex, pons, caudate, cerebellar dentate nucleus, and cerebellar white matter. Although the substantia nigra pars compacta and ventrosegmental areas are affected in Richardson’s syndrome and PD, the severity of the pathology is substantially higher in the former.¹⁹ The dopamine cell groups in the substantia nigra pars compacta and ventrosegmental areas innervate the motor and limbic cortical and thalamic regions, influencing motor function and executive and other cognitive and behavioural features. The destruction of these cell groups is likely to contribute to levodopa non-responsiveness and frontostriatal cognitive dysfunction in patients with PSP.²⁰ Although the substantia nigra is severely affected in PSP-P, the clinical features that distinguish PSP-P from Richardson’s syndrome, including tremor and moderate levodopa responsiveness, might be due to less severe depletion of dopamine in the extranigral midbrain in PSP-P.¹⁰

The distribution and severity of pathological changes in patients with PAGF have been investigated in several small clinicopathological series. In one detailed study, patients with pathologically diagnosed PSP who also had severe atrophy, neuronal loss, and gliosis in the globus pallidus, substantia nigra, and subthalamic nucleus were

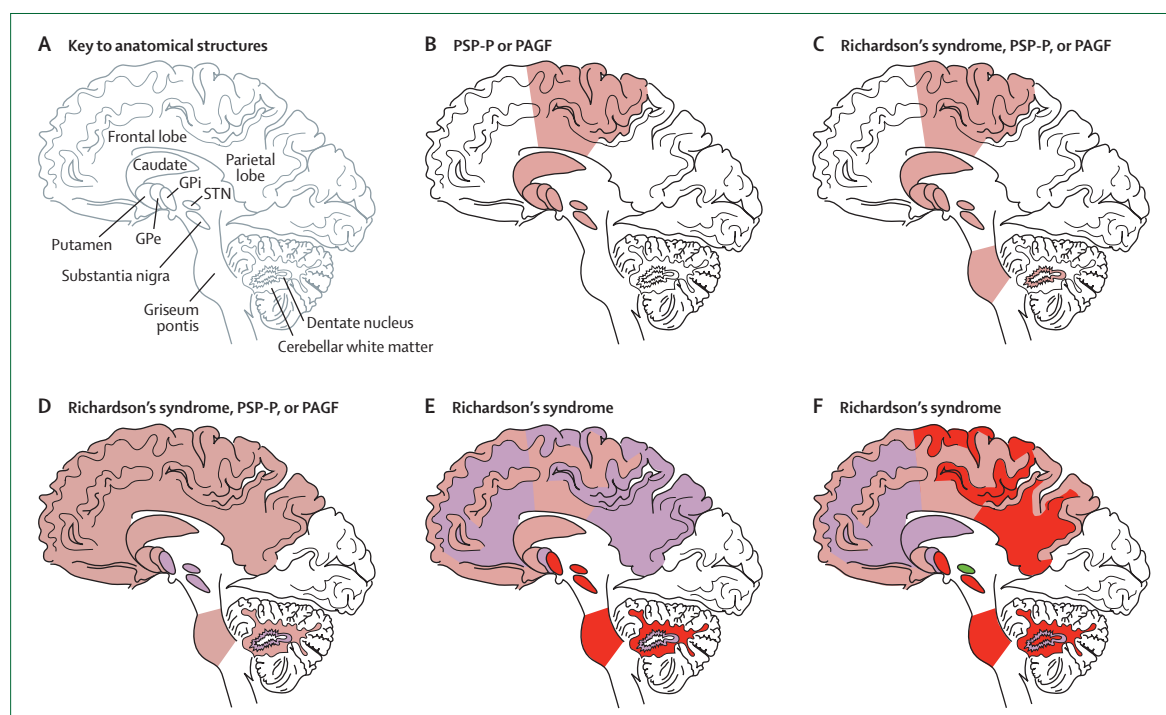


Figure 2: Severity of PSP tau pathology varies according to distribution

Brown=mild severity. Purple=moderate severity. Red=severe. Green=very severe. PSP=progressive supranuclear palsy. PSP-P=PSP-parkinsonism. PAGF=pure akinesia with gait freezing. STN=subthalamic nucleus. GPi=globus pallidus interna. GPe=globus pallidus externa. Reproduced with permission from Oxford University Press.¹⁸

selected from a large autopsy series.¹³ The pathology in these individuals was described as pallido-nigro-luysial and their clinical features were consistent with PAGF. Typical diagnostic PSP-type lesions (ie, astrocytic tufts and neurofibrillary tangles) were present, but compared with patients with Richardson's syndrome these patients had less severe tau pathology in the motor cortex, striatum, pontine nuclei, and cerebellum.¹³ The severity of tau pathology was lower in patients with PAGF than it was in patients with Richardson's syndrome, with less severe tau deposition in the cerebellum, dentate nucleus, and pontine nuclei.¹² Functional imaging studies support these pathological observations, with a similar but attenuated pattern of brain glucose metabolism in patients with PAGF compared with patients with Richardson's syndrome.²¹ The areas of decreased glucose metabolism were seen only in the midbrain of patients with PAGF, with preservation of frontal metabolism. The restricted distribution of pathology in PAGF is thought to be the cause of the clinical differences and probably contributes to its better prognosis.^{12,13} The functional consequences of these pathological differences have been shown with tests of brainstem reflexes.²²

In a small series, patients who presented with PSP-CBS had a higher density of tau pathology in the midfrontal and inferior parietal cortices, but not in the motor cortex, compared with patients with Richardson's syndrome.¹⁴ The distribution of tau pathology in patients with PSP-CBS was similar to that seen in corticobasal degeneration, suggesting that the topography, not the type, of tau pathology affects the clinical picture.¹⁴ Patients with PSP-tau pathology who presented with PSP-PNFA had more severe pathology in the temporal cortex and superior frontal gyrus than patients with Richardson's syndrome, but they had less severe pathology in the brainstem and subcortical grey matter regions.¹⁵

Other neurofibrillary tangle primary tauopathies

The pathological diagnosis of PSP is based on the identification of neurofibrillary degeneration with a typical distribution. Disappointingly, there are no pathological findings that are pathognomonic for PSP, and comparative analyses with other tauopathies have found many similarities to PSP.²³ In their original report, Olszewski and colleagues remarked on the similarities between the pathological features of PSP and postencephalitic parkinsonism (PEP), Hirano's parkinsonism dementia complex of Guam (PDC-Guam), and Alzheimer's disease.²⁴

Subsequent observations have enabled further characterisation of these diseases, although the pathological boundaries between the primary tauopathies are blurred and, in many cases, absolute distinction between them is impossible without clinical data (figure 1).²³ PEP is thought of as a multisystem tauopathy that is characterised by widespread neuronal loss, the accumulation of tau aggregates in neurons and glia, and severe degradation of

the dopaminergic substantia nigra.³ In PDC-Guam, tau-positive neurofibrillary tangles are found in the neocortex and basal ganglia structures, but the neuropil threads and coiled bodies are sparse compared with the distribution seen in PSP.²⁵ The topographical distribution of tau pathology in PDC-Guam is similar to the pattern of atrophy and neuronal loss and includes substantial deposition of tau in the cortex.²⁶ This distribution of tau is not typical of Richardson's syndrome, and ultrastructural analysis of insoluble tau might be required to distinguish PDC-Guam from PSP.²⁷ Guadeloupean parkinsonism is thought of as one form of tauopathy, although the tufted astrocytes are a less prominent feature.²⁸ In contrast to PDC-Guam, the distribution of pathological changes seen in patients with Guadeloupean parkinsonism is indistinguishable from the distribution seen in patients with PSP.

Although the pathological distinction of PSP from corticobasal degeneration is routine, many of the features of tau accumulation in corticobasal degeneration are similar to those in PSP:^{14,29,30} the neurons and glia express the same pathological form of tau, and the tangles in both disorders are ultrastructurally composed of predominantly straight filaments. Furthermore, the tau H1c susceptibility haplotype is strongly associated with the pathology of PSP and corticobasal degeneration.³¹ Corticobasal degeneration is characterised by ballooned neurons and characteristic glial pathology, including tau-positive astrocytic plaques.²⁹ In general, the tau pathology in corticobasal degeneration has a more cortical distribution than the distribution in PSP, although substantial overlap exists.¹⁴ Widespread deposition of beta-amyloid in the cerebral cortex in Alzheimer's disease and post-traumatic encephalopathy helps to distinguish neuropathologically these disorders from PSP; AD and post-traumatic encephalopathy have an excess of all six pathological forms of tau on immunoblotting.³²

Tau mutations and PSP

Tau has six alternatively spliced isoforms, which differ by the presence or absence of a 29 amino acid insert (N1) and/or a 59 amino acid insert (N2) at the N terminus, and several 31 amino acid repeats in the microtubule-binding domain (figure 3).³² The microtubule-binding domain contains either three 31 amino acid repeats (3R) or four 31 amino acid repeats (4R). In the brains of healthy adults, the concentrations of 3R tau and 4R tau are similar, but in PSP the concentration of 4R increases and the 3R:4R ratio falls.³³

Mutations in *MAPT*, the gene that encodes microtubule-associated tau on chromosome 17, are commonly associated with frontotemporal dementia with parkinsonism (FTDP-17), which is pathologically classified as a primary tauopathy. The pathological features of FTDP-17 overlap with PSP, Alzheimer's disease, corticobasal degeneration, and Pick's disease. *MAPT* is not mutated in sporadic PSP, but there are several reports of

mutations in *MAPT* that are associated with clinical and pathological abnormalities that closely resemble those of Richardson's syndrome.^{34–38} A diagnosis of FTDP-17 requires molecular genetic analysis for confirmation, but the routine screening of sporadic cases of PSP for mutations in *MAPT* is not recommended because the yield is small.³⁵ In rare cases, patients with some of the clinical features of PSP and mutations in *MAPT* have atypical clinical or pathological features. For example, one patient with a tau exon 10 +16 (intronic) mutation had young-onset PSP at 40 years old but no family history of neurological disease.³⁹ A silent mutation—Ser305Ser—in exon 10 of tau was identified in a patient with a history of early dementia, abnormalities of gaze, and the pathological characteristics of PSP, but without falls or axial rigidity. Two affected members of this patient's family had atypical clinical features of PSP, including early severe dementia, early dystonia, and gaze abnormalities, without dementia.⁴⁰ Two brothers from a family in Spain, who were born from a third-degree consanguineous marriage, developed dementia and supranuclear gaze palsy in their fourth decade and died within 5 years of disease onset.³⁷ A homozygous deletion in codon 296 of *MAPT* was identified in one of the affected siblings. Two family members with Parkinson's disease were identified as the heterozygous carriers, but neither of them developed PSP or atypical parkinsonism.⁴¹ Another genetic association has been reported in a large Spanish family with a PSP phenotype linked to a locus on chromosome 1q31.1.³⁸ Pathological changes that would satisfy the diagnostic criteria for PSP were reported in one member of this family.

Clinical heterogeneity

The early clinical features of PSP are often subtle and can be difficult to discern from those of other physical or psychological disorders.⁴² Early diagnosis is a challenge in primary health-care settings, and the definitive clinical diagnosis is commonly delayed for many months. Fewer than half of patients with pathologically diagnosed PSP will have received a diagnosis of PSP at presentation, and 20% will have had a different diagnosis at the time of death.^{43–47} However, in most cases of Richardson's syndrome, the clinical diagnosis is evident within the first 2 years.^{10, 48}

The National Institute of Neurological Disorders and Stroke (NINDS) PSP clinical diagnostic criteria were compiled to identify reliably patients for clinical research who had underlying PSP-tau pathology.⁴⁹ These stringent and specific criteria state that early falls due to postural instability and supranuclear gaze palsy or slowed vertical saccades are the most helpful defining clinical features.⁵⁰ When present, these two physical signs are particularly useful to distinguish PSP from Parkinson's disease but they have restricted value in routine clinical practice because of their low sensitivity and the absence of falls and gaze palsies in many patients.^{49–51}

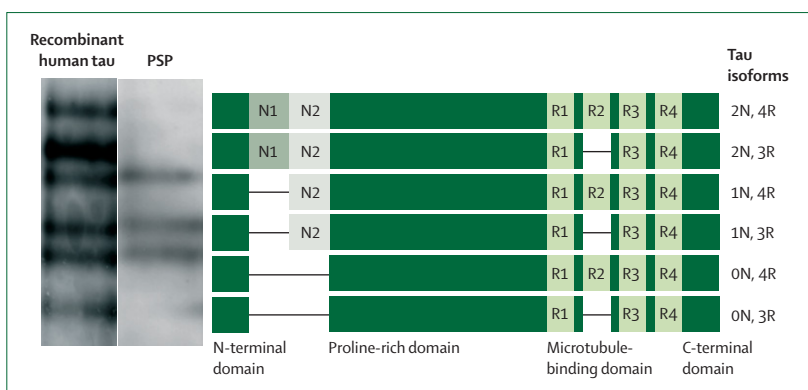


Figure 3: Isoforms of tau

The six microtubule-associated isoforms of tau are shown. (N=N-terminal repeats; R=microtubule-binding domains). The left panels show the detection of the isoforms by western blot in homogenates from bacteria expressing recombinant human tau (all six isoforms are detected) and a patient with PSP-tau pathology (the four-repeat isoforms are predominantly detected). The blots were analysed with the polyclonal TP70 anti-tau antibody, which was raised against the C-terminal domain and hence can be used to detect all six isoforms. PSP=progressive supranuclear palsy. Figure reproduced with permission from Wiley-Blackwell.²³

The different modes of presentation and clinical variability have led to several studies that were designed to assess the clinical and pathological heterogeneity of PSP. A new nosology is emerging that confirms the original observations of Richardson but also separates out several other useful clinical subtypes that would otherwise not satisfy the operational clinical diagnostic criteria for PSP.

Richardson's syndrome

A lurching gait, sometimes described as that of a drunken sailor or a dancing bear, and unexplained falls backwards without loss of consciousness are the commonest presentations of PSP. More than half of patients with PSP will also develop some personality change or cognitive slowing within the first 2 years.^{10, 52–54} Non-specific ocular symptoms are also common, including dry, red, sore eyes; photophobia; blurred vision; and difficulty in focussing.^{1, 10, 42, 52} Supranuclear gaze palsy with difficulty looking up or messy eating (the dirty tie phenomenon) usually occur later, but a slowing of vertical saccadic eye movements is an early telltale sign on neurological examination.^{1, 10, 53, 55} Vertical supranuclear gaze palsy is the definitive diagnostic feature most often looked for in the clinic but this commonly develops many years into the disease, which delays the diagnosis. Other diagnostic possibilities should also be considered when oculomotor abnormalities are seen (panel). Eyelid abnormalities are common and include spontaneous involuntary eyelid closure or apraxia of eyelid opening, which is often most prominent when talking or eating and can cause functional blindness. Spontaneous blink rate is severely impaired and contributes to ocular irritation, epiphora, and blurring of vision. A slow, slurred, growling speech and difficulties in swallowing are other typical early features.^{10, 52, 53} Overactivity of the frontalis, procerus, and corrugator

Panel: Potential causes of eye movement abnormalities, postural instability, and parkinsonism that are not due to progressive supranuclear palsy

- Dementia with Lewy bodies⁵⁶
- Multiple system atrophy⁴⁸
- Cerebrovascular disease⁵⁷
- Aortic surgery and hypoxic damage^{58,59}
- Frontotemporal dementia associated with chromosome 17³⁰
- Ubiquitin-positive frontotemporal lobar degeneration⁶⁰
- Neurosyphilis⁶¹
- Motor neuron disease with congophilic angiopathy⁶²
- Amyotrophic lateral sclerosis⁶³
- Antiphospholipid syndrome⁶⁴
- Prion disease⁶⁵
- Lytico-Bodig disease⁶⁶
- Cerebral autosomal dominant arteriopathy with subcortical infarcts and leukoencephalopathy⁶⁷
- Whipple's disease⁶⁸
- Neimann-Pick disease type C⁶⁹

muscles cause eyelid retraction and a staring gaze, which contribute to the characteristic surprised, worried facial appearance of patients with PSP.⁷⁰

These symptoms lead to an inexorable decline in functional capacity and quality of life, with increasing motor and mental handicap. Most patients become dependent on others for care within 3 to 4 years of diagnosis.^{52,71} Speech becomes unintelligible, and recurrent choking often necessitates the insertion of a percutaneous gastrostomy.^{52,72} Motor recklessness, difficulties with visual orientation, and postural instability lead to recurrent falls with resultant fractures and, inevitably, the patient becomes wheelchair bound.^{47,73}

The median survival in the original series was 5 years from disease onset; in larger, more recent studies, disease durations to death of 5 to 8 years have been reported.^{10,52,71,72,74} The most common causes of death are aspiration pneumonia, primary neurogenic respiratory failure, or pulmonary emboli.^{73,75} When this clinical syndrome is associated with the pathological findings of PSP, we have suggested that it should be called Richardson's syndrome.

PSP-P

None of the patients described by Richardson had "the characteristic parkinsonian features, and none had tremor".^{1,54} He did describe facial inexpressivity, a reduced volume of speech, and "rubbery" rigidity, but he emphasised the absence of limb rigidity and bradykinesia. He was more struck by the pseudobulbar weakness and rigidity in extension, and was bemused by the later classification of PSP under the rubric of 'atypical parkinsonism' or 'Parkinson's plus' (personal communication, J Steele).

Pathological series of patients with PSP have consistently identified a small group of patients who did not fit the classic clinical description and had atypical clinical features of PSP, including normal eye movements, resting tremor, a positive levodopa response, and focal dementia.¹⁰ We have examined the clinical features of patients with PSP-tau pathology with a data-driven approach and without a priori assumptions, to define more clearly the composite clinical characteristics of these patients.¹⁰ A similar methodology has also been used by Kaat and colleagues⁵³ to analyse a prospectively collected, clinically diagnosed group of patients with presumed PSP-tau pathology. Both studies reported the classic presentation of Richardson's syndrome and a smaller group in whom parkinsonism dominated the early clinical picture. The patients in the latter group presented with limb bradykinesia, rigidity, and, in some cases, tremor, and were commonly misdiagnosed with Parkinson's disease. Asymmetry of limb signs was seen in some cases. Although axial rigidity was often a striking early feature, with associated speech and gait difficulties, limb rigidity was more common and severe than in patients with Richardson's syndrome, in whom muscle tone can be normal. Tremor is part of the mandatory exclusion criteria in some diagnostic guidelines for PSP,^{44,76} but jerky postural tremor and even a 4–6 Hz rest tremor were common in the patients with PSP-P.^{11,52,76} A moderate or good improvement in bradykinesia and rigidity follows initiation of levodopa therapy in a proportion of patients with PSP-P, although the response is rarely excellent,^{10,73} and secondary unresponsiveness that occurs over a few years is usual.⁷⁷

PSP-P and Richardson's syndrome can be distinguished by their different clinical pictures in the first 2 years; however, there is clinical overlap, and after 6 years of follow up the clinical phenomenology might become similar.¹⁰ Few of the patients who were classified as having PSP-P had all the clinical features, and they were classified in this way because the symptoms of parkinsonism were more conspicuous than those of Richardson's syndrome (postural instability, falls, cognitive decline, and eye movement abnormalities) in the first 2 years.¹⁰ We have proposed several clinical features as clues to the clinical diagnosis of PSP-P, but we emphasise the difficulty in separating these patients from those with idiopathic Parkinson's disease (table 1). Early pointers that might help a clinical diagnosis of PSP-P could include rapid progression, prominent axial symptomatology, or a poor response to levodopa, despite clinical features that are typical of idiopathic Parkinson's disease. Falls and cognitive dysfunction occur later in PSP-P than they do in Richardson's syndrome and, perhaps as a consequence, the time for disease duration to death is about 3 years longer in PSP-P.^{17,78}

In a few patients, a purely parkinsonian syndrome predominates until death, and abnormalities of eye movement or other characteristics of Richardson's syndrome might never appear.^{10,77} A sustained response to

levodopa and drug-induced choreic dyskinesias with a long duration of disease seem to characterise these patients. Furthermore, they seem to have the most distinct form of PSP-P and might be analogous to patients with benign minimal lesion change multiple system atrophy, in whom the full spectrum of clinical features do not develop and pathological examination shows a more restricted distribution than usual.

The prevalence of PSP-P is difficult to estimate because of the inherent biases in pathological series, including selection bias that favours unusual cases and patients who attend tertiary referral centres.⁷⁹ 32% of patients with PSP pathology in the Queen Square Brain Bank (QSBB) series presented with a predominantly parkinsonian syndrome. This is probably an overestimation of the true prevalence because of the emphasis of the QSBB on parkinsonian symptoms.¹⁰ In a regional study of clinically diagnosed PSP, 8% of patients initially presented with an asymmetric, levodopa-responsive tremor, bradykinesia, and rigidity.⁵³ However, this study excluded patients who had not developed eye movement abnormalities or early postural instability or falls, and the authors predicted that they had underestimated the community prevalence of PSP-P.¹⁰

PSP-PAGF

The syndrome of PSP-PAGF seems to be highly predictive of PSP-tau pathology.^{16,80,81} Pure akinesia was first described in 1974 in two patients who developed freezing of gait, writing, and speech, with paradoxical kinesia.⁸² At presentation, these patients were cognitively intact, had no abnormalities of eye movement, and, as is the case in many patients, there was a long disease duration without the development of other parkinsonian features.^{12,83} The clinical diagnostic criteria that have recently been proposed for this syndrome include progressive onset of gait disturbance with start hesitation and subsequent freezing of gait, speech, or writing, without rigidity; tremor;

dementia; or eye movement abnormality during the first 5 years of the disease. There is no benefit with levodopa therapy, and no clinical or radiological evidence of lacunar infarcts or diffuse deep white matter ischaemia.¹²

When the PSP-PAGF criteria were applied retrospectively to a clinically diagnosed series of 759 patients with parkinsonism, seven patients with this disorder were identified: six had PSP-tau pathology and one had Lewy body pathology at post mortem. The six patients with PSP-tau pathology presented with gait disturbances and postural instability that lasted for up to 24 months before they developed freezing, start hesitation, and gait initiation failure. Phonation difficulties, facial immobility, and a reduction in the size of handwriting were other early signs. Axial rigidity with pronounced neck stiffness without limb rigidity was also a distinctive feature.^{12,83} Supranuclear downgaze paresis and blepharospasm developed late in most patients but, in contrast to Richardson's syndrome, frontolimbic cognitive deficits and bradyphrenia were not prominent.^{12,13} The median duration of disease was 11 years.

The diagnostic criteria for PSP-PAGF have not been prospectively studied and require assessment of symptoms over 5 years; therefore, their true clinical value is unknown. A prospective study of patients with isolated gait freezing (ie, not the full syndrome of PAGF) showed that several diseases, including subcortical white matter ischaemia (Binswanger leukoaraiosis), Parkinson's disease, and dementia with Lewy bodies, can also present in this way.⁸⁴

In a small clinical series, the acoustic startle response was absent in most patients with Richardson's syndrome or PSP-P but was present in all patients with PSP-PAGF. The acoustic startle response is generated in the nucleus reticularis pontis caudalis, in which there is less severe pathology according to pathological studies of PSP-PAGF.^{13,16,17} The auditory blink reflex, by contrast, is mediated by midbrain structures and passes through the

| | Richardson's syndrome | PSP-P | PSP-PAGF | PSP-CBS | PSP-PNFA | Parkinson's disease |
|-------------------------------------|---------------------------|-------------------------------------|----------|-----------|-----------|---------------------------|
| Rigidity | Axial much more than limb | Axial less than or the same as limb | Axial | Yes | Sometimes | Limb much more than axial |
| Bradykinesia | Mild | Moderate | Moderate | Yes | Mild | Moderate |
| Tremor | No | Yes/no (rest or jerky postural) | No | No | No | Yes (at rest) |
| Early falls | Yes | No | No | Sometimes | Sometimes | No |
| Early postural instability | Yes | No | Yes | .. | .. | No |
| Early cognitive decline | Often | No | No | No | Yes | No |
| Early abnormalities of eye movement | Yes | No | No | No | Sometimes | No |
| Response to levodopa | No | Often | No | No | No | Usually |
| Hyposmia | No | No | .. | .. | .. | Yes |
| Cardiac MIBG | Normal | Normal* | Normal* | .. | .. | Abnormal |

PSP=progressive supranuclear palsy. CBS=corticobasal syndrome. PAGF=pure akinesia with gait freezing. PNFA=progressive non-fluent aphasia. MIBG=¹²³I-labelled meta-iodobenzylguanidine. ..=unknown. *Author's unpublished data.

Table 1: Clinical features of Richardson's syndrome, PSP-PAGF, PSP-CBS, PSP-PNFA, and Parkinson's disease

| | Clinical features |
|--|---|
| Frontal cortex | Dysexecutive syndrome; progressive non-fluent aphasia; perseveration; impulsivity |
| Parietal cortex | Alien limb |
| Substantia nigra | Rigidity; bradykinesia; postural instability; dystonia |
| Extranigral midbrain dopamine neurons | No response to levodopa |
| Periaqueductal grey and raphe nucleus | Sleep disturbances |
| Dentate nucleus | Gaze fixation (excess of square wave jerks) |
| Pontine and medullary nuclei | Dysarthria; dysphagia |
| riMLF (premotor burst neurons) | Slow saccades |
| Cholinergic neurons of the lower pontine reticular formation | No startle response; oculomotor dysfunction |

riMLF=rostral interstitial nuclei of the medial longitudinal fasciculus.

Table 2: Clinical and anatomical correlations of progressive supranuclear palsy-tau pathology

upper medulla and superior olivary complex.⁸⁵ This reflex was absent in most patients with Richardson's syndrome but was preserved in all patients with PSP-P or PSP-PAGF.^{13,16,17}

PBS-CBS

PSP-CBS is characterised by progressive, asymmetric dyspraxia, cortical sensory loss, including an alien limb, jerky dystonia of the limb with rigidity, and bradykinesia that is unresponsive to levodopa.⁸⁶ PSP-CBS was first described in patients with corticobasal degeneration.⁸⁷ Pathological series have indicated that only 50% of patients with CBS have pathology that is typical of corticobasal degeneration, which is characterised by archimorphic, balloon-shaped neurons and prominent diffuse cortical glial tau pathology, including neuropil threads, coiled bodies, and astrocytic plaques that immunostain strongly with antibodies to 4R tau. Cerebrovascular disease, Alzheimer's disease, and progressive supranuclear pathology account for most of the other patients.^{14, 88-91}

PSP-CBS seems to be a rare presentation of PSP-tau pathology; only five patients from a pathological series of 160 patients with PSP were identified with asymmetric limb dystonia, apraxia, and alien limb phenomena.¹⁴ Cortical sensory loss and aphasia were seen in some patients. None of these patients developed postural instability or falls within the first year of disease, and dysarthria, dysphagia, and axial rigidity were also absent early on. Most patients with PSP-CBS eventually develop postural instability but this occurs much later than in Richardson's syndrome.^{14,89} An increase in latency to initiate saccadic eye movements, which leads eventually to compensatory head tilts, is the most common eye movement abnormality and is typically more pronounced on the side on which the apraxia predominates.⁹² The

distinction between this and the typical slowness of saccadic eye movements in Richardson's syndrome can be difficult to make early in the course of the disease.^{92,93} Patients with advanced disease might also develop some mild slowing of saccadic velocity, although this is not as severe as that seen in Richardson's syndrome.

PNFA

PNFA is a disorder of language that is characterised by non-fluent spontaneous speech, with hesitancy, agrammatism, and phonemic errors that require substantial effort in speech production.⁹⁴ PNFA fits within the spectrum of frontotemporal dementia syndromes and might be seen in corticobasal syndrome.⁹⁵ There are several components to the speech and language difficulties in PNFA, including apraxia of speech, which describes errors in the timing, coordination, and initiation of speech, that are secondary to disorders of motor command.⁹⁶ Clinically, apraxia of speech is evident during serial repetition, and although it usually accompanies agrammatism, it has been reported as an isolated, early sign of PNFA.¹⁵ In a small case series, five of seven patients who presented with PNFA and prominent early apraxia of speech had underlying PSP-tau pathology.⁹⁷ The other two patients had Pick's disease and corticobasal degeneration, respectively. The apparent specificity of prominent early apraxia of speech for tauopathies, particularly PSP-tau pathology, has led to the suggestion that this syndrome should be regarded as a clinical subtype of PSP (PSP-PNFA). Patients who present with prominent early apraxia of speech do so at similar ages of onset or disease duration as patients with Richardson's syndrome.^{15,97} PNFA with less prominent apraxia of speech is more likely to be due to corticobasal degeneration or frontotemporal lobar degeneration with tau-negative and ubiquitin-positive inclusions.⁹⁷ These findings are yet to be replicated and are conspicuously absent from other clinicopathological series of patients who presented with frontotemporal dementia syndromes.⁹⁵

Conclusions

The classic Richardson's syndrome is the most distinctive clinical disorder related to PSP-tau pathology. As with other neurodegenerative conditions, including Alzheimer's disease,³⁰ idiopathic Parkinson's disease,⁹⁸ and even among patients with monogenetic parkinsonism⁹⁹ and frontotemporal dementias,¹⁰⁰ there is clinical variability among patients with PSP-tau pathology. The identification of PSP-P, PAGF, PSP-CBS, and PNFA indicate that there are other related but distinct clinical syndromes in addition to Richardson's syndrome. The pathological hallmarks of PSP cannot any longer be thought to predict the clinical features of Richardson's syndrome reliably, and the clinical variants challenge the singularity of clinicopathological PSP. Nevertheless, the disease subtypes can be included under the generic term PSP owing to a similar rapidly progressive course that leads to death in 6 to 12 years and a

Search strategy and selection criteria

References for this Review were identified through searches of PubMed from 1966 until October, 2008, with the terms “progressive supranuclear palsy” and “corticobasal syndrome”. Articles were also identified through searches of the authors’ own files. We selected papers in which clinicopathological correlations had been made, and relied less on phenomenological descriptions from clinically defined cases. Only papers published in English were reviewed.

broadly similar pathology, including 4R tau inclusions, tufted astrocytes, and coiled bodies. The regional differences in pathological severity almost certainly account for the clinical differences and logically correlate with the different clinical features (table 2). These observations challenge the reliance on prototype clinical syndromes to predict pathological findings and further emphasise the need for the careful investigation of each patient in terms of their natural history, physical signs, and genetic abnormalities.

The early recognition of patients with Richardson’s syndrome, PSP-P, PSP-CBS, PAGF, or PSP-PNFA would be enhanced by biomarkers for tauopathies and clinical criteria with a high positive predictive value for Parkinson’s disease, which is the main differential diagnosis for these conditions and is 30 times more prevalent than PSP.^{101–103} Clinical features, such as visual hallucinations, drug-induced dyskinesias, hyposmia, and a prolonged sustained response to levodopa are uncommon in PSP, but have not yet been prospectively assessed in PSP-P, PAGF, or PSP-CBS.^{73,76,104,105}

A better understanding of the factors that influence neuronal vulnerability in the different clinical groups is likely to lead to further insights into the pathological processes that lead to neurodegeneration. In that sense, the clinical assessment of patients is important for scientists and clinicians. Whether the abnormal aggregation of hyperphosphorylated tau protein in the brain links PSP to the other primary tauopathies and will prove to be the key abnormality that unlocks the mystery of this group of brutal incurable neurodegenerative disorders still needs to be understood.

Contributors

DRW planned the Review, searched the published works, wrote the first draft, produced the images, and edited the manuscript. AJL reviewed the published articles and edited the first draft.

Conflicts of interest

We have no conflicts of interest.

References

- 1 Steele JC, Richardson JC, Olszewski J. Progressive supranuclear palsy. A heterogeneous degeneration involving the brain stem, basal ganglia and cerebellum with vertical supranuclear gaze and pseudobulbar palsy, nuchal dystonia and dementia. *Arch Neurol* 1964; **10**: 333–59.
- 2 Hauw JJ, Daniel SE, Dickson D, et al. Preliminary NINDS neuropathologic criteria for Steele–Richardson–Olszewski syndrome (progressive supranuclear palsy). *Neurology* 1994; **44**: 2015–19.
- 3 Litvan I, Hauw JJ, Bartko JJ, et al. Validity and reliability of the preliminary NINDS neuropathologic criteria for progressive supranuclear palsy and related disorders. *J Neuropathol Exp Neurol* 1996; **55**: 97–105.
- 4 Caparros-Lefebvre D, Lees AJ. Atypical unclassifiable parkinsonism on Guadeloupe: an environmental toxic hypothesis. *Mov Disord* 2005; **20** (suppl 12): S114–18.
- 5 Oyanagi K, Chen KM, Craig UK, Yamazaki M, Perl DP. Parkinsonism, dementia and vertical gaze palsy in a Guamanian with atypical neuroglial degeneration. *Acta Neuropathol* 2000; **99**: 73–80.
- 6 Oyanagi K, Tsuchiya K, Yamazaki M, Ikeda K. Substantia nigra in progressive supranuclear palsy, corticobasal degeneration, and parkinsonism–dementia complex of Guam: specific pathological features. *J Neuropathol Exp Neurol* 2001; **60**: 393–402.
- 7 Yamazaki M, Makifuchi T, Chen KM, Mori O, Katayama Y, Takahashi H, et al. Progressive supranuclear palsy on Guam. *Acta Neuropathol* 2001; **102**: 510–14.
- 8 de Silva R, Lashley T, Gibb G, et al. Pathological inclusion bodies in tauopathies contain distinct complements of tau with three or four microtubule-binding repeat domains as demonstrated by new specific monoclonal antibodies. *Neuropathol Appl Neurobiol* 2003; **29**: 288–302.
- 9 Dickson DW. Tauopathies. Neurodegeneration: the molecular pathology of dementia and movement disorders. Basel: ISN Neuropath Press; 2006. p 82–154.
- 10 Williams DR, de Silva R, Paviour DC, et al. Characteristics of two distinct clinical phenotypes in pathologically proven progressive supranuclear palsy: Richardson’s syndrome and PSP-parkinsonism. *Brain* 2005; **128**: 1247–58.
- 11 Williams DR, Lees AJ, Wherrett JR, Steele JC. J. Clifford Richardson and 50 years of progressive supranuclear palsy. *Neurology* 2008; **70**: 566–73.
- 12 Williams DR, Holton JL, Strand K, Revesz T, Lees AJ. Pure akinesia with gait freezing: A third clinical phenotype of progressive supranuclear palsy. *Mov Disord* 2007; **22**: 2235–41.
- 13 Ahmed Z, Josephs KA, Gonzalez J, DelleDonne A, Dickson DW. Clinical and neuropathologic features of progressive supranuclear palsy with severe pallido–nigro–luisial degeneration and axonal dystrophy. *Brain* 2008; **131**: 460–72.
- 14 Tsuboi Y, Josephs KA, Boeve BF, et al. Increased tau burden in the cortices of progressive supranuclear palsy presenting with corticobasal syndrome. *Mov Disord* 2005; **20**: 982–88.
- 15 Josephs KA, Boeve BF, Duffy JR, Smith GE, Knopman DS, Parisi JE, et al. Atypical progressive supranuclear palsy underlying progressive apraxia of speech and nonfluent aphasia. *Neurocase* 2005; **11**: 283–96.
- 16 Williams DR, Holton J, Strand C, et al. Pathological tau burden and distribution distinguishes progressive supranuclear palsy-parkinsonism from Richardson’s syndrome. *Brain* 2007; **130**: 1566–76.
- 17 Jellinger KA. Different tau pathology pattern in two clinical phenotypes of progressive supranuclear palsy. *Neurodegenerative Dis* 2008; **5**: 339–46.
- 18 Williams DR, Holton J, Strand C, et al. Pathological tau burden and distribution distinguishes PSP-P from Richardson’s syndrome. *Brain* 2007; **130**: 1566–76.
- 19 Murphy KE, Karacsonji T, Hardman CD, Halliday GM. Excessive dopamine neuron loss in progressive supranuclear palsy. *Mov Disord* 2008; **23**: 607–10.
- 20 Sanchez-Gonzalez MA, Garcia-Cabezas MA, Rico B, Cavada C. The primate thalamus is a key target for brain dopamine. *J Neurosci* 2005; **25**: 6076–83.
- 21 Park HK, Kim JS, Im KC, et al. Functional brain imaging in pure akinesia with gait freezing: [(18)F] FDG PET and [(18)F] FP-CIT PET analyses. *Mov Disord* 2008; **24**: 237–45.
- 22 Williams DR, Doyle LM, Lees AJ, Brown P. The auditory startle response in parkinsonism may reveal the extent but not type of pathology. *J Neurol* 2008; **255**: 628–32.
- 23 Hauw JJ, Dickson DW. Tauopathies. Neurodegeneration: the molecular pathology of dementia and movement disorders. Basel: ISN Neuropath Press; 2003. p 82–154.
- 24 Olszewski J, Steele J, Richardson JC. Pathological report on six cases of heterogeneous system degeneration. *J Neuropathol Exp Neurol* 1963; **23**: 187–88.

- 25 Wakayama I, Kihira T, Yoshida S, Garruto RM. Rare neurofibrillary threads in amyotrophic lateral sclerosis and parkinsonism-dementia on Guam and in the Kii Peninsula of Japan. *Dementia* 1993; **4**: 75–80.
- 26 Oyanagi K, Makifuchi T, Ohtoh T, Chen KM, Gajdusek DC, Chase TN. Distinct pathological features of the gallyas- and tau-positive glia in the Parkinsonism-dementia complex and amyotrophic lateral sclerosis of Guam. *J Neuropathol Exp Neurol* 1997; **56**: 308–16.
- 27 Yamazaki M, Hasegawa M, Mori O, et al. Tau-positive fine granules in the cerebral white matter: a novel finding among the tauopathies exclusive to parkinsonism-dementia complex of Guam. *J Neuropathol Exp Neurol* 2005; **64**: 839–46.
- 28 Caparros-Lefebvre D, Sergeant N, Lees A, et al. Guadeloupean parkinsonism: a cluster of progressive supranuclear palsy-like tauopathy. *Brain* 2002; **125**: 801–11.
- 29 Dickson DW, Bergeron C, Chin SS, et al. Office of Rare Diseases neuropathologic criteria for corticobasal degeneration. *J Neuropathol Exp Neurol* 2002; **61**: 935–46.
- 30 Mizuno T, Shiga K, Nakata Y, et al. Discrepancy between clinical and pathological diagnoses of CBD and PSP. *Journal of Neurology* 2005; **252**: 687–97.
- 31 Pittman AM, Myers AJ, Abou-Sleiman P, et al. Linkage disequilibrium fine mapping and haplotype association analysis of the tau gene in progressive supranuclear palsy and corticobasal degeneration. *J Med Genet* 2005; **42**: 837–46.
- 32 Williams DR. Tauopathies: classification and clinical update on neurodegenerative diseases associated with microtubule-associated protein tau. *Intern Med J* 2006; **36**: 652–60.
- 33 Goedert M. Tau protein and neurodegeneration. *Semin Cell Dev Biol* 2004; **15**: 45–49.
- 34 Poorkaj P, Muma NA, Zhukareva V, et al. An R5L tau mutation in a subject with a progressive supranuclear palsy phenotype. *Ann Neurol* 2002; **52**: 511–16.
- 35 Williams DR, Pittman AM, Revesz T, Lees AJ, de Silva R. Genetic variation at the tau locus and clinical syndromes associated with progressive supranuclear palsy. *Mov Disord* 2007; **22**: 895–97.
- 36 Morris HR, Katzschlager R, Janssen JC, et al. Sequence analysis of tau in familial and sporadic progressive supranuclear palsy. *JNNP* 2002; **72**: 388–90.
- 37 Pastor P, Pastor E, Carnero C, et al. Familial atypical progressive supranuclear palsy associated with homozygosity for the delN296 mutation in the tau gene. *Ann Neurol* 2001; **49**: 263–67.
- 38 Ros R, Gomez GP, Hirano M, et al. Genetic linkage of autosomal dominant progressive supranuclear palsy to 1q31.1. *Ann Neurol* 2005; **57**: 634–41.
- 39 Morris HR, Osaki Y, Holton J, et al. Tau exon 10 +16 mutation FTDP-17 presenting clinically as sporadic young onset PSP. *Neurology* 2003; **61**: 102–04.
- 40 Stanford PM, Halliday GM, Brooks WS, et al. Progressive supranuclear palsy pathology caused by a novel silent mutation in exon 10 of the tau gene: expansion of the disease phenotype caused by tau gene mutations. *Brain* 2000; **123**: 880–93.
- 41 Friedland RP, Koss E, Haxby JV, et al. NIH conference. Alzheimer disease: clinical and biological heterogeneity *Annals of Internal Medicine* 1988; **109**: 298–311.
- 42 Williams DR, Lees AJ. How do patients with parkinsonism present? A clinicopathological study. *Internal Medicine Journal* 2008; published online April 16. DOI:10.1111/j.1445-5994.2008.01635.
- 43 Osaki Y, Ben-Shlomo Y, Lees AJ, et al. Accuracy of clinical diagnosis of progressive supranuclear palsy. *Mov Disord* 2004; **19**: 181–89.
- 44 Hughes AJ, Daniel SE, Ben-Shlomo Y, Lees AJ. The accuracy of diagnosis of parkinsonian syndromes in a specialist movement disorder service. *Brain* 2002; **125**: 861–70.
- 45 Morris HR, Gibb G, Katzschlager R, et al. Pathological, clinical and genetic heterogeneity in progressive supranuclear palsy. *Brain* 2002; **125**: 969–75.
- 46 Daniel SE, de BV, Lees AJ. The clinical and pathological spectrum of Steele-Richardson-Olszewski syndrome (progressive supranuclear palsy): a reappraisal. *Brain* 1995; **118**: 759–70.
- 47 Litvan I, Grimes DA, Lang AE, et al. Clinical features differentiating patients with postmortem confirmed progressive supranuclear palsy and corticobasal degeneration. *J Neurol* 1999; **246** (suppl 2): III–5.
- 48 Santacruz P, Uttl B, Litvan I, Grafman J. Progressive supranuclear palsy: a survey of the disease course. *Neurology* 1998; **50**: 1637–47.
- 49 Litvan I, Agid Y, Calne D, et al. Clinical research criteria for the diagnosis of progressive supranuclear palsy (Steele-Richardson-Olszewski syndrome): report of the NINDS-SPSS international workshop. *Neurology* 1996; **47**: 1–9.
- 50 Litvan I, Agid Y, Jankovic J, et al. Accuracy of clinical criteria for the diagnosis of progressive supranuclear palsy (Steele-Richardson-Olszewski syndrome). *Neurology* 1996; **46**: 922–30.
- 51 Williams DR, Watt HC, Lees AJ. Predictors of falls and fractures in bradykinetic rigid syndromes: a retrospective study. *JNNP* 2006; **77**: 468–73.
- 52 Nath U, Ben-Shlomo Y, Thomson RG, Lees AJ, Burn DJ. Clinical features and natural history of progressive supranuclear palsy: a clinical cohort study. *Neurology* 2003; **60**: 910–16.
- 53 Kaat LD, Boon AJ, Kamphorst W, Ravid R, Duivenvoorden HJ, van Swieten JC. Frontal presentation in progressive supranuclear palsy. *Neurology* 2007; **69**: 723–29.
- 54 Richardson JC, Steele JC, Olszewski J. Supranuclear ophthalmoplegia, pseudobulbar palsy, nuchal dystonia and dementia. *Trans Am Neurol Assoc* 1963; **8**: 25–29.
- 55 Rottach KG, Riley DE, DiScenna AO, Zivotofsky AZ, Leigh RJ. Dynamic properties of horizontal and vertical eye movements in parkinsonian syndromes. *Ann Neurol* 1996; **39**: 368–77.
- 56 Fearnley JM, Revesz T, Brooks DJ, Frackowiak RS, Lees AJ. Diffuse Lewy body disease presenting with a supranuclear gaze palsy. *JNNP* 1991; **54**: 159–61.
- 57 Josephs KA, Ishizawa T, Tsuboi Y, Cookson N, Dickson DW. A clinicopathological study of vascular progressive supranuclear palsy: a multi-infarct disorder presenting as progressive supranuclear palsy. *Arch Neurol* 2002; **59**: 1597–601.
- 58 Mokri B, Ahlskog JE, Fulgham JR, Matsumoto JY. Syndrome resembling PSP after surgical repair of ascending aorta dissection or aneurysm. *Neurology* 2004; **62**: 971–73.
- 59 Kim HT, Shields S, Bhatia KP, Quinn N. Progressive supranuclear palsy-like phenotype associated with bilateral hypoxic-ischemic striopallidal lesions. *Mov Disord* 2005; **20**: 755–57.
- 60 Paviour DC, Lees AJ, Josephs KA, et al. Frontotemporal lobar degeneration with ubiquitin-only-immunoreactive neuronal changes: broadening the clinical picture to include progressive supranuclear palsy. *Brain* 2004; **127**: 2441–51.
- 61 Murialdo A, Marchese R, Abbruzzese G, Tabaton M, Michelozzi G, Schiavoni S. Neurosyphilis presenting as progressive supranuclear palsy. *Mov Disord* 2000; **15**: 730–31.
- 62 Weeks RA, Scaravilli F, Lees AJ, Carroll C, Husain M, Rudge P. Cerebral amyloid angiopathy and motor neurone disease presenting with a progressive supranuclear palsy-like syndrome. *Mov Disord* 2003; **18**: 331–36.
- 63 Morris HR, Bronstein AM, Shaw CE, Lees AJ, Love S. Clinical grand round: a rapidly progressive pyramidal and extrapyramidal syndrome with a supranuclear gaze palsy. *Mov Disord* 2005; **20**: 826–31.
- 64 Reitblat T, Polishchuk I, Dorodnikov E, et al. Primary antiphospholipid antibody syndrome masquerading as progressive supranuclear palsy. *Lupus* 2003; **12**: 67–69.
- 65 Revesz T, Daniel SE, Lees AJ, Will RG. A case of progressive subcortical gliosis associated with deposition of abnormal prion protein (PrP). *JNNP* 1995; **58**: 759–60.
- 66 Lepore FE, Steele JC, Cox TA, et al. Supranuclear disturbances of ocular motility in Lytico-Bodig. *Neurology* 1988; **38**: 1849–53.
- 67 Van Gerpen JA, Ahlskog JE, Petty GW. Progressive supranuclear palsy phenotype secondary to CADASIL. *Parkinsonism Relat Disord* 2003; **9**: 367–69.
- 68 Verbuch-Heller L, Paulson GW, Daroff RB, Leigh RJ. Whipple's disease mimicking progressive supranuclear palsy: the diagnostic value of eye movement recording. *JNNP* 1999; **66**: 532–35.
- 69 Neville BG, Lake BD, Stephens R, Sanders MD. A neurovisceral storage disease with vertical supranuclear ophthalmoplegia, and its relationship to Niemann-Pick disease. A report of nine patients. *Brain* 1973; **96**: 97–120.
- 70 Romano S, Colosimo C. Procerus sign in progressive supranuclear palsy. *Neurology* 2001; **57**: 1928.
- 71 Golbe LI, Ohman-Strickland PA. A clinical rating scale for progressive supranuclear palsy. *Brain* 2007; **130**: 1552–65.
- 72 Goetz CG, Leurgans S, Lang AE, Litvan I. Progression of gait, speech and swallowing deficits in progressive supranuclear palsy. *Neurology* 2003; **60**: 917–22.

- 73 Maher ER, Lees AJ. The clinical features and natural history of the Steele-Richardson-Olszewski syndrome (progressive supranuclear palsy). *Neurology* 1986; **36**: 1005–08.
- 74 Bower JH, Maraganore DM, McDonnell SK, Rocca WA. Incidence of progressive supranuclear palsy and multiple system atrophy in Olmsted County, Minnesota, 1976 to 1990. *Neurology* 1997; **49**: 1284–88.
- 75 Nath U, Thomson R, Wood R, et al. Population-based mortality and quality of death certification in progressive supranuclear palsy (Steele-Richardson-Olszewski syndrome). *JNNP* 2005; **76**: 498–502.
- 76 Golbe LI. Progressive supranuclear palsy. In: Jankovic J, Tolosa E, eds. *Parkinson's disease and movement disorders*. 2nd ed. Baltimore: Williams and Wilkins; 1993. 145–61.
- 77 Birdi S, Rajput AH, Fenton M, et al. Progressive supranuclear palsy diagnosis and confounding features: report on 16 autopsied cases. *Mov Disord* 2002; **17**: 1255–64.
- 78 O'Sullivan SS, Massey LA, Williams DR, et al. Clinical outcomes of progressive supranuclear palsy and multiple system atrophy. *Brain* 2008; **131**: 1362–72.
- 79 Maraganore DM, Anderson DW, Bower JH, McDonnell SK, Rocca WA. Autopsy patterns for Parkinson's disease and related disorders in Olmsted County, Minnesota. *Neurology* 1999; **53**: 1342–44.
- 80 Riley DE, Fogt N, Leigh RJ. The syndrome of 'pure akinesia' and its relationship to progressive supranuclear palsy. *Neurology* 1994; **44**: 1025–29.
- 81 Compta Y, Valldeoriola F, Tolosa E, Rey MJ, Marti MJ, Valls-Sole J. Long-lasting pure freezing of gait preceding progressive supranuclear palsy: a clinicopathological study. *Mov Disord* 2007; **22**: 1954–58.
- 82 Imai H, Narabayashi H. Akinesia—concerning 2 cases of pure akinesia. *Adv Neurol Sci* (Tokyo) 1974; **18**: 787–94.
- 83 Mizusawa H, Mochizuki A, Ohkoshi N, Yoshizawa K, Kanazawa I, Imai H. Progressive supranuclear palsy presenting with pure akinesia. *Adv Neurol* 1993; **60**: 618–21.
- 84 Factor SA, Higgins DS, Qian J. Primary progressive freezing gait: a syndrome with many causes. *Neurology* 2006; **66**: 411–14.
- 85 Hori A, Yasuhara A, Naito H, Yasuhara M. Blink reflex elicited by auditory stimulation in the rabbit. *J Neurol Sci* 1986; **76**: 49–59.
- 86 Cordato NJ, Halliday GM, McCann H, et al. Corticobasal syndrome with tau pathology. *Mov Disord* 2001; **16**: 656–67.
- 87 Rebeiz JJ, Kolodny EH, Richardson EP Jr. Corticodentatonigral degeneration with neuronal achromasia: a progressive disorder of late adult life. *Trans Am Neurol Assoc* 1967; **92**: 23–26.
- 88 Josephs KA, Petersen RC, Knopman DS, et al. Clinicopathologic analysis of frontotemporal and corticobasal degenerations and PSP. *Neurology* 2006; **66**: 41–48.
- 89 Wakabayashi K, Takahashi H. Pathological heterogeneity in progressive supranuclear palsy and corticobasal degeneration. *Neuropathology* 2004; **24**: 79–86.
- 90 Boeve BF, Maraganore DM, Parisi JE, et al. Pathologic heterogeneity in clinically diagnosed corticobasal degeneration. *Neurology* 1999; **53**: 795–800.
- 91 Motoi Y, Takahashi M, Itaya M, Ikeda K, Mizuno Y, Mori H. Glial localization of four-repeat tau in atypical progressive supranuclear palsy. *Neuropathology* 2004; **24**: 60–65.
- 92 Rivaud-Pechoux S, Vidailhet M, Galloudec G, Litvan I, Gaymard B, Pierrot-Deseilligny C. Longitudinal ocular motor study in corticobasal degeneration and progressive supranuclear palsy. *Neurology* 2000; **54**: 1029–32.
- 93 Leigh RJ, Zee DS. The saccadic system. In: Leigh RJ, Zee DS, editors. *The Neurology of Eye Movements*. 4th edn. Oxford: Oxford University Press; 2006. 108–87.
- 94 Neary D, Snowden JS, Gustafson L, et al. Frontotemporal lobar degeneration: a consensus on clinical diagnostic criteria. *Neurology* 1998; **51**: 1546–54.
- 95 Hodges JR, Davies RR, Xuereb JH, et al. Clinicopathological correlates in frontotemporal dementia. *Ann Neurol* 2004; **56**: 399–406.
- 96 Duffy JR. *Motor speech disorders: substrates, differential diagnosis, and management*. St. Louis: Mosby; 1995.
- 97 Josephs KA, Duffy JR, Strand EA, et al. Clinicopathological and imaging correlates of progressive aphasia and apraxia of speech. *Brain* 2006; **129**: 1385–98.
- 98 Lewis SJ, Foltynie T, Blackwell AD, Robbins TW, Owen AM, Barker RA. Heterogeneity of Parkinson's disease in the early clinical stages using a data driven approach. *JNNP* 2005; **76**: 343–48.
- 99 Zimprich A, Biskup S, Leitner P, et al. Mutations in *LRRK2* cause autosomal-dominant parkinsonism with pleomorphic pathology. *Neuron* 2004; **44**: 601–07.
- 100 van Swieten JC, Heutink P. Mutations in progranulin (GRN) within the spectrum of clinical and pathological phenotypes of frontotemporal dementia. *Lancet Neurol* 2008; **7**: 965–74.
- 101 Schrag A, Ben-Shlomo Y, Quinn NP. Prevalence of progressive supranuclear palsy and multiple system atrophy: a cross-sectional study. *Lancet* 1999; **354**: 1771–75.
- 102 Nath U, Ben-Shlomo Y, Thomson RG, et al. The prevalence of progressive supranuclear palsy (Steele-Richardson-Olszewski syndrome) in the UK. *Brain* 2001; **124**: 1438–49.
- 103 Porter B, Macfarlane R, Unwin N, Walker R. The prevalence of Parkinson's disease in an area of north tyneside in the north-east of England. *Neuroepidemiology* 2006; **26**: 156–61.
- 104 Williams DR, Warren JD, Lees AJ. Using the presence of visual hallucinations to differentiate Parkinson's disease from atypical Parkinsonism. *JNNP* 2008; **79**: 652–55.
- 105 Lees AJ. The Steele-Richardson-Olszewski syndrome (progressive upranuclear palsy). In: Marsden CD, Fahn S, editors. *Movement Disorders 2*. London: Butterworths; 1987. 272–87.