

## JOURNAL CLUB

# Prospective Evaluation of Point-of-Care Ultrasonography for the Diagnosis of Pneumonia in Children and Young Adults

Vaishali P. Shah, MD; Michael G. Tunik, MD; James W. Tsung, MD, MPH

**Objective:** To determine the accuracy of point-of-care ultrasonography for the diagnosis of pneumonia in children and young adults by a group of clinicians.

**Design:** Prospective observational cohort study.

**Setting:** Two urban emergency departments.

**Participants:** Patients from birth to age 21 years undergoing chest radiography for suspected community-acquired pneumonia.

**Intervention:** After documenting clinical examination findings, clinicians with 1 hour of focused training used ultrasonography to diagnose pneumonia in children and young adults.

**Main Outcomes Measures:** Test performance characteristics for the ability of ultrasonography to diagnose pneumonia were determined using chest radiography as a reference standard. Subgroup analysis was performed in patients having lung consolidation exceeding 1 cm with sonographic air bronchograms detected on ultrasonography; specificity and positive likelihood ratio (LR) were calculated to account for lung consolidation of 1 cm or

less with sonographic air bronchograms undetectable by chest radiography.

**Results:** Two hundred patients were studied (median age, 3 years; interquartile range, 1-8 years); 56.0% were male, and the prevalence of pneumonia by chest radiography was 18.0%. Ultrasonography had an overall sensitivity of 86% (95% CI, 71%-94%), specificity of 89% (95% CI, 83%-93%), positive LR of 7.8 (95% CI, 5.0-12.4), and negative LR of 0.2 (95% CI, 0.1-0.4) for diagnosing pneumonia by visualizing lung consolidation with sonographic air bronchograms. In subgroup analysis of 187 patients having lung consolidation exceeding 1 cm, ultrasonography had a sensitivity of 86% (95% CI, 71%-94%), specificity of 97% (95% CI, 93%-99%), positive LR of 28.2 (95% CI, 11.8-67.6) and negative LR of 0.1 (95% CI, 0.1-0.3) for diagnosing pneumonia.

**Conclusion:** Clinicians are able to diagnose pneumonia in children and young adults using point-of-care ultrasonography, with high specificity.

*JAMA Pediatr.* 2013;167(2):119-125.

Published online December 10, 2012.

doi:10.1001/2013.jamapediatrics.107


#### Author Affiliations:


Department of Emergency Medicine, Children's Hospital at Montefiore, Albert Einstein College of Medicine, Bronx, New York (Dr Shah); and Division of Pediatric Emergency Medicine, Departments of Pediatrics and Emergency Medicine, Bellevue Hospital Center, New York University School of Medicine (Dr Tunik), and Departments of Emergency Medicine and Pediatrics, Mount Sinai School of Medicine (Dr Tsung), New York, New York.

**P**NEUMONIA IS THE LEADING cause of death in children worldwide according to the World Health Organization.<sup>1</sup>

Infants and children having pneumonia may initially be seen with clinical symptoms and signs of fever, cough, and tachypnea. Although tachypnea is thought to be the best clinical predictor of pneumonia, other clinical examination findings,

pneumonia in children. However, the World Health Organization<sup>5</sup> has estimated that as many as three-quarters of the world's population do not have access to diagnostic imaging services. Reliance on clinical examination alone results in many children being treated with antibiotics who have only viral infections, contributing to the overuse of antibiotics and to bacterial antibiotic resistance.<sup>6,7</sup>

 CME available online at [www.jamanetworkcme.com](http://www.jamanetworkcme.com) and questions on page 106

 Journal Club slides available at [www.jamaped.com](http://www.jamaped.com)

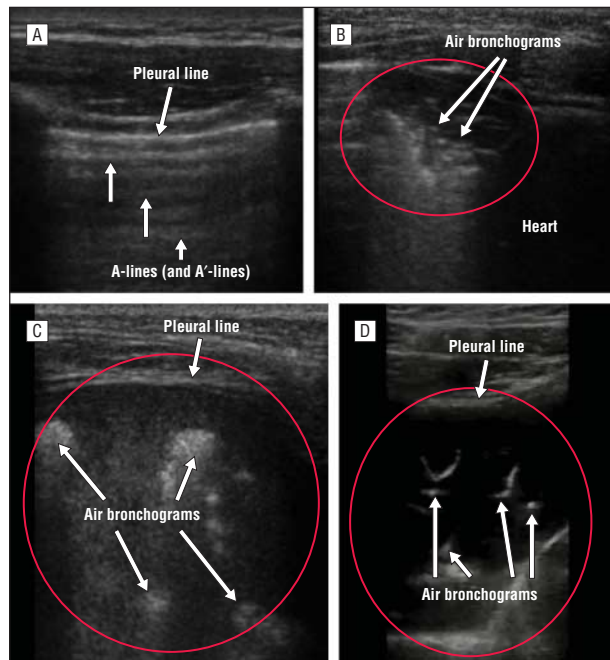
including those by auscultation, have proven to be unreliable.<sup>2-4</sup> Chest radiography is considered the test of choice for diagnosing pneu-

For editorial comment  
see page 187



Video available online at  
[www.jamaped.com](http://www.jamaped.com)

The initial description of ultrasonography to evaluate pneumonia by finding the sonographic air bronchograms within



**Figure 1.** Ultrasonography to evaluate pneumonia by finding the sonographic air bronchograms within lung consolidation in children. A, Normal sonographic appearance of aerated lung with horizontal A-lines (and A'-lines). B-D, Lung consolidation (red oval or circle) with sonographic air bronchograms (arrows).

lung consolidation in children (**Figure 1** and video [<http://www.jamapeds.com>]) was reported by Weinberg et al<sup>8</sup> in 1986. Because it was impractical to use as an initial diagnostic test if used at all, radiology department ultrasonography has been largely confined to a supplemental role in evaluating complex pneumonia.<sup>9</sup> Recent advances in technology have made portable or handheld ultrasonography machines more available.<sup>10</sup> Point-of-care ultrasonography use by clinicians of different medical specialties—beyond traditional users, such as cardiologists and obstetrician-gynecologists—has grown in the past decade.<sup>11,12</sup> Such use for evaluating pneumonia has been shown to be feasible and accurate with experienced clinician-sonologists.<sup>13-16</sup>

Our objective was to determine the accuracy of clinician-performed point-of-care ultrasonography for the diagnosis of pneumonia in children and young adults. We used chest radiography as a reference standard for the diagnosis of pneumonia in children and young adults seen in an acute care setting.

## METHODS

### STUDY DESIGN AND SETTING

This prospective observational study adhered to the Standards for Reporting of Diagnostic Accuracy criteria<sup>17</sup> for research involving diagnostic accuracy. The study was conducted from November 1, 2008, until May 31, 2010, at 2 affiliated academic urban emergency departments. The study was approved by our institutional review board. Our study population consisted of a convenience sample of patients who met predetermined inclusion criteria and in whom informed consent and patient assent in those 7 years or older had been obtained and docu-

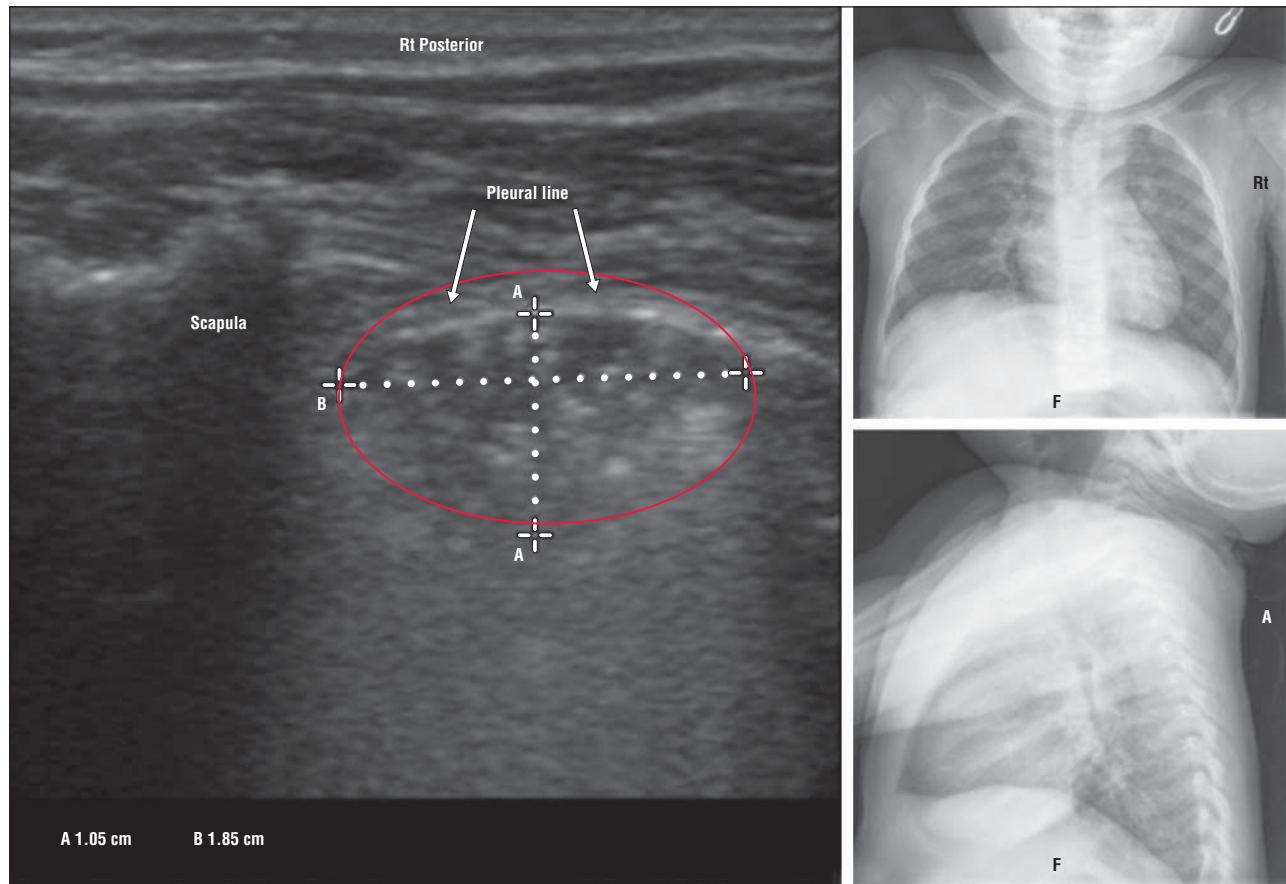
mented from the patient or a guardian for enrollment into the study.

Inclusion criteria were patients from birth to age 21 years seen in the emergency department with clinical suspicion of community-acquired pneumonia requiring chest radiography for evaluation. We excluded (1) patients who arrived in the emergency department with a chest radiograph, (2) patients who had a previously confirmed diagnosis of pneumonia by diagnostic imaging, and (3) patients who had hemodynamic instability.

Study sonologists (clinicians who perform and interpret ultrasonography) consisted of 15 pediatric emergency physicians with varying levels of emergency ultrasonography experience.<sup>18</sup> They underwent a 1-hour chest sonography training session given by one of us (J.W.T.) before the start of the study. The training consisted of a 30-minute lecture on lung ultrasonography and recognition of pathology and potential errors, followed by a 30-minute practical hands-on imaging session of normal models. During this training, sonologists were taught to identify the presence of pneumonia (lung consolidation with sonographic air bronchograms<sup>8</sup>), as well as viral pneumonia lung ultrasonography patterns (B-lines, confluent B-lines, or small subpleural consolidations),<sup>19,20</sup> pleural effusion (anechoic space between the lung and chest wall or diaphragm), atelectasis (lung consolidation without sonographic air bronchograms), and pneumothorax (absent lung sliding or lung point).<sup>21</sup>

### METHODS OF MEASUREMENT

Enrolled patients had a routine clinical examination performed in the emergency department by study sonologists. Abnormalities in auscultation were documented as crackles, rhonchi, decreased breath sounds, or wheezes on anterior, posterior, and lateral diagrams of the lung and preceded ultrasonography. Crackles or decreased breath sounds were defined as the diagnostic test findings used to classify pneumonia in patients by auscultation. The overall clinical impression and the pretest probability for pneumonia were also documented on a structured data sheet before ultrasonography. The patients then were classified as positive or negative for pneumonia based on the presence or absence of lung consolidation with sonographic air bronchograms<sup>8,13,14</sup> on ultrasonography (and the presence was noted of any other abnormal lung ultrasonography findings demonstrated in the training session already described) using a 6-zone lung ultrasonography imaging protocol (video and eFigure 1) similar to that described by Copetti and Cattarossi.<sup>13</sup> Lung consolidation on ultrasonography is visualized as a subpleural echopoor or tissuelike region with blurred margins or wedge-shaped borders. Sonographic air bronchograms are hyperechoic linear elements representing air in bronchioles that appear within the hypoechoic consolidated lung.<sup>8</sup> The reference standard for pneumonia was the attending pediatric radiologist's reading of the chest radiograph (posteroanterior and lateral views), reported as consolidation, infiltrate, or pneumonia, with negative and equivocal chest radiograph definitions similar to those in the study by Neuman et al.<sup>22</sup> Equivocal chest radiograph readings for pneumonia ("cannot exclude pneumonia" or "infiltrate vs atelectasis") by radiologists were defined as negative for pneumonia to avoid inflating test performance characteristics of ultrasonography relative to chest radiography. Results of clinical examination findings and point-of-care ultrasonography were compared with the reference standard to determine test performance characteristics. Study sonologists were blinded to chest radiography results when performing the auscultation and point-of-care ultrasonography. Radiologists were blinded to auscultation and ultrasonography results.



**Figure 2.** Lung consolidation of 1 cm or less with sonographic air bronchograms on ultrasonography not detected by chest radiography. F indicates frontal view; RT, right; and red oval, lung consolidation. A is caliper A measurement, and B is caliper B measurement.

## OUTCOME MEASURES

Clinical follow-up measures were obtained and documented on a structured data sheet by one of us (V.P.S.) after 2 weeks to determine the disposition and the clinical course of enrolled patients. Follow-up outcomes obtained included (1) clinical deterioration requiring treatment with antibiotics following discharge from the index emergency department visit, (2) the need for an unscheduled health care visit or hospitalization after the index emergency department visit, and (3) clinical improvement on an antibiotic regimen if prescribed.

To determine reasons for discrepancies between point-of-care ultrasonography and chest radiography, quality assurance monitoring was performed by a sonologist (J.W.T.) with more than 10 years of point-of-care ultrasonography experience. The investigators-sonologists (V.P.S. and J.W.T.) reviewed all ultrasonography images via digital movie clips to classify errors<sup>23</sup> made by study sonologists.

## DATA ANALYSIS

Demographic data are reported as frequencies, medians (interquartile ranges) for ordered nonnormal data and as means (SDs) for continuous normal data. Discrete and ordinal variables are described as counts and proportions. We calculated point-of-care ultrasonography and clinical examination test performance characteristics, including likelihood ratios (LRs) and sensitivity and specificity with 95% CIs. Based on pilot data to anticipate discrepancies between ultrasonography and chest radiography, we had observed that ultrasonography would identify lung consolidation of 1 cm or less with sonographic air bron-

chograms undetectable by chest radiography (**Figure 2**). Subcentimeter lung consolidation with sonographic air bronchograms was classified on ultrasonography image review. We performed a subgroup analysis with these cases excluded because they were classified as false-positives in the overall analysis. This was to account for the inability of chest radiography to detect subcentimeter lung consolidation with sonographic air bronchograms visualized on ultrasonography that would artifactually decrease the specificity of ultrasonography. To examine the effect of experience on accuracy, a subgroup analysis stratified by sonologists with more than 25 vs 25 or fewer lung ultrasonography examinations was performed. This cutoff was chosen because it is the minimum number of training examinations per application required for emergency ultrasonography credentialing based on the American College of Emergency Physicians' emergency ultrasonography guidelines.<sup>18</sup> Also calculated was the interobserver agreement (Cohen  $\kappa$ ) for the diagnosis of pneumonia between enrolling sonologists' interpretation and an investigator-sonologist (J.W.T.) reviewing obtained video blinded to clinical examination findings. Data analysis and test performance characteristics were calculated using commercially available software (SPSS version 16.0 for Windows; SPSS Inc).

## ULTRASONOGRAPHY TECHNIQUE

Ultrasonography machines with a linear array transducer at 7.5 to 10 MHz (Micromaxx; Sonosite and GS60; Siemens) were used to image the lungs in perpendicular planes (transverse, parasagittal, and coronal) in the midclavicular line anteriorly and posteriorly on the chest and in the midaxillary line



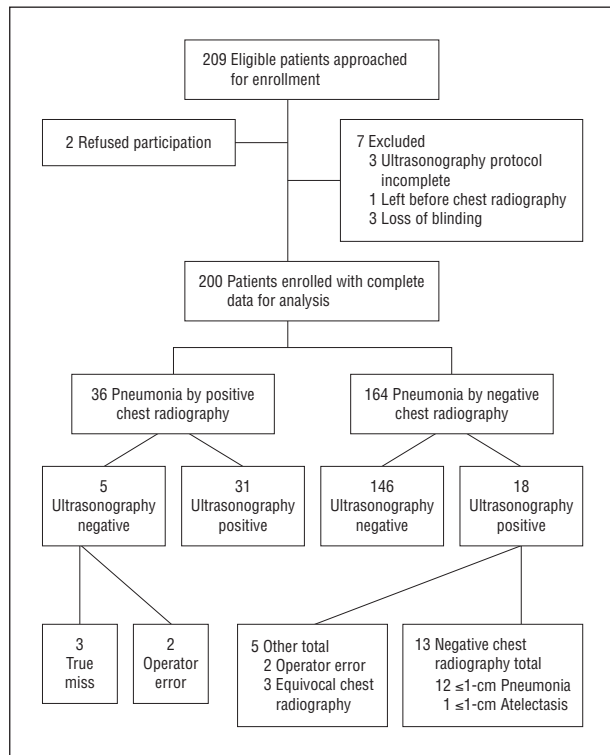


Figure 3. Standards for Reporting of Diagnostic Accuracy<sup>17</sup> flowchart.

from the axillae to the diaphragm (eFigure 1). The duration of ultrasonography was determined by time-stamped video recordings.

## RESULTS

Two hundred nine patients were approached for enrollment, and 200 (56.0% male; median [interquartile range] age, 3 [1-8] years) were enrolled into the study (Figure 3), with alveolar infiltrate present by chest radiography in 36 (18.0%). Seventy-three percent of patients had a history of fever (68.4%) or fever in triage (51.0%) exceeding 38.1°C; 81.8% had a cough, and 26.0% had a history of World Health Organization—defined tachypnea at ED triage. Fifteen of 36 patients (41.7%) with alveolar infiltrate on chest radiography required admission to the hospital. Thirteen of 200 enrolled patients (6.5%) had chest radiograph–negative lung consolidation of 1 cm or less detected on ultrasonography; 3 of these 13 patients required admission to the hospital for pneumonia.

Forty-nine of 200 patients (24.5%) were identified as having pneumonia by ultrasonography, with 36 of the lung consolidations exceeding 1 cm. This yielded an overall sensitivity of 86% (95% CI, 71%-94%) and specificity of 89% (95% CI, 83%-93%) for any positive ultrasonography finding and a sensitivity of 86% (95% CI, 71%-94%) and specificity of 97% (95% CI, 93%-99%) for lung consolidation with sonographic air bronchograms exceeding 1 cm only. Test performance characteristics for clinical examination findings are given in Table 1. The mean (SD) ultrasonography examination time was 7 (2) minutes. Among 122 ultrasonography examinations pre-

formed by sonologists with less experience ( $\leq 25$  ultrasonography examinations), the mean (SD) examination time was 8 (3) minutes; among 78 ultrasonography examinations performed by sonologists with more experience ( $> 25$  ultrasonography examinations), the mean (SD) examination time was 7 (2) minutes.

Follow-up measures, obtained 2 to 3 weeks after discharge, were completed in 187 patients (93.5%). Clinical follow-up data and outcomes are shown in eFigure 2.

The interobserver agreement was excellent between the enrolling sonologist's interpretation and the blinded reviewing sonologist's interpretation for lung consolidation with sonographic air bronchograms on ultrasonography video image review. Cohen  $\kappa$  was 0.93 (95% CI, 0.87-0.99).

Our 15 sonologists enrolled a median of 4 patients (interquartile range, 1-17 patients) in the study and a mean (SD) of 13.7 (21.7) patients (range, 1-84 patients enrolled). The effect of sonologist experience on test performance characteristics of ultrasonography is summarized in Table 1. The point estimates for sonologist sensitivity increased with more experience relative to specificity but was not statistically significant (the 95% CIs were overlapping).

Discordant results between ultrasonography and chest radiography are shown at the bottom of Figure 3. There were 18 ultrasonography-positive and chest radiography–negative discordant results; 13 of these were chest radiography–negative lung consolidations of 1 cm or less (Figure 2). Twelve of 13 chest radiography–negative lung consolidations of 1 cm or less with sonographic air bronchograms detected by ultrasonography were confirmed by blinded quality assurance review and were consistent with the clinical course of pneumonia (eFigure 2). These cases were treated with antibiotics, resulting in subsequent improvement of symptoms.

Of the remaining 5 ultrasonography-positive and chest radiography–negative results, 3 were equivocal chest radiography readings (Table 2),<sup>24-26</sup> defined as negative for pneumonia (counted against ultrasonography) to avoid inflating test performance characteristics of ultrasonography relative to chest radiography. The remaining 2 ultrasonography-positive and chest radiography–negative results were due to sonologist interpretation error at the left lower chest, misreading the combination of spleen and air in the stomach as lung consolidation with sonographic air bronchograms (eFigure 3).

Of 5 ultrasonography-negative and chest radiography–positive discordant results, 2 were missed lung consolidations with sonographic air bronchograms detected on video review (both  $> 1$  cm) due to operator error and the remaining 3 discordant results were true misses by ultrasonography, with no evidence of lung consolidation on review of recorded ultrasonography video. Pleural effusions were found in 7 of 200 patients (3.5%) by point-of-care ultrasonography and in 3 patients (1.5%) by chest radiography.

## COMMENT

We demonstrated that clinician-sonologists were able to quickly (mean ultrasonography examination time, 7 min-

**Table 1. Test Performance Characteristics Using Chest Radiography as a Reference Standard Among 200 Patients**

Variable	LR (95% CI)		% (95% CI)	
	Positive	Negative	Sensitivity	Specificity
Point-of-care ultrasonography (n = 200)	7.8 (5.0-12.4)	0.16 (0.07-0.35)	86 (71-94)	89 (83-93)
Subgroup with point-of-care ultrasonography >1-cm lung consolidation (n = 187) <sup>a</sup>	28.2 (11.8-67.6)	0.14 (0.06-0.32)	86 (71-94)	97 (93-99)
<b>Clinical Examination</b>				
Overall clinical impression (n = 200)	1.4 (1.1-1.7)	0.41 (0.19-0.88)	84 (69-92)	39 (32-57)
Tachypnea (n = 200)	1.7 (1.0-2.7)	0.79 (0.60-1.04)	41 (26-57)	76 (68-81)
Decreased breath sounds only (n = 200)	1.5 (0.8-2.9)	0.91 (0.75-1.1)	24 (13-40)	83 (77-88)
Crackles only (n = 200)	1.0 (0.5-1.9)	1.0 (0.82-1.23)	24 (13-40)	75 (68-81)
<b>Overall Results Stratified by Clinician-Sonologist Experience (n = 200)<sup>b</sup></b>				
Clinician-sonologist with ≤25 ultrasonography examinations (n = 131)	6.9 (4.0-11.8)	0.20 (0.08-0.48)	83 (63-93)	88 (81-93)
Clinician-sonologist with >25 ultrasonography examinations (n = 69)	10.3 (4.4-24.2)	0.08 (0.01-0.56)	92 (67-99)	91 (81-96)
<b>Subgroup Results Stratified by Clinician-Sonologist Experience<sup>c</sup></b>				
Clinician-sonologist with ≤25 ultrasonography examinations (n = 122)	23.1 (8.6-61.7)	0.18 (0.07-0.44)	83 (63-93)	96 (91-99)
Clinician-sonologist with >25 ultrasonography examinations (n = 65)	51.7 (7.3-363.0)	0.08 (0.12-0.52)	92 (67-99)	98 (90-100)

Abbreviation: LR, likelihood ratio.

<sup>a</sup>Subgroup with lung consolidation of 1 cm or less detected on point-of-care ultrasonography excluded.

<sup>b</sup>Including lung consolidation of 1 cm or less, ultrasonography positive, and chest radiography negative.

<sup>c</sup>Lung consolidation exceeding 1 cm detected by point-of-care ultrasonography, ultrasonography positive, and chest radiography positive only.

**Table 2. Agreement Between Ultrasonography and Chest Radiography Among 200 Patients Undergoing Chest Radiography for Suspected Community-Acquired Pneumonia**

Variable	No. of Patients		
	Chest Radiography Positive (n = 36)	Chest Radiography Equivocal (n = 3)	Chest Radiography Negative (n = 161)
Ultrasonography positive (n = 36)	31	3 <sup>a</sup>	2
Ultrasonography positive ≤1 cm (n = 13)	0	0	13 <sup>b</sup>
Ultrasonography negative (n = 151)	5	0	146

<sup>a</sup>Lung consolidations with sonographic air bronchograms were found measuring between 1.5 and 1.8 cm at the detection limit of chest radiography.<sup>24-26</sup>

<sup>b</sup>One of 13 patients had lung consolidation of 1 cm or less without sonographic air bronchograms, indicating consolidation from atelectasis as opposed to pneumonia. Twelve of 13 patients had lung consolidation of 1 cm or less with sonographic air bronchograms, consistent with pneumonia.

utes) and accurately identify pneumonia in children and young adults. Our prevalence rate of pneumonia (18.0%) is within the range of that reported in published literature (14%-35%).<sup>2,3,27,28</sup> Our test performance characteristics for World Health Organization–defined tachypnea and auscultation (Table 1) are similar to other published data regarding clinical examination findings for pneumonia.<sup>3-5,27-29</sup> Based on our data, ultrasonography is more specific (accurate ruling in) than sensitive (accurate ruling out) for pneumonia and is more accurate than overall clinical impression, auscultation, and World Health Organization–defined tachypnea.

Previous investigators have reported on the accuracy of point-of-care ultrasonography for pneumonia by single expert sonologists. Unlike prior research, we used multiple operators with varied ultrasonography experience to evaluate diagnostic accuracy. Copetti and Cattarossi<sup>13</sup> observed that ultrasonography was positive for lung consolidation more often than posteroanterior chest radiography in 79 children with suspected pneumonia seen in an emergency department. Ultrasonography was positive for lung consolidation in 60 of 60 children with confirmed pneumonia, whereas 1-view posteroanterior chest radiographs were positive in 53 of 60 children. Seven children with ultrasonography-positive and chest radiography–negative findings were subsequently confirmed to have pneumonia by computed tomography (CT) or by clinical course and follow-up examination. No children in their study had ultrasonography-negative and chest radiography–positive results (false-negative errors). In a study at the same institution, Parlamento et al<sup>15</sup> reported on point-of-care ultrasonography diagnosis for pneumonia in 49 adults and found similar results.

We speculate that ultrasonography-positive and chest radiography–negative discordant results in these studies were possibly due to radiographically negative small lung consolidations detected on point-of-care ultrasonography, such as were observed in our study. The mean size of missed solitary pulmonary nodules from lung cancer in adults on chest radiography is 1.6 to 1.8 cm (actual range, 0.4-5.5 cm).<sup>24-26</sup> In our study, 3 chest radiography readings were equivocal for pneumonia and, on ultrasonography image review, lung consolidations with sonographic air bronchograms measuring between 1.5 to 1.8 cm were found (Table 2). This observation supports a limit near 1.5 cm for the detection of lung con-

solidation by chest radiography. The finding that chest radiography will miss small pneumonia should be expected and is supported by our observations. In our study, 13 lung consolidations of 1 cm or less detected by ultrasonography were found to be negative on chest radiography. Twelve of 13 contained sonographic air bronchograms, indicating pneumonia as opposed to atelectasis.<sup>8,30</sup> The only chest radiography–negative lung consolidation of 1 cm or less without sonographic air bronchograms detected on ultrasonography in our study had a clinical course consistent with atelectasis and improved without antibiotic treatment.

Using CT as a reference standard among 117 adult patients in the intensive care unit, Lichtenstein et al<sup>14</sup> reported a positive LR of 47, a negative LR of 0.04, 91% sensitivity, and 98% specificity for point-of-care ultrasonography diagnosis of pneumonia. That study included 6 ultrasonography–negative and CT–positive patients. Five were missed because of the posterior location of the pneumonia and because the institution's adult intensive care unit ultrasonography protocol omits imaging of the posterior thorax (anterior, anterolateral, and posterolateral only). The remaining pneumonia (1.5% of pneumonia cases in the study) was undetectable by ultrasonography and was located posteriorly on CT but did not reach the pleural surface. The only ultrasonography–positive and CT–negative result in their study was a very small lung consolidation with an estimated volume of less than 2 mL visualized on ultrasonography.

Studies<sup>31,32</sup> of lung ultrasonography have shown that clinicians with ultrasonography training (10–30 minutes) can rapidly (in <2 to 5 minutes) and accurately identify pulmonary pathology using point-of-care ultrasonography. With 1 hour of focused training in a standardized imaging protocol, our sonologists achieved a mean ultrasonography examination time of 7 minutes, consistent with other published data.<sup>31,32</sup> In comparing novice sonologists with sonologists who have performed more than 25 lung ultrasonography examinations, we observed no statistically significant difference in accuracy (Table 1). Although our 95% CIs were large, the intervals for positive and negative LRs for novice and experienced sonologists did not cross 1 and significantly change pretest probability.

Ultrasonography of the left lower chest can be problematic, with the combination of spleen and air in the stomach being mistaken for lung consolidation and sonographic air bronchograms. This error occurred twice in our study and can be avoided by paying attention to the location of the diaphragm or the transition of the end of the pleural line to the spleen (eFigure 3). In addition, the sonographic appearance of the thymus (eFigure 4) can also be mistaken for lung consolidation. No errors were made in mistaking the thymus for lung consolidation. Recognition of these potential pitfalls was included in our 30-minute training session.

Although tachypnea may be the most predictive in ruling in or ruling out pneumonia, systematic reviews<sup>4,27</sup> on the subject indicate that no clinical examination finding alone is sufficiently powerful to predict the presence or absence of pneumonia. Point-of-care ultrasonography may prove to be a powerful diagnostic tool to complement the

physical examination. Compared with adults, children and infants have thinner chest walls and smaller lung mass, which make them ideal to image by point-of-care ultrasonography. The advantage of ultrasonography over other imaging modalities is that it can be performed at the point of care, without exposing children to the greater cancer risks of ionizing radiation relative to adults.<sup>33</sup> It is feasible and less costly to implement ultrasonography in remote regions<sup>34,35</sup> or underserved areas and developing countries<sup>36–39</sup> compared with radiography.<sup>37–39</sup> These features and the high accuracy rate demonstrated in this and other studies<sup>13–15</sup> make ultrasonography a promising alternative that has the potential to rapidly diagnose pneumonia at the point of care and to improve outcomes.

Our study has several limitations. Despite our not optimizing or standardizing the reference standard interpretations of chest radiography, the number of equivocal chest radiographs was unexpectedly low. This may have been because of the high experience level of our attending pediatric radiologists. However, chest radiography is an imperfect reference standard but is still a practical and standard diagnostic test for pneumonia. Computed tomography of the chest would be a more accurate reference standard, particularly for very small lung consolidation, as well as for pleural effusions that were detected by ultrasonography but not by chest radiography. Furthermore, CT would allow identification of centrally located pneumonia that did not reach the pleural surface and may be undetectable by ultrasonography,<sup>14</sup> which may be a possible explanation for the 3 true misses (Figure 2) by ultrasonography in our study, as well as allow direct comparison of point-of-care ultrasonography with chest radiography. Based on the data by Lichtenstein et al<sup>14</sup> using CT, 98.5% of pneumonia cases have a pleural component in adults. Although it is taught that pneumonia in children is typically peripheral, published data are lacking on the frequency of pneumonia without pleural involvement in children. Obtaining chest CT in all enrolled children and young adults in our study was not practical and is not our standard of care.

In summary, clinicians with variable ultrasonography experience can diagnose pneumonia in children and young adults using point-of-care ultrasonography. The specificity of ultrasonographic findings obtained in this manner is high.

**Accepted for Publication:** June 21, 2012.

**Published Online:** December 10, 2012. doi:10.1001/2013.jamapediatrics.107

**Correspondence:** James W. Tsung, MD, MPH, Department of Emergency Medicine, Mount Sinai School of Medicine, One Gustave Levy Place, New York, NY 10029 (jtsung@gmail.com).

**Author Contributions:** *Acquisition of data:* Shah and Tsung. *Analysis and interpretation of data:* Shah, Tunik, and Tsung. *Drafting of the manuscript:* Shah, Tunik, and Tsung. *Critical revision of the manuscript for important intellectual content:* Shah and Tsung. *Statistical analysis:* Shah, Tunik, and Tsung. *Study supervision:* Tunik and Tsung.

**Conflict of Interest Disclosures:** None reported.

**Previous Presentations:** This study was presented at the 2010 Society for Academic Emergency Medicine An-

nual Meeting; June 5, 2010; Phoenix, Arizona; and at the 2010 Pediatric Academic Societies Annual Meeting; May 2, 2010; Vancouver, British Columbia, Canada.

**Online-Only Material:** The video and eFigures are available at <http://www.jamapeds.com>. This article is featured in the *JAMA Pediatrics* Journal Club. Go to <http://www.jamapeds.com> to download teaching PowerPoint slides.

**Additional Contributions:** The following sonologists recruited patients and enrolled them into the study: Marc Auerbach, MD; Lili Banan, MD; Sarah Case, MD; Carrie Danziger, MD; Jeffrey Fine, MD; Dennis Heon, MD; David O. Kessler, MD; George Kristinsson, MD; Rachel Kowalsky, MD; Deborah Levine, MD; Adriana Manikian, MD; Michael Mojica, MD; and Ee T. Tay, MD. Raeshem Nijhon, Deepak Penesetti, MD, and Anh Nguyen, MD, MBA, assisted with production of the video.

## REFERENCES

1. World Health Organization. *World Report on Child Injury Prevention*. Geneva, Switzerland: World Health Organization; 2008.
2. Shah S, Bachur R, Kim D, Neuman MI. Lack of predictive value of tachypnea in the diagnosis of pneumonia in children. *Pediatr Infect Dis J*. 2010;29(5):406-409.
3. Leventhal JM. Clinical predictors of pneumonia as a guide to ordering chest roentgenograms. *Clin Pediatr (Phila)*. 1982;21(12):730-734.
4. Margolis P, Gadomski A. The rational clinical examination. Does this infant have pneumonia? *JAMA*. 1998;279(4):308-313.
5. World Health Organization Essential health technologies: strategy 2004-2007. [http://www.who.int/eht/en/EHT\\_strategy\\_2004-2007.pdf](http://www.who.int/eht/en/EHT_strategy_2004-2007.pdf). Accessed September 19, 2012.
6. Kallen AJ, Brunkard J, Moore Z, et al. *Staphylococcus aureus* community-acquired pneumonia during the 2006 to 2007 influenza season. *Ann Emerg Med*. 2009;53(3):358-365.
7. Moran GJ, Talan DA. MRSA community-acquired pneumonia: should we be worried? *Ann Emerg Med*. 2009;53(3):366-368.
8. Weinberg B, Diakoumakis EE, Kass EG, Seife B, Zvi ZB. The air bronchogram: sonographic demonstration. *AJR Am J Roentgenol*. 1986;147(3):593-595.
9. Kurian J, Levin TL, Han BK, Taragin BH, Weinstein S. Comparison of ultrasound and CT in the evaluation of pneumonia complicated by parapneumonic effusion in children. *AJR Am J Roentgenol*. 2009;193(6):1648-1654.
10. Ishrak TO. Ultrasound: a revolution in the making. *Crit Ultrasound J*. 2009;1(1):27-32.
11. Moore CL, Copel JA. Point-of-care ultrasonography. *N Engl J Med*. 2011;364(8):749-757.
12. Levy JA, Noble VE. Bedside ultrasound in pediatric emergency medicine. *Pediatrics*. 2008;121(5):e1404-e1412. <http://pediatrics.aappublications.org/content/121/5/e1404.long>. Accessed September 19, 2012.
13. Copetti R, Cattarossi L. Ultrasound diagnosis of pneumonia in children. *Radiol Med*. 2008;113(2):190-198.
14. Lichtenstein DA, Lascols N, Mezière G, Gepner A. Ultrasound diagnosis of alveolar consolidation in the critically ill. *Intensive Care Med*. 2004;30(2):276-281.
15. Parlamento S, Copetti R, Di Bartolomeo S. Evaluation of lung ultrasound for the diagnosis of pneumonia in the ED. *Am J Emerg Med*. 2009;27(4):379-384.
16. Volpicelli G, Elbarbary M, Blaivas M, et al; International Liaison Committee on Lung Ultrasound (ILC-LUS) for International Consensus Conference on Lung Ultrasound (ICC-LUS). International evidence-based recommendations for point-of-care lung ultrasound. *Intensive Care Med*. 2012;38(4):577-591.
17. Bossuyt PM, Reitsma JB, Bruns DE, et al; Standards for Reporting of Diagnostic Accuracy. Towards complete and accurate reporting of studies of diagnostic accuracy: the STARD Initiative. *Ann Intern Med*. 2003;138(1):40-44.
18. American College of Emergency Physicians. Emergency ultrasound guidelines. *Ann Emerg Med*. 2009;53(4):550-570.
19. Caiulo VA, Gargani L, Caiulo S, et al. Lung ultrasound in bronchiolitis: comparison with chest X-ray. *Eur J Pediatr*. 2011;170(11):1427-1433.
20. Tsung JW, Kessler DO, Shah VP. Prospective application of clinician-performed lung ultrasonography during the 2009 H1N1 influenza A pandemic: distinguishing viral from bacterial pneumonia. *Crit Ultrasound J*. 2012;4(1):16.
21. Lichtenstein DA. Ultrasound in the management of thoracic disease. *Crit Care Med*. 2007;35(5)(suppl):S250-S261.
22. Neuman MI, Monuteaux MC, Scully KJ, Bachur RG. Prediction of pneumonia in a pediatric emergency department. *Pediatrics*. 2011;128(2):246-253.
23. Newman-Toker DE, Pronovost PJ. Diagnostic errors—the next frontier for patient safety. *JAMA*. 2009;301(10):1060-1062.
24. White CS, Flukinger T, Jeudy J, Chen JJ. Use of a computer-aided detection system to detect missed lung cancer at chest radiography. *Radiology*. 2009;252(1):273-281.
25. White CS, Salis AI, Meyer CA. Missed lung cancer on chest radiography and computed tomography: imaging and medicolegal issues. *J Thorac Imaging*. 1999;14(1):63-68.
26. Wu MH, Gotway MB, Lee TJ, et al. Features of non-small cell lung carcinomas overlooked at digital chest radiography. *Clin Radiol*. 2008;63(5):518-528.
27. Ostrovsky D. Update: pneumonia, infant and child. In: Simel DL, Rennie D, Keitz S, eds. *The Rational Clinical Examination: Evidence-Based Clinical Diagnosis*. New York, NY: McGraw Hill Publishing; 2009:447-450.
28. Zukin DD, Hoffman JR, Cleveland RH, Kushner DC, Herman TE. Correlation of pulmonary signs and symptoms with chest radiographs in the pediatric age group. *Ann Emerg Med*. 1986;15(7):792-796.
29. World Health Organization. *Technical Updates of the Guidelines on the Integrated Management of Childhood Illness (IMCI): Evidence and Recommendations for Further Adaptations*. Geneva, Switzerland: Dept of Child and Adolescent Health and Development, World Health Organization; 2005.
30. Lichtenstein D, Mezière G, Seitz J. The dynamic air bronchogram: a lung ultrasound sign of alveolar consolidation ruling out atelectasis. *Chest*. 2009;135(6):1421-1425.
31. Bedetti G, Gargani L, Corbisiero A, Frassi F, Poggianti E, Mottola G. Evaluation of ultrasound lung comets by hand-held echocardiography. *Cardiovasc Ultrasound*. 2006;4:34. <http://www.ncbi.nlm.nih.gov/pmc/articles/PMC1569440/>. Accessed September 19, 2012.
32. Monti JD, Younggren B, Blankenship R. Ultrasound detection of pneumothorax with minimally trained sonographers: a preliminary study. *J Spec Oper Med*. 2009;9(1):43-46.
33. Hall EJ, Brenner DJ. Cancer risks from diagnostic radiology. *Br J Radiol*. 2008;81(965):362-378.
34. Fagenholz PJ, Gutman JA, Murray AF, Noble VE, Thomas SH, Harris NS. Chest ultrasonography for the diagnosis and monitoring of high-altitude pulmonary edema. *Chest*. 2007;131(4):1013-1018.
35. Sargsyan AE, Hamilton DR, Jones JA, et al. FAST at MACH 20: clinical ultrasound aboard the International Space Station. *J Trauma*. 2005;58(1):35-39.
36. Spencer JK, Adler RS. Utility of portable ultrasound in a community in Ghana. *J Ultrasound Med*. 2008;27(12):1735-1743.
37. Ma OJ, Norvell JG, Subramanian S. Ultrasound applications in mass casualties and extreme environments. *Crit Care Med*. 2007;35(5)(Suppl):S275-S279.
38. Mercado-Young R, Martin DS, Caine T, et al. Virtual guidance: a new technique to empower point-of-care ultrasound in remote or extreme environments. *Crit Ultrasound J*. 2010;2(1):19-24.
39. McBeth PB, Hamilton T, Kirkpatrick AW. Cost-effective remote iPhone-teathered telemonitored trauma telesonography. *J Trauma*. 2010;69(6):1597-1599.