

American Journal of Sports Medicine

<http://ajs.sagepub.com>

Prospective Evaluation of Prolonged Fresh Osteochondral Allograft Transplantation of the Femoral Condyle: Minimum 2-Year Follow-Up

Patrick C. McCulloch, Richard W. Kang, Mohamed H. Sobhy, Jennifer K. Hayden and Brian J. Cole
Am. J. Sports Med. 2007; 35; 411 originally published online Jan 29, 2007;
DOI: 10.1177/0363546506295178

The online version of this article can be found at:
<http://ajs.sagepub.com/cgi/content/abstract/35/3/411>

Published by:

 SAGE Publications

<http://www.sagepublications.com>

On behalf of:



[American Orthopaedic Society for Sports Medicine](#)

Additional services and information for *American Journal of Sports Medicine* can be found at:

Email Alerts: <http://ajs.sagepub.com/cgi/alerts>

Subscriptions: <http://ajs.sagepub.com/subscriptions>

Reprints: <http://www.sagepub.com/journalsReprints.nav>

Permissions: <http://www.sagepub.com/journalsPermissions.nav>

Citations (this article cites 47 articles hosted on the SAGE Journals Online and HighWire Press platforms):
<http://ajs.sagepub.com/cgi/content/abstract/35/3/411#BIBL>

Prospective Evaluation of Prolonged Fresh Osteochondral Allograft Transplantation of the Femoral Condyle

Minimum 2-Year Follow-Up

Patrick C. McCulloch,* MD, Richard W. Kang,[†] Mohamed H. Sobhy,[‡] MD, Jennifer K. Hayden,[§] MS, and Brian J. Cole,^{†§||} MD, MBA

From the *Department of Orthopedics, Baylor College of Medicine, Houston, Texas,

[†]Department of Anatomy & Cell Biology and [§]Department of Orthopedics, Rush University Medical Center, Chicago, Illinois; and [‡]Cairo, Egypt

Background: Focal articular cartilage lesions of the knee in young patients present a therapeutic challenge. Little information is available pertaining to the results after implantation of prolonged fresh grafts.

Hypothesis: Prolonged fresh osteochondral allografts present a viable option for treating large full-thickness articular cartilage lesions.

Study Design: Case series; Level of evidence, 4.

Methods: This study presents the results of 25 consecutive patients who underwent prolonged fresh osteochondral allograft transplantation for defects in the femoral condyle. The average patient age was 35 years (range, 17-49 years). The average length of follow-up was 35 months (range, 24-67 months). Prospective data were collected using several subjective scoring systems, as well as objective and radiographic assessments.

Results: Statistically significant improvements ($P < .05$) were seen for the Lysholm (39 to 67), International Knee Documentation Committee scores (29 to 58), all 5 components of the Knee injury and Osteoarthritis Outcome Score (Pain, 43 to 73; Other Disease-Specific Symptoms, 46 to 64; Activities of Daily Living Function, 56 to 83; Sport and Recreation Function, 18 to 46; Knee-Related Quality of Life, 22 to 50), and the Short Form-12 physical component score (36 to 40). Overall, patients reported 84% (range, 25% to 100%) satisfaction with their results and believed that the knee functioned at 79% (range, 35% to 100%) of their unaffected knee. Radiographically, 22 of the grafts (88%) were incorporated into host bone.

Conclusion: Fresh osteochondral allograft transplantation is an acceptable intermediate procedure for treatment of localized osteochondral defects of the femur. At 2-year follow-up, it is well incorporated and offered consistent improvements in pain and function.

Clinical Relevance: Prolonged fresh allograft transplantation is a safe and effective technique for addressing symptomatic osteoarticular lesions in the knees of young patients.

Keywords: osteochondral allograft; prolonged fresh; clinical outcomes; femoral condyle

Localized articular cartilage lesions of the knee are relatively common but rarely require initial treatment.^{11,23,35,53} They may become symptomatic, with patients experiencing

pain, swelling, and mechanical symptoms. These lesions have limited ability to heal and may progress to osteoarthritis.^{5,36,37-39,41} This presents an especially difficult clinical problem in young, high-demand patients. Arthroplasty is considered only under exceptional circumstances, because revision is a nearly certain outcome at some predictable time frame because of loosening and implant failure. An unloading osteotomy alone may reduce the symptoms, but the patient is still left with the osteochondral defect along with biological symptoms of swelling and barometric pain, the potential for ligamentous redundancy, and possibly accelerated wear of the opposite compartment.^{27,40} This has led surgeons to pursue more biological solutions to restore damaged cartilage and underlying bone.

^{||}Address correspondence to Brian J. Cole, MD, MBA, Section Head, Cartilage Restoration Center at Rush, Departments of Orthopedics and Anatomy & Cell Biology, Rush University Medical Center, 1725 W. Harrison St, POB Ste 1063, Chicago, IL 60612 (e-mail: bcole@rushortho.com).

Presented at the interim meeting of the AOSSM, Chicago, Illinois, March 2007.

No potential conflict of interest declared.

Microfracture, mosaicplasty, and autologous chondrocyte implantation are all useful techniques, of which each has its own limitations.^{3,18,31} The marrow stimulation procedures such as microfracture, drilling, and abrasion chondroplasty all resurface the defects with fibrocartilage rather than true articular hyaline cartilage. Although excellent early-term results have been reported,⁵⁴ the durability of this hyaline-like repair tissue remains questionable.²⁶ Mosaicplasty performed with autologous osteochondral plugs is an excellent alternative for smaller defects, but its use is limited by the amount of available nonarticulating cartilage and concerns about donor site morbidity.^{13,17,21,28,33,59} Autologous chondrocyte implantation may have results comparable with those of mosaicplasty^{24,29,50}; however, it is less able to restore a significant underlying bony defect and remains expensive and technically difficult.^{8,30,31} Biphasic grafts, hyaluronan and polyester-based scaffolds, biochemically treated mesenchymal progenitor cells, and the tissue engineered osteochondral substitutes, although quite promising, are considered investigational.^{1,7,14,22,25,34,44-46,49,51,52,55,57,58}

Osteochondral allograft transplantation (OCA) is appealing because it provides the ability to resurface larger and deeper defects with mature hyaline articular cartilage and addresses the underlying bone deficit in a single procedure. The appropriate size and surface contour can be matched when the graft is obtained from an appropriately selected organ donor. The biology of articular cartilage makes it ideal for transplantation. It is both aneural and relatively avascular, receiving its nutrition by diffusion from synovial fluid. Furthermore, it is a relatively immunoprivileged tissue.³² The chondrocytes are protected from the host immune surveillance by the surrounding matrix. Therefore, this allows mature living chondrocytes to survive for many years after transplantation without the need for tissue matching or immunosuppression.^{10,12}

In the 1970s, musculoskeletal tumor surgeons began using frozen osteochondral allografts for reconstruction.^{39,56} The freezing process decreased immunogenicity and prolonged storage times, but at the expense of chondrocyte viability. These are best considered biological implants, rather than transplants, because the cells are not alive. Therefore, surgeons seeking to restore focal articular defects with living chondrocytes have sought to use fresh allografts traditionally implanted within 1 week. Recent safety concerns have resulted in strict guidelines for serologic and bacteriologic testing before implantation. This process often takes a minimum of 14 days before the graft is released for use. In the interim, the grafts are harvested and are typically maintained refrigerated in dimethyl sulfoxide at 4°C. This allows for storage of the grafts for up to 42 days, or so-called "prolonged fresh" grafts.^{15,63} These grafts have been shown to have minimal immune response, preserved chondrocyte viability, and enhanced revascularization of the bone.^{47,61} Furthermore, this improves the safety of these grafts by allowing more time for bacteriologic and DNA polymerase chain reaction (PCR) screening.

Limited data are available, however, on the clinical results after prolonged fresh OCA transplantation of the knee. The purpose of this study is to report prospective results after fresh OCA transplantation at a minimum follow-up of 2 years.

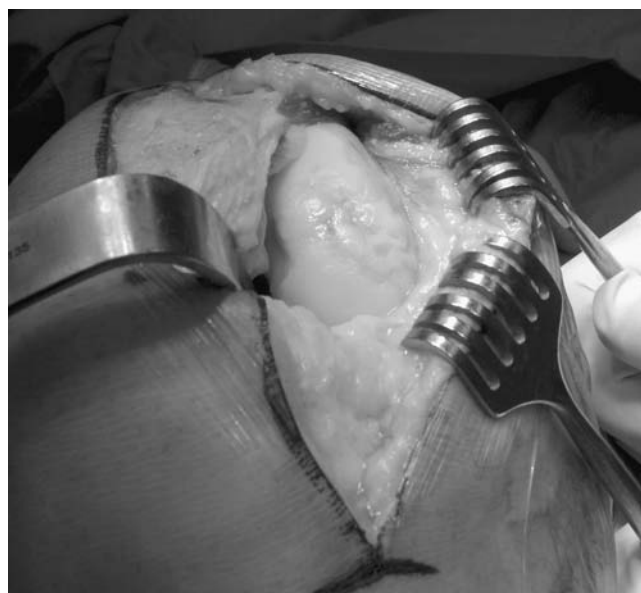


Figure 1. Arthroscopy to expose the defect of the femoral condyle.

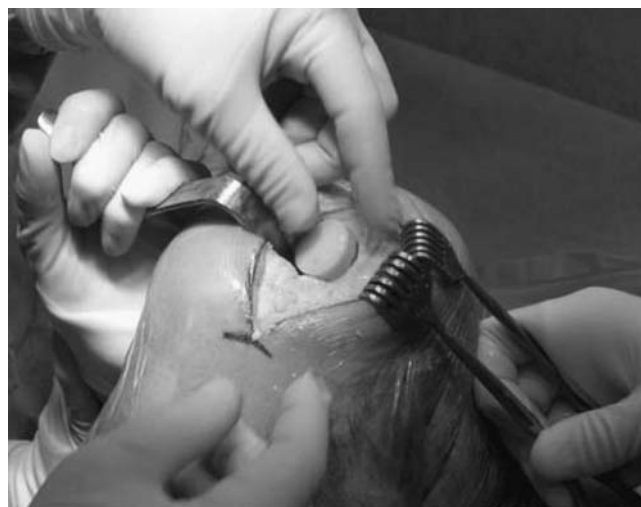

Figure 2. Press-fitting the osteochondral allograft into the recipient hole.

MATERIALS AND METHODS

Patient Selection

The study was approved by the Institutional Review Board at our institution, and all patients signed informed consent to participate. Between March 2000 and November 2003, 25 consecutive patients (25 knees) who received prolonged fresh osteochondral allografts to repair articular cartilage defects in the femoral condyle were enrolled into our prospective database. The main indication for allograft resurfacing was the presence of a symptomatic full-thickness cartilage defect of at least 2 cm². The lesion size was assessed radiographi-

TABLE 1
Causes of Injury Leading to Osteochondral Allograft Procedure

Injury Type	Number
Degenerative	9
Traumatic	8
Osteochondritis dissecans	6
Osteonecrosis	2

TABLE 2
Count of Previous and Concomitant Procedures^a

Previous Procedures	Concomitant Procedures
18 Meniscectomy	10 Meniscus transplantation
11 Microfracture	4 High tibial osteotomy
6 ACL reconstruction	1 Removal of hardware
5 Debridement/synovectomy	
4 Loose body removal	
3 Incision and drainage ^b	
2 ACI	
2 Lateral release	
2 High tibial osteotomy	
2 Manipulation ^b	
1 Bony fixation	
1 OCD fixation	
1 Realignment osteotomy	
1 Osteochondral allograft	
1 Thermal chondroplasty	

^aACL, anterior cruciate ligament; ACI, autologous chondrocyte implantation; OCD, osteochondritis dissecans.

^bDenotes a single patient who had 3 incision and drainage and 2 manipulation procedures.

cally and confirmed via diagnostic arthroscopy performed before allograft transplantation by either the referring physician or the senior author in an effort to appropriately indicate the patient for cartilage treatment by defining all relevant intra-articular pathologic changes.

Graft Selection

The grafts were procured from healthy donors according to the American Association of Tissue Banks standards. Three graft sources were used: AlloSource (Denver, Colo), CryoLife Incorporated (Kennesaw, Ga), and Regeneration Technologies Incorporated (Alachua, Fla). After size matching, the knees were harvested within 24 hours of death and stored in Ringer's lactate with 1 g cefazolin and 10 mg/L gentamicin and stored at 4°C. Tissue typing, immunosuppressive therapy, gender matching, and blood grouping were not used. Graft age was determined by calculating the number of days after procurement. The graft was transplanted on average at 24 days (range, 15-43 days) after procurement.

Operative Technique

The authors' operative technique has been well described.¹⁶ Measurements taken from the patient's magnification-corrected anteroposterior and lateral radiographs were used

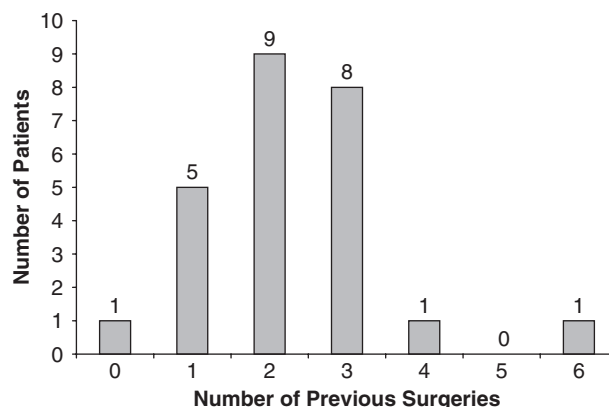


Figure 3. Distribution of previous surgeries.

to match the host to the prospective donor. Specifically, the medial-lateral dimension of the tibial plateau obtained 1 cm below the articular surface and the anteroposterior and lateral diameter of the involved condyle were used in conjunction with the known defect size to determine the appropriate donor measurements required for graft acceptance.

A small arthrotomy and vastus sparing or lateral retinacular incision was used depending on the defect location (Figure 1). The defect was identified and a reamer was used to convert the defect to a circular recipient hole with a uniform depth of 6 to 8 mm. An appropriate size- and location-matched site was identified on the allograft condyle. Next, the graft was cut to size in a graft workstation using a coring reamer. Pulsatile lavage was then used to wash out any remaining marrow elements from the donor plug. The graft was press-fit into the recipient socket (Figure 2), followed by impaction with an oversized tamp to make the graft surface flush with the surrounding native cartilage. In 5 of the initial cases, backup fixation was provided with bioabsorbable polydioxanone pins. However, the press-fit was deemed to be secure enough not to require any fixation in these or subsequent cases. Associated procedures included 10 meniscal transplantations, 4 opening wedge high tibial osteotomies (HTOs), and 1 removal of previous osteotomy plate.

Patients remained touchdown weightbearing with the assistance of crutches for 6 weeks. During this period they used a continuous passive motion machine for up to 6 hours a day. Their progress was monitored by a physical therapist and they were allowed unrestricted passive range of motion.

Clinical Assessment

All 25 patients were available for assessment at a minimum of 2 years of follow-up. Subjective measures were based on several scoring systems including Lysholm, International Knee Documentation Committee (IKDC), Knee injury and Osteoarthritis Outcome Score (KOOS), and Short Form-12 (SF-12). The KOOS is a validated self-administered instrument for follow-up of several types of knee injury, including osteoarthritis. It holds 5 separately scored subscales: Pain, Other Disease-Specific Symptoms, ADL Function, Sport and Recreation Function, and Knee-Related Quality of Life.⁴⁸ Objective measures included active range of motion (to full

TABLE 3
Objective Assessments

		Affected Side	Unaffected Side	Difference (Affected vs Unaffected)	P Value
Range of motion (degrees)	Preoperative	123	129	6	.221
	Follow-up	127	130	3	.103
	Difference (preoperative vs follow-up)	4 ($P = .774$)	1 ($P = .434$)		
Quadriceps size (cm)	Preoperative	47.2	48.6	1.4	.651
	Follow-up	46.2	47.6	1.4	.401
	Difference (preoperative vs follow-up)	-1 ($P = .987$)	-1 ($P = .909$)		

flexion) and quadriceps muscle size (measured 10 cm proximal to the superior pole of the patella). The degree of effusion at final follow-up was also noted.

Radiographic Assessment

Extension anterior to posterior and 45° flexion posterior to anterior weightbearing radiographs and nonweightbearing lateral radiographs were obtained at a minimum of 2 years postoperatively to determine graft incorporation. Long leg alignment films were obtained to record mechanical axis at both preoperative and follow-up periods. Malalignment was defined as mechanical axis deviation of greater than 7° in valgus or greater than 5° in varus. Patients meeting this criterion were offered an osteotomy with the goal of returning the mechanical axis to the center of the knee.

Statistical Analysis

Statistical analysis was performed using SPSS version 11.5 (SPSS, Inc, Chicago, IL). Descriptive statistics included frequencies, means, standard deviations, and ranges where appropriate. Tests used in this analysis include chi-square, Mann-Whitney, Wilcoxon signed ranks test, and Kruskal-Wallis. Results were considered statistically significant when $P < .05$.

RESULTS

General

The average patient age was 35 years (range, 17-49 years). There were 18 men and 7 women. The cause of injury is summarized in Table 1. For the purposes of classification, a lesion was considered traumatic if it had an acute onset of symptoms following an event such as a fall or a motor vehicle accident. There had been 1 or more previous operations on 24 (96%) knees (Figure 3). These included such palliative or reparative measures as osteochondritis dissecans fixation, debridement, microfracture, and autologous chondrocyte implantation (Table 2). The average interval from injury to surgery was 25 months (range, 3-70

months). Thirteen (52%) patients were on workers' compensation at the time of surgery. There were 17 (68%) patients with defects on the medial femoral condyle, 7 (28%) with defects on the lateral femoral condyle, and 1 (4%) with defects on both condyles. There were 20 (80%) patients with neutral alignment, and 5 (20%) with varus alignment at the time of surgery.

Intraoperative Results

The graft age on the day of surgery was, on average, 24 days (range, 15-43 days). Five (20%) patients had more than 1 lesion or lesion configurations that required more than 1 graft to replace the damaged region. One patient had 1 plug on the medial and the other on the lateral femoral condyle, whereas the other 4 patients required 2 plugs on the same condyle because of the shape of the defect. The primary lesion size was 5.24 cm² (range, 2.25-10.50 cm²) and the secondary lesion size was 2.31 cm² (range, 0.81-4.00 cm²). The primary plug size was 3.98 cm² (range, 1.77-7.07 cm²) and the secondary plug size was 1.80 cm² (range, 0.64-3.14 cm²). The concomitant procedures with the allograft procedures are summarized in Table 2. Five patients had preoperative malalignment, all in varus. Four were treated with an opening wedge HTO. The fifth patient had previously undergone an HTO with slight undercorrection but refused revision osteotomy.

Clinical Assessment

The average follow-up was 35 months (range, 24 to 67 months). Figure 4 summarizes the overall subjective results for the Lysholm, IKDC, KOOS, and SF-12 scoring systems. Statistically significant improvements were seen for the Lysholm (39 to 67, $P < .0001$), IKDC scores (29 to 58, $P < .0001$), all 5 components of the KOOS (Pain: 43 to 73, $P < .0001$; Other Disease-Specific Symptoms: 46 to 64, $P = .001$; ADL Function: 56 to 83, $P < .0001$; Sport and Recreation Function: 18 to 46, $P < .0001$; Knee-Related Quality of Life: 22 to 50, $P < .0001$), and the SF-12 physical component score (36 to 40, $P = .014$). The objective assessments of range of motion and quadriceps size revealed no significant differences and are summarized in Table 3.

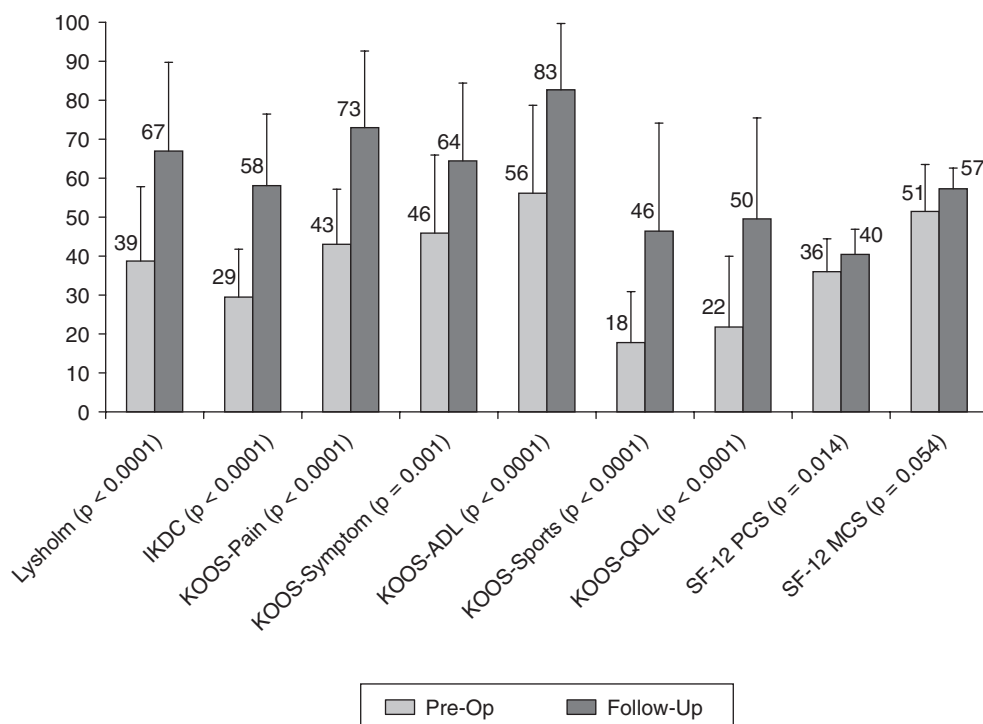


Figure 4. Overall subjective scores with comparison of preoperative and final follow-up. IKDC, International Knee Documentation Committee; KOOS, Knee injury and Osteoarthritis Outcome Score; ADL, Activities of Daily Living; QOL, Quality of Life; SF-12, Short Form-12; PCS, Physical Component Summary; MCS, Mental Component Summary.

TABLE 4

Significant Differences, at Follow-Up, Between Patients Who Received Grafts Aged >28 Days Versus ≤28 Days (Preoperative Scores Provided as Reference)^a

	Graft Age		P Value
	>28 Days	≤28 Days	
Preop KOOS Pain score	41	44	.747
F/U KOOS Pain score	90	69	.025
Preop KOOS Other Disease-Specific Symptoms score	40	47	.481
F/U KOOS Other Disease-Specific Symptoms score	81	60	.035
Preop KOOS ADL Function score	49	58	.432
F/U KOOS ADL Function score	96	79	.032

^aKOOS, Knee injury and Osteoarthritis Outcome Score; F/U, follow-up; ADL, Activities of Daily Living.

Twenty patients had no effusion, 1 patient had a 1+ effusion, and no assessment was made for the other 4 patients.

Patient Satisfaction

Patients were asked 3 questions to determine their overall satisfaction. When asked “How satisfied are you with your

results (eg, daily activity, functionality)?” the patients had an average of 84% (range, 25% to 100%) satisfaction with their results. When asked “Your affected/operated knee is functionally what percentage of your good leg?” patients responded that the affected knee was an average of 79% (range, 35% to 100%) compared with the unaffected knee with respect to function. When asked “Would you do the surgery again knowing what you know now and after all that you have experienced?” 20 (80%) patients answered “yes,” 2 (8%) patients answered “no,” and 3 (12%) declined to answer. One patient who did not want to repeat the surgery noted an 80% satisfaction with results.

Radiographic Assessment

Follow-up radiographs revealed 22 (88%) grafts that were incorporated into the host bone (Figure 5), 2 (8%) that had osteoarthritis, and 1 (4%) that was fragmented. At final follow-up, neutral alignment was found in 21 patients (84%), including the 2 with osteoarthritis and the 1 patient with fragmentation of the graft. Four patients (16%) were determined to be malaligned by virtue of mechanical axis deviation of more than 7° in valgus (2 patients, 8%) and 5° in varus (2 patients, 8%). Three of these patients were neutral preoperatively and did not have an HTO. One patient who received an HTO for varus was found to be in valgus at final follow-up. There were no statistical differences between malaligned and neutral aligned patients with respect to any subjective scores ($P > .05$). At follow-up, IKDC scores revealed significantly different scores

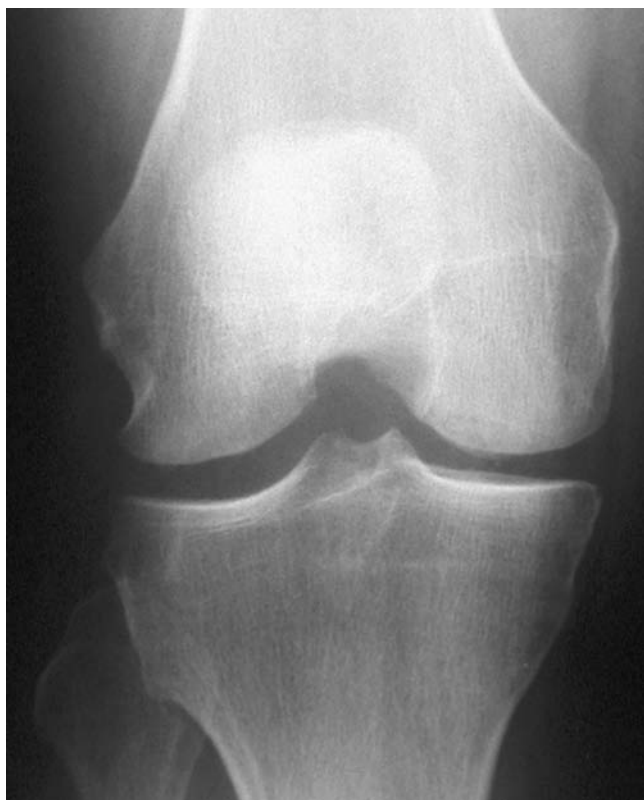

Figure 5. Well-incorporated medial femoral condyle osteochondral allograft at 2-year follow-up.

between the malaligned (IKDC = 39) and neutrally aligned (IKDC = 62) groups. The significant differences between these groups are summarized in Table 5. All other assessments were not statistically significant.

Complications

There were 2 (8%) complications by the final follow-up period. One was a failure secondary to allograft fragmentation, which was treated with allograft removal followed by a microfracture. No patients required further surgery as a result of either their osteotomy or their meniscal transplant. Another patient had marked pain for greater than 6 months, which was managed with physical therapy and analgesics.

Graft Age

Because graft age at 28 days was reported as a critical time point in a previous study, we quantified the clinical differences between grafts implanted greater than or less than this time point.⁶⁰ Five grafts (20%) were implanted at greater than 28 days after procurement, and 20 grafts (80%) were implanted at fewer than or equal to 28 days after procurement. None of the preoperative scores were statistically different ($P > .05$). At follow-up, there were no statistically significant differences between the fewer than or greater than 28-day groups, except for 3 KOOS subscores. For KOOS Pain, Other Disease-Specific Symptoms, and ADL

TABLE 5
Significant Differences Between Patients With Neutral Alignment Versus Malalignment at Final Follow-Up^a

	Malaligned	Neutral	P Value
Preoperative IKDC score	24	31	.305
Follow-up IKDC score	39	62	.024
Have surgery again?			
Yes	1	19	<.0001
No	2	0	

^aPreoperative IKDC scores are also included as a reference. IKDC, International Knee Documentation Committee.

Function scores, the greater than 28-day group actually had statistically higher follow-up scores than the fewer than 28-day group (Table 4). However, these differences are most likely secondary to the small sample size in the greater than 28-day group. All other assessments were not significantly different.

Workers' Compensation

Thirteen patients (52%) were on workers' compensation or had made a workers' compensation claim at the time of surgery. None of the preoperative assessments were statistically different between the workers' compensation and non-workers' compensation groups ($P > .05$). The only significant difference between these 2 groups was in the follow-up KOOS Sport and Recreation Function score, which averaged 35 for the workers' compensation group and 58 for the non-workers' compensation group ($P = .049$); whereas their preoperative KOOS Sport and Recreation Function scores were similar, with a mean of 17 for the worker's compensation group and a mean of 19 for the non-workers' compensation group ($P = .626$). All other assessments were not significantly different.

Associated Procedures

Eleven patients (44%) had isolated osteochondral allograft transplantation, whereas 14 patients (56%) had comorbidities that required concomitant procedures. When we compared the patients with an isolated procedure with the group that had a concomitant procedure, there were no significant differences in the demographics or preoperative or final follow-up scores ($P > .05$). However, there were differences when the group with concomitant procedures was divided into subgroups of 10 patients who also had a meniscus transplantation (MTx) in the same compartment and 4 others who had an HTO. As expected, there was a significant difference ($P = .001$) in preoperative alignment between the group requiring an HTO (4 varus alignment) and the group with an isolated allograft procedure (11 neutral alignment). Similarly, the preoperative alignment between the HTO group and the MTx group (9 neutral and 1 varus alignment) was significantly different ($P = .005$). The only other difference between the HTO and MTx groups was with respect to the total area of chondral lesion (5.23 cm² for MTx group and 7.63 cm² for HTO; $P = .030$). There were no

TABLE 6
Subjective Scores With Respect to
Associated Procedure (Mean \pm SD)^a

Score	Isolated Allograft (n = 11)	Allograft + MTx (n = 10)	Allograft + HTO (n = 4)
Lysholm			
Preoperative	34 (\pm 20)	47 (\pm 16)	30 (\pm 19)
Follow-up	60 (\pm 26)	68 (\pm 22)	82 (\pm 2)
P value	.008	.013	.002
IKDC			
Preoperative	26 (\pm 8)	36 (\pm 14)	22 (\pm 13)
Follow-up	59 (\pm 23)	55 (\pm 16)	62 (\pm 10)
P value	.003	.017	.003
KOOS Pain			
Preoperative	40 (\pm 15)	49 (\pm 12)	38 (\pm 15)
Follow-up	68 (\pm 23)	75 (\pm 19)	81 (\pm 9)
P value	.004	.005	.003
KOOS Symptom^b			
Preoperative	43 (\pm 21)	54 (\pm 15)	36 (\pm 28)
Follow-up	62 (\pm 23)	63 (\pm 19)	75 (\pm 7)
P value	.028	.069	.033
KOOS ADL^c			
Preoperative	48 (\pm 20)	70 (\pm 17)	43 (\pm 27)
Follow-up	78 (\pm 21)	85 (\pm 15)	90 (\pm 4)
P value	.004	.028	.013
KOOS Sport^d			
Preoperative	17 (\pm 11)	20 (\pm 16)	15 (\pm 13)
Follow-up	50 (\pm 34)	39 (\pm 23)	54 (\pm 20)
P value	.007	.032	.018
KOOS QOL^e			
Preoperative	24 (\pm 18)	19 (\pm 21)	22 (\pm 13)
Follow-up	59 (\pm 31)	41 (\pm 19)	45 (\pm 21)
P value	.007	.012	.106
SF-12 PCS			
Preoperative	38 (\pm 8)	37 (\pm 9)	29 (\pm 5)
Follow-up	40 (\pm 6)	42 (\pm 8)	38 (\pm 5)
P value	.286	.093	.057
SF-12 MCS			
Preoperative	53 (\pm 14)	53 (\pm 10)	43 (\pm 9)
Follow-up	56 (\pm 5)	57 (\pm 6)	61 (\pm 6)
P value	.859	.285	.016

^aMTx, meniscus transplantation; HTO, high tibial osteotomy; IKDC, International Knee Documentation Committee; KOOS, Knee injury and Osteoarthritis Outcome Score; SF-12, Short Form-12; PCS, Physical Component Summary; MCS, Mental Component Summary.

^bOther Disease-Specific Symptoms subscale.

^cActivities of Daily Living Function subscale.

^dSport and Recreation Function subscale.

^eKnee-Related Quality of Life subscale.

significant differences between the isolated allograft group and the allograft with MTx group. Table 6 summarizes the subjective scores of the isolated allograft and combined procedure groups. As expected, we found a number of significant differences between preoperative and follow-up scores. However, there were no significant subjective score comparisons among the groups ($P > .05$).

DISCUSSION

Many surgical options exist for patients with pure focal cartilage lesions. Most notably, these include microfracture, autologous chondrocyte implantation, or osteochondral autologous plug transfer. However, the appropriate treatment for larger, deeper osteochondral lesions remains controversial. When there is insufficient underlying bone, surgeons may be forced to consider staged bone grafting procedures. Furthermore, the appropriate treatment for those patients who fail these other chondral resurfacing techniques must also be determined.

Recent advances in allograft procurement, screening, and storage have made fresh osteochondral allografts commercially available. In the past, these procedures were only performed in large transplantation centers where the grafts were harvested and implanted within a week. Now, these grafts can safely be "prolonged" up to several weeks, which is an option that offers numerous benefits. It allows more time for thorough testing of the donor tissue, which may take up to 14 days. During this testing period, the patient and surgeon are able to schedule and plan for the surgery. This also affords more time to find a match and perform the transplant, thereby minimizing the number of donor grafts wasted because of expiration. This effectively increases the supply of grafts and makes them now more available to the general orthopaedic community. This has spawned renewed interest in the use of grafts for treatment of osteochondral defects in young, active patients. However, there are few data on grafts prolonged for greater than 14 days.

This study provides comprehensive prospective data on the results of 25 consecutive prolonged fresh osteochondral allografts for defects of the femoral condyles. Preoperatively, these patients reported significant pain and functional limitations that affected their daily activities. The average age of these patients was 35 (range, 17-49) years. Because they were young and active, they were poor candidates for a knee arthroplasty because of eventual loosening and need for multiple revision surgeries. At the time of OCA transplantation, 24 of 25 (96%) of these patients had undergone a previous procedure to address the lesion. Not including diagnostic arthroscopy, the average number of previous procedures was 2.28. Most of these patients were referred to our institution by other orthopaedic surgeons. Furthermore, 52% of the patients were on workers' compensation at the time of surgery. Clearly, this is a challenging patient population for which any improvements that allowed a return to the workforce and a more normal lifestyle would be welcomed.

The clinical results of prolonged OCA transplantation are encouraging at a minimum of 2 years of follow-up. The average length of follow-up was almost 3 years, with some patients reporting data more than 5 years out from surgery. Their overall subjective scores showed significant and robust improvements in nearly every index (Figure 4). Overall, patients reported 84% satisfaction with their results and believed that the knee functioned at an average of 79% of their unaffected knee. The objective measures of knee range of motion and quadriceps size were not significantly different from the unaffected knee (Table 3). Furthermore, the results

in the workers' compensation subgroup were similar to those in the rest of the cohort. The only significant difference for the workers' compensation group was a lower KOOS Sport and Recreation Function score of 35 compared with 58 for the non-workers' compensation group.

Many of these patients had other comorbidities that were addressed concomitantly. It has been established that chondral resurfacing procedures in the face of malalignment, ligamentous instability, or meniscal deficiency provide sub-optimal results.^{20,43} Therefore, we thought it was imperative to address these issues at the time of the transplantation. One could argue that the improvements seen were not solely attributable to the osteochondral allograft procedure itself. However, no significant differences in preoperative or post-operative scores were seen between those who underwent an isolated OCA transplantation and the group that had either a concomitant HTO or a meniscus transplant.

Follow-up radiographic assessment emphasized the need to correct alignment. At final evaluation, 21 of 25 patients (84%) were determined to have neutral alignment. However, 4 patients were determined to have residual malalignment. These malaligned patients had significantly lower IKDC follow-up scores (39 compared with 62) than those with neutral alignment. Of the 2 patients who stated that they would not have the surgery again, both were found to have malalignment. However, the radiographic data were encouraging with respect to osseous integration. Twenty-two of the grafts (88%) showed a normal contour and were well incorporated into the host bone. Two grafts had developed osteoarthritis but had not yet needed further surgery. There was 1 case of fragmentation of the graft.

There were only 2 complications (8%) in this study group, and only 1 patient required reoperation. The patient in whom radiographs had shown fragmentation of the graft had return of his previous symptoms. This patient had a concomitant meniscal transplant but no osteotomy, and it is not clear why this graft fragmented. The initial lesion size was 4 cm² and the depth of the plug used was 10 mm. Because the fragmentation occurred near the surface, this was salvaged with an arthroscopic debridement and microfracture of the defect. A second patient had normal radiographs but pain lasting longer than 6 months that eventually resolved after treatment with analgesics and a prolonged course of physical therapy. Although infection is a frequent patient concern when considering allograft surgery, there were no infections in this patient group. In fact, since the advent of DNA PCR testing, no viral infections with either HIV or hepatitis C from the use of osteochondral allografts have been documented in the literature.

One particularly interesting finding in this study is that clinical results did not deteriorate with increasing age of the graft. Although most of the grafts were implanted at 28 or fewer days after procurement, 5 (20%) patients received grafts after storage for greater than 28 days. When we compared the 2 groups, the preoperative scores and final scores were similar, except the greater than 29-day group had higher final KOOS scores for the pain, symptoms, and ADL indices. One would expect the opposite based on recently published data, which have shown a decline in chondrocyte viability and increased matrix degradation after several

weeks of storage.^{2,4,47,60-62} It is possible that the longer storage resulted in depletion of the bone and marrow elements that are known to be more immunogenic. More likely, the small number of grafts in this more prolonged group yielded a false-positive correlation. Despite these findings, given the aforementioned viability studies, we still recommend that OCA transplantation be performed within 28 days whenever possible.

A handful of other studies have reported the outcome of fresh OCA transplantation in the knee; however, these studies were performed with allografts that were implanted within a week of procurement.^{3,6,9,18-20,42} This is different from the "prolonged fresh" transplantation that we are reporting here. Two studies looked specifically at the use of fresh OCA transplantation for the treatment of osteochondritis dissecans (OCD) of the femoral condyles. Garrett¹⁸ reported a successful outcome in 16 of 17 patients who were asymptomatic at 2- to 9-year follow-up. These grafts were implanted within 4 days of harvesting. Bugbee et al⁶ reported 79% good or excellent results for a larger series of 69 patients at an average follow-up of 5 years when the grafts were implanted within 5 days of procurement. Since 1972, Allen Gross has been a pioneer in the use of OCA transplantation for traumatic defects of the knee. Although many of these were larger, uncontained structural grafts, his Toronto group still reported excellent results, with 85% survivorship of the grafts at follow-up of 7.5 and 10 years.^{3,19,20} Again, these grafts were stored for a maximum of 72 hours. Meyers et al⁴² and Chu et al⁹ reported on the use of fresh OCA for lesions attributable to multiple different diagnoses. In addition to OCD and traumatic defects, these authors included degenerative and osteonecrotic lesions, as we have in our series. They reported 77% and 84% good and excellent results, respectively, when the grafts were implanted within 6 days. In contrast, our "prolonged fresh" grafts were implanted at an average of 24 days after procurement. Despite this important difference, our subjective improvements and 84% satisfaction rate as presented here are similar to these other published reports of OCA transplantation.

No other study has used such comprehensive data collection and as complete follow-up as this report. We had complete data on all 25 patients. We were also able to evaluate them using Lysholm, IKDC, KOOS, SF-12, and patient satisfaction, as well as objective and radiographic assessments. This provides for a greater understanding of the results of this procedure than simply using "good-excellent" or graft survival assessments. However, there are some limitations to this study. Although this is one of the largest cohorts of fresh OCA transplantation in the United States, the number of patients is still small. Larger numbers would allow further subgroup analysis. This may demonstrate differences in outcome based on type or size of defect or interval from symptom onset to transplantation. This is a prospective cohort in whom we believed there was a need for this specific intervention and in whom we thought nonoperative management was not appropriate. Therefore, there is no control group. We cannot compare this group with those treated with other surgical procedures because many of these patients had already failed some of the alternative treatments. Although the natural history of these different

lesions is not certain, we do know that symptomatic large osteochondral lesions tend to progress to osteoarthritis.⁴¹ Patient selection is critical to obtaining a successful outcome. Determining when a patient is in need of treatment, but not too far along the path to osteoarthritis, is often challenging, and this selection bias makes comparison between studies difficult. The average follow-up is 3 years at this point, and it remains to be seen how lasting these improvements will be. However, each year that these patients are able to function and delay knee arthroplasty has significant potential long-term benefit.

Prolonged fresh osteochondral allograft transplantation is a safe and effective procedure for the treatment of osteochondral defects of the femoral condyles. It decreases pain and improves function in young, high-demand patients for whom knee arthroplasty is a poor option. The effects of the length of prolonged storage of these grafts on clinical outcome remain to be determined.

ACKNOWLEDGMENT

We sincerely appreciate the efforts of Loukas D. Koyonos for his efforts in patient recruitment.

REFERENCES

- Adachi N, Ochi M, Uchio Y, Iwasa J, Furukawa S, Deie M. Osteochondral lesion located at the lateral femoral condyle reconstructed by the transplantation of tissue-engineered cartilage in combination with a periosteum with bone block: a case report. *Knee Surg Sports Traumatol Arthrosc.* 2004;12:444-447.
- Allen RT, Robertson CM, Pennock AT, et al. Analysis of stored osteochondral allografts at the time of surgical implantation. *Am J Sports Med.* 2005;33:1479-1484.
- Aubin PP, Cheah HK, Davis AM, Gross AE. Long-term follow-up of fresh femoral osteochondral allografts for posttraumatic knee defects. *Clin Orthop.* 2001;391s:318-327.
- Ball ST, Amiel D, Williams SK. The effects of storage on fresh human osteochondral allografts. *Clin Orthop.* 2004;418:246-252.
- Buckwalter JA. Articular cartilage injuries. *Clin Orthop.* 2002;402:21-37.
- Bugbee WD, Emmerson BC, Jamali A. Fresh osteochondral allografting in the treatment of osteochondritis dissecans of the femoral condyle. Paper presented at: the AAOS 70th Annual Meeting; February 2003; New Orleans, La.
- Cao T, Ho KH, Teoh SH. Scaffold design and in vitro study of osteochondral co-culture in a three-dimensional porous polycaprolactone scaffold fabricated by fused deposition modeling. *Tissue Eng.* 2003;9(Suppl 1):s103-s112.
- Chow JC, Hantes ME, Houle JB, Zalavras CG. Arthroscopic autogenous osteochondral transplantation for treating knee cartilage defects: a 2- to 5-year follow-up study. *Arthroscopy.* 2004;20:681-690.
- Chu CR, Convery FR, Akeson WH, Meyers M, Amiel D. Articular cartilage transplantation: clinical results in the knee. *Clin Orthop.* 1999;360:159-168.
- Convery FR, Akeson WH, Meyers MH. The operative technique of fresh osteochondral allografting of the knee. *Oper Tech Orthop.* 1997;47:340-344.
- Curl W, Krome J, Gordon ES, Rushing J, Smith BP, Poehling GG. Cartilage injuries: a review of 31,516 knee arthroscopies. *Arthroscopy.* 1997;13:456-460.
- Czitrom AA, Keating S, Gross AE. The viability of articular cartilage in fresh osteochondral allografts after clinical transplantation. *J Bone Joint Surg Am.* 1990;72:574-581.
- Delcogliano A, Caporaso A, Menghi A, Rinonapoli G, Chiassi S. Results of autologous osteochondral grafts in chondral lesions of the knee. *Minerva Chir.* 2002;57:273-281.
- Diduch DR, Jordan LC, Mierisch CM, Balian G. Marrow stromal cells embedded in alginate for repair of osteochondral defects. *Arthroscopy.* 2000;16:571-577.
- Egli RJ, Sckell A, Fraitz CR, et al. Cryopreservation with dimethyl sulfoxide sustains partially the biological function of osteochondral tissue. *Bone.* 2003;33:352-361.
- Fox JA, Freedman KB, Lee SJ, Cole BJ. Fresh osteochondral allograft transplantation for articular cartilage defects. *Oper Tech Sports Med.* 2002;10:168-173.
- Garretson RB III, Katolik LI, Verma N, Beck PR, Bach BR, Cole BJ. Contact pressure at osteochondral donor sites in the patellofemoral joint. *Am J Sports Med.* 2004;32:967-974.
- Garrett JC. Fresh osteochondral allografts for treatment of articular defects in osteochondritis dissecans of the lateral femoral condyle in adults. *Clin Orthop.* 1994;303:33-37.
- Ghazavi MT, Pritzker KP, Davis AM, Gross AE. Fresh osteochondral allografts for post-traumatic defects of the knee. *J Bone Joint Surg Br.* 1997;79:1008-1013.
- Gross AE, Shasha N, Aubin P. Long-term follow-up of the use of fresh osteochondral allografts for post-traumatic knee defects. *Clin Orthop.* 2005;435:79-87.
- Guettler JH, Demetropoulos CK, Yang KH, Jurist KA. Dynamic evaluation of contact pressure and the effects of graft harvest with subsequent lateral release at osteochondral donor sites in the knee. *Arthroscopy.* 2005;21:715-720.
- Guo X, Wang C, Duan C, et al. Repair of osteochondral defects with autologous chondrocytes seeded onto bioceramic scaffold in sheep. *Tissue Eng.* 2004;10:1830-1840.
- Hjelle K, Solheim E, Strand T, Muri R, Brittberg M. Articular cartilage defects in 1,000 knee arthroscopies. *Arthroscopy.* 2002;18:730-734.
- Horas U, Pelinkovic D, Herr G, Aigner T, Schnettler R. Autologous chondrocyte implantation and osteochondral cylinder transplantation in cartilage repair of the knee joint: a prospective, comparative trial. *J Bone Joint Surg Am.* 2003;85:185-192.
- Hui JH, Chen F, Thambyah A, Lee EH. Treatment of chondral lesions in advanced osteochondritis dissecans: a comparative study of the efficacy of chondrocytes, mesenchymal stem cells, periosteal graft, and mosaicplasty (osteochondral autograft) in animal models. *J Pediatr Orthop.* 2004;24:427-433.
- Hunziker EB. Articular cartilage repair: basic science and clinical progress: a review of current status and prospects. *Osteoarthritis Cartilage.* 2002;10:432-463.
- Insall JN, Joseph DM, Msika C. High tibial osteotomy for varus gonarthrosis: a long-term follow-up study. *J Bone Joint Surg Am.* 1984;66:1040-1048.
- Jakob RP, Franz T, Gautier E, Mainil-Varlet P. Autologous osteochondral grafting in the knee: indication, results, and reflections. *Clin Orthop.* 2002;401:170-184.
- Kish G, Hangody L. A prospective, randomized comparison of autologous chondrocyte implantation versus mosaicplasty for osteochondral defects in the knee. *J Bone Joint Surg Br.* 2004;86:619-620.
- Koh JL, Wirsing K, Lautenschlager E, Zhang LO. The effect of graft height mismatch on contact pressure following osteochondral grafting: a biomechanical study. *Am J Sports Med.* 2004;32:317-320.
- Koulalis D, Schultz W, Heyden M, Konig F. Autologous osteochondral grafts in the treatment of cartilage defects of the knee joint. *Knee Surg Sports Traumatol Arthrosc.* 2004;12:329-334.
- Langer F, Gross AE. Immunogenicity of allograft articular cartilage. *J Bone Joint Surg Am.* 1974;56:297-304.
- LaPrade RF, Botker JC. Donor-site morbidity after osteochondral autograft transfer procedures. *Arthroscopy.* 2004;20:e69-e73.
- Lima EG, Mauck RL, Han SH, et al. Functional tissue engineering of chondral and osteochondral constructs. *Biorheology.* 2004;41:577-590.
- Major NM, Helms CA. MR Imaging of the knee: findings in asymptomatic collegiate basketball players. *Am J Roentgenol.* 2002;179:641-644.

36. Maletius W, Messner K. The effect of partial meniscectomy on the long-term prognosis of knees with localized, severe chondral damage: a 12-15 year follow-up. *Am J Sports Med.* 1996;24:258-262.
37. Mankin HJ. The reaction of articular cartilage to injury and osteoarthritis. *N Engl J Med.* 1974;291:1285-1292.
38. Mankin HJ. The response of articular cartilage to mechanical injury. *J Bone Joint Surg Am.* 1982;64:460-465.
39. Mankin HJ, Gebhart MC, Tomford WW. The use of frozen cadaveric allograft in the management of patients with bone tumors of the extremities. *Orthop Clin North Am.* 1987;18:275-289.
40. Matthews LS, Goldstein SA, Malvitz TA, Katz BP, Kaufer H. Proximal tibial osteotomy: factors that influence the duration of satisfactory function. *Clin Orthop.* 1988;229:193-200.
41. Messner K, Maletius W. The long-term prognosis for severe damage to weight-bearing cartilage in the knee: a 14 year clinical and radiographic follow-up in 28 young athletes. *Acta Orthop Scand.* 1996;67:165-168.
42. Meyers MH, Akeson WA, Convery FR. Resurfacing of the knee with fresh osteochondral allograft. *J Bone Joint Surg Am.* 1989;71:704-713.
43. Oakeshott RD, Farine I, Pritzker KP, Langer F, Gross AE. A clinical and histologic analysis of failed fresh osteochondral allografts. *Clin Orthop.* 1988; 233:283-294.
44. O'Driscoll SW. Technical considerations in periosteal grafting for osteochondral injuries. *Clin Sports Med.* 2001;20:379-402, vii.
45. Oshima Y, Watanabe N, Matsuda K, Takai S, Kawata M, Kubo T. Behavior of transplanted bone marrow-derived GFP mesenchymal cells in osteochondral defect as a simulation of autologous transplantation. *J Histochem Cytochem.* 2005;53:207-216.
46. Oshima Y, Watanabe N, Matsuda K, Takai S, Kawata M, Kubo T. Fate of transplanted bone-marrow-derived mesenchymal cells during osteochondral repair using transgenic rats to simulate autologous transplantation. *Osteoarthritis Cartilage.* 2004;12:811-817.
47. Pearsall AW, Tucker JA, Hester RB, Heitman RJ. Chondrocyte viability in refrigerated osteochondral allografts used for transplantation within the knee. *Am J Sports Med.* 2004;32:125-131.
48. Roos EM, Lohmander LS. The Knee Injury and Osteoarthritis Outcome Score (KOOS): from joint injury to osteoarthritis. *Health Qual Life Outcomes.* 2003;1:64.
49. Schek RM, Taboas JM, Segvich SJ, Hollister SJ, Krebsbach PH. Engineered osteochondral grafts using biphasic composite solid free-form fabricated scaffolds. *Tissue Eng.* 2004;10:1376-1385.
50. Smith GD, Richardson JB, Brittberg M, et al. Autologous chondrocyte implantation and osteochondral cylinder transplantation in cartilage repair of the knee joint. *J Bone Joint Surg Am.* 2003;85:2487-2488.
51. Solchaga LA, Gao J, Dennis JE, et al. Treatment of osteochondral defects with autologous bone marrow in a hyaluronan-based delivery vehicle. *Tissue Eng.* 2002;8:333-347.
52. Solchaga LA, Temenoff JS, Gao J, Mikos AG, Caplan AI, Goldberg VM. Repair of osteochondral defects with hyaluronan- and polyester-based scaffolds. *Osteoarthritis Cartilage.* 2005;13:297-309.
53. Sowers MF, Hayes C, Jamadar D, et al. Magnetic resonance-detected subchondral bone marrow and cartilage defect characteristics associated with pain and X-ray-defined knee osteoarthritis. *Osteoarthritis Cartilage.* 2003;11:387-393.
54. Steadman JR, Briggs KK, Rodrigo JJ, Kocher MS, Gill TJ, Rodkey WG. Outcomes of microfracture for traumatic chondral defects of the knee: average 11 year follow-up. *Arthroscopy.* 2003;19:477-484.
55. Tanaka T, Komaki H, Chazono M, Fujii K. Use of a biphasic graft constructed with chondrocytes overlying a beta-tricalcium phosphate block in the treatment of rabbit osteochondral defects. *Tissue Eng.* 2005;11:331-339.
56. Tomford WW, Springfield DS, Mankin HJ. Fresh and frozen articular cartilage allografts. *Orthopedics.* 1992;15:1183-1188.
57. Tuli R, Nandi S, Li WJ, et al. Human mesenchymal progenitor cell-based tissue engineering of a single-unit osteochondral construct. *Tissue Eng.* 2004;10:1169-1179.
58. Wakitani S, Aoki H, Harada Y, et al. Embryonic stem cells form articular cartilage, not teratomas, in osteochondral defects of rat joints. *Cell Transplant.* 2004;13:331-336.
59. Wang CJ. Treatment of focal articular cartilage lesions of the knee with autogenous osteochondral grafts: a 2- to 4-year follow-up study. *Arch Orthop Trauma Surg.* 2002;122:169-172.
60. Williams JM, Viridi AS, Pylawka TK, Edwards RB III, Markel MD, Cole BJ. Prolonged-fresh preservation of intact whole canine femoral condyles for the potential use as osteochondral allografts. *J Orthop Res.* 2005;23:831-837.
61. Williams RJ III, Dreese JC, Chen CT. Chondrocyte survival and material properties of hypothermally stored cartilage: an evaluation of tissue used for osteochondral allograft transplantation. *Am J Sports Med.* 2004;32:132-139.
62. Williams SK, Amiel D, Ball ST, et al. Prolonged storage effects on the articular cartilage of fresh human osteochondral allografts. *J Bone Joint Surg Am.* 2003;85:2111-2120.
63. Wingenfeld C, Egli RJ, Hempfing A, Ganz R, Leunig M. Cryopreservation of osteochondral allografts: dimethyl sulfoxide promotes angiogenesis and immune tolerance in mice. *J Bone Joint Surg Am.* 2002;84: 1420-1429.