

REVIEW ARTICLE

CURRENT CONCEPTS

Prosthetic-Joint Infections

Werner Zimmerli, M.D., Andrej Trampuz, M.D., and Peter E. Ochsner, M.D.

PROSTHETIC-JOINT REPLACEMENT IS USED INCREASINGLY TO ALLEVIATE pain and to improve mobility. Infections associated with prosthetic joints cause significant morbidity and account for a substantial proportion of health care expenditures.^{1,2} The use of perioperative antimicrobial prophylaxis and a laminar air-flow surgical environment has reduced the risk of intraoperative infection to less than 1 percent after hip and shoulder replacement and to less than 2 percent after knee replacement.³⁻⁵ Whereas the management of native-joint infection and osteomyelitis is well established,^{6,7} the management of infection associated with prosthetic joints is less standardized, because of the variable clinical presentations and the lack of data from randomized, controlled trials. This review focuses on the pathogenesis, diagnosis, and treatment of infection associated with prosthetic joints.

Uniform criteria have not been established for the diagnosis of infection associated with prosthetic joints. In several studies,⁸⁻¹¹ infection was diagnosed if at least one of the following criteria was present: growth of the same microorganism in two or more cultures of synovial fluid or periprosthetic tissue, purulence of synovial fluid or at the implant site, acute inflammation on histopathological examination of periprosthetic tissue, or presence of a sinus tract communicating with the prosthesis. The most commonly cultured microorganisms are coagulase-negative staphylococci (in 30 to 43 percent of cases) and *Staphylococcus aureus* (12 to 23 percent), followed by mixed flora (10 to 11 percent), streptococci (9 to 10 percent), gram-negative bacilli (3 to 6 percent), enterococci (3 to 7 percent), and anaerobes (2 to 4 percent).^{1,12,13} No microorganisms are detected in about 11 percent of apparent infections. The specificity of the above criteria for infection is high; however, some patients may present with infections that do not meet these criteria. The growth of a virulent microorganism (such as *S. aureus*) usually indicates infection, whereas low-virulence microorganisms that are typically part of normal skin flora (e.g., coagulase-negative staphylococci and *Propionibacterium acnes*) may be either contaminants or pathogens. Supportive laboratory findings — such as growth in more than one specimen, a short time to culture positivity, a positive Gram's stain, and the presence of acute inflammation on histopathological examination — may help determine the pathogenic role of low-virulence microorganisms. The location of the prosthesis also helps in interpreting the relevance of an isolated microorganism. For example, *P. acnes* causes infection after shoulder arthroplasty more frequently than it does after replacement of other joints (16 percent vs. <2 percent).^{1,4}

From the Basel University Medical Clinic, Liestal, Switzerland (W.Z.); the Division of Infectious Diseases, Department of Internal Medicine, Mayo Clinic College of Medicine, Rochester, Minn. (A.T.); and the Clinic of Orthopedic Surgery, Kantonsspital, Liestal, Switzerland (P.E.O.). Address reprint requests to Dr. Zimmerli at the University Medical Clinic, Kantonsspital, CH-4410 Liestal, Switzerland, or at werner.zimmerli@unibas.ch.

N Engl J Med 2004;351:1645-54.

Copyright © 2004 Massachusetts Medical Society.

PATHOGENESIS

ROLE OF BIOFILM

Infection that is associated with prosthetic joints is typically caused by microorganisms that grow in biofilms (Fig. 1).¹⁴ Within biofilms, microorganisms are enclosed in a polymeric matrix and develop into organized, complex communities with structural and functional heterogeneity, resembling multicellular organisms.¹⁵ When the microbial density is high, the volume of released cell-to-cell signaling molecules is suffi-

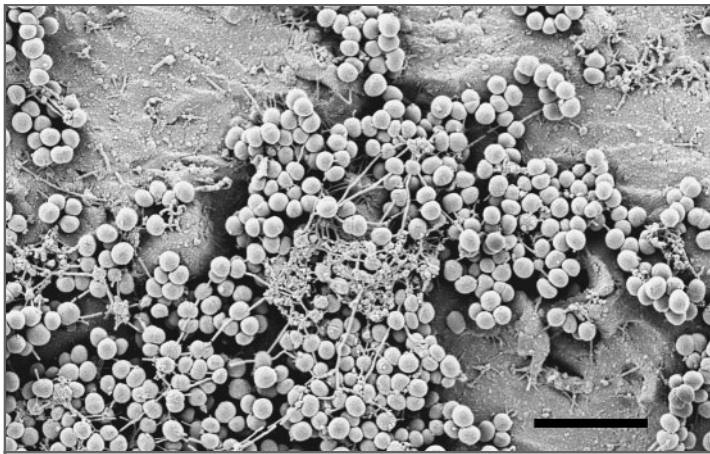


Figure 1. Scanning Electron Micrograph of a *Staphylococcus epidermidis* Biofilm on Foreign Material.

Bacteria grow in multicellular clusters. The scale bar represents 10 μ m. (Photograph courtesy of Robin Patel, Mayo Clinic College of Medicine.)

cient to activate genes involved in biofilm production, a phenomenon called quorum sensing.¹⁶ In the biofilm, microbes are protected from antimicrobial agents and host immune responses. Biofilm microorganisms have much greater resistance to antimicrobial killing than do planktonic bacteria.¹⁷ This resistance may be related to the reduced growth rate of biofilm microorganisms, which enter a stationary phase of growth, probably because of incomplete penetration of metabolic substrates, such as glucose or oxygen.¹⁸

INTERACTION AMONG MICROBIAL, HOST, AND PROSTHETIC FACTORS

Adherence of *S. epidermidis* to the surface of a prosthesis is a two-step process involving a primary attachment mediated by nonspecific factors (such as surface tension, hydrophobicity, and electrostatic interactions) or by specific adhesins, followed by biofilm formation, which is mediated in part by the polysaccharide intercellular adhesin encoded by the intercellular adhesion (*ica*) operon.^{19,20} Whereas the type of prosthetic material may play a role in *S. epidermidis* infection, *S. aureus* interacts with host proteins, such as fibronectin, fibrinogen, and collagen, covering the device immediately after implantation.²¹ *S. aureus* adheres to such ligands by means of adhesins, commonly referred to as MSCRAMM (microbial surface components recognizing adhesive matrix molecules).^{22,23}

Foreign bodies remain devoid of a microcircula-

tion, which is crucial for host defense and the delivery of antibiotics. The presence of a subcutaneous foreign body reduces the minimal inoculum of *S. aureus* that is required to cause infection by a factor of more than 100,000.²⁴ This increased susceptibility to infection is at least partially due to a locally acquired granulocyte defect.^{24,25} Activation of neutrophils on foreign surfaces results in the release of human neutrophil peptides that deactivate granulocytes.²⁶ In the presence of a foreign body, infection can occur despite the use of perioperative antimicrobial prophylaxis, since less than 100 colony-forming units of microorganisms can cause an infection.²⁴ Extravascular implants can be selectively infected in animals with 100 to 1000 colony-forming units of *S. aureus* per milliliter of blood.²⁷ This experimental observation has been confirmed in humans. Murdoch et al.²⁸ observed that during *S. aureus* bacteremia, an implant-associated infection developed in 15 of 44 patients with prosthetic joints. Thus, infection can occur not only during surgery but during the entire lifetime of the implant.

CLINICAL PRESENTATION

Infections associated with prosthetic joints can be classified as early (those that develop less than 3 months after surgery), delayed (3 to 24 months after surgery), or late (more than 24 months after surgery).²⁹ Early infections are typically manifested as an acute onset of joint pain, effusion, erythema and warmth at the implant site, and fever and are commonly caused by virulent microorganisms, such as *S. aureus* and gram-negative bacilli. During the course of infection, clinically significant cellulitis and the formation of a sinus tract with purulent discharge may occur. Patients with delayed (low-grade) infection usually present with subtle signs and symptoms, such as implant loosening, persistent joint pain, or both, which may be difficult to distinguish from aseptic failure; the infections are usually caused by less virulent microorganisms, such as coagulase-negative staphylococci and *P. acnes*.¹ Early and delayed infections are usually acquired during implantation of the prosthesis, whereas late infections are predominantly acquired by hematogenous seeding. The most frequent sources of bacteremia are skin, respiratory tract, dental, and urinary tract infections.³⁰ In a recent study of 63 consecutive episodes of infection associated with hip prostheses during a 16-year-

period, 29 percent of the cases were early infections, 41 percent were delayed infections, and 30 percent were late infections.³¹

DIAGNOSIS

LABORATORY STUDIES

The blood leukocyte count and the percentage of band forms are not sufficiently discriminative to predict the presence or absence of infection. After surgery, the C-reactive protein level is elevated and returns to normal within weeks.³² Therefore, serial postoperative measurements are more informative than a single value. In a recent study, using previously described criteria for infections associated with prosthetic joints, a synovial-fluid leukocyte count of more than 1700 per cubic millimeter or a finding of more than 65 percent neutrophils had sensitivities for infection of 94 and 97 percent, respectively, and specificities of 88 and 98 percent, respectively, in patients without underlying inflammatory joint diseases.³³

HISTOPATHOLOGICAL STUDIES

The definition of acute inflammation in the periprosthetic tissue varies in studies from 1 to 10 or more neutrophils per high-power field at a magnification of 400. Histopathological examination has a sensitivity of more than 80 percent and a specificity of more than 90 percent.³⁴ The interobserver variability is high, and the degree of infiltration with inflammatory cells may vary considerably among specimens from the same patient, even within individual tissue sections. Therefore, areas with the most florid inflammatory changes should be sampled.

MICROBIOLOGIC STUDIES

Gram's staining of synovial fluid and periprosthetic tissue has a high specificity (more than 97 percent) but generally has a low sensitivity (less than 26 percent).³⁴ Cultures of a superficial wound or sinus tract are often positive because of microbial colonization from the surrounding skin and should therefore be avoided. In aspirated synovial fluid, the pathogen can be detected in 45 to 100 percent of cases.³⁴ Cultures of periprosthetic tissue provide the most reliable means of detecting the pathogen and are frequently used as the reference standard for diagnosing infections associated with prosthetic joints. The sensitivity of these cultures ranges from 65 to 94 percent, depending on the

definition of infection.³⁴ At least three intraoperative tissue specimens should be sampled for culture.^{12,35,36} Swab cultures have a low sensitivity and should be avoided.²⁹ Cultures may be negative because of prior antimicrobial exposure, a low number of organisms, an inappropriate culture medium, fastidious organisms, or prolonged transport time to the microbiology laboratory. Some microorganisms, such as *Abiotrophia defectiva* or *Granulicatella adiacens* (formerly classified as nutritionally variant streptococci) or small-colony variants of staphylococci, are difficult to detect.^{36,37} To detect cases of low-grade infection, antimicrobial therapy should be discontinued at least two weeks before tissue specimens are obtained. If revision surgery is planned, perioperative prophylaxis should not be administered until after tissue specimens have been collected for culture.³⁴ If the prosthesis is removed, the implant or its components can be cultured in enrichment broth. However, the risk of contamination during specimen processing is high.

IMAGING STUDIES

Plain radiographs are helpful to detect infection when they are studied serially over time after implantation.³⁸ New subperiosteal bone growth and transcortical sinus tracts are specific for infection; however, migration of the implant and periprosthetic osteolysis can also occur without infection. The prosthesis (especially if it is uncemented) may be loose without accompanying radiologic abnormalities. Arthrography is useful for detecting implant loosening, pseudobursae, and abscesses.²⁹ Nuclear scintigraphy detects inflammation in periprosthetic tissue. Although bone scintigraphy with technetium-99m-labeled methylene diphosphonate has very high sensitivity, it lacks specificity for infection.³⁹ A technetium bone scan can remain positive more than a year after implantation because of increased periprosthetic bone remodeling. Since the use of indium-111-labeled autologous leukocytes is time-consuming,⁴⁰ this technique has been replaced in Europe by technetium-99m-labeled monoclonal anti-NCA-90 antibody Fab' fragments, which have an accuracy of 81 percent for detecting arthroplasty-associated infection.⁴¹ Positron-emission tomography with fludeoxyglucose F 18 needs further evaluation for implant imaging; a specificity of only 55 percent has been reported for detecting infection associated with prosthetic joints.⁴² Computed tomography provides better contrast between normal and abnormal tissue than

does plain radiography; however, imaging artifacts caused by metal implants limit its use. Magnetic resonance imaging (MRI) can be performed only in patients with implants that are safe for MRI, such as those composed of titanium or tantalum.

TREATMENT

The goal of treating infection associated with a prosthetic joint is a pain-free, functional joint. This can best be achieved by eradication of the infection. Various therapies have been used, including surgical removal of all infected tissue and the implant and a combination of débridement with implant retention and long-term antimicrobial therapy that is active against biofilm microorganisms. In North America, débridement with device retention and a one-stage exchange (in which the infected prosthesis is removed and a new one implanted in the same procedure) is performed less frequently than it is in Europe, and the interval between resection and reimplantation of the prosthesis in a two-stage exchange is generally longer (typically six weeks).^{43,44} In addition, long-term therapy with suppressive oral antimicrobial agents is commonly used in North America; in Europe, this treatment is reserved mainly for patients in whom surgery is contraindicated.⁴⁵

MEDICAL THERAPY

In prosthesis-associated infection, standard antimicrobial-susceptibility tests cannot be used to reliably predict the outcome.^{11,46-49} Ideally, the antimicrobial agent should have bactericidal activity against surface-adhering, slow-growing, and biofilm-producing microorganisms.^{15,18,46,47,49} Rifampin fulfills these requirements for staphylococci and has been tested in vitro, in animal models,^{47,49,50} and in clinical studies.^{48,51,52} Rifampin should never be administered alone, since staphylococci rapidly develop antimicrobial resistance.⁵³ Quinolones are excellent combination agents because of their bioavailability, antimicrobial activity, and tolerability.⁴⁸ Ciprofloxacin and ofloxacin have been extensively tested in studies of long-term therapy in patients with bone or joint infection.^{48,51,54} Newer quinolones such as levofloxacin, moxifloxacin, and gatifloxacin are more effective against gram-positive microorganisms than is ciprofloxacin. However, data on efficacy and toxicity with long-term therapy are lacking. Before treatment, the antimicrobial susceptibility of the pathogen

needs to be determined. Alternative antimicrobial combination regimens are needed because of increasing resistance of staphylococci to quinolones. A clinical trial of fusidic acid in combination with rifampin showed a success rate of 55 percent.⁵² Trimethoprim-sulfamethoxazole, minocycline, and linezolid can also be combined with rifampin; however, no data on these combination regimens have been reported. Few data are available on the treatment of gram-negative bacilli. In vitro studies and an animal model showed that ciprofloxacin had better efficacy against gram-negative bacilli than did beta-lactams.⁴⁶ Table 1 summarizes the choice of antimicrobial agent according to the pathogen. Since long-term antimicrobial therapy is needed, the microorganism should be susceptible to oral antimicrobial agents with good bioavailability. If intravenous drugs, such as beta-lactams, glycopeptides, or quinupristin-dalfopristin, are the only option, the use of an intravenous access device for outpatient treatment may be considered.⁵⁵

SURGICAL THERAPY

Surgical treatments include débridement with retention of the prosthesis, one- or two-stage exchange, resection arthroplasty, arthrodesis, and amputation.⁴³ Débridement involves removal of the hematoma, fibrous membranes, sinus tracts, and devitalized bone and soft tissue. One-stage revision includes removal of all foreign material, débridement, and reimplantation of a new prosthesis during the same procedure. If the pathogen is known preoperatively and the patient has no signs of severe systemic infection, antimicrobial treatment is given for two to three weeks before the prosthesis exchange is performed. In a two-stage exchange, implantation of the new prosthesis is delayed for a variable period of time. Resection arthroplasty consists of permanent removal of the prosthesis and débridement without reimplantation.

An antimicrobial-impregnated spacer can keep the limb at its correct length and allows partial joint mobility. However, the spacer is a foreign body, is prone to dislocation, and can be painful. Drainage with irrigation and suction for about three days is preferable to drainage alone.^{29,48} The use of antimicrobial-impregnated cement is suggested; however, data from randomized, controlled trials are lacking.⁴³ Analysis of pooled data from 29 studies of hip-prosthesis-associated infection that had been treated with a direct exchange showed a better cure rate with the use of antibiotic-impregnated

Table 1. Treatment of Infection Associated with a Prosthetic Joint Caused by Common Microorganisms.*

Microorganism	Antimicrobial Agent	Dose	Route
<i>Staphylococcus aureus</i> or coagulase-negative staphylococci			
Methicillin-susceptible	Nafcillin or floxacillin† <i>plus</i>	2 g every 6 hr	IV
	Rifampin for 2 wk, <i>followed by</i>	450 mg every 12 hr	PO or IV
	Rifampin <i>plus</i>	450 mg every 12 hr	PO
	Ciprofloxacin <i>or</i>	750 mg every 12 hr	PO
	Levofloxacin	750 mg every 24 hr to 500 mg every 12 hr	PO
Methicillin-resistant	Vancomycin <i>plus</i>	1 g every 12 hr	IV
	Rifampin for 2 wk, <i>followed by</i>	450 mg every 12 hr	PO or IV
	Rifampin <i>plus</i>	450 mg every 12 hr	PO
	Ciprofloxacin‡ <i>or</i>	750 mg every 12 hr	PO
	Levofloxacin‡ <i>or</i>	750 mg every 24 hr to 500 mg every 12 hr	PO
	Teicoplanin§ <i>or</i>	400 mg every 24 hr	IV or IM
	Fusidic acid§ <i>or</i>	500 mg every 8 hr	PO
	Trimethoprim–sulfamethoxazole <i>or</i>	1 DS tablet every 8 hr	PO
	Minocycline	100 mg every 12 hr	PO
	Penicillin G <i>or</i>	5 million U every 6 hr	IV
Streptococcus species (except <i>Streptococcus agalactiae</i>)	Ceftriaxone for 4 wk, <i>followed by</i>	2 g every 24 hr	IV
	Amoxicillin	750–1000 mg every 8 hr	PO
	Amoxicillin	750–1000 mg every 8 hr	PO
Enterococcus species (penicillin-susceptible) and <i>Streptococcus agalactiae</i>	Penicillin G <i>or</i>	5 million U every 6 hr	IV
	Ampicillin or amoxicillin <i>plus</i>	2 g every 4–6 hr	IV
	Aminoglycoside¶ for 2–4 wk, <i>followed by</i>		IV
Enterobacteriaceae (quinolone-susceptible)	Ciprofloxacin	750 mg every 12 hr	PO
	Ciprofloxacin	750 mg every 12 hr	PO
Nonfermenters (e.g., <i>Pseudomonas aeruginosa</i>)	Ceftazidime or cefepime <i>plus</i>	2 g every 8 hr	IV
	Aminoglycoside¶ for 2 wk, <i>followed by</i>		IV
	Ciprofloxacin	750 mg every 12 hr	PO
Anaerobes	Clindamycin for 2–4 wk, <i>followed by</i>	600 mg every 6–8 hr	IV
	Clindamycin	300 mg every 6 hr	PO
Mixed infections (without methicillin-resistant staphylococci)	Amoxicillin–clavulanic acid§ <i>or</i>	2.2 g every 8 hr	IV
	Ampicillin–sulbactam <i>or</i>	3 g every 6 hr	IV
	Carbapenem for 2–4 wk, <i>followed by</i> individual regimens according to antimicrobial susceptibility	According to compound	IV

* The antimicrobial susceptibility of the pathogen needs to be determined before treatment. The antimicrobial dose is given for adults with normal renal and hepatic clearance. PO denotes oral administration, IV intravenous administration, IM intramuscular administration, and DS double strength (trimethoprim, 160 mg, and sulfamethoxazole, 800 mg). The total duration of antimicrobial treatment in patients with implant retention or a one-stage exchange should be three months for a hip prosthesis and six months for a knee prosthesis.

† In patients with delayed hypersensitivity, cefazolin (2 g every 8 hours, given intravenously) can be administered. In patients with immediate hypersensitivity, penicillin should be replaced by vancomycin (1 g every 12 hours intravenously). In Europe, floxacillin is better known as flucloxacillin, and oxacillin is often used as an alternative drug.

‡ Methicillin-resistant *S. aureus* should not be treated with quinolones, since antimicrobial resistance may emerge during treatment.

§ Teicoplanin, fusidic acid, and intravenous amoxicillin–clavulanic acid are not approved for this indication by the Food and Drug Administration.

¶ Aminoglycosides can be administered in a single daily dose.

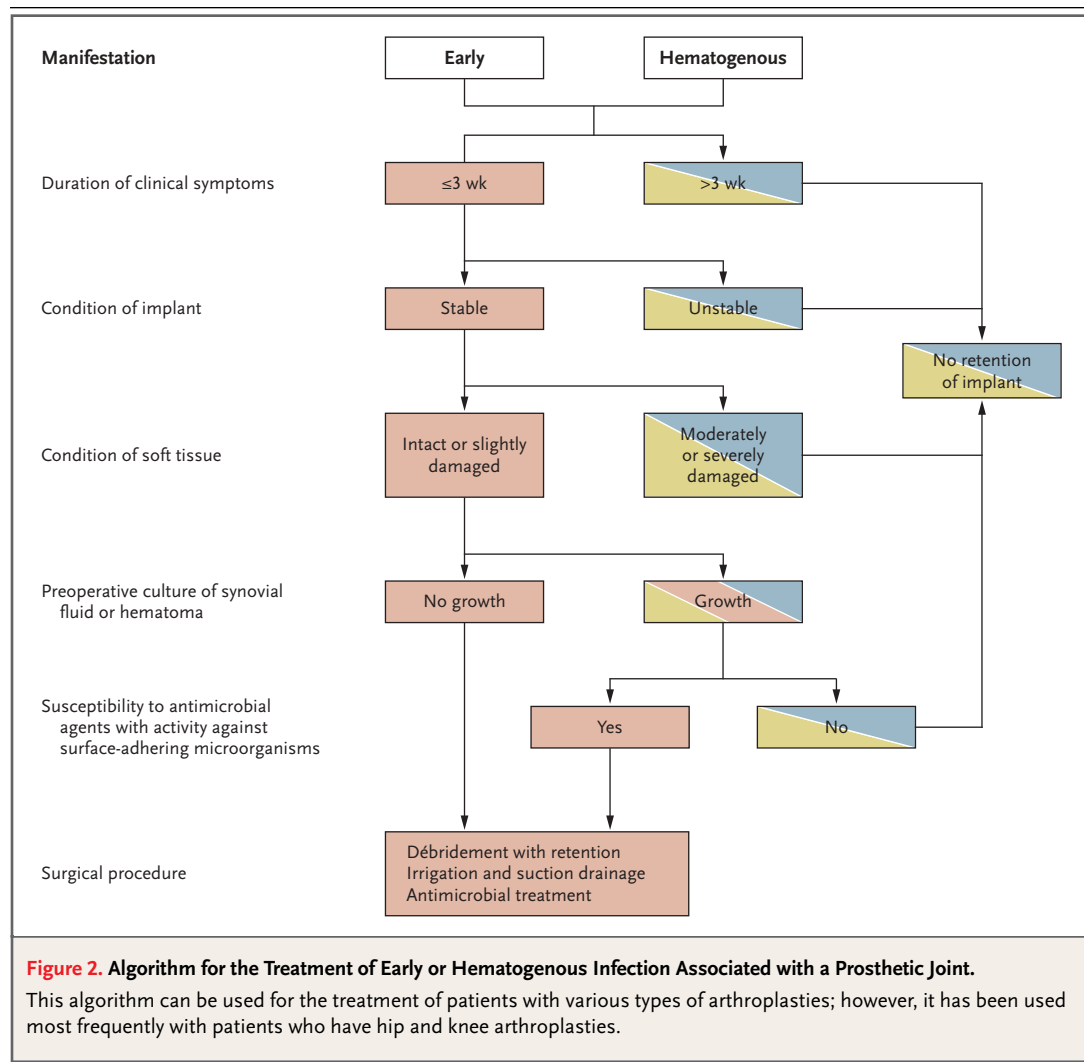
|| Alternatively, penicillin G (5 million U every 6 hours, given intravenously) or ceftriaxone (2 g every 24 hours intravenously) can be used for gram-positive anaerobes (e.g., *Propionibacterium acnes*), and metronidazole (500 mg every 8 hours intravenously or orally) for gram-negative anaerobes (e.g., bacteroides species).

bone cement (86 percent) than without it (59 percent).⁴⁴ If multidrug-resistant microorganisms are isolated, the preferred treatment is limb extension (in a procedure involving the hip) or either external fixation or stabilization with a brace (in a procedure involving the knee) instead of implantation of a spacer.²⁹ In the knee and ankle, permanent removal of the prosthesis often requires arthrodesis. Alternatively, a drop-lock hinged brace is suitable for limited ambulation.

TREATMENT ALGORITHM

Figures 2 and 3 show treatment algorithms for infections associated with prosthetic hip and knee joints that are based on published data and on our experience and that of our colleagues.^{1,29,31,43,56,57} Débridement with retention (Fig. 2) is a reason-

able option for patients with an early postoperative or acute hematogenous infection, if the duration of clinical signs and symptoms is less than three weeks, the implant is stable, the soft tissue is in good condition, and an agent with activity against biofilm microorganisms is available. Intravenous treatment should be administered for two to four weeks, followed by oral therapy (Table 1). We suggest a total treatment duration of three months in patients with hip prostheses and six months in those with knee prostheses.⁴⁸ These empirical recommendations are based on a single controlled trial rather than on studies comparing different durations.⁴⁸ The rationale for the longer duration of treatment in patients who have infection associated with prosthetic knees is the often unfavorable condition of the surrounding soft tissue. The suc-

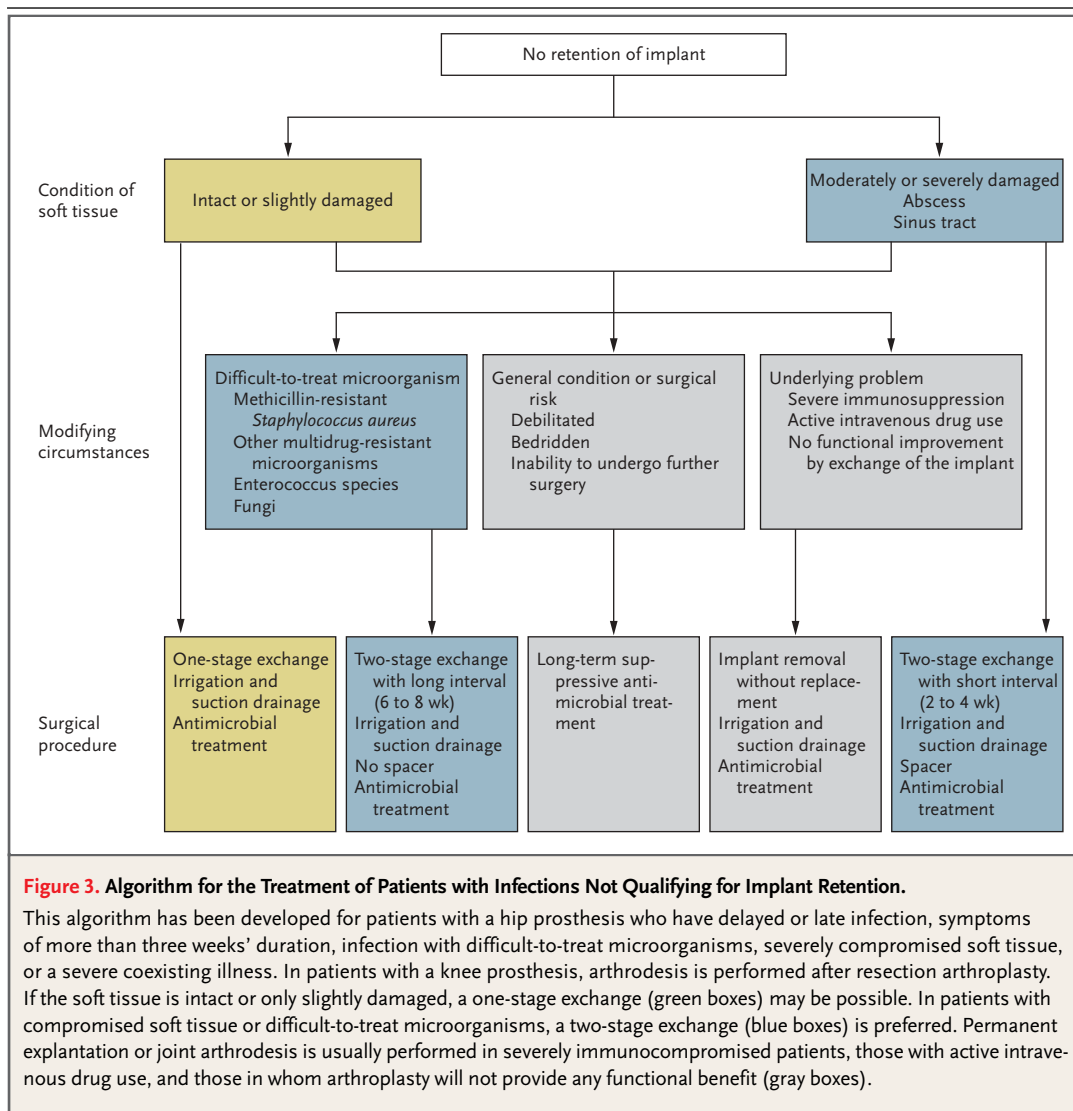


cess rate in this patient population is 82 to 100 percent for staphylococcal infections associated with different types of orthopedic devices.^{48,51} However, if these requirements are not fulfilled, the success rate with débridement and implant retention is only 14 to 68 percent.^{10,11,45,58-61} In a study of 19 patients with streptococcal infection, stable implants, and a short duration of symptoms, the rate of success of débridement with retention was 89 percent.⁹ Thus, the stability of the implant, the type of microorganism, and the interval between the onset of symptoms and treatment with débridement and antimicrobial therapy are crucial predictors of success.

If the duration of signs or symptoms of infec-

tion exceeds three weeks, retention of the implant should not be attempted. The prerequisites for a one-stage exchange (Fig. 3) are the satisfactory condition of soft tissue, the absence of severe coexisting illnesses, and the absence of difficult-to-treat microorganisms. The rate of success of a one-stage exchange in patients with prosthetic hips is 86 to 100 percent.⁶²⁻⁶⁵

In patients with compromised soft tissue, a two-stage exchange is preferred (Fig. 3). With this strategy, the success rate is more than 90 percent.^{43,44,56,66,67} The short interval until reimplantation (two to four weeks) allows both procedures to be performed during a single hospitalization. After explantation, a spacer or external-fixation de-



vice is inserted to maintain the length of the limb. Antimicrobial treatment is administered for a total of three months in the case of hip replacement and six months in the case of knee replacement. In infections with difficult-to-treat microorganisms such as methicillin-resistant *S. aureus*, other multi-drug resistant bacteria, enterococci, or fungi, an interval of six to eight weeks between removal of the first prosthesis and placement of the second, without the use of a spacer, is preferable. Among these patients, the whole course of antimicrobial treatment is administered without the presence of any foreign material. Two weeks before reimplantation of the prosthesis, antimicrobial treatment is discontinued in order to obtain reliable tissue specimens for culture at the time of reimplantation. If these specimens show no growth and no acute inflammation, antimicrobial treatment can be discontinued. Otherwise, it is continued, for a total of three months after hip replacement and for six months after knee replacement.

Permanent explantation or joint arthrodesis is usually performed in severely immunocompromised patients, those with active intravenous drug use, and those in whom arthroplasty will not provide any functional benefit (Fig. 3). Long-term suppressive antimicrobial therapy is reasonable if surgery is contraindicated because the patient has a severe coexisting illness, does not need a functional prosthesis because of immobility, or refuses further procedures. The goal of suppressive treatment is to control clinical manifestations rather than eradicate infection. Therefore, in this situation, rifampin is not required; depending on the microbiologic findings, trimethoprim-sulfamethoxazole or a tetracycline can be used.

PREVENTION

A review of antimicrobial therapy to prevent intraoperative and hematogenous infections associated with prosthetic joints is beyond the scope of this article and is extensively discussed in advisory statements of the American Academy of Orthopaedic Surgeons.^{68,69} Antimicrobial prophylaxis

during routine invasive procedures is controversial; however, rapid initiation of antimicrobial treatment when bacteremia is suspected appears to be crucial.³⁰

OUTLOOK

New techniques to disrupt microbial biofilms and quantitative molecular methods will further facilitate the diagnosis of infection associated with prosthetic joints.⁷⁰ Polymerase chain reaction (PCR) is an extremely sensitive diagnostic method. In broad-range PCR, universal primers are used to amplify regions of DNA (usually 16S ribosomal RNA genes) that are present in most bacteria, but not in human, fungal, or viral genomes. Improved PCR techniques allow rapid real-time detection and quantification of the amplification product. However, false positive results due to contaminating DNA can complicate the interpretation of molecular findings. In addition, in most cases, PCR assays cannot be used to determine the antimicrobial susceptibility of the pathogen or to identify individual pathogens in mixed infections.

CONCLUSIONS

A better understanding of the pathogenesis of infection associated with prosthetic joints, such as microbial interaction with the implant and mechanisms of resistance in surface-adhering microorganisms, has led to a more rational approach to antimicrobial therapy. Diagnosis and treatment of infection have improved during the past decade. The analysis of treatment failures, experimental treatment in animal models, and clinical studies of various surgical procedures and antimicrobial regimens are the basis for an algorithm that includes a combined approach of surgical and antimicrobial therapy for each case.

Dr. Trampuz reports having received grant support from the Roche Research Foundation and the Swiss National Science Foundation (BS81-64248), and Dr. Ochsner grant support from Centerpulse.

We are indebted to Drs. Peter Graber, Rajesh M. Prabhu, and Richard Trebse for their critical comments and suggestions.

REFERENCES

1. Steckelberg JM, Osmon DR. Prosthetic joint infections. In: Waldvogel FA, Bisno AL, eds. Infections associated with indwelling medical devices. 3rd ed. Washington, D.C.: American Society for Microbiology, 2000: 173-209.
2. Darouiche RO. Treatment of infections associated with surgical implants. *N Engl J Med* 2004;350:1422-9.
3. NIH Consensus Development Panel on Total Hip Replacement. NIH consensus conference: total hip replacement. *JAMA* 1995; 273:1950-6.
4. Sperling JW, Kozak TK, Hanssen AD, Cofield RH. Infection after shoulder arthroplasty. *Clin Orthop* 2001;382:206-16.
5. Harris WH, Sledge CB. Total hip and total knee replacement. *N Engl J Med* 1990; 323:801-7.
6. Lew DP, Waldvogel FA. Osteomyelitis. *N Engl J Med* 1997;336:999-1007.

7. Shirtliff ME, Mader JT. Acute septic arthritis. *Clin Microbiol Rev* 2002;15:527-44.
8. Berbari EF, Hanssen AD, Duffy MC, et al. Risk factors for prosthetic joint infection: case-control study. *Clin Infect Dis* 1998;27:1247-54.
9. Meehan AM, Osmon DR, Duffy MC, Hanssen AD, Keating MR. Outcome of penicillin-susceptible streptococcal prosthetic joint infection treated with debridement and retention of the prosthesis. *Clin Infect Dis* 2003;36:845-9.
10. Tattavin P, Cremieux AC, Pottier P, Hutten D, Carbon C. Prosthetic joint infection: when can prosthesis salvage be considered? *Clin Infect Dis* 1999;29:292-5.
11. Brandt CM, Sistrunk WW, Duffy MC, et al. *Staphylococcus aureus* prosthetic joint infection treated with debridement and prosthesis retention. *Clin Infect Dis* 1997;24:914-9.
12. Pandey R, Berendt AR, Athanasou NA. Histological and microbiological findings in non-infected and infected revision arthroplasty tissues. *Arch Orthop Trauma Surg* 2000;120:570-4.
13. Segawa H, Tsukayama DT, Kyle RF, Becker DA, Gustilo RB. Infection after total knee arthroplasty: a retrospective study of the treatment of eighty-one infections. *J Bone Joint Surg Am* 1999;81:1434-45.
14. Gristina AG. Biomaterial-centered infection: microbial adhesion versus tissue integration. *Science* 1987;237:1588-95.
15. Costerton JW, Stewart PS, Greenberg EP. Bacterial biofilms: a common cause of persistent infections. *Science* 1999;284:1318-22.
16. Vuong C, Gerke C, Somerville GA, Fischer ER, Otto M. Quorum-sensing control of biofilm factors in *Staphylococcus epidermidis*. *J Infect Dis* 2003;188:706-18.
17. Ceri H, Olson ME, Stremick C, Read RR, Morck D, Buret A. The Calgary Biofilm Device: new technology for rapid determination of antibiotic susceptibilities of bacterial biofilms. *J Clin Microbiol* 1999;37:1771-6.
18. Anderl JN, Zahler J, Roe F, Stewart PS. Role of nutrient limitation and stationary-phase existence in *Klebsiella pneumoniae* biofilm resistance to ampicillin and ciprofloxacin. *Antimicrob Agents Chemother* 2003;47:1251-6.
19. Williams RJ, Henderson B, Sharp LJ, Nair SP. Identification of a fibronectin-binding protein from *Staphylococcus epidermidis*. *Infect Immun* 2002;70:6805-10.
20. Darouiche RO. Device-associated infections: a macroproblem that starts with microadherence. *Clin Infect Dis* 2001;33:1567-72.
21. Foster T, Höök M. Molecular basis of adherence of *Staphylococcus aureus* to biomaterials. In: Waldvogel FA, Bisno AL, eds. *Infections associated with indwelling medical devices*. 3rd ed. Washington, D.C.: American Society for Microbiology, 2000:27-39.
22. Patti JM, Allen BL, McGavin MJ, Hook M. MSCRAMM-mediated adherence of microorganisms to host tissues. *Annu Rev Microbiol* 1994;48:585-617.
23. Wolz C, Goerke C, Landmann R, Zimmerli W, Fluckiger U. Transcription of clumping factor A in attached and unattached *Staphylococcus aureus* in vitro and during device-related infection. *Infect Immunol* 2002;70:2758-62.
24. Zimmerli W, Waldvogel FA, Vaudaux P, Nydegger UE. Pathogenesis of foreign body infection: description and characteristics of an animal model. *J Infect Dis* 1982;146:487-97.
25. Zimmerli W, Lew PD, Waldvogel FA. Pathogenesis of foreign body infection: evidence for a local granulocyte defect. *J Clin Invest* 1984;73:1191-200.
26. Kaplan SS, Heine RP, Simmons RL. Defensins impair phagocytic killing by neutrophils in biomaterial-related infection. *Infect Immun* 1999;67:1640-5.
27. Zimmerli W, Zak O, Vosbeck K. Experimental hematogenous infection of subcutaneously implanted foreign bodies. *Scand J Infect Dis* 1985;17:303-10.
28. Murdoch DR, Roberts SA, Fowler VG Jr, et al. Infection of orthopedic prostheses after *Staphylococcus aureus* bacteremia. *Clin Infect Dis* 2001;32:647-9.
29. Schafroth M, Zimmerli W, Brunazzi M, Ochsner PE. Infections. In: Ochsner PE, ed. *Total hip replacement*. Berlin: Springer-Verlag, 2003:65-90.
30. Maderazo EG, Judson S, Pasternak H. Late infections of total joint prostheses: a review and recommendations for prevention. *Clin Orthop* 1988;229:131-42.
31. Giulieri SG, Graber P, Ochsner PE, Zimmerli W. Management of infection associated with total hip arthroplasty according to a treatment algorithm. *Infection* 2004;32:222-8.
32. Shih LY, Wu JJ, Yang DJ. Erythrocyte sedimentation rate and C-reactive protein values in patients with total hip arthroplasty. *Clin Orthop* 1987;225:238-46.
33. Trampuz A, Hanssen AD, Osmon DR, Mandrekar J, Steckelberg JM, Patel R. Synovial fluid leukocyte count and differential for the diagnosis of prosthetic knee infection. *Am J Med* 2004;117:556-62.
34. Trampuz A, Steckelberg JM, Osmon DR, Cockerill FR, Hanssen AD, Patel R. Advances in the laboratory diagnosis of prosthetic joint infection. *Rev Med Microbiol* 2003;14:1-14.
35. Atkins BL, Athanasou N, Deeks JJ, et al. Prospective evaluation of criteria for microbiological diagnosis of prosthetic-joint infection at revision arthroplasty. *J Clin Microbiol* 1998;36:2932-9.
36. Spangehl MJ, Masri BA, O'Connell JX, Duncan CP. Prospective analysis of preoperative and intraoperative investigations for the diagnosis of infection at the sites of two hundred and two revision total hip arthroplasties. *J Bone Joint Surg Am* 1999;81:672-83.
37. Proctor RA. Microbial pathogenic factors: small-colony variants. In: Waldvogel FA, Bisno AL, eds. *Infections associated with indwelling medical devices*. 3rd ed. Washington, D.C.: American Society for Microbiology, 2000:41-54.
38. Tigges S, Stiles RG, Roberson JR. Appearance of septic hip prostheses on plain radiographs. *AJR Am J Roentgenol* 1994;163:377-80.
39. Smith SL, Wastie ML, Forster I. Radionuclide bone scintigraphy in the detection of significant complications after total knee joint replacement. *Clin Radiol* 2001;56:221-4.
40. Hain SF, O'Doherty MJ, Smith MA. Functional imaging and the orthopaedic surgeon. *J Bone Joint Surg Br* 2002;84:315-21.
41. Ivancevic V, Perka C, Hasart O, Sandrock D, Munz DL, Ivancevic V. Imaging of low-grade bone infection with a technetium-99m labelled monoclonal anti-NCA-90 Fab' fragment in patients with previous joint surgery. *Eur J Nucl Med Mol Imaging* 2002;29:547-51. [Erratum, *Eur J Nucl Med Mol Imaging* 2002;29:835.]
42. Love C, Pugliese PV, Afriyie MO, Tomas MB, Marwin SE, Palestro CJ. Utility of F-18 FDG imaging for diagnosing the infected joint replacement. *Clin Positron Imaging* 2000;3:159.
43. Westrich GH, Salvati EA, Brause B. Postoperative infection. In: Bono JV, McCarty JC, Thornhill TS, Bierbaum BE, Turner RH, eds. *Revision total hip arthroplasty*. New York: Springer-Verlag, 1999:371-90.
44. Langlais F. Can we improve the results of revision arthroplasty for infected total hip replacement? *J Bone Joint Surg Br* 2003;85:637-40.
45. Tsukayama DT, Wicklund B, Gustilo RB. Suppressive antibiotic therapy in chronic prosthetic joint infections. *Orthopedics* 1991;14:841-4.
46. Widmer AF, Wiestner A, Frei R, Zimmerli W. Killing of nongrowing and adherent *Escherichia coli* determines drug efficacy in device-related infections. *Antimicrob Agents Chemother* 1991;35:741-6.
47. Widmer AF, Frei R, Rajacic Z, Zimmerli W. Correlation between in vivo and in vitro efficacy of antimicrobial agents against foreign body infections. *J Infect Dis* 1990;162:96-102.
48. Zimmerli W, Widmer AF, Blatter M, Frei R, Ochsner PE. Role of rifampin for treatment of orthopedic implant-related staphylococcal infections: a randomized controlled trial. *JAMA* 1998;279:1537-41.
49. Zimmerli W, Frei R, Widmer AF, Rajacic Z. Microbiological tests to predict treatment outcome in experimental device-related infections due to *Staphylococcus aureus*. *J Antimicrob Chemother* 1994;33:959-67.
50. Schwank S, Rajacic Z, Zimmerli W, Blaser J. Impact of bacterial biofilm formation

- on in vitro and in vivo activities of antibiotics. *Antimicrob Agents Chemother* 1998; 42:895-8.
51. Widmer AE, Gaechter A, Ochsner PE, Zimmerli W. Antimicrobial treatment of orthopedic implant-related infections with rifampin combinations. *Clin Infect Dis* 1992; 14:1251-3.
 52. Drancourt M, Stein A, Argenson JN, Roiron R, Groulier P, Raoult D. Oral treatment of *Staphylococcus* spp. infected orthopaedic implants with fusidic acid or ofloxacin in combination with rifampicin. *J Antimicrob Chemother* 1997;39:235-40.
 53. Kadurugamuwa JL, Sin LV, Yu J, Francis KP, Purchio TF, Contag PR. Noninvasive optical imaging method to evaluate postantibiotic effects on biofilm infection in vivo. *Antimicrob Agents Chemother* 2004;48:2283-7.
 54. Drancourt M, Stein A, Argenson JN, Zannier A, Curvale G, Raoult D. Oral rifampin plus ofloxacin for treatment of *Staphylococcus*-infected orthopedic implants. *Antimicrob Agents Chemother* 1993;37:1214-8.
 55. Osmon DR, Berbari EF. Outpatient intravenous antimicrobial therapy for the practicing orthopaedic surgeon. *Clin Orthop* 2002; 403:80-6.
 56. Fisman DN, Reilly DT, Karchmer AW, Goldie SJ. Clinical effectiveness and cost-effectiveness of 2 management strategies for infected total hip arthroplasty in the elderly. *Clin Infect Dis* 2001;32:419-30.
 57. Trebbe R, Pisot V, Trampuz A. Treatment of orthopedic device-associated infections with implant retention. *J Bone Joint Surg Br* (in press).
 58. Tsukayama DT, Estrada R, Gustilo RB. Infection after total hip arthroplasty: a study of the treatment of one hundred and six infections. *J Bone Joint Surg Am* 1996;78:512-23.
 59. Schoifet SD, Morrey BF. Treatment of infection after total knee arthroplasty by debridement with retention of the components. *J Bone Joint Surg Am* 1990;72:1383-90.
 60. Crockarell JR, Hanssen AD, Osmon DR, Morrey BF. Treatment of infection with debridement and retention of the components following hip arthroplasty. *J Bone Joint Surg Am* 1998;80:1306-13.
 61. Deirmengian C, Greenbaum J, Lotke PA, Booth RE Jr, Lonner JH. Limited success with open debridement and retention of components in the treatment of acute *Staphylococcus aureus* infections after total knee arthroplasty. *J Arthroplasty* 2003;Suppl 1:18:22-6.
 62. Ure KJ, Amstutz HC, Nasser S, Schmalzried TP. Direct-exchange arthroplasty for the treatment of infection after total hip replacement: an average ten-year follow-up. *J Bone Joint Surg Am* 1998;80: 961-8.
 63. Hope PG, Kristinsson KG, Norman P, Elson RA. Deep infection of cemented total hip arthroplasties caused by coagulase-negative staphylococci. *J Bone Joint Surg Br* 1989;71:851-5.
 64. Raut VV, Siney PD, Wroblewski BM. One-stage revision of infected total hip replacements with discharging sinuses. *J Bone Joint Surg Br* 1994;76:721-4.
 65. Callaghan JJ, Katz RP, Johnston RC. One-stage revision surgery of the infected hip: a minimum 10-year followup study. *Clin Orthop* 1999;369:139-43.
 66. Windsor RE, Insall JN, Urs WK, Miller DV, Brause BD. Two-stage reimplantation for the salvage of total knee arthroplasty complicated by infection: further follow-up and refinement of indications. *J Bone Joint Surg Am* 1990;72:272-8.
 67. Colyer RA, Capello WN. Surgical treatment of the infected hip implant: two-stage reimplantation with a one-month interval. *Clin Orthop* 1994;298:75-9.
 68. American Academy of Orthopaedic Surgeons. Antibiotic prophylaxis for dental patients with total joint replacements. Document no. 1014. (Accessed September 17, 2004, at <http://www.aaos.org/wordhtml/papers/advistmt/1014.htm>.)
 69. *Idem*. Antibiotic prophylaxis for urological patients with total joint replacements. Document no. 1023. (Accessed September 17, 2004, at <http://www.aaos.org/wordhtml/papers/advistmt/1023.htm>.)
 70. Trampuz A, Osmon DR, Hanssen AD, Steckelberg JM, Patel R. Molecular and antibiofilm approaches to prosthetic joint infection. *Clin Orthop* 2003;414:69-88.

Copyright © 2004 Massachusetts Medical Society.

CLINICAL PROBLEM-SOLVING SERIES

The *Journal* welcomes submissions of manuscripts for the Clinical Problem-Solving series. This regular feature considers the step-by-step process of clinical decision making. For more information, please see <http://authors.nejm.org>.