

Protective Effect of Quercetin Against Renal Toxicity Induced by Cadmium in Rats

Tevfik Aktoz¹, Mehmet Kanter², Yeşim Hülya Uz², Cevat Aktaş³, Mustafa Erboğa², İrfan Hüseyin Atakan¹

¹Department of Urology, Faculty of Medicine, Trakya University, Edirne, Turkey

²Department of Histology and Embryology, Faculty of Medicine, Trakya University, Edirne, Turkey

³Department of Histology and Embryology, Faculty of Medicine, Namık Kemal University, Tekirdağ, Turkey

ABSTRACT

Objective: The aim of the present study was to examine the protective effect of quercetin (QE) against cadmium (Cd)-induced renal toxicity.

Material and Methods: A total of 24 male Wistar albino rats were divided into three groups: control, Cd-treated and Cd-treated with QE; each group containing 8 animals. The Cd-treated group was injected subcutaneously with CdCl₂ dissolved in saline in the dose of 2 ml/kg/day for 30 days, resulting in a dosage of 1 mg/kg Cd. The rats in the QE treated groups were given QE (15 mg/kg body weight) once a day intraperitoneally starting 2 days prior to Cd injection during the study period.

Results: The renal histology in Cd-treated rats showed mesangial expansion, thickening of capsular basement membranes, glomerular basement membranes and tubular basement membranes, characterized by an increase in periodic acid Schiff (PAS)-positive areas as compared with control animals. With the QE treatment, despite the presence of only a few swollen glomeruli, we noticed a marked protection of renal structure when compared with the Cd-treated rats. Furthermore, QE pretreatment resulted in increased proliferating cell nuclear antigen (PCNA) immunoreactivity and decreased the activity of Terminal Transferase dUTP Nick End Labeling (TUNEL).

Conclusion: These findings suggest that QE may attenuate Cd-induced renal toxicity.

Key Words: Cadmium, immunohistochemistry, quercetin, renal toxicity, TUNEL

Received: 13.01.2011

Accepted: 14.04.2011

Introduction

Cadmium (Cd) is a heavy metal present in air, water, soils, and sediments (1, 2). Cd accumulates largely in the liver and kidney and produces pulmonary, liver, and renal tubular diseases. Chronic intake of Cd in food or in air produces organ dysfunction as a result of cell death (3). Cd is widely used in pigments, plastic stabilizers, electroplating, alloys, nickel-Cd batteries, and welding in industry and is also present in tobacco (4, 5). Natural sources of Cd are spread into the atmosphere by volcanic activity, forest fires, and wind-blown transport of soil particles. Other sources are phosphate fertilizers, which may contain high concentrations of Cd, depending on the origin of the rock, and the application of contaminated sewage sludge as a soil additive (1). It has been demonstrated that the kidney is one of the most critically affected organs following long-term environmental and occupational exposure to Cd (1, 6). Cd-induced nephropathy is characterized functionally by various signs of tubular dysfunction, such as low molecular weight proteinuria, glucosuria, and aminoaciduria, and pathologically by chronic interstitial nephritis (6).

Flavonoids are a group of naturally occurring compounds widely distributed as secondary metabolites in the plant

kingdom. They are recognized as having interesting clinical properties, such as anti-inflammatory, antiallergic, antiviral, antibacterial, and antitumoral activities [7]. One of these flavonoids, quercetin (QE) (3, 5, 7, 3', 4'-pentahydroxyflavone), prevents oxidant injury and cell death by several mechanisms, such as scavenging oxygen radicals, protecting against lipid peroxidation and chelating metal ions (8-10).

The aim of the present study was to examine the protective effect of QE against Cd-induced renal toxicity.

Material and Methods

Animals

Twenty four healthy male Wistar albino rats, (weighing 200-250 g and averaging 16 weeks old) housed at the Trakya University Animal Care and Research Unit, were used for this study. Food and tap water were available ad libitum. In the windowless animal quarter automatic temperature (21±1°C) and lighting controls (12 h light/12 h dark cycle) were maintained. Humidity ranged from 55% to 60%. All animals received humane care according to the criteria outlined in the "Guide for the Care and Use of Laboratory Animals" prepared by the National Academy of Sciences and published by

the National Institutes of Health. In addition, the experimental protocol was approved by the Ethical Committee of Trakya University Medical Faculty (approved date and number: 05/01/2011 and 2011.01.010). QE was obtained from Sigma Chemical (St Louis, MO, USA) and dissolved in 0.5 ml of 60% ethanol just before intraperitoneal (i.p.) injection (15 mg/kg). The control group was injected with the same volume of saline as the Cd treated groups received.

Experimental groups

A total of 24 male Wistar albino rats were divided into three groups: control, Cd-treated and Cd-treated with QE; each group containing 8 animals. Control animals received daily injections of the saline vehicle alone. The Cd-treated group were injected subcutaneously with CdCl₂ dissolved in saline at a dose of 2 ml/kg/day for 30 days, resulting in a dosage of 1 mg/kg Cd (11). The rats in QE treated groups were given QE (15 mg/kg body weight) once a day intraperitoneally starting 2 days prior to the Cd injection during the study period. At the end of the study, all animals were anesthetized with an i.p. injection of sodium thiopental (100 mg/kg, Sigma, St. Louis, MO, USA). After twenty minutes, the anesthetized rats were sacrificed and renal tissues were removed for histopathological investigation.

Histopathologic evaluation

The renal tissues were individually immersed in Bouin's fixative, dehydrated in alcohol and embedded in paraffin. Sections of 5 µm were obtained, deparaffinized and stained with hematoxylin and eosin (H&E) and periodic acid Schiff (PAS). The renal tissue was examined and evaluated in random order under blindfold conditions with standard light microscopy.

The thickening of the renal basement membrane was scored in a semiquantitative manner in order to determine the differences between the control group and the experimental groups. The thickening of the renal basement membrane was recorded as normal (+), thick (++) , very thick (+++) and extremely thick (++++). These analyses were performed in two sections from each animal at x400 magnification in at least ten different regions for each section.

Immunohistochemistry

The harvested renal tissues were fixed in Bouin's, embedded in paraffin and sectioned at 5 µm thickness. Immunohistochemical reactions were performed according to the ABC technique described by Hsu et al. (12). The procedure involved the following steps: (1) endogenous peroxidase activity was inhibited by 3% H₂O₂ in distilled water for 30 min; (2) the sections were washed in distilled water for 10 min; (3) non-specific binding of antibodies was blocked by incubation with normal goat serum (DAKOX0907, Carpinteria, CA) with phosphate-buffered saline (PBS), diluted 1:4 (4). The sections were incubated with specific mouse monoclonal anti-PCNA antibody (Cat. # MS-106-B, Thermo LabVision, USA), diluted 1:50 for 1h at room temperature; (5) then washed in PBS 3×3min (6). The sections were incubated with biotinylated anti-mouse IgG (DAKO LSAB 2 Kit); (7) and were washed in PBS 3×3 min; (8) then incubated with ABC complex (DAKO LSAB

2 Kit) (9). The sections were washed in PBS 3×3 min; (10) peroxidase was detected with an aminoethylcarbazole substrate kit (AEC kit; Zymed Laboratories); (11) the sections were then washed in tap water for 10 min and then dehydrated; (12) the nuclei were stained with hematoxylin; and (13) the sections were mounted in DAKO paramount. All dilutions and thorough washes between steps were performed using PBS unless otherwise specified. All steps were carried out at room temperature. As a negative control, the primary antibody was replaced with PBS.

TUNEL assay

The TUNEL method, which detects fragmentation of DNA in the nucleus during apoptotic cell death in situ, was employed using an apoptosis detection kit (TdT-Fragel™ DNA Fragmentation Detection Kit, Cat. No. QIA33, Calbiochem, USA). All reagents listed below are from the kit and were prepared following the manufacturer's instructions. 5-µm-thick renal sections were deparaffinized in xylene and rehydrated through a graded ethanol series as described previously. They were then incubated with 20 mg/ml proteinase K for 20 minutes and rinsed in TBS. Endogenous peroxidase activity was inhibited by incubation with 3% hydrogen peroxide. Sections were then incubated with equilibration buffer for 10-30 minutes and then TdT-enzyme, in a humidified atmosphere at 37°C, for 90 minutes. They were subsequently put into pre-warmed working strength stop/wash buffer at room temperature for 10 minutes and incubated with blocking buffer for 30 minutes. Each step was separated by thorough washes in TBS. Labelling was shown using DAB, counter staining was performed using methyl green, and sections were dehydrated, cleared and mounted.

The number of PCNA and TUNEL positive cells in each specimen was also scored. Ten randomly selected areas were scored for each specimen in every experiment as follows: 0=no positive response; 1=less than 10% of cells; 2=11-20% of cells; 3=21-40% of cells; 4 =more than 40% of cells.

Statistical analysis

All statistical analyses were carried out using SPSS statistical software (SPSS for windows, version 11.0). All data were presented in mean (±) standard deviations (S.D.). Differences in measured parameters among the three groups were analyzed with a nonparametric test (Kruskal-Wallis). Dual comparisons between groups exhibiting significant values were evaluated with a Mann-Whitney U-test. These differences were considered significant when probability was less than 0.05.

Results

Histopathological findings

Normal structure of the renal cortical tissue was observed in control rats (Figure 1a). The animals exposed to Cd showed severe changes in the renal tubules and glomeruli. Hypertrophy and degeneration of renal tubules epithelia with infiltration of mononuclear cells, increased amounts of mesangial matrix and dilatation of glomeruli were evident in all animals treated with Cd (Figure 1b). With the QE treatment, despite

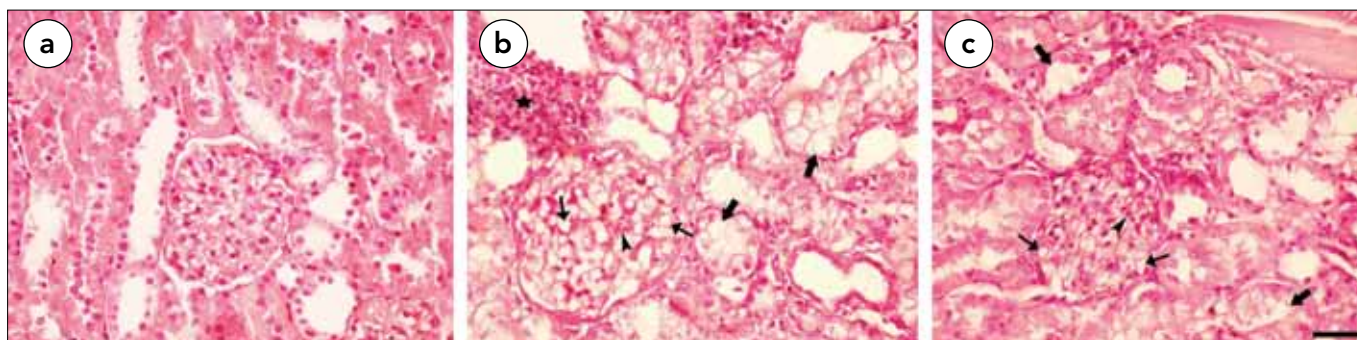


Figure 1. Light microscopy of renal cortical tissues in different groups. (a) In controls, normal renal cortical tissue architecture was seen; (b) In Cd-treated group, increased amounts of mesangial matrix, dilatation of glomeruli, tubuli and mononuclear cell infiltration; (c) Treatment of QE reduced the amounts of mesangial matrix, dilatation of glomeruli, tubuli and mononuclear cell infiltration (arrow head: mesangial matrix, thin arrows: glomerular dilatation, thick arrows: tubular dilatation, asterisk: mononuclear cell infiltration), (H&E, scale bar, 50 μ m)

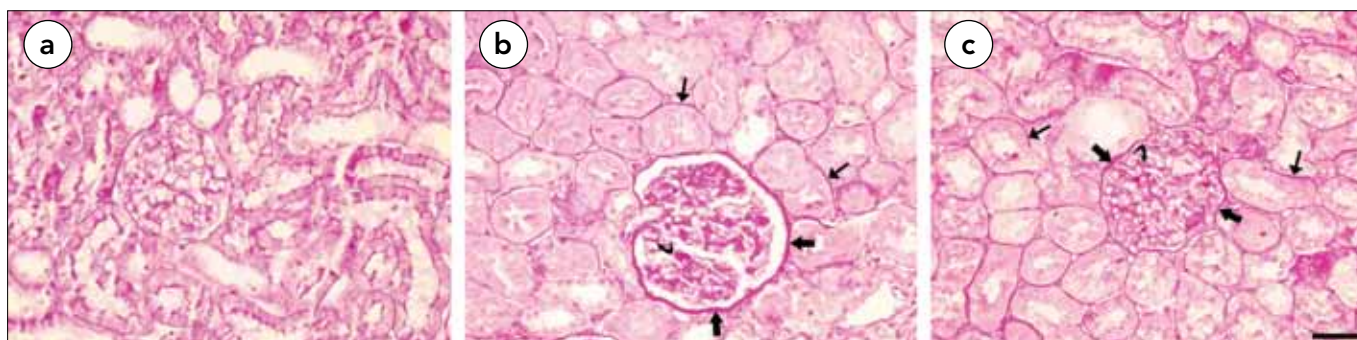


Figure 2. Light microscopy of renal cortical tissues in different groups. (a) In controls, normal renal cortical architecture was seen; (b,c) Decreased the thickened CBMs, GBMs and TBMs in Cd-treated with QE rats as compared with Cd-treated rats. (oblique arrows: CBMs PAS positive area, thick arrows: TBMs PAS positive area, thin arrows: GBMs PAS positive area), (PAS, scale bar, 50 μ m)

the presence of only a few swollen glomeruli and tubuli, we noticed a marked protection in renal structure when compared with the Cd-treated rats (Figure 1c). Moreover, the renal histology in Cd-treated rats showed an enlargement of the glomeruli, mesangial expansion, thickening of capsular basement membranes (CBMs), glomerular basement membranes (GBMs), and tubular basement membranes (TBMs), characterized by an increase in PAS-positive area as compared with control animals (Figure 2a, b). Treatment of QE reduced the glomerular size, thickening of CBMs, GBMs and TBMs as compared with the Cd-treated group (Figure 2c; Table 1).

Immunohistochemical findings

PCNA-positive cells were strongly detected in the renal cortical tissues of the control rats (Figure 3a). However, the signal density of positive cells was significantly higher in the Cd-treated group (Figure 3b). Treatment of QE markedly increased the reactivity of PCNA in the renal cortical tissues (Figure 3c; Table 2).

TUNEL findings

The number of TUNEL-positive cells in the control group was negligible (Figure 4a). When kidney sections were TUNEL stained, there was a clear increase in the number of positive cells in the Cd-treated rats in the renal cortical tissues (Figure

Table 1. Semiquantitative comparison of the thickening of renal basement membrane in control, Cd-treated and Cd-treated with QE groups

	Control	Cd-treated	Cd-treated with QE
Basement membrane thickening	+	++++	++
The thickening of the renal basement membrane was recorded as normal (+), thick (++) , very thick (+++) and extremely thick (++++) (n: 8 for each group)			

4b). Treatment of QE markedly reduced the reactivity and the number of TUNEL positive cells (Figure 4c, Table 2).

Discussion

Cd is a toxic, industrial and environmental metal (2, 5, 13, 14). The major environmental source of Cd for humans and animals is food and drinking water (15). With increasing production and utilization of Cd, not only industrial workers, but also the general population are also exposed to the toxic effects of Cd. It has been found that Cd produces various pathological conditions, including hepatic and renal dysfunctions, testicular damage, and respiratory and nervous system disorders (13, 14,

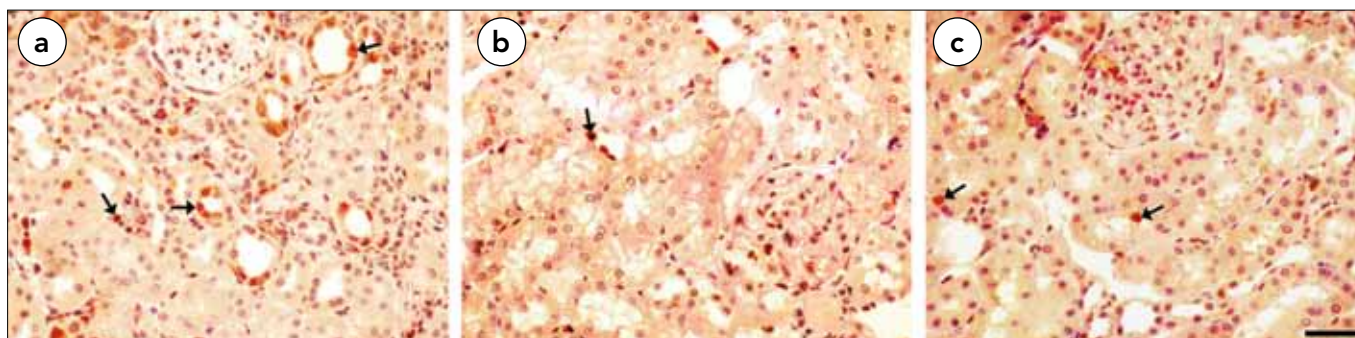


Figure 3. PCNA expression of renal cortical tissues in different groups. (a, b) PCNA-positive cells were decreased in the renal cortical tissues in the Cd-treated group as compared with the control group. (c) PCNA-positive cells were significantly increased in the Cd-treated with QE group. (Arrow: PCNA positive cells) (Immunoperoxidase, haematoxylin counterstain, scale bar, 50 μm)

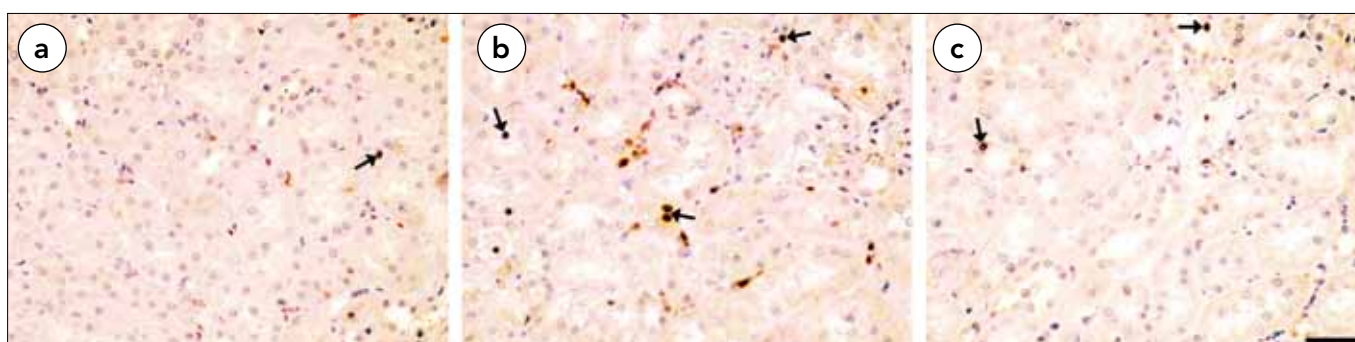


Figure 4. TUNEL staining of renal cortical tissues in different groups. (a) In the control group, a few TUNEL-positive cells were observed in the renal cortical tissues; (b) The positive cells were significantly higher in the renal cortical tissues of the Cd-treated group; (c) Treatment of QE markedly decreased the reactivity of TUNEL. (Arrow: TUNEL positive cells), (TUNEL, scale bar, 50 μm)

Table 2. Positive staining of PCNA and TUNEL cell numbers in renal cortical tissues for each group. Control, Cd-treated and Cd-treated with QE

	Control	Cd-treated	Cd-treated with QE
PCNA	3.27±0.42	0.96±0.11 ^a	2.36±0.14 ^c
TUNEL	0.08±0.01	2.72±0.17 ^b	0.86±0.07 ^d

Kruskal-Wallis test was used for statistical analysis. Values are expressed as means±SD, n = 8 for each group

^ap<0.001 compared with control group, ^bp<0.0001 compared with control group, ^cp<0.01 compared with control group, ^dp<0.01 compared with control group

16, 17). Cd induced chronic toxicity has been shown as histological and ultrastructural by various investigators in experiments using various species of animals (18, 19). During acute exposure, Cd-induced necrosis and cellular damage are produced in the kidney, liver and testicular tissue; chronic exposure results in damage to the kidney, pancreas, and bone (20).

Cd injection in rats also affects the genito-urinary system. The kidney is a critical target organ following Cd exposure (14). Renal metabolism is perturbed in both acute and chronic exposure. Adaptive mechanisms counteract renal tubular acidosis during chronic, but not following acute, exposure. Following chronic exposure, the kidney also shows an altera-

tion in lipid content, possibly caused by mitochondrial proliferation (20). The renal effects are generally considered to be mainly tubular. Scott et al. (11) showed cellular damage in the glomeruli with changes in glomerular capillaries by light microscopy. Chronic Cd exposure caused a nephropathy with peculiar damage of the renal proximal tubule. Atrophy and degeneration of proximal tubules with vacuolization of tubular cells were the most striking lesions seen (21). Cd exposure has been shown to cause large cytoplasmic vacuoles containing membranous material in proximal tubular lining cells. Light microscopy shows focal areas of necrosis and interstitial fibrosis within the renal cortex. These findings are associated with renal Cd levels (22). With increasing Cd doses, the size of nuclei and nucleoli in the cells of the proximal tubule shows significant enlargement and also an increase in the number of nucleoli on light microscopy. In the present study, the renal histology in Cd-treated rats showed mesangial expansion, thickening of capsular basement membranes, glomerular basement membranes and tubular basement membranes, characterized by an increase in PAS-positive areas as compared with control animals. With the QE treatment, despite the presence of only a few swollen glomeruli and tubuli, we noticed a marked protection in renal structure when compared with the Cd-treated rats. These findings are in agreement with the results of above mentioned investigators on Cd-induced renal toxicity in rats.

In a recent study (23), PCNA-immunoreactive cells were preferentially detected in the degenerating proximal tubular lesions observed histopathologically in animals treated with CdCl₂ at 200 and 600 ppm. Significantly, increases in PCNA were also found in these high-dose Cd-treated groups. In the experiment, the severity of proximal tubular degeneration and the mitotic figures in such degenerating tubules correlated well with both renal Cd-concentrations and PCNA in the proximal tubular epithelium. To date, no PCNA expression on Cd-induced renal toxicity in rats by QE treatment have been reported. In the present study, the signal density of positive cells was significantly higher in Cd-treated group. Treatment with QE markedly increased the reactivity of PCNA in the renal cortical tissues.

Both necrotic and apoptotic mechanisms have been implicated in the pathways leading to the death of proximal tubule epithelial cells during exposure to Cd. High levels of Cd are clearly capable of causing proximal tubule necrosis (22, 24). However, other studies indicate that the early stages of Cd nephrotoxicity primarily involve apoptosis of proximal tubule epithelial cells, with little evidence of necrosis (25, 26). Moreover, results of several recent studies suggest that the early stages of Cd-nephrotoxicity may involve changes in cell adhesion molecule function and cytoskeletal organization that occur before the onset of either necrotic or apoptotic death of proximal tubule epithelial cells (27, 28).

Recently, Iwai and Matsuno (29) have shown that chronic Cd exposure induces apoptosis and subsequent regeneration of the renal tubular epithelium in rats and beagle dogs, respectively. Apoptosis, a distinctive form of cell death, which occurs in various tissues under certain physiological or pathological conditions (30), differs obviously from necrosis. Thus, since apoptosis may be one of the main features of Cd intoxication, it seems necessary to conduct more effective studies on the phenomenon in the tubular epithelium after exposure to higher doses of Cd. In one study (26), the basement membrane was intact and no macrophages infiltration was found in tubular epithelium. Furthermore, since the regenerating tubular cells actively proliferated and replaced the epithelium, the dead cells seemed to be pushed out into the tubular lumen. The cell interfaces between the regenerating cells and the dead cells were simple without any cytoplasmic infoldings or junctional complexes. In vitro experimental studies using proximal tubular cells have shown that Cd damages F-actin and disrupts intercellular junctions (31). These junctional changes might result in easy detachment of dead cells from the tubular lining.

In a more recent study, Aoyagi et al. (25) noted an increase in the number of TUNEL-labeled cells in the renal cortex of Cd treated rats after 4 and 5 weeks of exposure, but the level of apoptotic labeling was much less pronounced after 6 and 8 weeks of exposure. However, no quantitative data was included in their analysis. In our present study, the number of TUNEL positive cells was semi-quantitatively higher in the Cd-treated group than the control group. Treatment with QE markedly reduced the reactivity and the number of TUNEL positive cells. In conclusion, these findings suggest that QE may attenuate Cd-induced renal toxicity.

Conflict of Interest

No conflict of interest was declared by the authors.

References

1. Waisberg M, Joseph P, Hale B, Beyersmann D. Molecular and cellular mechanisms of cadmium carcinogenesis. *Toxicology* 2003;192:95-117. [CrossRef]
2. Koçak M, Akçil E. The effects of chronic cadmium toxicity on the hemostatic system. *Pathophysiol Haemost Thromb* 2006;35:411-6. [CrossRef]
3. Kim SC, Cho MK, Kim SG. Cadmium-induced nonapoptotic cell death mediated by oxidative stress under the condition of sulfhydryl deficiency. *Toxicol Lett* 2003;144:325-36. [CrossRef]
4. Ohta H, Yamauchi Y, Nakakita M, Tanaka H, Asami S, Seki Y, et al. Relationship between renal dysfunction and bone metabolism disorder in male rats after long-term oral quantitative cadmium administration. *Industr Health* 2000;38:339-55. [CrossRef]
5. Washington B, Williams S, Armstrong P, Mtshali C, Robinson JT, Myles EL. Cadmium toxicity on arteriolar vascular smooth muscle cells of spontaneously hypertensive rats. *Int J Environ Res Public Health* 2006;3:232-8. [CrossRef]
6. Bernard A, Lauwerys R. Effects of cadmium exposure in humans. In *Handbook of Experimental Pharmacology* (E. C. Foulkes, Ed.), Springer-Verlag, Heidelberg 1986;135-77.
7. Middleton E Jr. Effect of plant flavonoids on immune and inflammatory cell function. *Adv Exp Med Biol* 1998;439:175-82. [CrossRef]
8. Inal ME, Akgun A, Kahraman A. Radioprotective effects of exogenous glutathione against whole-body gamma-ray irradiation: age- and gender-related changes in malondialdehyde levels, superoxide dismutase and catalase activities in rat liver. *Methods Find Exp Clin Pharmacol* 2002;24:209-12. [CrossRef]
9. Laughton MJ, Evans PJ, Moroney MA, Hoult JR, Halliwell B. Inhibition of mammalian 5-lipoxygenase and cyclo-oxygenase by flavonoids and phenolic dietary additives. Relationship to antioxidant activity and to iron ion-reducing ability. *Biochem Pharmacol* 1991;42:1673-81. [CrossRef]
10. Afanas'ev IB, Dorozhko I, Brodskii AV, Korstyuk VA, Potapovitch A. Chelating and free radical scavenging mechanisms of inhibitory action of rutin and quercetin in lipid peroxidation. *Biochem Pharmacol* 1989;38:1763-9. [CrossRef]
11. Scott R, Aughey E, Sinclair J. Histological and ultrastructural changes in rat kidney following cadmium injection. *Urol Res* 1977;5:15-20. [CrossRef]
12. Hsu SM, Raine L, Fanger H. Use of avidin-biotin-peroxidase complex (ABC) in immunoperoxidase techniques: a comparison between ABC and unlabeled antibody (PAP) procedures. *J Histochem Cytochem* 1981;29:577-80. [CrossRef]
13. Yiin SJ, Chern CL, Sheu JY, Lin TH. Cadmium-induced lipid peroxidation in rat testes and protection by selenium. *Biomaterials* 1999;12:353-9. [CrossRef]
14. Yiin SJ, Chern CL, Sheu JY, Tseng WC, Lin TH. Cadmium-induced renal lipid peroxidation in rats and protection by selenium. *J Toxicol Environ Health* 1999;57:403-13. [CrossRef]
15. Ohta H, Cherian MG. Gastrointestinal absorption of cadmium and metallothionein. *Toxicol Appl Pharmacol* 1991;107:63-72. [CrossRef]
16. Nigam D, Shukla GS, Agarwal AK. Glutathione depletion and oxidative damage in mitochondria following exposure to cadmium in rat liver and kidney. *Toxicol Lett* 1999;106:151-7. [CrossRef]
17. Newairy AA, El-Sharaky AS, Badreldeen MM, Eweda SM, Sheweita SA. The hepatoprotective effects of selenium against cadmium toxicity in rats. *Toxicology* 2007;242:23-30. [CrossRef]
18. Asar M, Kayisli UA, Izgut-Uysal VN, Akkoyunlu G. Immunohistochemical and ultrastructural changes in the renal cortex of cadmium-treated rats. *Biol Trace Elem Res* 2004;97:249-63. [CrossRef]

19. Takaki A, Jimi S, Segawa M, Hisano S, Takebayashi S, Iwasaki H. Longterm cadmium exposure accelerates age-related mitochondrial changes in renal epithelial cells. *Toxicology* 2004;203:145-54. [\[CrossRef\]](#)
20. Griffin JL, Walker LA, Shore R, Nicholson JK. Metabolic profiling of chronic cadmium exposure in the rat. *Chem Res Toxicol* 2001;14:1428-34. [\[CrossRef\]](#)
21. Gatta A, Bazerla G, Amodio P, Menon F, Angeli P, Schiaffino E, et al. Detection of the early steps of cadmium nephropathy-comparison of light- and electron-microscopical patterns with the urinary enzymes excretion. An experimental study. *Nephron* 1989;51:20-4. [\[CrossRef\]](#)
22. Goyer RA, Miller CR, Zhu S, Vicitry W. Non-metallothionein-bound cadmium in the pathogenesis of cadmium nephrotoxicity in the rat. *Toxicol Appl Pharmacol* 1989;101:232-44. [\[CrossRef\]](#)
23. Shibutani M, Mitsumori K, Niho N, Satoh S, Hiratsuka H, Satoh M, et al. Assessment of renal toxicity by analysis of regeneration of tubular epithelium in rats given low-dose cadmium chloride or cadmium-polluted rice for 22 months. *Arch Toxicol* 2000;74:571-7. [\[CrossRef\]](#)
24. Brzoska MM, Kaminski M, Supernak-Bobko D, Zwierz K, Moniuszko-Jakoniuk J. Changes in the structure and function of the kidney of rats chronically exposed to cadmium. I. Biochemical and histopathological studies. *Arch Toxicol* 2003;77:344-52.
25. Aoyagi T, Hayakawa K, Miyaji K, Ishikawa H, Hata M. Cadmium nephrotoxicity and evacuation from the body in a rat modeled subchronic intoxication. *Int J Urol* 2003;10:332-8. [\[CrossRef\]](#)
26. Tanimoto A, Hamada T, Koide O. Cell death and regeneration of renal proximal tubular cells in rats with subchronic cadmium intoxication. *Toxicol Pathol* 1993;21:341-52. [\[CrossRef\]](#)
27. Jacquillet G, Barbier O, Cougnon M, Tauc M, Namorado MC, Martin D, et al. Zinc protects renal function during cadmium intoxication in the rat. *Am J Physiol Renal Physiol* 2006;290:F127-37. [\[CrossRef\]](#)
28. Prozialeck WC, Vaidya VS, Liu J, Waalkes MP, Edwards JR, Lamar PC, et al. Kidney injury molecule-1 (Kim-1) as an early biomarker of cadmium nephrotoxicity. *Kidney Int* 2007;72:985-93. [\[CrossRef\]](#)
29. Iwai S, Matsuno K. An ultrastructural study on cadmium-induced damage of the renal proximal tubules of rats. *J Med Soc Toho* 1991;137:757-71.
30. Walker NI, Harmon BV, Gobé GC, Kerr JF. Patterns of cell death. *Meth Archiev Exp Pathol* 1988;13:18-54.
31. Prozialeck WC, Niewcnhuis RJ. Cadmium (Cd²⁺) disrupts intercellularjunctions and actin filaments in LLC-PK1 cells. *Toxicol Appl Pliarmacol* 1991;107:81-97. [\[CrossRef\]](#)