

Protective effect of silymarin in streptozotocin-induced diabetic dyslipidaemia in rats

Manju Sharma^{1,*}, K. K. Pillai¹, Tarique Anwer¹, Abul Kalam Najmi¹, Syed Ehtaishamul Haque¹ and Yasmin Sultana²

¹Department of Pharmacology, Faculty of Pharmacy, Jamia Hamdard, (Hamdard University), New Delhi-110 062, India; ²Department of Pharmaceutics, Faculty of Pharmacy, Jamia Hamdard, (Hamdard University), New Delhi-110 062, India

Received for publication March 18, 2009; accepted July 23, 2010

SUMMARY

The present study investigated the effect of silymarin, a flavonoid, on streptozotocin (STZ) - induced diabetic dyslipidaemia in rats. Experimental diabetes was induced by a single intraperitoneal injection of STZ (60 mg/kg). Silymarin (25 mg/kg and 50 mg/kg) was orally administered to diabetic rats for a period of 15 days. Blood glucose levels, serum lipid profile and liver glycogen levels were estimated following the established procedures. Biochemical observations were supplemented with histological examination of liver sections. Oral administration of silymarin to diabetic rats significantly ($P < 0.001$) decreased the blood glucose levels (259.99 ± 23.64 vs. 99.90 ± 2.62 [25 mg] & 89.17 ± 3.32 [50 mg]). The most interesting finding was the significant ($p < 0.001$) increase in HDL-cholesterol levels (26.99 ± 0.61 vs. 40.55 ± 0.52 [25 mg] & 41.12 ± 0.37 [50 mg]) whereas, there was a significant decrease in serum total cholesterol (TCh), triglycerides (TG), low density lipoprotein (LDL) and very low density lipoprotein (VLDL) cholesterol levels observed in silymarin treated diabetic rats. STZ treatment caused significant degeneration of liver parenchyma, which was normalized to near normal morphology by administration of silymarin. The findings indicate that silymarin effectively improved the overall lipid profile and restored the glycogen stores in the liver of STZ-induced diabetic rats, in a dose dependent manner. The results indicate existence of abnormalities in lipid metabolism in STZ-induced diabetic rats and suggest a protective effect of silymarin in this animal model.

Key words: Diabetes mellitus; Silymarin; Streptozotocin; Dyslipidaemia; Liver glycogen

INTRODUCTION

Diabetes mellitus produces lipid abnormalities, which is the main risk factor for coronary heart disease (CHD) (Stamler *et al.*, 1993; Haffner, 1999).

*Correspondence: Manju Sharma, Department of Pharmacology, Faculty of Pharmacy, Jamia Hamdard (Hamdard University), New Delhi-110 062, India. Tel: +9111260596865648; Fax: +911126059663; E-mail: manju_sharma72@yahoo.com

In both types of diabetes, abnormalities of lipid metabolism are important, but the nature of these abnormalities is different and the therapeutic approach also differs. Elevated triglyceride (TG) level, reduced high density lipoprotein (HDL) cholesterol and a preponderance of small, dense low density lipoprotein (LDL) particles are the key abnormalities that constitute diabetic dyslipidaemia (Barrett-Connor *et al.*, 1982). Poor glycemic control exaggerates these abnormalities (Adeneye *et al.*,

2008). Early detection and treatment of elevated cholesterol levels is likely to be of benefit in these patients (Pyolara *et al.*, 1997). The management of dyslipidaemia, a well recognized and modifiable risk factor among patients with DM, is an important element in the multifactorial approach to prevent CVD (Schwartz, 2006). Any therapy that improves glycaemic control will improve diabetic dyslipidaemia. Thus treatment with insulin, sulfonylurea, metformin, acarbose and rosiglitazone has all been reported to improve lipid profile (Best and Neal, 2000).

Many plant extracts and some compounds purified from them have been reported to decrease blood glucose and reverse above mentioned abnormalities (Shukla *et al.*, 2000). Purified orally active compounds from fenugreek seeds, banyan tree bark, bitter gourd fruits and garlic bulbs have been extensively investigated in several Indian laboratories for their beneficial effect in diabetes hypercholesterolemia (Shukla *et al.*, 2004; Sathishekar and Subramanian, 2005). Silymarin is a flavonoid extracted from *Silybum marianum* L. (milk thistle) that grows in Europe and some parts of Asia including India. Silymarin contains 50 - 70% of flavolignans (silybin, silycristin, silydianin and isosilybin as the major constituents (Muriel *et al.*, 1992). Chemically the drug is 7, 8-dihydroxyflavone. It is commonly used as a hepatoprotective agent. It is a free radical scavenger and a membrane stabilizer that prevents lipid peroxidation and its associated cell damage in some experimental models (Muriel and Mourelle, 1990; Paya *et al.*, 1993). Silymarin has also been shown to prevent the damage induced by oxidative agents in hepatic membranes (Greimel and Koch, 1977), microsomes and mitochondria (Bindoli *et al.*, 1977). Furthermore, silybinin is reported to protect the exocrine pancreas from cyclosporin A toxicity (Schonfeld *et al.*, 1997). Beneficial effect of silymarin in improving the glycaemic profile in type 2 diabetic patients has also been reported (Huseini *et al.*, 2006). Silymarin, due to its antioxidant action has been found to be protective in alloxan induced diabetes (Soto *et al.*,

1998, Soto *et al.*, 2003) and anthracycline induced toxicity (Chlopeikova *et al.*, 2004). Recently we have demonstrated that silymarin provides protection against STZ-induced lipid peroxidation and β cell damage in rat pancreas possibly by inhibiting lipid peroxidation and scavenging the free radicals (Sharma *et al.*, 2008). These findings support the notion that possibly due to its antioxidant and membrane stabilizing properties silymarin is known to protect different organs and cells. However, the effect of silymarin on STZ-induced diabetic dyslipidaemia has not yet been studied. We therefore further investigated the effect of silymarin on STZ-induced diabetic dyslipidaemia in rats.

MATERIALS AND METHODS

Animals

Wistar rats weighing (150 - 200 g) were used for this study. They were kept in the animal house (Faculty of Pharmacy, Jamia Hamdard, New Delhi, India) for one week for proper acclimatization before starting the experiment under controlled condition of illumination (12 h light/12 h darkness) and temperature 20 - 25 °C. They were housed under ideal laboratory conditions, maintained on standard pellet diet (Lipton rat feed, Ltd; Pune) and water *ad libitum* throughout the experimental period. The experimental study was approved by the Institutional Animal Ethics Committee of Jamia Hamdard, New Delhi.

Drugs and chemicals

STZ was purchased from the Sigma Chemical Co. (USA). Silymarin (Silybon) was obtained from Microlabs Ltd., India. Glucose, cholesterol and triglycerides kits were procured from Span diagnostics, Surat, India. All the other chemicals used were of analytical grade.

Induction of diabetes

STZ in citrate buffer (pH - 4.5) was administered intraperitoneally (i.p.) at a single dose of 60 mg/kg

to groups II, III and IV. Three days after STZ treatment, development of diabetes was confirmed by measuring blood glucose level. Rats with blood glucose level of 200 mg/dl or higher were considered to be diabetic. Silymarin (25 and 50 mg/kg, p.o.) was given to STZ-diabetic rats for 15 days to group III and IV animals.

Experimental design

The rats were divided into four groups containing six animals in each group and received the following treatment.

- Group I: Normal control rats, received normal saline (1 ml/kg, p.o.) for 15 days
- Group II: Diabetic control rats, received STZ in a single dose (60 mg/kg, i.p.)
- Group III: Diabetic treated rats, received silymarin (25 mg/kg, p.o.) for 15 days
- Group IV: Diabetic treated rats, received silymarin (50 mg/kg, p.o.) for 15 days

Biochemical estimations

On the last day of experiment, blood samples were collected for biochemical estimations. Later the animals were sacrificed and livers were removed,

cleaned and washed in ice- cold normal saline for biochemical and histological study. Blood glucose was determined by glucose oxidase method (Braham and Trinder, 1972) using a commercial diagnostic kit from Span diagnostics Ltd. Surat, India. Serum was separated for assessment of lipid profile i.e. serum total cholesterol (Wybenga *et al.*, 1970), Serum triglycerides (Bucolo and David, 1973) and HDL-cholesterol (Warnick *et al.*, 1985) were estimated using diagnostic kits of Span Diagnostics, Surat, India. LDL and VLDL-cholesterol levels were calculated by the method of Friedwald *et al.*, (1972). The liver glycogen content was determined using the method of Montgomery (1957). The liver was isolated immediately after sacrificing the animal and washed with ice-cold saline. It was then fixed in 10% neutral buffered formalin solution. Sections of 3-5 μm thickness were stained with hematoxylin and eosin (H.E.) for histopathological examination.

Statistical analysis

Data were expressed as the mean \pm standard error (S.E) of the means. For a statistical analysis of the data, group means were compared by one-way analysis of variance (ANOVA) with post hoc analysis.

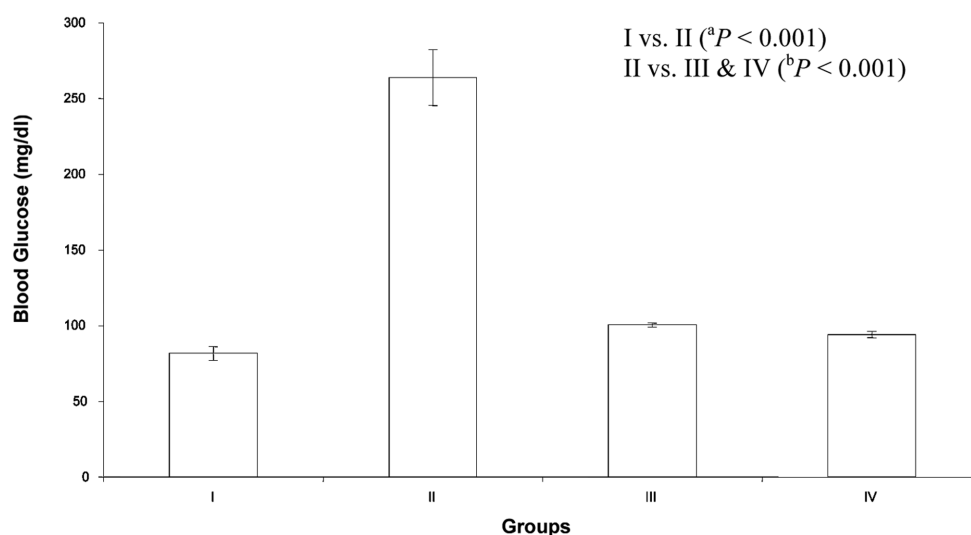


Fig. 1. Effect of silymarin on blood glucose level in STZ-induced diabetic rats. The data are expressed in mean \pm S.E. (n = 6). ^aP < 0.001 compared with the corresponding value for normal control group (group I). ^bP < 0.001 compared with diabetic control animals (group II).

The Tukey-Karmer test post hoc was applied to identify significance among groups. $P < 0.05$ was considered to be statistically significant.

RESULTS

Fig. 1. shows the effect of silymarin on blood glucose level. Significant ($P < 0.001$) increase in the blood glucose level was observed in animals treated with STZ when compared with normal control rats. Oral administration of silymarin at two doses (25 mg/kg and 50 mg/kg) reduced the blood glucose level significantly ($P < 0.001$).

Table 1 shows the effect of silymarin on the serum lipid profile. A significant increase ($P < 0.001$) in TCh, TG, LDL and VLDL-cholesterol levels were observed in STZ diabetic rats. Administration of silymarin at the doses of 25 mg/kg and 50 mg/kg significantly ($P < 0.001$) reduced the elevated levels of these cholesterol and triglycerides when compared with diabetic control rats. Diabetic animals treated with silymarin (50 mg/kg) had better effect in respect to the reduction in the level of serum cholesterol and triglycerides. The HDL-cholesterol level was decreased significantly ($P < 0.001$) in STZ diabetic rats when compared with normal control rats. Co-administration with silymarin in two doses increased the HDL-cholesterol level significantly ($P < 0.001$). Diabetic rats treated with silymarin (50 mg/kg) had almost same level of HDL cholesterol as of normoglycemic animals.

Effect of silymarin on liver glycogen content of different groups is shown in Fig. 2. Liver glycogen

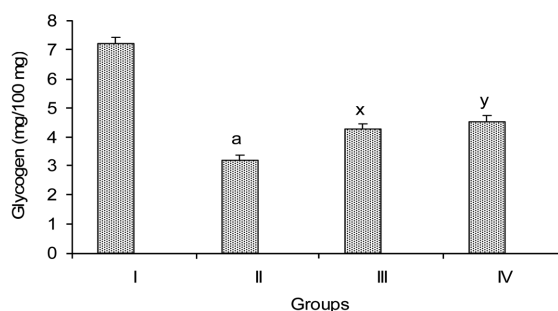


Fig. 2. Effect of silymarin on liver glycogen in streptozotocin-induced diabetic rats. The data are expressed as mean \pm S.E. ($n = 6$). ^a $P < 0.001$ when compared with normal control animals (group I). ^x $P < 0.05$, ^y $P < 0.01$ when compared with diabetic control animals (group II).

content was reduced significantly ($P < 0.001$) in STZ-diabetic rats when compared with normal control rats. It was further observed that diabetic rats treated with silymarin (25 and 50 mg/kg) showed a significant ($P < 0.05 - P < 0.01$) replenishment of glycogen stores in the liver. However, the levels of glycogen build up had not touched those observed in normal control rats.

Fig. 3A showed a section of rat liver from normal control group revealing normal hepatocytes and well brought out portal triad comprising hepatic artery, bile duct and portal vein. STZ administration induced severe degeneration of liver parenchyma and occasional focal necrosis with lymphocytic infiltration (Fig. 3B). Silymarin (25 mg/kg) treated rat liver showed normal portal triad comprising hepatic artery, bile duct and portal vein. Hepatocytes were found to be perfectly normal (Fig. 3C).

Table 1. Effect of silymarin on serum lipid profile (Total Cholesterol, HDL cholesterol, Triglycerides, VLDL Cholesterol and LDL Cholesterol) in streptozotocin-induced diabetic rats

Groups	Treatment	TCh (mg/dl)	HDL (mg/dl)	TG (mg/dl)	VLDL	LDL
I	Normal control	81.53 \pm 1.18	41.37 \pm 0.89	75.53 \pm 1.53	15.10 \pm 0.30	25.05 \pm 1.61
II	STZ (60 mg/kg, i.p)	119.43 \pm 3.44 ^a	26.99 \pm 0.61 ^a	135.10 \pm 1.37 ^a	27.02 \pm 0.27 ^a	65.43 \pm 3.39 ^a
III	STZ+Silymarin (25 mg/kg)	87.75 \pm 0.50 ^b	40.55 \pm 0.52 ^b	95.73 \pm 1.55 ^b	19.15 \pm 0.30 ^b	28.04 \pm 0.78 ^b
IV	STZ+Silymarin (50 mg/kg)	80.73 \pm 1.10 ^b	41.12 \pm 0.37 ^b	83.86 \pm 0.62 ^b	16.77 \pm 0.12 ^b	22.83 \pm 1.13 ^b

The data are expressed in mean \pm SEM; $n = 6$ in each group. ^a $P < 0.001$ compared with the corresponding value for normal control group (group I). ^b $P < 0.001$ compared with the corresponding value of diabetic control animals (group II).

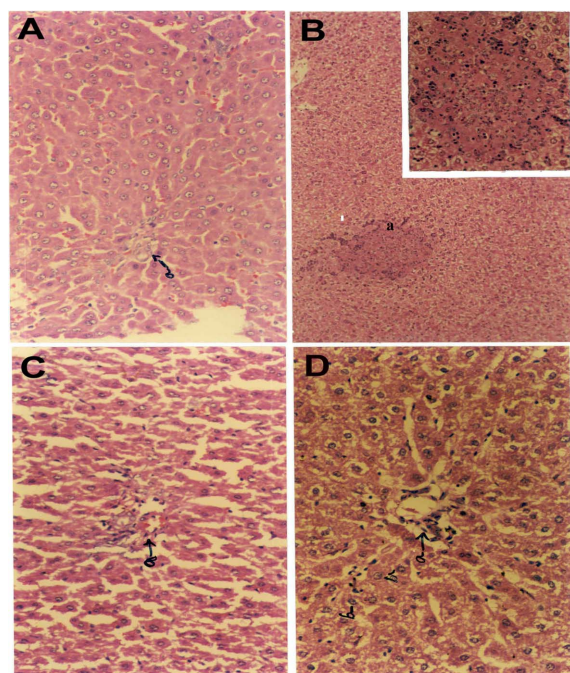


Fig. 3. Histology of liver tissue of rats: (A) normal control rats (a) portal triad comprising of hepatic artery, bile duct and portal vein (H&E $\times 200$) (B) STZ diabetic rats (a) severe degeneration of liver parenchyma and occasional focal necrosis with lymphocytic infiltration (H&E $\times 100$, inset $\times 200$) (C) silymarin (25 mg/kg) treated diabetic rats (a) portal triad comprising of hepatic artery, bile duct and portal vein without any abnormality (b) perfectly normal hepatocytes without any abnormality (H&E $\times 200$) (D) silymarin (50 mg/kg) treated STZ rats (a) normal portal triad (b) Hepatocytes surrounding the portal triad are well preserved without any abnormality (H&E $\times 200$).

Silymarin (50 mg/kg) treatment remarkably reversed the damage of hepatic cells caused by STZ as evidenced by normal portal triad (Fig. 3D) and all the hepatocytes surrounding the portal triad are well preserved without any abnormality thereby revealing the well protective effect of silymarin.

DISCUSSION

Cardiovascular complication is the primary cause of mortality in diabetes mellitus (Alzahrani *et al.*, 2003). The long-term complications of diabetes are of great concern, but cardiovascular complication

is particularly serious. This accounts for much premature morbidity and mortality and is responsible for about 80% deaths among patients with type 2 diabetes (Barnett, 2001). For this reason, health professionals are emphasizing the importance of managing not just glycaemia, but also other cardiovascular risk factors including obesity, dyslipidaemia and hypertension. Dyslipidaemia, which may include raised total cholesterol and LDL-cholesterol, low HDL and raised triglycerides is seen in well over a third of people with diabetes and was observed in our study on STZ-diabetic rats. High level of total cholesterol is one of the major factors for coronary heart diseases and it is well known that hyperlipidaemia and the incidence of atherosclerosis is increased in diabetes (Tan *et al.*, 2005). The liver and some other tissues participate in the uptake, oxidation and metabolic conversion of free fatty acids, synthesis of cholesterol and phospholipids and secretion of specific classes of plasma lipoprotein. Lowering of serum lipid levels through dietary or drug therapy seems to be associated with a decrease in the risk of vascular disease and related complications (Betteridge, 1997).

The effect of flavonoids and flavonoid rich extracts on reducing lipid levels effectively has been reported in several studies (Valsa *et al.*, 1995; Anila and Vijayalakshmi, 2002). Silymarin, a flavonolignan has been widely used from ancient times to treat liver disorders, including acute and chronic viral hepatitis, toxin/drug-induced hepatitis and cirrhosis/alcoholic liver diseases. It has also been reported to be effective in certain cancers (Dixit *et al.*, 2007).

In our previous study we have shown that silymarin protects STZ-induced lipid peroxidation and β -cell damage in rat pancreas (Sharma *et al.*, 2008). The reduction in lipoperoxidative damage by silymarin resulted in a significant decrease in blood glucose levels. In the present study when silymarin was given to diabetic rats, the serum total cholesterol, LDL-cholesterol, VLDL-cholesterol and triglycerides levels were significantly reduced, in

addition to a reduction of blood glucose level. We observed an increase in HDL-cholesterol levels in silymarin treated group. This finding is in favour of silymarin, since low HDL-cholesterol levels are considered as a risk for coronary heart disease. HDL is strongly protective against atherosclerosis. An important mechanism underlying this protective effect is the role of HDL in the removal of excess cholesterol from the peripheral tissues. But in addition, HDL also protects by inhibiting lipoprotein role for oxidation of lipoproteins such as LDL in the pathogenesis of atherosclerosis (Steinberg *et al.*, 1989; Witztum and Steinberg, 1991). The antioxidant properties of HDL are due to in part to serum paraoxonase, an esterase carried on HDL that can degrade certain biologically active oxidized phospholipids (Hegele, 1999; Shih *et al.*, 2000). Over the past decade, a number of promising new targets have been identified that presents exciting new opportunities for treatment of low HDL levels. It has also become clear that HDL is functionally very heterogeneous (Navab *et al.*, 1996). Thus, rather than attempting to increase levels of HDL, it may be more productive to focus on functional properties such as its antioxidant activity. Silymarin itself an antioxidant was found to improve the HDL levels in diabetic rats.

The liver glycogen content was reduced significantly as compared to normal control rats, substantiating depletion of liver glycogen and failure of utilization by hepatocytes in STZ-diabetic rats. The increase in the content of liver glycogen in STZ diabetic rats treated with silymarin revealed its capacity to regenerate the liver cells. This can be explained by improvement in liver cell metabolism following antioxidant therapy. This compound has shown protective effects against several models of hepatotoxicity (Mourelle *et al.*, 1989; Muriel and Mourelle, 1990; Paya *et al.*, 1993) and has been used medicinally for centuries as herbal medicine for the treatment of liver related disorders. This might in turn contribute to the regulation of plasma glucose. Some recent studies have shown a direct cytoprotective

effect of silymarin in pancreatic beta cell (Matsuda *et al.*, 2005). The necrotic and infiltrative changes of liver, which were consistently observed in animals treated with STZ, were reduced to a minimum with silymarin treatment, further substantiating the protective effect of silymarin in the liver. These results suggest that silymarin may be therapeutically beneficial for the treatment of diabetes and related disorders.

In summary, the present study demonstrates the protective effect of silymarin by improving lipid profile, restoring the glycogen content and preventing liver damage in STZ-induced diabetic rats. Therefore, treatment with silymarin can be beneficial in maintaining a better metabolic compensation of glucose metabolism in diabetic patients with dyslipidaemia and liver disorder.

REFERENCES

- Adeneye AA, Adeleke TI, Adeneye AK. (2008) Hypoglycemic and hypolipidemic effects of the aqueous fresh leaves extract of *Clerodendrum capitatum* in Wistar rats. *J. Ethnopharmacol.* **116**, 7-10.
- Alzaharani T, Marrat S, Haider A. (2003) Management of dyslipidaemia in primary care. *Can. J. Cardiol.* **3**, 356-360.
- Anila L, Vijayalakshmi NR. (2002) Flavonoids from *Emblica officinalis* and *Mangifera indica* - effectiveness for dyslipidaemia. *J. Ethnopharmacol.* **79**, 81-87.
- Barnett A. (2001) Type 2 diabetes and cardiovascular disease. *Nursing Times* **97**, 33-35.
- Barrett-Connor E, Grundy SM, Holdbrook MJ. (1982) Plasma lipids and diabetes mellitus in an adult community. *Am. J. Epidemiol.* **115**, 657-663.
- Best J D and O'Neal DN. Diabetic Dyslipidaemia: Current treatment recommendations, *Drugs* **59**, 1101-1110.
- Betteridge J. (1997) Lipid disorders in diabetes mellitus. In: Pickup, JC, Williams, G. (Eds.), Textbook of Diabetes, 31, second ed. *Blackwell Science*, London, pp. 1-55.
- Bindoli A, Cavallini L, Siliprandi N. (1977) Inhibitory action of silymarin of lipid peroxide formation in rat liver mitochondria and microsomes. *Biochem. Pharmacol.* **26**, 2405-2409.
- Braham D, Trinder P. (1972) An improved colour reaction for the determination of blood glucose by

- oxidase system. *Analyst* **97**, 142-144.
- Bucolo G, David M. (1973) Quantitative determination of serum triglycerides by use of enzymes. *Clin. Chem.* **19**, 476-482.
- Chait A, Brazg RL, Tribble DL, Witztum JL, Krauss RM. (1993) Susceptibility of small, dense, LDL to oxidative modification in subjects with the atherogenic lipoprotein phenotype pattern B. *Am. J. Med.* **94**, 350-356.
- Dixit N, Baboota S, Kohli K, Ahmad S, Ali J. (2007) Silymarin: A review of pharmacological aspects and bioavailability enhancement approaches. *Ind. J. Pharmacol.* **39**, 172-179.
- Friedwald WT, Levy RL, Fredrickson DS. (1972) Estimation of the concentration of low-density lipoprotein cholesterol in plasma without use of the preparative ultracentrifuge. *Clin. Chem.* **18**, 499-502.
- Greimel A, Koch H. (1977) Silymarin-an inhibitor of horseradish peroxidase. *Experientia* **33**, 1417-1418.
- Haffner S. (1999) Diabetes, hyperlipidemia, and coronary artery disease. *Am. J. Cardiol.* **83**, 17F-21F.
- Hegele RA. (1999) Paraoxonase-genes and disease. *Annual Med.* **31**, 217-214.
- Huseini HF, Larijani B, Heshmat R, Fakhrzadeh H, Radjabipour B, Toliat T, Raza M. (2006) The efficacy of *silybum marianum* (L). Gaertn. (silymarin) in the treatment of type 2 diabetes: a randomized, double-blind, placebo-controlled, clinical trial. *Phytotherapy Res.* **20**, 1036-1039.
- Matsuda T, Ferrei K, Todorov I, Kuroda Y, Smith CV, Kandeel F, Muller Y. (2005) Silymarin protects pancreatic beta cells against cytokine-mediated toxicity: implication of C-Jun NH2-terminal kinase and janus kinase/signal transducer and activator of transcription pathways. *Endocrinology* **146**, 175-179.
- Montgomery R. (1957) Determination of Glycogen. *Arch. Biochem. Biophys.* **67**, 378-86.
- Mourelle M, Muriel P, Favari L, Franco T. (1989) Prevention of CCl₄ induced liver cirrhosis by silymarin. *Fundament. Clin. Pharmacol.* **3**, 183-191.
- Muriel P, Garciapina T, Perez V, Mourelle M. (1992) Silymarin protects against paracetamol-induced lipid peroxidation and liver damage. *J. Appl. Toxicol.* **12**, 439-442.
- Muriel P, Mourelle M. (1990) Prevention by silymarin of membrane alteration in acute CCl₄ liver damages. *J. Applied. Toxicol.* **10**, 275-279.
- Navab M, Berliner JA, Watson AD, Hama SY, Territo MC, Lusis AJ, Shih DM, Van Lenten BJ, Frank JS, Demer LL, Edwards PA, Fogelman AM. (1996) The yin and the yang of oxidation in the development of the fatty streak. A review based on the 1994 George Lyman Duff Memorial Lecture. *Arterioscl. Thromb. Vascul. Biol.* **16**, 831-842.
- Paya M, Fernandez ML, Sanz MJ, Alcaraz MJ. (1993) Effects of phenolic compounds on bromobenzene mediated hepatotoxicity in mice. *Xenobiotica* **23**, 327-333.
- Pyolara K, Pedersen TK, Kjeshus J, Faergeman O, Oisson AG, Thorgeirsson G. (1997) Cholesterol lowering with simvastatin improves prognosis of diabetic patients with coronary heart disease. *Diabetes Care* **20**, 614-620.
- Sathishekar D and Subramanian S. (2005) Beneficial effects of momordica charantia seeds in the treatment of STZ-induced diabetes in experimental rats. *Biol. Pharm. Bull.* **28**, 978-982.
- Shukla R, Gupta S, Gambhir JK, Prabhu KM, Murthy PS. (2004) Antioxidant effect of aqueous extract of the bark of ficus bengalensis in hypercholesterolemic rabbits. *J. Ethnopharmacol.* **92**, 47-50.
- Shukla, Sharma SB, Puri D, Prabhu KM, Murthy PS. (2000) Medicinal plants for treatment of diabetes mellitus. *Ind J. Clin. Biochem.* **15**, 169-171.
- Schonfeld JV, Weisbrod B, Muller MK. (1997) Silibinin, a plant extract with antioxidant and membrane stabilizing properties, protects exocrine pancreas from cyclosporin A toxicity. *Cell. Mol. Life Sci.* **53**, 917-920.
- Schwartz SL. (2006) Diabetes and dyslipidemia. *Diabet. Obes. Metab.* **8**, 355-364.
- Sharma M, Anwer T, Pillai KK, Haque SE, Najmi AK, Sultana Y. (2008) Silymarin, a flavonoid antioxidant, protects streptozotocin-induced lipid peroxidation and β -cell damage in rat pancreas. *Orient. Pharm. Exp. Med.* **8**, 146-153.
- Shih DM, Xia YR, Wang XP, Miller E, Castellani LW, Subbanagounder G, Cheroutre H, Faull KF, Berliner JA, Witztum JL, Lusis AJ. (2000) Combined serum paraoxonase knockout/apolipoprotein E knockout mice exhibit increased lipoprotein oxidation and atherosclerosis. *J. Biol. Chem.* **276**, 17527-17535.
- Stamler J, Vaccaro O, Neaton JD, Wentworth D. (1993) Diabetes, other risk factors, and 12-years cardiovascular

- mortality for men screened in the multiple risk factor intervention trial. *Diabetes. Care.* **16**, 434-444.
- Steinberg D, Parthasarathy S, Cary TE, Khoo JC, Witztum JJ. (1989) Beyond Cholesterol. Modification of low-density lipoprotein that increase its atherogenicity. *New Eng. J. Med.* **30**, 915-914.
- Tan BK, Tan CH, Pushparaj PN. (2005) Anti-diabetic activity of the semipurified fractions of *Averrhoa bilimbi* in high fat diet fed-streptozotocin induced diabetic rats. *Life Sci.* **76**, 2827-2839.
- Valsa AK, Ushakumary B, Vijayalakshmi NR. (1995) Effect of catechin on lipid metabolism. *J. Clin. Biochem. Nutr.* **19**, 175-182.
- Warnick GR, Nguyen T, Albers AA. (1985) Comparison of improved precipitation methods for quantification of high-density lipoprotein cholesterol. *Clin. Chem.* **31**, 217-222.
- Witztum L, Steinberg D. (1991) Role of oxidized low-density lipoprotein in atherogenesis. *J. Clin. Invest.* **88**, 1785-1792.
- Wybenga DR, Pileggi VJ, Dirstine PH, Di Giorgio J. (1970) Direct manual determination of serum total cholesterol with a single stable reagent. *Clin. Chem.* **16**, 980-984.