

Protective effect of *Terminalia chebula* against experimental myocardial injury induced by isoproterenol

S Suchalatha & C S Shyamala Devi*

Department of Biochemistry and Molecular Biology, University of Madras, Guindy Campus, Chennai 600 025, India

Received 1 September 2003; revised 29 October 2003

Cardioprotective effect of ethanolic extract of *Terminalia chebula* fruits (500 mg/kg body wt) was examined in isoproterenol (200 mg/kg body wt) induced myocardial damage in rats. In isoproterenol administered rats, the level of lipid peroxides increased significantly in the serum and heart. A significant decrease was observed in the activity of the myocardial marker enzymes with a concomitant increase in their activity in serum. Histopathological examination was carried out to confirm the myocardial necrosis. *T. chebula* extract pretreatment was found to ameliorate the effect of isoproterenol on lipid peroxide formation and retained the activities of the diagnostic marker enzymes.

Keywords: Isoproterenol, Lipid peroxide, Marker enzymes, Myocardial infarction, *Terminalia chebula*

Several plant products are known to exhibit creditable medicinal properties for the treatment of heart ailments and need to be explored to identify their potential application in prevention and therapy of human ailments. Notable among these are the fruits of *T. chebula*, a legendary, ayurvedic drug that has been advocated for cardiac disorders¹. The fruits of *T. chebula* extract are claimed to be useful in treating, liver diseases, urinary disorders, and heart diseases² and has been demonstrated for its hypoglycemic³, hypolipidemic⁴, antimutagenic⁵, anti-stress⁶, immunomodulatory⁶ and anti-inflammatory⁷ properties. *T. chebula* is proved to be a powerful antioxidant than butylated hydroxy toluene, butylated hydroxy anisole⁸ and α -tocopherol⁹.

Myocardial infarction, the most dreaded sequelae among ischemic heart diseases, is invariably followed by several biochemical alterations, such as lipid peroxidation, free radical damage, hyperglycemia, hyperlipidemia etc., leading to qualitative and quantitative alterations of the myocardium¹⁰. Isoproterenol¹¹, a β -adrenergic agonist was chosen to induce myocardial necrosis, and the extent of cardioprotection offered by *T. chebula* was studied.

Experimental evidence on biochemical role of *T. chebula* in myocardial damage is lacking. In this context, an attempt has been made to elucidate the maintenance of myocardial integrity in presence or absence of *T. chebula* on isoproterenol induced

cardiac damage with reference to biochemical markers and histology.

Materials and Methods

Drug—Fruits of *T. chebula* powder was gifted by Rohini Herbal Research Institute Private Limited, Chennai. *T. chebula* powder (1 kg) was soaked in ethanol for 7 days with intermittent shaking and the solvent was filtered with Whatman filter paper. The filtrate was evaporated under vacuum drier and the brown mass residue obtained was stored at -4°C for further use. For experimental study, the weighed amount of residue was dissolved in 0.9% saline and used.

Chemicals and reagents—Isoproterenol, ethanol, α -ketoglutarate, bovine serum albumin, adenosine triphosphate were obtained from Sigma Chemical Company (St. Louis, Mo, USA). All other chemicals used were of highest purity.

Animals—Adult male albino rats of Wistar strain weighing 120 - 150g were used for the study. The rats were fed with commercial pellet rat chow and water *ad libitum*. They were maintained under standard laboratory conditions with 12 hr light and dark cycle. The rats were divided into four groups of six animals each - Group I: normal rats; Group II: administered isoproterenol (20 mg/100g; sc, twice at an interval of 24 hr); Group III: rats pretreated with *T. chebula* extract po (50 mg/100g for a period of 30 days); and Group IV: rats pretreated with *T. chebula* extract po (50 mg/100g for a period of 30 days) + isoproterenol (20 mg/100 g; sc, twice at an interval of 24 hr) at the end of the treatment period.

*Address for correspondence:

Old No. 62, New No. 66 II Main Road, Gandhi Nagar, Adayar, Chennai-20.

Fax: 91-44-2352494, E-mail: cssdevi@yahoo.com

At the end of the experimental period, the animals were anaesthetized with pentobarbital sodium (35 mg/kg, ip). Blood was drawn from the external jugular vein of the rat and serum separated by centrifugation. Serum marker enzymes such as lactate dehydrogenase (LDH)¹², creatine kinase (CK)¹³, aspartate transaminase (AST), alanine transaminase (ALT)¹⁴, lipid peroxides (LPO)¹⁵ and protein¹⁶ were assayed. The animals were sacrificed 60 ± 5 sec after the injection. Heart was dissected out and immediately washed in ice cold saline and a homogenate was prepared in 0.1M Tris HCl buffer (pH 7.4). The homogenate was centrifuged at 2500 g and the supernatant was collected. This was used for the assay of marker enzymes and lipid peroxides. A portion of the heart tissue was fixed in formalin (10%) and subjected to histopathology studies. The study was approved by the Institutional Animals Ethics Committee.

Statistical analysis—The data were analysed using one way ANOVA followed by Duncan's multiple comparison test. The results from experimental groups were compared with respective control and *p* values < 0.05 were considered statistically significant.

Results

There was a significant elevation in lipid peroxides and ALT, AST, CK and LDH activity in isoproterenol injected animals compared to control (Table 1). *T. chebula* extract pretreatment significantly reduced the level of lipid peroxides and the activity of the

marker enzymes when compared with isoproterenol administered rats (group II). Administration of *T. chebula* extract alone (group III) did not show any significant change.

There was a significant elevation in lipid peroxides with a concomitant reduction in the activity of marker enzymes (AST, ALT, CK and LDH) on isoproterenol administration (group II) when compared to control (Table 2). Pretreatment with *T. chebula* extract (group IV) on isoproterenol administration retained the activity of these enzymes to near normal levels when compared to group II rats given isoproterenol alone. In drug control animals (group III), the level of lipid peroxides and the activity of these marker enzymes were similar to that of normal rats (group I).

Histopathological studies—Biochemical findings on effective dose of *T. chebula* were further confirmed by histopathological studies. Examination of myocardial tissue of the control group (Fig.1a) depicted clear integrity of myocardial cell membrane. Light microscopy showed normal myofibrillar structure with striations, branched appearance and continuity with adjacent myofibrils. Isoproterenol administered heart tissue (Fig.1b) showed patchy areas of necrosis, hyalinization of muscle fibres with focal cellular infiltrations. The muscle fibres showed vacuolar changes with fragmentation suggestive of necrosis. In animals pretreated with *T. chebula* alone (Fig.1c), the morphology of the myocardium was essentially within normal limits. No area of necrosis and cellular infiltration was seen. Nuclear and fibril

Table 1—Effect of *T. chebula* pretreatment on isoproterenol induced changes in the activities of serum LDH, CK, AST, ALT and lipid peroxide

[Values are expressed as mean ± SE for 6 animals in each group]					
Treatment	Lipid peroxide	LDH	CK	AST	ALT
Control	2.22 ± 0.19	75.70 ± 2.45	269.67 ± 3.72	25.48 ± 0.69	12.69 ± 0.44
Isoproterenol (20 mg/100 g; sc)	4.51 ± 0.39*	143.48 ± 4.91*	527.60 ± 6.06*	45.25 ± 1.6*	23.43 ± 0.89*
<i>T. chebula</i> (50 mg/100 g; po)	2.17 ± 0.19	76.20 ± 2.87	286.28 ± 3.78	22.12 ± 0.91	11.97 ± 0.60
<i>T. chebula</i> (50 mg/100 g; po) + Isoproterenol (20 mg/100 g; sc)	2.49 ± 0.21†	87.11 ± 4.27†	293.76 ± 1.26†	29.21 ± 1.30†	14.02 ± 0.50†
F	105.85	73.948	160.618	58.923	73.167
df	3,20	3,20	3,20	3,20	3,20

Activities of AST and ALT are expressed as nmole of phosphorous liberated/sec/mg protein and CK expressed as μ mole of phosphorous liberated/sec/mg protein. The level of lipid peroxides expressed as TBARS formed/ml/mg protein.

* *P* < 0.05 compared with control animals.

† *P* < 0.05 compared with animals that received isoproterenol alone.

characters were similar to control. Architecture of *T. chebula* pretreated rats subjected to injection of isoproterenol revealed mild edema (Fig.1d).

Inflammatory cells with reduced density, no confluent area of multiple sub-endocardial damage was seen as compared to group II.

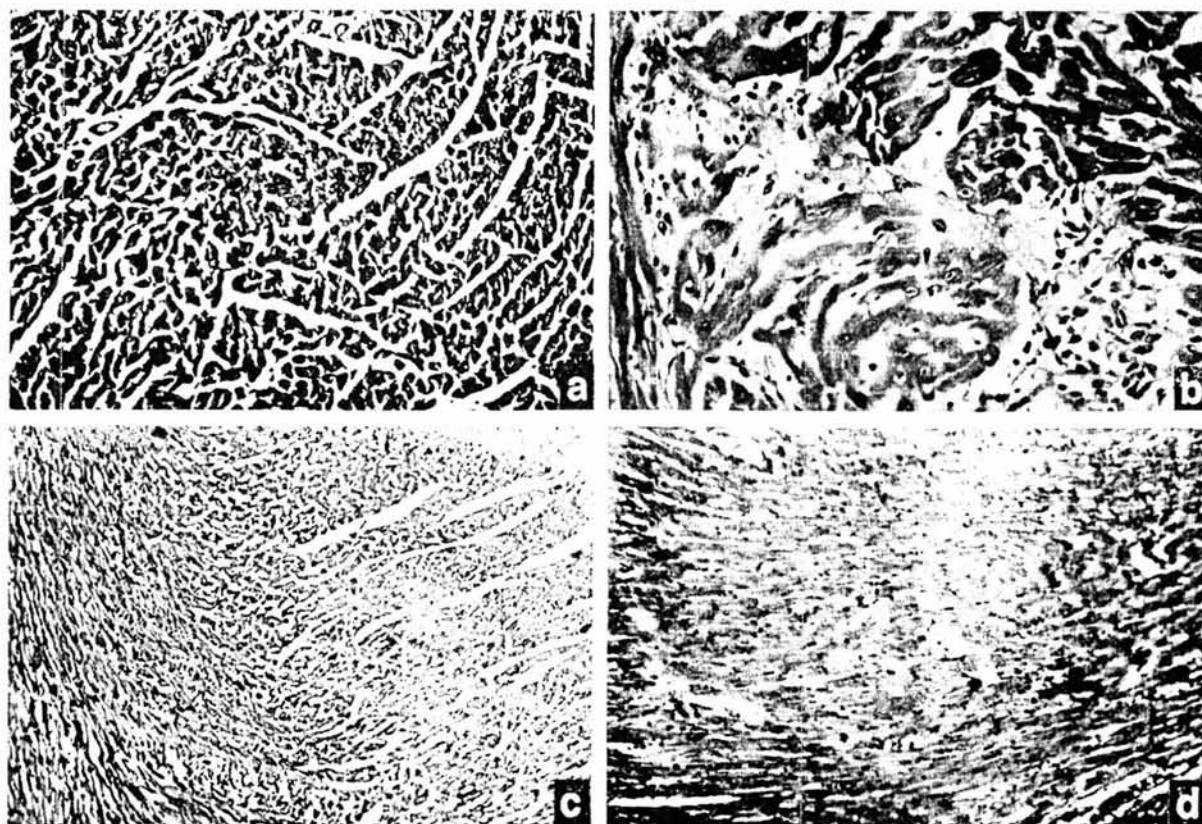


Fig. 1 — Histological examination of heart in experimental animals. [Hematoxylin and eosin $\times 100$] (a) — Section of heart from control rat showing normal architecture; (b) — Section of heart from isoproterenol administered heart reveals degenerative changes, hyalinization of muscle fibres and cellular infiltration; (c) — Section of heart from *T. chebula* pretreated rats showing apparently normal architecture; and (d) — Section of heart from *T. chebula* pretreated rat on isoproterenol injection reveals near normal architecture

Table 2 — Effect of *T. chebula* pretreatment on isoproterenol induced changes in the activities of heart LDH, CK, AST, ALT and lipid peroxide

[Values are expressed as mean \pm SE for 6 animals in each group]

Treatment	Lipid peroxide	LDH	CK	AST	ALT
Control	3.27 \pm 0.26	111.20 \pm 0.33	11.01 \pm 0.32	40.33 \pm 0.28	21.30 \pm 0.44
Isoproterenol (20 mg/100 g; sc)	5.54 \pm 0.41*	63.15 \pm 5.35*	7.35 \pm 0.38*	27.12 \pm 0.54*	13.19 \pm 0.89*
<i>T. chebula</i> (50 mg/ 100 g; po)	3.20 \pm 0.31	110.36 \pm 1.42	10.93 \pm 0.36	39.42 \pm 0.76	20.70 \pm 0.60
<i>T. chebula</i> (50 mg/100g; po) Isoproterenol 20 mg/100 g; sc)	3.69 \pm 0.40†	104.08 \pm 2.72†	10.14 \pm 0.16†	38.05 \pm 0.52†	18.38 \pm 0.50†
F	57.14	58.454	26.894	37.099	29.130
df	3,20	3,20	3,20	3,20	3,20

Activities of AST and ALT are expressed as nmole of phosphorous liberated/sec/mg protein and CK expressed as μ mole of phosphorous liberated/sec/mg protein. The level of lipid peroxides expressed as TBARS formed/ml/mg protein.

* $P < 0.001$ compared with control animals. † $P < 0.001$ compared with animals that received isoproterenol alone.

Discussion

Need for assessing the size of experimental infarct arises while evaluating the drugs for their beneficial effect against myocardial infarction. The serum enzymes viz., transaminases, creatine kinase and lactate dehydrogenase serve as sensitive index to assess the severity of myocardial infarction¹⁷. In isoproterenol treated rats, the increased activities of the serum marker enzymes accompanied by their concomitant reduction in the heart homogenate, confirms the onset of myocardial necrosis^{18,19}.

Free radical generated by isoproterenol, initiate lipid peroxidation of the membrane bound polyunsaturated fatty acids, leading to impairment of membrane structural and functional integrity. Myocardium contains an abundant concentration of many enzymes and once metabolically damaged releases its content into extracellular fluid (ECF)²⁰. Hence, the total concentration of the marker enzymes found to be decreased in the tissue of isoproterenol administered rats as compared to control, might reflect the consequences of cellular injury due to lipid peroxides²¹. This concurs with our findings wherein the activity of marker enzymes was found to be decreased in animals subjected to isoproterenol exposure.

Elevation in the activities of serum CK, LDH and transaminases in isoproterenol injected animals may be due to necrosis in the heart^{22,23}. The quantity of enzyme released from the damaged tissue is a measure of the number of necrotic cells²⁴.

Extent of cardioprotection offered by the drug is associated with significant attenuation of plasma creatine kinase²⁵ and LDH levels²⁶. In the present study, near normal activity of the diagnostic marker enzymes in the serum and heart tissue of group IV animals is indicative of the fact that *T. chebula* extract has significant cardioprotective effect and maintains myocardial membrane integrity.

It has been demonstrated earlier that *T. chebula* extract has beneficial effects on cardiovascular system²⁷. This confirms its traditional usefulness in cardiovascular diseases. *T. chebula* has been reported to possess direct muscuranic activity on the heart muscle. The negative inotropic, negative chronotropic and hypotensive response observed with it, causes a reduction in oxygen demand and might protect the myocardium by decreasing its overload²⁸. This activity of the ethanolic extract of *T. chebula* is contradictory to the positive inotropic and positive chronotropic action of isoproterenol which increases the work load of the myocardium²⁹. Chebulinic acid,

one of the active principles of *T. chebula* has shown to elicit blood pressure lowering effect in rats, on aortic contraction as well as on cardiac contraction in rats³⁰.

Flavonol aglycone and their glycosides as main phenolic contents of *T. chebula*, are potent antioxidants^{31,32} which are believed to prevent degenerative diseases including cardiovascular diseases. They exhibit a wide range of biological effects including vasodilatory actions^{33,34} and inhibition of platelet aggregation³⁵.

Combined effect of active principles present in the ethanolic extract of *T. chebula* might offer protection against cardiac damage in *T. chebula* pretreated isoproterenol injected rats. The histopathological observations of the heart tissue of *T. chebula* extract pretreated animals (group IV) showed a near normal pattern, supporting its role as a promising cardioprotective agent.

Acknowledgement

The author (SS) gratefully acknowledges the financial assistance provided by the council of Scientific and Industrial Research (CSIR), New Delhi, India.

References

- 1 Nandkarni K M, in *Indian Materia Medica*, Vol. I, (Popular Prakashan, Bombay, India) 1976, 1206.
- 2 Kirtikar K R & Basu B D, in *Indian Medicinal Plants*, Vol. II, 3rd edition (International Book Distributors, Dehradun, India) 1988, 1020.
- 3 Sabu M C & Kuttan R, Antidiabetic activity of medicinal plants and its relationship with their antioxidant property, *J Ethnopharmacol*, 81 (2002) 155.
- 4 Shaila H P & Udupa S L, Hypolipidemic activity of three indigenous drugs in experimentally induced atherosclerosis, *Int J Cardiol*, 67 (1998) 119.
- 5 Jain A K, Shimoi K, Nakamura Y, Tomita I & Kada T, Preliminary study on the desmutagenic and antimutagenic effect of some natural products, *Curr Sci*, 56 (1987) 266.
- 6 Thatte U & Dahanukar S, Rasayana concept: Clues from immuno-modulatory therapy, in *Immunomodulation*, edited by S N Upadhyay, (Narosa Publishing House, New Delhi, India) 1997, 141.
- 7 Sharma A & Singh R H, Screening of antiinflammatory activity of certain indigenous drugs on carrageenin induced hind paw oedema, *Bull Med Ethno Bot Res*, 1 (1980) 262.
- 8 Kim *et al.*, Antioxidant effectiveness of ether extract of *Crataegus pinnatifida* and *T. chebula*, *Hanguk Nonghwa Hakhoechi*, 36 (1993) 203.
- 9 Ammar S, Markku A, Kaleri P, Total phenolics concentration and antioxidant potential of extracts of medicinal plants of Pakistan, *Z Naturforsch*, 56 (2001) 973.
- 10 Suresh Kumar J S & Menon V P, Changes in levels of LPO and activity of superoxide dismutase and catalase in diabetes associated with myocardial infarction, *Indian J Exp Biol*, 30 (1992) 122.

- 11 Tipnis U P, He G Y, Li S, Campbell G & Boor P J, Attenuation of isoproterenol-mediated myocardial injury in rat by an inhibitor of polyamine synthesis, *Cardiovasc Pathol*, 9 (2000) 273.
- 12 Nieland A A, Lactic acid dehydrogenase of heart muscle, *Methods Enzymol*, 1 (1985) 449.
- 13 Norman Hall & Marlene Deluca, Electrophoretic separation and quantification of creatine kinase isoenzymes, *Anal Biochem*, 76 (1967) 561.
- 14 Mohur A F & Cooke I J Y, Simple method of measuring serum level of glutamate oxaloacetic acid and glutamate pyruvate transaminase in routine laboratories, *J Clin Pathol*, 10 (1975) 394.
- 15 Okhawa H, Onishi N & Yagi K, Assay of lipid peroxidation in animal tissue by thiobarbituric acid reaction, *Anal Biochem*, 95 (1970) 351.
- 16 Lowry O H, Rosebrough N J, Farr A L & Randall R J, Protein measurement with the Folin phenol reagent, *J Biol Chem*, 193 (1951) 265.
- 17 Sheela S C & Shyamala Devi C S, Protective effect of Abana, a polyherbal formulation on isoproterenol induced myocardial infarction in rats, *Indian J Pharmacol*, 32 (2000) 198.
- 18 Saxena K K, Gupta B, Srivastava V K, Singh R C & Prasad D N, Creatine kinase and aspartate transaminase in experimental model to predict size of cardiac infarct, *Indian J Exp Biol*, 26 (1988) 235.
- 19 Satish V, Ebenezer K K & Devaki T, Synergistic effect of nicorandil and amlodipine on mitochondrial function during isoproterenol induced myocardial infarction in rats, *J Pharm Pharmacol*, 54 (2002) 133.
- 20 Sharma M, Kishore K, Gupta S K, Joshi S & Arya D S, Cardioprotective potential of *Ocimum sanctum* in isoproterenol induced myocardial infarction in rats, *Mol Cell Biochem*, 225 (2001) 75.
- 21 Paritha Ithayarasi, Padmavathy V N & Shyamala Devi C S, Effect of α -tocopherol on isoproterenol induced myocardial infarction in rats—Electrocardiographic, biochemical and histological evidences, *Indian J Physiol Pharmacol*, 40 (1996) 297.
- 22 Tipnis U R, He G Y, Li S, Campbell G & Boor P J, Attenuation of isoproterenol-mediated myocardial injury in rats by an inhibitor of polyamine synthesis, *Cardiovasc Pathol*, 9 (2000) 273.
- 23 Hagar H, Folic acid and vitamin B₁₂ supplementation attenuates isoprenaline induced myocardial infarction in experimental hyper homocysteinemic rats, *Pharmacol Res*, 46 (2002) 213.
- 24 Manjula T S, Geetha A & Shyamala Devi C S, Effect of aspirin on isoproterenol induced myocardial infarction - A pilot study, *Indian J Biochem Biophys*, 29 (1992) 378.
- 25 Gao F, Chen J, Lopez B L, Christopher T A, Juanli G, Paul L, Robert R, Xin L M, Hlstein EH & Tian-Li Y, Comparison of bisoprolol and carvedilol, cardioprotection in a rabbit ischemia and reperfusion model, *Eur J Pharmacol*, 406 (2000) 109.
- 26 Hung L M, Chen J K, Lee R S, Luang H C & Jai Su M, Beneficial effects of astringinin a resveratrol analogue, on the ischemia and reperfusion damage in rat heart, *Free Radic Biol Med*, 30 (2001) 877.
- 27 Inamdar M C & Rajarama Rao M R, Studies on the pharmacology of *T. chebula* (Retz.), Department of Chemical Technology, University of Bombay, 6 April 1962.
- 28 Srivastava R D, Dwivedi S, Sreenivasan K K & Chandrasekhar C N, Cardiovascular effects of *Terminalia* species of plants, *Indian Drugs*, 29 (1991) 144.
- 29 Harada K, Fukata Y, Miwa A, Kaneta S, Fukushima H & Ogawa N, Effect of KRN 2391, a novel vasodilator, on various experimental anginal models in rats, *JPN J Pharmacol*, 63 (1993) 35.
- 30 Guan Y Y, Kwan C Y, Hsu F L & Cheng J T, *In vitro* inhibitory effects of chebulinic acid on the contractile responses of cardiovascular muscles, *Clin Exp Pharmacol Physiol*, 23 (1996) 747.
- 31 Kato Y, Nagao A, Terao J & Osawa T, Inhibition of myeloperoxidase-catalyzed tyrosylation by phenolic antioxidants *in vitro*, *Biosci Biotechnol Biochem*, 67 (2003) 1136.
- 32 Roginsky V, Chain breaking antioxidant activity of natural polyphenols as determined during the chain oxidation of methyl linoleate in Triton X-100 micelles, *Arch Biochem Biophys*, 414 (2003) 261.
- 33 Duarte J, Vizcaino F P, Utrilla P, Jimenez J, Tamargo J & Zazzuelo A, Vasodilatory effects of flavonoids in rat aortic smooth muscles: Structure-activity relationships, *Biochem Pharmacol*, 24 (1993) 857.
- 34 Hanaski Y, Ogawa S & Fukui S, The correlation between active oxygen scavengers and antioxidative effects of flavonoids, *Free Rad Biol Med*, 16 (1994) 845.
- 35 Tzeng S H, Ko W C, Ko F N & Tzeng C M, Inhibition of platelet aggregation by some flavonoids, *Thromb Res*, 64 (1991) 91.