

**PROTECTIVE EFFECTS OF QUERCETIN, A FLAVONOID  
ANTIOXIDANT, IN ABSOLUTE ETHANOL-INDUCED  
ACUTE GASTRIC ULCER**

*Ömer Coşkun<sup>1</sup>, Mehmet Kanter<sup>1</sup>, Ferah Armutçu<sup>2</sup>, Kurtuluş Çetin<sup>1</sup>,  
Betül Kaybolmaz<sup>1</sup>, Ömer Yazgan<sup>1</sup>.*

Karaelmas University, Faculty of Medicine, Departments of Medical Histology-Embryology<sup>1</sup>  
and Biochemistry<sup>2</sup>

Free radicals have been reported to be responsible for many ailments including gastroduodenal ulcers. Recent studies demonstrated that quercetin (QE) has an antioxidant effects on injuries caused by various toxic agents in different experimental models. In our study, we examined anti-ulcerogen and antioxidant effects of quercetin on ethanol-induced gastric lesions in rats. QE was administered intraperitoneally (i.p.) 50 mg/kg. It was found that pretreatment with QE significantly reduced ethanol-induced gastric damage and malondialdehyde levels, and significantly increased antioxidant enzyme activities. We conclude that QE clearly has antioxidant properties and that the protective effect of QE against ethanol-induced gastric mucosal lesion, at least in part, depends upon the reduction in the lipid peroxidation and an increase in the activity of antioxidant enzymes.

**Key words:** Quercetin, ethanol, antioxidant enzymes, gastric damage, oxidative stress, rat.

**INTRODUCTION**

Ethanol manifests its harmful effects either through direct generation of reactive metabolites, including free radical species that react with most of the cell components, changing their structures and functions, or by contributing to other mechanisms that finally promote enhanced oxidative damage (1,2). Ethanol-induced gastric mucosal injury is associated with extensive damage to mucosal capillaries and increased vascular permeability (3,4). Mucosal capillary necrosis, vascular congestion and thrombosis in the subepithelial microvasculature accompany disruption of the gastric mucosal barrier. In addition to the direct injurious effects of ethanol on gastric mucosa, other factors are also thought to be involved in the pathogenesis of injury (5).

Flavonoids are a group of naturally occurring compounds widely distributed as secondary metabolites in the plant kingdom. They have been recognized for having interesting clinical properties, such as anti-inflammatory, antiallergic, antiviral, antibacterial, and antitumoral activities (6).

One of these flavonoids, quercetin (3,5,7,3',4'-pentahydroxyflavone), prevents oxidant injury and cell death by several mechanisms, such as scavenging oxygen radicals (7,8) protecting against lipid peroxidation (9) and chelating metal ions (10). Quercetin, a flavonoid found in many plants, is widely distributed in edible fruits and vegetables. When quercetin was administered orally, it was poorly absorbed from the digestive tract and did not have a great influence on the organs (11,12). Quercetin is the major flavonoid in the human diet and its daily intake with foods is estimated to be 50–500 mg (13). Its preventive roles in experimental models of various agent-induced damage, including ethanol, gastric ulcers have been reported (14-16). This study aimed to examine anti-ulcerogen and antioxidant effects of quercetin on ethanol-induced gastric lesions in rats. For this purpose, we studied the effects of quercetin antioxidant activity, and changes in lipid peroxidation which were determined by measuring MDA level.

**MATERIALS AND METHODS**

**Animals**

Thirty healthy inbred male Wistar albino rats, weighing 200-250 g, and averaging 16 weeks old were utilized in this study. They were housed in macrolon cages under standard

*Correspondence:* Dr. Omer Coşkun  
Zonguldak Karaelmas Üniversitesi, Tıp Fakültesi  
Histoloji-Embriyoloji AD Zonguldak- Turkey  
Tel: +903722577394  
Fax: +903722577395  
E-mail: dromercos@yahoo.com

**Table 1. Erythrocyte MDA ( $\mu\text{mol/g Hb}$ ), serum NO ( $\mu\text{mol/l}$ ) and gastric tissue MDA ( $\mu\text{mol/g protein}$ ), SOD (U/mg protein), GSH-Px (U/mg protein) and CAT (k/mg protein) levels of all groups. A (control), B (ethanol) and C (ethanol+quercetin 50 mg) groups. Values are expressed as mean  $\pm$  SD, and n = 10 for all groups.**

	A	B	C
Erythrocyte MDA	8.92 $\pm$ 1.07	15.23 $\pm$ 2.03 <sup>a</sup>	11.48 $\pm$ 1.24 <sup>b</sup>
Tissue MDA	94 $\pm$ 11	134 $\pm$ 22 <sup>a</sup>	108 $\pm$ 14 <sup>b</sup>
Serum NO	4.12 $\pm$ 0.68	7.42 $\pm$ 1.22 <sup>a</sup>	4.76 $\pm$ 0.84 <sup>c</sup>
Tissue SOD	22.88 $\pm$ 9.61	12.42 $\pm$ 1.32 <sup>a</sup>	16.08 $\pm$ 2.24 <sup>b</sup>
Tissue GSH-Px	0.37 $\pm$ 0.03	0.23 $\pm$ 0.03 <sup>a</sup>	0.30 $\pm$ 0.03 <sup>b</sup>
Tissue CAT	0.34 $\pm$ 0.02	0.21 $\pm$ 0.02 <sup>a</sup>	0.26 $\pm$ 0.02 <sup>b</sup>

<sup>a</sup>  $P < 0.05$  when compared with group A, <sup>b</sup>  $P < 0.05$  when compared with group A and B, <sup>c</sup>  $P < 0.05$  when compared with group B

laboratory conditions (light period 7.00 a.m. to 7.00 p.m., 21 $\pm$ 2°C, relative humidity 55%). The animals were given standard rat pellets (Murat Animal Food Product CO., Ankara, Turkey) and tap water ad libitum.

All animals received human care according to the criteria outlined in the "Guide for the Care and Use of Laboratory Animals" prepared by the National Academy of Sciences and published by the National Institutes of Health.

#### Treatment of rats

The rats were randomly allotted into three experimental groups: A (control), B (ethanol) and C (ethanol+quercetin 50 mg) each containing 10 animals. In groups B and C, gastric ulcers were induced by administrating 100% ethanol (1 ml/200 g, intragastric) (17). In group C, QE (Sigma, St. Louis, M.O., USA) was given two hour prior to administrating 100% ethanol (50 mg/kg/day, intragastric). QE was dissolved in 0.5 ml of DMSO (Merck) just before injection. The solution was always kept in the dark. The dose of QE was chosen on the basis of a previous study (18).

One hour after the administration of ethanol, animals were sacrificed by cervical dislocation and the stomach of each was

removed and opened along the greater curvature and washed in physiological saline solution. For the measurement of the gross gastric mucosal lesions, freshly excised stomach was laid flat and the mucosal lesions were traced on clear acetate paper. Gross mucosal lesions were recognized as haemorrhage or linear breaks (erosions) with damage to the mucosal surface. The area of stomach and gross lesions were calculated by image analysis system. The system used is composed of a PC, hardware and software (Image-Pro Plus 5.0-Media Cybernetics, USA) for image acquisition and analysis, Spot Insight QE (Diagnostic Instruments, USA) camera and optical microscope. The method requires preliminary software procedures of spatial calibration (micron scale) and setting of color segmentation for quantitative color analysis.

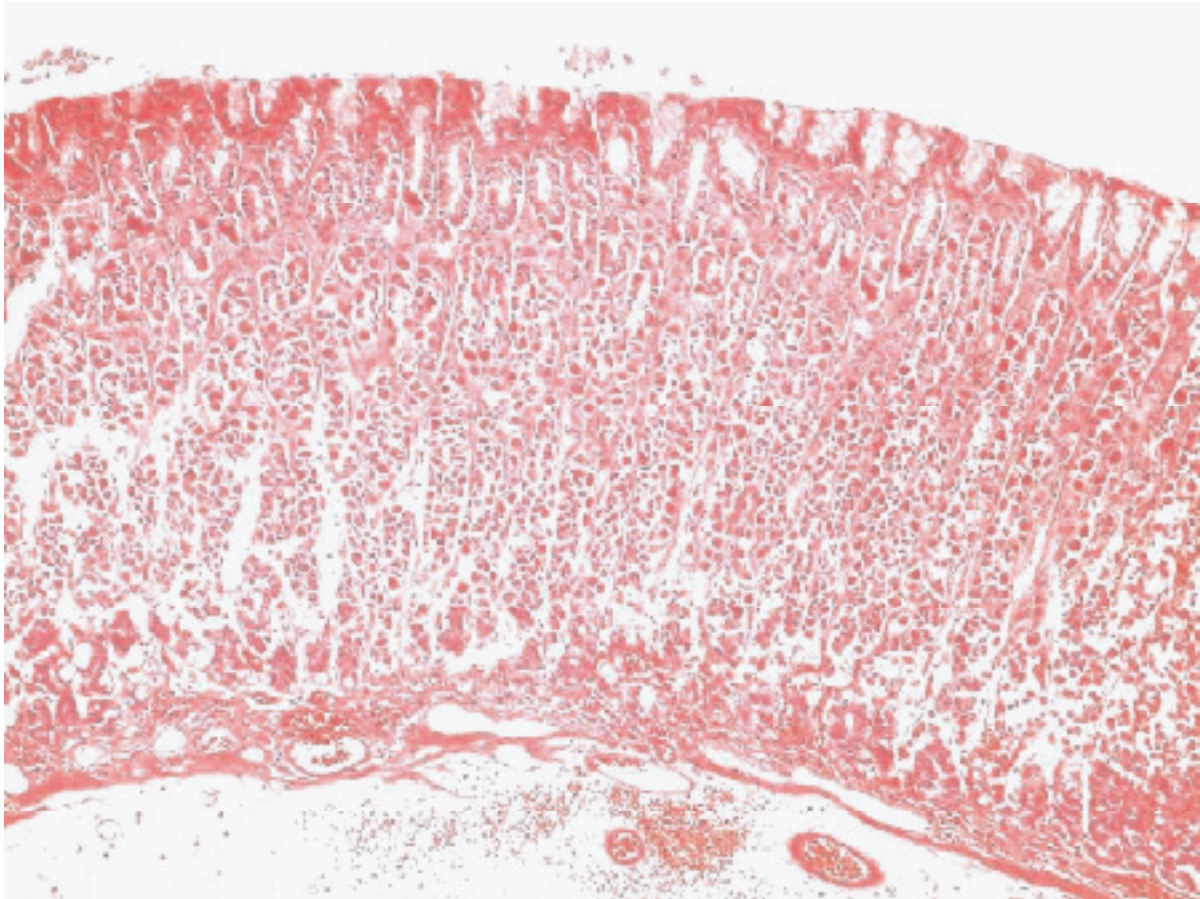
#### Biochemical analysis

Blood and tissue malondialdehyde (MDA) (mmol/l) was determined by the double heating method of Draper and Hadley (19). The reaction solution containing 8.1% sodium dodecyl sulfate, 20% acetate buffer (pH 3.5), and 0.8% thiobarbituric acid (TBA) was mixed well with 0.2 ml of stomach tissue homogenate for 3 min and incubated at 95 °C for 60 min. After chilling, TBA reactive substance, malondialdehyde (MDA) was extracted with 1 ml of H<sub>2</sub>O and 2.5 ml of n-butanol:pyridine mixture (15:1, v/v). The upper organic layer containing MDA produced by lipid peroxidation was measured at 532 nm. The absorbance measured at 532 nm was expressed as nM of MDA. Protein measurements were made according to Lowry's method (20). Tissue SOD and GSH-Px activities were measured by using Ransod and Ransel (Randox Laboratories GmbH, Deutschland) commercial kits, respectively with the Shimadzu UV-1601

**Table 2. Comparison of the area of the gastric lesion in A (control), B (ethanol) and C (ethanol+quercetin 50 mg) groups. Kruskal-Wallis test was used for statistical analysis. Values are expressed as mean  $\pm$  SD, and n = 10 animals for all groups.**

Groups	Gastric Lesions (mm <sup>2</sup> )
A	0
B	62.9 $\pm$ 4.2
C	18.6 $\pm$ 1.2 <sup>a</sup>

<sup>a</sup>  $P < 0.01$  when compared with group A and B



**Figure 1.** The histology of stomach was normal in control group (H & E; 120x).

spectrophotometer. Tissue CAT activity was determined according to Aebi's method (21). NO production ( $\mu\text{mol/l}$ ) was measured indirectly using a quantitative, colorimetric assay (22) based on the Griess reaction.

#### ***Histopathological procedures***

Gastric tissues were harvested from the sacrificed animals, and the fragments from tissues were fixed in 10% neutral formalin solution, embedded in paraffin and then, stained with haematoxylin and eosin.

#### ***Statistical analysis***

The data were expressed as mean  $\pm$  standard deviation (SD) and analysed using repeated measures of variance. Tukey test was used to test for differences among means when ANOVA indicated a significant ( $P < 0.05$ ) and ( $P < 0.001$ ). For the analysis of the morphometrical data, a nonparametric test (Kruskal-Wallis) was used. Differences were considered statistically significant if  $P < 0.05$ .

## **RESULTS**

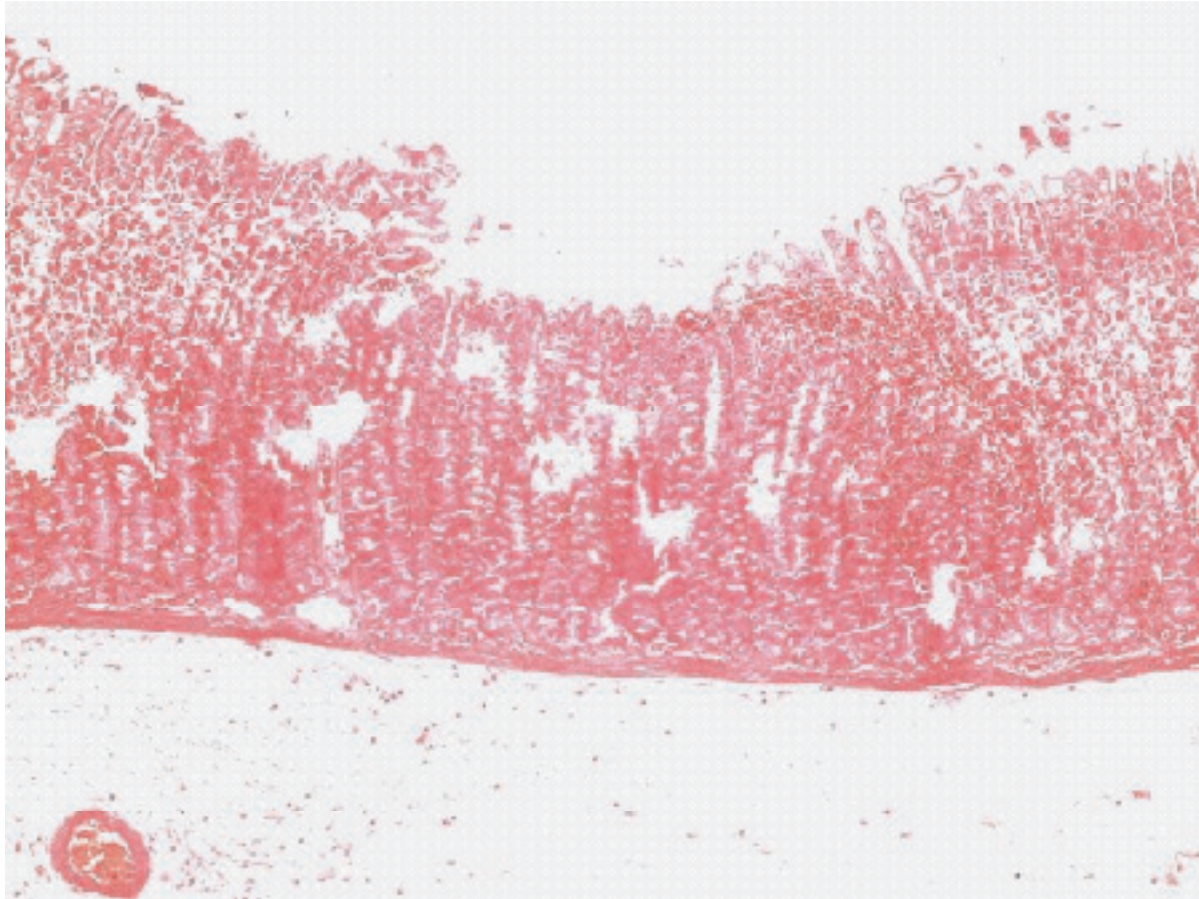
### ***Biochemical findings***

Erythrocyte MDA, serum NO and gastric tissue MDA, SOD, GSH-Px and CAT levels were presented in Table 1. Erythrocyte MDA, serum NO and gastric tissue MDA significantly increased ( $P < 0.05$ ) and also the antioxidant levels significantly decreased ( $P < 0.05$ ) in group B. QE treatment significantly decreased the elevated MDA and NO ( $P < 0.05$ ), and also increased the reduced antioxidant enzyme activities ( $P < 0.05$ ) in group C.

### ***Histological findings***

The ulcer index was evaluated macroscopically as depicted on table 2. Gastric lesion area was  $62.9 \pm 4.2 \text{ mm}^2$  and ulcerations were predominately localized in the corpus of the stomach in group B. Quercetin pretreatment significantly inhibited mucosal injury caused by ethanol and resulted in approximately 70% reduction in lesion area:  $18.6 \pm 1.2 \text{ mm}^2$  ( $P < 0.01$ ). The gastric damage was also confirmed by histological examination. The histology of stomach was normal in control group (Figure 1).





**Figure 2.** In group B (ethanol), gastric mucosa was extensively damaged. The resulting mucosal lesions extend at different depths into the mucosa involving the surface mucous cells only or extending to the cells lining the gastric pits or into the gland area (H & E; 120x).

In group B, gastric mucosa was extensively damaged. The resulting mucosal lesions could vary in that they could extend at different depths into the mucosa involving the surface mucous cells only or extending to the cells lining the gastric pits or into the gland area (Figure 2). In group C, gastric mucosa was partly protected from ethanol induced-damage by QE (Figure 3).

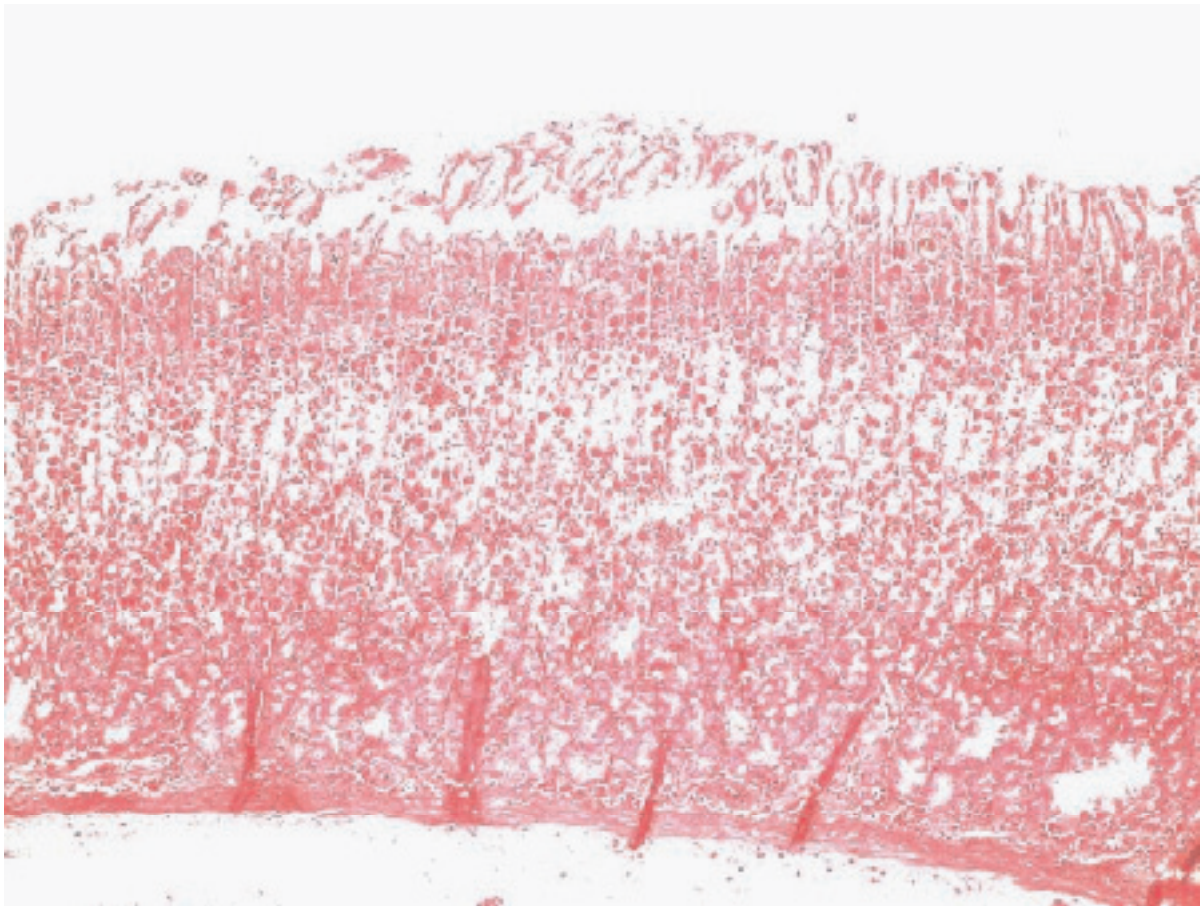
## DISCUSSION

Oxygen derived free radicals have been implicated in the pathogenesis of a wide variety of clinical disorders and gastric damage is caused by physical, chemical and psychological factors that leads to gastric ulceration in human and experimental animals (23). Most of the available drugs are thought to act on the offensive factors which neutralize acid secretion like antacids, H<sub>2</sub> receptor blockers like ranitidine, famotidine, anticholinergics like pirenzepin, telezipine, proton pump blockers like omeprazole,

lansoprazole, etc. which interfere with acid secretion (24). The present study was designed to demonstrate gastric ulcer protective activity of quercetin in rats.

Quercetin is a phenolic compound widely distributed in the plant kingdom. It is found in frequently consumed foods, including apples, berries, onions, tea and brassica vegetables. Quercetin is reported to have many beneficial effects on human health, including cardiovascular protection, anticancer activity, antiulcer effects, antiallergic activity, cataract prevention, antiviral activity and anti-inflammatory effects (25-27).

In the present study, quercetin significantly decreased the concentration of malondialdehyde, an indicator of lipid peroxidation, in the stomach homogenates. Among the numerous pathological events that are caused by an imbalance between oxidative damage and antioxidant defense systems, lipid peroxidation is a wellknown example of oxidative damage that affects cell membranes,



**Figure 3.** In group C (ethanol+quercetin 50 mg), gastric mucosa was partly protected from ethanol induced-damage by QE (H & E; 120x).

lipoproteins, and other lipid-containing structures under conditions of oxidative stress. Therefore, the fact that quercetin decreased lipid peroxidation might mean that quercetin has an antioxidant effect.

Quercetin has effective antiulcer activity against ethanol-induced ulcerogenesis and it can be used for therapy of ulcerogenesis and gastric mucosal injury. Quercetin protects and prevents changes in biochemical parameters and morphologic changes observed after ethanol consumption. In our study, erythrocyte and tissue MDA and serum NO concentration was significantly increased in ethanol group with reduction in antioxidant enzyme activities of SOD, GSHPx and CAT.

QE treatment decreased the elevated MDA and NO and also increased the reduced antioxidant enzyme activities. Namely, our results indicate that the preventive effects of QE may be due to inhibition of lipid peroxidation by its antioxidant nature.

As conclusion, QE shows protective effects in ethanol-induced gastric ulcer, possibly by decreasing oxidative stress and increasing antioxidant enzyme activity. But to elucidate

the exact mechanism of this modulatory effect, and to examine its potential therapeutic effects further studies are essential.

#### REFERENCES

- 1- Kato S, Kawase T, Alderman J, Inatomi N, Lieber CS. Role of xanthine oxidase in ethanol-induced lipid peroxidation in rats. *Gastroenterology* 1990;98:203-10
- 2- Nordmann R. Alcohol and antioxidant systems. *Alcohol* 1994;29:513-22
- 3- Szabo S, Trier JS, Brown A, Schnoor J. Early vascular injury and increased vascular permeability in gastric mucosal injury caused by ethanol in the rat. *Gastroenterology* 1985;88:228-36
- 4- Bou-Abboud CF, Wayland H, Paulsen G, Guth PH. Microcirculatory stasis precedes tissue necrosis in ethanol-induced gastric mucosal injury in the rat. *Dig Dis Sci* 1988;33:872-7
- 5- Konturek SJ, Stachura J, Konturek JW. Gastric cytoprotection and adaptation to ethanol. In: V.R. Preedy and R.R. Watson, Editors. *Alcohol and the gastrointestinal*



- tract, CRC Press, New York, 1996, pp 123–41
- 6- Middleton E Jr. Effect of plant flavonoids on immune and inflammatory cell function. *Adv Exp Med Biol* 1998;439: 175-82
  - 7- Bors W, Heller W, Michel C, Saran M. Flavonoids as antioxidants: determination of radical-scavenging efficiencies. *Methods Enzymol* 1990;186:343-55
  - 8- Park C, So HS, Shin CH et al. Quercetin protects the hydrogen peroxide-induced apoptosis via inhibition of mitochondrial dysfunction in H9c2 cardiomyoblast cells. *Biochem Pharmacol* 2003;66(7):1287-95
  - 9- Loughton MJ, Evans PJ, Moroney MA, Hoult JR, Halliwell B. Inhibition of mammalian 5-lipoxygenase and cyclooxygenase by flavonoids and phenolic dietary additives. Relationship to antioxidant activity and to iron ion-reducing ability. *Biochem Pharmacol* 1991;42(9):1673-81
  - 10- Afanas'ev IB, Dorozhko I, Brodskii AV, Korstyuk VA, Potapovitch A. Chelating and free radical scavenging mechanisms of inhibitory action of rutin and quercetin in lipid peroxidation. *Biochem Pharmacol* 1989;38(11):1763-9
  - 11- Yoshida M, Sakai T, Hosokawa N et al. The effect of quercetin on cell cycle progression and growth of human gastric cancer cells. *FEBS Lett* 1990;260:10-3
  - 12- Murota K, Terao J. Antioxidative flavonoid quercetin: implication of its intestinal absorption and metabolism. *Arch Biochem Biophys* 2003;417:12–7
  - 13- Deschner EE, Ruperto J, Wong G, Newmark HL. Quercetin and rutin as inhibitors of azoxymethanol-induced colonic neoplasia. *Carcinogenesis* 1991; 12:1193–6
  - 14- Mizui T, Sato H, Hirose F, Doteuchi M. Effect of antiperoxidative drugs on gastric damage induced by ethanol in rats. *Life Sci* 1987;41:755-63
  - 15- Martin MJ, La-Casa C, Alarcon-de-la-Lastra C et al. Anti-oxidant mechanisms involved in gastroprotective effects of quercetin. *Z Naturforsch* 1998;53:82-8
  - 16- La Casa C, Villegas I, Alarcon de la Lastra C et al. Evidence for protective and antioxidant properties of rutin, a natural flavone, against ethanol induced gastric lesions. *J Ethnopharmacol* 2000;71:45-53
  - 17- Hollander D, Taranawski A, Krause WJ, Gergely H. Protective effect of sucralfate against alcohol-induced gastric mucosal injury in the rat. *Gastroenterology* 1985; 88:366–74
  - 18- Molina MF, Sanchez-Reus I, Iglesias I, Benedi J. Quercetin, a flavonoid antioxidant, prevents and protects against ethanol-induced oxidative stress in mouse liver. *Biol Pharm Bull* 2003;26:1398-1402
  - 19- Draper HH, Hadley M. Malondialdehyde determination as index of lipid peroxidation. *Methods Enzymol* 1990; 186:421-31
  - 20- Lowry OH, Rosebrough NJ, Randall RJ. Protein measurement with the Folin phenol reagent. *J Biol Chem* 1951;193: 265-72
  - 21- Aebi H. Catalase. In: Bergmeyer HU. *Methods of enzymatic analysis*. New York, Academic Press 1974;673-7
  - 22- Cattell V, Cook T, Moncada S. Glomeruli synthesise nitrite in experimental nephrotoxic nephritis. *Kidney Int* 1990; 38(6):1056-60
  - 23- Rao ChV, Maiti RN, Goel RK. Effect of mild irritant on gastric mucosal offensive and defensive factors. *Indian Journal of Physiology and Pharmacology* 1999; 44: 185-191
  - 24- Sairam K, Rao ChV, Dora Babu M, Goel RK. Prophylactic and curative effects of *Bacopa monnieri* in gastric ulcer models. *Phytomedicine* 2001;8:423-30
  - 25- Bronner C, Landry Y. Kinetics of the inhibitory effect of flavonoids on histamine secretion from mast cells. *Agents Actions* 1985;16:147–151
  - 26- Kaul RN, Middleton JrE, Ogra PL. Antiviral effect of flavonoids on human viruses. *J Med Virol* 1985;15:71–9
  - 27- De-Whalley C, Rankin SM, Houct JRS, Jessup W, Leake DS. Flavonoids inhibit the oxidative modification of low-density lipoproteins by macrophages. *Biochem. Pharmacol* 1990;39:1743–50