

# Proton Magnetic Resonance Spectroscopy in First Episode Psychosis and Ultra High-Risk Individuals

by Stephen J. Wood, Gregor Berger, Dennis Velakoulis, Lisa J. Phillips, Patrick D. McGorry, Alison R. Yung, Patricia Desmond, and Christos Pantelis

## Abstract

The underlying neurobiology of emerging psychotic disorders is not well understood. Recent neuroimaging findings have suggested that some brain areas are affected prior to the onset of psychosis, while changes occur in other brain regions during the transition to illness. Further, previous research using magnetic resonance spectroscopy (MRS) has generally demonstrated that there are changes to the brain chemistry of patients with schizophrenia. However, it is unclear whether these changes are present prior to or at the onset of the disorder, and to what extent they are specific to schizophrenia. In this study, we assessed the left medial temporal and left dorsolateral prefrontal regions of 56 patients in their first episode of a psychotic disorder, 30 young people at ultra high-risk (UHR) of developing psychosis, and 21 healthy controls, using proton MRS. Six of the UHR group developed a first episode psychosis over the study period. No differences were identified between the first episode and control groups for any metabolite ratio in either region of interest. This may reflect intact neuronal circuits in the early phase of psychotic disorders. There were also no differences between the UHR and control groups for the medial temporal region. However, there was a significant elevation of the NAA/Creatine and the Choline/Creatine ratios in the dorsolateral prefrontal region of the UHR group, which was interpreted as a decline in creatine indicative of hypometabolism. This finding did not discriminate between those UHR individuals who later became psychotic and those who did not.

**Keywords:** MRS, early psychosis, dorsolateral prefrontal, medial temporal, schizophrenia, prodrome. *Schizophrenia Bulletin*, 29(4):831–843, 2003.

The underlying neurobiology of early psychosis is not well understood. The term “early psychosis” represents a

broad range of possible diagnostic and prognostic categories, which include but are not limited to the traditionally studied groups of disorders such as schizophrenia and schizoaffective and bipolar disorder. Most neurobiological studies in early psychosis have been carried out in first episode schizophrenia and have not considered the heterogeneity of the initial presentation nor the instability of diagnosis at the onset of psychotic disorders (Lieberman et al. 2001). Indeed, it may be more meaningful to consider the “emerging psychotic state” as a gateway for a range of psychotic disorders, of which schizophrenia is only one.

The most commonly accepted etiopathological model of schizophrenia was proposed more than 15 years ago by Weinberger (Weinberger 1987) and, separately, Murray and Lewis (Murray and Lewis 1987). This neurodevelopmental theory suggested that schizophrenia was related to a defect in brain development that predisposed patients to a characteristic pattern of brain malfunction in early adult life. In order to explain the delay between an early insult and the onset of symptoms in adolescence, it was hypothesized that the behavioral abnormalities appear later in life, at a time when the maturing brain circuits are placed under functional demand (Weinberger 1987). The clinical silence of the disorder in the majority of cases during childhood and the epidemiology of onset, typically in adolescence and early adulthood (van Os et al. 1997), are in contrast to other neurodevelopmental disorders such as Down’s syndrome, Fragile X syndrome, autism, or velo-cardio-facial syndrome. Furthermore, the motor, cognitive, social, and emotional changes that have been described in children who go on to develop schizophrenia may be subtle manifestations of an early neurodevelopmental lesion (Walker et al. 1994; Pantelis 1996), although there is little or no evidence for specificity of these deviations to schizophre-

---

Send reprint requests to Dr. S. Wood, Cognitive Neuropsychiatry Unit, Sunshine Hospital, Furlong Road, St. Albans VIC 3021, Australia; e-mail: stephen.wood@wh.org.au.

nia. Evidence for the neurodevelopmental model of schizophrenia includes findings that, despite evidence of tissue loss, reduced cortical folding, and other structural changes (e.g., ventricular enlargement), these occur in the absence of any age-related effects and/or increase in gliosis (Harrison 1999; McCarley et al. 1999), which is regarded as a necessary neuropathological hallmark of neuronal degeneration (Oppenheimer 1984). These data have suggested a pathogenesis that is different from other adult-onset and chronic neurodegenerative diseases.

One example of prenatal disturbances to brain development in patients with schizophrenia is provided by our own work examining the surface morphology of the anterior cingulate cortex (ACC). Using magnetic resonance imaging (MRI), we found that, as a group, patients with schizophrenia lacked the “normal” leftward ACC sulcal asymmetry, which was explained by reduced folding in the left ACC. These differences were over and above differences in cortical folding across the entire left hemisphere (Yücel et al. 2002). Given that sulcal/gyral folding is almost complete by the third trimester of gestation (Chi et al. 1977; Worthen et al. 1986) and remains relatively stable from soon after birth (Zilles et al. 1988; Armstrong et al. 1995), these anomalies of ACC folding are likely to reflect early (prenatal) neurodevelopmental contributions to the etiology of schizophrenia. Such findings are in accord with other work that has identified surface morphological anomalies in schizophrenia (Kulynych et al. 1997; Vogeley et al. 2000; Narr et al. 2001), thereby implicating early neurodevelopmental factors in the disorder.

More recently, we have explored the same region in patients at UHR for psychosis, identified through a combination of trait and state risk factors (Yung et al. 1996). This has the advantage of a high transition rate over a relatively short followup interval, of around 30 to 40 percent (Phillips et al. 2000; Yung et al. 2003). As predicted by the neurodevelopmental model, the UHR patients showed the same ACC anomalies as those with established schizophrenia—a reduction in paracingulate folding on the left hemisphere (Yücel et al. 2003). However, this sulcal/gyral anomaly was not specific to the subgroup of UHR participants who later developed a psychotic illness, implying that the anomaly is associated with mental state changes and risk status, rather than transition to psychosis.

While such evidence is consistent with an early neurodevelopmental insult, this does not provide a convincing explanation for the long delay between the proposed insult and the onset of symptoms. Despite the fact that proponents of the neurodevelopmental hypothesis have tended to emphasize the influence of pre- or perinatal factors (McGrath et al. 1995; Marenco and Weinberger 2000),

there is likely to be an interaction between such early neurodevelopmental influences and dynamic changes occurring as the brain develops in adolescence (Weinberger 1987). Given that neurodevelopment does not end with birth, a model that incorporates possible anomalies of later developmental processes such as myelination, synaptic pruning, or altered synaptic plasticity is required. Studies that have examined such processes have provided evidence that they are disrupted in schizophrenia (Benes 1989; McGlashan and Hoffman 2000). In particular, Benes proposed that discrete alteration of neurons within, and interconnectivity between, the ACC and prefrontal cortices are at the core of schizophrenia. Benes (1989) speculates that such abnormalities may give rise to schizophrenia-like symptoms during late adolescence and early adulthood because this is the period of increased myelination of the perforant pathway. This pathway carries fibers from the entorhinal cortex to the hippocampus and when “activated” may trigger the expression of abnormalities in the cortical regions as they impinge on cortico-limbic circuitry.

In part because of this proposal, the hippocampus has been extensively examined in schizophrenia and there is general agreement that it is smaller in the disorder (Nelson et al. 1998). It remains open, however, as to exactly when this reduction in hippocampal volume arises (Pantelis et al. 2003c), its functional consequences (Wood and Pantelis 2001), and indeed its specificity to schizophrenia over other psychotic disorders. In particular, does a reduction in hippocampal volume predate the onset of psychosis and is it predictive for the development of the illness? Prodromal studies in Melbourne and Edinburgh examining the hippocampi (Melbourne) or the amygdalo-hippocampal complex (Edinburgh) suggest that the answer to the first question is “Yes,” since in both cases the high-risk group had smaller volumes than a comparison population (Lawrie et al. 1999; Phillips et al. 2002). However, this does not necessarily imply that these abnormalities represent lesions associated with or predictive of psychosis. To date, only the Melbourne study has been able to report such data. We have identified that, contrary to the models presented above, the high-risk subjects who did *not* develop acute levels of psychotic symptoms within 12 months of recruitment had smaller hippocampal volumes at intake while the group developing psychosis did not differ from a comparable normal sample (Phillips et al. 2002). Similarly, a survival analysis indicated that normal (not smaller) left hippocampal volume was predictive of psychosis in the high-risk group.

It is not immediately obvious why nonreduction of left hippocampal volume should be predictive of the transition to psychosis. One possibility is that onset of acute psychosis is preceded by normal hippocampal size with a

subsequent decrease in size as acute illness develops. It may be (a) that the process of transition from an at-risk mental state to acute illness is associated with some loss of hippocampal structure; or (b) as predicted by the neurodevelopmental model, the hippocampi of the UHR sample are small initially (as seen in those UHR subjects who did not develop an acute psychosis) but immediately prior to the onset of psychosis there was a physiological change that was manifested as an increase in hippocampal size to within normal limits (perhaps a compensatory reaction); or (c) there are developmental abnormalities in the hippocampi of people who eventually develop acute psychosis that make the hippocampal size larger than might otherwise be expected prior to illness onset. This explanation is also consistent with the neurodevelopmental model as this abnormal structure would have been determined early in life.

The above findings suggest that in order to produce the consistent findings of reduced hippocampal volume in first episode psychosis there must be a reduction in the hippocampal volume of the UHR patients who develop psychosis, assuming that the populations are similar. In order to investigate this possibility, a prospective, longitudinal study is required. To date, only one such study has reported changes in brain volume over the transition phase to illness (Pantelis et al. 2003a). In this study, 21 of the 75 high-risk individuals who had a baseline MRI scan were followed up with a second MRI scan, either immediately postpsychosis (psychotic group) or after 12 months (nonpsychotic group). The comparison between baseline and followup scans for the two groups indicated that both showed a reduction of grey matter volume in the left cerebellum. However, in the UHR-psychotic group, an additional three regions were reduced (a left inferior frontal region; a left medial temporal region that included the hippocampus, surrounding parahippocampal gyrus and the fusiform gyrus; and the cingulate bilaterally). This finding, if confirmed by further investigations, implies that there are active brain changes occurring in patients with emerging psychotic disorders, something that could perhaps be prevented, ameliorated, or at least delayed by early intervention during or before the first episode of psychosis (McGorry et al. 2002). These initial results are suggestive of progressive brain changes that would be consistent with clinical changes manifest in these patients.

What is still unclear is whether the normal volume of the hippocampus in the later-psychotic UHR (as measured prior to illness onset) reflects normal underlying neurobiology. One way of answering this question is with magnetic resonance spectroscopy (MRS), which enables us to examine brain neurochemistry *in vivo*. The most frequently used application of this technique, proton MRS,

provides us with a tool for measuring N-acetyl-aspartate (NAA), creatine, choline, myo-inositol, and glutamine/glutamate containing compounds in the living human brain. Most emphasis in schizophrenia research has been placed on the N-acetyl peak, with NAA as its major contributor, a metabolite synthesised almost entirely in neurons (Urenjak et al. 1993) and reduced in disorders associated with persistent or reversible neuronal loss (Birken and Oldendorf 1989).

<sup>1</sup>H-MRS studies in patients with established schizophrenia have inconsistently identified NAA reductions in the frontal and temporal lobes, partly because of the diverse methodologies used and the heterogeneity of the study populations (Keshavan et al. 2000). NAA measures have also been associated with cognition (Bertolino et al. 2000), symptomatology (Callicott et al. 2000), and duration of illness (Stanley et al. 1996), although, surprisingly, no such associations have been reported for structural brain changes such as hippocampal volume loss (Deicken et al. 1999).

Studies in first episode psychosis patients with schizophrenia have been even more inconclusive. This may in part be due to generally small patient numbers (frequently fewer than ten), variable regions of interest, and the selection of patients who, though drug-naïve, have illness durations already counted in years (Keshavan et al. 2000). One study that has demonstrated no change in NAA concentration in the temporal lobe of drug-naïve first episode schizophrenia patients was careful to use a patient group with a relatively short duration of untreated psychosis (mostly less than 18 months) (Bartha et al. 1999), although a more recent study of schizophreniform psychosis has demonstrated reductions in NAA similar to those previously reported in chronic schizophrenia (Bertolino et al. 2003). There have been no studies that have compared patients with a primary diagnosis of schizophrenia/schizophreniform disorder to those with other psychotic disorders (e.g., bipolar disorder with psychotic features), so it is unclear to what extent the reported findings are specific to schizophrenia rather than being representative of psychotic disorders in general.

<sup>1</sup>H-MRS studies of people at high risk of developing a psychotic illness have been limited. To date there have only been four published studies in relatives of patients with schizophrenia, with mixed findings (Keshavan et al. 1997; Callicott et al. 1998; Block et al. 2000; Španiel et al. 2003). The largest family study included 47 patients with schizophrenia and 60 siblings, studied the largest number of brain regions, and found that there was a reduction in the hippocampal NAA/Cr ratio in both groups compared to controls (Callicott et al. 1998). However, the mean age of all three groups was greater than 30, implying that few if any of the siblings would go on to develop schizophre-

nia. The only study to examine people at genetic risk for psychosis prior to the period of maximum risk was that of Keshavan et al. (1997). However, the only region examined in that study was the anterior cingulate, where a trend for a NAA/Cr reduction in the high-risk group was identified.

To date there are no published studies that have used proton MRS to investigate patients at ultra high-risk for psychotic disorders. Our MRI volumetric studies in this population compared with a recent-onset first episode psychosis group have identified reduced volume of the left hippocampus early in the illness (Velakoulis et al. 1999), whereas high-risk individuals who subsequently developed psychosis (UHR-P group) had normal left hippocampal volumes, as described above (Phillips et al. 2002). Further, using a voxel-based method, frontal and temporal lobe abnormalities were observed premorbidly in the UHR-P group with further loss in left-sided medial temporal lobe and frontal lobe areas with transition to illness (Pantelis et al. 2003a), suggesting that active neurobiological processes may occur during the transition to psychosis.

In this study, we investigated the left hippocampus and left dorsolateral prefrontal cortex (DLPFC) of 56 patients in their first episode of a psychotic disorder, 30 patients at ultra high-risk of developing psychosis, and 21 healthy comparison subjects using proton MR spectroscopy. The decision to investigate the left hippocampus was based on our previous work, which had suggested that left, and not right, hippocampal volume reductions were evident in first episode psychosis (Velakoulis et al. 1999). We predicted that abnormal hippocampal and DLPFC metabolite levels would be identified in the first episode cohort, but that only DLPFC changes would precede illness onset and thus be present in the UHR group.

## Methods

**Participants.** Fifty-six first episode (FE) patients were recruited from the Early Psychosis Prevention and Intervention Centre (EPPIC), ORYGEN Youth Health, Melbourne, Australia (McGorry et al. 1996). These patients have not previously been included in a published imaging study. Inclusion criteria were (1) age at onset 15 to 30 years and (2) currently psychotic as reflected by the presence of at least one of (a) delusions; (b) hallucinations; (c) disorder of thinking/speech, other than simple acceleration or retardation; or (d) disorganized, bizarre, or markedly inappropriate behavior. *DSM-IV* diagnoses were based on chart review, Structured Clinical Interview for *DSM-IV* disorders (SCID; First et al. 1997), and the Royal Park Multidiagnostic Instrument for Psychosis (RPMIP; McGorry et al. 1989) administered during the initial treatment episode. Diagnoses were schizophrenia

( $n = 21$ ), schizophreniform psychosis ( $n = 10$ ), schizoaffective disorder ( $n = 7$ ), bipolar disorder with psychotic symptoms ( $n = 10$ ), major depression with psychotic symptoms ( $n = 2$ ), delusional disorder ( $n = 2$ ), and psychosis NOS ( $n = 4$ ). All had received antipsychotic medication since entry to the EPPIC program. At time of scanning all but five patients were treated with atypical antipsychotics (mainly 2–4 mg risperidone or 5–10 mg olanzapine), one with fluphenazine decanoate and two with chlorpromazine. One patient was receiving both chlorpromazine and risperidone and medication data were unavailable for one subject.

Thirty UHR patients were recruited from the Personal Assessment and Crisis Evaluation (PACE) Clinic, ORYGEN Youth Health, in Melbourne, Australia (McGorry et al. 2001a; McGorry et al. 2001b; Yung et al. 2003). Fifteen of these participants were included in a recent MRI study of anterior cingulate folding (Yücel et al. 2003). Criteria for the identification of the UHR cohort and the rationale for these criteria have been previously described (McGorry et al. 2001a; McGorry et al. 2001b). Briefly, patients were recruited if they had experienced either brief self-limiting bursts of acute psychotic symptoms with a duration of less than 1 week (BLIPS), and/or subthreshold attenuated psychotic symptoms (Attenuated group), and/or they had a family history of a psychotic disorder or personal history of schizotypal personality disorder in conjunction with a marked deterioration in global functioning maintained for at least 1 month (Trait plus State group). The percentage of subjects in each intake group was: Attenuated Symptoms = 13 (43%); BLIPs = 2 (7%); Trait plus State = 5 (17%); Attenuated Symptoms and Trait plus State = 10 (33%). In addition to these inclusion criteria, all UHR patients were aged between 14 and 30 years, had not experienced a previous psychotic episode (treated or untreated), did not have a neurological disorder, and were not intellectually disabled.

In order to identify the onset of acute levels of psychosis in the UHR group, operationalized criteria for onset of psychosis have been defined (Yung et al. 1998). This threshold requires the presence of daily psychotic symptoms for longer than 1 week, on the clinical grounds that a psychiatrist would normally prescribe antipsychotic medication in these circumstances. UHR subjects were monitored regularly following recruitment to the study to detect whether this threshold for onset of acute psychotic symptoms had been breached. The UHR group was thus subsequently divided into two subgroups: UHR-psychotic (UHR-P;  $n = 6$ ) and UHR-nonpsychotic (UHR-NP;  $n = 24$ ). Of the six UHR-P patients, three developed schizophrenia or schizophreniform disorder, one bipolar disorder with psychotic symptoms, one psychosis NOS, and one delusional disorder.

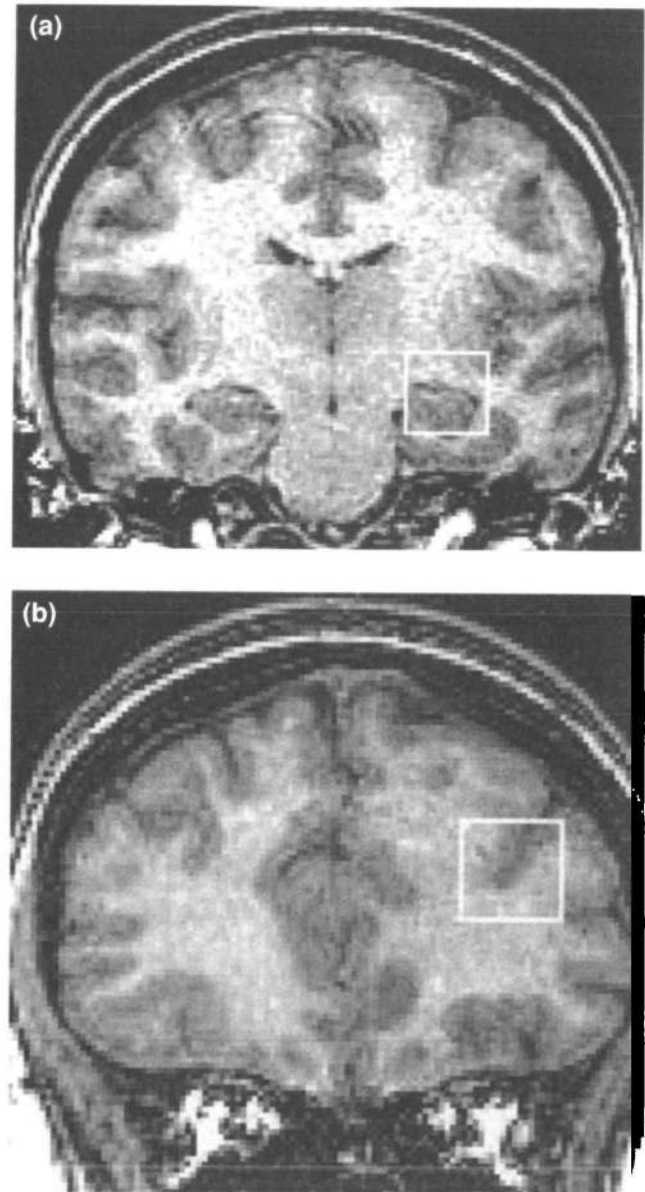
Twenty-one healthy comparison subjects (HC) were recruited by approaching ancillary staff and through advertisements. These subjects were recruited from similar sociodemographic areas as the patients. None have previously been included in a published imaging study.

All subjects were screened for comorbid medical and psychiatric conditions by clinical assessment, physical and neurological examination, and premorbid IQ was estimated using the National Adult Reading Test (NART; Nelson and Willison 1991). Exclusion criteria were a history of significant head injury and/or loss of consciousness for more than 1 minute, electroconvulsive therapy during the 6 months prior to scanning, polydipsia, neurological disease such as epilepsy or cerebrovascular accident, impaired thyroid function, steroid abuse, or *DSM-IV* diagnosis of alcohol or substance dependence. Normal volunteers with a personal or family history of psychiatric illness were excluded. The institutional North Western Health Care Research and Ethics committees approved the research protocol and all subjects provided written informed consent prior to entry into the study.

**MR Spectroscopy.** Proton spectra were acquired from all subjects using a 1.5 Tesla scanner (GE, Milwaukee, WI) at the Royal Melbourne Hospital. Two volumes of interest (VOI; dimensions  $15 \times 15 \times 15$  mm) were obtained from the left hemisphere in each patient, one in the left medial temporal lobe and one in the left middle frontal gyrus. These were localized on the T1 coronal images obtained for volumetric purposes—the midpoint of the medial temporal voxel was positioned 4.5 mm posterior to the amygdala, and the midpoint of the middle frontal voxel was positioned 7.5 mm anterior to the genu of the corpus callosum (figure 1). Shimming was performed by an automated global shim, and water suppressed spectra acquired using a point-resolved spectroscopy sequence (PRESS; TR = 1500 ms, TE = 135 ms, NEX = 128). Spectra were analyzed using LCModel (Provencher 1993), and data are reported as the ratio over the creatine/phosphocreatine peak (Cr; 3.02 ppm) of N-acetylaspartate (NAA; 2.01 ppm) and choline-containing compounds (Cho; 3.20 ppm), and the ratio of NAA to Cho.

**MR Volumetry.** A three-dimensional volumetric spoiled gradient recalled echo in the steady state sequence generated 124 contiguous, 1.5-mm coronal slices. Imaging parameters were: time-to-echo, 3.3 msec; time-to-repetition, 14.3 msec; flip angle,  $30^\circ$ ; matrix size,  $256 \times 256$ ; field of view,  $24 \times 24$  cm matrix; voxel dimensions,  $0.938 \times 0.938 \times 1.5$  mm. MRI data were transferred from DAT tape to an SGI-O2 workstation and analyzed using ANALYZE 7.2 (MAYO). A code was used to ensure

**Figure 1.** MR Images showing the location of the midpoint of (a) the medial temporal voxel and (b) the dorsolateral prefrontal voxel. Note that images are presented in radiological format, with the left hemisphere on the right.



patient confidentiality and blind rating of data. Methods for estimating hippocampal and whole brain volumes, and intraclass correlations for intra- and interrater reliability, have been previously described (Velakoulis et al. 1999).

**Statistical Analysis.** Demographic information was compared between the groups using chi-square, *t* tests, and one-way analyses of variance. Metabolite ratios were compared between groups using an analysis of covari-

ance, which controlled for age. Post-hoc comparisons were performed with Sidak's test.

## Results

**Demographic Data.** Demographic details are presented in table 1. The HC group was significantly older than both patient groups, and the FE group was also significantly older than the UHR group. In addition, the HC group had significantly higher NART-estimated IQ scores than the FE group.

**Left Medial Temporal Lobe.** Two FE patients and three UHR subjects (one UHR-P and two UHR-NP) had unusable spectra and were excluded from the analysis. Given the significant difference in age between patient and control groups, analyses of covariance were performed controlling for age, which revealed no significant group differences for either NAA/Cr ( $F_{2,101} = 0.52, p = 0.594$ ), Cho/Cr ( $F_{2,101} = 0.37, p = 0.69$ ), or NAA/Cho ( $F_{2,101} = 0.47, p = 0.626$ ). Mean data are displayed in table 2.

**Left Dorsolateral Prefrontal Cortex.** Seven spectra were unavailable for this location (two FE, one UHR-P, and four HC) owing to time constraints during the scanning procedure. A further four spectra (three FE and one UHR-P) were regarded as unusable and excluded from analysis. Mean data are displayed in table 2. Again, age was controlled for when comparing the mean ratios of the three groups. There was no significant difference for the NAA/Cho ratio ( $F_{2,95} = 0.27, p = 0.761$ ). However, signif-

icant differences were identified for both NAA/Cr ( $F_{2,95} = 5.13, p = 0.008$ ) and Cho/Cr ( $F_{2,95} = 3.33, p = 0.040$ ). Post-hoc comparisons revealed that the UHR group had significantly higher ratios than both the FE and HC groups for both NAA/Cr and Cho/Cr ( $p < 0.05$ ; figure 2).

**Psychotic versus Non-psychotic Outcome in the UHR Group.** The UHR group was subdivided into those who later developed psychosis and those who did not. No significant differences were identified between these two groups for any ratio of interest. However, there was a trend toward a significantly higher NAA/Cho ratio in the UHR-P subgroup compared to the UHR-NP group for the medial temporal voxel (UHR-P =  $4.24 \pm 0.98$ , UHR-NP =  $3.25 \pm 0.93$ ;  $F_{1,26} = 4.11, p = 0.054$ ).

**Schizophrenia versus Affective Psychosis.** The FE group was subdivided into those with a primary diagnosis of schizophrenia or schizophreniform disorder, and those with affective psychosis (bipolar disorder or major depression with psychotic features). There were no differences between these two groups for any ratio in either region of interest.

**Short versus Long Duration of Untreated Psychosis.** Duration of untreated psychosis (DUP) data were available for 47 of the 56 FE patients, and the group was stratified by a median split into those with short (less than 1 month,  $n = 23$ ) versus those with long (greater than 1 month,  $n = 24$ ) DUP. The median DUP for this latter group was 182 days, with a maximum DUP of 3,317 days. No significant differences were identified between these

**Table 1. Demographic details for the subject groups; displayed as means (standard deviations)**

	Subject Group			Test statistic
	FE	UHR	HC	
Percentage male, $p = n.s.$	64%	57%	62%	$\chi^2(2)=0.48$
Age at baseline assessment, $p < 0.001$	21.7 (3.2)	19.5 (3.5)	34.1 (10.0)	$F(2,106)=53.1$
Premorbid IQ, $p < 0.05^1$	91.1 (13.5)	97.7 (14.7)	103.0 (13.3)	$F(2,88)=4.8$

<sup>1</sup> Data available for only 45 FE, 29 UHR, and 15 HC participants.

**Table 2. Proton MRS metabolite ratios (adjusted for age) for the three groups at each voxel; data displayed as mean (95% confidence interval)**

	Left medial temporal voxel			Left dorsolateral prefrontal voxel		
	NAA/Cr	Cho/Cr	NAA/Cho	NAA/Cr	Cho/Cr	NAA/Cho
FE	1.594 (0.085)	0.490 (0.024)	3.283 (0.222)	2.355 (0.136)	0.424 (0.027)	5.677 (0.273)
UHR	1.574 (0.125)	0.476 (0.036)	3.400 (0.325)	2.685 (0.191)	0.471 (0.038)	5.820 (0.383)
HC	1.694 (0.176)	0.505 (0.052)	3.508 (0.457)	2.172 (0.329)	0.373 (0.066)	5.845 (0.663)

**Figure 2. Bar chart showing the mean metabolite ratios ( $\pm$  95% confidence intervals) in the left DLPFC for (a) NAA/Cr and (b) Cho/Cr. \*Mark significant differences to the HC group at  $p < 0.05$ .**

Figure 2 (a)

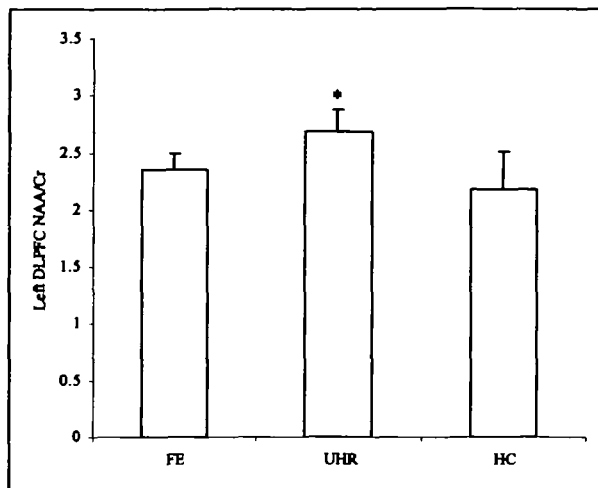
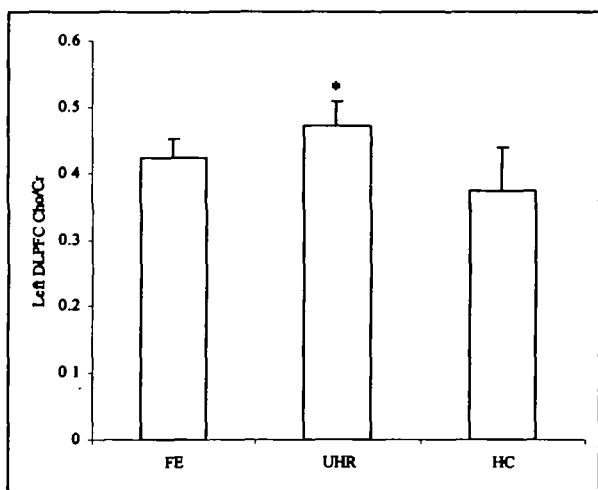


Figure 2 (b)



two groups for any ratio of interest. This result was supported by Spearman's correlations, all of which were non-significant (NAA/Cr  $\rho = -0.2$ ; Cho/Cr  $\rho = 0.03$ ; NAA/Cho  $\rho = -0.18$ ).

**Correlations Between Left Hippocampal Volume and Metabolite Ratios.** Hippocampal and whole brain volumes were available for all but seven participants (four FE, one UHR-NP, and two HC). A comparison of left hippocampal volume between the three groups, covarying for whole brain volume, did not reveal a significant difference ( $F_{2,99} = 0.61$ ,  $p = 0.55$ ). However, an exploratory correla-

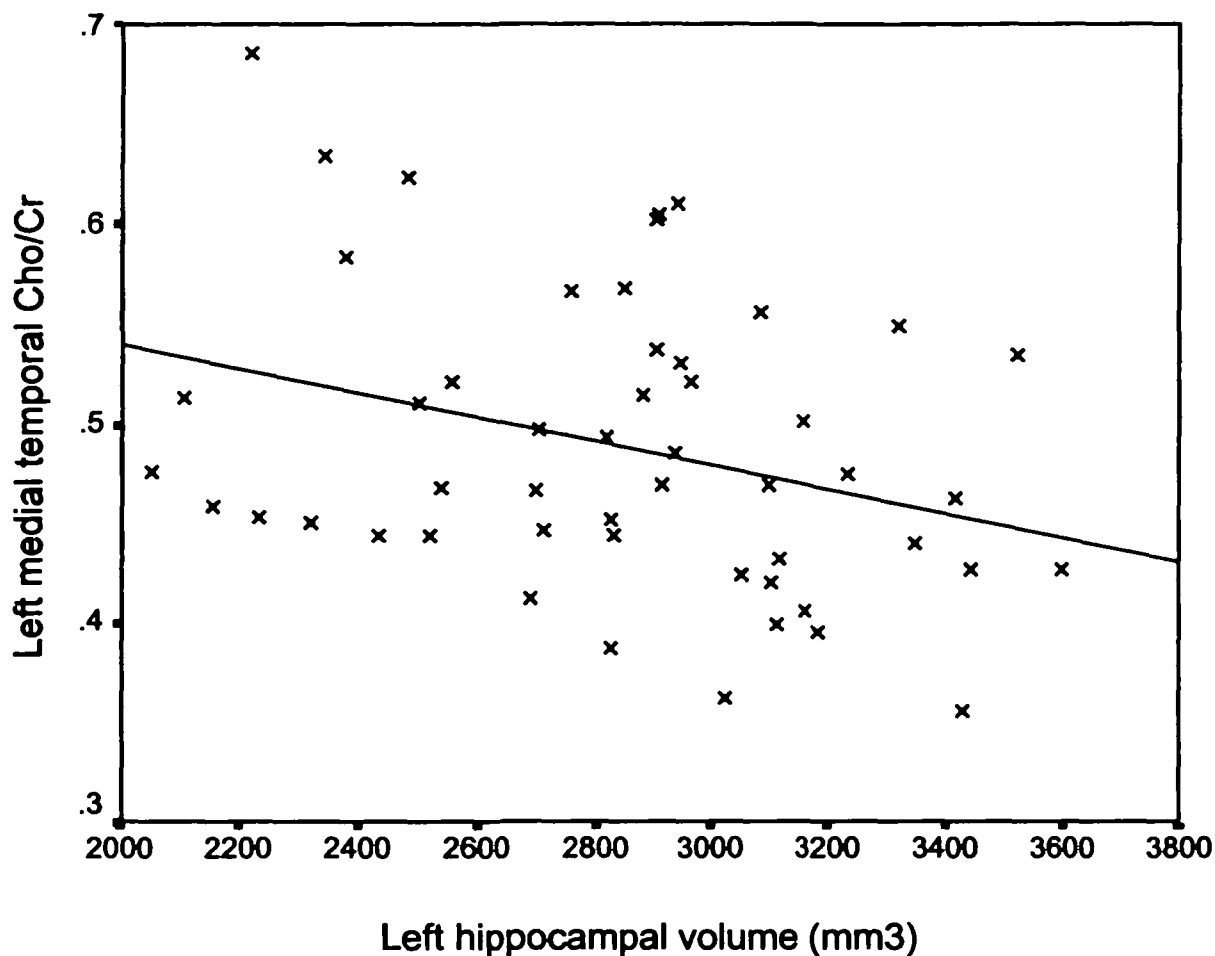
tional analysis of the relationship between left hippocampal volume and the left medial temporal metabolite ratios revealed a significant negative association between volume and Cho/Cr ratio, which was specific to the FE group ( $r = -0.31$ ,  $p = 0.025$ ; figure 3).

## Discussion

To our knowledge, this is the largest cross-sectional proton spectroscopy study in first episode psychosis, and the only such study of subjects at ultra high-risk for psychosis. Our results indicate that there are no significant reductions in NAA/Cr or Cho/Cr ratios in either patient group, in either the left medial temporal lobe or the left dorsolateral prefrontal region. However, there was a significant increase in NAA/Cr and Cho/Cr ratios in the DLPFC of the UHR group, with no difference identified in the NAA/Cho ratio. These results are suggestive of a reduction in the Cr peak rather than an increase in NAA or choline-containing compounds. This may reflect hypometabolism in the frontal lobe prior to onset of psychosis (see below). Interestingly there was a trend toward a significantly higher medial temporal NAA/Cho ratio in the UHR-P group compared to the UHR-NP group. This result is consistent with our unexpected volumetric findings that "normal" left hippocampi in the UHR-P group were predictive for transition to psychosis (Phillips et al. 2002). Taken together, these data may suggest that the left hippocampus of the UHR-P group is undergoing compensatory change under the influence of whatever trigger has initiated the onset of psychosis, which is followed by a decline in volume after transition (Pantelis et al. 2003a).

Normal NAA/Cr and Cho/Cr ratios may reflect intact neuronal circuits in the early phase of psychotic disorders, which may not be the case in more chronic stages of schizophrenia. While this interpretation is speculative, it is supported by the clinical observation that a majority of first episode psychosis patients (over 80%) have a good initial treatment response (Robinson et al. 1999), with a decrease in treatment response over the course of illness (Lieberman et al. 1996). However, this group of first episode psychosis patients did not display a reduction in left hippocampal volume (in contrast to an earlier cohort from the same centre [Velakoulis et al. 1999]), which may indicate that they are different from other first episode populations, perhaps in that they are very much earlier in the course of illness. An alternative proposition would be that abnormal ratios of NAA/Cr are predictive of a poor prognosis, implying that as long as metabolic changes are not present a better clinical outcome can be expected. While there is some evidence for the prognostic value of structural brain imaging (Wassink et al. 1999; Rossi et al. 2000), the predictive value of metabolic imaging for outcome is still

**Figure 3. Scatter graph of the relationship between left hippocampal volume and left medial temporal Cho/Cr ratio for the FE group.**



unclear. In this regard it is interesting that the stratification of the FE cohort into long versus short duration of untreated psychosis did not reveal any significant differences, suggesting that there is unlikely to be a longitudinal decline in metabolite ratios.

It is also possible that our lack of significant differences between FE and HC groups reflects the diagnostic heterogeneity of the FE sample, where previous publications have included only patients with schizophrenia or schizophreniform disorder. However, a direct comparison of subgroups comprised only of those with schizophrenia-spectrum or affective psychosis diagnoses did not support the notion that the former group displays greater degrees of metabolic abnormalities. This may be because these diagnoses were made at a relatively early stage of the disorder and are open to revision in the light of subsequent episodes.

The increase in NAA/Cr and Cho/Cr ratios in the UHR group (with a normal NAA/Cho ratio) suggests a reduction in the Cr peak. The Cr peak is made up of contri-

butions from both creatine (Cr) and phosphocreatine (PCr), meaning that a change in the concentration of either metabolite could potentially result in a change to the overall peak. In states of increased metabolic demand (such as during an activation paradigm), PCr is converted to Cr. Because the relaxation time of Cr is greater than that of PCr (Ke et al. 2002), this hypermetabolic state results in an increase in the total creatine resonance peak. Conversely, increased amounts of PCr compared to Cr (as would be seen in cases of hypometabolism) would produce a lower total creatine resonance peak. It therefore seems possible that the UHR group is experiencing a hypometabolic state in the left DLPFC. Although there are no previously published data demonstrating an association between increased Cr (as opposed to PCr) levels and hypometabolism, such an explanation provides a potential explanation for the working memory deficits found in this population (Wood et al. 2003). A preliminary correlational analysis between working memory performance and prefrontal metabolite ratios (covaried for estimated IQ) in 25



of the UHR demonstrates a significant association for both NAA/Cr and Cho/Cr ( $r = 0.44$  and  $r = 0.35$ , respectively). However, this association implies that better working memory performance was associated with higher NAA/Cr and Cho/Cr levels, which does not support the hypometabolism hypothesis, but a fuller interpretation of these findings requires investigation with functional imaging and an appreciation of the developmental trajectory for this function (Wood et al., in press *a*).

An alternative hypothesis for the increase in the NAA/Cr and Cho/Cr ratios in the UHR group is that it reflects different proportions of grey and white matter within the voxel in this population compared to the FE and HC groups. We have already demonstrated that there are alterations in cortical folding in the anterior cingulate region of UHR patients (Yücel et al. 2003), so potentially this could also occur in the dorsolateral prefrontal cortex. Yet another possibility is that this metabolic change may be a transitory compensatory reaction, an explanation that can only be demonstrated by longitudinal studies.

Correlations between MRS measures and hippocampal volume have been previously reported in disorders with known neuropathology, such as temporal lobe epilepsy (Sawrie et al. 2001), although the shared variance is low (presumably because the hippocampus makes up only part of the MRS voxel). Of more interest to this study, however, is the fact that neuropsychiatric disorders such as schizophrenia (Deicken et al. 1999; Maier et al. 2000), posttraumatic stress disorder (Schuff et al. 2001), and depression (Mervaala et al. 2000), where our understanding of the neuropathology is scant, show little or no relationship between the two MR measures. Because of this, and given the number of statistical comparisons performed, the moderate correlation between reduced hippocampal volume and increased Cho/Cr ratio in the FE group should be treated cautiously. However, one interpretation of this finding is that it may reflect increased apoptotic activity and less neuronal trophic activity in temporal structures in some patients during the early phase of psychotic disorders (Berger et al. 2003). Increased apoptotic activity is associated with the breakdown of cell membranes, which contain a large amount of choline-containing compounds, and studies in drug-naïve patients with a first episode psychosis do suggest that the emerging psychotic state is associated with increased membrane turnover (Pettegrew et al. 1991; Stanley et al. 1995). However, proton MRS is not the best tool for the investigation of these metabolites and a better explanation of these findings will require research using phosphorous spectroscopy in the early phase of psychotic illnesses.

There were some limitations to this study, not least the small and poorly matched comparison sample. This group was the most variable of the three in terms of their

metabolite ratios, which may have contributed to our failure to find additional significant effects. Second, we used ratios of the three metabolites rather than absolute quantitation. In addition, there may be alterations in the chemical environment of the brains of patients with schizophrenia that materially affect the signal from the metabolites being measured by this technique, further confusing the issue (Ke et al. 2003).

This study only investigated voxels placed in the left hemisphere. The decision to examine only left-sided structures was determined by both theoretical and logistic considerations. The theoretical considerations were based on our previous hippocampal volumetric findings (Velakoulis et al. 1999) and the extant literature that has implicated left dorsolateral prefrontal cortex structural and functional abnormalities in schizophrenia (Gur et al. 2000; Barch et al. 2001). The logistic considerations related to the acceptable length of time subjects could remain in the scanner. In order to acquire spectroscopic data, standard volumetric scans are initially acquired and used to facilitate voxel placement. This time remaining was sufficient for the spectroscopic examination of two regions of interest. Future studies will need to explore the possible effects of hemisphere (including altered asymmetry) in these groups.

The effect of medication is another potentially confounding factor. Whereas none of the prodromal patients were medicated, all but five FE patients were treated with atypical neuroleptics. Treatment with antipsychotics is already known to increase NAA concentrations within the DLPFC (Bertolino et al. 2001) and to change activation patterns on functional imaging (Braus et al. 1999; Honey et al. 1999; Liddle et al. 2000). It is therefore possible that medication effects may have resulted in changes in energy metabolism (Cr and PCr) in the frontal lobe, thereby explaining the difference between the UHR and FE groups in this region. Future longitudinal research using absolute values in drug-naïve FE patients will need to address this question.

In conclusion, this study did not demonstrate left medial temporal or prefrontal neurochemical changes in first episode psychosis patients. Although some left prefrontal differences of uncertain etiology were identified in subjects at ultra high-risk, this group also had apparently normal left medial temporal biochemistry (although there was a trend toward an elevation of NAA/Cho in the UHR-P subgroup). This study, taken together with our previous reports (Phillips et al. 2002; Pantelis et al. 2003a; Wood et al. 2003; Yücel et al. 2003), suggests that while the frontal lobes appear to be both structurally and functionally altered prior to the onset of psychotic illness, changes in the medial temporal lobe are less pronounced. Instead, it appears that these abnormalities arise during the emerging psychotic state. This model is in accord with our prelimi-

nary data indicating that medial temporal function (verbal paired associate memory) is also unimpaired in the UHR cohort (Pantelis et al. 2003b).

Future longitudinal MRI and MRS studies, at high field and at different illness stages beginning at the prodrome, are now needed to confirm and extend our findings, and may contribute to a greater understanding of the neurobiological processes related to the early course of schizophrenia and related disorders.

## References

- Armstrong, E.; Schleicher, A.; Omran, H.; Curtis, M.; and Zilles, K. The ontogeny of human gyrification. *Cerebral Cortex*, 5:56–63, 1995.
- Barch, D.M.; Carter, C.S.; Braver, T.S.; Sabb, F.W.; MacDonald, A.; Noll, D.; and Cohen, J.D. Selective deficits in prefrontal cortex function in medication-naive patients with schizophrenia. *Archives of General Psychiatry*, 58:280–288, 2001.
- Bartha, R.; Al-Semaan, Y.M.; Williamson, P.C.; Drost, D.J.; Malla, A.K.; Carr, T.J.; Densmore, M.; Canaran, G.; and Neufeld, R.W. A short echo proton magnetic resonance spectroscopy study of the left mesial-temporal lobe in first-onset schizophrenic patients. *Biological Psychiatry*, 45:1403–1411, 1999.
- Benes, F.M. Myelination of cortical-hippocampal relays during late adolescence. *Schizophrenia Bulletin*, 15:585–593, 1989.
- Berger, G.; Wood, S.J.; and McGorry, P.D. Incipient neurovulnerability and neuroprotection in early psychosis. *Psychopharmacology Bulletin*, 37:79–101, 2003.
- Bertolino, A.; Callicott, J.H.; Mattay, V.S.; Weidenhammer, K.M.; Rakow, R.; Egan, M.; and Weinberger, D.R. The effect of treatment with antipsychotic drugs on brain N-acetylaspartate measures in patients with schizophrenia. *Biological Psychiatry*, 49:39–46, 2001.
- Bertolino, A.; Esposito, G.; Callicott, J.H.; Mattay, V.S.; Van Horn, J.D.; Frank, J.A.; Berman, K.F.; and Weinberger, D.R. Specific relationship between prefrontal neuronal N-Acetylaspartate and activation of the working memory cortical network in schizophrenia. *American Journal of Psychiatry*, 157:26–33, 2000.
- Bertolino, A.; Sciota, D.; Brudaglio, F.; Altamura, M.; Blasi, G.; Bellomo, A.; Antonucci, N.; Callicott, J.H.; Goldberg, T.E.; Scarabino, T.; Weinberger, D.R.; and Nardini, M. Working memory deficits and levels of N-Acetylaspartate in patients with schizophreniform disorder. *American Journal of Psychiatry*, 160:483–489, 2003.
- Birken, D., and Oldendorf, W. N-acetyl-L-aspartic acid: A literature review of a compound prominent in  $^1\text{H}$  NMR spectroscopic studies of the brain. *Neuroscience and Biobehavioural Reviews*, 13:23–31, 1989.
- Block, W.; Bayer, T.A.; Tepest, R.; Träber, F.; Rietschel, M.; Müller, D.J.; Schulze, T.G.; Honer, W.G.; Maier, W.; Schild, H.H.; and Falkai, P. Decreased frontal lobe ratio of N-acetyl aspartate to choline in familial schizophrenia: A proton magnetic resonance spectroscopy study. *Neuroscience Letters*, 289:147–151, 2000.
- Braus, D.F.; Ende, G.; Weber-Fahr, W.; Sartorius, A.; Krier, A.; Hubrich-Ungureanu, P.; Ruf, M.; Stuck, S.; and Henn, F.A. Antipsychotic drug effects on motor activation measured by functional magnetic resonance imaging in schizophrenic patients. *Schizophrenia Research*, 39(1):19–29, 1999.
- Callicott, J.H.; Bertolino, A.; Egan, M.; Mattay, V.S.; Langheim, F.J.; and Weinberger, D.R. Selective relationship between prefrontal N-acetylaspartate measures and negative symptoms in schizophrenia. *American Journal of Psychiatry*, 157:1646–1651, 2000.
- Callicott, J.H.; Egan, M.; Bertolino, A.; Mattay, V.S.; Langheim, F.J.; Frank, J.A.; and Weinberger, D.R. Hippocampal N-acetyl aspartate in unaffected siblings of patients with schizophrenia: A possible intermediate neurobiological phenotype. *Biological Psychiatry*, 44:941–950, 1998.
- Chi, J.; Dooling, E.; and Gilles, F. Gyril development of the human brain. *Annals of Neurology*, 1:86–93, 1977.
- Deicken, R.F.; Pegues, M.; and Amend, D. Reduced hippocampal N-acetylaspartate without volume loss in schizophrenia. *Schizophrenia Research*, 37:217–223, 1999.
- First, M.B.; Spitzer, R.L.; Gibbon, M.; and Williams, J.B. *Structured Clinical Interview for DSM-IV Axis I Disorders*. Washington, DC: American Psychiatric Press, 1997.
- Gur, R.E.; Cowell, P.; Latshaw, A.; Turetsky, B.I.; Grossman, R.I.; Arnold, S.E.; Bilker, W.; and Gur, R.C. Reduced dorsal and orbital prefrontal gray matter volumes in schizophrenia. *Archives of General Psychiatry*, 57:761–768, 2000.
- Harrison, P.J. The neuropathology of schizophrenia: A critical review of the data and their interpretation. *Brain*, 122:593–624, 1999.
- Honey, G.D.; Bullmore, E.T.; Soni, W.; Varatheesan, M.; Williams, S.C.; and Sharma, T. Differences in frontal cortical activation by a working memory task after substitution of risperidone for typical antipsychotic drugs in patients with schizophrenia. *Proceedings of the National Academy of Sciences of the United States of America*, 96(23):13432–13437, 1999.

- Ke, Y.; Cohen, B.M.; Lowen, S.; Hirashima, F.; Nassar, L.; and Renshaw, P.F. Biexponential transverse relaxation ( $T_2$ ) of the proton MRS creatine resonance in human brain. *Magnetic Resonance in Medicine*, 47:232–238, 2002.
- Ke, Y.; Coyle, J.T.; Simpson, N.; Gruber, S.A.; Renshaw, P.F.; and Yurgelun-Todd, D. Frontal brain NAA T2 values are significantly lower in schizophrenia. *Schizophrenia Research*, 60:242, 2003.
- Keshavan, M.S.; Montrose, D.M.; Pierri, J.N.; Dick, E.L.; Rosenberg, D.; Talagala, L.; and Sweeney, J.A. Magnetic resonance imaging and spectroscopy in offspring at risk for schizophrenia: Preliminary studies. *Progress in Neuro-Psychopharmacology and Biological Psychiatry*, 21:1285–1295, 1997.
- Keshavan, M.S.; Stanley, J.A.; and Pettegrew, J.W. Magnetic resonance spectroscopy in schizophrenia: Methodological issues and findings—Part II. *Biological Psychiatry*, 48:369–380, 2000.
- Kulynych, J.; Luevano, L.; Jones, D.; and Weinberger, D.R. Cortical abnormality in schizophrenia: An in vivo application of the gyrification index. *Biological Psychiatry*, 41:995–999, 1997.
- Lawrie, S.M.; Whalley, H.; Kestelman, J.N.; Abukmeil, S.S.; Byrne, M.; Hodges, A.; Rimmington, J.E.; Best, J.J.; Owens, D.G.; and Johnstone, E.C. Magnetic resonance imaging of brain in people at high risk of developing schizophrenia. *The Lancet*, 353:30–33, 1999.
- Liddle, P.F.; Lane, C.J.; and Ngan, E.T. Immediate effects of risperidone on cortico-striato-thalamic loops and the hippocampus. *British Journal of Psychiatry*, 177:402–407, 2000.
- Lieberman, J.A.; Alvir, J.M.; Koreen, A.; Geisler, S.; Chakos, M.; Sheitman, B.B.; and Woerner, M.G. Psychobiologic correlates of treatment response in schizophrenia. *Neuropsychopharmacology*, 14:13S–21S, 1996.
- Lieberman, J.A.; Perkins, D.; Belger, A.; Chakos, M.; Jarskog, F.; Boteva, K.; and Gilmore, J. The early stages of schizophrenia: Speculations on pathogenesis, pathophysiology, and therapeutic approaches. *Biological Psychiatry*, 50:884–897, 2001.
- Maier, M.; Mellers, J.; Toone, B.K.; Trimble, M.; and Ron, M.A. Schizophrenia, temporal lobe epilepsy and psychosis: An in vivo magnetic resonance spectroscopy and imaging study of the hippocampus/amygdala complex. *Psychological Medicine*, 30:571–581, 2000.
- Marenco, S., and Weinberger, D.R. The neurodevelopmental hypothesis of schizophrenia: Following a trail of evidence from cradle to grave. *Development and Psychopathology*, 12:501–527, 2000.
- McCarley, R.W.; Wible, C.G.; Frumin, M.; Hirayasu, Y.; Fischer, I.A.; and Shenton, M.E. MRI anatomy of schizophrenia. *Biological Psychiatry*, 45:1085–1098, 1999.
- McGlashan, T.H., and Hoffman, R.E. Schizophrenia as a disorder of developmentally reduced synaptic connectivity. *Archives of General Psychiatry*, 57:637–648, 2000.
- McGorry, P.D.; Edwards, J.; Mihalopoulos, C.; Harrigan, S.; and Jackson, H. EPPIC—An evolving system of early detection and optimal management. *Schizophrenia Bulletin*, 22:305–326, 1996.
- McGorry, P.D.; Kaplan, I.; Dossessor, C.; Herman, H.; Copolov, D.; and Singh, B. *Royal Park Multidiagnostic Instrument for Psychosis*. Melbourne: Australian National Health and Medical Research Council, 1989.
- McGorry, P.D.; Phillips, L.J.; and Yung, A.R. Recognition and treatment of the pre-psychotic phase of psychotic disorders: Frontier or fantasy? In: Miller, T.; Mednick, S.A.; McGlashan, T.H.; Libiger, J.; and Johanssen, J., eds. *Early Intervention in Psychiatric Disorders*. Amsterdam, Netherlands: Kluwer, 2001a. pp. 101–122.
- McGorry, P.D.; Yung, A.R.; and Phillips, L.J. 'Closing in': What features predict the onset of first episode psychosis within a high risk group? In: Zipursky, R., and Schulz, S.C., eds. *The Early Stages of Schizophrenia*. Washington, DC: American Psychiatric Press, 2001b. pp. 3–32.
- McGorry, P.D.; Yung, A.R.; Phillips, L.J.; Yuen, H.P.; Francey, S.; Cosgrave, E.; Germano, D.; Bravin, J.; McDonald, A.; Blair, A.; Adlard, S.; and Jackson, H.J. Randomized controlled trial of interventions designed to reduce the risk of progression to first-episode psychosis in a clinical sample with subthreshold symptoms. *Archives of General Psychiatry*, 59:921–928, 2002.
- McGrath, J.; Van Os, J.; Hoyos, C.; Jones, P.; Harvey, I.; and Murray, R.M. Minor physical anomalies in psychoses: Associations with clinical and putative aetiological variables. *Schizophrenia Research*, 18:9–20, 1995.
- Mervaala, E.; Föhr, J.; Könönen, M.; Valkonen-Korhonen, M.; Vainio, P.; Partanen, K.; Partanen, J.; Tiitonen, J.; Viinamäki, H.; Karjalainen, A.; and Lehtonen, J. Quantitative MRI of the hippocampus and amygdala in severe depression. *Psychological Medicine*, 30:117–126, 2000.
- Murray, R.M., and Lewis, S. Is schizophrenia a neurodevelopmental disorder? [Editorial]. *British Medical Journal*, 295:681–682, 1987.
- Narr, K.L.; Thompson, P.; Sharma, T.; Moussai, J.; Zoumalan, C.; Rayman, J.; and Toga, A. Three-dimensional mapping of gyral shape and cortical surface asymmetries in schizophrenia: Gender effects. *American Journal of Psychiatry*, 158:244–255, 2001.

- Nelson, H.E., and Willison, J.R. Restandardisation of the NART against the WAIS-R. In: Nelson, H.E., ed. *National Adult Reading Test (NART) Test Manual*. Windsor, U.K.: NFER-Nelson, 1991. pp. 13–23.
- Nelson, M.D.; Saykin, A.J.; Flashman, L.A.; and Riordan, H.J. Hippocampal volume reduction in schizophrenia as assessed by magnetic resonance imaging: A meta-analytic study. *Archives of General Psychiatry*, 55:433–440, 1998.
- Oppenheimer, D. Diseases of the basal ganglia, cerebellum, and motor neurons. In: Adams, J.; Corsellis, J.; and Duchen, L., eds. *Greenfield's Neuropathology*. New York, NY: Wiley, 1984. pp. 699–747.
- Pantelis, C. Overview: Towards a neuropsychology of schizophrenia. In: Pantelis, C.; Nelson, H.E.; and Barnes, T.R., eds. *Schizophrenia: A Neuropsychological Perspective*. London, UK: John Wiley & Sons, 1996. pp. 3–18.
- Pantelis, C.; Velakoulis, D.; McGorry, P.D.; Wood, S.J.; Suckling, J.; Phillips, L.J.; Yung, A.R.; Bullmore, E.T.; Brewer, W.J.; Soulsby, B.; Desmond, P.; and McGuire, P.K. Neuroanatomical abnormalities before and after onset of psychosis: A cross-sectional and longitudinal MRI study. *The Lancet*, 361:281–288, 2003a.
- Pantelis, C.; Wood, S.J.; Tarnawski, A.; Proffitt, T.; Francey, S.; Brewer, W.J.; Phillips, L.J.; Savage, G.R.; Smith, D.; Anderson, V.; and McGorry, P.D. Verbal paired associate learning in schizophrenia, schizophreniform psychosis and 'at risk' mental state. *Schizophrenia Research*, 60:151–152, 2003b.
- Pantelis, C.; Yücel, M.; Wood, S.J.; McGorry, P.D.; and Velakoulis, D. Early and late neurodevelopmental disturbances in schizophrenia and their functional consequences. *Australian and New Zealand Journal of Psychiatry*, 37:399–406, 2003c.
- Pettegrew, J.W.; Keshavan, M.S.; Panchalingam, K.; Strychor, S.; Kaplan, D.; Tretta, M.; and Allen, M. Alterations in brain high-energy phosphate and membrane phospholipid metabolism in first-episode, drug-naive schizophrenics. A pilot study of the dorsal prefrontal cortex by in vivo phosphorus 31 nuclear magnetic resonance spectroscopy. *Archives of General Psychiatry*, 48:563–568, 1991.
- Phillips, L.J.; Velakoulis, D.; Pantelis, C.; Wood, S.J.; Yuen, H.P.; Yung, A.R.; Desmond, P.; Brewer, W.J.; and McGorry, P.D. Non-reduction in hippocampal volume is associated with risk for psychosis. *Schizophrenia Research*, 58:145–158, 2002.
- Phillips, L.J.; Yung, A.R.; and McGorry, P.D. Identification of young people at risk of psychosis: Validation of Personal Assessment and Crisis Evaluation Clinic intake criteria. *Australian and New Zealand Journal of Psychiatry*, 34 (Suppl):S164–S169, 2000.
- Provencher, S. Estimation of metabolite concentrations from localized in vivo proton NMR spectra. *Magnetic Resonance in Medicine*, 30:672–679, 1993.
- Robinson, D.; Woerner, M.G.; Alvir, J.M.; Geisler, S.; Koreen, A.; Sheitman, B.B.; Chakos, M.; Mayerhoff, D.; Bilder, R.M.; Goldman, R.; and Lieberman, J.A. Predictors of treatment response from a first episode of schizophrenia or schizoaffective disorder. *American Journal of Psychiatry*, 156:544–549, 1999.
- Rossi, A.; Bustini, M.; Prosperini, P.; Marinangeli, M.; Splendiani, A.; Daneluzzo, E.; and Stratta, P. Neuromorphological abnormalities in schizophrenic patients with good and poor outcome. *Acta Psychiatrica Scandinavica*, 101:161–166, 2000.
- Sawrie, S.M.; Martin, R.C.; Knowlton, R.C.; Faught, E.; Gilliam, F.G.; and Kuzniecky, R. Relationships among hippocampal volumetry, proton magnetic resonance spectroscopy, and verbal memory in temporal lobe epilepsy. *Epilepsia*, 42:1403–1407, 2001.
- Schuff, N.; Neylan, T.; Lenoci, M.; Du, A.; Weiss, D.; Marmar, C.; and Weiner, M. Decreased hippocampal N-acetylaspartate in the absence of atrophy in posttraumatic stress disorder. *Biological Psychiatry*, 50:952–959, 2001.
- Španiel, F.; Hájek, T.; Tintera, J.; Harantová, P.; Dezortová, M.; and Hájek, M. Differences in fMRI and MRS in a monozygotic twin pair discordant for schizophrenia (case report). *Acta Psychiatrica Scandinavica*, 107:155–158, 2003.
- Stanley, J.A.; Williamson, P.; Drost, D.J.; Carr, T.J.; Rylett, R.; Malla, A.K.; and Thompson, R. An in vivo study of the prefrontal cortex of schizophrenic patients at different stages of illness via phosphorus magnetic resonance spectroscopy. *Archives of General Psychiatry*, 52:399–406, 1995.
- Stanley, J.A.; Williamson, P.C.; Drost, D.; Rylett, R.; Carr, T.J.; Malla, A.K.; and Thompson, R. An in vivo proton magnetic resonance spectroscopy study of schizophrenia patients. *Schizophrenia Bulletin*, 22:597–609, 1996.
- Urenjak, J.; Williams, S.R.; Gadian, D.G.; and Noble, M. Proton nuclear magnetic resonance spectroscopy unambiguously identifies different neural cell types. *Journal of Neuroscience*, 13(3):981–989, 1993.
- van Os, J.; Jones, P.; Lewis, G.; Wadsworth, M.; and Murray, R. Developmental precursors of affective illness in a general population birth cohort. *Arch Gen Psychiatry*, 54(7):625–631, 1997.
- Velakoulis, D.; Pantelis, C.; McGorry, P.D.; Dudgeon, P.; Brewer, W.J.; Cook, M.J.; Desmond, P.; Bridle, N.;

- Tierney, P.; Murrie, V.; Singh, B.; and Copolov, D. Hippocampal volume in first-episode psychoses and chronic schizophrenia: A high-resolution magnetic resonance imaging study. *Archives of General Psychiatry*, 56:133–140, 1999.
- Vogeley, K.; Schneider-Axmann, T.; Pfeiffer, U.; Tepest, R.; Bayer, T.A.; Bogerts, B.; Honer, W.G.; and Falkai, P. Disturbed gyrification of the prefrontal region in male schizophrenic patients: A morphometric postmortem study. *American Journal of Psychiatry*, 157:34–39, 2000.
- Walker, E.; Savoie, T.; and Davis, D. Neuromotor precursors of schizophrenia. *Schizophrenia Bulletin*, 20:441–451, 1994.
- Wassink, T.H.; Andreasen, N.C.; Nopoulos, P.; and Flaum, M. Cerebellar morphology as a predictor of symptom and psychosocial outcome in schizophrenia. *Biological Psychiatry*, 45:41–48, 1999.
- Weinberger, D.R. Implications of normal brain development for the pathogenesis of schizophrenia. *Archives of General Psychiatry*, 44:660–669, 1987.
- Wood, S.J.; De Luca, C.R.; Anderson, V.; and Pantelis, C. Cognitive development in adolescence: Cerebral underpinnings, neural trajectories and the impact of aberrations. In: Keshavan, M.S.; Kennedy, J.L.; and Murray, R.M., eds. *The Developmental Trajectory to Schizophrenia: From Neurodevelopmental Deviance to Psychotic Syndrome*. Cambridge, U.K.: Cambridge University Press, in press.
- Wood, S.J., and Pantelis, C. Does a neurodevelopmental lesion involving the hippocampus explain memory dysfunction in schizophrenia? *Zeitschrift für Neuropsychologie*, 12(1):61–67, 2001.
- Wood, S.J.; Pantelis, C.; Proffitt, T.; Phillips, L.J.; Stuart, G.W.; Buchanan, J.-A.; Mahony, K.; Brewer, W.J.; Smith, D.; and McGorry, P.D. Spatial working memory ability is a marker of risk-for-psychosis. *Psychological Medicine*, 33:1239–1247, 2003.
- Worthen, N.; Gilbertson, V.; and Lau, C. Cortical sulcal development seen on sonography: Relationship to gestational parameters. *Journal of Ultrasound in Medicine*, 5:153–156, 1986.
- Yücel, M.; Stuart, G.W.; Maruff, P.; Wood, S.J.; Savage, G.; Smith, D.; Crowe, S.F.; Copolov, D.; Velakoulis, D.; and Pantelis, C. Paracingulate morphologic differences in males with established schizophrenia: A magnetic resonance imaging morphometric study. *Biological Psychiatry*, 52:15–23, 2002.
- Yücel, M.; Wood, S.J.; Phillips, L.J.; Stuart, G.W.; Smith, D.; Yung, A.R.; Velakoulis, D.; McGorry, P.D.; and Pantelis, C. Morphological anomalies of the anterior cingulate cortex in young individuals at ultra high-risk of developing a psychotic illness. *British Journal of Psychiatry*, 182:518–524, 2003.
- Yung, A.R.; McGorry, P.D.; McFarlane, C.A.; Jackson, H.J.; Patton, G.C.; and Rakkar, A. Monitoring and care of young people at incipient risk of psychosis. *Schizophrenia Bulletin*, 22:283–303, 1996.
- Yung, A.R.; Phillips, L.J.; Yuen, H.P.; Francey, S.; McFarlane, C.A.; Hallgren, M.; and McGorry, P.D. Psychosis prediction: 12 month follow-up of a high risk ('prodromal') group. *Schizophrenia Research*, 60(1):21–32, 2003.
- Yung, A.R.; Yuen, H.P.; McGorry, P.D.; Hallgren, M.; McFarlane, C.A.; Jackson, H.J.; Francey, S.; and Patton, G.C. Can we predict onset of first episode psychosis in a high risk group? *International Clinical Psychopharmacology*, 13:S23–S30, 1998.
- Zilles, K.; Armstrong, E.; Schleicher, A.; and Kretschmann, H. The human pattern of gyrification in the cerebral cortex. *Anatomy and Embryology*, 179:173–179, 1988.

### Acknowledgments

This research (ID: 981112) and the clinical research structure of the PACE Clinic (ID: 970598 and 970391) were supported by grants from the National Health and Medical Research Council (Australia). This research was presented in part at the 9th International Congress on Schizophrenia Research, Colorado Springs, Colorado, in April 2003.

### About the Authors

Stephen J. Wood, Ph.D., is Research Fellow, Melbourne Neuropsychiatry Centre, University of Melbourne and Sunshine Hospital, Melbourne, Australia, and Brain Research Institute, Melbourne, Australia. Gregor Berger, M.D., is Senior Research Fellow, ORYGEN Youth Health (including PACE & EPPIC program), Melbourne, Australia. Dennis Velakoulis, FRANZCP, is Co-Director, Melbourne Neuropsychiatry Centre, University of Melbourne and Sunshine Hospital, Melbourne, Australia. Lisa J. Phillips, Grad. Dip., is Pace Coordinator, ORYGEN Youth Health (including PACE & EPPIC program), Melbourne, Australia. Patrick D. McGorry, PhD, is Director, ORYGEN Youth Health (including PACE & EPPIC program), Melbourne, Australia. Alison R. Yung, Ph.D., is Principal Research Fellow, ORYGEN Youth Health (including PACE & EPPIC program), Melbourne, Australia. Patricia Desmond, FRANZCR, is Radiologist, Department of Radiology, Royal Melbourne Hospital, Melbourne, Australia. Christos Pantelis, FRANZCP, is Co-Director, Melbourne Neuropsychiatry Centre, University of Melbourne and Sunshine Hospital, Melbourne, Australia.

