

Case Report

Pseudomyxoma Peritonei: A Case Report

MA Ahad¹, SM Kamal², MA Bakar³, MYusuf Ali⁴

Abstract

Pseudomyxoma peritonei (PMP) is an uncommon condition characterized by abundant extracellular mucinous material in the peritoneal cavity and tumoural implants on the peritoneal and epiploic surfaces. Aim of this case report is to create awareness among the clinicians regarding this uncommon disease presented with ascites and irregular masses in the abdomen. PMP is a rare disease, may be benign or malignant, presented with ascites and irregular masses in the abdomen which is infrequently encountered in our clinical practice.

Key words: Pseudomyxoma peritonei, mucinous carcinomatosis, hyperthermic chemotherapy, gelatinous material, irregular masses

Introduction

Pseudomyxoma peritonei (PMP) was first described by Rokitansky in 1842¹. It is an uncommon condition characterized by abundant extracellular mucinous material in the peritoneal cavity and tumoural implants on the peritoneal and the epiploic surfaces². Incidence is one per million per year³ and encountered in 2 of 10,000 laparotomies with gelatinous masses called "Jelly belly" (Fig-1)^{4,5}. It is three to four times more in women than in men⁶. The median age of presentation is 54 years⁷. The origin of pseudomyxoma peritonei is very controversial^{8,9}. Tumour often arises from goblet cells of large bowel or appendix¹⁰. Over expression of the gene MUC-2 responsible for mucin secretion is noted in PMP¹¹. This case report highlights the diagnosis of pseudomyxoma peritonei of a patient presented with clinical features of ascites and irregular masses in the abdomen. Pseudomyxoma peritonei is not commonly encountered in our clinical practice. So we decided to publish the case report for creating awareness among the clinicians.

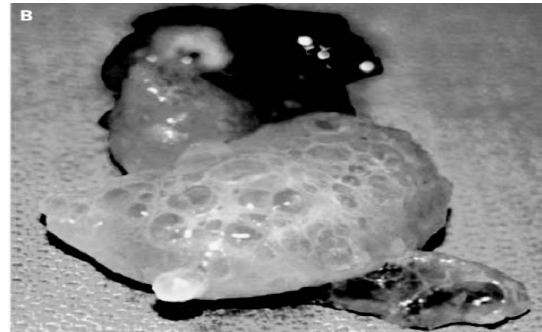


Fig-1: Gelatinous masses

Case Report

A 40 years old male patient was admitted in medicine ward of Khulna Medical College Hospital, Khulna with the complains of gradual swelling of abdomen and weight loss for one year. This was associated with mild abdominal pain and loss of appetite. On examination abdomen was swollen, flanks were full and umbilicus was everted. There was firm, non-tender, mobile, nodular masses involving almost whole abdomen. Huge ascites was present as revealed by the presence of shifting dullness and fluid thrill. There was venous engorgement on the abdominal wall with direction of blood flow from below upwards. Complete blood count, blood sugar, urine analysis, X-ray chest, ECG, Mantoux test, serum bilirubin and serum creatinine were within normal level. Serum albumin was 3.5 gm/dl. Prothrombin time 14 sec (control 12sec), SGPT 210 IU/L. HBsAg and Anti-HCV were negative. Upper GIT endoscopy was normal. Ultrasonogram of abdomen revealed appendicular growth with loculated immobile ascites (Fig-II.) Diagnostic aspiration of ascitic fluid revealed

1. Dr. MA Ahad, FCPS, MD, FACP; Associate Professor, Department of Gastroenterology Khulna Medical College, Khulna.

2. Dr. S M Kamal, FCPS; Associate Professor, Department of Medicine, Khulna Medical College, Khulna.

3. Dr. Md. Abu Bakar, FCPS, FRCP; Professor, Department of Medicine, Khulna Medical College, Khulna.

4. Dr. Md. Yusuf Ali, FCPS; Associate Professor, Department of Medicine, Faridpur Medical College, Faridpur.

Address of correspondence:

Dr. MA Ahad, FCPS, MD, FACP; Associate Professor, Department of Gastroenterology, Khulna Medical College, Khulna.
Ph: 8801711184343.

thick gelatinous material. Study of this material showed sugar 3.5 mmol/L, Protein 5.1 gm/dl and no malignant cell was found. Ultrasonogram guided FNAC of the mass in the abdomen revealed mucin secreting malignant cells and the comment was mucinous adenocarcinoma (Fig-III)

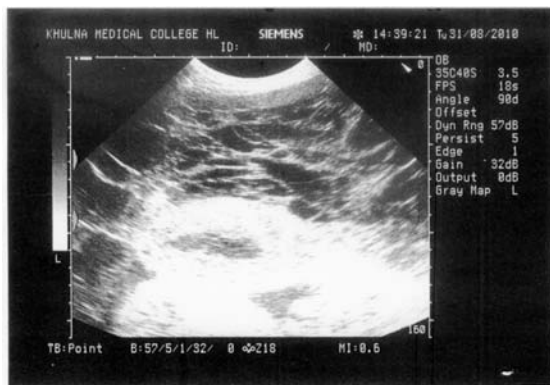

Fig-II: USG of abdomen showing appendicular growth with loculated immobile ascities.

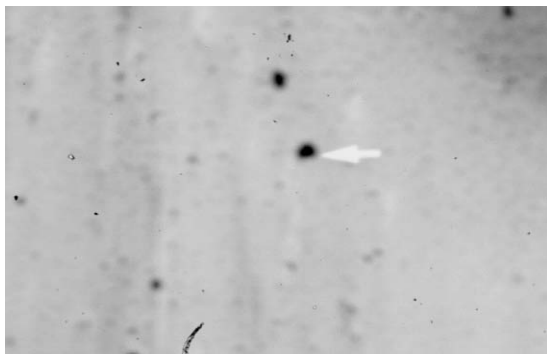


Fig-III: Mucin secreting malignant cell.

So the reported case was diagnosed as peritoneal mucinous carcinomatosis variety of pseudomyxoma peritonei (PMP).

Discussion

The clinical presentation of pseudomyxoma peritonei is caused by overwhelming increase in MUC-2 secreting cells and accumulation of excessive mucin secreted by these cells in the peritoneal cavity with no place of drainage¹². The accumulated mucinous material gives the appearance of gelatinous masses. So the condition is called "Jelly Belly"¹³. The mucin sets on the peritoneal surfaces, gives compression on the vascular structures, hepatic hilum, gastrointestinal tract and other abdominal structures. There is distortion and impaired function of the visceral organs in the abdomen^{14,15}.

The reported case presented with gradual swelling of abdomen and weight loss associated with mild abdominal pain and loss of appetite. Clinical examination revealed findings suggestive of ascites with irregular firm masses involving almost whole abdomen. Ultrasonogram of the abdomen revealed appendicular growth with irregular masses with ascites in the abdomen. Upper GIT endoscopy revealed no varices or no features of malignancy. Then diagnostic aspiration of the swollen abdominal content was done. The aspirated material was not ascitic fluid or pyogenic fluid. It was very thick and gelatinous. So it was not ascites due to abdominal malignancy, tuberculosis, pyogenic peritonitis or cirrhosis of liver. FNAC from the irregular masses in the abdomen gave the comment that it is mucinous adenocarcinoma. No lymphoid tissue was found. So the case is not lymphoma. Irregular masses are formed by deposition of thick gelatinous mucin. Then we diagnosed the reported case as peritoneal mucinous carcinomatosis variety of pseudomyxoma peritonei.

The origin of PMP is very controversial^{8,9}. This is an unusual low grade malignancy often arising from the goblet cells of large bowel or appendix^{10,16}. Commonly it arises from mucinous tumour of the appendix and occasionally from ovary, colon, rectum, stomach, gall bladder, bile duct, small intestine, urinary bladder, lung, breast, pancreas and fallopian tube^{3,16,17}. The benign cases are called disseminated peritoneal adenomucinosis and when malignant features are present the term peritoneal mucinous carcinomatosis is used¹⁸. This low grade malignancy may spread through the peritoneal cavity. Visceral invasion is rare and metastatic spread by haematogenous or lymphatic route is not seen¹⁶. Metastasis to lungs by transdiaphragmatic seeding has been reported¹⁹.

Debulking surgery combined with intraperitoneal hyperthermic chemotherapy is the standard treatment^{17,20}. Systemic chemotherapy is given occasionally¹⁷. Ronnett et al observed 75% and 68% of 5 years and 10 years survival rate respectively for cases of disseminated peritoneal adenomucinosis, 14% and 3% for cases of peritoneal mucinous carcinomatosis respectively²¹.

Conclusion

Pseudomyxoma peritonei is a rare disease, may be benign or malignant. The reported patient presented with features of ascites, which is common in our country. After investigation it was diagnosed as a case of pseudomyxoma peritonei, which is infrequently found in our clinical practice.

References

- Carter J, Moradi MM, Eig S. Pseudomyxoma peritonei - experience from a tertiary referral center. *Aust NZ J obstet Gynaecol Pathol* 1992;31:177-8.
- Weaver CH. Mucocele of appendix with pseudomucinous degeneration. *Am J surg* 1937;36:347-51.
- Saleem SM, Mehboob M, Qayyum A. Pseudomyxoma peritonei: A rare clinical entity. *Journal of Surgery Pakistan* 2008;13:139-40.
- Sanford HB, Kathryn M. Pseudomyxoma peritonei. *N Eng J med* 2004;350:15.
- Mann WJ, Wagner J, Chumas J, Chalas E. The management of pseudomyxoma peritonei. *Cancer* 1990;66:1636-40.
- Hinson FL, Ambrose NS. Pseudomyxoma peritonei. *Br J Surg* 1998;85:1332-39.
- Cough DB, Donohue JH, Schutt AJ. Pseudomyxoma peritonei - long term patient survival with an aggressive regional approach. *Ann Surg* 1994;219:112-9.
- Merino M J, Edmonds P, Livolsi V. Appendiceal carcinoma metastatic to the ovaries and mimicking primary ovarian tumour. *Int J Gynecol Pathol* 1985;4:110-20.
- Lash RH, Hart WR. Intestinal adenocarcinomas metastatic to the ovaries: a clinicopathologic evaluation of 22 cases. *Am J surg pathol* 1987;11:114-21.
- Mann WJ Jr, Wagner J, Chumas J, Charles E. The management of pseudomyxoma peritonei. *Cancer* 1990;66:1636-40.
- O'Connell JT, Hacker CM, Barsky SH. MUC2 is a molecular marker for pseudomyxoma peritonei. *Mod Pathol* 2002;15:958-72.
- O'Connell JT, Tomlinson JS, Robert AA, Mc Gonigle KF, Borsky SH. Pseudomyxoma peritonei is a disease of MUC2 expressing goblet cells. *Am J pathol* 2002;161:551-64.
- Fann JJ, Viersa M, Fisher D. Pseudomyxoma peritonei. *Surg Gynecol Obstet* 1993;177:441-7.
- Lanteri R, Santangelo M, Rapisarda C, Racalbutto A, Cataldo AD, Licata A. Pseudomyxoma peritonei: a case report. *Cancer therapy* 2009;7:31-34.
- Harshen R, Jyothirmayi R, Mithal N. Pseudomyxoma Peritonei. *Clin Oncol* 2003;15:73-77.
- Smith JW, kemeny N, Caldwell C, Banner P, Sigurdson E, Huvos A. Pseudomyxoma peritonei of appendiceal origin. *Cancer* 1992;70:369-401.
- Jacquemin G, Laloux P. Pseudomyxoma peritonei: Review on a cluster of peritoneal mucinous diseases. *Acta chir belg* 2005;105:127-133.
- Ronnet BM, Zahn CM, Kurman RJ, Kass ME, Sugarbaker PH, Shmookler BM. Disseminated peritoneal adenomucinosis and peritoneal mucinous carcinomatosis. A clinicopathologic analysis of 109 cases with emphasis on distinguishing pathologic features, site of origin, prognosis and relationship to pseudomyxoma peritonei. *Am J Surg pathol* 1995;19:1390-1408.
- Berge T. Mucocele appendicitis with pseudomyxoma peritonei and pulmonary metastasis. *Act Pathol Microbiol Scand* 1964;60:483.
- Sugarbaker PH. Cytoreductive surgery and perioperative intraperitoneal chemotherapy as a curative approach to pseudomyxoma peritonei syndrome. *Eur J Surg Oncol* 2001;27:239-43.
- Ronnett BM, Yan H, Kurman RJ, Shmookler BM, Wu L, Sugarbaker PH. Patients with pseudomyxoma peritonei associated with disseminated peritoneal adenomucinosis have a significantly more favorable prognosis than patients with peritoneal mucinous carcinomatosis. *Cancer* 2001;92:85-91.