

Psychiatric manifestations revealing inborn errors of metabolism in adolescents and adults

F. Sedel · N. Baumann · J.-C. Turpin · O. Lyon-Caen ·
J.-M. Saudubray · D. Cohen

Received: 17 April 2007 / Submitted in revised form: 2 July 2007 / Accepted: 3 July 2007 / Published online: 10 August 2007
© SSIEM and Springer 2007

Summary Inborn errors of metabolism (IEMs) may present in adolescence or adulthood as a psychiatric disorder. In some instances, an IEM is suspected because of informative family history or because psychiatric symptoms form part of a more diffuse clinical picture with systemic, cognitive or motor neurological signs. However, in some cases, psychiatric signs may be apparently isolated. We propose a schematic classification of IEMs into three groups according to the type of psychiatric signs at onset. Group 1 represents emergencies, in which disorders can present with acute and recurrent attacks of confusion, sometimes misdiagnosed

as acute psychosis. Diseases in this group include urea cycle defects, homocysteine remethylation defects and porphyrias. Group 2 includes diseases with chronic psychiatric symptoms arising in adolescence or adulthood. Catatonia, visual hallucinations, and aggravation with treatments are often observed. This group includes homocystinurias, Wilson disease, adrenoleukodystrophy and some lysosomal disorders. Group 3 is characterized by mild mental retardation and late-onset behavioural or personality changes. This includes homocystinurias, cerebrotendinous xanthomatosis, nonketotic hyperglycinaemia, monoamine oxidase A deficiency, succinic semialdehyde dehydrogenase deficiency, creatine transporter deficiency, and α and β mannosidosis. Because specific treatments should be more effective at the 'psychiatric stage' before the occurrence of irreversible neurological lesions, clinicians should be aware of atypical psychiatric symptoms or subtle organic signs that are suggestive of an IEM. Here we present an overview of IEMs potentially revealed by psychiatric problems in adolescence or adulthood and provide a diagnostic strategy to guide metabolic investigations.

Communicating editor: John Walter

Competing interests: None declared

F. Sedel (✉) · O. Lyon-Caen
Federation of Nervous System Diseases,
Hôpital de la Salpêtrière, 47 Boulevard de l'Hôpital,
75651 Paris cedex 13, France
e-mail: frederic.sedel@psl.aphp.fr

F. Sedel
National Reference Center for Lysosomal Diseases,
Hôpital de la Salpêtrière, Paris, France

N. Baumann · J.-C. Turpin
Unité mixte de recherche INSERM U-711,
Hôpital de la Salpêtrière, Paris, France

D. Cohen
Service de Psychiatrie de l'Enfant et de l'Adolescent,
Hôpital de la Salpêtrière and Université Pierre et Marie
Curie (Paris VI), Paris, France

J.-M. Saudubray
National Reference Center for Metabolic Diseases,
Necker-enfants malades Hospital and Université René
Descartes (Paris V), Assistance Publique-Hôpitaux de Paris,
Paris, France

Abbreviations

ADHD attention deficit hyperactivity disorder
ALD adrenoleukodystrophy
IEM inborn errors of metabolism
MTHFR methylene tetrahydrofolate reductase

Introduction

Inborn errors of metabolism (IEMs) represent rare but important causes of psychiatric disorders in adolescents or adults. Retrospective analysis of patients with various IEMs shows that psychiatric signs may remain

isolated for years before more specific organic signs become obvious. Since psychiatrists are poorly aware of these rare disorders, IEMs presenting only with a purely psychiatric illness are probably missed. However, it is important to detect IEMs for several reasons: (1) specific treatments may be available; (2) metabolic decompensation may be avoided; and (3) accurate counselling may be given. Furthermore, in most cases, treatments are more effective at the ‘psychiatric stage’ of the disease, before the development of irreversible neurological lesions. It is therefore an important challenge for metabolicians to ensure that psychiatrists and clinicians in general are aware of these particular clinical presentations.

Some aspects of psychiatric presentations of certain groups of IEMs have been reviewed previously (Estrov et al 2000; Turpin and Baumann 2003). Here, from an extensive review of the literature and based on our own experience, we aimed at (1) describing briefly IEMs that may present with psychiatric signs, (2) categorizing IEMs according to specific psychiatric profiles, and (3) providing simple guidelines to help physicians who are not familiar with metabolic medicine not to miss an IEM in a patient with atypical psychiatric signs.

We focused on late-onset presentations that can be seen first in adolescent or adult psychiatric departments. However, we included diseases in which mild clinical signs such as intellectual impairment (mild mental retardation, mild behavioural problems), or organic signs (hypotonia, cataracts, mild dysmorphism, organomegaly, etc.) could be present from infancy. In a preliminary pragmatic approach, diseases were separated into three categories: (1) emergencies, (2) chronic treatable diseases and (3) chronic nontreatable diseases. Clinical, radiological and biological signs of diseases are presented in Table 1. Treatable diseases and principles of treatments are listed in Table 2. Types of psychiatric disturbances observed in each disease are summarized in Table 3. A list of treatments that may aggravate metabolic diseases is provided in Table 4. Finally, a diagnostic strategy to guide metabolic investigations in a patient with atypical psychiatric signs is proposed in Fig. 1.

Overview of IEMs that may associate with psychiatric signs

Emergencies

Emergencies include urea cycle disorders, homocysteine remethylation defects and porphyrias.

Urea cycle disorders may present with confusion, bizarre behaviour or delusion resembling acute psychosis (DiMagno et al 1986; Enns et al 2005), or depressive-like syndrome (Arn et al 1990). Recurrent episodes of hallucinations/bizarre behaviour may be misdiagnosed as schizophrenia. Patients often exhibit protein intolerance and change their alimentation, becoming vegetarian or anorexic (Blans et al 2001). Late-onset metabolic attacks can be apparently spontaneous or triggered by conditions of high protein intake, high protein catabolism or treatments with corticoids or valproate. During metabolic attacks, psychiatric symptoms are almost always accompanied by headache, and gastrointestinal symptoms (nausea, vomiting).

Homocysteine remethylation defects (methylenetetrahydrofolate reductase (MTHFR) deficiency and cobalamin metabolism defects (CblC) can also present with chronic or subacute psychiatric symptoms (Freeman et al 1975; Pasquier et al 1994; Roze et al 2003). In our experience, occurrence of psychiatric illness in adulthood is frequently triggered by a surgical intervention. It can occur as late as the fifth decade in a patient with normal intelligence. Symptoms are most often psychotic in nature, including disorganized behaviour, delusions of persecution, auditory and visual hallucinations. These can be followed by alteration of consciousness, subacute paraplegia, peripheral neuropathy and coma. In all cases, treatments are very efficient if started early. However, paraplegia due to subacute degeneration of the spinal cord or peripheral neuropathy is poorly reversible, making diagnosis and treatment an emergency.

Acute attacks of porphyrias are often triggered by porphyrogenic drugs, infectious disorders or alcohol (reviewed in Crimlisk 1997; Kauppinen 2005). They usually begin with minor behavioural changes such as anxiety, restlessness, and insomnia and proceed rapidly to symptoms of autonomic and sensory motor neuropathy. Acute attacks may also present as aggressive or impulsive behaviour, suicide attempts, psychotic features (delusion, hallucinations), or catatonia (references in Crimlisk 1997). Conversion disorder or chronic fatigue syndrome are sometimes suspected. Monthly luteal attacks in women may lead to the diagnosis of cycloid psychosis. Exacerbations with alcohol can mimic excessive alcohol intake.

Case report

A 56-year-old woman was referred to our department for acute confusion and paraplegia. She suffered from mild depression from the age of 30

Table 1 Inherited metabolic diseases presenting with psychiatric troubles in adolescents or adults

Diseases	Inheritance/ age at onset	Psychiatric signs	Neurological signs	Systemic signs	Brain MRI	Major biological disturbances	Screening tests (first line tests in bold type)
Intoxications							
Urea cycle disorders	X-linked (OTC deficiency), AR/any age	Attacks of confusion, bizarre behaviour, delusion triggered by high protein intake or situations of protein catabolism	Stroke-like episodes (diplopia, hemiparesis), pyramidal signs, epilepsy, coma	Nausea, vomiting, headache	Normal or cerebral oedema or high signal of the cortex on T ₂ weighted sequences	Hyperammonaemia, hyperglutaminaemia, other amino acids abnormalities depend on the metabolic block	Ammoniaemia , AAC, urinary orotic acid
MTHFR deficiency	AR/any age	Mild mental retardation, confusion, depression, psychosis	Coma, pyramidal syndrome (subacute degeneration of the cord), peripheral neuropathy, strokes	Thromboembolic events	Normal or leukoencephalopathy	Hyperhomocysteinaemia >100 µmol/L, hypomethioninaemia, low folates	Homocysteinaemia , AAC, blood folates
Cbls	AR/any age	Mild mental retardation, confusion, depression, psychosis	Pyramidal signs (subacute degeneration of the cord), peripheral neuropathy, optic atrophy	Retinitis pigmentosa, glomerular nephritis, thromboembolic events	Normal or leukoencephalopathy, high signal of spinal pyramidal tracts and posterior columns	Hyperhomocysteinaemia >100 µmol/L, hypomethioninaemia, methylmalonic aciduria	Homocysteinaemia , AAC, OAC
Acute porphyrias	AD/adult	Episodes of confusion, psychosis, depression	Acute peripheral neuropathy, epilepsy	Intestinal problems (pain, constipation), dysautonomia, dark urines, cutaneous signs (coproporphyrin and porphyrin variegata)	Normal or posterior leukoencephalopathy or cortical and subcortical areas of high signal	High urinary excretion of δ-aminolevulinic acid and porphobilinogen	Urinary porphobilinogen
Wilson disease	AR/any age	Disorders of behaviour and personality, depression. Rare cases of psychosis	Movement disorders, dysarthria	Corneal Kayser–Fleischer ring, chronic liver disease	High signal of basal ganglia on T ₂ -weighted sequences	High urinary copper excretion, low plasma copper, low ceruloplasminaemia	Ceruloplasmin , cupraemia, cupruria
Cystathionine β-synthase deficiency)	AR/any age	Mental retardation, disorders of personality or behaviour. Rare cases of psychosis	Epilepsy, strokes, dystonia	Thromboembolic events, Marfan-like appearance, lens dislocation	Normal	Hyperhomocysteinaemia >100 µmol/L, hypermethioninaemia	Homocysteinaemia , AAC
Nonketotic hyperglycinaemia	AR/any age	Mental retardation, behavioural problems, episodes of confusion	Paroxysmal movement disorders triggered by febrile illness	None	Normal	Hyperglycinaemia, hyperglycinuria, CSF/blood glycine ratio above 0.04	AAC (blood and CSF)
Succinic semialdehyde dehydrogenase deficiency	AR/child	Mental retardation, behavioural problems	Seizures	none	Normal or high T ₂ weighted signals of globi pallida	High urinary excretion of γ-hydroxybutyric acid	OAC
Complex molecules metabolism							
Cerebrotendinous xanthomatosis	AR/any age	Rare cases of psychosis	Cerebellar ataxia, spastic paraparesis, dementia, peripheral neuropathy, parkinsonism	Juvenile cataract, xanthomas, chronic diarrhoea	Leukoencephalopathy, signal abnormalities (low or high) of dentate nuclei of the cerebellum	High cholesterol	Sterols HPLC
Metachromatic leukodystrophy	AR/any age	Psychosis-like features (mimics schizophrenia)	Cognitive troubles, spastic paraparesis, cerebellar ataxia, demyelinating polyneuropathy	None	Periventricular leukoencephalopathy	Low arylsulfatase A activity, high urinary excretion of sulfatides	Arylsulfatase A activity (blood)

Table 1 (continued)

Diseases	Inheritance/ age at onset	Psychiatric signs	Neurological signs	Systemic signs	Brain MRI	Major biological disturbances	Screening tests (first line tests in bold type)
GM ₂ gangliosidosis	AR/any age	Episodes of psychosis, depression, mania	Lower motor neuron disease, cerebellar ataxia, pyramidal signs, dystonia, sensitive polyneuropathy	Dysautonomia	Normal or cerebellar atrophy	Low activity of hexosaminidases A or A+B	Hexosaminidases activity (blood)
Niemann-Pick disease type C	AR/any age	Psychosis, depression, mania	Cognitive troubles, cerebellar ataxia, vertical oculomotor apraxia, movement disorders (dystonia, myoclonus)	Splenomegaly, hepatomegaly	Normal or cortical/ cerebellar atrophy	Abnormal accumulation of unesterified cholesterol in lysosomes	Filipin staining (fibroblasts)
α -Mannosidosis	AR/any age	Mental retardation, episodes of psychosis, confusion	Cerebellar ataxia, pyramidal signs	Deafness, upper airways infections, dysmorphia	Normal or thick diploic spaces, posterior leuko- encephalopathy	High urinary excretion of oligosaccharides, low α -mannosidase activity	Oligosaccharides analysis (urines), α -mannosidase activity (blood)
β -Mannosidosis	AR/any age	Mental retardation, hyperactivity, aggressiveness	Demyelinating polyneuropathy (one case)	Angiokeratomas, deafness, upper airways infections	Normal	High urinary excretion of oligosaccharides, low β -mannosidase activity	Oligosaccharides analysis (urines), β -mannosidase activity (blood)
Sanfilippo syndrome (MPS III)	AR/any age	Mental retardation, disintegrative behaviour, autism	Dementia	Mild dysmorphic signs, retinitis pigmentosa	Normal	High urinary excretion of heparan sulfate. Low enzymatic activities (type of enzyme deficiency depends on the type of Sanfilippo syndrome: A, B, C or D)	Mucopolysaccharides analysis (urines), specific enzymatic analysis (blood)
Ceroid lipofuscinosis	AR (sometimes AD)/any age	Depression	Dementia, extrapyramidal signs, epilepsy, cerebellar ataxia, optic atrophy	None	Brain atrophy	Lipofuscin deposits in neurons, rare adult cases of palmitoyl-protein thioesterase (PPT) deficiency	Electronic microscopy of cutaneous, rectal or brain biopsies, PPT activity (blood)
Fabry disease	X linked	Depression, suicide	Acroparaesthesias strokes	Cornea verticillata, proteinuria, cardiomyopathy, angiokeratomas, hearing loss	Strokes, leukoencephalopathy, high signal of pulvinars (T ₁ sequences), vertebrobasilar dolichoectasia	Low α -galactosidase activity	α -Galactosidase activity in blood
Adrenoleukodystrophy (cerebral form)	X-linked/any age	Psychosis, mania, depression	Spastic paraparesis, epilepsy, optic atrophy	Adrenal insufficiency (Addison disease)	Leukodystrophy	High very long-chain fatty acids (VLCFA)	VLCFA (blood)
Others							
Creatine transporter deficiency	X-linked/childhood	Mental retardation, behavioural problems	Hemizygotes: myopathic-like features, epilepsy	Intestinal problems (hemizygotes)		Low creatine on brain MR spectroscopy	Brain MR spectroscopy
Monoamine oxidase A deficiency	X-linked/childhood	Mild mental retardation, paroxysmic behavioural disorders	None	None		Low prolactinaemia, high dopamine, low homovanillic acid and 5-hydroxyindoleacetic acid	Prolactinaemia , dopamine and serotonin metabolites analysis (urines, CSF, blood)

AAC, amino acids chromatography (plasma and urines); AR, autosomal recessive; AD, autosomal dominant; MSUD, maple syrup urine disease; OAC, organic acid chromatography (urines only); OTC, ornithine transcarbamylase deficiency; X, X-linked.

Table 2 Treatable IEMs presenting with psychiatric signs (see also Sedel et al 2007)

Diseases	Treatments
Urea cycle defects	Protein restriction, sodium benzoate, sodium phenylbutyrate, L-arginine, haemodiafiltration if coma
MTHFR deficiency	Folinic acid, betaine, vitamin B ₁₂ , riboflavin
Cbls	Hydroxocobalamin, folic acid; betain
Acute porphyrias	Avoid triggering factors, glucose perfusion, haem perfusion
Wilson disease	D-Penicillamine, zinc, trientine
Cystathionine-β synthase deficiency)	Vitamin B ₆ , protein restriction diet
Cerebrotendinous xanthomatosis	Chenodeoxycholic acid
Nonketotic hyperglycinaemia	Sodium benzoate, dextromethorphan
Succinic semialdehyde dehydrogenase	Benzodiazepines

MTHFR, methylene tetrahydrofolate reductase; Cbls, disorders of cobalamin metabolism.

years. At the age of 50 years, after an operation on her knees, she made a suicide attempt. Three years later she was hospitalized in a psychiatric department for an

acute delusion with visual hallucinations. From that time she became socially retired and was diagnosed as having late-onset schizophrenia. When 56 years old, after a benign head trauma, she became acutely confused and paraplegic. Metabolic investigations showed hyperhomocysteinaemia (192 μmol/L, normal <20), normal methioninaemia and low folates (1.3 mg/L, normal >3). Enzymatic studies showed MTHFR deficiency, which was confirmed by molecular analysis. Treatment with folinic acid, betaine and hydroxocobalamin led to a complete recovery of her psychiatric illness after several months but she remained paraplegic.

Chronic treatable diseases

Chronic treatable diseases include neurological Wilson disease, homocystinuria due to cystathionine β-synthase deficiency and cerebrotendinous xanthomatosis, although in the last psychiatric signs are rarely isolated.

In a retrospective study of 195 patients with Wilson disease, psychiatric symptoms were found in 51% of cases (Denning and Berrios 1989). They preceded motor signs in at least 20% of cases, a percentage also found by Walshe and Yealland (1992). Main psychiatric

Table 3 Psychiatric signs in IEMs in adolescents and adults: review of the literature and personal experience

	Confusion	Mental retardation	Behavioural disturbances	Catatonia	Visual hallucinations	Psychosis (schizophrenia)	Depression
Urea cycle defects	+	+/-	+	+	+	+	+
Cbl (C, G)	+	+	+		+		+
MTHFR deficiency	+	+	+	+	+	+	+
Porphyria	+		+	+		+	+
Wilson disease		+/-	+	+		+/-	+
CBS deficiency		+	+			+/-	+
CTX		+	+	+		+	
MLD			+			+	
GM ₂ gangliosidosis			+	+	+	+	+
NPC			+	+	+	+	+
α-Mannosidosis		+	+		+	+	
β-Mannosidosis		+	+				
ALDc			+			+	+
Nonketotic hyperglycinaemia		+	+				
Monoamine oxidase A deficiency		+	+				
Creatine transporter deficiency		+	+				
Succinic semialdehyde dehydrogenase deficiency		+	+				

ALDc, cerebral adrenoleukodystrophy; CBS, cystathionine β-synthase; CTX, cerebrotendinous xanthomatosis; MLD, metachromatic leukodystrophy; MTHFR, methylene tetrahydrofolate reductase; NPC, Niemann–Pick type C.

+, frequently reported; +/-, unusual; empty cell, not reported.

Table 4 Treatment used in psychiatry and which may aggravate metabolic diseases^a

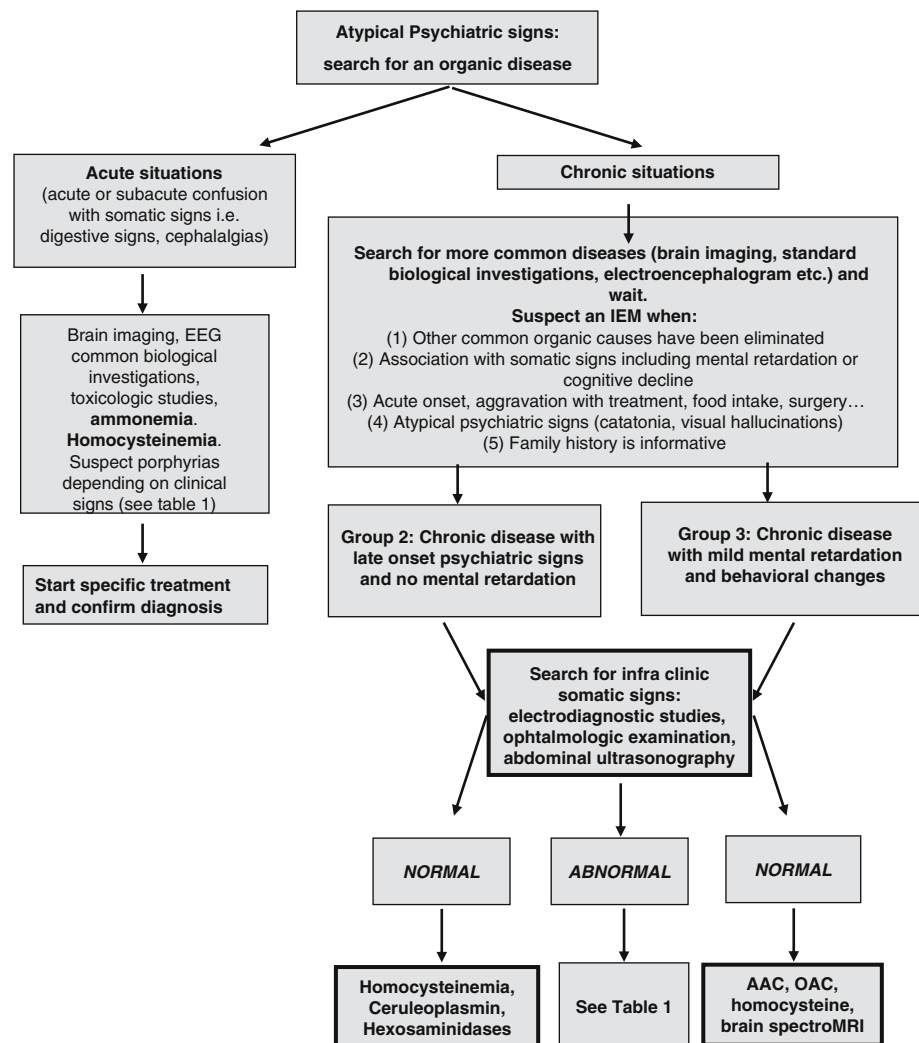
Disease	Drug(s)	Mechanism
Urea cycle disorders	Valproate	Blockage of urea cycle
Porphyrias	Imipramine, meprobamate, methypylon	Porphyrogenic
Wilson disease	Neuroleptics	Blockage of D ₂ dopamine receptors
GM ₂ gangliosidosis	Tricyclic antidepressants, phenothiazines	Increased lipid storage?
Respiratory chain disorders	Valproate	Blocks the respiratory chain

^a Of note, when catatonia occurs, recommended symptomatic treatment is lorazepam but antipsychotic drugs should be avoided as they may provoke malignant catatonia (Cohen et al 2005).

symptoms were behavioural changes (irritability, aggression, personality change, incongruous behaviour, disinhibition) or depression. There was a positive correlation between psychiatric symptoms and neurological abnormalities. Dysarthria was the best predictor of psychiatric illness. Psychosis was found in only 1% of cases. Akil and colleagues (1991) found

psychiatric symptoms at onset in 64.8% of 42 patients with Wilson disease. Again, behavioural changes were found in 70% of cases (irritability, emotionality, aggression, anger), followed by depression, cognitive decline, anxiety, and in less than 10% of cases, psychosis or catatonia. Neuroleptics must be avoided because they may provoke an acute progressive

Fig. 1 Diagnostic strategy to guide metabolic investigations in a patient with atypical psychiatric signs. AAC, amino acids chromatography (plasma); OAC, organic acids chromatography (urine)



Abbreviations: AAC: amino acids chromatography (plasma), OAC: organic acids (urines) chromatography

syndrome with akinesia and rigidity which may progress despite treatment with copper chelators (Chroni et al 2001).

Cystathionine β -synthase deficiency usually manifests with mild mental retardation, lens dislocation, Marfan-like appearance and thromboembolic complications. Psychiatric complications occur in as many as 51% of adult patients (Abbott et al 1987) and include behavioural disorders (physical violence, drug or alcohol abuse), personality disorders (hyperactivity, overdependence, unusual appearance, lack of inhibition), depression and obsessive-compulsive disorder. Schizophrenia or psychotic episodes have been reported in several case reports but remain very uncommon in large studies (Abbott et al 1987; Mudd et al 1985; Ryan et al 2002).

Cerebrotendinous xanthomatosis usually present with juvenile cataracts and tendinous xanthomas, cerebellar ataxia, spastic paraparesis and dementia. In addition, Berginer and colleagues (1988) found 4 patients with a psychiatric presentation among 35 patients. All patients developed tendon xanthomas before occurrence of psychiatric signs. Three patients had psychotic features including catatonia (1 patient), delusion with auditory hallucinations (2 patients) and personality changes. Three patients exhibited cognitive decline consistent with dementia. Treatment with chenodeoxycholic acid produced stabilization or improvement of psychiatric signs.

Late-onset or milder forms of nonketotic hyperglycinaemia may present in adolescents or adults with a previous history of infantile hypotonia, mild mental retardation or attention deficit hyperactivity disorder (ADHD). Subsequently patients may develop behavioural problems including outbursts of aggressiveness and sexual impulsivity (Dinopoulos et al 2005). There may be a partial response to treatment.

Succinic semialdehyde dehydrogenase deficiency has been reported in several adult patients with varying degrees of mental retardation and speech and behavioural problems including autistic-like features, hallucinations, disabling anxiety, aggressive behaviour, sleep disorder and occasional catatonic posturing. Patients may also exhibit seizures and increased T₂-weighted intensity of the globus pallidus on brain MRI (Gibson et al 2003). Benzodiazepines were reported to be very effective for behavioural problems (Gibson et al 2003).

Case report

A 21-year-old man was investigated because of behavioural disturbances. His history was remarkable for a

chronic axonal sensorimotor polyneuropathy diagnosed as 'Charcot–Marie–Tooth disease'. He experienced difficulties in school. He was reported to have relational difficulties from early childhood that increased during adolescence when he was hospitalized in a psychiatric department because of aggressiveness against his mother (he threatened her with a knife) and oppositional behaviour. Association of psychiatric problems with polyneuropathy led to metabolic investigations that disclosed a very high concentration of cholestanol reminiscent of cerebrotendinous xanthomatosis. Interestingly, no xanthoma and no cataract were found. Neuropsychological testing showed a mild frontal syndrome.

Chronic less treatable diseases

Several lysosomal storage diseases may present as isolated psychiatric disorders in adulthood. These purely psychiatric presentations can be observed in metachromatic leukodystrophy, late-onset GM₂ gangliosidosis, and Niemann–Pick type C disease. Metachromatic leukodystrophy is suggested by brain MRI, which shows a periventricular leukodystrophy. Adult forms with psychiatric onset are particularly frequent in heterozygotes for the I179S mutation (Rauschka et al 2006). Initial psychiatric symptoms can mimic schizophrenia including delusion, hallucinations, disorganized behaviour and social dysfunction (Baumann et al 1991). Mental deterioration is often contemporaneous with psychiatric symptoms and is consistent with frontal lobe dysfunction. The clinical picture is completed after several years or decades by neurological dysfunction (dementia, spastic paraparesis, cerebellar ataxia, polyneuropathy). Late-onset GM₂ gangliosidosis usually presents with lower motor neuron disease, cerebellar ataxia or dystonia (Gravel et al 2001). In addition, psychiatric signs are relatively common, affecting around 20–40% of patients (Gravel et al 2001; Navon 1991; Neudorfer et al 2005). They may remain isolated for years before appearance of motor signs or may appear later. Acute episodes of psychosis are characteristic. During attacks, patients often exhibit delusions of persecution, disorganization of thought, agitation, and hallucinations which may persist more or less between attacks. Less commonly, mania or depression can be observed (Argov and Navon 1984; Federico et al 1991). Tricyclic antidepressants and phenothiazines are poorly effective and may worsen psychiatric signs (Hurowitz et al 1993). Adults with Niemann–Pick type C disease may also suffer from isolated psychiatric problems for years. In the study of the adult form of Niemann–Pick disease type C by Sevin

and colleagues (2007), psychiatric troubles constituted the presenting feature in 36.4% of patients. Psychiatric signs were usually consistent with psychosis, but other types of psychiatric disturbances included major depressive episodes, transient isolated visual hallucinations, bipolar disorders and obsessive-compulsive disorders. Onset could be progressive or acute, with spontaneous remissions and relapses. Most patients who presented with psychosis as the initial manifestation of the disease did not have abnormalities at neurological examination, and therefore were diagnosed as having schizophrenia or other forms of psychosis. Splenomegaly was, however, an almost constant feature (in 90% of patients) when searched for using ultrasonography. Vertical oculomotor apraxia is a characteristic feature of the disease but may appear later and may be missing in around 20% of cases. α -Mannosidosis is characterized by mild mental retardation, progressive neurosensory hearing loss, recurrent infections, skeletal dysmorphism and progressive neurological signs including visual loss, cerebellar ataxia and pyramidal signs (Gutschalk et al 2004; Niemann et al 1996). In addition, from puberty or adolescence, patients may exhibit recurrent episodes of confusion and psychosis including delusion and auditory and visual hallucinations. These may last 3–12 weeks and are followed by a period of somnolence and asthenia (Gutschalk et al 2004; Malm et al 2005). Patients with β -mannosidosis usually present with mild retardation, upper airway infections, angiokeratomas, mild dysmorphism and hearing loss (Bedilu et al 2002). Behavioural disturbances including hyperactivity or aggressiveness are found in around two-thirds of patients (Bedilu et al 2002). We have reported the case of a 19-year-old man with β -mannosidosis who exhibited features of Gilles de la Tourette's syndrome (Sedel et al 2006). Sanfilippo syndrome (MPS III) is a cause of major childhood disintegrative disorder, but a few adult-onset cases have been reported who presented mainly with a progressive dementia (Berger-Plantinga et al 2004). Van Diggelen et al (2001) reported the cases of two sisters with palmitoyl-protein thioesterase deficiency (CLN1) who developed depression in adulthood followed by progressive dementia and bilateral optic atrophy. In patients with Fabry disease, an increased frequency of depression and suicide has been reported (Grewal 1993).

Late-onset forms of cerebral adrenoleukodystrophy (ALD), which represent less than 5% of cases of adrenoleukodystrophy, are almost exclusively seen in hemizygous men (Moser 1997). In addition, 20% of cases of adrenomyeloneuropathy (the most common form in adults, which is dominated by a progressive spastic paraparesis), develop a cerebral ALD (Van

Geel et al 2001). The majority adult patients with ALD described so far have exhibited some kind of psychiatric signs which preceded motor signs for years (reviewed in Rosebush et al 1999). Psychiatric symptoms included behavioural changes, mania, depression or acute episodes of psychosis (Angus et al 1994; Sereni et al 1987).

Several disorders of intermediary metabolism may manifest with mild mental retardation and behavioural disturbances. Brunner and colleagues (1993) described a single Dutch family with X-linked monoamine oxidase type A (MAOA) deficiency. Fourteen males in this family exhibited mild mental retardation and abnormal aggressiveness which tended to cluster in periods of 1–3 days, during which they slept very little and experienced night terrors. During these periods of abnormal behaviour, they also undertook arson, attempted rape of female relatives, and showed exhibitionism and voyeurism. Such abnormal behaviours were suggested to be linked to high brain concentrations of serotonin and dopamine, normally catabolized by MAOA. Female carriers of mutations in the creatine transporter gene (*SLC6A8*) may exhibit mild mental retardation and behavioural disturbances (mainly aggressiveness). Affected males show a more diffuse clinical picture including behavioural disturbances but with more severe mental retardation, intestinal problems, movement disorders, seizures and myopathic-like face (Hahn et al 2002). Some studies have reported psychiatric disorders in patients with respiratory chain disorders (Fattal et al 2007). However, these psychiatric manifestations rarely represent a main characteristic of the clinical picture.

Case report

A 40-year-old woman had normal psychomotor development, with normal schooling, and worked as an employee in a supermarket. She had two normal pregnancies. When 30 years old she suffered from an acute persecutive delusion with acoustic hallucinations. Persistent delusion led to the diagnosis of late-onset schizophrenia. Despite chronic therapy with neuroleptics and mood stabilizers, she experienced eight delusion relapses in 6 years, requiring hospitalization each time. She refused medical follow-up for the next 4 years. At the age of 40 years, neurological examination revealed vertical supranuclear ophthalmoplegia, cerebellar ataxia, pyramidal signs, left upper limb rest tremor and rigidity. Abdominal ultrasonography disclosed hepatomegaly and splenomegaly. The diagnosis of Niemann–Pick disease type C was made by demonstrating accumulation of free cholesterol in

cultured fibroblasts with filipin staining and confirmed by the molecular analysis of the *NPCI* gene (Sevin et al 2007).

Diagnostic strategy in a patient with a psychiatric presentation

An IEM is usually suspected in a patient with psychiatric problems in several situations (for a general diagnostic approach to IEMs in children and adults, see Saudubray et al (2006) and Sedel et al (2007)): (1) when the family history is suggestive of recessive or X-linked genetic transmission or when an IEM has already been identified in the family; (2) when clinical signs are triggered by conditions leading to increased protein catabolism, such as fever, food intake, surgery or prolonged fasting; (3) when signs of a more diffuse clinical picture are present including neurological signs of cognitive and motor dysfunction as well as systemic signs (skin problems, ophthalmological signs, visceral signs, etc.).

The problem is more difficult when psychiatric signs are initially isolated without a familial history or clinical somatic involvement. In addition, it is sometimes difficult, in a patient with somatic signs, to determine whether psychiatric problems are due to the same disease. Furthermore, somatic signs may not be evident after a clinical examination (for example, leukodystrophies may be missed if a brain MRI is not performed; cataract or xanthomas may not be symptomatic; organomegaly is often clinically missed in an adult). It is therefore important to determine which psychiatric symptomatology points to an IEM and should lead to further investigations. From a careful reading of the literature and based on our own experience, the type of psychiatric presentations of IEMs are summarized in Table 3. From this compilation, diseases can be schematically classified into three groups.

Group 1 includes diseases with acute and recurrent attacks of confusion and behavioural changes which are usually associated with somatic signs (gastrointestinal signs, cephalalgia, dysautonomia, pyramidal signs, alteration of consciousness). This group includes emergencies: urea cycle defects, homocysteine remethylation defects and porphyrias.

Group 2 includes diseases with isolated psychiatric signs arising in adolescence or adulthood in a previously normal patient. This group includes homocystinurias (homocysteine remethylation defects and cystathionine β -synthase deficiency), Wilson disease, and neurolipidosis (metachromatic leukodystrophy,

GM₂ gangliosidosis, Niemann–Pick type C disease, adrenoleukodystrophy and rare cases of cerebrotendinous xanthomatosis). Patients in this group may initially present with recurrent psychotic attacks, chronic delusion or disorganized behaviour which may mimic schizophrenia. It also includes behavioural and personality changes. Diagnostic problems are especially difficult in this group given the relative nonspecificity of psychiatric signs, especially when they remain isolated for years or decades. However, catatonia, visual hallucinations and deterioration with treatments (see Table 4) are all atypical features that suggest an IEM.

Group 3 includes patients with mild mental retardation since childhood and disorders of behaviour or personality with no definite psychiatric syndrome. This group includes homocystinurias, cerebrotendinous xanthomatosis, nonketotic hyperglycinaemia, monoamine oxidase A deficiency (only one family described so far), succinic semialdehyde dehydrogenase deficiency, creatine transporter deficiency, and α - and β -mannosidosis.

Based on this classification of IEMs into three groups, we propose a simple diagnostic strategy aimed at guiding metabolic investigations (Fig. 1). It should be emphasized that this review is based on current knowledge concerning adult metabolic diseases, but given the rapid evolution of the knowledge in this field this strategy should be adapted and implemented according to the personal experience of each reader.

References

- Abbott MH, Folstein SE, Abbey H, Pyeritz RE (1987) Psychiatric manifestations of homocystinuria due to cystathionine beta-synthase deficiency: prevalence, natural history, and relationship to neurologic impairment and vitamin B₆-responsiveness. *Am J Med Genet* **26**: 959–969.
- Akil M, Schwartz JA, Dutchak D, et al (1991) The psychiatric presentations of Wilson's disease. *J Neuropsychiatry Clin Neurosci* **3**: 377–382.
- Angus B, de Silva R, Davidson R, Bone I (1994) A family with adult-onset cerebral adrenoleukodystrophy. *J Neurol* **241**: 497–499.
- Argov Z, Navon R (1984) Clinical and genetic variations in the syndrome of adult GM₂ gangliosidosis resulting from hexosaminidase A deficiency. *Ann Neurol* **16**: 14–20.
- Arn PH, Hauser ER, Thomas GH et al (1990) Hyperammonemia in women with a mutation at the ornithine carbamoyl-transferase locus. A cause of postpartum coma. *N Engl J Med* **322**: 1652–1655.
- Baumann N, Masson M, Carreau V, Lefevre M, Herschkowitz N, Turpin JC (1991) Adult forms of metachromatic leukodystrophy: clinical and biochemical approach. *Dev Neurosci* **13**: 211–215.

- Bedilu R, Nummy KA, Cooper A, et al (2002) Variable clinical presentation of lysosomal beta-mannosidosis in patients with null mutations. *Mol Genet Metab* **77**: 282–290.
- Berger-Plantinga EG, Vanneste JA, Groener JE, van Schooneveld MJ (2004) Adult-onset dementia and retinitis pigmentosa due to mucopolysaccharidosis III-C in two sisters. *J Neurol* **251**: 479–481.
- Berginer VM, Foster NL, Sadowsky M, et al (1988) Psychiatric disorders in patients with cerebrotendinous xanthomatosis. *Am J Psychiatry* **145**: 354–357.
- Blans MJ, Vos PE, Faber HJ, Boers GH (2001) Coma in a young anorexic woman. *Lancet* **357**: 1944.
- Brunner HG, Nelen MR, van Zandvoort P, et al (1993) X-linked borderline mental retardation with prominent behavioral disturbance: phenotype, genetic localization, and evidence for disturbed monoamine metabolism. *Am J Hum Genet* **52**: 1032–1039.
- Chroni E, Lekka NP, Tsibri E, Economou A, Paschalis C (2001) Acute, progressive akinetic-rigid syndrome induced by neuroleptics in a case of Wilson's disease. *J Neuropsychiatry Clin Neurosci* **13**: 531–532.
- Cohen D, Nicolas JD, Flament MF, et al (2005) Clinical relevance of chronic catatonic schizophrenia in children and adolescents: evidence from a prospective naturalistic study. *Schizophr Res* **76**: 301–308.
- Crimlisk HL (1997) The little imitator—porphyria: a neuropsychiatric disorder. *J Neurol Neurosurg Psychiatry* **62**: 319–328.
- Denning TR, Berrios GE (1989) Wilson's disease. Psychiatric symptoms in 195 cases. *Arch Gen Psychiatry* **46**: 1126–1134.
- DiMagno EP, Lowe JE, Snodgrass PJ, Jones JD (1986) Ornithine transcarbamylase deficiency—a cause of bizarre behavior in a man. *N Engl J Med* **315**: 744–747.
- Dinopoulos A, Kure S, Chuck G, et al (2005) Glycine decarboxylase mutations: a distinctive phenotype of nonketotic hyperglycinemia in adults. *Neurology* **64**: 1255–1257.
- Enns GM, O'Brien WE, Kobayashi K, Shinzawa H, Pellegrino JE (2005) Postpartum “psychosis” in mild argininosuccinate synthetase deficiency. *Obstet Gynecol* **105**: 1244–1246.
- Estrov Y, Scaglia F, Bodamer OA (2000) Psychiatric symptoms of inherited metabolic disease. *J Inherit Metab Dis* **23**: 2–6.
- Fattal O, Link J, Quinn K, Cohen BH, Franco K (2007) Psychiatric comorbidity in 36 adults with mitochondrial cytopathies. *CNS Spectr* **12**: 429–438.
- Federico A, Palmeri S, Malandrini A, Fabrizi G, Mondelli M, Guazzi GC (1991) The clinical aspects of adult hexosaminidase deficiencies. *Dev Neurosci* **13**: 280–287.
- Freeman JM, Finkelstein JD, Mudd SH (1975) Folate-responsive homocystinuria and “schizophrenia”. A defect in methylation due to deficient 5,10-methylenetetrahydrofolate reductase activity. *N Engl J Med* **292**: 491–496.
- Gibson KM, Gupta M, Pearl PL, et al (2003) Significant behavioral disturbances in succinic semialdehyde dehydrogenase (SSADH) deficiency (gamma-hydroxybutyric aciduria). *Biol Psychiatry* **54**: 763–768.
- Gravel RA, Kaback MM, Proia RL, Sandhoff K, Suzuki K, Suzuki K (2001) The GM2 gangliosidosis. In: Scriver CR, Beaudet AL, Sly WS, Valle D, eds; Childs B, Kinzler KW, Vogelstein B, assoc. eds. *The Metabolic and Molecular Bases of Inherited Disease*, 8th edn. New York: McGraw-Hill, 3827–3865.
- Grewal RP (1993) Psychiatric disorders in patients with Fabry's disease. *Int J Psychiatry Med* **23**: 307–312.
- Gutschalk A, Harting I, Cantz M, Springer C, Rohrschneider K, Meinck HM (2004) Adult alpha-mannosidosis: clinical progression in the absence of demyelination. *Neurology* **63**: 1744–1746.
- Hahn KA, Salomons GS, Tackels-Horne D, et al (2002) X-linked mental retardation with seizures and carrier manifestations is caused by a mutation in the creatine-transporter gene (SLC6A8) located in Xq28. *Am J Hum Genet* **70**: 1349–1356.
- Hurowitz GI, Silver JM, Brin MF, Williams DT, Johnson WG (1993) Neuropsychiatric aspects of adult-onset Tay-Sachs disease: two case reports with several new findings. *J Neuropsychiatry Clin Neurosci* **5**: 30–36.
- Kauppinen R (2005) Porphyrrias. *Lancet* **365**: 241–252.
- Malm D, Pantel J, Linaker OM (2005) Psychiatric symptoms in alpha-mannosidosis. *J Intellect Disabil Res* **49**: 865–871.
- Moser HW (1997) Adrenoleukodystrophy: phenotype, genetics, pathogenesis and therapy. *Brain* **120**: 1485–1508.
- Mudd SH, Skovby F, Levy HL, et al (1985) The natural history of homocystinuria due to cystathionine beta-synthase deficiency. *Am J Hum Genet* **37**: 1–31.
- Navon R (1991) Molecular and clinical heterogeneity of adult GM2 gangliosidosis. *Dev Neurosci* **13**: 295–298.
- Neudorfer O, Pastores GM, Zeng BJ, Gianutsos J, Zaroff CM, Kolodny EH (2005) Late-onset Tay-Sachs disease: phenotypic characterization and genotypic correlations in 21 affected patients. *Genet Med* **7**: 119–123.
- Niemann S, Beck M, Seidel G, Spranger J, Vieregge P (1996) Neurology of adult alpha-mannosidosis. *J Neurol Neurosurg Psychiatry* **61**: 116–117.
- Pasquier F, Lebert F, Petit H, et al (1994) Methylenetetrahydrofolate reductase deficiency revealed by a neuropathy in a psychotic adult. *J Neurol Neurosurg Psychiatry* **57**: 765–766.
- Rauschka H, Colsch B, Baumann N, et al (2006) Late-onset metachromatic leukodystrophy: genotype strongly influences phenotype. *Neurology* **67**: 859–863.
- Rosebush PI, Garside S, Levinson AJ, Mazurek MF (1999) The neuropsychiatry of adult-onset adrenoleukodystrophy. *J Neuropsychiatry Clin Neurosci* **11**: 315–327.
- Roze E, Gervais D, Demeret S, et al (2003) Neuropsychiatric disturbances in presumed late-onset cobalamin C disease. *Arch Neurol* **60**: 1457–1462.
- Ryan MM, Sidhu RK, Alexander J, Megerian JT (2002) Homocystinuria presenting as psychosis in an adolescent. *J Child Neurol* **17**: 859–860.
- Saudubray JM, Desguerre I, Sedel F, Charpentier C (2006) A clinical approach to inherited metabolic disorders. In: Saudubray JM, van den Berghe G, Walter J, eds. *Inborn Metabolic Diseases: Diagnosis and Treatment*. Berlin: Springer-Verlag, 3–48.
- Sedel F, Friderici K, Nummy K, et al (2006) Atypical Gilles de la Tourette syndrome with beta-mannosidase deficiency. *Arch Neurol* **63**: 129–131.
- Sedel F, Lyon-Caen O, Saudubray JM (2007) Inborn errors of metabolism in adult neurology—a clinical approach focused on treatable diseases. *Nat Clin Pract Neurol* **3**: 279–290.
- Sereni C, Ruel M, Iba-Zizen T, Baumann N, Marteau R, Paturneau-Jouas M (1987) Adult adrenoleukodystrophy: a sporadic case? *J Neurol Sci* **80**: 121–128.

- Sevin M, Lesca G, Baumann N, et al (2007) The adult form of Niemann–Pick disease type C. *Brain* **130**: 120–133.
- Turpin JC, Baumann N (2003) Presenting psychiatric and cognitive disorders in adult neuropilidoses. *Rev Neurol (Paris)* **159**: 637–647.
- Van Diggelen OP, Thobois S, Tilikete C, et al (2001) Adult neuronal ceroid lipofuscinosis with palmitoyl-protein thioesterase deficiency: first adult-onset patients of a childhood disease. *Ann Neurol* **50**: 269–272.
- Van Geel BM, Bezman L, Loes DJ, Moser HW, Raymond GV (2001) Evolution of phenotypes in adult male patients with X-linked adrenoleukodystrophy. *Ann Neurol* **49**: 186–194.
- Walshe JM, Yealland M (1992) Wilson's disease: the problem of delayed diagnosis. *J Neurol Neurosurg Psychiatry* **55**: 692–696.