

Q-switched Ruby Laser in the Treatment of Nevus of Ota

Hong-Yoon Yang, M.D.* , Chang-Woo Lee, M.D.** , Young-Suck Ro, M.D.** ,
Hee-Joon Yu, M.D.* , Young-Tae Kim, M.D.** , Jae-Hong Kim, M.D.** ,
Joong-Hwan Kim, M.D.***

*Department of Dermatology, Hanyang University, College of Medicine,
Kuri Hospital, Kuri, Kyunggido,

**Department of Dermatology, Hanyang University, College of Medicine, Seoul

***Department of Dermatology, Eulji General Hospital, Seoul, Korea

The purpose of this study is to evaluate the efficacy of Q-switched ruby laser in the treatment of nevus of Ota, a pigmented lesion on the face. The Q-switched ruby laser has been shown to remove tattoos without scarring. With this in mind, the nevus of Ota with pigmented cells in the dermis could be effectively treated with Q-switched ruby laser. Eighty patients (19 men, and 61 women) with nevus of Ota on the face were enlisted to be tested in evaluating the efficiency of Q-switched ruby laser therapy. The age of patients ranged from 1 to 62 years. The energy fluence used varied from 6 to 8.5 J/cm². Treatment intervals ranged from 4 to 16 weeks, and the number of treatment sessions varied between 1 to 9 visits. During a 2-year follow-up period, more than fifty percent removal of nevus-pigment was noted in 64 of the 80 patients. Transient hyperpigmentation was noted in 32 patients lasting for 2 to 6 months after treatment; transient hypopigmentation was seen in 3 cases which recovered within one year. No patients had permanent textural or pigmentary changes or scarring. Q-switched ruby laser therapy appears to be an effective and safe modality for the treatment of nevus of Ota.

Key Words: Q-switched ruby laser, Nevus of Ota

INTRODUCTION

Nevus of Ota was originally described by Ota and Tanino in 1939 (Ota and Tanino, 1939). It is a nevus consisting of dermal melanocytes, usually a unilateral, mottled, blue or brownish black macules occurring in

the sclera and the surrounding skin, innervated by the first and second branches of the trigeminal nerves. The third branch of the trigeminal nerve may be occasionally affected (Hidano et al., 1967).

There are reports on the effect of treatment of nevus of Ota with several different ways of treatment (Ota and Tanino, 1939; Mishima and Mevorah, 1961; Hidano et al., 1967; Apfelberg et al., 1981; Hori et al., 1984; Hidano et al., 1985; Cosman et al., 1989; Kobayashi 1991; Geronemus 1992; Goldberg and Nychay, 1992; Lowe et al., 1993; Taylor et al., 1994). Opaque makeup is often recommended. The application of dry ice may scar and be ineffective, especially

Address for correspondence: Hong-Yoon Yang, M.D., Department of Dermatology, Kuri Hospital, Hanyang University, College of Medicine, 249-1, Kyomoon-dong, Kuri, Kyungki-do, 471-020, Korea.
Tel: (0346) 60-2280, Fax: (0346)557-4872.

in treating deeper pigment. Dermabrasion, electrodesiccation, and skin grafting are also associated with scarring. Removal of pigmented lesions with lasers have been previously reported (Goldman et al., 1965; Apfelberg et al., 1981; Oshiro and Maruyama, 1983; Brauner and Schlifman, 1992). Lasers such as the carbon dioxide, argon, excimer, and pigmented lesion pulse-dye have been used. However, many of these have proven to be unsatisfactory.

Laser-induced clearing of pigmentation is believed to be from selective photothermolysis that refers to the production of specific, thermally mediated injury to pigmented skin structures, with brief and selectively absorbed laser pulses (Anderson and Parrish, 1981; Anderson and Parrish, 1983; Anderson and Parrish, 1987). Q-switched ruby laser pulses interact selectively with the cutaneous pigment system (Parrish et al., 1983; Polla et al., 1987; Dover et al., 1989). The nevus of Ota is one of the deeper melanoses and therefore requires a laser wavelength long enough to penetrate its depths. Shorter wave length radiation, such as the excimer(351 nm) and argon(488 nm), are absorbed by the epidermis and oxyhemoglobin (Margolis et al., 1989). The ruby laser (694 nm) penetrates

about 1-2 mm into the skin and is minimally absorbed by oxyhemoglobin but maximally absorbed by melanin (Anderson and Parrish, 1983; Anderson and Parrish, 1987).

There are reports of success with Q-switched ruby laser in removing a variety of benign lesions involving melanin as well as with tattoos (Goldman et al., 1965; Reid et al., 1983; Levin et al., 1988; Scheibner et al., 1990; Taylor et al., 1990; Taylor et al., 1991; Ashinoff and Geronemus, 1992; Grevelink et al., 1992; Delaney and Walker, 1994). In connection with these effects we tried to examine the Q-switched ruby laser for the treatment of nevus of Ota.

MATERIALS AND METHODS

During a 2-year period, eighty patients with nevus of Ota were treated. Clinical diagnosis of nevus of Ota was made and five patients with atypical clinical features were selected and confirmed the diagnosis by histopathological studies. Sixty-one patients were women and nineteen were men, their ages ranged from 1 to 62 years. Age of onset, and treatment schedules performed are summarized in Table 1.

Table 1. Q-Switched ruby laser treatment of nevus of Ota

| Patient No. | Age (Yrs) | Sex | Age of onset** | Mean fluence (J/cm ²) | Mean treatment interval(Wks) | No. of treatment | Graded response*** after last treatment |
|-------------|-----------|-----|----------------|-----------------------------------|------------------------------|------------------|-----------------------------------------|
| 1 | 33 | F | B | 7 | 8 | 3 | 3 |
| 7 | 20 | F | B | 8 | 6 | 4 | 4 |
| 9 | 23 | F | C | 7.5 | 4 | 9 | 4 |
| 15 | 13/12 | F | B | 6 | 12 | 3 | 4 |
| 21 | 4 | F | B | 7 | 12 | 2 | 3 |
| 26 | 53 | F | P | 7.5 | 8 | 5 | 4 |
| 29 | 33 | F | B | 7 | 0 | 1 | 2 |
| 31 | 62 | F | C | 8 | 8 | 4 | 3 |
| 34 | 19 | M | B | 8 | 4 | 5 | 4 |
| 36 | 54 | M | B | 8 | 0 | 1 | 4 |
| 37 | 30 | M | Ad | 8 | 8 | 2 | 3 |
| 41 | 25 | F | Ad | 6 | 4 | 2 | 2 |
| 46 | 37 | F | Ad | 7 | 4 | 5 | 4 |
| 47 | 44 | F | AD | 8.5 | 6 | 4 | 2 |
| 56 | 3 | M | B | 6 | 12 | 4 | 4 |
| 58 | 22 | F | C | 8 | 6 | 5 | 3 |
| 63 | 2 | F | B | 6 | 12 | 3 | 3 |
| 73 | 3 | M | B | 6 | 12 | 1 | 3 |
| 77 | 6 | M | B | 6 | 16 | 2 | 3 |
| 80 | 49 | F | B | 7 | 4 | 4 | 3 |

**Age of onset: B, birth; C, child; P, puberty; Ad, adolescence; AD, adult

***Graded response: 1, up to 25% clearance; 2, 26%-49% clearance; 3, 50%-75% clearance; 4, > 75% clearance (The numbers indicate given number of each patient, selected randomly among those 80 patients treated)

Before laser therapy no systemic or local anesthesia were used except for those six child patients who could not tolerate the accompanying pain. The latter group were given ketamin (Ketara[®]) intravenously (2 mg/kg). Treatment intervals ranged from 4 to 16 weeks.

The Q-switched ruby laser (Model QRS2 Derma-lase[®], England) delivering at 694nm rays with a pulse width of 40ns was used. The energy fluence used ranged from 6 to 8.5 J/cm² (Table 1).

Photographs were taken of all patients before treatment and during each subsequent visit. An attempt was made to take all photographs using the same camera, at the same distance, angle, with the same magnification, lighting and exposure time. All patients had test sites treated with a 4-6 mm spot size with fluences ranging from 4 to 9 J/cm². All treatments incorporated overlapping pulses of 10 % to 20 %. All tested sites were evaluated at 6-8 weeks and then treated with 6 to 8.5 J/cm². During treatments, all patients and physicians wore protective eyewear. When eyelids were treated eye protection was provided with the use of a stainless steel shield over the ocular glove after application of topical tetracaine hydrochloride 0.5 %. Postoperative dressing included topical tetracycline ointment. When blister formation was found on the treated area the next day, the fluid was drawn and topical antibiotics were used if necessary. Patients were instructed to apply a thin layer of ointment daily for 7 to 14 days postoperatively. Patients were recommended to avoid sun exposure and to use sunscreens until the next session of treatment. Retreatments were performed after 4 weeks or more (range 4 to 16 weeks). All subjects were evaluated after each treatment by three physicians. Responses were graded as 1-4 scale. Grade 1 response (poor) represented up to 25 % improvement (< 25 % removal of pigment from the existing lesion), grade 2 (fair) represented 25 % to 50 % improvement, grade 3 (good) represented 50 % to 75 % improvement, and grade 4 (excellent) represented greater than 75 % improvement. One hundred percent represented complete clearing of the pigment with no recognizable difference from surrounding normal skin.

RESULTS

The clinical histories of the patients and their responses to treatment are summarized in Table 1. Fifty percent or more improvement (good or excellent

response) was noted in 64 patients (80 %) among those 80 patients. The average number of treatment sessions was 3.6 per patient. After two treatment sessions, 55.6 % of patients showed a good or excellent response. After three treatment sessions, 85.7 % of patients showed a good or excellent response. After four treatment sessions, 87.5 % of patients showed a good or excellent response. All patients who were treated more than five times showed a good or excellent response (Fig. 1, 2, 3).

The degree of lightening after each treatment session was variable and was not related much to the treatment protocol in each patient. After the first session the lesions showed only a minor degree of

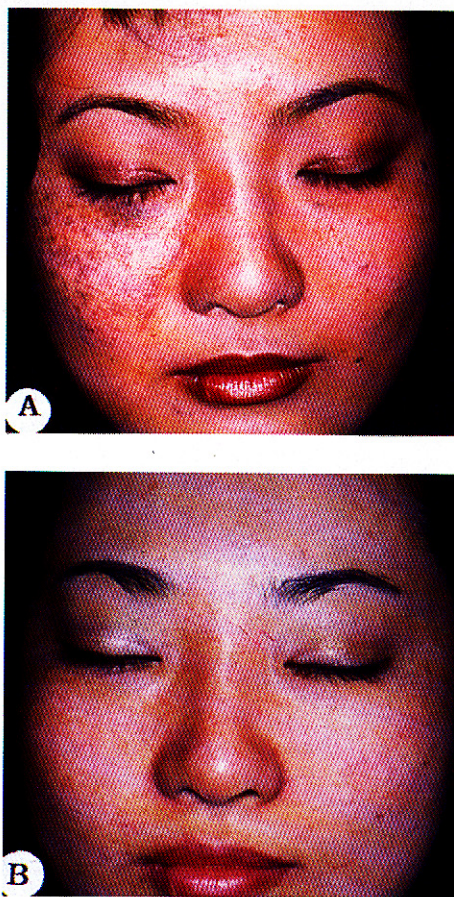

Fig. 1. Nevus of Ota before (A) and after (B) nine treatment sessions with the Q-switched ruby laser using 7 to 8 J/cm² fluence (Patient 9).

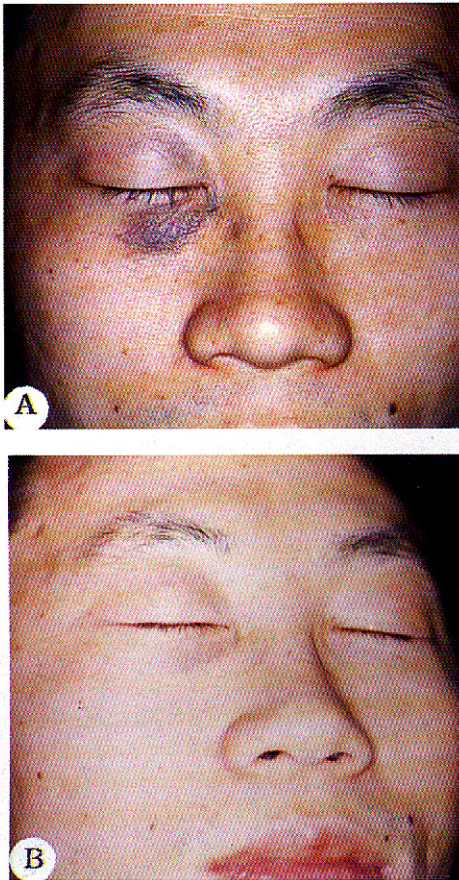


Fig. 2. Nevus of Ota before (A) and after (B) two treatment sessions with the Q-switched ruby laser using 7.5 to 8 J/cm² fluence (Patient 37).

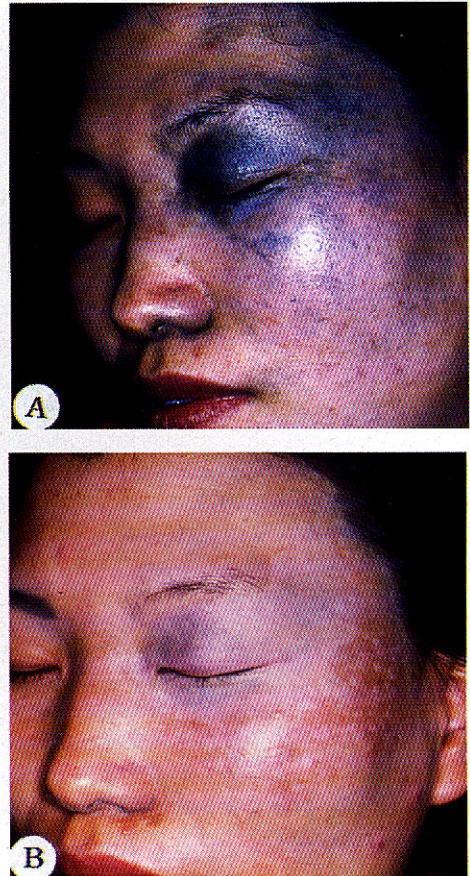

Fig. 3. Nevus of Ota before (A) and after (B) five treatment sessions with the Q-switched ruby laser using 8 J/cm² fluence (Patient 58).

bleaching in color. In many patients the degree of lightening was most marked following the third or fourth treatment. The effect of laser treatment is more striking in child patients than in adult patients.

There was no significant difference in response between those treated with short intervals (≤ 2 months) and those treated with longer intervals.

All patients experienced immediate but transient skin whitening. The whitening was more intense in the nevus than in the surrounding normal skin and usually faded away in 20 minutes. A wheal-and-flare reaction occurred in all patients.

After the first treatment blister formations were seen in 17 patients. After the second treatment, blisters appeared in five of these patients. These blisters were dried up without any sequela. However, on the

eyelids, severe edema were frequently observed.

In thirty-two patients transient hyperpigmentations lasting 2 to 6 months thereafter were noted following treatment. In three patients, scattered patches of hypopigmentation lasting until the 12th month after the last session of treatment were observed. No scarring appeared in any of those patients.

DISCUSSION

Nevus of Ota (Nevus fuscocaeruleus ophthalmomaxillaris) is a nevus consisting of dermal melanocytes, usually involving the first and second branches of the trigeminal nerve. These can be clinically classified into four types: small (type I), moderate-size (type II), extensive (type III), and bilateral (type IV) (Hori and

Takayama, 1988; Mosher et al., 1993). The nevus is most commonly found in females (80 % of all reported cases). An incidence of 1 in 500 has been reported in Japan (Hidano et al., 1967). Over half of the cases (Yoshida, 1952; Hidano et al., 1967) the lesions were first noted at or soon after birth, others during the teens, possibly due to hormonal influence. The lesions persist throughout the person's life.

To date, various modalities have been used in the management of nevus of Ota, however, many of these have proven to be unsatisfactory. Camouflage cosmetics are time consuming, messy and frustrating for patients trying to achieve a perfect match. Also, chemical bleaching agents or cryotherapy may be used, however, these agents sometimes induce permanent damage to epidermal melanocytes leading to irreversible hypopigmentation or depigmentation (Cosman et al., 1989; Goldberg and Nychay, 1992). Surgical excisions are not applicable because of the large size of the lesion. Sequential dry ice application combined with argon laser exposure has been reported as an effective treatment. But the continuous wave radiation of the argon laser commonly causes nonspecific thermal injury resulting in scarring (Cosman et al., 1989; Dover et al., 1990).

The mechanism of action of treatment using Q-switched ruby laser relates to selective photothermolysis that occurs by targeting a subcellular chromophore, and inducing specific thermal injuries to it without damaging surrounding structures thereby avoiding scar formation (Anderson and Parrish, 1981; Anderson and Parrish, 1983; Parrish et al., 1983). Neighboring tissue remains undamaged because the chosen pulse width is less than or equal to the target's thermal relaxation time of 50 to 100 nsec, and therefore require lasers with very short pulse widths. Q-switching produces rapid pulse width of 20 to 50 nsec, permitting the laser to remain below the thermal relaxation time for melanosomes (Murphy et al., 1983; Margolis et al., 1989).

Following treatment with the Q-switched ruby laser, one sees a nuclear injury that is postulated to be caused by thermomechanical destruction as a result of damage to nearby melanosomes. On treating with the Q-switched ruby laser, there is clinical whitening of the area for approximately 20 minutes. With the laser application, there are extremely high thermal temperatures generated that create water vapor within the tissue, thus creating the clinical whitening (Murphy et al., 1983; Margolis et al., 1989; Hruza et al., 1991;

Geronemus, 1992). Hruza et al (1991) has demonstrated that Q-switched ruby laser treatment of pigmented cells results in melanosome rupture and the sparing of poorly melanized stage I and II melanosomes. They postulated that absorption by melanin is necessary to cause damage to the melanosome.

Geronemus (1992) reported that a minimum 50 % lightening was seen in all patients with nevus of Ota treated with Q-switched ruby laser. Lowe et al. (1993) showed that after four treatments all 16 patients with nevus of Ota treated with Q-switched ruby laser showed a 50 % or more (good or excellent) improvement. In our study, similar to previous findings, after five sessions of treatments, all 80 patients with nevus of Ota treated with Q-switched ruby laser showed a more than 50 % improvement (good or excellent). A recent study of therapeutic effect with Korean patients of nevus of Ota using Q-switched Nd:YAG laser was reported (Kim et al., 1995); The results appeared similar to our study.

This Q-switched ruby laser treatment appears to be advantageous compared to other modalities; strong points are lack of scarring and low incidence of depigmentation (Apfelberg et al., 1981; Dover et al., 1990). Despite the need for multiple treatments, Q-switched ruby laser therapy is considered to be a safe and effective method of lightening or removing nevus of Ota.

REFERENCES

- Anderson RR, Parrish JA. *Microvasculature can be selectively damaged using dye lasers: a basic theory and experimental evidence in human skin. Lasers Surg Med* 1981; 1:263-76(cited from Taylor et al., 1994).
- Anderson RR, Parrish JA. *Selective photothermolysis: Precise microsurgery by selective absorption of pulsed radiation. Science* 1983; 220:524-7.
- Anderson RR, Parrish JA. *The optics of human skin. J Invest Dermatol* 1987; 77:13-9.
- Apfelberg DB, Moser M, Lash H, Rieters J. *The argon laser for cutaneous lesions. JAMA* 1981; 245:2073-5.
- Ashinoff R, Geronemus RG. *Q-switched ruby laser treatment of labial lentigos. J Am Acad Dermatol* 1992; 27:809-11.
- Brauner G, Schlittman A. *Treatment of pigmented lesions of the skin with alexandrite laser. Lasers Surg Med Suppl* 1992; 4:73(cited from Lowe et al., 1993).
- Cosman B, Apfelberg DB, Drucker D. *An effective cosmetic treatment for Ota's nevus. Ann Plast Surg* 1989; 22:36-42.
- Delaney TA, Walker NPJ. *Penile melanosis successfully treated with the Q-switched ruby laser. Br J Dermatol*

- 1994; 130: 663-4.
- Dover JS, Arndt KA, Geronemus RG, Olbricht SM, Noe JM, Stern RS. Argon laser. In: *Illustrated Cutaneous Laser Surgery: A Practitioner's Guide*. East Norwalk, Conn: Appleton & Lange, 1990; 73-106.
- Dover JS, Margolis RJ, Polla LL, Watanabe S, Hruza GJ, Parrish JA, Anderson RR. Pigmented guinea pig skin irradiated with Q-switched ruby laser pulses. *Arch Dermatol* 1989; 125: 43-9.
- Geronemus RG. Q-switched ruby laser therapy of nevus of Ota. *Arch Dermatol* 1992; 128: 1618-22.
- Goldberg DJ, Nychay SG. Q-switched laser treatment of nevus of Ota. *J Dermatol Surg Oncol* 1992; 18: 817-21.
- Goldman L, Wilson RG, Homby P, Meyer RG. Radiation from a Q-switched ruby laser: effect of repeated impacts of power output of 10 megawatts on a tattoo of man. *J Invest Dermatol* 1965; 44: 69-71.
- Grevelink JM, Lui H, Taylor CR, Anderson RR. Update on the treatment of benign pigmented lesions with the Q-switched ruby laser. *Lasers Surg Med Suppl* 1992; 4: 73.
- Hidano A. Acquired, bilateral nevus of Ota-like macule. *J Am Acad Dermatol* 1985; 12: 368-9.
- Hidano A, Kajama H, Ikeda S, Mizutani, Miyasato H, Nimura A. Natural history of Ota. *Arch Dermatol* 1967; 95: 187-95.
- Hori Y, Kawashima M, Oohara K, Kukita A. Acquired, bilateral nevus of Ota-like macules. *J Am Acad Dermatol* 1984; 10: 961-4.
- Hori Y, Takayama O. Circumscribed dermal melanosomes: classification and histologic features. *Dermatol Clin* 1988; 6: 315-26.
- Hruza GJ, Dover JS, Flotte TJ, Goetschkes M, Watanabe S, Anderson RR. Q-switched ruby laser irradiation of normal human skin. *Arch Dermatol* 1991; 127: 1799-1805.
- Kim JG, Kim KT, Nam IW, Ahn SK. A study of the therapeutic effect of nevus of Ota by the Q-switched Nd:YAG laser. *Kor J Dermatol* 1995; 33: 686-92.
- Kobayashi T. Microsurgical treatment of nevus of Ota. *J Dermatol Surg Oncol* 1991; 17: 936-41.
- Levin JA, Margolis R, Hruza G, Dover JS, Anderson RR. Q-switched ruby laser irradiation of lentigines. *Lasers Surg Med* 1988; 8: 185.
- Lowe NJ, Wieder JM, Sawcer D, Burrows P, Chalet M. Nevus of Ota: treatment with high energy fluences of the Q-switched ruby laser. *J Am Acad Dermatol* 1993; 29: 997-1001.
- Margolis RJ, Dover JS, Polla LL, Watanabe S, Shea CR, Hruza GJ, Parrish JA, Anderson RR. Visible action spectrum for melanin-specific selective photothermolysis. *Lasers Surg Med* 1989; 9: 389-97.
- Mishima Y, Mevorah B. Nevus Ota and nevus Ito in American negroes. *J Invest Dermatol* 1961; 36: 133-54.
- Mosher DB, Fitzpatrick TB, Hori Y, Ortonne J-P. Disorders of pigmentation. In: *Fitzpatrick TB, Eisen AZ, Wolff K, et al, eds. Dermatology in general medicine, 4th ed. New York: McGraw-Hill Book, 1993; 979.*
- Murphy GF, Shepard RS, Paul BS, Menkes A, Anerson RR, Parrish JA. Organelle-specific injury to melanin-containing cells in human skin by pulsed laser irradiation. *Lab Invest* 1983; 49: 680-5.
- Oshiro T, Maruyama Y. The ruby and argon laser in the treatment of naevi. *Ann Acad Med Singapore* 1983; 12(suppl 2): 388-95(Cited from Lowe et al. 1993).
- Ota M, Tanino H. A variety of nevus frequently encountered in Japan, nevus fusco-caeruleus ophthalmomaxillaris and its relation to pigmentary changes in the eye. *Tokyo Med J* 1939; 63: 1243-4 (Cited from Taylor et al. 1994).
- Parrish JA, Anderson RR, Harrist T. Selective thermal effects with pulsed irradiation from lasers: from organ to organelle. *J Invest Dermatol* 1983; 80(suppl): 75s-80s.
- Polla LL, Margolis RJ, Dover JS, Whitaker D, Murphy GF, Jacques SL, Anderson RR. Melanosomes are a primary target of Q-switched ruby laser irradiation in guinea pig skin. *J Invest Dermatol* 1987; 89: 281-6.
- Reid WH, McLeod PJ, Ritchie A, Ferguson-Pell M. Q-switched ruby laser treatment of black tattoos. *Br J Plast Surg* 1983; 36: 455-9.
- Scheibner A, Kenny G, White W, Wheeland RG. Lasers: a superior method of tattoo removal using the Q-switched ruby laser. *J Dermatol Surg Oncol* 1990; 16: 1091-8.
- Taylor CR, Anderson RR, Gange RW, Michaud NA, Flotte TJ. Light and electron microscopic analysis of tattoos treated by Q-switched ruby laser. *J Invest Dermatol* 1991; 97: 131-6.
- Taylor CR, Flotte TJ, Gange W, Anerson RR. Treatment of nevus of Ota by Q-switched ruby laser. *J Am Acad Dermatol* 1994; 30: 743-51.
- Taylor CR, Gange RW, Dover JS, Flotte TJ, Gonzalez E, Michaud NA, Anderson RR. Treatment of tattoos by Q-switched ruby laser: a dose-response study. *Arch Dermatol* 1990; 126: 893-9.
- Yoshida K. Nevus fusco-caeruleus ophthalmomaxillaris Ota. *Tohoku J Exp Med* 1952; 55(suppl.1): 34-43(Cited from reference Hidano A et al., 1967).