

Quantification of aortic valve calcification in contrast enhanced computer tomography

D. Laohachewin, M. Hein, P. Ruile, N. Jander, F.J. Neumann, J. Minners

University Heart Center Freiburg-Bad Krozingen, Bad Krozingen, Germany

Funding Acknowledgement: Type of funding sources: None.

Introduction: Aortic valve calcification (AVC) is linked to higher gradients and worse prognosis in aortic valve stenosis. Current guidelines recommend calcium scoring of the aortic valve as additional factor for decision making in low-flow, low-gradient aortic stenosis. Calcium Scoring is performed by native computed tomography (CT). For planning of interventional valve replacement (TAVR) a second scan with contrast agent (CECT) is needed at the cost of additional radiation exposure and work up time. The aim of this study is to assess and validate an estimate conversion factor of aortic valve quantification by using CECT without native imaging.

Methods: The Agatston score was measured on native CT in 45 patients and used as a reference. In contrast enhanced CT, mean aortic attenuation values in Hounsfield units (HU) were determined by placement of a region of interest in the ascending aorta with a standard deviation of 4xHU

for calcification threshold. AVC was segmented semi-automatically. A conversion formula was created by plotting of native Agatston score versus aortic valve calcification segmented on contrast enhanced CT and linear regression. Validation of calculated conversion formula was established by Intra-class coefficient (ICC) and Bland Altman analysis.

Results: The linear regression model yielded an Agatston score conversion formula of $691 + 1.83 \times \text{AVCCECT}$. Validation of the formula in a validation cohort (n=20) showed high agreement ($r^2=0.802$, ICC 0.915 (CI 95%: 0.786–0.966) $p<0.001$, $p=0.055$).

Conclusion: Approximation by our calculated conversion factor from contrast enhanced CT has shown excellent reliability to determine aortic valve calcification. Further studies are needed to extend this finding to larger cohorts and diverse clinical environments.

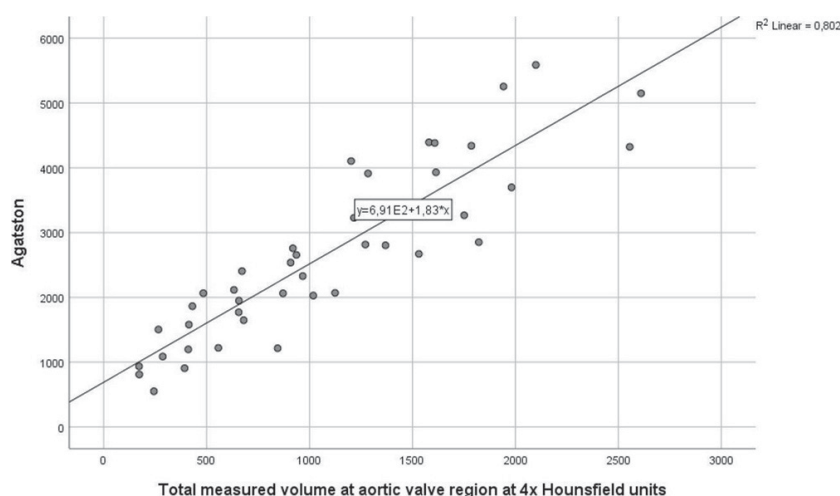


Fig. 1 Correlation of aortic valve volume on contrast enhanced CT and standard Agatston score on non-contrast enhanced CT with line of best fit