

Quantitative Assessment of Emphysema, Air Trapping, and Airway Thickening on Computed Tomography

Young Kyung Lee · Yeon-Mok Oh · Ji-Hyun Lee · Eun Kyung Kim ·
Jin Hwa Lee · Namkug Kim · Joon Beom Seo · Sang Do Lee ·
KOLD Study Group

Published online: 29 May 2008
© Springer Science+Business Media, LLC 2008

Erratum to: Lung
DOI 10.1007/s00408-008-9071-0

Below is the correct Figure 4B for the above-mentioned article, published online on March 20, 2008.

The online version of the original article can be found under doi:[10.1007/s00408-008-9071-0](https://doi.org/10.1007/s00408-008-9071-0).

Y. K. Lee · N. Kim · J. B. Seo (✉)
Department of Radiology, Asan Medical Center, University of Ulsan College of Medicine, Research Institute of Radiology, 388-1, Pungnap-dong, Songpa-ku, Seoul 138-736, Korea
e-mail: seojb@amc.seoul.kr; joonbeom.seo@gmail.com

Y. K. Lee
Department of Radiology, Bundang CHA Hospital, University of Pocheon Jungmoon College of Medicine, 183-8 Yatap-dong, Bundang-Ku, Seongnam-City, Gyeonggi-Do 463-712, Korea

Y.-M. Oh · S. D. Lee (✉)
Division of Pulmonary and Critical Care Medicine, Department of Internal Medicine, Asan Medical Center, University of Ulsan College of Medicine, Research Institute of Radiology, 388-1, Pungnap-dong, Songpa-ku, Seoul 138-736, Korea
e-mail: sdlee@amc.seoul.kr

J.-H. Lee · E. K. Kim
Department of Internal Medicine, Bundang CHA Hospital, University of Pocheon Jungmoon College of Medicine, 183-8 Yatap-dong, Bundang-Ku, Seongnam-City, Gyeonggi-Do 463-712, Korea

J. H. Lee
Department of Internal Medicine, Ewha Womans University Mokdong Hospital, College of Medicine, Ewha Womans University, Seoul, Korea

KOLD Study Group
Seoul, Korea

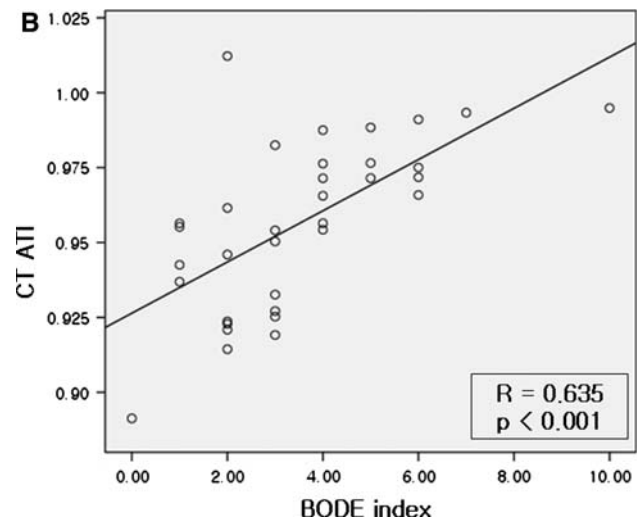


Fig. 4