

Quantitative Retinal Optical Coherence Tomography Angiography in Patients With Diabetes Without Diabetic Retinopathy

Galina Dimitrova,¹ Etsuo Chihara,² Hirokazu Takahashi,² Hiroyuki Amano,² and Kazushiro Okazaki²

¹Department of Ophthalmology, City General Hospital "8th September," Skopje, Macedonia

²Sensho-kai Eye Institute, Iseda, Uji, Kyoto, Japan

Correspondence: Galina Dimitrova, Department of Ophthalmology, City General Hospital, "8th September," Pariska bb, Skopje 1000, Macedonia; galinadimi@gmail.com.

Submitted: August 15, 2016
Accepted: November 18, 2016

Citation: Dimitrova G, Chihara E, Takahashi H, Amano H, Okazaki K. Quantitative retinal optical coherence tomography angiography in patients with diabetes without diabetic retinopathy. *Invest Ophthalmol Vis Sci*. 2017;58:190–196. DOI:10.1167/iovs.16-20531

PURPOSE. To compare optical coherence tomography (OCT) angiographic parameters in retina and choriocapillaris between control subjects and diabetic patients without diabetic retinopathy (NDR). Correlations were studied between OCT angiography parameters, retinal structure parameters, and systemic characteristics in all subjects.

METHODS. Sixty-two patients were included in the study: control subjects ($n = 33$) and patients with NDR ($n = 29$). Optical coherence tomography angiographic parameters were as follows: vessel density (%) (in superficial, deep retinal vessel plexus and in choriocapillary layer) and foveal avascular zone (FAZ) area (mm^2) in superficial and deep retinal vessel plexus of parafovea. Split-spectrum amplitude decorrelation angiography (SSADA) software algorithm was used for evaluation of vessel density and FAZ area (nonflow area tool). Spectral-domain OCT was used to assess full, inner, and outer retinal thickness and volume in parafovea.

RESULTS. In superficial and deep retina, vessel densities in NDR ($44.35\% \pm 13.31\%$ and $31.03\% \pm 16.33\%$) were decreased as compared to control subjects ($51.39\% \pm 13.05\%$, $P = 0.04$; and $41.53\% \pm 14.08\%$, $P < 0.01$). Foveal avascular zone in superficial retina of NDR patients ($0.37 \pm 0.11 \text{ mm}^2$) was greater than in controls ($0.31 \pm 0.10 \text{ mm}^2$, $P = 0.02$). Superficial vessel density significantly correlated with full retinal thickness and volume in parafovea ($r = 0.43$, $P = 0.01$; $r = 0.43$, $P = 0.01$) and with outer retinal volume in parafovea ($r = 0.35$, $P < 0.05$) of healthy subjects. Systolic blood pressure and ocular perfusion pressure significantly correlated with deep vessel density in NDR ($r = -0.45$, $P = 0.02$; $r = -0.46$, $P = 0.01$), but not in controls.

CONCLUSIONS. Superficial and deep retinal vessel density in parafovea of diabetic patients without diabetic retinopathy are both decreased compared to healthy subjects. The associations between vessel density with retinal tissue thickness and with subject's clinical characteristics differ between healthy subjects and patients with NDR.

Keywords: diabetic retinopathy, blood flow, angiography, pathogenesis

The pathogenetic mechanism of diabetic retinopathy (DR), the leading cause of blindness in the working population of developed countries, is still unresolved.¹ Because DR is a microangiopathy, numerous studies have focused on retinal blood vessel morphology and retinal blood flow in diabetes. Circulatory alteration is detected in patients with diabetes by using a number of methods for circulatory evaluation and examining different segments of ocular tissue circulation.^{2–8} However, a consensus has not been established concerning blood flow alteration in different stages of DR.

The blood flow in diabetic retinal vessels is reported both to decrease^{2–4} and to increase.^{5–8} Results depend on the method used as well as on the inclusion/exclusion criteria. The blood vessels of the retina have a strong capacity for autoregulation, and therefore the retinal circulatory response would also be expected to vary depending on the metabolic demands of the retinal tissue. On the other hand, it has been suggested that the autoregulatory response of the retinal blood vessels is affected

in the early stages of the disease, or even before the occurrence of visible signs of DR.⁹

A recent technology using optical coherence tomography angiography (OCTA) enables us to study both qualitatively and quantitatively retinal blood vessel density and flow in human subjects without using any contrast.¹⁰ In addition to the issue of safety, reports indicate a strong reproducibility and reliability of this method.¹¹ Studies of OCTA in diabetic patients suggest enlargement and disintegrity of the vascular arcades of the foveal avascular zone (FAZ) and visible areas of reduced capillary density.^{12,13} Using this method, blood vessel alterations have been observed in diabetic retina without clinically apparent DR.^{14,15} To the best of our knowledge, there have been no reports on quantitative data concerning blood flow and density in the retina and choriocapillaris of patients without DR, using OCTA.

In this report we aimed to compare optical coherence tomography (OCT) angiographic retinal and choriocapillary vascular flow parameters in the parafovea between normal and



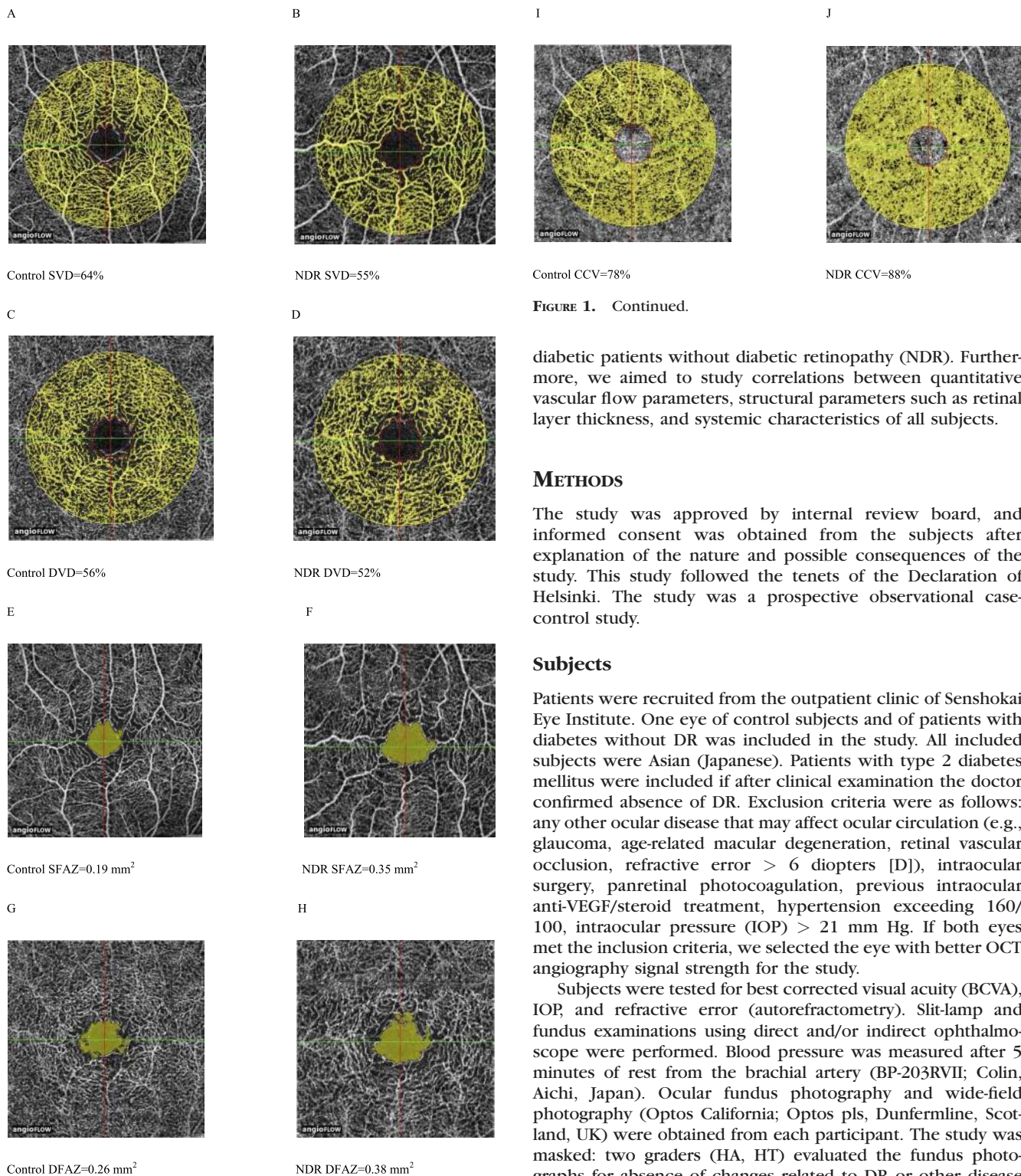


FIGURE 1. Continued.

diabetic patients without diabetic retinopathy (NDR). Furthermore, we aimed to study correlations between quantitative vascular flow parameters, structural parameters such as retinal layer thickness, and systemic characteristics of all subjects.

METHODS

The study was approved by internal review board, and informed consent was obtained from the subjects after explanation of the nature and possible consequences of the study. This study followed the tenets of the Declaration of Helsinki. The study was a prospective observational case-control study.

Subjects

Patients were recruited from the outpatient clinic of Senshokai Eye Institute. One eye of control subjects and of patients with diabetes without DR was included in the study. All included subjects were Asian (Japanese). Patients with type 2 diabetes mellitus were included if after clinical examination the doctor confirmed absence of DR. Exclusion criteria were as follows: any other ocular disease that may affect ocular circulation (e.g., glaucoma, age-related macular degeneration, retinal vascular occlusion, refractive error > 6 diopters [D]), intraocular surgery, panretinal photocoagulation, previous intraocular anti-VEGF/steroid treatment, hypertension exceeding 160/100, intraocular pressure (IOP) > 21 mm Hg. If both eyes met the inclusion criteria, we selected the eye with better OCT angiography signal strength for the study.

Subjects were tested for best corrected visual acuity (BCVA), IOP, and refractive error (autorefractometry). Slit-lamp and fundus examinations using direct and/or indirect ophthalmoscope were performed. Blood pressure was measured after 5 minutes of rest from the brachial artery (BP-203RVII; Colin, Aichi, Japan). Ocular fundus photography and wide-field photography (Optos California; Optos pls, Dunfermline, Scotland, UK) were obtained from each participant. The study was masked: two graders (HA, HT) evaluated the fundus photographs for absence of changes related to DR or other disease that may affect retinal blood flow. In case of inconsistent opinions between graders, a third grader (EC) determined the status of the participant. The analyzer of OCTA (GD) was unaware of subjects' status. Macular blood flow parameters were obtained before pupillary dilation in a dark room by using AngioVue OCTA system (RTVue-XR Avanti; Optovue, Fremont, CA, USA) with an SSADA (split-spectrum amplitude decorrelation angiography) software algorithm (v2014.2.0.90). Retinal morphology data were obtained by using the same equipment. Retinal tissue layers' thickness data were expressed as mean

FIGURE 1. Representative images of a male control subject and a female patient with diabetes without diabetic retinopathy. Control subject (age = 64 years, signal strength = 73), NDR subject (age = 66 years, signal strength = 69). The selected area in yellow is the measured area. (A) Superficial vessel density (SVD) in the control subject. (B) Superficial vessel density in the NDR subject. (C) Deep vessel density (DVD) in the control subject. (D) Deep vessel density in the NDR subject. (E) Superficial foveal avascular zone (SFAZ) in the control subject. (F) Superficial foveal avascular zone in the NDR subject. (G) Deep foveal avascular zone (DFAZ) in the control subject. (H) Deep foveal avascular zone in the NDR subject. (I) Choriocapillary density (CCV) in the control subject. (J) Choriocapillary density in the NDR subject.

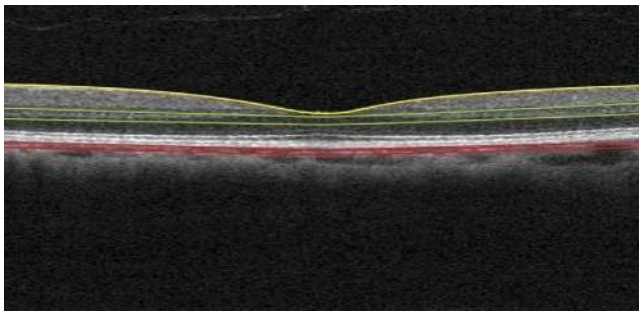


FIGURE 2. B scan representing the boundaries of parafoveal tissue slabs with respective vascular networks from which OCT angiographic parameters were generated. Superficial retinal vessel network (from the yellow line to the upper green line), deep retinal vessel network (between the two green lines), and choriocapillary vessel network (between the two red lines).

values evaluated in a donut-shaped area (1.5-mm radius from the center of fovea for parafovea, excluding central foveal 0.5-mm radius area) (Retina Map; Optovue). The following parameters in parafoveal retina were evaluated: full retinal thickness and volume, inner retinal thickness and volume, outer retinal thickness and volume. Vessel density and flow index were evaluated in the central area with a radius of 1.25 mm from the foveolar center for both retina and choriocapillaris, excluding the central foveal area (0.3 mm radius) (Figs. 1A-D, 2I, 2J). The following parameters in this region were evaluated: superficial vessel density (%) and flow index, superficial FAZ area (mm²), deep vessel density (%) and flow index, deep FAZ area (mm²) and choriocapillary density (%) and flow index. The vessel density is the percentage of signal positive pixels per total pixels in an area of interest. Flow index is the average decorrelation value (correlated with flow velocity) in the selected area. Foveal avascular zone area (mm²) was evaluated in the superficial and deep vessel plexus by using the nonflow area tool of the software that delineated it automatically after selecting a segment of the FAZ (Figs. 1E-H). The superficial retinal, deep retinal, and choriocapillary vascular networks were generated by using automated software algorithm. The boundaries for each layer were as follows: a slab extending from 3 to 15 μm from the internal limiting membrane was generated for detecting the superficial vascular layer, a slab extending from 15 to 70 μm below the internal limiting membrane for the deep retinal vascular layer, and a slab extending from 30 to 60 μm below retinal pigment epithelium reference for choriocapillaris vascular network (Fig. 2).

Image quality was considered by including images having signal strength (SS) of at least 40. We categorized the quality of images considering presence of artifacts such as double vessel pattern and dark areas from blinks or media opacities that obscure vessel signal. Images were categorized in three groups: good (absence of artifacts), fair (cumulative presence of artifacts in less than 1/3 of the image), and poor (cumulative presence of artifacts in more than 1/3 of the image). In patients with initially poor images, we repeated the scans until an image with at least fair quality could be obtained. The image with highest SS and image quality was included in the study. Intraoperator reproducibility was checked in five control participants for whom five consecutive measurements were taken by two technicians who took the OCTA measurements.

Statistical Analysis

Unpaired *t*-test was used to compare retinal layers' structure and OCTA parameters between control subjects and diabetic

TABLE 1. Demographic and Clinical Characteristics of Study Participants

Subjects	Age, y	Sex	SBP, mm Hg	DBP, mm Hg	BCVA, logMAR	SE, D	IOP, mm Hg	OPP, mm Hg	HbA1c, %	DM Duration, y
Control, n = 33	65 (11.38)	14 men	134.28 (17.65)	79.56 (9.09)	-0.10 (0.03)	-0.19 (2.28)	15.55 (2.83)	54.75 (6.57)	NA	NA
NDR, n = 29	69 (9.01)	13 men	140.15 (15.31)	82.19 (6.96)	-0.10 (0.03)	-0.21 (2.12)	15.93 (3.07)	57.05 (5.44)	7.39 (1.96)	7.37 (5.96)
<i>P</i> value	0.13	0.87	0.18	0.22	0.89	0.96	0.59	0.20		

Values are shown as mean (SD), *P* value: Student's *t*-test, Kruskal-Wallis test (for testing sex distribution). Control, control subject group; DBP, diastolic blood pressure; DM, diabetes mellitus; OPP, ocular perfusion pressure; SBP, systolic blood pressure; SE, spherical equivalent refractive error.

TABLE 2. Full, Inner, and Outer Retinal Thickness in the Parafoveal Area of Study Participants

Subjects	Full Retinal Thickness, μm	Full Retinal Volume, mm^3	Inner Retinal Thickness, μm	Inner Retinal Volume, mm^3	Outer Retinal Thickness, μm	Outer Retinal Volume, mm^3
Control, $n = 33$	315.46 (14.45)	1.98 (0.09)	126.55 (10.47)	0.80 (0.06)	188.69 (9.84)	1.19 (0.06)
NDR, $n = 29$	319.48 (14.58)	2.00 (0.08)	123.75 (8.91)	0.78 (0.06)	194.56 (14.33)	1.22 (0.09)
<i>P</i> value	0.30	0.46	0.30	0.45	0.07	0.08

Values are shown as mean (SD).

patients. Kruskal-Wallis test was used for nonparametric data. Pearson's coefficient of correlation was used to check correlation between retinal structure (full, inner, and outer retinal thickness [μm] and volume [mm^3]), clinical characteristics (age, glycated hemoglobin [HbA1c], duration of diabetes, systolic blood pressure, diastolic blood pressure, spherical equivalent, IOP, ocular perfusion pressure), signal strength, and flow parameters (superficial and deep vascular density, superficial and deep FAZ, and choriocapillary vessel density). Microsoft Excel xlsx. and StatView (SAS, Cary, NC, USA) were used for data analysis. A 2-tailed *P* value < 0.05 was considered statistically significant.

RESULTS

Initially, 67 subjects were recruited for this study. Five subjects were excluded owing to values of blood pressure (BP) above the inclusion criteria or low signal strength. There were no significant differences between control subjects and diabetic patients concerning demographic and clinical characteristics (Table 1). The diabetic patients were treated with oral antidiabetic drugs ($n = 22$), insulin ($n = 5$), or only diet ($n = 2$).

The mean coefficients of variation for each of the OCTA parameters were as follows: superficial vessel density: 3.31%, superficial FAZ: 10.70%, deep vessel density: 8.87%, deep FAZ: 17.30%, and choriocapillary density: 1.91%. There was no significant difference between the coefficients of variation between the two technicians who did the measurements. Signal strength for OCTA measurements was not significantly different between the two groups (control group: 65.62 ± 8.68 , NDR: 63.03 ± 6.78 ; $P = 0.18$). In the control group, in 27 subjects the quality of image was good and in 6 patients the quality of image was fair. In the NDR group, in 22 subjects the quality of image was good and in 7 patients the quality of image was fair.

Retinal thickness in the macular and parafoveal region did not differ significantly among the two groups (Table 2).

Duration of diabetes and HbA1c were not associated significantly with any of the OCTA parameters in diabetic patients' parafovea (data not shown). We obtained blood sugar data from 15 subjects in the diabetic subjects' group (143.40 ± 31.20 mg/dL), and the associations with the OCTA parameters were not significant.

Superficial vessel density was significantly decreased ($44.35\% \pm 13.31\%$) and superficial FAZ was significantly increased (0.37 ± 0.11 mm^2) in patients with diabetes in comparison to control subjects ($51.39\% \pm 13.05\%$, $P = 0.04$; 0.31 ± 0.10 mm^2 , $P = 0.02$) (Fig. 3). In control subjects, superficial vessel density was significantly correlated with patients' full retinal thickness ($r = 0.43$, $P = 0.01$) (Fig. 4A) and volume ($r = 0.43$, $P = 0.01$) in parafovea, outer retinal volume in parafovea ($r = 0.35$, $P = 0.05$), age ($r = -0.47$, $P < 0.01$), BCVA ($r = 0.42$, $P = 0.02$), and signal strength ($r = 0.82$, $P < 0.01$). In diabetic subjects, superficial vessel density was significantly correlated with patients' IOP ($r = 0.45$, $P = 0.02$) and signal strength ($r = 0.74$, $P < 0.01$).

Deep vessel density significantly decreased in patients with diabetes ($31.03\% \pm 16.33\%$) in comparison to control subjects ($41.53\% \pm 14.08\%$, $P < 0.01$) (Fig. 3). In control subjects, deep vessel density was significantly associated with full retinal thickness ($r = 0.35$, $P = 0.05$) (Fig. 4B), full retinal volume ($r = 0.36$, $P = 0.04$), inner retinal thickness ($r = 0.59$, $P < 0.01$), inner retinal volume ($r = 0.58$, $P < 0.01$) in parafovea, age ($r = -0.54$, $P < 0.01$) (Fig. 4C), BCVA ($r = 0.42$, $P = 0.02$), and signal strength ($r = 0.85$, $P < 0.01$). In diabetic subjects, deep vessel density was significantly associated with age ($r = -0.41$, $P = 0.03$) (Fig. 4C), systemic blood pressure ($r = -0.45$, $P = 0.02$), ocular perfusion pressure ($r = -0.46$, $P = 0.01$) (Fig. 4D), and signal strength ($r = 0.83$, $P < 0.01$).

In NDR patients, there were no statistically significant associations between OCTA parameters and retinal structure in parafovea (data not shown).

Choriocapillary density was significantly associated with diastolic blood pressure in the NDR group ($r = -0.42$, $P = 0.02$).

The flow index in the v2014.2.0.90 software had a very close association with density index, with a Pearson's correlation coefficient of $r = 0.93$ to 0.99 , and was considered as a related variable of vessel density.

DISCUSSION

Results from this study indicate that in the parafovea of patients with NDR vessel density in the superficial and deep vascular plexus decreased, whereas FAZ in the superficial vascular plexus increased when compared to control subjects. There were no significant differences in the retinal thickness between control subjects and patients with NDR, suggesting that retinal vascular alterations precede retinal structural

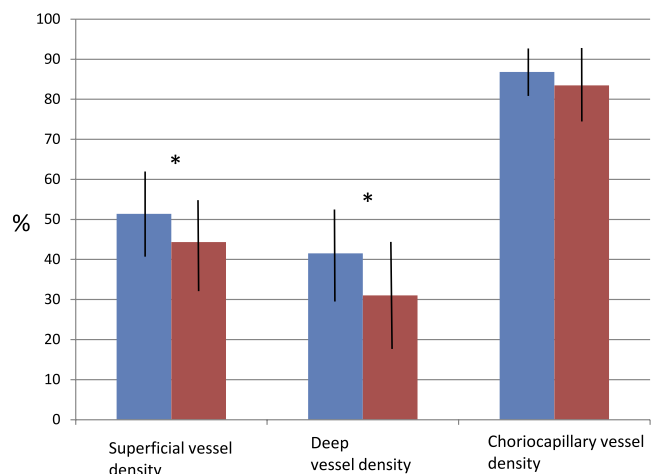


FIGURE 3. Superficial, deep, and choriocapillary vessel density in control subjects (CTRL) and diabetic patients without diabetic retinopathy. *Statistically significant difference.

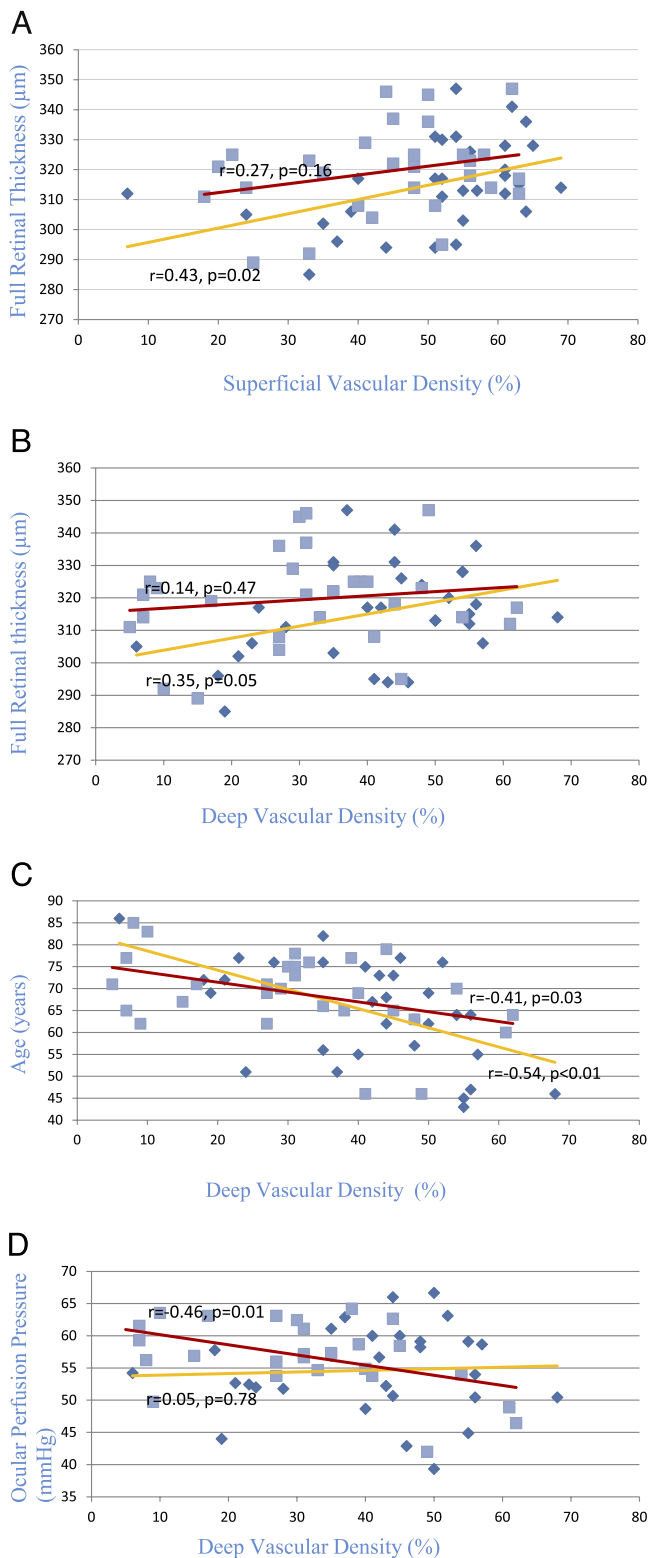


FIGURE 4. Scatterplots of associations between superficial vascular density with full retinal thickness (A), and deep vascular density with full retinal thickness (B), age (C), and ocular perfusion pressure (D) in parafovea of control subjects and patients with diabetes without diabetic retinopathy. *Yellow line* shows control subjects' regression line, *red line* shows diabetic patients' regression line, *light blue square* shows diabetic patients' data, and *dark blue diamond* shows control subjects' data.

alterations. This may indicate a causative role of circulatory alterations to the development of DR.

In patients with NDR, superficial vessel density was decreased and superficial FAZ was increased in comparison to the control group (Fig. 3). The increase of FAZ in patients without DR has been reported before.^{12,14} These findings suggest compromised circulation in the inner retinal layers before manifested DR.

The deep vessel density was significantly decreased in our diabetic patients without DR (Fig. 3). Previous reports¹⁶⁻¹⁸ have found microaneurysms to be present in a larger extent in the deep vascular plexus than in the superficial plexus. It has also been suggested that ischemia at the deep capillary layer may play an important role in the changes of the outer retina detected with spectral-domain OCT.¹⁹

Previous studies report that choroidal circulation, estimated by color Doppler imaging of posterior ciliary arteries, is significantly decreased in patients with background DR.²⁰ In this study the choriocapillary vessel density tended to decrease in patients with NDR in comparison to control subjects. This may indicate that both retinal and choroidal circulation are affected before clinical manifestation of DR, and the pathophysiologic process in both vascular systems may be interrelated. Furthermore, there was a significant negative association between diastolic blood pressure and choriocapillary density and flow index in patients with NDR, indicating that diastolic blood pressure may affect choriocapillary blood flow in NDR.

Retinal tissue thickness and volume in parafovea had a significantly positive correlation with superficial and deep vessel density in control subjects. This suggests that in health, the thicker the retinal tissue, the higher is its vascular density. Conversely, in diabetic retina, the same pattern was not observed. To the best of our knowledge this is the first report concerning correlation of retinal thickness and vessel density, using OCTA in diabetic patients. Yu et al.²¹ have found a significant relationship between retinal vessel density and inner retinal thickness of healthy subjects when using OCTA. In the control group we also detected a significant positive relationship between inner retinal thickness in the parafovea, the inner retinal volume in parafovea, and deep vessel density. It has been reported that most of the major veins in the inner retina are connected to the deep vessel layer,¹⁷ which may also be explanatory for our findings.²²

In accordance to previous reports, age and signal strength had a significantly negative association with retinal vessel density in both study groups^{10,23} (Fig. 4C). Age was significantly correlated with superficial vessel density in control subjects and with deep vessel density in both study groups. Best corrected visual acuity was significantly correlated with superficial and deep vessel density in control subjects. A significantly negative association was present between deep vessel density and systolic blood pressure and ocular perfusion pressure in diabetic patients (Fig. 4D). Such an association was absent in control subjects. Considering that healthy retinal blood vessels are able to autoregulate for systemic variations of blood pressure in order to maintain regular retinal blood perfusion, the significantly negative association of deep vessel density with systemic blood pressure and with ocular perfusion pressure in diabetic patients suggests altered autoregulation in retinal vessels of patients with NDR. On the other hand, there was a significantly positive correlation between IOP and superficial and deep vessel density in NDR patients. The nature of these associations needs to be explored in further studies.

The correlation analysis of patients' clinical characteristics and the OCTA blood flow parameters indicate that systemic factors such as blood pressure have a significant relation to the retinal tissue blood circulation in patients with NDR. The

association of diabetes and hypertension are considered as significant risk factors for occurrence of DR.²⁴ There is evidence that presence of DR is associated with morbidity and mortality from cardiovascular disease.^{25,26} The central retinal artery at the level of lamina cribrosa has a structure of a medium-sized artery and is susceptible to atherosclerosis.²⁷ The close relationship that the central retinal artery has with the central retinal vein, sharing their common adventitia at the level of lamina cribrosa, may be the point of retinal venous outflow impedance.²⁸

Recently, a number of studies reporting qualitative and quantitative OCTA in diabetic patients have been published.^{14,15,29-31} Kim et al.³⁰ have detected progressively decreasing capillary density, branching complexity, and progressively increasing average vascular caliber in eyes with different stages of DR. They have not been able to detect a significant difference in these variables between healthy subjects and patients with mild nonproliferative DR. This discrepancy from the present study may be caused by difference in equipment and/or smaller control group in their study. Significantly reduced density in the superficial and deep vascular plexus in mild nonproliferative DR in comparison to control subjects has also been observed in the study of Agemy et al.³¹ In diabetic patients without DR, the FAZ is enlarged in the superficial^{14,15} and deep retinal vascular plexi.¹⁵ In the present study we also detected increased FAZ in both superficial and deep retinal vessel layers of patients with NDR in comparison to control subjects, with the difference being significant in the superficial vascular plexus. The enlargement of FAZ is consistent with the reduced vessel density in both superficial and deep vascular plexi that was detected in patients with NDR in this study. To the best of our knowledge the present study is the first to report on quantitative vessel density in patients without DR.

A study that investigated retinal blood circulation, using video fluorescein angiography, has reported decreased mean circulation time in diabetic patients without DR.³² Insulin-resistant patients without DR had decreased retinal blood flow (evaluated by scanning laser Doppler flowmetry) in comparison to control subjects or patients with lower insulin resistance.³³ These reports support the results from the present study. However, increased retinal blood flow has also been reported when using retinal function imager in diabetic patients without DR.⁶ Differences in methodology and technology may be the cause of these discrepancies.

Concerning limitations of this study, the mean superficial vessel density of the parafoveal region in our group of control subjects was very similar to that of previous reports using the same method in a similar age group.²³ However, our results showed that, both in the control and diabetic patient groups, the deep vessel density had lower values than the superficial layer. This finding differs from that of previous reports where increased^{10,23} or similar vessel density is observed in the deep vessel layer of healthy retina.³⁰ The difference in the software algorithm or racial difference in patient groups may be the cause of this discrepancy. However, the same software was used in both healthy subjects and in patients with NDR, which allows for a comparative analysis of OCTA parameters. Furthermore, the data were obtained from the parafovea, which may have specific hemodynamics, and the results may not be representative for the whole retina in general. There was also a small difference in radius of parafoveal region measured by the OCT Retina Map program (radius = 1.5 mm) and the Angio Retina program (radius = 1.25 mm); and the excluded area from the foveal radius was 0.5 mm with the OCT Retina Map and the radius was 0.3 mm with the OCT Angio Retina, meaning that the parafoveal area that was assessed for retinal thickness and volume parameters did not match

perfectly the parafoveal area assessed for OCT angiography parameters.

In conclusion, results from this study suggest that superficial and deep retinal vessel density in the parafovea of diabetic patients without DR is decreased as compared to healthy subjects. The differences between the control and diabetic group's associations of OCT angiography parameters with the subjects' systemic characteristics suggests altered autoregulation of the retinal blood vessels in diabetic patients without DR. The results also suggest that OCT angiography may be a potential biomarker for evaluating the risk of developing DR in patients with diabetes without DR.

Acknowledgments

The authors thank Tomomi Morigaki, Naomi Hashimoto, Miya Nishimura, Yui Nagaoka for technical support; data collection by Shizu Nakagami, Chiaki Mifune, Sanae Tatsumi, Mika Ohtou, Eri Tsurumaki, Kimi Nakatani from Sensho-kai Eye Institute; and Igor Sekovski, MFA, for graphic design support.

Supported by Sensho-kai grant 2016.

Disclosure: **G. Dimitrova**, None; **E. Chihara**, Sensho-kai Institute (F), Chuo-sangio (C), Nidek (C), Pfizer (C), Santen (C); **H. Takahashi**, None; **H. Amano**, None; **K. Okazaki**, None

References

1. Prokofyeva E, Zrenner E. Epidemiology of major eye diseases leading to blindness in Europe: a literature review. *Ophthalmic Res.* 2012;47:171-188.
2. Dimitrova G, Kato S, Yamashita H, et al. Relation between retinobulbar circulation and progression of diabetic retinopathy. *Br J Ophthalmol.* 2003;87:622-625.
3. Arend O, Wolf S, Jung F, et al. Retinal microcirculation in patients with diabetes mellitus: dynamic and morphological analysis of perifoveal capillary network. *Br J Ophthalmol.* 1991;75:514-518.
4. Rimmer T, Fallon TJ, Kohner EM. Long-term follow-up of retinal blood flow in diabetes using the blue light entoptic phenomenon. *Br J Ophthalmol.* 1989;73:1-5.
5. Grunwald JE, Riva CE, Sinclair SH, Baine J, Brucker AJ. Total retinal volumetric blood flow rate in diabetic patients with poor glycaemic control. *Invest Ophthalmol Vis Sci.* 1992;33:356-363.
6. Burgansky-Eliash Z, Barak A, Barash H, et al. Increased retinal blood flow velocity in patients with early diabetes mellitus. *Retina.* 2012;32:112-119.
7. Pemp B, Polska E, Garhofer G, Bayerle-Eder M, Kautzky-Willer A, Schmetterer L. Retinal blood flow in type 1 diabetic patients with no or mild diabetic retinopathy during euglycemic clamp. *Diabetes Care.* 2010;33:2038-2042.
8. Patel V, Rassam S, Newsom R, Wiek J, Kohner E. Retinal blood flow in diabetic retinopathy. *BMJ.* 1992;305:678-683.
9. Lorenzi M, Feke GT, Pitler L, Berisha F, Kolodjaschna J, McMeel JW. Defective myogenic response to posture change in retinal vessels of well-controlled type 1 diabetic patients with no retinopathy. *Invest Ophthalmol Vis Sci.* 2010;51:6770-6775.
10. Shahlaee A, Samara WA, Hsu J, et al. In vivo assessment of macular vascular density in healthy human eyes using optical coherence tomography angiography. *Am J Ophthalmol.* 2016;165:39-46.
11. Li J, Yang YQ, Yang DY, et al. Reproducibility of perfusion parameters of optic disc and macula in rhesus monkeys by optical coherence tomography angiography. *Chin Med J (Engl).* 2016;129:1087-1090.
12. Di G, Weihong Y, Xiao Z, et al. A morphological study of the foveal avascular zone in patients with diabetes mellitus using

- optical coherence tomography angiography. *Graefes Arch Clin Exp Ophthalmol*. 2016;254:873-879.
13. Freiberg FJ, Pfau M, Wons J, Wirth MA, Becker MD, Michels S. Optical coherence tomography angiography of the foveal avascular zone in diabetic retinopathy. *Graefes Arch Clin Exp Ophthalmol*. 2016;254:1051-1058.
 14. de Carlo TE, Chin AT, Bonini Filho MA, et al. Detection of microvascular changes in eyes of patients with diabetes but not clinical diabetic retinopathy using optical coherence tomography angiography. *Retina*. 2015;35:2364-2370.
 15. Takase N, Nozaki M, Kato A, Ozeki H, Yoshida M, Ogura Y. Enlargement of foveal avascular zone in diabetic eyes evaluated by en face optical coherence tomography angiography. *Retina*. 2015;35:2377-2383.
 16. Hasegawa N, Nozaki M, Takase N, Yoshida M, Ogura Y. New insights into microaneurysms in the deep capillary plexus detected by optical coherence tomography angiography in diabetic macular edema. *Invest Ophthalmol Vis Sci*. 2016;57:OCT348-OCT355.
 17. Ishibazawa A, Nagaoka T, Takahashi A, et al. Optical coherence tomography angiography in diabetic retinopathy: a prospective pilot study. *Am J Ophthalmol*. 2015;160:35-44.e1.
 18. Couturier A, Mané V, Bonnin S, et al. Capillary plexus anomalies in diabetic retinopathy on optical coherence tomography angiography. *Retina*. 2015;35:2384-2391.
 19. Scarinci F, Jampol LM, Linsenmeier RA, Fawzi AA. Association of diabetic macular nonperfusion with outer retinal disruption on optical coherence tomography. *JAMA Ophthalmol*. 2015;133:1036-1044.
 20. Dimitrova G, Kato S, Tamaki Y, et al. Choroidal circulation in diabetic patients. *Eye (Lond)*. 2001;15:602-607.
 21. Yu J, Gu R, Zong Y, et al. Relationship between retinal perfusion and retinal thickness in healthy subjects: an optical coherence tomography angiography study. *Invest Ophthalmol Vis Sci*. 2016;57:OCT204-OCT210.
 22. Genevois O, Paques M, Simonutti M, et al. Microvascular remodeling after occlusion-recanalization of a branch retinal vein in rats. *Invest Ophthalmol Vis Sci*. 2004;45:594-600.
 23. Coscas F, Sellam A, Glacet-Bernard A, et al. Normative data for vascular density in superficial and deep capillary plexuses of healthy adults assessed by optical coherence tomography angiography. *Invest Ophthalmol Vis Sci*. 2016;57:211-223.
 24. Liu L, Wu J, Yue S, et al. Incidence density and risk factors of diabetic retinopathy within type 2 diabetes: a five-year cohort study in China. *Int J Environ Res Public Health*. 2015;12:7899-7909.
 25. Klein R, Sharrett AR, Klein BE, et al.; ARIC Group. The association of atherosclerosis, vascular risk factors, and retinopathy in adults with diabetes: the atherosclerosis risk in communities study. *Ophthalmology*. 2002;109:1225-1234.
 26. van Hecke MV, Dekker JM, Stehouwer CD, et al. Diabetic retinopathy is associated with mortality and cardiovascular disease incidence: the EURODIAB prospective complications study. *Diabetes Care*. 2005;28:1383-1389.
 27. McAllister A. A review of the vascular anatomy of the optic nerve head and its clinical implications. *Cureus*. 2013;5:e98.
 28. Dimitrova G. Morphometric characteristics of central retinal artery and vein in the optic nerve head of patients with diabetes. *Invest Ophthalmol Vis Sci*. 2012;53:1637.
 29. Miwa Y, Murakami T, Suzuma K, et al. Relationship between functional and structural changes in diabetic vessels in optical coherence tomography angiography. *Sci Rep*. 2016;28:29064.
 30. Kim AY, Chu Z, Shahidzadeh A, Wang RK, Puliafito CA, Kashani AH. Quantifying microvascular density and morphology in diabetic retinopathy using spectral-domain optical coherence tomography angiography. *Invest Ophthalmol Vis Sci*. 2016;57:OCT362-OCT370.
 31. Agemy SA, Scripsema NK, Shah CM, et al. Retinal vascular perfusion density mapping using optical coherence tomography angiography in normals and diabetic retinopathy patients. *Retina*. 2015;35:2353-2363.
 32. Bursell SE, Clermont AC, Kinsley BT, Simonson DC, Aiello LM, Wolpert HA. Retinal blood flow changes in patients with insulin-dependent diabetes mellitus and no diabetic retinopathy. *Invest Ophthalmol Vis Sci*. 1996;37:886-897.
 33. Forst T, Weber MM, Mitry M, et al. Pilot study for the evaluation of morphological and functional changes in retinal blood flow in patients with insulin resistance and/or type 2 diabetes mellitus. *J Diabetes Sci Technol*. 2012;6:163-168.