

Research Article

Queer localizations of primary hydatid disease: experience from a single institute

Rekha Porwal, Hanuman Prasad Gupta, Amit Singh*, Rajesh Kumar Singh

Department of Surgery, JLN Medical College, Ajmer, Rajasthan, India

Received: 23 May 2016

Accepted: 02 July 2016

***Correspondence:**

Dr. Amit Singh,

E-mail: dr.amit5280@gmail.com

Copyright: © the author(s), publisher and licensee Medip Academy. This is an open-access article distributed under the terms of the Creative Commons Attribution Non-Commercial License, which permits unrestricted non-commercial use, distribution, and reproduction in any medium, provided the original work is properly cited.

ABSTRACT

Background: Cystic hydatid disease is a zoonosis caused by *Echinococcus granulosus*. It may affect any organ and tissue in the body, in particular the liver and Lung. Primary extrahepatic hydatid cysts are rare, can have atypical presentations and can pose a diagnostic challenge.

Methods: This retrospective study was carried out in the Department of Surgery at tertiary care hospital in Ajmer, Rajasthan, India. Twenty patients diagnosed with hydatid cysts without involving liver were included in this study. All patients were managed surgically from January 2009 to December 2015 and evaluated retrospectively collected data.

Results: The cysts were present in lungs (30%), kidney (15%), spleen (10%), subcutaneous (10%), inguinal canal (5%), breast (5%), intramuscular (10%), thyroid (5%), retroperitoneal (5%), parotid (5%).

Conclusions: The occurrence of Hydatid cystic disease in locations sites other than liver and lungs is very rare. Symptoms are related to size, location or possible complication of the cyst. Hydatid disease is a differential diagnosis of cystic lesions, especially for the cystic lesions encountered in patients who live in or have come from endemic region.

Keywords: Queer locations, Hydatid, Echinococcosis, Zoonosis

INTRODUCTION

Echinococcosis (hydatid disease) is a zoonosis caused by the larval stage of *Echinococcus granulosus*. Humans are accidental intermediate hosts, whereas animals can be both intermediate hosts and definitive hosts. Hydatid disease is endemic mainly in the Mediterranean countries, the Middle East, the Baltic areas, South America, India, China; however, owing to increased travel and tourism all over the world, it can be found anywhere, even in developed countries.¹ In India, Hydatid disease is common in most of the states of which Andhra Pradesh, Tamil Nadu and Jammu-Kashmir predominate.

The most frequently involved organ is the liver (65%), other organs involved are the lungs (25%) and, less

frequently, the spleen, kidneys, heart, bone and central nervous system and head and neck region.²

METHODS

Hydatid disease in atypical region without primary involvement of liver is very rare even in endemic areas, and only a few case reports were found in the literature. Herein, we report cases diagnosed with Hydatid cysts in atypical locations without involving liver and discuss diagnosis and management. Twenty patients with primary Hydatid cysts in atypical locations managed surgically from January 2009 to December 2015 at J.L.N Medical College, Ajmer, Rajasthan, India were evaluated retrospectively. Preoperative diagnosis was established by the history; clinical examination, complete blood

counts, liver and kidney function tests, X-ray chest, ultrasound and contrast enhanced computerized tomography (CECT). The treatment for all the patients was surgical. All the patients received postoperative Albendazole chemotherapy.

RESULTS

Table 1: Various queer locations of hydatid cystic disease, their clinical presentation and management in present study.

Cyst location	Number (%)	Symptoms (n)	Surgical treatment
Lungs	6 (30%)	Chest pain-3 Cough with expectoration-2 Hemoptysis-1	Thoracotomy with cystectomy
kidney	3 (15%)	Lump abdomen, upper abdominal pain	Nephrectomy, cystectomy
Spleen	2 (10%)	Splenomegaly, upper abdominal pain,	Splenectomy
subcutaneous	2 (10%)	swelling	cystectomy
Inguinal canal	1 (5%)	Swelling mimicking obstructed inguinal hernia.	cystectomy
breast	1 (5%)	Lump breast mimicking abscess breast	Incision and drainage of cyst with cystectomy
retroperitoneum	1 (5%)	Lump abdomen	cystectomy
Intramuscular	2 (10%)	Swelling Cold abscess	cystectomy
Thyroid	1 (5%)	swelling	cystectomy
Parotid	1 (5%)	swelling	cystectomy

Hydatid disease involving atypical sites without involvement of liver was seen in a total of 20 patients. Of these patients 7 were male and 13 females, the sex incidence revealed female preponderance in the study (M: F: 1: 2). Patient age ranged from 22 to 65 years. The mean age was 38.6 years.

Majority of the patients belongs to, fourth decade of life. Majority of patients were from rural areas (14) and remaining (6) was from urban areas. History of contact with dogs, goat and sheep was available in eight cases. The cysts were present in lungs (30%), kidney (15%), spleen (10%), subcutaneous (10%), inguinal canal (5%), breast (5%), intramuscular (10%), thyroid (5%), retroperitoneal (5%), parotid (5%) (Table 1). Nonspecific abdominal pain and a nontender palpable abdominal lump were the most predominant symptoms; other symptoms varied according to the localization of

the cyst. Palpable lump was also a presenting symptom in patients with subcutaneous and muscle cysts. In one case Hydatid cyst was present in inguinal canal and mimics obstructed inguinal hernia, and in one case cyst was present in breast which mimics breast abscess (Table 1). Surgical treatments include complete cyst excision in most of the patients. Nephrectomy, splenectomy, incision and drainage with cyst excision (breast) were performed whenever cysts invaded these organs. All the patients were given postoperative chemotherapy (Albendazole 10 mg/kg/day) for three cycles of 21 days each with a gap of 1 week between each cycle. Morbidity was minimal, with a wound infection recorded postoperatively in two cases. The diagnosis of Hydatid cyst was confirmed on histopathological examination of the specimen in all cases.

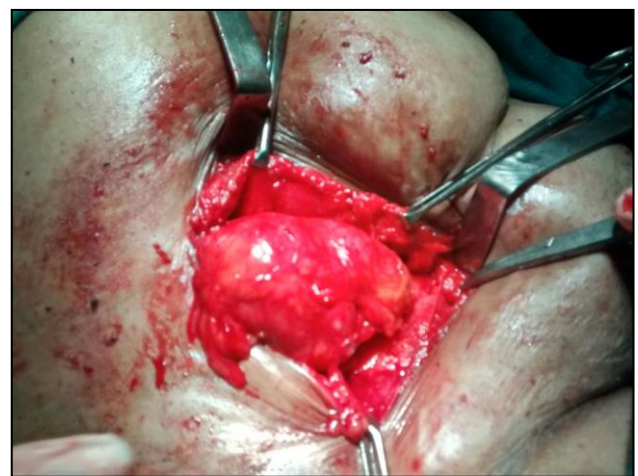


Figure 1: Intramuscular location of hydatid cyst in thigh region.

DISCUSSION

Hydatid disease is seen endemically among sheep-raising communities. As India is not a major sheep-rearing country, it seems that this disease is uncommon here. However the present study is a clinical study of Hydatid disease in central Rajasthan in which practice of sheep and goat grazing is quite common and most of the rural background persons who have goat and sheep moves whole of the year in search of grass in desert area. In the present study, most of the patients were from rural areas associated with farming and field work and kept domestic animals including goat, sheep and dog. Various studies have reported mean age of nearly 40 years which is similar to our study.^{3,4} Imaging modalities such as ultrasonography, CT scan, and MRI have been the methods of choice, especially the latter, which has been the diagnostic method of choice for the preoperative diagnosis of the Hydatid cyst in most unusual locations.⁵ In our study, ultrasonography was done in 16 cases and proved diagnostic in only 11 cases and CECT scan was done in 13 (65%) cases, It was 100%

diagnostic. Three patients of pulmonary Hydatid disease in the present study presented with chest pain, two patients presented with cough with expectoration, and one patient had minimal haemoptysis. Chest x-ray study is of more help in diagnosis of pulmonary hydatids than liver. On chest film, an intact pulmonary Hydatid cyst appears as rounded homogenous shadow with well-defined margins.⁶ The reported prevalence of splenic involvement by Hydatid disease varies from 0.9% to 8%.⁷ Hydatid cyst is the only parasitic cyst of the spleen and it is said to be twice as common as the non-parasitic variety. Any type of Hydatid cyst can be seen in the spleen. Isolated splenic involvement itself is very uncommon. Two cases of Hydatid cyst affecting the spleen were seen in the present study, an incidence of 10% and were managed by splenectomy. Primary Hydatid of the kidney is rare entity and is responsible for only 2 to 3% of all Hydatid disease.⁸ Renal involvement could be primary or secondary, in primary Hydatid disease cyst passes through the portal system into the liver and retroperitoneal lymphatic. The Hydatid cyst of the kidney is considered closed if all three layers of the cyst are intact. When the cyst goes outside the pericyst confined by the lining of collecting system it is considered to be an exposed cyst. If all the three layers of the cyst have ruptured resulting in free communication with the calyces and pelvis, it is called an open or communicating cyst. Three cases of Hydatid disease affecting the kidney were seen in this study, an incidence of 15%. In present study one case of renal Hydatid was associated with massive renal destruction which was treated with nephrectomy, remaining two cases of isolated renal Hydatid treated with cyst excision alone. In present study one case of Hydatid cyst was found in inguinal canal associated with outside the sac of indirect hernia, signs and symptoms were in favour of obstructed inguinal hernia and sonography was inconclusive, inguinal canal exploration presumed diagnosis and cyst excision with standard hernia repair was done, diagnosis confirmed by histopathology. The parotid gland Hydatid cysts are always primary.⁹ In present study A 36-year-old woman presented with slowly progressive swelling in the right periauricular region for 6 month duration. It was non-tender and mobile. On ultrasonography a cystic mass was reported. Fine needle aspiration of a parotid mass revealed inflammatory swelling. Computed tomography (CT) scan of the head and neck revealed a round, well-demarcated water-density cystic mass in the right parotid gland. A provisional clinical diagnosis of a cyst or a neoplasm of the parotid gland was made. At the operation, the cystic mass replacing most of the superficial part of right parotid gland was demonstrated. Superficial parotidectomy was carried out. Histopathological examination confirmed the diagnosis of Hydatid disease. Hydatid cyst of the breast is very rare. The breast can be a primary site or part of a disseminated Hydatidosis. It might mimicked fibroadenoma, phyllodes tumors, chronic abscesses, or even carcinoma.¹⁰ A 28-year-old woman presented with gradually progressive, painful left breast since one month

duration. There was no history of injury, discharge from the nipple and family history of breast cancer. Examination revealed a red inflamed tender area measuring 5 cm × 5 cm in the subareolar region extending to upper outer quadrant of the left breast. The nipple of the left breast was retracted. The right breast and nipple were normal and there was no axillary or cervical lymphadenopathy. USG study of the breasts revealed a thick walled cavitory lesion with internal echoes in the subareolar region of the left breast suggestive of abscess cavity. The patient underwent surgery for the abscess left breast. This case was diagnosed as Hydatid cyst incidentally during surgery, and confirmed by histopathology.

Soft tissue Hydatid disease is rare even in endemic areas, and a primary focus within muscle in the absence of pulmonary or hepatic involvement is most unusual. Muscle Hydatidosis accounts only for 3-5% of all cases.¹¹ In present study A 45-year-old female patient presented to our surgical outpatient department, with a history of painless, slow growing swelling in posterior aspect of her left leg since 10 years. On physical examination, the swelling was non-tender, measuring approximately 10 cm x 6 cm in size in the calf region of left leg. A clinical diagnosis of a lipoma or a large sebaceous cyst was made and FNAC was done which was suggestive of suppurative inflammatory pathology. The diagnosis of Hydatid cyst was set intraoperatively. A postoperative CTscan of the thorax and USG abdomen revealed no signs of other echinococcal cysts. Thus, the case was considered as a primary Hydatid cyst of the calf. Another case with intramuscular Hydatid disease in thigh region clinically resembles cold abscess and diagnosed intraoperatively (Figure 1).

The mechanism of primary subcutaneous localization is unclear. There are two potential mechanisms; (a) direct subcutaneous contamination through an injured skin or (b) subcutaneous colonization of ingested eggs after passing liver and lungs, incidence of subcutaneous Hydatid disease is 1.5%.¹² In the present study two case was diagnosed subcutaneous Hydatid, both were leg swelling and wrongly labelled as soft tissue mass or sebaceous cyst, diagnosed intraoperatively and confirmed by histopathology.

The thyroid gland is an extremely rare site of Hydatid cyst, even in endemic regions.¹³ In the present study a 26 year old male present with solitary thyroid swelling since one year. The local examination showed a right solitary thyroid nodule, measuring 2 × 1 cm, cystic, nontender, and not fixed to the surrounding structures with no cervical lymph node. Thyroid function tests were within normal limits. Thyroid ultrasonography (US) showed a 2 × 1.5 cm diameter cystic nodule in the right thyroid lobe. FNAC revealed thyroid cyst. Cyst was excised and diagnosis was confirmed by histopathology. Postoperative radiologic examination of

the chest and US examination of the abdomen were normal.

Hydatid cyst which develops only in the retroperitoneal space without an accompanied lesion in other organs is defined as primary retroperitoneal Hydatid cyst. It is extremely rare, seen in 0.8% of the cases.¹⁴ In the present study a 28 year women comes with lump lower abdomen since one year. On examination 10 cm 12 cm globular nontender firm mass arising from pelvis and moves with horizontal direction with restricted mobility in vertical direction. Ultrasound (USG) of the whole abdomen revealed a 10.4 cm × 6.4 cm right adenexal multiloculated mass occupying the right pelvis with internal debris. The liver, spleen and kidneys showed a normal echo pattern. On exploration both ovaries and uterus was seen normal and bulging seen from retroperitoneal space, on exploration of retroperitoneal space a cystic mass seen which was enblock removed. Diagnosis of Hydatid was confirmed by histopathology.

Atypical localization of Hydatid disease usually poses a diagnostic dilemma. It is well known that specific local or general symptoms and signs of Hydatid disease do not exist. The uncommon localization frequently causes diagnostic problems and specific diagnostic tests do not have 100% reliability in these cases. Hydatid disease in extra hepatic locations usually follows a silent clinical course unless it grows and produces pressure symptoms or develops complications which may include local pressure, rupture, secondary infection, and an allergic reaction.¹⁵ There are currently three treatment options for Hydatidosis: surgery (total/partial cystectomy), which remains the mainstay of radical treatment; ultrasound-guided aspiration (puncture/aspiration/injection/re-aspiration, PAIR); and chemotherapy with benzimidazole compounds (albendazole and mebendazole). According to the World Health Organization (WHO) guidelines, chemotherapy is the preferred treatment when the disease is inoperable, when surgery or PAIR is not available, or when the cysts are too numerous. Another important indication for chemotherapy is the prevention of secondary echinococcosis.¹⁶ Surgery still remains the mainstay of treatment for Hydatid disease with special attention to avoid any spread of Hydatid with subsequent secondary echinococcosis. There are many surgical procedures for the management of Hydatid cysts. Indications for surgery include large cysts with multiple daughter cysts, superficial location amenable to rupture, cysts exerting pressure on adjacent organs, and cysts in ectopic locations.¹⁷ The type of procedure is selected by taking into consideration the cyst location. In our series of atypical and rare Hydatid cyst locations, we performed total cystectomy (cystopericystectomy) in patients with disease involving the lungs, muscle, subcutaneous tissue, inguinal canal, parotid, thyroid, breast and retroperitoneum. Nephrectomy and splenectomy was performed in patients with renal, and spleen Hydatidosis respectively to eradicate the disease, avoiding secondary Hydatid spread.

CONCLUSION

Echinococcosis can appear at any site of the human body, and so should always be considered in the differential diagnosis of cystic space-occupying lesions or unidentified tumor formations in patients from endemic areas. Hydatid diseases at unusual sites are like iceberg because actual incidences are much higher than reported. Proper surgical and medical management to avoid any recurrences, and a regular follow-up, are of utmost importance to detect any late complications such as local recurrence of the disease and development of Hydatidosis at the primary sites.

Funding: No funding sources

Conflict of interest: None declared

Ethical approval: The study was approved by the institutional ethics committee

REFERENCES

1. Huizinga WKJ, Grant CS, Daar AS. Hydatid disease," in Oxford Textbook of Surgery, P. J. Morris and W. C. Wood, Eds. Oxford University Press, 2nd edition, 2000:3298-3305.
2. Tekin M, Osma U, Yaldiz M, Topcu I. Preauricular hydatid cyst: an unusual location for echinococcosis. *Eur Arch Otorhinolaryngol.* 2004;261:87-9.
3. Ertem M, Karahasanoglu T, Yavuz N, Erguney S. Laparoscopically treated liver hydatid cysts. *Archives of Surgery.* 2002;137(10):1170-3.
4. Palanivelu C, Jani K, Malladi V. Laparoscopic management of hepatic hydatid disease. *Journal of the Society of Laparoendoscopic Surgeons.* 2006;10(1):56-62.
5. Dahniya MH, Hanna RM, Ashebu S, Muhtaseb SA, el-Beltagi A, Badr S, et al. The imaging appearances of hydatid disease at some unusual sites. *Br J Radiol.* 2001;74:283-9.
6. Kayal A, Hussain A. A Comprehensive Prospective Clinical Study of Hydatid Disease. *ISRN Gastroenterology.* Available at: <http://dx.doi.org/10.1155/2014/514757>.
7. Polat P, Kantarci M, Alper F, Suma S, Koruyusu MB, Okur A. Hydatid disease from head to toe. *Radiographics.* 2003;23:475-94.
8. Gogus C, Safak M, Baltaci S, Turkolmez K. Isolated renal hydatidosis: experience with 20 cases. *J Urol.* 2003;169(1):186-9.
9. Kothari DC, Tailor SB, Baid HK, Singh P. Hydatid disease of the parotid gland: a case report *IOSR Journal of Dental and Medical Sciences (IOSR-JDMS)* e-ISSN: 2279-0853, p-ISSN: 2279-0861. 2014;13(11):81-84.
10. Kumar A, Kumar A, Kumar G, Chandra G, Tiwary AK, Bhagat S, Sarawgi M. A rare case of isolated hydatid cyst of breast. *Int J Surg Case Rep.* 2015;7:115-8.
11. Bunkar SK, Vyas S, Kasliwal N, Sharma UC, Tholiya OP. Primary Intramuscular Hydatid Cyst of

- the Gastrocnemius Muscle : a Rare Case Report. *International Journal of Anatomy, Radiology and Surgery.* 2014;3(3):13-5.
12. Kayaalp C, Dirican A, Aydin C. Primary subcutaneous hydatid cysts: a review of 22 cases. *International Journal of Surgery.* 2011;117e121.
 13. Erbil, Yeşim MD; Barbaros, Umut MD. Hydatid Cyst of the Thyroid Gland: Two Case Reports. *Infectious Diseases in Clinical Practice.* 2005;13(6):318-20.
 14. Sarma YS, Prabhu R, Koduru V, Nandra A, Sadhu S. Primary retroperitoneal Hydatid cyst; a rare presentation of echinococcus. *J Surg Arts (Cer San D).* 2015(1):26-8.
 15. Mushtaque M, Mir MF, Malik AA, Arif SH, Khanday SA, Rayees A. Dar Atypical Localizations of Hydatid Disease: Experience from a Single Institute Niger J Surg. 2012;18(1):2-7.
 16. Saimot AG. Medical treatment of liver hydatidosis. *World J Surg.* 2001;25:15-20.
 17. Safioleas M, Misiakos EP, Kakisis J, Manti C, Papachristodoulou A, Lambrou P, et al. Surgical treatment of human echinococcosis. *Int Surg.* 2000;85:358-65.

Cite this article as: Porwal R, Gupta HP, Singh A, Singh RK. Queer localizations of primary hydatid disease: experience from a single institute. *Int Surg J* 2016;3:1538-42.