





# Radiation safety for cardiovascular computed tomography imaging in paediatric cardiology: a joint expert consensus document of the EACVI, ESCR, AEPC, and ESPR

**Marco Francone (Chair)<sup>1,2</sup>, Alessia Gimelli (Co-Chair) <sup>3\*</sup>, Ricardo P. J. Budde<sup>4</sup>, Pablo Caro-Dominguez<sup>5</sup>, Andrew J. Einstein<sup>6,7</sup>, Matthias Gutberlet<sup>8,9</sup>, Pal Maurovich-Horvat<sup>10</sup>, Owen Miller<sup>11</sup>, Eszter Nagy<sup>12</sup>, Luigi Natale<sup>13</sup>, Charles Peebles<sup>14</sup>, Steffen E. Petersen<sup>15,16</sup>, Thomas Semple<sup>17,18</sup>, Israel Valverde<sup>19</sup>, Inga Voges <sup>20</sup>, Aurelio Secinaro <sup>21,22</sup>, and Giovanni Di Salvo <sup>23,24</sup>**

<sup>1</sup>Department of Biomedical Sciences, Humanitas University, Via Rita Levi Montalcini 4, 20072 Pieve Emanuele, Milan, Italy; <sup>2</sup>IRCCS Humanitas Research Hospital, via Manzoni 56, 20089 Rozzano, Milan, Italy; <sup>3</sup>Imaging Department, Fondazione Toscana Gabriele Monasterio, via Moruzzi 1, 56124 Pisa, Italy; <sup>4</sup>Department of Radiology and Nuclear Medicine, Erasmus Medical Center, Rotterdam, The Netherlands; <sup>5</sup>Pediatric Radiology Unit, Department of Radiology Hospital, Universitario Virgen del Rocío, Sevilla, Spain; <sup>6</sup>Seymour, Paul and Gloria Milstein Division of Cardiology, Department of Medicine, Columbia University Irving Medical Center and NewYork-Presbyterian Hospital, New York, NY, USA; <sup>7</sup>Seymour, Paul and Gloria Milstein, Department of Radiology, Columbia University Irving Medical Center and NewYork-Presbyterian Hospital, New York, NY, USA; <sup>8</sup>Department of Diagnostic and Interventional Radiology, Heart Center Leipzig, Leipzig, Germany; <sup>9</sup>Medical Faculty, University of Leipzig, Leipzig, Germany; <sup>10</sup>Medical Imaging Centre, Semmelweis University, Budapest, Hungary; <sup>11</sup>Evelina London Children's Hospital, London, UK; <sup>12</sup>Division of Paediatric Radiology, Department of Radiology, Medical University Graz, Graz, Austria; <sup>13</sup>Radiological, Radiotherapeutic and Haematological Sciences, Fondazione Policlinico Universitario Gemelli—IRCCS, Università Cattolica S. Cuore Rome, Rome, Italy; <sup>14</sup>Department of Radiology, University Hospital Southampton, Southampton, UK; <sup>15</sup>William Harvey Research Institute, NIHR Barts Biomedical Research Centre, Queen Mary University of London, Charterhouse Square, London EC1M 6BQ, UK; <sup>16</sup>Barts Heart Centre, St Bartholomew's Hospital, Barts Health NHS Trust, West Smithfield, London EC1A 7BE, UK; <sup>17</sup>Department of Radiology, The Royal Brompton Hospital, Sydney Street, London SW3 6NP, UK; <sup>18</sup>Centre for Paediatrics and Child Health, Imperial College London, London, UK; <sup>19</sup>Pediatric Cardiology and Cardiovascular Pathology Unit, Virgen del Rocío University Hospital, Institute of Biomedicine of Seville (IBIS), University of Seville, Seville, Spain; <sup>20</sup>Department of Congenital Heart Disease and Paediatric Cardiology, University Hospital Schleswig-Holstein, Kiel, Germany; <sup>21</sup>Department of Pediatric Cardiology and Cardiac Surgery, Bambino Gesù Children's Hospital, Rome, Italy; <sup>22</sup>Advanced Cardiothoracic Imaging Unit, Department of Imaging, Bambino Gesù Children's Hospital, IRCCS, Rome, Italy; <sup>23</sup>Department of Woman and Child Health, Paediatric Research Institute, University of Padua, Padua, Italy; and <sup>24</sup>Experimental Cardiology Department, Paediatric Research Institute, University of Padua, Padua, Italy

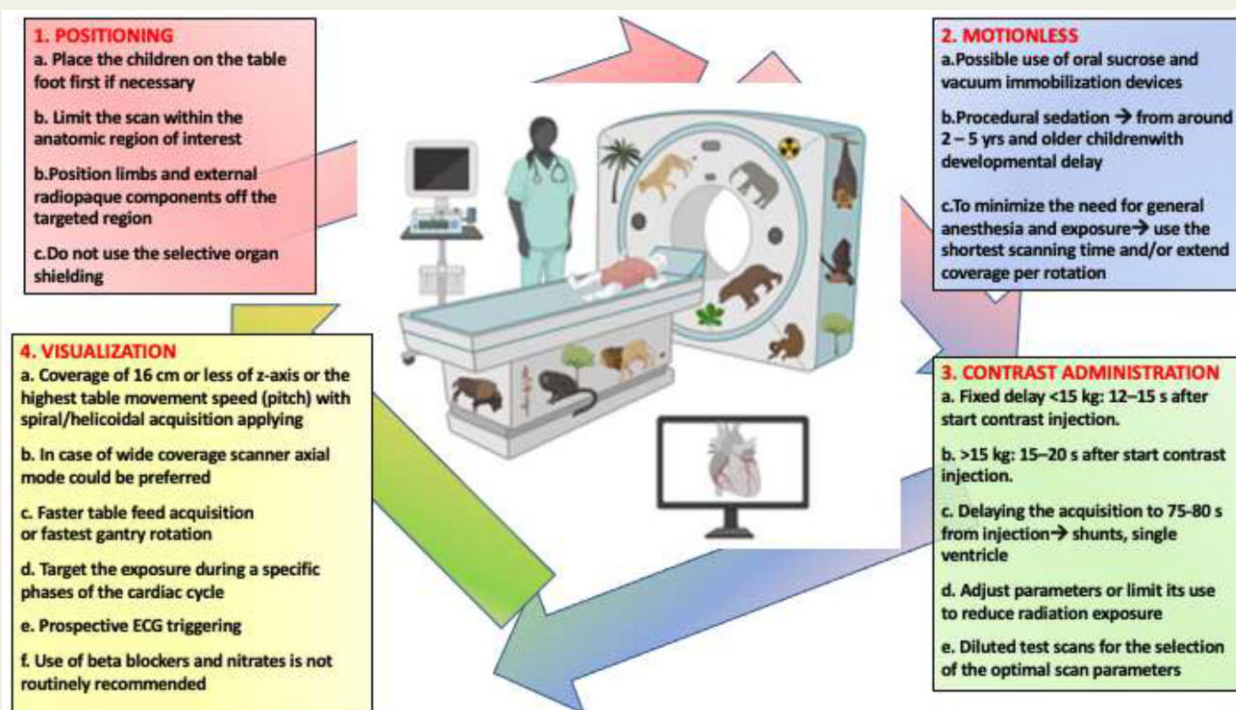
Received 7 February 2022; editorial decision 20 February 2022; accepted 2 March 2022; online publish-ahead-of-print 9 March 2022

Children with congenital and acquired heart disease may be exposed to relatively high lifetime cumulative doses of ionizing radiation from necessary medical invasive and non-invasive imaging procedures. Although these imaging procedures are all essential to the care of these complex paediatric population and have contributed to meaningfully improved outcomes in these patients, exposure to ionizing radiation is associated with potential risks, including an increased lifetime attributable risk of cancer. The goal of this manuscript is to provide a comprehensive review of radiation dose management and cardiac computed tomography performance in the paediatric population with congenital and acquired heart disease, to encourage informed imaging to achieve indication-appropriate study quality at the lowest achievable dose.

\*Corresponding author. Tel: +39 050 3152153. E-mail: [gimelli@ftgm.it](mailto:gimelli@ftgm.it)

Published on behalf of the European Society of Cardiology. All rights reserved. © The Author(s) 2022. For permissions, please email: [journals.permissions@oup.com](mailto:journals.permissions@oup.com).

## Graphical Abstract



## Keywords

CCT • children • congenital heart disease • radiation exposure • radiation protection

## Introduction

In the past decades, the diagnostic approach to cardiovascular diseases has been largely revised by the growing role of imaging technologies, such as echocardiography (echo), cardiovascular computed tomography (CCT), cardiovascular magnetic resonance (CMR), single-photon emission computed tomography (SPECT), and positron emission tomography (PET).<sup>1–3</sup> In addition to the relevant benefits and technical improvements in each of these modalities, great efforts have been made to broaden clinical indications, demonstrate accuracy and prognostic utility, and improve safety profiles.<sup>4–8</sup>

Advances in CCT currently enable detailed anatomical information pertaining to small vascular structures that can be acquired rapidly, even under difficult technical conditions (e.g. high heart rates, challenging contrast administration protocols).<sup>9</sup> This is particularly true for the paediatric population; in fact, the use of cardiovascular CT has been extensively utilized in children of all ages with cardiovascular disorders varying widely in the degree of complexity.<sup>9–11</sup>

The main drawbacks of paediatric CCT are certainly radiation exposure and the potential need for general anaesthesia (the latter for younger and non-compliant patients). Since the introduction of new strategies to reduce radiation dose and cardio-respiratory motion artefact, the ‘safe’ acquisition of high-quality anatomical images has been notably improved<sup>12–15</sup> (Supplementary data online, Table S1).

Consequently, CCT is increasingly considered in the minimally invasive diagnostic workup of paediatric patients as a supplement to echocardiography and may sometimes be preferred over competing second-line imaging tools.<sup>5,16</sup>

Reports on the use of paediatric CCT suggest trends of a slight increase of 1–3% in the annual volume of examinations performed, whilst at the same time there is a decrease in diagnostic cardiac catheterization.<sup>17–19</sup> Despite this, a further rise in the number of paediatric CCT scans in infants, children, and young adults is expected in the near future as a consequence of the technological improvements in newer scanners combined with a wider availability of advanced technology. In this regard, it is also important to be mindful of the overall cumulative dose and risk for paediatric patients with cardiovascular malformations, who are longitudinally exposed to different procedures involving ionizing radiation, including chest radiographs, CCT, cardiac catheterization, and SPECT/PET.<sup>20,21</sup>

Several high-quality review articles and technical papers on CCT are available in the literature.<sup>6,11,22–25</sup> Moreover, in 2015 the Society of Cardiovascular Computed Tomography produced expert consensus documents on CCT in Congenital Heart Disease (CHD)<sup>6</sup> and more recently the American College of Cardiology collaborated with different North-American clinical and imaging societies to develop an appropriate use criteria for CHD multimodality imaging, including paediatric CCT.<sup>4</sup> Finally, in 2021, a European document focused on recommendations on adults with CHD.<sup>26</sup>

The aim of this Expert Consensus Document of the four European associations in the field of cardiac imaging and paediatric care—European Association of Cardiovascular Imaging (EACVI), European Society of Cardiovascular Radiology (ESCR), Association for European Paediatric and Congenital Cardiology (AEPC), and European Society of Paediatric Radiology (ESPR)—is to provide information to foster the clinical use of paediatric CCT with safe and high-quality scans at the lowest possible dose, according to as low as reasonably achievable (ALARA) and as low as diagnostically acceptable (ALADA) principles and to the European Guidelines on Diagnostic Reference Levels for Paediatric Imaging.<sup>27</sup>

The document could be of help to paediatric cardiologist/surgeons who take care of these paediatric population to give all the needed information to patients (when feasible) as well as families and caregivers before the procedure to optimize the clinical decision-making process.

## Indication for CCT

Despite the widespread availability of each of the imaging modalities, there are still insufficient pathology- and age-specific indications for clinicians to clearly define which is the most appropriate imaging modality in the different clinical scenarios. In addition, there is large variability in the frequency with which some non-invasive imaging modalities are prescribed during patient follow-up, and imaging as used sometimes in addition to more invasive procedures.

In this section, we list the main clinical conditions in which CCT can be considered according to previous evidence and expert opinion.<sup>4–6,25</sup> Table 1 summarizes the main age-specific clinical conditions in which the different modalities can be considered and are useful.

### Newborns (birth–2 months)

In newborns, CCT is primarily used to assess complex cardiovascular anatomy that is incompletely visualized or characterized with echocardiography or when CMR is not possible or appropriate. CCT can also be used as an adjunct to echocardiography and cardiac catheterization when the diagnosis is clear but specific anatomical information is needed for planning an intervention or surgery, and/or assessing its feasibility. CCT is especially useful for assessing the anatomy and size of the aorta and pulmonary arteries as well as its branches. These include newborns with a hypoplastic aorta, aortic coarctation, pulmonary atresia (with or without ventricular septal defect), major aortopulmonary collateral arteries, truncus arteriosus, vascular rings and slings, heterotaxy syndromes and complex congenital defects with associated extracardiac anomalies. More commonly, in case of abnormal pulmonary venous return CCT is the gold standard non-invasive technique to evaluate the size, number, and anatomy of the abnormal venous connections, assessment of patent ductus arteriosus anatomy.<sup>28,29</sup>

Assessment of the coronary arteries in newborns is particularly challenging due to the very high heart rates and small vessel caliber. There are limited indications for coronary evaluation in newborns that should be reserved for the visualization of coronary origins and proximal course [anomalous origin of coronary artery from the pulmonary trunk, anomalous coronaries in transposition of great arteries (TGA)].<sup>15,30</sup> Each case should be thoroughly discussed to optimize the scan setting and manage expectations.

Furthermore, CCT can determine atrial and ventricular size and potentially detect additional septal defects. However, CCT should be considered only after transthoracic and/or transoesophageal echocardiography and MRI. In these complex cases, CCT might also improve the understanding of the cardiovascular anatomy and can help in surgical planning.<sup>30</sup>

In the post-operative setting, when the acoustic window is often suboptimal, and the patient unstable, CCT can provide crucial and fast information about post-procedural anatomy, especially in case of (suspected) complications such as post-surgical pulmonary artery narrowing or shunt/stent occlusion.<sup>31</sup>

### Infants (2 months–1 year)

CCT imaging in infants could be used to assess anatomy after initial surgical reconstruction of CHD and planning of sequential stages of initial repairs (e.g. bidirectional cavo-pulmonary connection) if MRI is not available.<sup>30,31</sup> In many patients after the initial diagnosis of CHD, the timing for surgical correction can be delayed until infancy if the condition is well tolerated (e.g. some cases of total anomalous pulmonary venous return) to reduce surgical mortality and morbidity. Sometimes CCT imaging in those cases might be performed close to intervention to assess anatomic details and/or how much vessels have increased in size as a result of deliberate shunt palliation.

Imaging of the coronary arteries in infants is often still difficult. Whilst distal parts of the coronary arteries remain a challenge, the most proximal parts can be adequately evaluated. Thus, CCT should be considered in Kawasaki disease, particularly if persistent coronary dilatation is seen with transthoracic echocardiography.

In cases of suspected complications after initial surgical repair, CCT can be used to assess the size, patency and location of extracardiac surgical shunts. CCT can also be helpful in the combined evaluation of vessels and central airways anatomy in cases where bronchial compression is suspected (e.g. tetralogy of Fallot with absent pulmonary valve, pulmonary sling, or other vascular rings).<sup>32,33</sup>

### Children (1–18 years)

The role of CCT in children is for known or suspected anomalous coronaries and/or for the follow-up of previous procedures. CCT can be helpful in the multi-stage planning of single ventricle repair, (re-)interventions, and detecting complications.

Large vessel complications of earlier surgical corrections include pulmonary artery stenosis after repair for tetralogy of Fallot or TGA, large vessel in-stent re-stenosis or stent fracture, and re-coarctation or false aneurysm formation after aortic coarctation repair, all of which can be accurately assessed with CCT. Also, in children with a bicuspid aortic valve, or inherited aortic dilatation disorders such as Marfan or Loey-Dietz syndromes, CCT can be used to accurately monitor the aortic diameters even if MRI should be preferred for long-term follow-up monitoring.

Percutaneous pulmonary valve implantation is used in patients with severe pulmonary valve regurgitation or pulmonary stenosis after previous right ventricular outflow tract and/or pulmonary valve and trunk corrections. CCT can be used for valve sizing (including advanced 3D modelling of the pulmonary trunk) and assessing the risk of procedural complications (calcified conduit rupture or coronary compression).<sup>34</sup>

**Table 1** Main age-specific clinical conditions for cardiac CT imaging

	Assessment performed	Clinical condition	Imaging <sup>a</sup>
Newborns (birth–2 months) <sup>a</sup>	Anatomy and size of the aorta and pulmonary arteries as well as its branches	- Hypoplastic aorta	TTE +++
		- Aortic coarctation	CCT +++
		- Pulmonary atresia	CMR ++
		- Major aortopulmonary collateral arteries	
		- Truncus arteriosus	
		- Vascular rings and slings, heterotaxy syndromes and complex congenital defects with associated extracardiac anomalies	
Coronary artery origin and proximal course	Anomalous origin of coronary artery from the pulmonary trunk	TTE +++	
	Anomalous coronaries in transposition of great arteries	CCT +++ CMR +	
Post-procedural anatomy	- Post-surgical aortic and pulmonary artery narrowing/dilatation	CCT +++	
	- Shunt/stent patency	TTE ++ CMR +	
Infants (2 months—1 year) <sup>a</sup>	Anatomy after initial surgical reconstruction	Numerous	CCT +++ TTE ++ CMR ++
		Planning of sequential stages of initial repairs	Bidirectional cavo-pulmonary connection
	Coronary aneurysms and thrombosis	Kawasaki's disease	CCT +++ TTE ++ CMR ++
		Suspected complications after initial surgical repair	Numerous
	Vessels and central airway anatomy in cases where bronchial compression is suspected	- Tetralogy of Fallot with absent pulmonary valve	CCT +++
		- Pulmonary sling	TTE ++
Children (1–18 years)	Multi-stage planning of single ventricle repair	Other vascular rings	CMR ++
		(Re-)interventions and possible complications	CMR +++ TTE ++ CCT ++ TOE +
	Evaluation of large vessel complications of earlier surgical corrections	- Pulmonary artery stenosis after tetralogy of Fallot	CCT +++
		- TGA repair	TTE ++
		- Large vessel in stent re-stenosis	CMR ++
		- Stent fracture	TOE +
	Aortic diameters	- Re-coarctation False aneurysm after aortic coarctation repair	
		- Bicuspid aortic valve	CMR +++
		- Inherited aortic dilatation disorders (Marfan and Loeys–Dietz syndromes)	CCT +++ TTE ++ TOE ++
	Valve sizing (including advanced 3D modelling of the pulmonary trunk)	- Percutaneous pulmonary valve implantation	CCT +++
- Calcified conduits rupture		CMR ++	
Coronary compression assessment		TTE + TOE +	
	Leaflet motion	- Prosthetic dysfunction	TTE +++ TOE +++ CCT ++ CMR +
Coronary arteries origin and course	Suspected or known coronary anomalies		CCT +++ CMR +++

Continued

**Table 1** Continued

Assessment performed	Clinical condition	Imaging <sup>a</sup>
Great arteries anatomy	TGA after arterial switch operation	TTE ++
		TOE ++
		CMR +++
		CCT +++
		TTE ++
Coronary aneurysms and thrombosis	Kawasaki's disease	TOE +
		CCT +++
		CMR ++
		TTE ++
		TOE +
Cardiac allograft vasculopathy assessment	Post-heart transplant	CCT +++
		CMR ++
		TTE +
		TOE +
		TOE +
During and after the staged palliation	Functionally single ventricle	TTE +++
		CMR +++
		TOE ++
		CCT ++

Minimally invasive imaging techniques compared in terms of diagnostic accuracy, feasibility, and safety.<sup>4,9</sup>

CCT, cardiac computed tomography; CMR, cardiac magnetic resonance; TOE, trans-oesophageal echocardiogram; TTE, trans-thoracic echocardiogram.

<sup>a</sup>TOE is occasionally performed in newborns and infants due to technical limitations (availability of dedicated probes).

In children who had a prosthetic heart valve (PHV) implantation, PHV dysfunction and endocarditis are feared complications. In case of prosthetic dysfunction, CCT is used to assess leaflet motion (especially mechanical PHVs) and signs of thrombosis or pannus tissue ingrowth. In suspected endocarditis, CCT is especially helpful to detect perivalvular recess/aneurysms and abscesses.

As children get older, coronary CCT visualization becomes more feasible. In fact, CCT is increasingly used for assessment of suspected coronary anomalies, in the follow-up of TGA after arterial switch operation,<sup>35</sup> to assess coronary aneurysms and thrombosis in Kawasaki disease,<sup>15,36</sup> particularly if long-term follow-up suggests coronary ischaemia,<sup>37</sup> and in the follow-up after heart transplantation to detect cardiac allograft vasculopathy.<sup>38</sup>

When a re-operation is considered, CCT can provide important information to plan surgery, including the extent of homograft calcifications, retrosternal distance to the right ventricular free wall as well as a complete overview of the anatomy possibly including vascular access evaluation.

CCT is also often used during and after the staged palliation in patients with a functionally single ventricle. It allows visualization of the anastomoses of the total cavo-pulmonary connection and the pulmonary arteries. CCT can also be used to detect thrombi in the Fontan circuit.

In some cases, a congenital heart defect only becomes apparent during childhood (e.g. aortic coarctation, vascular slings and rings, partial abnormal pulmonary venous return, and persistent ductus arteriosus) and not infrequently are unexpected findings whilst imaging for another indication. CCT then again is well suited to assess the

complete anatomy. CCT can also be performed prior to surgery to obtain a 3D model for surgeons to familiarize themselves with complex cardiopathies, plan surgery, and decrease surgical time and complications.<sup>39</sup>

## Radiation dose metrics

Understanding the basic principles of radiation dose metrics is a necessary step to establish what has been called a 'radiation protection culture' by the International Radiation Protection Association (IRPA) ([www.irpa.net](http://www.irpa.net)) (Table 2).

Most important measures of the radiation output from CT scanners are the volume CT dose index (CTDI<sub>vol</sub>; expressed in units of mGy) and the dose length product (DLP; expressed in units of mGy cm).

The CTDI<sub>vol</sub> is an estimate of the average radiation dose delivered within a volume of tissue, calculated from measurements made in dedicated polymethylmethacrylate phantoms. CTDI<sub>vol</sub> can be used to compare radiation outputs between different CT scanners and different acquisition protocols within a single scanner, since it is sensitive to changes in scan parameters but independent of patient size.

The DLP is a second key patient dose descriptor in CT, which measures the CTDI<sub>vol</sub> delivered over a specific scan length.<sup>40</sup> It is calculated by multiplying the CTDI<sub>vol</sub> by the scan length.

It is important to remember that the CTDI<sub>vol</sub> as well as the DLP do not represent the actual absorbed or effective dose for the patient, which are respectively defined as a measure of the energy

**Table 2** Description of the main metrics used for characterization of CT radiation dose

Computed tomography dose index (CTDI)	Area under the radiation-dose profile for a single rotation and fixed table position along the axial direction of the scanner divided by the total number of detectors for slice thickness and is expressed in coulomb/kg
CTDI100	Integrated radiation dose from acquiring a single scan over a length of 100 m
CTDIw	Average radiation dose to a cross section of a patient's body determined with the equation $CTDI_w = 2/3CTDI_{100}$ at periphery + $1/3CTDI_{100}$ at centre
CTDIvol	Average radiation dose over the volume scanned determined by the equation $CTDI_{vol} = CTDI_w/pitch$ , where pitch is defined as table movement expressed in millimetres for each 360° gantry rotation, divided by the product of the number of slices and slice width. It is measured in milligrey
SSDE	$CTDI_{vol}$ is normalized to SSDE using a size-dependent conversion factor ( $f$ ) that considers the size of the patient as an effective diameter
Dose length product (DLP)	Integrated radiation dose for a complete CT examination measured in milligrey × centimetres and calculated by the formula $DLP = CTDI_{vol} \times \text{length irradiated}$
Effective dose (ED)	Measured as the product between DLP and $k$ , the region-specific conversion factor

deposited in matter by ionizing radiation per unit mass and the tissue-weighted sum of the doses in all specified tissues and organs of the human body. They should be taken as an index of radiation output by the system for comparison purposes.

In fact, if an estimate of effective dose is calculated based on DLP, then sex- and age-specific cardiac conversion factors should be used.<sup>41</sup>

Regarding paediatric patients, specific conversion factors depending on tube potentials should be applied.<sup>41</sup>

Another radiation parameter gaining popularity is the size-specific dose estimate (SSDE). The concept of SSDE was introduced by the American Association of Physicists in Medicine (AAPM) to refine  $CTDI_{vol}$  on the basis of patient body size.<sup>42</sup>  $CTDI_{vol}$  is normalized to SSDE using a size-dependent conversion factor ( $f$ ) that considers the size of the patient as an effective diameter.

Therefore, SSDE is a much more patient-specific dosimetric quantity with an accuracy of 20%,<sup>42</sup> and it should be indicated in every dose report, as reported in the 2018 document of the EuroSafe Imaging, that is the European Society of Radiology's flagship initiative to promote quality and safety in medical imaging.<sup>27</sup>

Tube current modulation, frequently deployed in CCT to reduce dose, unfortunately makes calculation of SSDE more complex and consequently may limit its use until all scanners calculate SSDE automatically.

European guidelines on diagnostic reference levels for paediatric imaging<sup>27</sup> recommend that dose management systems for paediatric CT imaging should provide the following parameters/units as a minimum:  $CTDI_{vol}$  (calibration obtained by 16 cm phantom size), DLP, SSDE, patient width, or water equivalent diameter, mSv.

## Paediatric CCT technique: the optimization principle

### Patient preparation

Tailoring scanning protocols to patient's characteristics and clinical context is crucial for paediatric CCT; indeed, intravenous access

caliber, contrast bolus timing, and scan parameters can largely vary and may significantly affect the image quality of the exam ([Supplementary data online, Video tutorial](#)).

Individual- and scanner-based optimization in paediatric patients should include the following strategies<sup>43</sup> to achieve the best image properties by increasing intravascular contrast while reducing image degradation due to noise (increase contrast to noise ratio).

Scanning an awake child has numerous advantages, but also requires adequate pre-scan strategies. Ideally, preparation should include parent's involvement throughout the investigation and the use of play/child-life specialists, story books, toy scanners, and other entertainment tools, thus considerably increasing the chances of a successful scan and reducing child and parental stress.

Key notes for patient positioning:

- (1) Scan range must be limited to within the anatomic region of interest; centring the heart at the isocentre of the gantry may reduce surface dose.
- (2) The limbs should be positioned off the targeted region as well as all external radiopaque components (i.e. tube, lines, and monitor leads).
- (3) Use of selective organ shielding is not recommended if the CCT protocols are already efficiently optimized for children, because of the limited impact of diffuse radiation and possible interferences with modern systems of automatic dose modulation.<sup>44</sup>

Key notes for motionless imaging:

- (1) Neonates and infants can be generally scanned awake with oral administration of sucrose<sup>45</sup> and the use of vacuum immobilization devices to limit gross patient movement.<sup>44</sup>
- (2) Children from around 2–5 years of age and older children with developmental delay may require procedural sedation or general anaesthesia.
- (3) Compliant older children can follow breath hold instructions and be scanned in the same way an adult would be.
- (4) In order to minimize the need for general anaesthesia and the patient's exposure, the shortest scanning time should be offered by increasing tube rotation time and table speed (can reach up to 737 mm/s in last generation dual source scanners) or, alternatively,

by using wide detectors (i.e. 16 cm) offering extended coverage per rotation and eliminating the need to do multiple acquisitions.

There is a close relationship between temporal resolution and image quality, which allows one to acquire virtually motionless images.<sup>15,46</sup>

When required, procedural sedation can be performed with low incidence of adverse events.<sup>47–49</sup> Sedation should only be performed by experienced and trained personnel with appropriate monitoring and medication/equipment immediately available for resuscitation.<sup>49,50</sup> The main disadvantages of sedation are an unprotected airway with the risks of aspiration, airway obstruction and hypoventilation.

General anaesthesia should be reserved for patients who are not able to adequately cooperate and in case of single source CT scanner with <128 detector rows, in order to compensate for slower acquisition speed, so as to minimize respiratory motion artefacts. Like sedation, general anaesthesia is associated with procedural risks, that can be very high in specific clinical circumstances (e.g. Williams Syndrome),<sup>51</sup> and requires more specialized personnel and greater equipment resources.

Considering the risks of anaesthesia and the potential for adverse neurodevelopment outcome,<sup>52</sup> awake scanning should be always preferred and sedation and general anaesthesia only considered in scenarios where awake scanning is not possible.<sup>13,53</sup> The use of an advanced scanner, e.g. dual source or wide coverage scanner, should be prioritized so as to reduce the need for anaesthesia.

## Contrast administration protocols (in newborns, infants, and children)

Several protocols for cardiovascular CCT in children have been proposed in the literature.<sup>5</sup> Optimizing iodine contrast delivery is a further highly effective strategy to minimize unnecessary radiation exposure (reduced need of repeated CCT acquisition, reduced tube output with better image contrast, and even data suggesting that iodinated contrast dose increases radiation deposition in tissues)<sup>54,55</sup> and risks of contrast-related nephrotoxicity.

Three basic concepts should be considered to optimize contrast administration in paediatric CCT:

- (1) Injecting intravenous contrast to achieve adequate arterial opacification, timing the scan to match the moment where more contrast is present in the region of interest and optimizing image quality.
- (2) The use of faster acquisition protocols allows to deliver smaller amounts of contrast material (30–50%)<sup>56</sup> and acquire imaging in a more precise point in time and space (i.e. arterial enhancement without venous contamination).
- (3) The time required from injection to optimal enhancement of a vascular structure depends on cardiac output, distance from the intravenous site, injection rate and angiocatheter diameter and the type of CHD.

Typically, a dosage of 1–2 mL/kg of contrast medium (CM) is needed for the detailed cardiovascular assessment as well as the visualization of the coronary arteries. Contrast injection rates range from 1 to 5 mL/s and depend on the size of the child and the intravenous catheter.<sup>57,58</sup> Meticulous care must be taken to de-air the contrast lines and flushes in patients with potential right to left shunts or intracardiac mixing lesions. Intravenous contrast administration is

normally well tolerated, and the number of reported contrast reactions is low.<sup>59,60</sup>

The intravenous access should be obtained in the peripheral veins, preferably in the antecubital fossa (hand injection should be avoided due to the high rate of extravasion). However, foot veins can be an acceptable alternative in neonates and infants<sup>61</sup> and central catheters can also be used with some precautions.<sup>62</sup> It is advisable to place the peripheral cannula in a comfortable environment possibly after the application of a local anaesthetic gel or ointment (e.g. lidocaine hydrochloride gel).<sup>44</sup> The optimal intravenous cannula size in children is a 20- to 22-gauge that allows adequate contrast injection rates. However, in neonates and infants a 24-gauge intravenous cannula can also be utilized. A saline bolus should be injected immediately after contrast infusion in a sufficient amount to avoid stagnation of contrast in the tubing and systemic veins (ranging from ~10 to 12 mL in neonates).<sup>56</sup>

A biphasic/dual phase injection protocol (contrast at a constant rate followed by a saline flush) is typically used to for pulmonary or systemic arterial angiography, with image acquisition timed to opacification of the vessel of interest. For patients with intra-cardiac shunting, a longer and slower contrast injection with image acquisition at the end of injection often allows venous and arterial opacification on the same scan without a separate initial bolus. This can be helpful in patients such as neonates with intra-cardiac mixing or a suspected combination of arterial and venous malformation.<sup>5,6</sup>

Generally, administration strategies can be classified into two main approaches of injection: using a fixed scan delay or bolus timing techniques (bolus tracking and test bolus). Depending on the vessel being imaged, in the bolus timing techniques the volume of contrast is tracked using a region of interest ('ROI') at a certain level and then followed by the CCT acquisition once it reaches its optimal intravascular concentration.

### Key notes for fixed scan delay:

- (1) Fixed delay <15 kg: 12–15 s after start CM injection.
- (2) >15 kg: 15–20 s after start CM injection.<sup>44</sup>
- (3) In neonates in case of hand injection of contrast due to inadequate peripheral intravenous access.<sup>22</sup>
- (4) Delaying the acquisition to 75–80 s from the start of injection achieves good venous and arterial enhancement in children with large intracardiac shunts and is particularly effective in single ventricle physiology, such as Glenn or Fontan pathways.<sup>63</sup>

### Key notes for test bolus and bolus tracking:

- (1) Adjust parameters or limit its use to reduce additional radiation exposure, especially in neonates.
- (2) From the age of around 5 years, coronary imaging is performed in a similar fashion to adult coronary CT with a small test bolus used to time the diagnostic acquisition.
- (3) Modern protocols in infants may include diluted test scans for the selection of the optimal scan parameters.<sup>64</sup>

## Patient-based and scanner-based optimization approach

Optimizing the scan acquisition is highly dependent on the technical configuration of the scanner but some general principles apply:

- Precontrast CCT acquisition rarely results in clinically relevant extra information, with the exception of an urgent scan performed to rule out sources of acute bleeding. Thus, as in the adult procedures, avoiding non-contrast CT allows one to minimize radiation exposure and theoretically halve the dose.
- All types of CT scanners are equipped with predefined and recommended paediatric acquisition settings. This implies that parameters for the entire examination are specifically tailored for children, including preliminary exam planning images (i.e. surview or topogram, as well as contrast monitoring).
- Multiphase CT examinations in children should be avoided, however, if the initial scan has insufficient contrast enhancement, it is acceptable to prepare and run a second scan acquisition, optimizing the amount of contrast and timing of administration and scan. This needs to be decided immediately after the first acquisition by reviewing the images on the scanner console directly as soon as they are visualized, in order to avoid the administration of an additional dose of contrast;
- Tube potential (kV)<sup>65</sup> and tube current (mA)<sup>66</sup> should be optimized to patient size;
- In smaller children it is preferable to use low tube potential (70–80 kV), thus exponentially decreasing radiation dose. This adjustment also increases endovascular contrast enhancement<sup>67</sup> at the cost of higher image noise. The higher tube current required at lower potential can be minimized by means of recently developed iterative reconstruction algorithms, which substantially reduce image quantum noise with no impact on spatial or contrast resolution.<sup>68–70</sup> Tube potential may be increased up to 80–100 kVp for older children and adolescents with larger body habitus.<sup>71,72</sup>
- Newer exposure control systems allow to automatically modulate the tube current.
- Both high-pitch helical scan and wide coverage scanning technique can be used. High-pitch helical scan modes are performed using dual-source scanners which allow the acquisition of a full volume in less than a second or within a single heartbeat.<sup>73</sup> This high-pitch helical scan mode often precludes the need for sedation or controlled ventilation in infants or uncooperative children. Main disadvantage of present approach is that it requires a dual-source technique and that it is strongly dependent on the presence of a regular heart rate, which is not always obtainable in paediatric patients. Additionally, scan mode cannot be used for ventricular function assessment.<sup>74</sup> The wide coverage scanning technique, conversely, can acquire the entire cardiac volume in a single heartbeat and misregistration artefacts are completely avoided resulting in no step artefacts, a particular issue in patients with irregular and high heart rates; volume of the administered contrast agent can also be minimized. Wide-coverage scanners are ideally suited to perform dynamic myocardial perfusion studies which are, however, rarely used in paediatric studies. Major potential drawback of this technology is the possible occurrence of the so-called ‘cone-beam’ artefacts, depending on the divergence of X-ray-beam on scanner with wide volume coverage.<sup>75</sup>
- From a theoretical point of view when appropriately used, bismuth or lead shielding technique is a valid and valuable tool to protect superficial organs.<sup>76</sup> Despite this, use of selective organ shielding is not universally recommended in the paediatric population as dose reduction can be efficiently achieved by lowering the tube current and kV.<sup>77</sup> In addition, some authors advocate that organ shielding can increase the impact of diffuse radiation and reduce the performance of modern systems of automatic dose modulation (angular and z-axis, organ, and age-based tube current modulation).<sup>44,78</sup>

Key notes for optimal visualization of cardiovascular structures:

- (1) Ideal morphological assessment can be obtained using a wide coverage scanner up to 16 cm z-axis coverage or with spiral/helicoidal acquisition applying the highest table movement speed (pitch).
- (2) Faster table feed acquisition, when available, can further reduce artefacts related to cardiac movement.
- (3) Cardiac synchronization with ECG gating is the best tool to adapt image acquisition to cardiac movement, while targeting the exposure during a specific phase of the cardiac cycle.
- (4) Prospective ECG triggering is a reliable and robust cardiac gating strategy; appropriate use of specific settings (short pulsing window) can further decrease irradiation<sup>15,66</sup> and it should be encouraged in clinical practice.
- (5) The best cardiac phase acquisition depends on patient’s heart rate and the clinical query (i.e. coronaries are generally best evaluated around diastole, although the right coronary artery at higher heart rates<sup>79</sup> may be best at end systole, while ventricular septal defects are best evaluated during systole<sup>30</sup>).
- (6) Good quality image during the diastolic phase cannot be always accurately achieved in paediatric patients, particularly in the presence of higher heart rates (rest time of the heart is shorter).
- (7) End-systolic time frame acquisition (end of T wave, 40–45% of the R-R interval, 220–270 ms delay from the R wave) should be applied in paediatric patients with irregular and fast heart rate (generally >75 bpm, with some cut-off value variations depending on the scanner temporal resolution).<sup>15,73,74</sup>
- (8) The use of beta blockers and nitrates is not routinely recommended for paediatric coronary CT evaluation, in particular for newborn and younger children, but rather should be considered on a case-by-case basis; it may be more advantageous for older children and to assess rare cases of distal/stenotic coronary artery disorders (e.g. Kawasaki disease).<sup>15</sup>
- (9) Full cardiac cycle acquisition with retrospective ECG-gating offers flexibility for phase selection with additional dynamic information (i.e. biventricular volumes/function), but comes at considerably higher radiation dose; it should be avoided in clinical routine practice.<sup>80</sup> Nevertheless, with very careful and stringent optimization of tube potential, current, and scan length, even full cardiac cycle acquisition can often be performed at modest radiation dose.

## Importance of patient/caregiver-centred imaging

Generally, parents and caregivers have a restricted knowledge of the potential for harmful effects of ionizing radiation, and often it is influenced by media misrepresentation, perceiving risks far greater than those that actually exist.<sup>1–3</sup>

Families and caregivers have to be informed of risks regarding medical imaging procedures, thus a detailed discussion of the risk/benefit profile of a CCT exam may be a multidisciplinary responsibility involving the referring physician, the whole congenital heart team, and the radiologists.<sup>2,3</sup> Optimal informed decision-making for paediatric CCT is a collaborative process centred on families, caregivers individualizing the conversation to the specificity of the selected paediatric patient.<sup>2,3</sup>

Families should be involved in the decision-making process by communicating anticipated risks and benefits of the planned procedure,



including those associated with radiation exposure. Families and caregivers must be made aware of risks and benefits of any given imaging technique, such as potential cognitive deficits from general anaesthesia,<sup>25,43,81</sup> gadolinium-based contrast brain deposit used for CMR evaluation in young children, radiation exposure, intravenous contrast and need for general anaesthesia for a diagnostic catheterization, or intravenous contrast media for either CT or CMR.<sup>25,43,82</sup> We strongly encourage direct verbal communication, with or without formal written consent depending on the procedural risk level.

Consistent with the expert consensus recommendations from a symposium supported by the National Institutes of Health–National Heart, Lung, and Blood Institute/National Cancer Institute, when there is an anticipated procedural effective dose of  $\leq 3$  mSv, the procedure is considered of very low risk and thus written or web-based materials should be adequate. Radiologists, cardiologists, technicians and/or imaging nurses will play an pivotal role within the dialogue with the patient and family, not warranting written informed consent.<sup>25,43,82</sup>

In contrast, an anticipated effective dose of  $\geq 20$  mSv or, administration of pulse lowering medications, anaesthesia, studies obtained in critically ill children, or patients who will undergo contrast exposure within the setting of renal disorder or iodinated contrast allergy, require either formal discussion or written informed consent.<sup>25,43,82</sup>

## Dose monitoring program

Even if direct studies of cancer risk in patients who have undergone CT scans have been undertaken to date, in 2017 a study assessing the question of whether cancer risks are increased after CT scans in childhood and young adulthood was published in *Lancet*.<sup>83</sup> The Authors concluded that even if the cumulative absolute risks of cancer are small (in the 10 years after the first scan for patients younger than 10 years, one excess case of leukaemia and one excess case of brain tumour per 10 000 head CT scan is estimated to occur) radiation doses from CT scans ought to be kept as low as possible and cumulative ionizing radiation doses must be quantified to avoid the increase of the risk.<sup>83</sup>

Inherent in the accountability for ionizing radiation dose management across all ages and for any imaging specialty is that of auditing of clinical practice and modification of practice on the basis of the results as necessary.

As reported in in the *Council Directive 2013/59/Euratom*, Article 4, chapter II, 'clinical audit' means a 'systematic examination or review of medical radiological procedures which seeks to improve the quality and outcome of patient care through structured review, whereby medical radiological practices, procedures and results are examined against agreed standards for good medical radiological procedures, with modification of practices, where appropriate, and the application of new standards if necessary' [European Commission (2018) European guidelines on diagnostic reference levels for paediatric imaging. Radiation Protection 185].

According to these principles, the major goal of a dose monitoring program is to improve the quality of individual patient care.<sup>27</sup>

The variables to evaluate in the dose monitoring program can be summarized as following: (i) definition of data to monitor, access to the data from each CT equipment vendor and evaluation of quality and accuracy of dose metrics provided by equipment and (ii)

definition of what is practice beyond standards, and what follow through to initiate in response to outlier data are some of the challenges for a dose management program.

Information to be collected in the dose monitoring program monitor includes protocol-specific dose metrics, which should be included in the DICOM header and should be calibrated and checked regularly, that can serve in the establishment of standards of performance for the practice. Methods should be established for identifying dose values outside of the defined reference range and for assessing system variability and trends over time, as well as discrepancies between the protocol definitions and protocols performed in clinical practice. In particular, all radiological departments should apply the available national diagnostic reference levels, unless lower (more strict) local diagnostic reference levels have been defined. Whenever the DRLs applied are consistently exceeded, appropriate investigations to identify the reasons, and corrective actions to improve the clinical practice, if necessary and feasible, should be undertaken without undue delay.

The dose monitoring program should be mandatory in all CT exams. In particular, in paediatric cardiac imaging, an additional layer of complexity is introduced in as the complex balance between image quality, contrast timing, and cardiac/respiratory gating can affect radiation dose. Anatomic variability can lead to substantial variation in dose or quality for the same CT protocol. For this reason, constant vigilance in reviewing radiation exposure data is needed to ensure that quality and dose are optimal in paediatric cardiac CT.

The dose monitoring program is a responsibility of a multi-disciplinary imaging team and includes not only physicians, but also technologists, medical physicists and information technology specialists.

## Conclusions

Paediatric patients with heart disease may require lifelong imaging surveillance. Advances in technology have made paediatric cardiac CT one of the best imaging modality choice in certain scenarios as detailed images can be obtained quickly and often without sedation. Understanding cardiac CT technical parameters and how to apply them to children of various sizes and heart rates is necessary to optimize image quality at the lowest radiation dose. Other measures, including a concerted effort to engage patients and caregivers in an informed decision-making process related to medical imaging are also recommended to improve patient care and to encourage informed imaging. Finally, instituting a dose management program will help ensure regulatory compliance and should aim to achieve consistently high-quality images at the lowest achievable dose.

## Supplementary data

Supplementary data are available at *European Heart Journal - Cardiovascular Imaging* online.

## Acknowledgements

The authors thank Professor Raffaella Motta, Department of Medicine, Institute of Radiology, University of Padua and Dr Valeria Pergola, Department of Cardiac, Thoracic and Vascular Sciences and Public Health, University of Padua, for their help with the video tutorial.

**Conflict of interest:** none declared.

## Data Availability

No new data were generated or analysed in support of this research.

## References

- Friedrich MG. The future of cardiovascular magnetic resonance imaging. *Eur Heart J* 2017;**38**:1698–701.
- Parsons IT, Nicol E. Cardiac CT: global use and comparison of international guidelines. *Curr Cardiovasc Imaging Rep* 2018;**11**:24–8.
- Gimelli A, Achenbach S, Buechel RR, Edvardsen T, Francone M, Gaemperli O, et al.; EACVI Scientific Documents Committee. Strategies for radiation dose reduction in nuclear cardiology and cardiac computed tomography imaging: a report from the European Association of Cardiovascular Imaging (EACVI), the Cardiovascular Committee of European Association of Nuclear Medicine (EANM). *Eur Heart J* 2018;**39**:286–94.
- Sachdeva R, Valente AM, Armstrong AK, Cook SC, Han BK, Lopez L et al. ACC/AHA/ASE/HRS/ISACHD/SCAI/SCCT/SCMR/SOPE 2020 appropriate use criteria for multimodality imaging during the follow-up care of patients with congenital heart disease. *J Am Coll Cardiol* 2020;**75**:657–703.
- Han BK, Rigsby CK, Hlavacek A, Leipsic J, Nicol ED, Siegel MJ, et al.; North American Society of Cardiac Imaging. Computed tomography imaging in patients with congenital heart disease part I: rationale and utility. An Expert Consensus Document of the Society of Cardiovascular Computed Tomography (SCCT). Endorsed by the Society of Pediatric Radiology (SPR) and the Nor. *J Cardiovasc Comput Tomogr* 2015;**9**:475–92.
- Han BK, Rigsby CK, Leipsic J, Bardo D, Abbara S, Ghoshhajra B, et al.; North American Society of Cardiac Imaging. Computed tomography imaging in patients with congenital heart disease, part 2: technical recommendations. An Expert Consensus Document of the Society of Cardiovascular Computed Tomography (SCCT). *J Cardiovasc Comput Tomogr* 2015;**9**:493–513.
- Francone M, Aquaro GD, Barison A, Castelletti S, de Cobelli F, de Lazzari M et al. Appropriate use criteria for cardiovascular MRI: SIC – SIRM position paper Part 2 (myocarditis, pericardial disease, cardiomyopathies and valvular heart disease). *J Cardiovasc Med (Hagerstown)* 2021;**22**:515–29.
- Pontone G, Di Cesare E, Castelletti S, De Cobelli F, De Lazzari M, Esposito A et al. Appropriate use criteria for cardiovascular magnetic resonance imaging (CMR): SIC—SIRM position paper part 1 (ischemic and congenital heart diseases, cardio-oncology, cardiac masses and heart transplant). *Radiol Med* 2021;**126**:365–79.
- Mangal R, Jain A, Amin P, Sheth MM, Jain S. Role of multi-detector computed tomography in congenital heart diseases. *Int J Res Med Sci* 2018;**6**:3423.
- Ugas Charcape CF, Alpaca Rodriguez LR, Matos Rojas IA, Lazarte Rantes CI, Valdez Quintana M, Katekaru Tokeshi DA et al. Characterisation of computed tomography angiography findings in paediatric patients with heterotaxy. *Pediatr Radiol* 2019;**49**:1142–51.
- Secinaro A, Curione D. Congenital heart disease in children. In: *Medical Radiology*. 2019, pp. 987–1009.
- Booij R, Dijkshoorn ML, van Straten M, Du Plessis FA, Budde RPJ, Moelker A et al. Cardiovascular imaging in pediatric patients using dual source CT. *J Cardiovasc Comput Tomogr* 2016; **10**:13–21.
- Tivnan P, Winant AJ, Johnston PR, Plut D, Smith K, MacCallum G et al. Thoracic CTA in infants and young children: image quality of dual-source CT (DSCT) with high-pitch spiral scan mode (turbo flash spiral mode) with or without general anesthesia with free-breathing technique. *Pediatr Pulmonol* 2021;**56**:2660–7.
- Han BK, Lindberg J, Grant K, Schwartz RS, Lesser JR. Accuracy and safety of high pitch computed tomography imaging in young children with complex congenital heart disease. *Am J Cardiol* 2011;**107**:1541–6.
- Secinaro A, Curione D, Mortensen KH, Santangelo TP, Ciancarella P, Napolitano C et al. Dual-source computed tomography coronary artery imaging in children. *Pediatr Radiol* 2019;**49**:1823–39.
- Han BK, Overman DM, Grant K, Rosenthal K, Rutten-Ramos S, Cook D et al. Non-sedated, free breathing cardiac CT for evaluation of complex congenital heart disease in neonates. *J Cardiovasc Comput Tomogr* 2013;**7**:354–60.
- Han BK, Lesser AM, Vezmar M, Rosenthal K, Rutten-Ramos S, Lindberg J et al. Cardiovascular imaging trends in congenital heart disease: a single center experience. *J Cardiovasc Comput Tomogr* 2013;**7**:361–6.
- Yang JCT, Lin MT, Jaw FS, Chen SJ, Wang JK, Shih TTF et al. Trends in the utilization of computed tomography and cardiac catheterization among children with congenital heart disease. *J Formos Med Assoc* 2015;**114**:1061–8.
- Bailliard F, Hughes ML, Taylor AM. Introduction to cardiac imaging in infants and children: techniques, potential, and role in the imaging work-up of various cardiac malformations and other pediatric heart conditions. *Eur J Radiol* 2008; **68**:191–8.
- Ciancarella P, Ciliberti P, Santangelo TP, Secchi F, Stagnaro N, Secinaro A. Noninvasive imaging of congenital cardiovascular defects. *Radiol Med* 2020;**125**:1167–85.
- ESR. *European Guidelines on DRLs for Paediatric Imaging (final complete draft)*. March 2015, p.117. [http://www.eurosafeimaging.org/wp/wp-content/uploads/2015/09/European-Guidelines-on-DRLs-for-Paediatric-Imaging\\_FINAL-for-workshop\\_30-Sept-2015.pdf](http://www.eurosafeimaging.org/wp/wp-content/uploads/2015/09/European-Guidelines-on-DRLs-for-Paediatric-Imaging_FINAL-for-workshop_30-Sept-2015.pdf).
- Schindler P, Kehl HG, Wildgruber M, Heindel W, Schülke C. Cardiac CT in the preoperative diagnostics of neonates with congenital heart disease: radiation dose optimization by omitting test bolus or bolus tracking. *Acad Radiol* 2020;**27**:e102-108–e108.
- Crean A. Cardiovascular MR and CT in congenital heart disease. *Heart* 2007;**93**:1637–47.
- Sigal-Cinqualbre A, Lambert V, Ronhean A, Paul JF. Place du scanner multicoups (SMC) et de l'IRM dans la stratégie diagnostique des cardiopathies congénitales. *Arch Pédiatrie* 2011;**18**:617–27.
- Rigsby CK, McKenney SE, Hill KD, Chelliah A, Einstein AJ, Han BK et al. Radiation dose management for pediatric cardiac computed tomography: a report from the Image Gently 'Have-A-Heart' campaign. *Pediatr Radiol* 2018;**48**:5–20.
- Di Salvo G, Miller O, Babu Narayan S, Li W, Budts W, Valsangiacomo Buechel ER et al. Imaging the adult with congenital heart disease: a multimodality imaging approach - position paper from the EACVI. *Eur Heart J Cardiovasc Imaging* 2018; **19**:1077–98.
- Granata C, Sorantin E, Seuri R, Owens CM. European Society of Paediatric Radiology Computed Tomography and Dose Task Force: European guidelines on diagnostic reference levels for paediatric imaging. *Pediatr Radiol* 2019;**49**:702–5.
- Dyer KT, Hlavacek AM, Meinel FG, De Cecco CN, McQuiston AD, Schoepf UJ et al. Imaging in congenital pulmonary vein anomalies: the role of computed tomography. *Pediatr Radiol* 2014; **44**:1158–68.
- Shen Q, Pa M, Hu X, Wang J. Role of plain radiography and CT angiography in the evaluation of obstructed total anomalous pulmonary venous connection. *Pediatr Radiol* 2013;**43**:827–35.
- Valverde I, Gomez-Ciriza G, Hussain T, Suarez-Mejias C, Velasco-Forte MN, Byrne N et al. Three-dimensional printed models for surgical planning of complex congenital heart defects: an international multicentre study. *Eur J Cardiothorac Surg* 2017;**52**:1139–48.
- Krupickova S, Vazquez-Garcia L, Obeidat M, Banya W, DiSalvo G, Ghez O et al. Accuracy of computed tomography in detection of great vessel stenosis or hypoplasia before superior bidirectional cavopulmonary connection: comparison with cardiac catheterization and surgical findings. *Arch Cardiovasc Dis* 2019;**112**:12–21.
- Sizarov A, Raimondi F, Bonnet D, Boudjemline Y. Cardiovascular anatomy in children with bidirectional Glenn anastomosis, regarding the transcatheter Fontan completion. *Arch Cardiovasc Dis* 2018;**111**:257–69.
- Leonardi B, Secinaro A, Cutrera R, Albanese S, Trozzi M, Franceschini A et al. Imaging modalities in children with vascular ring and pulmonary artery sling. *Pediatr Pulmonol* 2015;**50**:781–8.
- Tezza M, Witsenburg M, Nieman K, van de Woestijne PC, Budde RPJ. Cardiac CT to assess the risk of coronary compression in patients evaluated for percutaneous pulmonary valve implantation. *Eur J Radiol* 2019;**110**:88–96.
- Ou P, Celermajer DS, Marini D, Agnoletti G, Vouhé P, Brunelle F et al. Safety and accuracy of 64-slice computed tomography coronary angiography in children after the arterial switch operation for transposition of the great arteries. *JACC Cardiovasc Imaging* 2008;**1**:331–9.
- Marchesi A, Tarissi de Jacobis I, Rigante D, Rimini A, Malorni W, Corsello G et al. Kawasaki disease: guidelines of the Italian Society of Pediatrics, part I - definition, epidemiology, etiopathogenesis, clinical expression and management of the acute phase. *Ital J Pediatr* 2018;**44**:1–18.
- Brogan P, Burns JC, Cornish J, Diwakar V, Eleftheriou D, Gordon JB et al. Lifetime cardiovascular management of patients with previous Kawasaki disease. *Heart* 2020;**106**:411–20.
- Goody VD, Dillenbeck J, Arar Y, Castellanos DA, Greil GF, Hernandez NB et al. Coronary CT angiography in pediatric and young adult coronary allograft vasculopathy: single-center experience. *JACC: Cardiovascular Imaging* 2021;**14**:1065–7.
- Van Arsdell GS, Hussein N, Yoo SJ. Three-dimensional printing in congenital cardiac surgery—now and the future. *J Thorac Cardiovasc Surg* 2020; **160**:515–9.
- Catalano C, Francone M, Ascarelli A, Mangia M, Iacucci I, Passariello R. Optimizing radiation dose and image quality. *Eur Radiol Suppl* 2007;**17**:26–32.
- Deak PD, Smal Y, Kalender WA. Multisection CT protocols: sex- and age-specific conversion factors used to determine effective dose from dose-length product. *Radiology* 2010;**257**:158–66.

42. Burton CS, Szczykutowicz TP. Evaluation of AAPM Reports 204 and 220: estimation of effective diameter, water-equivalent diameter, and ellipticity ratios for chest, abdomen, pelvis, and head CT scans. *J Appl Clin Med Phys* 2018;**19**:228–38.
43. Hill KD, Frush DP, Han BK, Abbott BG, Armstrong AK, DeKemp RA et al. Radiation safety in children with congenital and acquired heart disease: a scientific position statement on multimodality dose optimization from the image gently alliance. *JACC Cardiovasc Imaging* 2017;**10**:797–818.
44. Nieuvelstein RAJ, Van Dam IM, Van Der Molen AJ. Multidetector CT in children: current concepts and dose reduction strategies. *Pediatr Radiol* 2010;**40**:1324–44.
45. McPherson C, Ortinau CM, Vesoulis Z. Practical approaches to sedation and analgesia in the newborn. *J Perinatol* 2020;**41**:383–95.
46. Lell MM, May M, Deak P, Alibek S, Kuefner M, Kuettner A et al. High-pitch spiral computed tomography: effect on image quality and radiation dose in pediatric chest computed tomography. *Invest Radiol* 2011;**46**:116–23.
47. Bellolio MF, Puls HA, Anderson JL, Gilani WI, Murad MH, Barrionuevo P et al. Incidence of adverse events in paediatric procedural sedation in the emergency department: a systematic review and meta-analysis. *BMJ Open* 2016; **6**:e011384.
48. Monroe KK, Beach M, Reindel R, Badwan L, Couloures KG, Hertzog JH et al. Analysis of procedural sedation provided by pediatricians. *Pediatr Int* 2013;**55**:17–23.
49. Bhatt M, Johnson DW, Chan J, Taljaard M, Barrowman N, Farion KJ, et al; Sedation Safety Study Group of Pediatric Emergency Research Canada (PERC). Risk factors for adverse events in emergency department procedural sedation for children. *JAMA Pediatr* 2017;**171**:957–64.
50. Krmptovic K, Rieder MJ, Rosen D. Recommendations for procedural sedation in infants, children, and adolescents. *Paediatr Child Health* 2021;**26**:128.
51. Staudt GE, Eagle SS. Anesthetic considerations for patients with Williams syndrome. *J Cardiothorac Vasc Anesth* 2021;**35**:176–86.
52. Rappaport B, Mellon RD, Simone A, Woodcock J. Defining safe use of anesthesia in children. *N Engl J Med* 2011;**364**:1387–90.
53. Mason KP, Zurakowski D, Zucker EJ, Tracy DA, Lee EY. Image quality of thoracic 64-MDCT angiography: imaging of infants and young children with or without general anesthesia. *Am J Roentgenol* 2013;**200**:171–6.
54. Boone JM, Hernandez AM. The effect of iodine-based contrast material on radiation dose at CT: it's complicated. *Radiology* 2017;**283**:624–627.
55. Sahbaee P, Abadi E, Segars WP, Marin D, Nelson RC, Samei E. The effect of contrast material on radiation dose at CT: part II. A Systematic Evaluation across 58 Patient Models. *Radiology* 2017;**283**:749–757.
56. Cademartiri F, Van der Lugt A, Luccichenti G, Pavone P, Krestin GP. Parameters affecting bolus geometry in CTA: a review. *J Comput Assist Tomogr* 2002;**26**:598–567.
57. Maloney E, Iyer RS, Phillips GS, Menon S, Lee JJ, Callahan MJ. Practical administration of intravenous contrast media in children: screening, prophylaxis, administration and treatment of adverse reactions. *Pediatr Radiol* 2019;**49**:433–47.
58. Callahan MJ, Servaes S, Lee EY, Towbin AJ, Westra SJ, Frush DP. Practice patterns for the use of iodinated IV contrast media for pediatric CT studies: a survey of the Society for Pediatric Radiology. *AJR Am J Roentgenol* 2014;**202**:872–9.
59. Callahan MJ, Poznauskis L, Zurakowski D, Taylor GA. Nonionic iodinated intravenous contrast material-related reactions: incidence in large urban children's hospital-retrospective analysis of data in 12 494 patients. *Radiology* 2009;**250**:674–81.
60. Dillman JR, Strouse PJ, Ellis JH, Cohan RH, Jan SC. Incidence and severity of acute allergic-like reactions to IV nonionic iodinated contrast material in children. *AJR Am J Roentgenol* 2007;**188**:1643–7.
61. Wienbeck S, Fischbach R, Kloska SP, Seidensticker P, Osada N, Heindel W et al. Prospective study of access site complications of automated contrast injection with peripheral venous access in MDCT. *Am J Roentgenol* 2010;**195**:825–9.
62. Plumb AAO, Murphy G. The use of central venous catheters for intravenous contrast injection for CT examinations. *Br J Radiol* 2011;**84**:197–203.
63. Mahani GM, Agarwal PP, Rigsby CK, Lu JC, Dehkordy SF, Wright RA et al. CT for assessment of thrombosis and pulmonary embolism in multiple stages of single-ventricle palliation: challenges and suggested protocols. *Radiographics* 2016; **36**:1273–84.
64. Masuda T, Funama Y, Nakaura T, Sato T, Tahara M, Matsumoto Y et al. Usefulness of diluted contrast medium for test-scanning of infants scheduled for contrast-enhanced cardiovascular computed tomography angiography. *Br J Radiol* 2019;**92**:2018–23.
65. Ghoshhajra BB, Lee AM, Engel LC, Celeng C, Kalra MK, Brady TJ et al. Radiation dose reduction in pediatric cardiac computed tomography: experience from a tertiary medical center. *Pediatr Cardiol* 2014;**35**:171–9.
66. Herzog C, Mulvihill DM, Nguyen SA, Savino G, Schmidt B, Costello P et al. Pediatric cardiovascular CT angiography: radiation dose reduction using automatic anatomic tube current modulation. *Am J Roentgenol* 2008;**190**:1232–4.
67. Jean-François P. Dual-source computed tomography in paediatric congenital heart disease patients – combination of low-kilovoltage protocols and ultravist injection. *Interv Cardiol Rev* 2008;**3**:16.
68. Han BK, Grant KLR, Garberich R, Sedlmair M, Lindberg J, Lesser JR. Assessment of an iterative reconstruction algorithm (SAFIRE) on image quality in pediatric cardiac CT datasets. *J Cardiovasc Comput Tomogr* 2012;**6**:200–4.
69. Miéville FA, Gudinchet F, Rizzo E, Ou P, Brunelle F, Bochud FO et al. Paediatric cardiac CT examinations: impact of the iterative reconstruction method ASiR on image quality - preliminary findings. *Pediatr Radiol* 2011;**41**:1154–64.
70. Singh R, Wu W, Wang G, Kalra MK. Artificial intelligence in image reconstruction: the change is here. *Phys Med* 2020;**79**:113–125.
71. Siegel MJ, Ramirez-Giraldo JC, Hildebolt C, Bradley D, Schmidt B. Automated low-kilovoltage selection in pediatric computed tomography angiography: phantom study evaluating effects on radiation dose and image quality. *Invest Radiol* 2013;**48**:584–9.
72. Zhang LJ, Qi L, Wang J, Tang CX, Zhou CS, Ji XM et al. Feasibility of prospectively ECG-triggered high-pitch coronary CT angiography with 30 mL iodinated contrast agent at 70 kVp: initial experience. *Eur Radiol* 2014;**24**:1537–46.
73. Flohr TG, Leng S, Yu L, Allmendinger T, Bruder H, Petersilka M et al. Dual-source spiral CT with pitch up to 3.2 and 75 ms temporal resolution: image reconstruction and assessment of image quality. *Med Phys* 2009.
74. Goo HW, Park SH. Semiautomatic three-dimensional CT ventricular volumetry in patients with congenital heart disease: agreement between two methods with different user interaction. *Int J Cardiovasc Imaging* 2015;**31**:223–232.
75. Lewis MA, Pascoal A, Keevil SF, Lewis CA. Selecting a CT scanner for cardiac imaging: the heart of the matter. *Br J Radiol* 2016;**89**(1065):20160376.
76. Akhlaghi P, Miri-Hakimabad H, Rafat-Motavalli L. Effects of shielding the radiosensitive superficial organs of ORNL pediatric phantoms on dose reduction in computed tomography. *J Med Phys* 2014;**39**:238.
77. Geleijns J, Salvadó Artells M, Veldkamp WJH, López Tortosa M, Calzado Cantera A. Quantitative assessment of selective in-plane shielding of tissues in computed tomography through evaluation of absorbed dose and image quality. *Eur Radiol* 2006;**16**:2334–2340.
78. McCollough CH, Wang J, Berland LL. Bismuth shields for CT dose reduction: do they help or hurt? *J Am Coll Radiol* 2011;**8**:878–9.
79. Isma'eel H, Hamirani YS, Mehrinfar R, Mao S, Ahmadi N, Larijani V et al. Optimal phase for coronary interpretations and correlation of ejection fraction using late-diastole and end-diastole imaging in cardiac computed tomography angiography: implications for prospective triggering. *Int J Cardiovasc Imaging* 2009;**25**:739–749.
80. Stolzmann P, Goetti R, Baumüller S, Plass A, Falk V, Scheffel H et al. Prospective and retrospective ECG-gating for CT coronary angiography perform similarly accurate at low heart rates. *Eur J Radiol* 2011;**79**:85–91.
81. Boutis K, Cogollo W, Fischer J, Freedman SB, David GB, Thomas KE. Parental knowledge of potential cancer risks from exposure to computed tomography. *Pediatrics* 2013;**132**:305–311.
82. Einstein AJ, Berman DS, Min JK, Hendel RC, Gerber TC, Carr JJ et al. Patient-centered imaging: Shared decision making for cardiac imaging procedures with exposure to ionizing radiation. *J Am Coll Cardiol* 2014;**63**:1480–1489.
83. Pearce MS, Salotti JA, Little MP, McHugh K, Lee C, Kim KP et al. Radiation exposure from CT scans in childhood and subsequent risk of leukaemia and brain tumours: a retrospective cohort study. *Lancet* 2012;**380**:499–505.