

 Open access • Journal Article • DOI:10.1111/J.1600-0501.2009.01717.X

Randomized-controlled clinical trial of customized zirconia and titanium implant abutments for single-tooth implants in canine and posterior regions: 3-year results.

— [Source link](#) 

[Anja Zembic](#), [Irena Sailer](#), [Ronald E. Jung](#), [Christoph H. F. Hämmerle](#)

Institutions: [University of Zurich](#)

Published on: 01 Aug 2009 - [Clinical Oral Implants Research](#) (Clin Oral Implants Res)

Topics: [Dental Abutments](#), [Osseointegration](#) and [Implant](#)

Related papers:

- [Experimental zirconia abutments for implant-supported single-tooth restorations in esthetically demanding regions: 4-year results of a prospective clinical study.](#)
- [Randomized controlled clinical trial of customized zirconia and titanium implant abutments for canine and posterior single-tooth implant reconstructions: preliminary results at 1 year of function](#)
- [A systematic review of the performance of ceramic and metal implant abutments supporting fixed implant reconstructions.](#)
- [Bacterial Adhesion on Commercially Pure Titanium and Zirconium Oxide Disks: An In Vivo Human Study](#)
- [In vitro color changes of soft tissues caused by restorative materials.](#)

Share this paper:    

View more about this paper here: <https://typeset.io/papers/randomized-controlled-clinical-trial-of-customized-zirconia-52shyj1k1a>



University of Zurich
Zurich Open Repository and Archive

Winterthurerstr. 190
CH-8057 Zurich
<http://www.zora.uzh.ch>

Year: 2009

Randomized-controlled clinical trial of customized zirconia and titanium implant abutments for single-tooth implants in canine and posterior regions: 3-year results

Zembic, A; Sailer, I; Jung, R E; Hämmerle, C H F

Zembic, A; Sailer, I; Jung, R E; Hämmerle, C H F (2009). Randomized-controlled clinical trial of customized zirconia and titanium implant abutments for single-tooth implants in canine and posterior regions: 3-year results. *Clinical Oral Implants Research*, 20:Epub ahead of print.

Postprint available at:
<http://www.zora.uzh.ch>

Posted at the Zurich Open Repository and Archive, University of Zurich.
<http://www.zora.uzh.ch>

Originally published at:
Clinical Oral Implants Research 2009, 20:Epub ahead of print.

Randomized-controlled clinical trial of customized zirconia and titanium implant abutments for single-tooth implants in canine and posterior regions: 3-year results

Abstract

Objectives: The aim was to test whether or not zirconia abutments exhibit the same survival and technical / biological outcome as titanium abutments. **Material and methods:** Twenty-two patients receiving 40 single-tooth implants in canine and posterior regions were included. The implant sites were randomly assigned to 20 zirconia and 20 titanium abutments. All-ceramic and metal-ceramic crowns were fabricated. At baseline, 6, 12 and 36 months, the reconstructions were examined for technical and biological problems. Probing pocket depth (PPD), plaque control record (PCR) and bleeding on probing (BOP) were assessed at abutments (test) and analogous contralateral teeth (control). Standardized radiographs of the implants were made and the bone level (BL) was measured referring to the implant shoulder on mesial (mBL) and distal sides (dBL). The difference of color (DeltaE) of the peri-implant mucosa and the gingiva of control teeth was assessed with a spectrophotometer. The data were statistically analyzed with Mann-Whitney Rank and Student's unpaired t-tests. **Results:** Eighteen patients with 18 zirconia and 10 titanium abutments were examined at a mean follow-up of 36 months (range 31.5-53.3 months). No fracture of an abutment or loss of a reconstruction was found. Hence, both exhibited 100% survival. At two metal-ceramic crowns supported by titanium abutments chipping of the veneering ceramic occurred. No difference of the biological outcome of zirconia and titanium abutments was observed: PPD (3.2 +/- 1 mm, mPPD(Ti) 3.4 +/- 0.5 mm), PCR (0.1 +/- 0.2, mPCR(Ti) 0.1 +/- 0.2) and BOP (0.4 +/- 0.4, mBOP(Ti) 0.2 +/- 0.3). Furthermore, the BL was similar at implants supporting zirconia and titanium abutments (1.7 +/- 1, 1.6 +/- 1; mBL(Ti) 2 +/- 1, dBL(Ti) 2.1 +/- 1). Both, zirconia and titanium abutments induced a similar amount of discoloration of the mucosa compared with the gingiva at natural teeth (9.3 +/- 3.8, DeltaE(Ti) 6.8 +/- 3.8). **Conclusions:** At 3 years, zirconia and titanium abutments exhibited same survival and technical, biological and esthetical outcomes. To cite this article: Zembic A, Sailer I, Jung RE, Hämmerle CHF. Randomized-controlled clinical trial of customized zirconia and titanium implant abutments for single-tooth implants in canine and posterior regions: 3-year results. Clin. Oral Impl. Res. xx, 2009; 000-000.

Randomized controlled clinical trial of customized zirconia and titanium implant abutments for single-tooth implants in canine and posterior regions: 3-year results.

Anja Zembic, Dr Med Dent^a

Irena Sailer, Dr Med Dent^b

Ronald Ernst Jung, PD Dr Med Dent^b

Christoph Hans Franz Hämmerle, Prof Dr Med Dent^d

^aPostgraduate Student, Department of Fixed and Removable Prosthodontics and Dental Material Science, Center for Dental and Oral Medicine, University of Zurich, Switzerland

^bAssistant Professor, Department of Fixed and Removable Prosthodontics and Dental Material Science, Center for Dental and Oral Medicine, University of Zurich, Switzerland

^cProfessor and Chairman, Department of Fixed and Removable Prosthodontics and Dental Material Science, Center for Dental and Oral Medicine, University of Zurich, Switzerland

Correspondence to: Dr. Irena Sailer, Department of Fixed and Removable Prosthodontics and Dental Material Science, Center for Dental and Oral Medicine, University of Zurich, Plattenstr. 11, 8032 Zurich, Switzerland. Tel: +41 44 634 32 52, Fax: +41 44 634 43 05
irena.sailer@zzmk.uzh.ch

Running title: Randomized controlled clinical trial of zirconia and titanium implant abutments for posterior single-tooth replacement.

Keywords: implant abutments, ceramic abutments, titanium, zirconia, survival

ABSTRACT

Objectives: The aim was to test whether or not zirconia abutments exhibit the same survival and technical/biological outcome as titanium abutments.

Material and Methods: Twenty-two patients receiving 40 single tooth implants in canine and posterior regions were included. The implant sites were randomly assigned to 20 zirconia and 20 titanium abutments. All-ceramic and metal-ceramic crowns were fabricated. At baseline, 6, 12 and 36 months, the reconstructions were examined for technical and biological problems. Probing pocket depth(PPD), plaque control record(PCR) and bleeding on probing(BOP) were assessed at abutments(test) and analogous contralateral teeth(control). Standardized radiographs of the implants were made and the bone level(BL) was measured referring to the implant shoulder on mesial(mBL) and distal sides(dBL). The difference of color(ΔE) of the peri-implant mucosa and the gingiva of control teeth was assessed with a spectrophotometer. The data were statistically analyzed with Mann-Whitney Rank and Student's unpaired t-tests.

Results: Eighteen patients with 18 zirconia and 10 titanium abutments were examined at a mean follow-up of 36 months (range 31.5–53.3 months). No fracture of an abutment or loss of a reconstruction was found. Hence, both exhibited 100% survival. At 2 metal-ceramic crowns supported by titanium abutments chipping of the veneering ceramic occurred. No difference of the biological outcome of zirconia and titanium abutments was observed: PPD (mean PPD_{ZrO₂} 3.2±1.0 mm, mPPD_{Ti} 3.4±0.5 mm), PCR (mPCR_{ZrO₂} 0.1±0.2, mPCR_{Ti} 0.1±0.2) and BOP (mBOP_{ZrO₂} 0.4±0.4, mBOP_{Ti} 0.2±0.3). Furthermore, the BL was similar at implants supporting zirconia and titanium abutments (mBL_{ZrO₂} 1.7±1.0, dBL_{ZrO₂} 1.6±1.0; mBL_{Ti} 2.0±1.0, dBL_{Ti} 2.1±1.0). Both, zirconia and titanium abutments induced a similar amount of discoloration of the mucosa compared to the gingiva at natural teeth (ΔE_{ZrO_2} 9.3±3.8, ΔE_{Ti} 6.8±3.8).

Conclusions: At 3 years, zirconia and titanium abutments exhibited same survival and technical, biological and esthetical outcomes.

INTRODUCTION

Customized implant abutments are increasingly applied for the fabrication of implant-borne reconstructions aimed at imitating the natural situation (Marchack 1996; Jemt 1998; Henriksson & Jemt 2003). These abutments are individually shaped according to the anatomical needs of the respective implant site (Marchack 1996; Jemt 1998; Henriksson & Jemt 2003).

Nowadays, customized abutments can be fabricated out of various materials like metals or ceramics. Each type of material has its benefits and shortcomings. Metals like titanium offer excellent material stability. They are very resistant towards distortion. In fact, the results of clinical studies revealed excellent survival rates of reconstructions supported by titanium abutments (Andersson et al. 1995). Until today, titanium abutments are considered the “gold-standard” for longevity of implant borne reconstructions in all regions of the jaw. One major drawback of titanium abutments is that their dark grey color can cause a greyish discoloration of the peri-implant mucosa impairing the esthetic result of implant reconstructions (Jung et al. 2007; Park et al. 2007).

As an alternative ceramic abutments made out of the high-strength ceramics alumina and zirconia can be used in esthetically demanding situations (Prestipino & Ingber 1993a, b; Wohlwend et al. 1996). The esthetic benefit of ceramic abutments over metal abutments has been well documented in a recent clinical study (Jung et al 2008a). The shortcoming of ceramic materials, however, is their brittleness (Belser et al. 2004). This specific material property of ceramic leads to less resistance towards tensile forces and micro-structural defects. High tensile forces or flaws within the ceramic increase the risk for a fracture during function. Whether or not a fracture will occur is predominately influenced by the fracture toughness of the ceramic (Seghi et al. 1995).

Among all dental ceramics zirconia exhibits the highest fracture toughness (Lüthy 1996). Clinical studies indicate that reconstructions can be fabricated with zirconia frameworks either on teeth or on implants with good clinical success. No zirconia abutment fractures have been reported in studies of implant single-crowns in anterior and premolar regions during a maximum of 4 years of function (Glauser et al. 2004, Canullo 2007). In contrast, at 1 year 7% fractures of alumina abutments have been reported when applied in the same type of indications (Andersson et al. 2001). The promising performance of zirconia is supported by studies with zirconia as framework material for tooth-borne reconstructions even in areas with high loading. As an example, after 3 to 5 years of loading posterior fixed dental prostheses

(FDPs) with zirconia frameworks showed excellent survival rates ranging from of 97.8% to 100% (Raigrodsky et al. 2006; Sailer et al. 2007; Tinschert et al. 2008; Molin & Karlsson 2008). In conclusion, this zirconia ceramic offers a combination of both sufficient strength for the application in regions with high occlusal loading and good esthetic properties. Unlike other ceramics zirconia may be suitable also for implant abutments in areas with high functional loading, like the canine and posterior regions. Comparative clinical studies, however, are needed to support this assumption.

The aim of this randomized controlled clinical trial was to test whether or not customized zirconia abutments exhibit the same survival and complication rates as customized titanium abutments in areas in canine and posterior regions.

MATERIAL AND METHODS

Patients and implants

Twenty-two consecutively recruited patients were included in this study (14 females, 8 males). They were in need of 40 fixed implant-supported crowns. The missing teeth comprised canines, premolars and molars in both jaws. The mean age of the patients was 41.3 with a standard deviation of ± 18.0 years. The inclusion/exclusion criteria for the patients have previously been described in detail (Sailer et al., accepted for publication). Eight patients were smokers.

The patients were randomly assigned to a test and control group during the time between implant placement and abutment connection. A randomization table was kept by an independent body, where the investigators received the assignment of the respective sites to either test or control groups. The test group consisted of 20 single tooth implants receiving customized zirconia abutments (Procera, Nobel Biocare AB, Carolinsk, Sweden) for the support of all-ceramic crowns (ACC). The control group consisted of 20 single tooth implants receiving customized titanium abutments (Procera, Nobel Biocare, Carolinsk, Sweden) for the support of metal-ceramic crowns (MCC).

All patients received implants with a regular platform (Brånemark RP, Nobel Biocare AB, Gothenburg, Sweden). Implants were inserted according to a standard 2-stage protocol (Adell 1985). Connective tissue grafts were placed in 5 patients receiving 6 implants with a lack of buccal soft tissue volume. Three grafted sites were located at implant sites receiving zirconia abutments, whereas the other three grafts were placed at implants supporting titanium abutments. Second stage surgery (abutment connection) was performed 4-6 months after implant placement.

Prosthetic procedure

The prosthetic treatment phase was previously described in detail (Sailer et al., accepted for publication). In brief, the fabrication of the customized zirconia and titanium abutments was performed by means of a CAD/CAM-system (Procera, Nobel Biocare AB, Carolinsk, Sweden). The abutments were fixed onto the implants with a torque of 32 Ncm.

All-ceramic (ACC) and metal-ceramic (MCC) crowns were fabricated. Zirconia abutments supported ACC, except in one case in which a MCC was made. The frameworks for the ACC were either fabricated out of glass-ceramic or out of one of two high-strength ceramics (alumina, zirconia). All titanium abutments supported MCC.

All except 2 crowns were cemented on the respective abutments. One of two resin cements (Panavia 21 TC, Kuraray, Okayama, Japan or RelyX Unicem, 3M Espe, Seefeld, Germany) or a glass-ionomer cement (Ketac Cem, 3M Espe, Seefeld, Germany) was used for cementation. The remaining two crowns were screw-retained with 32 Ncm of torque. Both were ACC supported by zirconia abutments.

Clinical examinations

The follow-up examinations comprised clinical and radiographic assessments of the implant reconstructions and were performed at crown insertion (baseline), 6, 12 and 36 months of loading.

Technical examination

The abutments and reconstructions were evaluated for fractures. The abutments and crowns were checked for loss of retention (abutment screw fracture or loosening, fracture of cement seal). Furthermore, the crowns were examined for chipping of the veneering ceramic.

Biological examination

The following biological parameters were assessed at four sites (mesial, buccal, distal, oral) of the implants and adjacent control teeth: Probing pocket depth (PPD), Plaque control record (PCR) (O'Leary et al. 1972) and Bleeding on probing (BOP).

Probing pocket depth (PPD) was measured from the mucosal/gingival margin to the bottom of the probeable pocket in millimeters using a periodontal probe. Plaque control record (PCR) and Bleeding on probing (BOP) were noted as present or absent.

Radiographs of the implants were made at baseline and at each follow-up visit using the long-cone paralleling technique (Updegrave 1951). For the evaluation of the marginal bone level (BL) the radiographs were digitized and the level of the crestal bone was assessed at all time points. The distance between the implant shoulder (reference) and the most coronal bone-to-implant contact was measured in 0.1 mm increments mesially and distally by 2 independent examiners (Fig. 1). The standardized distance between three implant threads (1.8 mm) was used for the calibration and determination of the exact magnification of the images. In case of

a difference between the two measurements of 0.5 mm, the mean value was used. In case of a difference > 0.5 mm, the radiographs were reexamined by both examiners and the results discussed until a consensus was found (measurements in accordance with: Rodoni et al. 2005).

Esthetical examination

The color of the peri-implant mucosa and the gingiva of analogous, natural control teeth were assessed by means of a spectrophotometer (Spectroshade, MHT, Niederhasli, Switzerland). The color assessments were performed 1 mm below the mucosal margin as previously described (Sailer et al., accepted for publication). The color differences ΔE of the implant and the tooth sites were calculated. The critical ΔE threshold for intra-oral color distinction has previously been demonstrated to be at 3.7 (Johnston & Kao 1989). The soft tissue thickness was recorded in the region of esthetic assessment both at implants and teeth using an endodontic file (ISO #20) with a rubber stop.

Finally, the height of the papillae was assessed at the mesial and distal site of the implant reconstructions by means of a published index (Jemt 1997).

Statistical analysis

The data was analyzed descriptively. Survival of the implant abutments and crowns were assessed. The technical, biological and esthetical outcomes of the test and control group zirconia and titanium abutments were compared. Bone levels were compared between the two groups at the various time points of examination. In addition, the bone level changes within each group were analyzed over time.

Technical, biological and esthetical outcomes of the test and control group were analyzed by means of Student's unpaired t-Test and Mann-Whitney Rank Test. The level of statistical significance was set at $p < 0.05$.

RESULTS

Eighteen patients (10 women, 8 men) with 18 zirconia and 10 titanium abutments could be examined at a mean follow-up period of 36 months (range 31.5 – 53.3 months).

Two of the initially included patients with 1 zirconia and 8 titanium abutments had to be withdrawn from the study. The initial treatment plan had been changed to splinted crowns instead of single-crowns.

Two more patients were not available for the 3-year follow up. One patient with 1 titanium abutment supporting a MCC replacing a premolar was not identifiable despite numerous attempts to contact her. The second patient with 1 zirconia and 1 titanium abutment, both replacing molars, had moved.

The 18 examined zirconia abutments had been reconstructed with 17 ACC and 1 MCC. These crowns were cemented with resin cement (11 crowns) and glass ionomer cement (5 crowns). Two of the crowns were screw-retained. The titanium abutments were supporting 10 MCC, all cemented with a glass-ionomer cement.

Eleven of the crowns were located in the maxilla and 17 in the mandible.

The implants in the group with zirconia abutments replaced 2 canines, 11 premolars and 5 molars. The ones in the group with titanium abutments replaced 2 canines and 8 premolars. All implants were successfully osseointegrated, resulting in a 100% survival rate for the implants in both groups (Fig. 2 a-d, 3 a-d).

Technical evaluation

No fracture of an abutment or a crown was found in either group. Furthermore, no loosening of an abutment screw or loss of crown retention was observed. Hence, the survival rate of the abutments as well as the crowns was 100% in both groups.

No chipping of the veneering ceramic occurred at the crowns supported by zirconia abutments. In contrast, minor chipping was found at two MCC supported by titanium abutments (Sailer et al., accepted for publication).

Biological evaluation

No biological complications were found at zirconia and titanium abutments. The comparison of the biological parameters (PPD, PCR, BOP, BL) of the sites with zirconia and titanium abutments revealed no statistical differences (Table 1). Yet, higher values of the mean PPDs were found at implants compared to neighboring teeth. The same amount of plaque (mean

PCR) was found at the abutments and the control teeth. Bleeding occurred with similar frequencies at implants and teeth (Table 1).

No significant difference of the mean mesial and distal bone level (mMBL, mDBL) was found at the implants supporting zirconia and titanium abutments at the 3-year follow-up visit (Table 2). There was either no or just a slight decrease of the bone levels from baseline to 3 years in both groups.

Esthetical evaluation

- Spectrophotometric color evaluation

Both zirconia and titanium induced a visible change of the mucosal color compared to the gingival of natural teeth (ΔE_{ZrO_2} 9.3 ± 3.8 , ΔE_{Ti} 6.8 ± 3.8) (Table 3). The amount of discoloration induced by zirconia and titanium abutments was not significantly different.

- Soft tissue thickness

No difference of the mean mucosal thickness was found at zirconia and titanium abutments (m thickness_{ZrO₂} 1.9 ± 0.8 mm; m thickness_{Ti} 1.7 ± 0.4 mm).

The overall mean soft tissue thickness at implant-supported crowns averaged 1.8 ± 0.7 mm and was slightly higher than the mean gingival thickness at the control teeth (1.5 ± 0.9 mm).

- Papilla Index

No significant difference of the mean papilla height (mP) was found at mesial and distal locations at the zirconia and titanium abutments (mesial: mP_{ZrO₂} 2.4 ± 0.9 , mP_{Ti} 2.0 ± 1.1 ; distal: mP_{ZrO₂} 1.6 ± 1.2 , mP_{Ti} 1.5 ± 1.0).

DISCUSSION

Both zirconia and titanium customized abutments exhibited a 100% survival rate in regions with high functional load at 3 years. Furthermore, no loss of implant crowns occurred rendering a survival rate for all-ceramic and for metal-ceramic crowns of 100%. Finally, no technical complications occurred at zirconia-supported crowns and only little problems were found at titanium-supported crowns.

The excellent performance of zirconia abutments and all-ceramic implant-borne single-crowns has been shown in an earlier study (Glauser et al. 2004). In that clinical study a 100% survival rate of the zirconia abutments was found at 4 years of function (Glauser et al. 2004). More than 70% of the replaced teeth comprised incisors and canines, whereas only one third of the replaced teeth included premolars. The results of the present study show, however, that the excellent outcome of zirconia abutments is not limited to anterior regions with lower loading forces, but can also be obtained in posterior regions. In the present study, mainly posterior teeth (68% premolars, 18% molars) were replaced and both zirconia and titanium abutments exhibited 100% survival. Yet, the observation period is still rather short and a longer follow-up is needed for final conclusions.

It should be kept in mind that it may not be possible to extrapolate these short-term data to the long-term performance of zirconia based reconstructions. Zirconia like all ceramics is prone to aging inducing a decrease in the physical properties of the material. In vitro studies have demonstrated a 50% decrease of the fracture toughness of zirconia during a simulated 10-year aging process in a humid environment (Studart et al. 2007).

In the present study only a small amount of technical complications occurred at the custom-made abutments. No fractures or loosening of reconstructions were found. Chipping of the veneering ceramic occurred at 2 metal-ceramic crowns, whereas no chippings occurred at all-ceramic crowns. Fractures of veneering porcelain are a common technical complication at implant supported single crowns and FDPs (Brägger et al. 2005, Jung et al. 2008b). A smaller rate for chipping of veneering ceramic (7.1%) was reported in a clinical study analyzing single-implant metal-ceramic crowns supported by titanium abutments (Hall et al. 2007). Another investigation reporting on all-ceramic reconstructions supported by zirconia abutments exhibited no technical complications (Henriksson & Jemt 2003). In that study, however, no molar reconstructions were included.

One frequently reported technical complication of implant-borne single-crowns was screw-loosening occurring in 4-43% during 4 years (for review see: Jung et al. 2008b). Absence of

rotation at the implant-abutment interface was a crucial factor for the maintenance of a stable abutment screw joint in numerous in-vitro studies (Binon 1995, 1996; Binon & McHugh 1996). It was suggested that the fit between implant and abutment should permit less than 5° of rotational freedom (Binon 1996; Binon & McHugh 1996). In a recent study customized zirconia and titanium abutments, fabricated with the same CAD/CAM procedure as in the present study, exhibited excellent fit with less than 3° rotational freedom (Vigolo et al. 2006). Furthermore, in the present study all abutments were tightened with a controlled torque of 32 Ncm. Tightening of implant components with a controlled torque of 20-30 Ncm was demonstrated to reduce the risk of screw loosening (Jorneus et al. 1992; McGlumphy et al. 1998). These factors may have contributed to the excellent technical outcome of both abutments types in the current study, where no screw loosening occurred.

Besides the excellent technical results, the biological reaction to the zirconia and titanium abutments was very good. No differences were found regarding the amount of plaque at the abutments and natural control teeth. Both zirconia and titanium abutments exhibited the same degree of plaque accumulation. This observation is not in accordance with the findings of laboratory studies of the bacterial adhesion on zirconia and titanium. In one study using zirconia and titanium disks significantly less adhesion and accumulation of bacteria was found on zirconia compared with titanium disks (Rimondini et al. 2002; Scarano et al. 2004). The favorable results for both abutment types in the present study might be due to the good oral hygiene of the patients.

Slightly more bleeding on probing was found at the reconstructions supported by zirconia abutments. This observation has already been made at one year of clinical follow-up (Sailer et al., accepted for publication). Whether or not this finding is related to a different biological response to the applied materials is difficult to evaluate. Unfortunately, the zirconia abutments in this study supported crowns made out of different ceramic materials. Furthermore, the crowns were cemented with different kinds of cements.

In the present study the bone level remained stable at all implants between the first and the third year of function. In addition, no significant difference of the bone level was found at implants supporting zirconia abutments compared to the ones supporting titanium abutments. Hence, the zirconia abutments did not exert any negative effect on the bone integration of the implants. In pre-clinical animal studies titanium and zirconia were proved to be similarly biocompatible (Abrahamsson et al. 1998; Kohal et al. 2004). In contrast to the clinical findings of the present study and the pre-clinical observations mentioned above, one clinical study reported slightly more bone loss at implants supporting titanium abutments than at

implants supporting alumina abutments (0.4 mm vs. 0.2 mm) (Andersson et al. 1999). There is a clear need for more comparative long-term clinical studies comparing zirconia and titanium abutments in large patient populations.

The esthetical evaluation of the present study revealed, that both abutment types led to a visible discoloration of the marginal mucosa compared to the gingiva of analogous teeth ($\Delta E > 3.7$, Johnston & Kao 1989). This finding has already been observed at the 1-year recall and remained unchanged at the 3-year observation. Furthermore, a slight increase in the papilla height was observed at mesial sites in the present study. The improvement of the papilla fill after implant-crown placement is in agreement with previous reports in the literature (Jemt 1999; Chang et al. 1999; Choquet et al. 2001; Henriksson & Jemt 2004; Cardaropoli et al. 2006).

CONCLUSION

Customized zirconia and titanium abutments for single-implant crowns exhibited excellent survival rates at 3 years of function. Both types of abutments exhibited very good technical and biological outcomes. Esthetically, both abutment materials induced the same amount of soft tissue discoloration. More randomized controlled clinical trials of zirconia and titanium abutments and larger patient groups are necessary.

Acknowledgements

The authors thank Dr. Giorgio Menghini for the statistical analysis of the data and Dr. Ameen Khraisat for his help with the radiographical evaluation of bone levels.

Nobel Biocare AB, Gothenburg, Sweden, provided the abutments for this study.

REFERENCES

- Abrahamsson, I., Berlundh, T., Glantz, P.-O. & Lindhe, J., (1998) The mucosal attachment at different abutments. An experimental study in dogs. *Journal of Clinical Periodontology* **25**: 721-727.
- Adell, R. (1985) Tissue integrated prostheses in clinical dentistry. *International Dental Journal* **35**: 259-265.
- Andersson, B., Odman, P., Lindvall, A.M. & Lithner, B., (1995) Single-tooth restorations supported by osseointegrated implants: Results and experiences from a prospective study after 2 to 3 years. *International Journal of Oral and Maxillofacial Implants* **10**: 702-711.
- Andersson, B., Schärer, P., Simion, M. & Bergström C. (1999) Ceramic Implant Abutments Used for Short-Span Fixed Partial Dentures: A Prospective 2-Year Multicenter Study. *International Journal of Prosthodontics* **12**: 318-324.
- Andersson, B., Taylor, A., Lang, B.R., Scheller, H., Schärer, P., Sorensen, J.A. & Tarnow, D. (2001) Alumina ceramic implant abutments used for single-tooth replacement: A prospective 1- to 3- year mulitcenter study. *International Journal of Prosthodontics* **14**: 432-438.
- Belser, U.C., Schmid, B., Higginbottom, F. & Buser, D. (2004) Outcome Analysis of Implant Restorations Located in the Anterior Maxilla: A Review of the Recent Literature. *International Journal of Oral and Maxillofacial Implants* **19**: 30-42.
- Binon, P.P., (1995) Evaluation of machining accuracy and consistency of selected implant standard abutments and laboratory analogues. *International Journal of Prosthodontics* **8**: 162-178.
- Binon, P.P., (1996) The effect of implant/abutment hexagonal misfit on screw joint stability. *International Journal of Prosthodontics* **9**: 149-160.
- Binon, P.P. & McHugh, M.J., (1996) The effect of eliminating implant/abutment rotational misfit on screw joint stability. *International Journal of Prosthodontics* **9**: 511-519.

Brägger, U., Karoussis, I., Persson, R., Pjetursson, B., Salvi, G. & Lang, N.P. (2005) Technical and biological complications/failures with single crowns and fixed partial dentures on implants: 1 10-year prospective cohort study. *Clinical Oral Implants Research* **16**: 326-34.

Canullo, L. (2007) Clinical outcome of customized zirconia abutments for single-implant restorations. *International Journal of Prosthodontics* **20**: 489-93.

Cardaropoli, G., Lekholm, U. & Wennstrom, J.L., (2006) Tissue alterations at implant-supported single-tooth replacements: A 1-year prospective clinical study. *Clinical Oral Implants Research* **17**: 165-171.

Chang, M., Wennstrom, J.L., Odman, P. & Andersson, B., (1999) Implant supported single-tooth replacements compared to contralateral natural teeth. Crown and soft tissue dimensions. *Clinical Oral Implants Research* **10**: 185-194.

Choquet, V., Hermans, M., Adriaenssens, P., Daelemans, P., Tarnow, D.P. & Malevez, C., (2001) Clinical and radiographic evaluation of the papilla level adjacent to single-tooth dental implants. A retrospective study in the maxillary anterior region. *Journal of Periodontology* **72**: 1364-1371.

Glauser, R., Sailer, I., Wohlwend, A., Studer, S., Schibli, M. & Schärer, P. (2004) Experimental zirconia abutments for implant-supported single-tooth restorations in esthetically demanding regions: 4-year results of a prospective clinical study. *International Journal of Prosthodontics* **17**: 285-90.

Hall, J.A.G., Payne, A.G.T., Purton, D.G., Torr, B., Duncan, W.J. & De Silva, R.K. (2007) Immediately restored, single-tapered implants in the anterior maxilla: prosthodontic and aesthetic outcomes after 1 year. *Clinical Implant Dentistry and Related Research* **9**: 34-45.

Henriksson, K. & Jemt, T. (2003) Evaluation of custom-made Procera ceramic abutments for single-implant tooth replacement: A prospective 1-year follow-up study. *International Journal of Prosthodontics* **16**: 626-630.

Henriksson, K. & Jemt, T., (2004) Measurements of soft tissue volume in association with single-implant restorations: A 1-year comparative study after abutment connection surgery. *Clinical Implant Dentistry and Related Research* **6**: 181-189.

Jemt, T. (1997) Regeneration of gingival papillae after single-implant treatment. *International Journal of Periodontics and Restorative Dentistry* **17**: 326-333.

Jemt, T., (1998) Customized titanium single-implant abutments: 2-year follow-up pilot study. *International Journal of Prosthodontics* **11**: 312-316.

Jemt, T., (1999) Restoring the gingival contour by means of provisional resin crowns after single-implant treatment. *International Journal of Periodontics and Restorative Dentistry* **19**: 20-29.

Johnston, W.M. & Kao, E.C. (1989) Assessment of Appearance Match by Visual Observation and Clinical Colorimetry. *Journal of Dental Research* **68**: 819-822.

Jorneus, L., Jemt, T. & Carlsson, L., (1992) Loads and designs of screw joints for single crowns supported by osseointegrated implants. *International Journal of Oral and Maxillofacial Implants* **7**: 353-359.

Jung, R.E., Sailer, I., Hämmerle, C.H.F., Attin, T. & Schmidlin, P. (2007) In vitro color changes of the covering mucosa caused by restorative materials. *International Journal of Periodontics and Restorative Dentistry* **27**: 251-57.

Jung, R.E., Holderegger, C., Sailer, I., Khraisat, A., Suter, A. & Hämmerle, C.H., (2008a) The effect of all-ceramic and porcelain-fused-to-metal restorations on marginal peri-implant soft tissue color: A randomized controlled clinical trial. *International Journal of Periodontics and Restorative Dentistry* **28**: 357-365.

Jung, R.E., Pjetursson, B.E., Glauser, R., Zembic, A., Zwahlen, M. & Lang, N.P. (2008b) A systematic review of the survival and complication rates of implant supported single crowns (SCs) after an observation period of at least 5 years. *Clinical Oral Implants Research* **19**: 119-30.

Kohal, R.J., Weng, D., Bachle, M. & Strub, J.R. (2004) Loaded custom-made zirconia and titanium implants show similar osseointegration: An animal experiment. *Journal of Periodontology* **75**: 1262-1268.

Lüthy H. Strength and toughness of dental ceramics. In: Mörmann WH (Ed.). CAD/CIM in aesthetic dentistry. Cerec 10 Year Anniversary Symposium. Quintessence 1996, Chicago, 229-240

Marchack, C.B. (1996) A custom titanium abutment for the anterior single-tooth implant. *Journal of Prosthetic Dentistry* **76**: 288-291.

McGlumphy, E.A., Mendel, D.A. & Holloway, J.A., (1998) Implant screw mechanics. *Dental Clinics of North America* **42**: 71-89.

Molin, M.K. & Karlsson, S.L., (2008) Five-year clinical prospective evaluation of zirconia-based denzir 3-unit FPDs. *International Journal of Prosthodontics* **21**: 223-227.

O'Leary, T.J., Drake, R.B. & Naylor, J.E., (1972) The plaque control record. *Journal of Periodontology* **43**: 38.

Park, S.E., Da Silva, J.D., Weber, H.P. & Ishikawa-Nagai, S. (2007) Optical phenomenon of peri-implant soft tissue. Part I. Spectrophotometric assessment of natural tooth gingiva and peri-implant mucosa. *Clinical Oral Implants Research* **18**: 569-574.

Prestipino, V. & Ingber, A. (1993a) Esthetic high-strength implant abutments. Part I. *Journal of Esthetic Dentistry* **5**: 29-36.

Prestipino, V. & Ingber, A. (1993b) Esthetic high-strength implant abutments. Part II. *Journal of Esthetic Dentistry* **5**: 63-68.

Raigrodsky, A.J., Chiche, G.J., Potiket, N., Hochstedler, J.L., Mohamed, S.E., Billiot, S. & Mecante, D.E. (2006) The efficacy of posterior three-unit zirconium-oxide-based ceramic fixed partial dentures: a prospective clinical pilot study. *Journal of Prosthetic Dentistry* **96**: 237-244.

Rimondini, L., Cerroni, L., Carrassi, A. & Torricelli, P., (2002) Bacterial colonization of zirconia ceramic surfaces: An in vitro and in vivo study. *International Journal of Oral and Maxillofacial Implants* **17**: 793-798.

Rodoni, L.R., Glauser, R., Feloutzis, A. & Hämmerle, C.H., (2005) Implants in the posterior maxilla: A comparative clinical and radiologic study. *International Journal of Oral and Maxillofacial Implants* **20**: 231-237.

Sailer, I., Fehér, A., Filser, F., Gauckler, L.J., Lüthy, H. & Hämmerle, C.H.F. (2007) 5-year clinical results of zirconia frameworks for posterior fixed partial dentures. *International Journal of Prosthodontics* **20**: 151-156.

Sailer, I., Zembic, A., Jung, R. E., Siegenthaler, D., Holderegger, C., Hämmerle, C. H. F. (2009) Randomized controlled clinical trial of customized zirconia and titanium implant abutments for posterior single-tooth implant reconstructions: Preliminary results at 1-year of function. *Clinical Oral Implants Research* **20**: 219-225.

Scarano, A., Piattelli, M., Caputi, S., Favero, G.A. & Piattelli, A., (2004) Bacterial adhesion on commercially pure titanium and zirconium oxide disks: An in vivo human study. *Journal of Periodontology* **75**: 292-296.

Seghi, R.R., Denry, I.L. & Rosenstiel, S.F., (1995) Relative fracture toughness and hardness of new dental ceramics. *Journal of Prosthetic Dentistry* **74**: 145-150.

Studart, A.R., Filser, F., Kocher, P. & Gauckler, L.J., (2007) Fatigue of zirconia under cyclic loading in water and its implications for the design of dental bridges. *Dental Materials* **23**: 106-114.

Tinschert, J., Schulze, K.A., Natt, G., Latzke, P., Heussen, N. & Spiekermann, H., (2008) Clinical behavior of zirconia-based fixed partial dentures made of DC-Zirkon: 3-year results. *International Journal of Prosthodontics* **21**: 217-222.

Updegrave, W.J. (1951) The paralleling extension-cone technique in intraoral dental radiography. *Oral Surgery Oral Medicine & Oral Pathology* **4**: 1250-61.

Vigolo, P., Fonzi, F., Majzoub, Z. & Cordioli, G., (2006) An in vitro evaluation of titanium, zirconia, and alumina Procera abutments with hexagonal connection. *International Journal of Oral and Maxillofacial Implants* **21**: 575-580.

Wohlwend, A., Studer, S. & Schärer, P. (1996) Das Zirkonoxidabutment- Ein neues vollkeramisches Konzept zur ästhetischen Verbesserung der Suprastruktur in der Implantologie. *Quintessenz Zahntechnik* **22**: 364-381.

Tables, Figures and Legends

	mPPD	mBOP	mPCR
ZrO₂ abutments	3.2 ± 1.0	0.4 ± 0.4	0.1 ± 0.2
Control teeth	2.1 ± 0.7	0.4 ± 0.4	0.2 ± 0.3
Ti abutments	3.4 ± 0.5	0.2 ± 0.3	0.1 ± 0.2
Control teeth	2.1 ± 0.4	0.2 ± 0.2	0.1 ± 0.2
Significance <i>ZrO₂ vs. Ti</i>	n.s.	n.s.	n.s.

Table 1: Biological parameters, including the evaluation of mean pocket probing depth (mPPD), mean bleeding on probing (mBOP) and mean plaque control record (mPCR) at abutment and control teeth. Statistical significance of comparisons was set at $p < 0.05$.

		Baseline	1 year	3 years
ZrO₂ abutments	mMBL	1.5 ± 0.7	1.4 ± 0.7	1.7 ± 1.0
	mDBL	1.5 ± 0.9	1.5 ± 0.9	1.6 ± 1.0
Ti abutments	mMBL	2.0 ± 0.7	2.2 ± 1.0	2.0 ± 1.0
	mDBL	2.0 ± 0.7	2.3 ± 1.0	2.1 ± 1.0
Significance <i>ZrO₂ vs. Ti</i>				n.s.

Table 2: Evaluation of the mean marginal bone levels (mm) mesially (mMBL) and distally (mDBL) at zirconia and titanium abutments. Statistical significance of the comparison between test and control group at 3 years was set at $p < 0.05$.

	ΔL	Δa	Δb	ΔE
ZrO₂ abutments	1.0 ± 7.2	3.2 ± 4.9	1.8 ± 2.9	9.3 ± 3.8
Ti abutments	1.2 ± 6.3	0.7 ± 3.6	2.0 ± 2.9	6.8 ± 3.8
Significance <i>ZrO₂ vs. Ti</i>				<i>n.s.</i>

Table 3: Spectrophotometric measurements of the mucosa around zirconia and titanium abutments (CIE-Lab parameters L, a and b). Statistical significance of the comparison of ΔE was set at a significance level of $p < 0.05$.

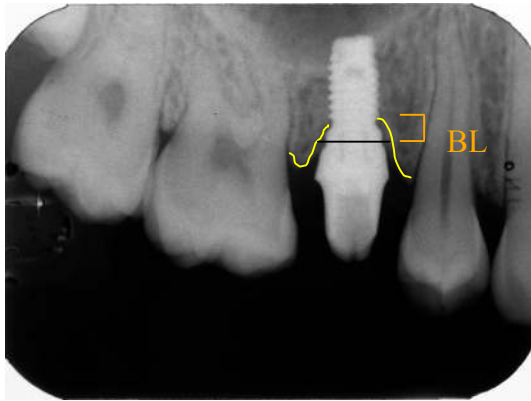


Fig. 1: Measurement first bone-to-implant contact to reference line (implant shoulder) in millimeters (+ values, when bone below the implant shoulder). BL: marginal bone level

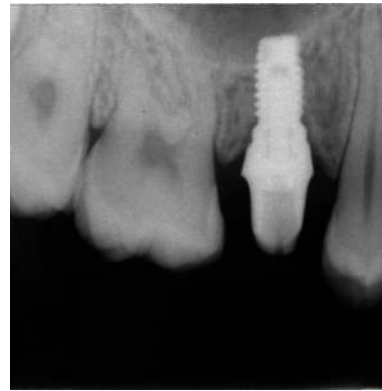
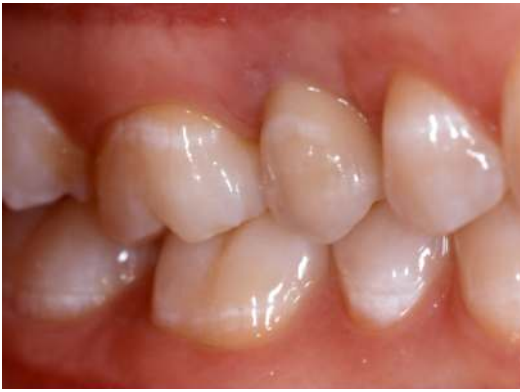
Fig. 2 a, b: Clinical situation of a metal-ceramic implant crown, cemented on a titanium abutment (control group) at crown insertion. Radiograph at baseline.

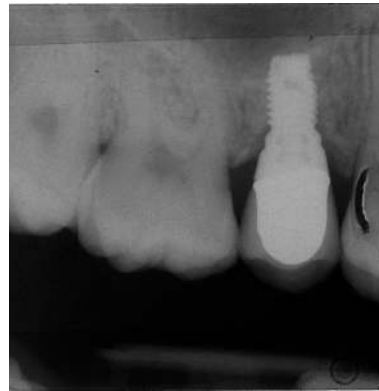
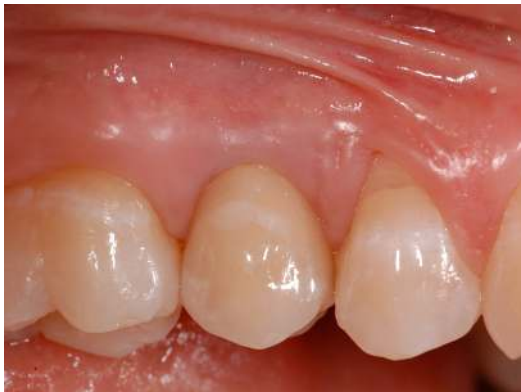
Fig. 2 c, d: Same patient with the metal-ceramic implant crown cemented on a titanium abutment at the 3-year follow-up. Radiograph at 3-years.

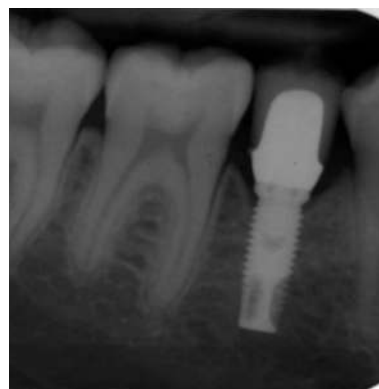
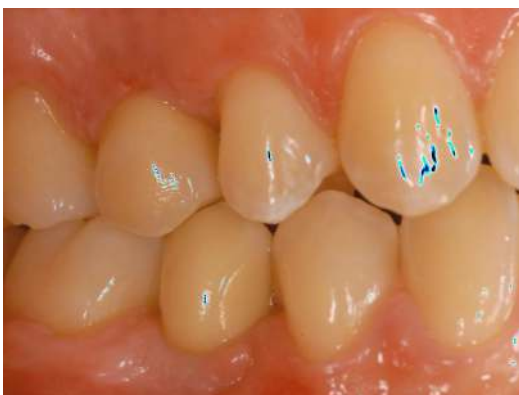
Fig. 3 a, b: Clinical situation of an all-ceramic implant crown, cemented on a zirconia abutment (test group) at crown insertion. Radiograph at baseline

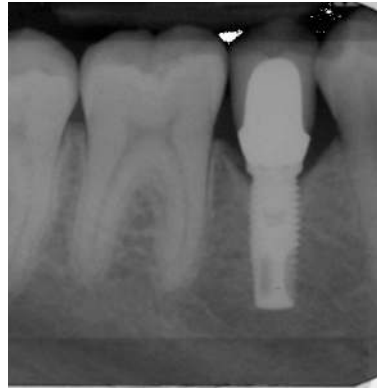
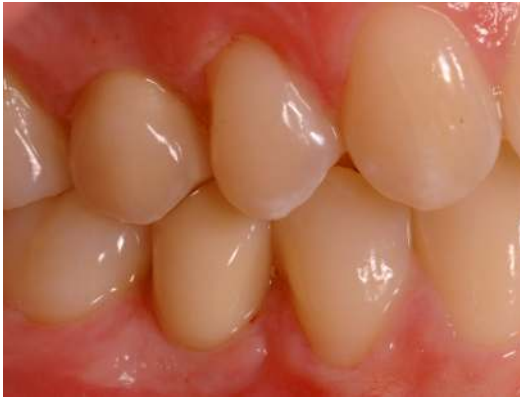
Fig. 3 c, d: Same patient with the all-ceramic crown cemented on a zirconia abutment at the 3-year follow-up. Radiograph at 3-years.