

# Real-time Elastography for the Diagnosis of Prostate Cancer: Evaluation of Elastographic Moving Images

Tomoaki Miyagawa<sup>1</sup>, Masakazu Tsutsumi<sup>2</sup>, Takeshi Matsumura<sup>3</sup>, Natsui Kawazoe<sup>2</sup>, Satoru Ishikawa<sup>2</sup>, Tatsuro Shimokama<sup>4</sup>, Naoto Miyanaga<sup>5</sup> and Hideyuki Akaza<sup>5</sup>

<sup>1</sup>Department of Urology, Kitaibaraki Municipal General Hospital, Ibaraki, <sup>2</sup>Department of Urology, Hitachi General Hospital, Hitachi City, Ibaraki, <sup>3</sup>Ultrasound Systems Division, Hitachi Medical Corporation, Kashiwa City, Chiba, <sup>4</sup>Department of Pathology, Hitachi General Hospital and <sup>5</sup>Department of Urology, Institute of Clinical Medicine, University of Tsukuba, Ibaraki, Japan

Received January 12, 2009; accepted March 5, 2009; published online April 9, 2009

**Objective:** Elastography is a technique for detecting the stiffness of tissues. We applied elastography for the diagnosis of prostate cancer and evaluated the usefulness of elastography for prostate biopsy.

**Methods:** The subjects of this study were 311 patients who underwent elastography during prostate needle biopsy at Hitachi General Hospital. Strain images obtained during compression of the prostate tissue were displayed on a monitor and recorded on the computer. The elastographic moving images (EMI) were evaluated retrospectively. The evaluable images and biopsy results were compared in terms of the feasibility and accuracy.

**Results:** The median patient age was 67 years (range 50–85 years), the median serum level of prostate-specific antigen was 8.4 ng/ml (range 0.3–82.5 ng/ml) and the median prostate volume was 42.6 ml (range 12–150 ml). Among the 311 patients, prostate cancer was detected in 95 patients (30%) by biopsy. The diagnostic sensitivity was 37.9% for digital rectal examination (DRE) and 59.0% for transrectal ultrasonography (TRUS), whereas it was 72.6% for elastography and 89.5% for the combination of TRUS and elastography. Elastography-positive EMIs with negative biopsies were eventually determined to be due to benign prostatic hyperplasia.

**Conclusion:** Elastography has a significantly higher sensitivity for the detection of prostate cancer than the conventionally used examinations including DRE and TRUS. It is a useful real-time diagnostic method because it is not invasive, and simultaneous evaluation is possible while performing TRUS.

*Key words: prostate cancer – screening – prostate-specific antigen – transrectal – ultrasonography – elastography*

## INTRODUCTION

Elastography is an imaging technique in which the differences in tissue stiffness, produced by compression and relaxation of the tissue, can be visualized. It has been shown to be highly useful for the diagnosis of breast cancer (1) and has now become available for the diagnosis of prostate cancer. Cochilin et al. (2), initially reported the clinical usefulness of this imaging modality in the diagnosis of

prostate cancer for the first time in 2002. König et al. (3) and Pallwein et al. (4) reported high diagnostic sensitivities of this technique of 84% and 80%, respectively. Miyanaga et al. (5) reported that the sensitivity of elastography in patients with untreated prostate cancer was 93%, which was significantly higher than that of digital rectal examination (DRE) or transrectal ultrasonography (TRUS). We previously evaluated the feasibility and accuracy of elastography using prostatectomy specimens (6). In the report, the superior characteristics of elastography for the detection of cancer in the anterior prostate, in particular, in addition to the possibility of real-time diagnosis when performed

For reprints and all correspondence: Tomoaki Miyagawa, Department of Urology, Kitaibaraki Municipal General Hospital, 4-5-15 Ohtsu-cho, Kita-cho, Kita-Ibaraki City, Ibaraki, Japan. E-mail sh-miya@umin.ac.jp

simultaneously with TRUS were shown. König et al. (3) reported the biopsy results, however, more than 50% of the patients were performed repeated biopsies, so far the results would be influenced by prostate fibrosis or inflammation due to previous biopsy.

In the present study, elastographic moving images (EMIs) obtained during prostate biopsy were retrospectively evaluated and classified by analyzing the efficacy of elastography alone and of elastography combined with TRUS, and the feasibility of use of this imaging modality for prostate cancer screening was verified. This is the first report of precise analysis of EMIs.

## PATIENTS AND METHODS

### PATIENTS

A total of 311 patients with suspected prostate cancer based on high serum levels of prostate-specific antigen (PSA) (<4.0 ng/ml) and abnormal findings on DRE (palpable nodular lesions), TRUS (detection of hypoechoic lesions) and magnetic resonance imaging (MRI) (detection of low-intensity lesions on T2-weighted images) were enrolled in this study. Prostate biopsies were performed at Hitachi General Hospital between April 2004 and March 2006. Correlations between the EMI findings and the biopsy results in each patient were analyzed.

### EXAMINATION PROCEDURE

The patient was placed in the left lateral position, and transrectal biopsy was performed under TRUS guidance; six to eight cores of tissue were collected using an 18G biopsy needle. For patients who had previously undergone transrectal biopsy or those suspected based on the MRI findings to have cancer in the anterior prostate, a total of 12–14 cores were obtained, i.e. four to six cores by the transperineal approach and eight cores by the transrectal approach, under spinal anesthesia.

The elastography system consisted of an external personal computer (PC, Inter(R) Xeon(R) 3.0 GHz  $\times$  4), a modified commercial ultrasound scanner (EUB-8500, Hitachi Medical Corporation, Tokyo, Japan) and a transrectal probe (7.5 MHz, dual 10R convex with manually perpendicular bipole, EUP-CC531, Hitachi Medical Corporation, Tokyo, Japan). The area from the base of the prostate to the apex was evaluated before performing the biopsy.

Our elastography procedure has been described previously (6): first, the prostate tissue is compressed by pushing the ultrasound probe from above down (free-hand method), and the ultrasound signals during compression are acquired. The signals are transferred to a PC, where the strain images are computed and displayed on the PC monitor using a translucent color scale and superimposed on the TRUS images. The color graduation extends from blue for hard tissue and red for soft tissue. The EMIs were obtained over about 2 s

per section and recorded on the external PC system. The EMIs were obtained transversely from the base to the apex of the prostate.

### EVALUATION OF THE EMIs

Blue-colored areas were defined as positive elastography findings, because cancer lesion is generally stiffer than the normal prostate tissue (7). The EMIs were obtained by three operators (T.M., M.T. and N.K.) who had the experience of performing elastography on more than 20 patients. The prostate biopsy results were evaluated in relation to the age, serum PSA level, prostate volume and the DRE/TRUS/elastography findings. One pathologist (T.S.) conducted the diagnostic examination on the biopsy specimens. The EMI findings were evaluated retrospectively blinded to the biopsy results. The EMI evaluation was as follows (6): images were classified as either evaluable (presence/absence of blue lesions) or unevaluable (unstable EMI: no image available, flicker or cross-sectional slip). Also, images in which the surface of the prostate was not visualized in red due to insufficient compression were classified as unevaluable. The blue areas of surrounding calcifications and anterior fibromuscular stroma (AFS) were classified as errors, which mean they were not evaluated as positive regions by elastography. EMI cross-sections were classified into the base, middle or apex of the prostate, and results were determined to be accurate when the positive sites as determined by elastography (as indicative of cancer) were the same as those found to be affected by cancer on prostate biopsy.

### STATISTICAL ANALYSIS

Patient data (age, serum PSA, prostate volume and biopsy results) were collected retrospectively from the patient records. The diagnostic sensitivity was calculated for each examination. The association of the modality and the sensitivity was examined by means of Fisher's test and Cochran–Mantel–Haenszel (CMH) test, employing the row mean score statistics. CMH test is similar to the  $\chi^2$  test but can have greater power to detect certain departures from the null hypothesis of row independence for ordinal variables (JMP5, SAS Institute Inc, Cary, NC, USA).

## RESULTS

The median age of the 311 patients was 67 years (range 50–85 years), the median serum PSA level was 8.4 ng/ml (range 0.3–82.5 ng/ml) and the median prostate volume was 42.6 ml (range 12–150 ml). An initial biopsy was performed on 219 patients. The remaining 92 patients underwent a repeat biopsy. Six to eight tissue cores were obtained in 245 patients, and 12–14 cores, including 4 to 6 by the transperineal approach, were obtained in 66 patients.

**Table 1.** Sensitivity of the examinations

| Modalities          | No. of positive/no. of cancer (sensitivity %) |
|---------------------|-----------------------------------------------|
| DRE                 | 36/95 (37.9)                                  |
| TRUS                | 56/95 (59.0)                                  |
| Elastography        | 69/95 (72.6)                                  |
| TRUS + elastography | 85/95 (89.5)                                  |

The sensitivities of elastography and TRUS + elastography were significantly higher than DRE or TRUS only by CMH test ( $P < 0.0001$ ). DRE, digital rectal examination; TRUS, transrectal ultrasonography; CMH test, Cochran–Mantel–Haenszel test.

Prostate cancer was detected in 95 patients (30.5%) by biopsy. The elastography findings were positive in 69 (72.6%) patients, in particular 27 (28.4%) were positive only on elastography, including 20 with peripheral lesions and 7 with anterior lesions. The elastography findings were negative in 26 (27.3%), however, 17 of these cases were judged to be positive on TRUS. All of the cancer lesions that were judged to be negative by elastography were in the peripheral regions of the prostate. The sensitivities of DRE, TRUS, elastography and elastography combined with TRUS (TRUS + elastography) are shown in Table 1. The overall sensitivities of elastography and TRUS + elastography were significantly higher than those of DRE or TRUS only, at 72.6% for elastography and 89.5% for TRUS + elastography ( $P < 0.001$ ). Table 2 shows the relationships among the serum PSA levels, prostate volume and the efficacy of elastography and TRUS + elastography. No differences were observed in terms of the serum PSA levels ( $P = 0.10, 0.92$ ) and the prostate volume ( $P = 0.12, 0.10$ ). However, the sensitivity of elastography tended to decrease as the prostate volume increased. There were no differences in the sensitivity related to the Gleason score ( $P = 0.61$ ) (Table 3).

Of all the obtained 2338 EMIs (mean 7.5 EMIs per patient, range 4–12), 1686 EMIs (72.1%: a mean of

**Table 2.** Impact of serum PSA and prostate volume on the sensitivity of elastography

|           | No. of positive elastography/no. of cancer (sensitivity %) | No. of positive TRUS + elastography/no. of cancer (sensitivity %) |
|-----------|------------------------------------------------------------|-------------------------------------------------------------------|
| PSA value |                                                            |                                                                   |
| <10 ng/ml | 32/49 (65.3)                                               | 44/49 (89.8)                                                      |
| ≥10 ng/ml | 37/46 (80.4)                                               | 41/46 (89.1)                                                      |
| Volume    |                                                            |                                                                   |
| <50 ml    | 58/76 (76.3)                                               | 70/76 (92.1)                                                      |
| ≥50 ml    | 11/19 (57.9)                                               | 15/19 (79.0)                                                      |

No differences were observed in terms of the serum PSA levels and the prostate volume on elastography ( $P = 0.10, 0.92$ ) and TRUS + elastography ( $P = 0.12, 0.10$ ).

PSA, prostate-specific antigen.

**Table 3.** Impact of Gleason score on the sensitivity of elastography

| Gleason score | No. of positive elastography/no. of cancer (sensitivity %) |
|---------------|------------------------------------------------------------|
| 6             | 23/35 (69)                                                 |
| 7             | 21/29 (72)                                                 |
| 8             | 13/16 (81)                                                 |
| 9–10          | 10/14 (71)                                                 |

There were no differences in the sensitivity related to Gleason score by CMH test ( $P = 0.61$ ).

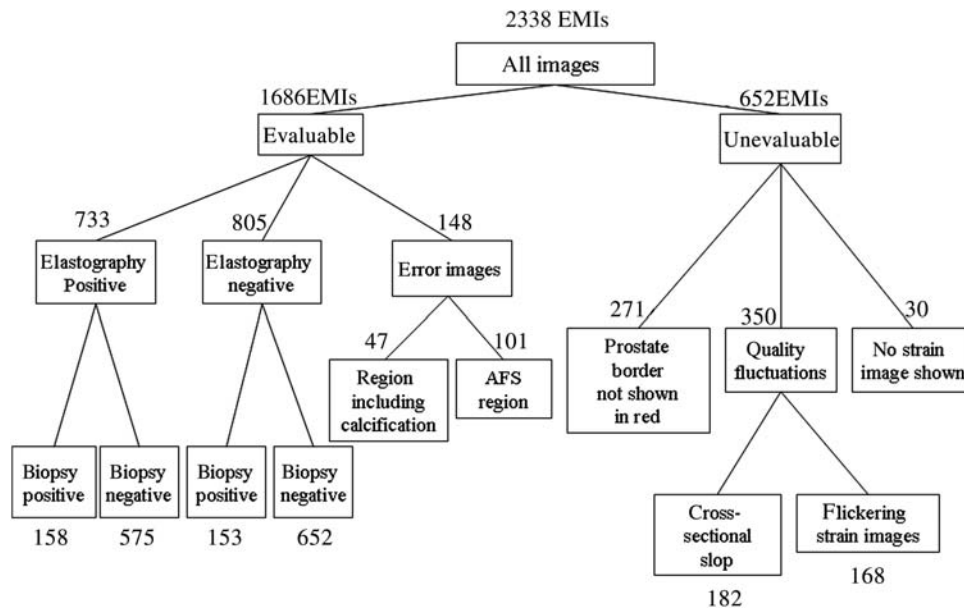
5.4 EMIs per patient, range 3–10) were considered to be evaluable (Fig. 1). In the 733 EMIs with positive findings, 158 were consistent with the characteristics of cancer lesions. Among the 575 elastography-positive EMIs with biopsy negative, 424 (73.7%) were considered to show benign prostatic hyperplasia (BPH). On the other hand, 652 EMIs (27.9%) were judged to be unevaluable: as a result of insufficient compression in 271 and poor-quality EMIs due to slip or flicker in 350. There were no differences in the diagnostic sensitivity in relation to the number of evaluable EMIs per patient ( $P = 0.70$ ).

Figure 2 shows a case of a patient in whom prostate cancer was detected only by elastography. He was a 62-year-old male with a serum PSA level of 22.0 ng/ml. DRE was negative, and there were no abnormal findings on TRUS (Fig. 2a). Elastography detected a blue lesion in the right anterior prostate region (Fig. 2b). Transperineal biopsy cores obtained from the right anterior prostate revealed adenocarcinoma with a Gleason score of 4 + 4. The prostatectomy specimen revealed the cancer in the same region (Fig. 2c).

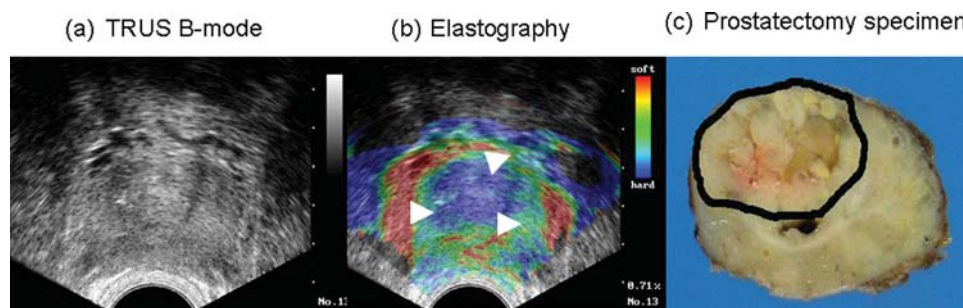
## DISCUSSION

Prostate biopsy is routinely performed for the diagnosis of prostate cancer. As compared with the conventional sextant biopsy technique of Hodge et al. (8), the more recent biopsy methods allow an increased number of biopsy cores to be obtained, with 8–12 as the standard (9). However, the complications associated with the increase in the number of biopsy cores (10) should be taken into consideration. Detection of insignificant cancer should also be taken into account, therefore, the targeted biopsy would be desirable.

Elastography is useful for the diagnosis of prostate cancer, because prostate cancer lesions are stiffer than the normal prostate tissue (7). This method is promising in that the examination can be performed with minimal extra time when performing TRUS (2). The reported sensitivity of elastography for the diagnosis of prostate cancer is in the range of 80–93% (3–5). Salomon et al. (11) reported that elastography identified at least one tumor focus in each patient of prostate cancer. Thus, elastography offers the potential for



**Figure 1.** Classification of the elastographic moving images according to the results of analysis of the EMIs, 1686 (73%) of a total 2338 EMIs were evaluable, and the remaining 652 (27%) were judged as unevaluable. Among 575 elastography-positive EMIs with biopsy negative, 424 (74%) images were considered to show prostatic hyperplasia. EMI, elastographic moving image; AFS, anterior fibromuscular stroma.



**Figure 2.** Case presentation 62-year-old, serum PSA of 22 ng/ml, negative DRE. (a) Unclear lesion on TRUS. (b) Elastography shows a blue area in the right anterior aspect (white arrow head). Biopsy result: right anterior lobe of the prostate (by transperineal biopsy), adenocarcinoma; Gleason score 4 + 4. (c) The pathology section revealed the tumor in the same region. PSA, prostate-specific antigen; DRE, digital rectal examination; TRUS, transrectal ultrasonography.

overcoming the disadvantages of DRE or TRUS by providing more information for the diagnosis of prostate cancer.

Our present study demonstrated the usefulness of elastography in prostate cancer screening. Elastography showed a significantly higher sensitivity than either DRE or TRUS alone. One of the advantages of elastography is that its diagnostic sensitivity for prostate cancer is nearly 90%, irrespective of the serum PSA, especially when the evaluation is conducted in combination with TRUS (PSA < 10 ng/ml vs. PSA ≥ 10 ng/ml: 89.8% vs. 89.1%, Table 2). Elastography is also less likely to be affected by the histological grades of prostate cancer. However, the sensitivity has been shown to decrease when the prostate volume is or exceeds 50 ml. This is considered to arise from the confounding effect of BPH. Also, there is a likelihood of the biopsy needle missing the cancerous regions in patients with a larger size of the prostate. Because this report was based on the results of prostate biopsy, the likelihood of ‘false-negative’ results should be

considered. Therefore, we considered that the specificity cannot be proved from this study.

Twenty-seven (28.4%) patients including 20 with peripheral lesions and 7 with anterior lesions were detected by elastography but not by TRUS. There were no special pathological findings including Gleason scores in these lesions. On the other hand, some patients included in this study had cancer lesions in the peripheral regions that were evaluated as negative by elastography but were detected by DRE or TRUS. Although it is not clear why peripheral lesions are sometimes not detected by elastography, possible effects of the characteristics of the probe or the anatomical features of the prostate may be involved (6).

There are some problems with the use of the free-hand method in performing elastography for the diagnosis of prostate cancer. One of the most limiting is the difficulty in mastering the technique required to obtain appropriate EMIs. As shown in Fig. 1, 27.8% of the EMIs, even those obtained by

experienced operators, were judged to be unevaluable due to technical problems. One of the causes is compression point deviations due to the shape of the biplane probe. Pallwein et al. (4) have used a linear endofire probe for performing elastography. Although the endofire probe allowed easier compression than the biplane probe, the examiner needs about 3 months of training. Another technical difficulty is the inability to visually confirm the degree and location of the compression when using a transrectal probe, whereas in the case of a breast lesion, for example, the operator can visually identify the compressed region. Furthermore, as an anatomic characteristic of the prostate, compression of the prostate from the anal canal may prevent transmission of sufficient compression through the entire prostate. It should be noted that compression applied to the posterior region of the prostate is different from that applied to the anterior region (12).

Another problem is the high frequency of elastography-positive EMIs due to the prevalence of BPH. Our elastography system produced many 'blue' EMIs in the presence of BPH, because hypertrophic prostate would be also stiffer than normal tissue (7). This tendency became more pronounced as the prostate volume increased. Pallwein et al. (4) did not include the inner gland findings because prostate cancer in the transition zone is rare, and elastography can produce stiffness artifacts with increasing depth of ultrasound penetration. However, our previous report showed the superior characteristics of elastography for the detection of lesions in the anterior prostate (6). Sumura et al. (13) also reported that the cancer detection rate in the anterior prostate was higher than that in the peripheral region (75% vs. 73.7%). These reports show that elastography is more effective for identifying cancer in the anterior region of the prostate, therefore, this region should not be excluded during the examination. Also, the evaluation criteria should be developed for EMIs obtained from the inner glands. These problems indicate the limitations of the free-hand method when performing elastography of the prostate. Improved evaluation methods should be considered to resolve these problems.

## CONCLUSION

In this study, we evaluated the usefulness of elastography during prostate biopsy for the detection of prostate cancer. The method provides advantages such as real-time diagnosis and shows a much higher sensitivity than that of the conventionally used TRUS or DRE. However, the difficulty in performing the examination and the high frequency of

elastography-positive EMIs with negative biopsy need to be addressed. Also, the reason for the difficulty in the detection of peripheral cancer lesions is unclear. At present, the free-hand method has limitations when it is applied for the diagnosis of prostate cancer.

## Funding

This work was conducted in part with a grant from the Fund-in-Trust for Cancer Research from the Governor of Ibaraki Prefecture.

## Conflict of interest statement

None declared.

## References

1. Itoh A, Ueno E, Tohno E, Kamma H, Takahashi H, Shiina T, et al. Breast disease: clinical application of US elastography for diagnosis. *Radiology* 2006;239:341–50.
2. Cochilin DL, Ganatra RH, Griffiths D. Elastography in the detection of prostatic cancer. *Clin Radiol* 2002;11:1014–20.
3. König K, Scheipers U, Pesavento A, Lorenz A, Ermert H, Senge T. Initial experiences with real-time elastography guided biopsies of the prostate. *J Urol* 2005;174:115–17.
4. Pallwein L, Mitterberger M, Struve P, Pinggera G, Horninger W, Bartsch G, et al. Real-time elastography for detecting prostate cancer: preliminary experience. *BJU Int* 2006;100:42–6.
5. Miyanaga N, Akaza H, Yamakawa M, Oikawa T, Sekido N, Hinotsu S, et al. Tissue elasticity imaging for diagnosis of prostate cancer: a preliminary report. *Int J Urol* 2006;13:1514–18.
6. Tsutsumi M, Miyagawa T, Matsumura T, Kawazoe N, Ishikawa S, Shimokama T, et al. The impact of real-time tissue elasticity imaging (elastography) on the detection of prostate cancer: clinicopathological analysis. *Int J Clin Oncol* 2007;12:250–55.
7. Krouskop TA, Wheeler TM, Kallel F, Garra BS, Hall T. Elastic moduli of breast and prostate tissues under compression. *Ultrason Imaging* 1998;20:260–74.
8. Hodge KK, McNeal JE, Terris MK, Stamey TA. Random systemic versus directed ultrasound guided transrectal core biopsies of the prostate. *J Urol* 1989;142:71–5.
9. Ramey JR, Halpern EJ, Gomella LG. Ultrasonography and biopsy of the prostate. In: Wein AJ, editor. *Campbell–Walsh Urology*. 9th ed. Philadelphia: Saunders 2007;2883–92.
10. Sieber PR, Rommel FM, Theodoran CG, Hong RD, Del Terzo MA. Contemporary prostate biopsy complication rates in community-based urology practice. *Urology* 2007;70:498–500.
11. Salomon G, Köllerman J, Thederan I, Chun FK, Budäus L, Schlomm T, et al. Evaluation of prostate cancer detection with ultrasound real-time elastography: a comparison with step section pathological analysis after radical prostatectomy. *Eur Urol* 2008;54:1354–62.
12. Matsumura T, Tonomura A, Shinomura R, Mitake T, Kanda H, Tsutsumi M, et al. Diagnostic results of elasticity imaging for prostate cancer detection based on clinicopathological analysis. *IEEE Ultrasonics Symposium* 2006;1238–41.
13. Sumura M, Shigeno K, Hyuga T, Yoneda T, Shiina H, Igawa M. Initial evaluation of prostate cancer with real-time elastography based on step-section pathologic analysis after radical prostatectomy: a preliminary study. *Int J Urol* 2007;14:811–16.