

# Reappraisal of the Vascular Anatomy of the Colon and Consequences for the Definition of Surgical Resection

Makio Mike Nobuyasu Kano

Department of Surgery, Kameda Medical Center, Kamogawa, Japan

## Key Words

Colon cancer · Vascular anatomy of the colon · Colon operations, definitions

## Abstract

**Introduction:** Databases of information on surgical treatment for colorectal cancer have been created in various countries and data have started to be released. The most important facets of research for statistical processing include the methodology and firm definitions of content. However, for trials involving colorectal cancer, the applicable terminology has not been defined, and much bias is frequently encountered. Starting from definitions of the colon and vascular system of the colon, we propose definitions of surgical procedures for colorectal cancer. **Methodology:** This paper reviews the colon segments and vascular anatomy of the colon. If surgical treatment of colon cancer is considered from this perspective, we can see that definitions for these surgical procedures are lacking. The definition of surgical treatment would also allow clarification of the range of lymph node dissection. In general, surgical procedures and the area of surgical lymph node dissection are both defined according to the basic structure of the associated arteries. However, the existing descriptions are not based on a definition of the

arteries. We therefore tried to establish the most useful nomenclature for the arterial system of the large intestine for colorectal surgeons and reviewed the frequency of important arterial variations. Using the resulting definitions, we provided consistent definitions for colon cancer surgery. **Conclusion:** The segments of the colon need to be defined. In surgery, procedures are performed using the arteries as indicators, so vessels originating from the superior and inferior mesenteric arteries are referred to as arteries, with others are referred to as branches. Surgical treatment of colon cancer can be defined from the relationship between these arteries. For the first time, this may allow proper application of statistics for the treatment of colon cancer.

© 2013 S. Karger AG, Basel

## Introduction

Databases collecting information on the surgical treatment of colorectal cancer have been created in various countries and the resulting data have started to be

This paper is not based on a previous communication to a society or meeting.

released [1–3]. In Japan, general rules for clinical and pathological studies on cancer of the colon, rectum and anus have been drawn up by the Japanese Society for Cancer of the Colon and Rectum (Japanese Classification of Colorectal Carcinoma, JCCRC) [4], and the data have been registered. Most surgeons have performed procedures to treat colorectal cancers under these general rules [4–6]. However, the definitions regarding surgical treatment are lacking consistency. Lymph node dissection, however, can be mentioned as having a clear definition of surgical treatments. In addition, both lymph node dissection and surgical procedures are usually defined according to the basic structure of the arteries. However, this situation has not been based on the definition of the arteries. We, therefore, tried to establish the most useful nomenclature for the arterial system of the large intestine for colorectal surgeons, and reviewed the frequency of key arterial variations. Using the resulting definition of the arterial system, we then defined colorectal cancer surgeries.

### Nomenclature of the Portions of the Colon

A key problem is the lack of consistent definitions for the portions of the colon and rectum around the world or between textbooks. The portion of the cecum terminates at the upper portion of the ileocecal valve, so the border between the cecum and the ascending colon is the upper border of the Bauhin valve [4, 7–10]. However, this border is not explicitly defined in many textbooks [11–13]. The ascending colon terminates at the hepatic flexure of the colon, but textbooks again fail to explicitly define the hepatic flexure. In the JCCRC, the hepatic flexure of the colon is defined as the line connecting the outer flexure point to the inner flexure point. A similar definition is used for the splenic flexure, which is in turn used to define the transverse colon [4]. The descending colon is then defined as extending from the splenic flexure to either the iliac crest [4, 10, 11, 13] or the linea terminalis [7–9, 12]. As a result, the sigmoid colon is defined from the iliac crest [4, 10, 11] or the linea terminalis [7–9, 12]. However, some textbooks also define the iliac colon as extending from the iliac crest to the linea terminalis [11, 13]. The sigmoid colon terminates at the promontory [4, 7, 12] or third sacral vertebra [8, 10, 11, 13]. The rectum is divided into three portions, with the portion above the peritoneal flexure divided into two portions [4, 8, 12]. However, many books use many different definitions [7, 9, 11, 13]. As stated above,

various definitions of the portions of the colon have also been given. Precise and consistent definitions of the portions of the colon are prerequisite to proper recording and analysis of treatments for colon cancer. This manuscript is based on the JCCRC. The JCCRC defined the lymph nodes as the coding of station numbers, the lymph node station numbers and the lymph node groups. But the JSCCR did not define the surgical treatment. In view of the definition the surgeons dissect the specimen along the feeding artery just after the operation to pick up the lymph nodes [4].

### Vascular Anatomy of the Colon

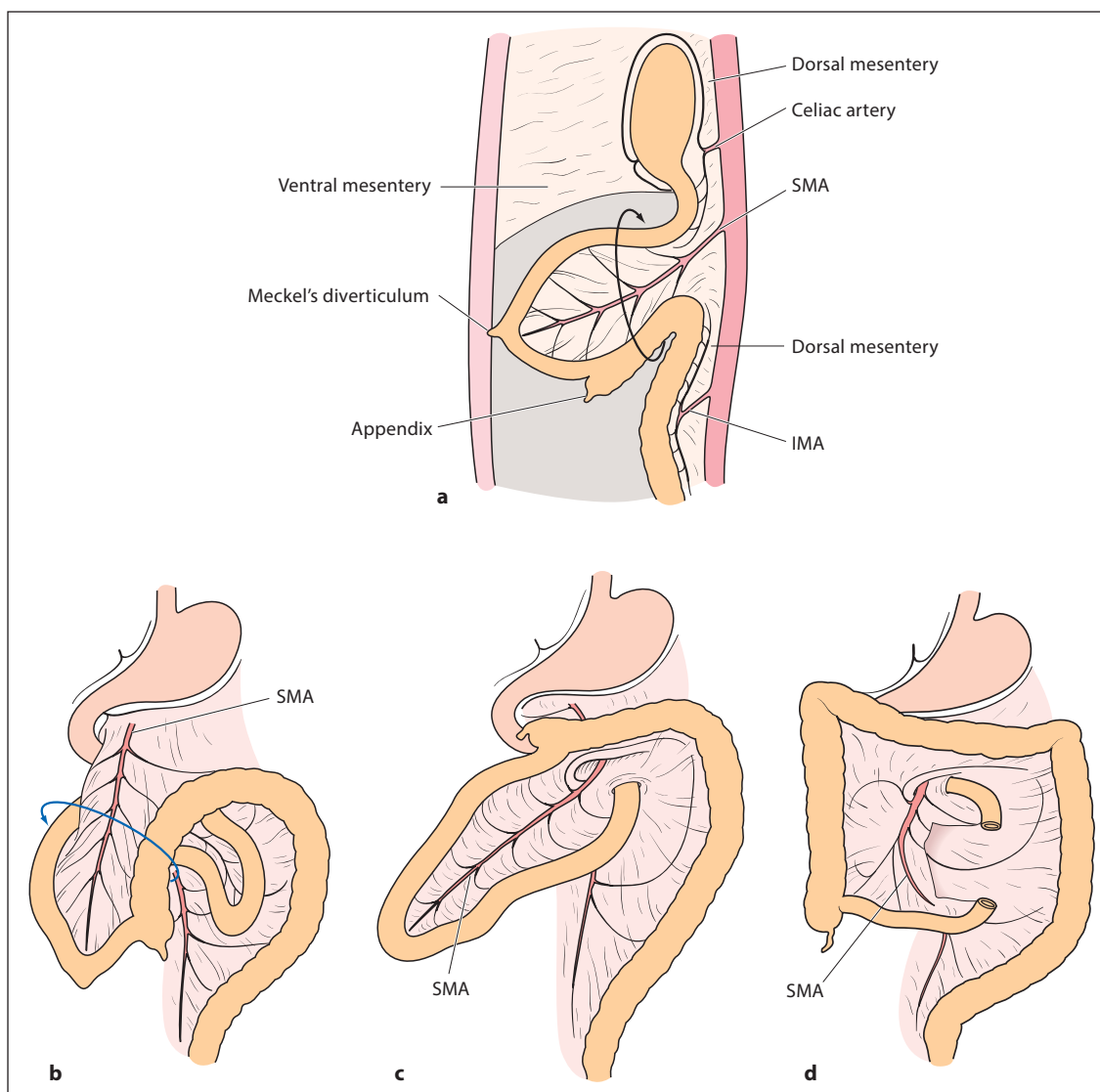
Despite many efforts to unify the anatomical terminologies [14–16], consensus has not been reached on uniform terminology for the colic arteries. Many authors have arbitrarily named the colic arteries independently of their origins [14, 17, 18], while other authors have used the name ‘colic artery’ for those vessels with an independent origin from the superior mesenteric artery (SMA) or inferior mesenteric artery (IMA) [16, 19]. Otherwise, branches without a direct origin from the SMA or IMA are indicated as a ‘colic branch’.

#### *Vascular Anatomy of the Right Colon*

We reviewed the anatomy of the SMA and its colonic arteries. First, the SMA should be defined in the right colon. The SMA is a vessel originating directly from the aorta and feeding the entire small intestine as well as the colon up to two thirds of the transverse colon. Embryologically, the intestine rotates around the SMA, the peripheral portion of which is the yolk sac. The yolk sac is also a portion of Meckel’s diverticulum (fig. 1). The SMA is thus defined as the artery that heads to the ileum, 50–100 cm from the terminal ileum.

Arteries arising from the SMA are highly variable compared with the left colon, but the terminal artery from the SMA, the ileocolic artery (ICA), is always present. The right colic artery (RCA) is an artery arising directly from the SMA, but is present in only 10–40% of cadavers (fig. 2) [19]. In 70–90% of cadavers, two arteries arise from the SMA to supply the right colon, while 10–30% have three arteries. This means that, in many cases, two arteries are present: the ICA and the middle colic artery (MCA) [19].

As for the arteries of the transverse colon, the first artery arising from the SMA to the right is the MCA, which arises within the lower border of the pancreas body. Then,



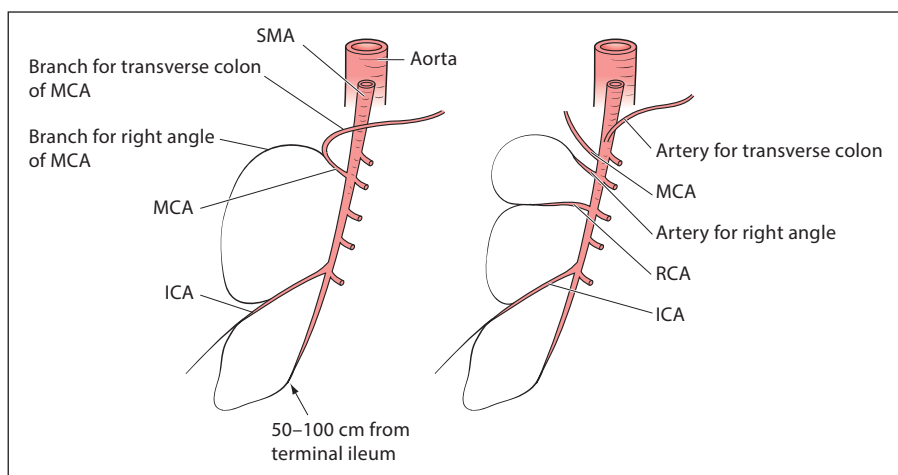
**Fig. 1.** SMA and intestinal rotation. Embryologically, the intestine rotates around the SMA, the peripheral portion of which is the yolk sac. The yolk sac is a portion of Meckel's diverticulum. The SMA is thus defined as the artery that heads to the ileum, 50–100 cm from the terminal ileum.

to avoid using words such as 'right branch' or 'left branch' of the MCA, the artery for the right angle or the branch for the right angle of the MCA, and the artery for the transverse colon or the branch for the transverse colon of the MCA are considered adequate representations of the arteries originating from the SMA or the branches arising from the MCA (fig. 2) [16].

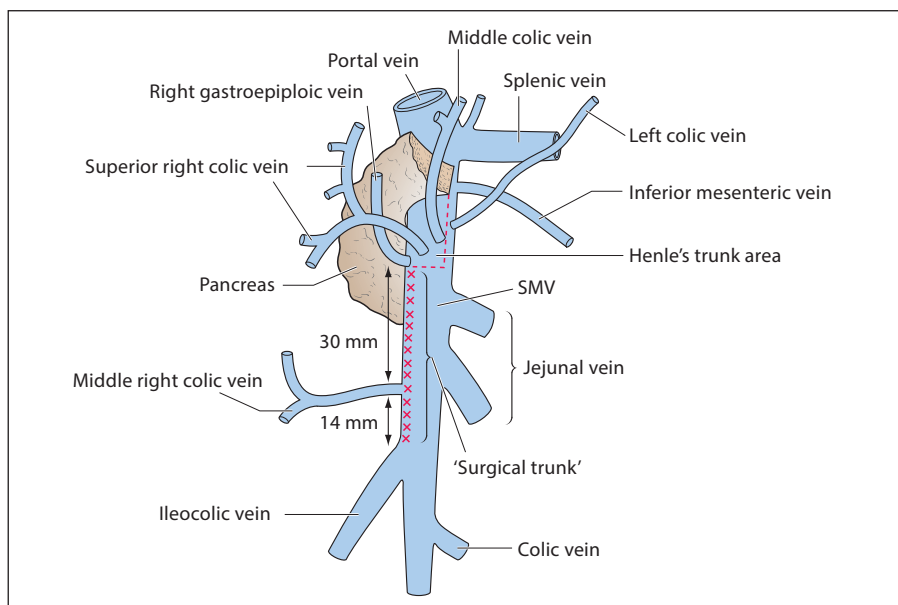
In the area between the RCA (or, in its absence, the ICA) and the left colic artery (LCA), more than one so-called 'MCA' arising directly from the SMA may be found. Among these 'MCAs', five distinct vessels have

been isolated, individually behaving like arteries (with separate origins) or like branches: (1) the true MCA (found in 46% of specimens), (2) the artery for the right angle (32%), (3) the artery for the transverse colon (12%), (4) the accessory artery for the transverse colon (3%), and (5) the accessory LCA (7%). There is one 'MCA' in 75% of cases, two 'MCAs' with separate origins in 24% and three in 1% [16]. Given these findings, it would be preferable to designate blood vessels arising directly from the SMA as 'artery' and blood vessels arising from an 'artery' as 'branch'.

**Fig. 2.** Vascular anatomy of the right colon. The terminal artery of the SMA is the ICA, which is constantly present. The RCA is a branch directly from the SMA, but its presence is recorded in only 10–40% of cadavers. The artery for the right angle (or branch for the right angle) and the artery for the transverse colon (or branch for the transverse colon) are considered adequate representations of arteries originating from the SMA (or branches from the MCA).



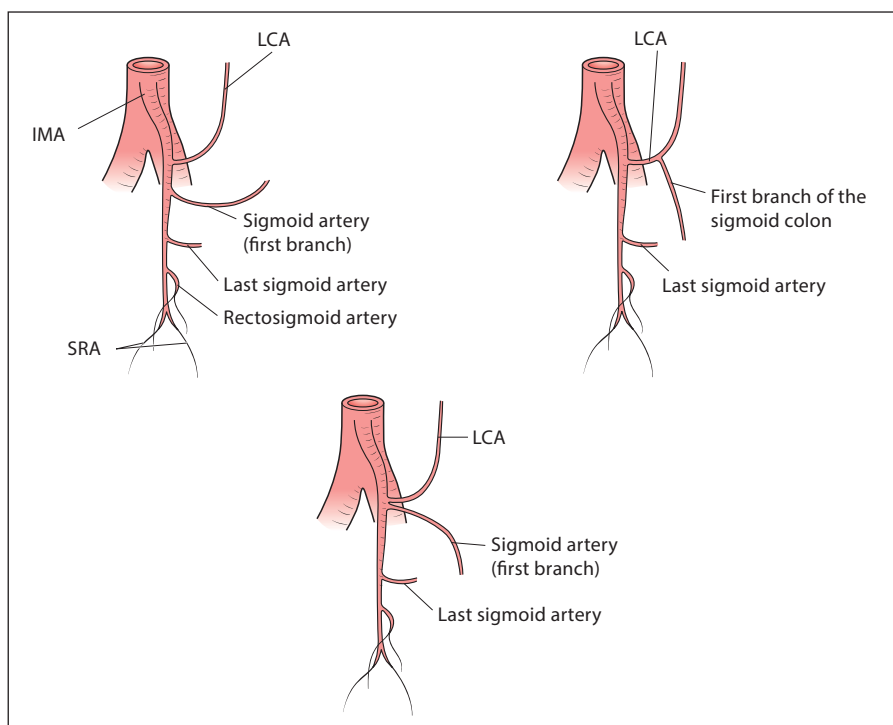
**Fig. 3.** Surgical trunk for the concept of Gillot. The ‘surgical trunk’ is limited to the confluent region of the SMV, which means only the right ventrolateral SMV. Lymph flow is present along this surgical trunk.



In Japan, lymphadenectomy is recommended to be performed centered on the arteries according to the JCCRC [4]. NCCN (National Comprehensive Cancer Network) Guidelines (Colon Cancer) recommend that the lymph nodes should be harvested for the pathological examination at the origin of the feeding vessel [20]. However, in reality, since Gillot's concept (fig. 3) [21] was introduced into Japan in the 1970s, two kinds of definitions have been applied in lymph node dissections of the right colon: one is that of main lymph node dissection corresponding to the root of the main feeding artery according

to the JCCRC [4], while the other is lymph node dissection according to lymph flow based on Gillot's concept, with dissection of the nodes of the surgical trunk as the main lymph nodes [21].

In the study of Gillot et al. [21], the term ‘surgical trunk’ has been limited to the superior mesenteric vein (SMV) between the ileocolic vein caudally and Henle's trunk (gastrocolic trunk) cranially. Speaking more generally, the ‘surgical trunk’ is limited to the region of confluence of the SMV, meaning only the right ventrolateral SMV. In the right colon, lymph node dissection along this



**Fig. 4.** Vascular anatomy of the left colon. The LCA is defined as the first left lateral branch from the IMA. Any vessel diverging from the LCA is termed a 'branch'. According to this definition, the variations of the IMA can be divided into: (1) the LCA continuing from the IMA with no further branches, (2) the first branch to the sigmoid colon branching from the LCA, or (3) the LCA and first sigmoid artery together branching from the same site on the IMA.

'surgical trunk' is better than lymph node dissection to the root of the main artery (fig. 3). However, whether lymph node dissection along the surgical trunk is appropriate has not been verified. In addition, formation of the gastrocolic trunk has been noted in 69% of cases [22].

#### *Vascular Anatomy of the Left Colon*

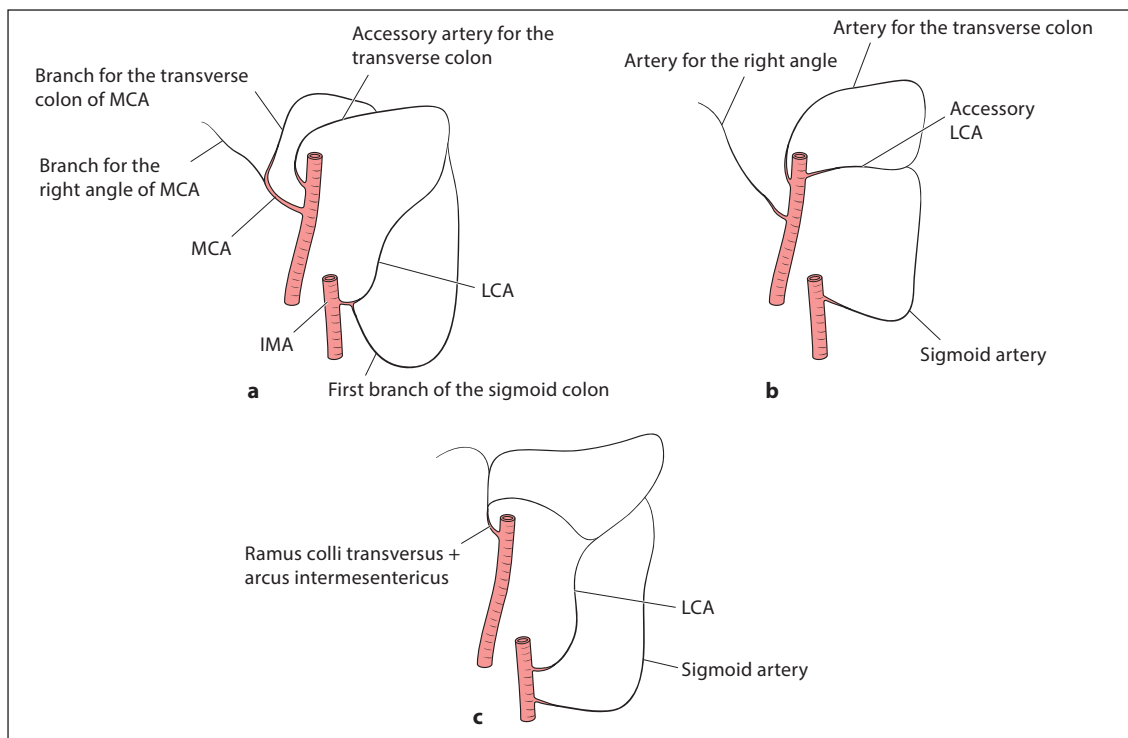
For the left colon, as the IMA is always present, the LCA has to be defined. Unless the artery arising from the SMA provides the only blood supply to the descending colon, the LCA is defined as the first left lateral artery arising from the IMA. Any vessel diverging from the LCA is called a 'branch' rather than an 'artery', using the same branch-naming system applied to the SMA (fig. 4). According to this definition, variations of the IMA can be divided into: (1) the LCA acting as the sole artery arising from the IMA (58%), (2) the first branch of the sigmoid vessel arising from the LCA (27%), or (3) the LCA and first sigmoid artery together arising from the same site on the IMA (15%) [23, 24]. Given these possibilities, those vessels arising directly from the IMA are termed 'artery' and those arising from the 'artery' are named 'branch' (fig. 4).

In many papers, the superior rectal artery (SRA) has been described as the artery immediately after diver-

gence of the LCA from the IMA. In 1908, Miles [25] referred to the route of lymphatic drainage along the IMA. He recommended the division of the IMA just distal to the LCA. After that the artery just distal to the LCA is not the SRA, but the IMA. Until 1993, in most publications 'high or low ligation of the IMA' is the usual presentation during surgery for cancer of the rectum. Ligation above the origin of the left colic artery had been high ligation and ligation below this level low ligation [26, 27]. But after Lanz and Wachsmuth the artery caudally to the origin of the LCA is denominated SRA and not IMA. SRA is incorrectly denominated as IMA caudally to the origin of the LCA [28]. Based on common sense the sigmoid arteries should not diverge from the SRA. The SRA has been defined as the artery after the diverging of the rectosigmoid artery (fig. 4) [29–31]. Such misapplication of the nomenclature should obviously be addressed. Of course, in this paper, the caudal side of the IMA after the diverging of the LCS is described as the IMA.

#### *Vascular Anatomy of the Splenic Flexure*

The splenic flexure of the colon is defined as extending from one third of the left transverse colon to the first portion of the descending colon [32]. Blood flow to this part



**Fig. 5. a–c** Vascular anatomy of the splenic flexure. Blood flow to this part is almost entirely from the LCA (a). However, although blood flow from the transverse colon to this portion involves a variety of vessels, the artery for the transverse colon (b) or the branch for the transverse colon from the MCA (c) are the most commonly used terms.

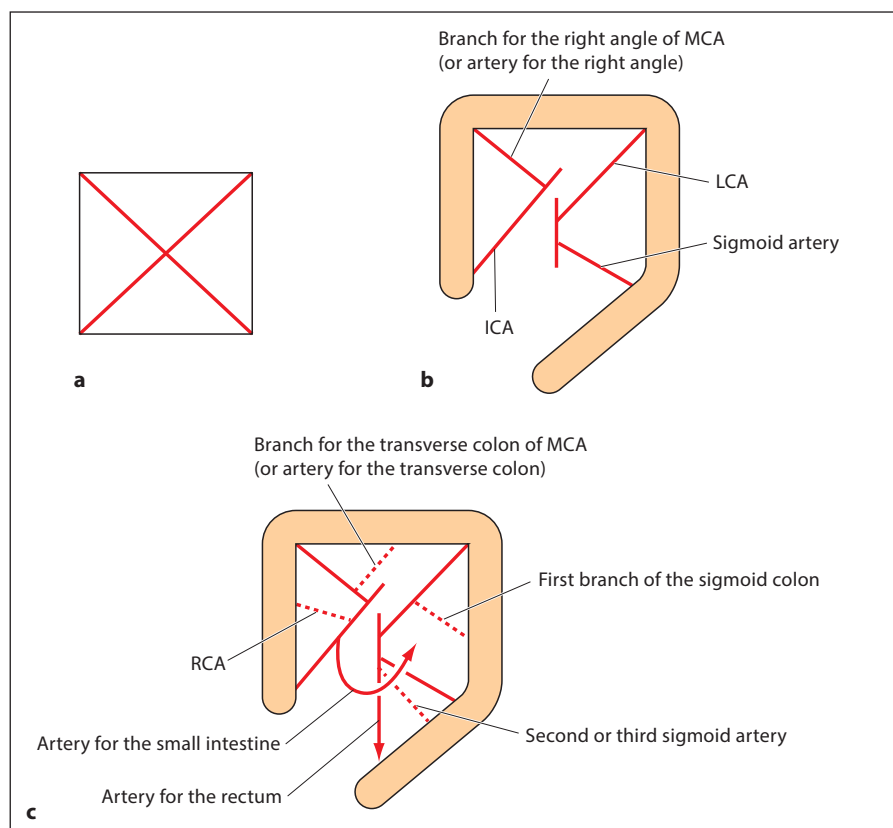
is almost entirely from the LCA. However, although blood flow from the transverse colon to this portion involves a variety of vessels, ‘the artery for the transverse colon’ and ‘the branch for the transverse colon’ from the MCA are the most commonly used terms (fig. 5).

### Definitions of Surgical Treatments for Colon Cancer

First, when considering surgery of the colon, the definitions of surgical procedures have to be checked. In the JCCRC [4], operative procedures include ileocecal resection, partial resection of the colon, right hemicolectomy, left hemicolectomy, sigmoidectomy, subtotal colectomy and total colectomy. Right hemicolectomy is defined as resection of the terminal ileum, cecum, ascending colon, rightmost one third of the transverse colon, ICA/ileocolic vein, RCA/right colic vein and right branch of the MCA/middle colic vein. Left hemicolectomy is defined as resection of the leftmost one

third of the transverse colon, descending colon, sigmoid colon, left branch of the MCA/middle colic vein, LCA/left colic vein and sigmoid artery/vein. In addition, ileocecal resection and sigmoidectomy must be defined. Surgical excision over a smaller range is defined as partial resection of the colon. However, resection of the right colon over a narrower range than right hemicolectomy is more likely to be performed, and furthermore the frequency of left hemicolectomy is considered very low. The definitions of these terms are thus unrealistic and the terms of segmental resection need to be defined.

There has been a concept that is accepted in French as the definition of surgical procedures for colorectal cancer surgery [33]. The four main arteries of the colon are defined using a square as a model, considered as the backbone of the large intestine (fig. 6a). The four vessels are the ICA, the branch for the right angle of the MCA (or the artery for the right angle), the LCA and the sigmoid artery (fig. 6b). Anomalous arteries in addition



**Fig. 6.** **a** The four main arteries of the colon are defined using a square as a model of the backbone of the large intestine. **b** Vessels comprise the ICA, branch for the right angle of the MCA (or artery for the right angle), LCA and sigmoid artery. **c** Anomalous arteries in addition to the four main arteries are the RCA, the branch for the transverse colon of the MCA (or the artery for the transverse colon), the first branch of the sigmoid colon, and the second or third sigmoid artery. Arrows represent arteries to the small intestine and rectum.

to the four main arteries are the RCA, the branch for the transverse colon of the MCA (or the artery for the transverse colon), the first branch of the sigmoid colon, and the second or third sigmoid artery (fig. 6c) [34, 35].

Based on the above definitions, colon cancer surgery can be defined. It includes colon segmental resection, hemicolectomy, subtotal colectomy and total colectomy.

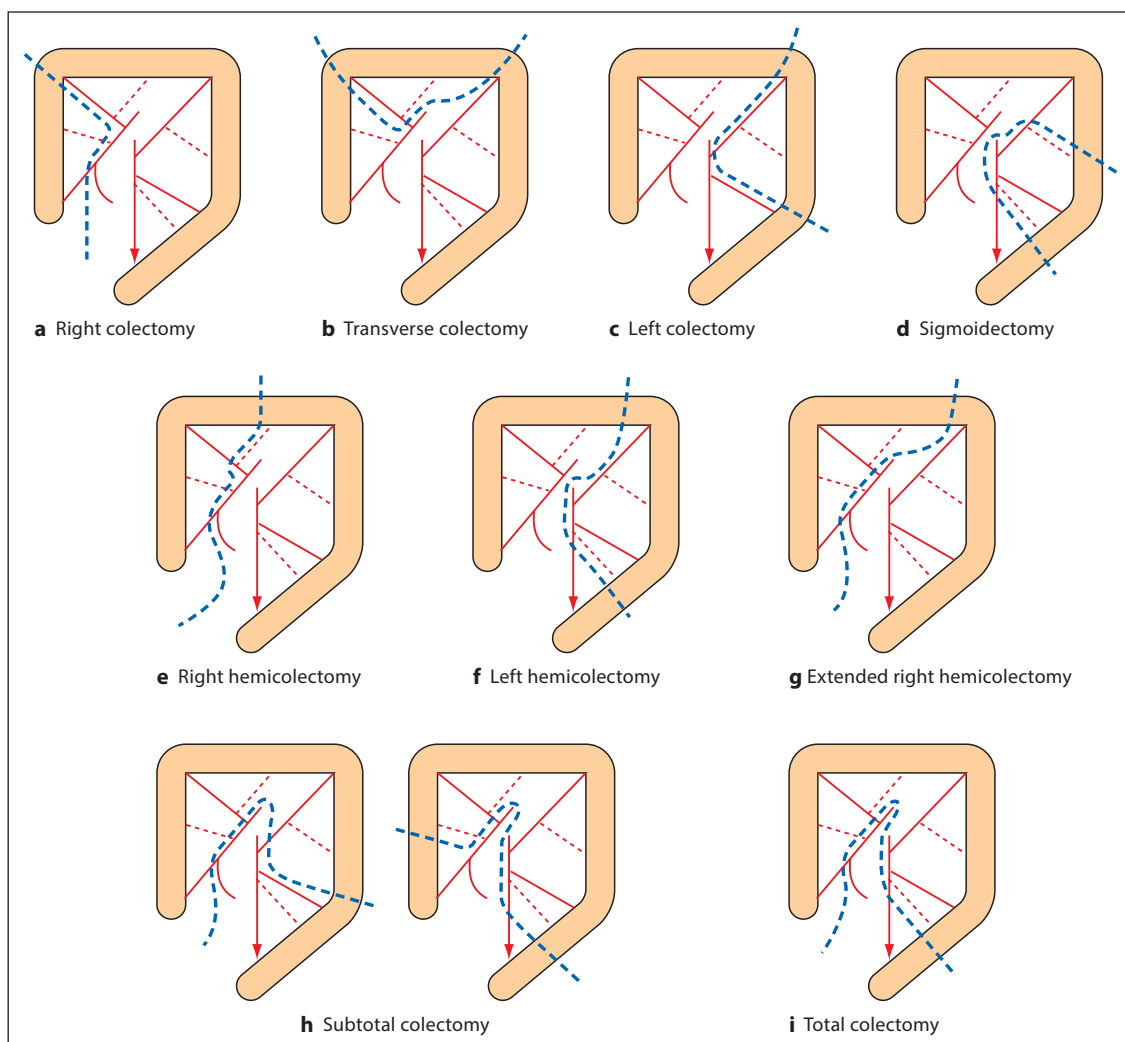
Segmental resection is defined as treatment in which one main artery is divided, whereas hemicolectomy is defined as treatment with a division of two main arteries. In this situation, ligation or division of additional colic arteries does not matter. However, in hemicolectomy, a certain portion of the transverse colon has to be resected in addition to the area of the right or left colon. Extended hemicolectomy thus involves the excision of additional arteries from the MCA. Subtotal colectomy divides three major colic arteries, and total colectomy divides four main colic arteries (fig. 7) [33].

However, there are problems with these ideas, in that the definition of ileocecal resection partially overlaps the definition of right colectomy. In addition, although right hemicolectomy plus left hemicolectomy would logically cover the entire colon, this has actually not been the case. In terms of the embryology of the blood supply, using the left one third as a border between the right and left colon appears to be a good idea.

Low anterior resection of the rectum involves dissection and anastomosis below the peritoneal reflection with ligation of superior and middle rectal arteries. High anterior resection involves anastomosis above the peritoneal reflection [36].

## Discussion

To date, cancer research has been undertaken without adequately addressing the many differences in terminological definitions between countries. Particularly in the treatment of colorectal cancer, differences exist in defini-



**Fig. 7. a–i** Definitions of surgical treatment for colon cancer. Segmental resection is defined as treatment in which one main artery is divided (**a–c**), while hemicolectomy involves division of two main arteries (**e, f**). In this situation, ligation and division of additional colic arteries does not matter. In hemicolectomy, however, a certain portion of the transverse colon has to be resected in addition to the area of the right or left colon. Extended hemicolectomy is performed if an additional artery from the MCA is excised (**g**). Subtotal colectomy is performed if three main colic arteries are divided, while total colectomy involves four main colic arteries (**i**).

tions, such as the names of each segment, the vascular anatomy and surgical procedures for the colon. We therefore considered the definitions of vessel structures and defined the surgical procedures. Today, with advances in diagnostic equipment and chemotherapeutic techniques, comparing the merits of surgical procedures is difficult. However, as a basis for further discussion of whether differences in surgical procedures exert effects on outcomes, exact and consistent definitions of surgical

terms will lead to exact recognition of the surgical procedures applied.

For colorectal cancer, the idea has been suggested that performing wide-ranging colon resection to increase the number of lymph nodes dissected will lead to an improved prognosis. However, with the increasing precision of preoperative computed tomography, narrower lymph node dissection has been considered preferable. With reference to the precise diagnosis of lymph



node metastases using current computed tomography techniques, intraoperative lymph node mapping of an accurately resected specimen by the surgeon should be done immediately postoperatively and histopathological findings should reveal which of the various surgical procedures are most advantageous. However, the definitions of surgical procedures underpin all of these considerations, and without consistent definitions there can be no truly comparative studies of surgical options. The current idea of creating a database of surgical treatments and accumulating data is important. With this idea, unless the underlying surgical terminology is consistently and precisely defined, progress is impossible. In addition, the collection of appropriate cases with pre-

cisely defined surgical procedures based on a rigorous definition of the vascular system is important. Such a system is necessary to guarantee the validity of surgical data.

We have reviewed and made recommendations for the nomenclature of the vascular system of the colon and the surgical techniques applicable to colon cancer. Establishing the basic anatomy of surgery techniques and the nomenclature for surgical procedures are crucial for future progress.

### Disclosure Statement

The authors received no financial support.

### References

- Nelson H, Petrelli N, Carlin A, Couture J, Fleshman J, Guillem J, Miedema B, Ota D, Sargent D: Guideline 2000 for colon and rectal cancer surgery. *J Natl Cancer Inst* 2001; 93:583–596.
- Smith AJ, Driman DK, Spithoff K, Hunter A, Mcleod RS, Simunovic M, Langer B: Guideline for optimization of colorectal cancer surgery and pathology. *J Surg Oncol* 2010;101:5–12.
- Tekkis PT, Smith JJ, Heriot AG, Darzi AW, Thompson MR, Stamatakis JD: A national study on lymph node retrieval in resectional surgery for colorectal cancer. *Dis Colon Rectum* 2006;49:1673–1683.
- Japanese Society for Cancer of the Colon and Rectum: General Rules for Clinical and Pathological Studies on Cancer of the Colon, Rectum and Anus. Revised Version, ed 7 (in Japanese). Tokyo, Kanehara, 2009, pp 36–37.
- Engstrom PF, Arnoletti JP, Benson AB 3rd, Chen YJ, Choti MA, Cooper HS, Covey A, Dilawari RA, Early DS, Enzinger PC, Fakin MG, Fleshman J Jr, Fuchs C, Grem JL, Kiel K, Knol JA, Leong LA, Lin E, Mulcahy MF, Rao S, Ryan DP, Saltz L, Shibata D, Skibber JM, Sofocleous C, Thomas J, Venock AP, Willett C: NCCN Clinical Practice Guidelines in Oncology: colon cancer. *J Natl Compr Canc Netw* 2009;7:778–831.
- Edge SB, Byrd DR, Compton CC, Fritz AG, Greene FL, Trotti A 3rd (eds): *AJCC Cancer Staging Manual*, ed 7. New York, Springer, 2010, pp 173–206.
- Keighley MRB, Williams NS: Anatomy and physiology investigations; in Keighley MRB, Williams NS (eds): *Surgery of the Anus, Rectum and Colon*, ed 3. Philadelphia, Saunders, 2008, pp 1–5.
- Wexner SD, Jorge JM: Anatomy and embryology of the anus, rectum, and colon; in Corman ML (ed): *Colon and Rectal Surgery*, ed 5. Philadelphia, Lippincott Williams & Wilkins, 2005, pp 1–7.
- Mahmoud N, Rombeau J, Ross HM, Fry RD: Colon and rectum; in Townsend CM, Beauchamp RD, Evers BM, Mattox KL (eds): *Sabiston Textbook of Surgery*, ed 17. Philadelphia, Elsevier Saunders, 2004, pp 1401–1403.
- Drake R: Anatomy of the colon; in Nyhus LM, Baker RJ, Fischer JE (eds): *Mastery of Surgery*, ed 3. Boston, Little, Braun, 1997, pp 1403–1406.
- Perlemuter L, Waligora J: Sigmoid colon; in Perlemuter L, Waligora J (eds): *Cahiers D'Anatomie: Abdomen (II)* (transl., in Japanese). Tokyo, Chuou Tosho, 1971, pp 60–76.
- Nivatvongs S, Gordon PH: Surgical anatomy; in Gordon PH, Nivatvongs S (eds): *Principles and Practice of Surgery for the Colon, Rectum, and Anus*, ed 3. New York, Informa Healthcare, 2007, pp 2–4.
- Goligher J, Duthie H: Surgical anatomy and physiology of the anus, rectum and colon; in Goligher J (ed): *Surgery of the Anus Rectum and Colon*, ed 5. London, Bailliere Tindall, 1984, pp 1–7.
- Sonneland J, Anson BJ, Beaton LE: Surgical anatomy of the arterial supply to the colon from the superior mesenteric artery based upon a study of 600 specimens. *Surg Gynecol Obstet* 1958;106:385–398.
- Federative Committee on Anatomical Terminology: *Terminologia Anatomica*. International Anatomical Terminology. Stuttgart, Thieme, 1998.
- VanDamme JP, Bonte J: The superior mesenteric artery; in *Vascular Anatomy in Abdominal Surgery*. Stuttgart, Thieme Medical Publishers, 1990, pp 48–69.
- Steward JA, Rankin JK: Blood supply of the large intestine. Its surgical considerations. *Arch Surg* 1933;26:843–891.
- Jamieson JK, Dobson JF: The lymphatics of the colon. With special reference to the operative treatment of cancer of the colon. *Ann Surg* 1909;2:1077–1090.
- García-Ruiz A, Milsom JW, Ludwig KA, Marchesa P: Right colonic arterial anatomy. Implications for laparoscopic surgery. *Dis Colon Rectum* 1996;39:906–911.
- National Comprehensive Cancer Network Practice Guidelines. [http://www.nccn.org/professionals/physician\\_gls/PDF/colon.pdf](http://www.nccn.org/professionals/physician_gls/PDF/colon.pdf) (accessed January 17, 2012).
- Gillot C, Hureau J, Aaron C, Martini R, Thaler G: The superior mesenteric vein. An anatomic and surgical study of eighty-one subjects. *J Int Coll Surg* 1964;41:339–369.
- Yamaguchi S, Kuroyanagi H, Milson JW, Sim R, Shimada H: Venous anatomy of the right colon. Precise structure of the major veins and gastrocolic trunk in 58 cadavers. *Dis Colon Rectum* 2002;45:1337–1340.
- Mayo CW: Blood supply of the colon: surgical considerations. *Surg Clin North Am* 1955;35:1117–1122.
- Basmajian JV: The main arteries of the large intestine. *Surg Gynecol Obstet* 1955;101:585–591.
- Miles WE: A method of performing abdominoperineal excision for the carcinoma of the rectum and the terminal portion of the pelvic colon. *Lancet* 1908;2:1812–1813.
- Surtees P, Ritchie JK, Phillips RK, et al: High versus low ligation of the inferior mesenteric artery in rectal cancer. *Br J Surg* 1990;77:618–662.
- Pezim ME, Nicholls RJ: Survival after high or low ligation of the inferior mesenteric artery during curative surgery for rectal cancer. *Ann Surg* 1984;200:729–733.

- 28 Lange MM, Buunen M, van de Velde CJH, Lange JF: Level of arterial ligation in rectal cancer surgery: low tie preferred over high tie. A review. *Dis Colon Rectum* 2008;51:1139–1145.
- 29 VanDamme JP, Bonte J: The superior mesenteric artery; in *Vascular Anatomy in Abdominal Surgery*. Stuttgart, Thieme Medical Publishers, 1990, pp 75–76.
- 30 Keighley MRB, Williams NS: Anatomy and physiology investigations; in Keighley MRB, Williams NS (eds): *Surgery of the Anus, Rectum and Colon*, ed 3. Philadelphia, Saunders, 2008, p 8.
- 31 Bonnet S, Berger A, Hentati N, et al: High tie versus low tie vascular ligation of the inferior mesenteric artery in colorectal cancer surgery: impact on the gain in colon length and implications on the feasibility of anastomoses. *Dis Colon Rectum* 2011;55:515–521.
- 32 Steffen C, Bokey EL, Chapus PH: Carcinoma of the splenic flexure. *Dis Colon Rectum* 1987;30:872–874.
- 33 Takahashi T: Artery (2) – division of the basis composition of the artery: anatomic basis of the radical operation for colon cancer (in Japanese). *Shoukakegika* 1993;16(suppl 5): 1732–1741.
- 34 Perlemuter L, Waligora J: Sigmoid colon; in Perlemuter L, Waligora J (eds): *Cahiers D'Anatomie. Abdomen (II)* (transl., in Japanese). Tokyo, Chuou Tosho, 1971, pp 43–59.
- 35 Perlemuter L, Waligora J: Sigmoid colon; in Perlemuter L, Waligora J (eds): *Cahiers D'Anatomie. Abdomen (II)* (transl., in Japanese). Tokyo, Chuou Tosho, 1971, pp 77–94.
- 36 Bleday R, Brindzei N: Surgical treatment of rectal cancer; in Beck DE, Roberts PL, Saclarides TJ, Senagore AJ, Stamos MJ, Wexner SD (eds): *The ASCRS Textbook of Colon and Rectal Surgery*, ed 2. New York, Springer, 2011, pp 743–759.