

Recent studies on aspergillosis in turkey poults

J. L. Richard, J. R. Thurston, W. M. Peden & C. Pinello¹

National Animal Disease Center, U.S. Department of Agriculture, Ames, IA 50010; ¹ Dothan Road, RFD 103, White River Junction, VT 05001, U.S.A.

Abstract

A review of the studies on aspergillosis in turkey poults at the National Animal Disease Center include limited field studies, pathogenicity studies, and vaccine development. Natural ventilation in turkey rearing houses was effective in reducing airborne propagules of four major fungal genera, but the effectiveness of ventilation appeared to be limited by the width of the building. *Aspergillus fumigatus* was more effective than *A. flavus* in producing mortalities in aerosol exposed poults. Toxigenicity of *A. flavus* did not enhance its pathogenicity, and no apparent aflatoxin production occurred during pathogenesis in infected turkey poults. Spores of *A. fumigatus* were disseminated quite rapidly in poults exposed to aerosols, and alveolar macrophages from respiratory lavages taken immediately after exposure contained spores of *A. fumigatus*. Vaccines produced from germlings of *A. fumigatus* and administered to turkey poults were the most efficacious of five vaccines tested against challenge exposure to aerosols of *A. fumigatus* spores.

Introduction

Aspergillosis is a common respiratory disease of avian species (1), and frequently causes mortalities of 5-10% in domestic flocks. The disease usually involves the air sacs and lungs, but may become systemic. The causative agents of the disease belong to the genus *Aspergillus* with *A. fumigatus* as the most frequently isolated pathogen and *A. flavus* as the second most common pathogen. Both species are ubiquitous and the disease is worldwide in occurrence.

Other than occasional reports of outbreaks or unusual infections occurring in various species of birds, there are few recent reports on studies of avian aspergillosis. However, comparative studies of aspergillosis have indicated that turkeys are more susceptible than chickens (2). Only a limited number of studies have been done with aspergillosis of turkey poults. We have investigated some aspects of aspergillosis of turkey poults with limited field studies, pathogenicity studies, and development of

Purchased by U.S. Department of Agriculture for Official Use.

vaccines for protection against aspergillosis in young turkey poults.

Field studies. Infection by *A. fumigatus* or *A. flavus* in turkey poults and other avian species is primarily by inhalation of spores of sufficient number to establish an infection. Airborne spores of these pathogenic fungi are a potential hazard to birds because they occur in confinement rearing houses. Although several investigators have studied the mold flora in poultry houses (3-9), including the flora of litter and the air, little attention has been given to turkey rearing houses.

We had the opportunity to examine the mycoflora in the air and woodchip litter of a turkey confinement brooder house in Iowa during the time in which a group of turkeys were housed. We also examined the flora of lungs, brain, liver and blood and the serologic response of selected birds at various time periods to an *A. fumigatus* antigen (10). The study was done from March to June when the weather changed from winter conditions with snow

and temperatures of -18°C to spring with ambient temperatures as high as 27°C .

Seventy-three species of fungi were isolated from air, litter or tissues. Fifty-nine species were isolated from the air, 33 species from the litter, and 36 species from the tissues (71% from the lungs) of selected poult. Seven species of fungi isolated from tissues were not isolated from either litter or air. Perhaps the source of fungi found in the tissues could have been from the feed. Certainly those species that were found in tissues are common contaminants of feed grains (10). Both *A. flavus* and *A. fumigatus* were isolated once from turkey tissue; *A. flavus* was isolated eight times and *A. fumigatus* was not isolated from air samples taken during the study. Neither species was isolated from the litter. It should be emphasized that aspergillosis was not a problem in this brooder house and that the source of both *A. fumigatus* and *A. flavus* could have been the feed which was not subjected to mycological examination. The major genera found from all isolations were *Scopulariopsis*, *Penicillium*, *Aspergillus*, and *Petriella*. Using these four genera as indicator organisms one can follow the airborne mycoflora density changes in the turkey brooder house during the study under changing conditions, primarily in ventilation (Fig. 1). Prior to samples taken on March 8, the house had been empty of poult for two days, the deep litter had been tilled, the house

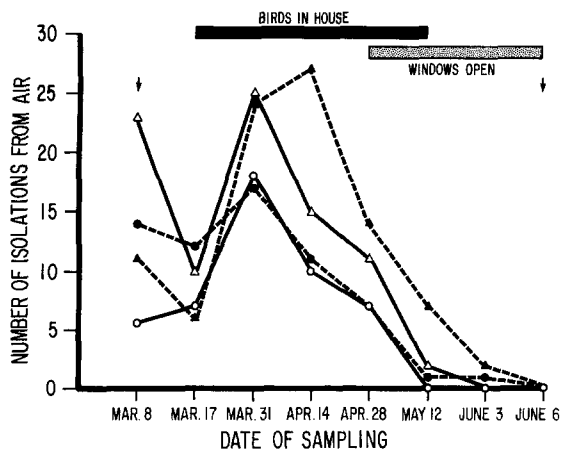


Fig. 1. Changes in the density of airborne propagules of *Scopulariopsis* Δ, *Penicillium* ▲, *Aspergillus* ●, and *Petriella* ○ in a turkey brooder house during a three-month period. Arrows indicate days on which the house was sprayed and the litter was tilled.

sprayed with a water mist and then with a 1% solution of 2 hydromethyl 2 nitro 1,3 propanediol. At this time the windows were opened for ventilation and the number of isolations of those genera varied. However, after the windows were closed and the small poult were in the warmed house (34°C) the number of isolates were lower except for *Petriella*. The number of isolations of these four genera increased initially and then decreased as the weather improved and the windows remained open after April 28. Interestingly, the conditions of the house were similar on March 8 and June 6, yet there were no isolations of these fungi on the latter date. However, the windows in the house had been opened for a much longer period prior to June 8 than on March 8 allowing for a decrease in the population of airborne fungi. While exact measurements were not made, observations on other turkey confinement houses having dust problems, revealed that the airborne dust was considerably reduced with cross ventilation. Also, natural ventilation appeared to be better than forced air ventilation because the latter failed to produce the correct air exchange in the houses to eliminate dusty conditions. Efficient natural ventilation occurred in those houses that were 15.5 m or less in width. In those houses with good ventilation, there were no problems with aspergillosis while those with 'dust' problems had considerable losses primarily caused by aspergillosis.

Of 144 sera tested for antibody to an *A. fumigatus* antigen only four were positive with the gel-precipitin test while 93 were positive with the passive hemagglutination test. The low number of birds having precipitins to *A. fumigatus* was expected as *A. fumigatus* was not isolated from the air or litter during the study. The passive hemagglutination test is considerably more sensitive than the precipitin test but it is less specific in that cross-reactions have been obtained with antisera against *A. niger*, *A. flavus*, *A. ochraceus*, and *Penicillium* sp. (11).

Pathogenicity studies. Only a few studies have been conducted whereby poultry have been experimentally exposed to agents of aspergillosis by aerosol (12). Methods have been developed at the National Animal Disease Center to conduct such exposures in turkey poult so that some degree of reproducibility could be attained. The methods have been described previously (12), and the expo-



Fig. 2. Exposure chamber and apparatus for exposure of turkey poults to aerosols of fungal spores (12).

sure apparatus described is shown (Fig. 2). Briefly, dry spores of *A. fumigatus*, or other fungi, were aerosolized into the plastic aerosol chamber (1 m^3) containing the turkey poults. Assessment of uniformity and concentration of the spore cloud was conducted during all exposures using a particle counter and impingement samplers as described (12).

Several exposures of three-week-old turkey poults to *A. fumigatus* spores were conducted to determine dosages that would kill approximately 50% of the poults within an eight-week postexposure period. Eventually, we determined that aerosolizing 72 mg of spores having a viability of 5×10^6 /mg spores resulted in approximately 5×10^5 colony-forming units/gm of lung tissue in poults killed

immediately after a 10 min exposure. This dose level caused death in about half of the exposed poults in a two-week postexposure period. A comparison was made by exposing a group of poults to 72 mg and another group to 144 mg of spores with the same viability and other conditions similar (Table 1). Doubling the amount of spores did not increase the number of colony-forming units/gm of lung tissue in exposed poults and number of deaths were increased slightly (Table 1). Deaths usually occurred within two weeks postexposure but organisms could be recovered from many surviving poults that were killed at eight weeks postexposure.

Since *A. flavus* is a frequent cause of aspergillosis in poultry (13-16), and since *A. flavus* isolates from the respiratory tract of birds have been shown to

Table 1. Mortality, antibody production, and recovery of *A. fumigatus* from lung tissue of turkey poult exposed to aerosols of *A. fumigatus* spores (16).

Amount of spores aerosolized (mg)	Exposure time (min)	Viable <i>A. fumigatus</i> in lungs colony-forming units/g lung tissue	Deaths	No. positive for precipitating antibody	<i>A. fumigatus</i> recovered
72	10	4.4×10^5	3/9	6/6	5/6 (8 weeks PE ^a)
144	10	5.0×10^5	5/9	3/4	1/4 (8 weeks PE)

^a PE = postexposure.

produce aflatoxin, we compared the pathogenicity of an aflatoxigenic strain of *A. flavus* with a non-aflatoxigenic strain (12). Aerosol exposures of turkey poult were conducted similar to that used for *A. fumigatus*.

Similar results were obtained with both strains of *A. flavus* (Table 2). To attain the quantity of spores/gm of lung tissue, approximating that causing about a 50% death loss with *A. fumigatus*, a larger quantity of spores of *A. flavus* was required (Table 2). Also, the length of time of exposure was increased up to 50 and 60 min to attain the desired exposure. However, even though the exposure dose approximated that which killed about 50% of poult exposed to *A. fumigatus*, only one death occurred among all of the poult exposed to the *A. flavus* strains (Table 2).

While *A. flavus* could be recovered from most of the poult at two weeks postexposure and about 20% of the poult at eight weeks postexposure, none of the poult developed precipitating antibodies to *A. fumigatus* or *A. flavus* antigen (Table 2). Almost all of the poult surviving the *A. fumigatus* exposure developed precipitating antibody to *A.*

fumigatus (Table 1). Results of this comparison of *A. flavus* strains indicated that toxigenicity of *A. flavus* did not enhance its pathogenicity nor did the organism appear to produce aflatoxin in animal tissues as assays for aflatoxin in lung and liver tissues of poult were negative.

No differences were noted in the visible lesions produced by the *A. flavus* isolates or *A. fumigatus*. Grossly, the early lesions noted were small (< 1 mm) white nodules occurring in lung tissues and similar sized caseous plaques on usually thickened air-sac membranes. In well developed cases, the plaques were larger and more numerous on the thickened air-sac membranes; these plaques tended to coalesce in clumps in more advanced cases. In field cases these clumps of caseous material became larger and in some instances would become 3-4 cm \times 1.5-2 cm in size within a single air sac. It was not unusual to find the greenish organism sporulating on the surface of such accumulations.

Histopathologic examination of stained sections of lung tissues from exposed poult revealed no differences in the lesions caused by *A. flavus* or *A. fumigatus* except more tissue was involved in the

Table 2. Mortality, antibody production and recovery of *A. flavus* from lung tissue of turkey poult exposed to aerosols of spores of an aflatoxigenic and a nonaflatoxigenic strain of *A. flavus*.

Amount spores aerosolized (mg)	Exposure time (min)	Viable <i>A. flavus</i> in lungs colony-forming units/g lung tissue	Deaths	No. positive for precipitating antibody	<i>A. flavus</i> recovered
1800 ^a	50	5.3×10^5	0/12	0/12	10/12 (2 weeks PE ^c)
1800 ^a	50	5.3×10^5	0/10	0/10	2/10 (8 weeks PE)
1800 ^b	60	2.9×10^5	0/25	0/25	25/25 (2 weeks PE)
1800 ^b	60	2.6×10^5	1/15	0/14	3/14 (8 weeks PE)

^a Aflatoxigenic strain.

^b Non-aflatoxigenic strain.

^c PE = postexposure.

disease process where *A. fumigatus* was used. The early lung lesion was characterized by small accumulations of lymphocytes, some macrophages and a few giant cells. Later, typical granulomas would be found consisting of a central area of necrosis containing heterophils surrounded by macrophages, giant cells, lymphocytes and some fibrous tissue. The late granulomatous lesion, typically seen in poult surviving the eight-week post-exposure period, consisted of a necrotic center surrounded by giant cells and a thick layer of fibrous tissue (Fig. 3).

Signs of disease in the exposed poult included, depression, drooping wings and head, and dyspnea; occasionally torticollis and, less frequently, cloudiness of the eye were noted. Onset of signs usually occurred no earlier than 48 h postexposure.

During necropsy, occasional birds infected with *A. fumigatus* had white to yellow circumscribed lesions present either in the cerebellum or cerebrum and less frequently in both areas of the brain. These

lesions and the cloudy eye were of frequent enough occurrence that they were considered related to the disease process particularly since torticollis was occasionally observed as a sign of disease (most notably in poult infected with *A. fumigatus*).

Histopathological examination of stained sections of brain lesions revealed solitary abscesses consisting of necrotic centers infiltrated with heterophils and surrounded by giant cells. Hyphae were observed in the central area of some abscesses. The eye lesions were characterized by edema of the pecten and heavily infiltrated with heterophils and mononuclear cells. Typical granulomas could be found in the pecten (Fig. 4). Fungal elements, heterophils, macrophages and cellular debris were found in the chambers and retina of the eye. Edema fluid and some heterophils were found in the sclera and surrounding tissues.

The brain lesions observed were considered to be the result of hematogenous dissemination because

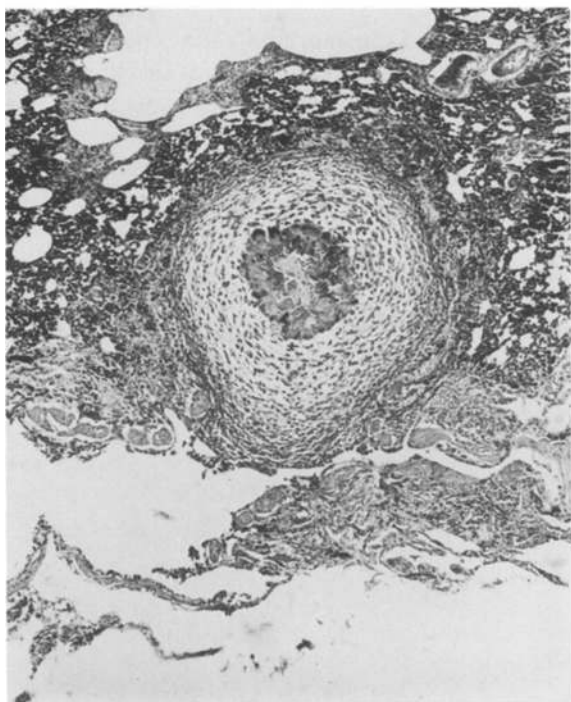


Fig. 3. Late granulomatous lesion of aspergillosis in the lung of a turkey poult, consisting of a necrotic center with giant cells surrounded by a thick layer of fibrous tissue containing a few scattered heterophils. H&E 63 × (12).

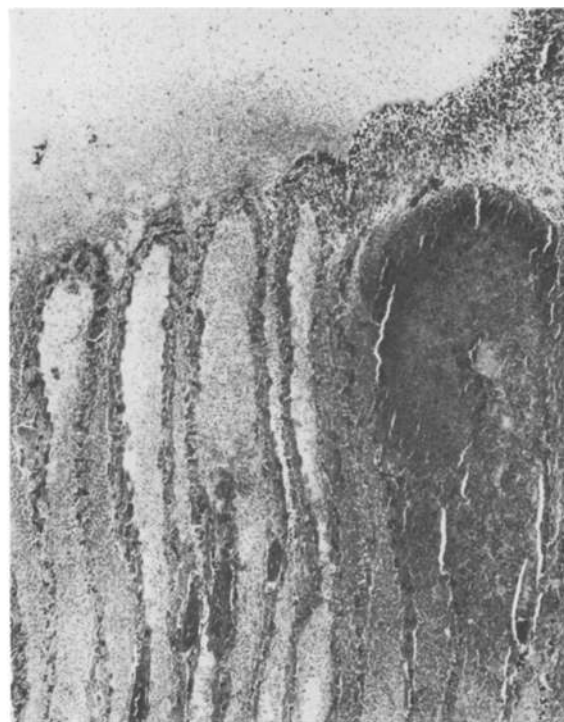


Fig. 4. Lamina of the pecten in the eye of a turkey poult infected with *A. fumigatus*. The pecten is edematous, infiltrated with heterophils and mononuclear cells. Note the granuloma at the right. H&E 40 × (12).

they were typical of lesions described in humans which resulted from hematogenous dissemination (17). Similarly, the eye lesions appeared to be the result of hematogenous dissemination because the infection involved the posterior chamber of the eyes and not the corneal surface as described previously (1). Therefore, we investigated the possibility that spores of *A. fumigatus* entered the blood stream following aerosol exposure of turkey poults.

Twenty-four poults were exposed (two replicates) to an aerosol of *A. fumigatus* spores for 15 min. Blood samples were taken for culture from all birds at 0, 6, 12 and 24 h postexposure. Three poults were killed at each bleeding time except at 24 h postexposure. All remaining poults were killed. Lung, liver, and brain tissues were removed from each poult and cultured (18).

The majority of the poults had spores of *A. fumigatus* in their circulating blood immediately after aerosol exposure for 15 min (Table 3). Also, lung, liver, and brain tissues collected from three poults in each replicate were culturally positive at this time. By 24 h postexposure, many of the poults still had spores in their circulating blood and most tissues were culturally positive.

Similar results of entrance of spores in the blood stream were obtained when *A. flavus* spores were used in a similar study (18).

In an effort to determine the mechanism by which the spores entered the blood stream, a group of turkeys were exposed to an aerosol of *A. fumigatus*, the poults were killed immediately and respiratory lavage was conducted. The suspension was centrifuged, and the pellet of cells resuspended in

M199 medium and the cells were allowed to attach to glass sides by incubation in tissue culture slides for 30 min at 37 °C. Fixed and stained cells could then be observed by light microscopy.

Spores of *A. fumigatus* could be observed as blue-green bodies 3–4 μm in diameter attached to or within the light pink stained cytoplasm of many of the macrophages in the preparation (Fig. 5). Often the macrophages contained more than one spore.

Because phagocytosis (at least ingestion) is quite rapid within the respiratory tract of turkey poults, the rapid appearance of *A. fumigatus* in the blood stream and tissues of exposed poults could be accomplished by macrophage migration from the respiratory tract into the lymphatics and blood.

An unexpected finding was the attachment of spores of *A. fumigatus* to red blood cells washed from the respiratory tract of exposed poults (18). This attachment could result from compatible receptor sites on the red blood cell surface with specific chemical configurations on the spore surface. However, attachment of spores to red blood cells was not a frequent finding and thus would not appear to be a major mechanism for transport of spores from the respiratory tract to circulating blood.

Vaccination studies. Past attempts to immunize rabbits against *Aspergillus fumigatus* infection with 'endotoxin' have produced varying results from affording some protection to no protection (19–21). Viable spores of *A. fumigatus* administered to mice and ducks have provided some protec-

Table 3. Isolation of *A. fumigatus* from blood and other tissues of turkey poults at four time periods after exposure to an aerosol of spores of *A. fumigatus* NADC 0073.

Time (h) after exposure		Blood	Lung	Liver	Brain
0	Replicate 1	16/24 ^a (0.6–11.2) ^b	3/3 (3.2 × 10 ⁵) ^c	3/3 (203)	3/3 (1033)
	Replicate 2	13/24 (0.6– 4.6)	3/3 (3.2 × 10 ⁵)	3/3 (32)	3/3 (26)
6	Replicate 1	6/21 (0.6– 4.6)	3/3 (2.0 × 10 ⁵)	3/3 (122)	3/3 (503)
	Replicate 2	9/21 (0.6– 1.2)	3/3 (5.1 × 10 ⁵)	3/3 (39)	3/3 (23)
12	Replicate 1	12/18 (0.6–22.0)	3/3 (3.3 × 10 ⁵)	3/3 (19)	1/3 (1.1)
	Replicate 2	8/18 (0.6– 5.2)	3/3 (3.2 × 10 ⁵)	3/3 (9)	3/3 (26)
24	Replicate 1	13/15 (0.6– 6.6)	15/15 (1.1 × 10 ⁵)	12/15 (15)	12/15 (36)
	Replicate 2	4/15 (1.2– 3.0)	15/15 (1.2 × 10 ⁵)	9/15 (15)	15/15 (5)

^a Number of birds culturally positive/number of birds exposed.

^b Range of number of colonies/ml of blood.

^c Average number of colonies/g of tissue.

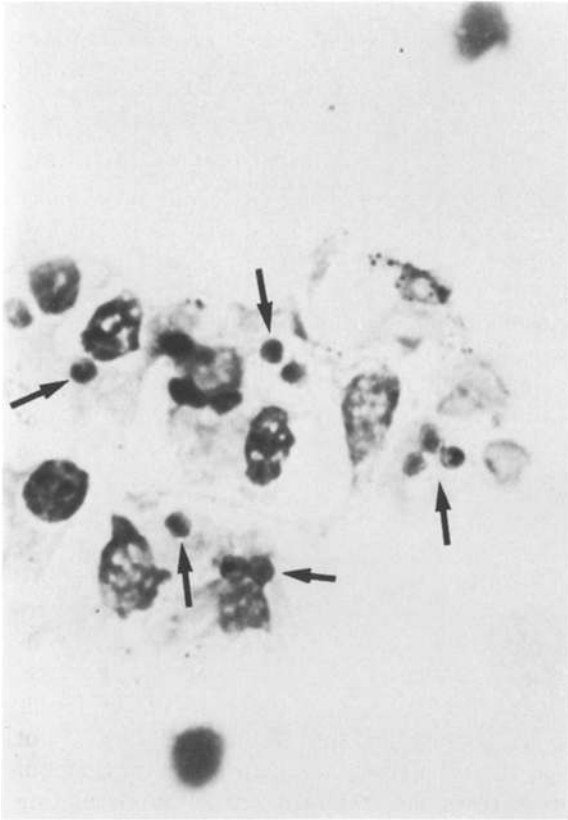


Fig. 5. Spores (arrows) of *A. fumigatus* within the cytoplasm of alveolar macrophages.

tion from death following I.V. challenge exposure (22, 23). No previous attempts have been made to vaccinate turkeys against challenge exposure to *A. fumigatus*. We have conducted three experiments where groups of turkeys were vaccinated with different vaccine preparations and their immunity was challenged by aerosol exposure to *A. fumigatus* spores.

The vaccines, prepared as described (24) from an isolate of *A. fumigatus*, were: a culture filtrate vaccine (I), a spore vaccine (II), a mycelial vaccine (III), and two germling vaccines (IV and V). The germlings in the latter two vaccines were produced on two different media. In the first two experiments, the vaccines were suspended in phosphate buffered saline and the poults were vaccinated by giving each poult two subcutaneous inoculations of the respective vaccine at one and two weeks of age (24). All birds were vaccinated using the same time schedule

in experiment 3, except that the vaccines were prepared by suspending in Freund's complete adjuvant and the vaccines were administered intraperitoneally. All poults were challenge exposed to an aerosol of spores of *A. fumigatus* at one month of age. In experiments 1, 2 and 3, the respective aerosol dose used to challenge expose the turkeys was 2.2×10^6 , 5.2×10^5 and 1.1×10^6 colony-forming units/g of lung tissue. Each vaccine in experiments 1 and 2 was tested in 21 poults and in experiment 3 in 14 poults.

In experiments 1 and 2, the germling vaccine (IV) administered subcutaneously protected 38 and 48%, respectively, of the poults challenge exposed to an aerosol of *A. fumigatus* spores (Figs. 6 and 7). In experiment 3, the other germling vaccine (V) proved most efficacious when administered intraperitoneally, because 57% of the poults were protected to challenge exposure (Fig. 8). Vaccine IV protected 29% of the poults given the challenge exposure. Either the intraperitoneal route is better

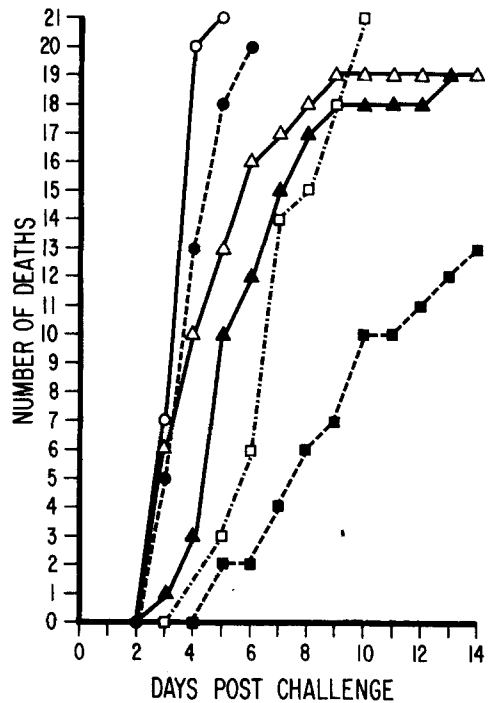


Fig. 6. Mortality of turkeys vaccinated subcutaneously with different vaccines from *A. fumigatus* and challenge exposed with an aerosol of *A. fumigatus* spores of 2.2×10^6 viable U/g of lung tissue (experiment 1). Nonvaccinated controls O; culture filtrate vaccine I ●; spore vaccine II Δ; mycelial vaccine III □; germling D&H vaccine IV ■; germling Neo vaccine ▲.

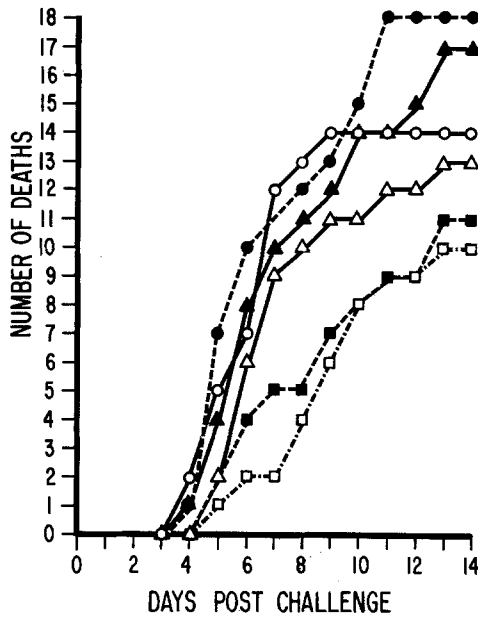


Fig. 7. Mortality of turkeys vaccinated subcutaneously with different vaccines from *A. fumigatus* and challenge exposed with an aerosol of *A. fumigatus* spores of 5.2×10^5 viable U/g of lung tissue (experiment 2). Nonvaccinated controls O; culture filtrate vaccine I ●; spore vaccine II Δ; mycelial vaccine III □; germling D&H vaccine IV ■; germling Neo vaccine V ▲.

than the subcutaneous route for vaccination or perhaps the Freund's adjuvant rendered the vaccine more efficacious. Regardless, the germling vaccines appear to provide the greatest potential for use in further studies of vaccination for avian aspergillosis.

The vaccines do not protect against infection by the organism because there was evidence of considerable infection in survivors based on lesions observed in the lung tissue on histopathologic examination, and the cultural recovery of *A. fumigatus* from lung tissue. Perhaps, the vaccines reduced the severity of the disease or increased resistance resulting in an increase in survivors among those groups having some protection.

While the intraperitoneal route of vaccine administration was investigated for purposes of examining the efficacy of vaccines, this route would not be acceptable as the vaccines caused considerable adhesions in the viscera of these poults. Also, we investigated the possibility of administering vaccines suspended in saline by the intratracheal route. This route was not considered after preliminary

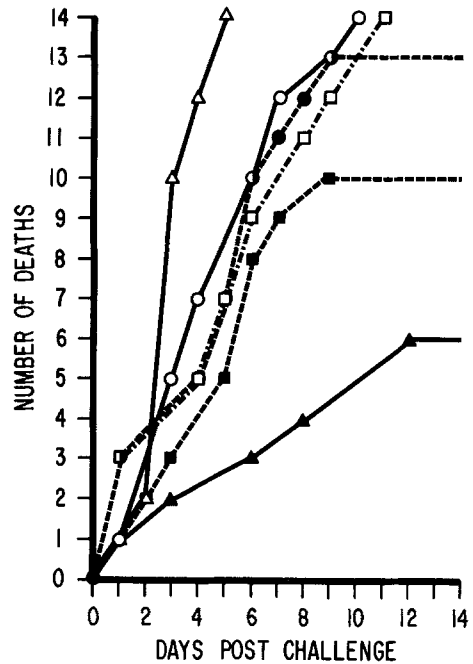


Fig. 8. Mortality of turkeys vaccinated intraperitoneally with different vaccines from *A. fumigatus* and challenge exposed with an aerosol of *A. fumigatus* spores of 1.1×10^6 viable U/g of lung tissue (experiment 3). Nonvaccinated controls O; culture filtrate vaccines I ●; a spore vaccine II Δ; a mycelial vaccine III □; germling D&H vaccine IV ■; germling Neo vaccine V ▲.

studies whereby poults given the second dose of certain vaccines died within a short time after vaccination. Obviously, the intramuscular route of vaccination would not be practical due to tissue destruction. Therefore, further work utilizing the subcutaneous route and adjuvants would appear to be most logical.

Conclusions

1. Field studies have indicated that natural ventilation in a turkey rearing house reduced the airborne mycoflora as evidenced by reduction in the airborne propagules of four major fungal genera. Natural ventilation appeared to be more efficient than forced air ventilation in turkey rearing houses 15.5 m or less in width.
2. While no differences were noted in the visible lesions produced by *A. fumigatus* or *A. flavus* isolates, the latter required more than ten times

the amount of spores aerosolized and a longer period of exposure to attain the quantity of spores/g of lung tissue approximating a 50% mortality with *A. fumigatus*. None of the poult exposed to *A. flavus* developed precipitins while almost all birds exposed to *A. fumigatus* developed precipitins. Toxicogenicity of *A. flavus* did not enhance its pathogenicity and no apparent aflatoxin production occurred during pathogenesis in infected turkey poults. Infections of brain and eyes were not uncommon in birds exposed to aerosols of *A. fumigatus* spores and *A. fumigatus* could be isolated from blood, brain and liver immediately after a 15-min exposure to an aerosol of *A. fumigatus* spores. Spores of *A. fumigatus* could be observed in alveolar macrophages from respiratory lavages taken immediately after such exposures.

3. Vaccines produced from germlings of *A. fumigatus* and administered to turkey poults were most efficacious of five vaccines tested against challenge exposure to aerosols of *A. fumigatus* spores. None of these vaccines protected against infection, but reduced mortalities by 38–57% depending upon route of vaccination and use of adjuvant.

Acknowledgements

This paper makes no endorsement expressed or implied.

References

1. Chute, H. L., 1978. Fungal Infections. In M. S. Hofstad (ed.), Diseases of Poultry. Iowa State University Press, Ames, Iowa: 367–373.
2. Ghori, H. M. & S. A. Edgar, 1973. Comparative susceptibility of chickens, turkeys and coturnix quail to aspergillosis. Poul. Sci. 52: 2311–2315.
3. Lovett, J., J. W. Messer & R. B. Read, 1971. The microflora of southern Ohio poultry litter. Poul. Sci. 50: 746–751.
4. Dennis, C. & J. Gee, 1973. The microbial flora of broiler house litter and dust. J. Gen. Microbiol. 78: 101–107.
5. Curtis, R. F., C. Dennis, J. M. Gu, M. G. Gee, N. M. Griffiths, D. G. Lang, J. L. Peel & D. Robinson, 1974. Chloroanisole as a cause of musty taint in chickens and their formation from chlorophenols in broiler house litter. J. Sci. Food Agr. 25: 811–828.
6. Katoch, R. C., K. B. D. Bhowmick & B. S. Katoch, 1975. Preliminary studies on mycoflora of poultry feed and litter. Indian Vet. J. 52: 759–762.
7. Bacon, C. W. & D. Burdick, 1977. Growth of fungi in broiler houses. Poul. Sci. 56: 653–661.
8. Thi So, D., J. W. Dick, K. A. Holleman & P. Labosky, 1978. Mold spore populations in bark residues used as broiler litter. Poul. Sci. 57: 870–874.
9. Sauter, E. A., C. F. Petersen, E. E. Steele, J. F. Parkinson, J. E. Dixon & R. C. Stroh, 1981. The airborne microflora of poultry houses. Poul. Sci. 60: 569–574.
10. Pinello, C. B., J. L. Richard & L. H. Tiffany, 1977. Mycoflora of a turkey confinement brooder house. Poul. Sci. 56: 1920–1926.
11. Thurston, J. R., G. W. Pugh, Jr. & J. L. Richard, 1983. Natural exposure and antibody to fungi in cattle raised in confinement. Mycopathologia (in press).
12. Richard, J. L., R. C. Cutlip, J. R. Thurston & J. Songer, 1981. Response of turkey poults to aerosolized spores of *Aspergillus fumigatus* and aflatoxinogenic and nonaflatoxinogenic strains of *Aspergillus flavus*. Avian Dis. 25: 53–67.
13. Connole, M. D. & L. A. Y. Johnston, 1967. A review of animal mycoses in Australia. Vet. Bull. 37: 145–153.
14. Knudtson, W. U. & C. F. Meinecke, 1972. Pneumonic aspergillosis in poults caused by *Aspergillus flavus*. Avian Dis. 16: 1130–1132.
15. Palya, V. & T. Balogh, 1971. Brain aspergillosis in goose and poultry. Magy. Allatorv. Lapja 6: 307–310.
16. Palya, V. & T. Balogh, 1972. Cerebral aspergillosis in geese and turkeys. Vet. Bull. 42: 1355.
17. Saravia-Homez, J., 1978. Aspergillosis of the central nervous system. In P. J. Vinken & G. W. Bruyn (eds.), Handbook of Clinical Neurology. North-Holland, Amsterdam: 395–400.
18. Richard, J. L. & J. R. Thurston, 1983. Rapid hematogenous dissemination of *Aspergillus fumigatus* and *Aspergillus flavus* spores in turkey poults following aerosol exposure. Avian Dis. 27: 1025–1033.
19. Henrici, A. T., 1939. An endotoxin from *Aspergillus fumigatus*. J. Immunol. 36: 319–338.
20. Tilden, E. B., E. H. Hatton, J. Freeman & W. M. Williamson, 1957. Studies of aspergilli from captive birds. Bact. Proc. 144.
21. Tilden, E. B., E. H. Hatton, S. Freeman, W. M. Williamson & V. L. Koenig, 1961. Preparation and properties of the endotoxins of *Aspergillus fumigatus* and *Aspergillus flavus*. Mycopathol. Mycol. Appl. 14: 325–346.
22. Smith, G. R., 1972. Experimental aspergillosis in mice: aspects of resistance. J. Hyg. (Lond.) 70: 741–754.
23. Asakura, S., S. Nakagawa, M. Masui & J. Yasuda, 1962. Immunological studies of aspergillosis in birds. Mycopathol. Mycol. appl. 18: 249–256.
24. Richard, J. L., J. R. Thurston, R. C. Cutlip & A. C. Pier, 1982. Vaccination studies of aspergillosis in turkeys: Subcutaneous inoculation with several vaccine preparations followed by aerosol challenge exposure. Am. J. Vet. Res. 43: 488–492.