

Rectal biopsy as an aid to cancer control in ulcerative colitis

B. C. MORSON AND LILLIAN S. C. PANG

From the Research Department, St. Mark's Hospital, London

EDITORIAL COMMENT This is a very important paper as it provides the clinician with a new method of identifying patients with total colitis who may be particularly exposed to the risk of carcinoma. Rectal biopsies of flat mucosa may demonstrate a certain cellular pattern which has been shown to be particularly associated with carcinoma.

There is general agreement that malignant change in ulcerative colitis mostly occurs in those patients whose large intestine is totally involved and have a history of symptoms for more than 10 years. Having thus defined the population of colitics most at risk the problem remains of identifying the individual patient destined to get carcinoma. There is yet no evidence that all the population at risk will eventually develop malignant change. It has been previously pointed out that some test is required which will decide that a patient with ulcerative colitis has entered a precancerous phase (Morson, 1966).

The detection of epithelial changes suggestive of precancer or carcinoma *in situ* in rectal biopsies from patients with ulcerative colitis prompted an investigation into the incidence and extent of such changes in colectomy specimens removed for colitis with and without malignant change. The results of this enquiry are reported here as well as an analysis of the first nine patients in whom the diagnosis of precancer was made in a rectal biopsy and played an important part, together with clinical and radiological observations, in the subsequent decision to perform total proctocolectomy.

MORPHOLOGY OF PRECANCER IN COLITIS

There are two main types of precancer in ulcerative colitis: the polypoid variety and precancerous change in a flat mucosa.

Precancerous polypoid changes in ulcerative colitis have been described and illustrated by Dawson and Pryse-Davies (1959). The appearances are similar to those found in solitary adenomas and villous papillomas of the colon and rectum without any colitis although there are some significant

differences. The polyps are nearly always multiple although few in number compared with inflammatory polyps. They are sessile, cover a relatively large field of mucosa and commonly have a villous or papillary surface configuration (Figs. 1 and 2) rather than the typical adenomatous appearance. In our experience the circumscribed, adenomatous polyp on a stalk so common as a solitary lesion and in familial polyposis is seldom seen as part of the precancerous phase of ulcerative colitis. The fact that the villous growth pattern is the commoner type of neoplastic change may be important, for there is evidence that this is more prone to produce invasive carcinoma than the adenomatous variety (Grinnell and Lane, 1958). However, many of the precancerous polyps of ulcerative colitis have a mixed villous and adenomatous structure and may be referred to as papillary adenomas. Another distinctive feature of precancerous polyp formation in ulcerative colitis is the presence of an obvious inflammatory component. This is in continuity with the inflammation in surrounding flat mucosa. The cytological changes found in these neoplastic or precancerous polyps of ulcerative colitis are described below. They are essentially similar to those seen in solitary adenomas and villous papillomas.

It would appear from our studies that neoplastic or precancerous change in ulcerative colitis more commonly occurs in a flat rather than a polypoid mucosa. This cannot be detected by macroscopic examination alone. However, those areas showing precancerous change at a microscopic level of observation vary in their macroscopic appearance from mucosa which looks almost normal to obviously inflamed mucous membrane. Perhaps the commonest change is a rather thick mucosa with a finely nodular or velvety surface configuration.

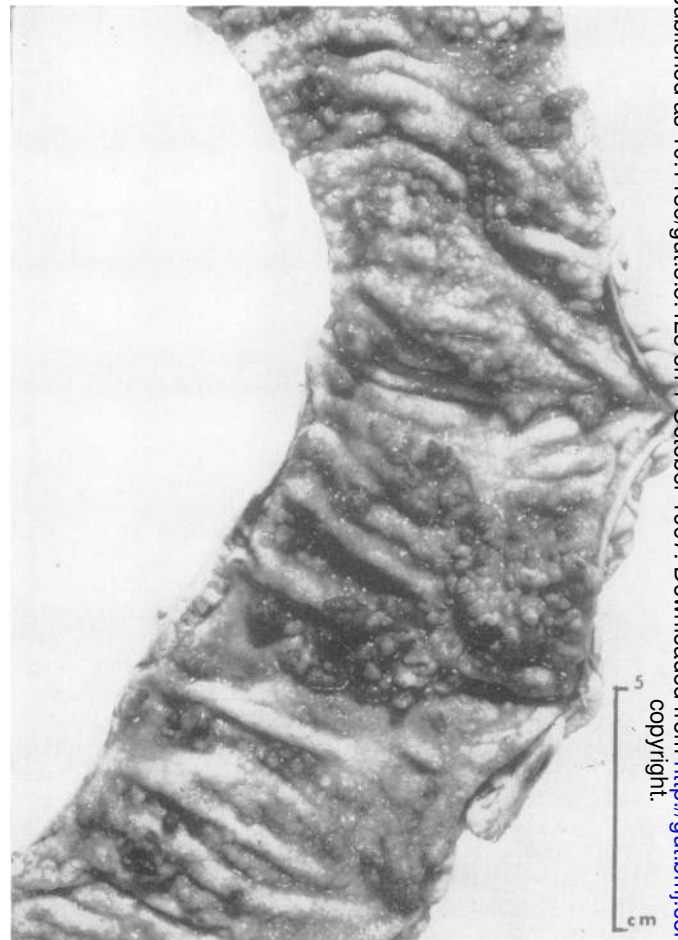
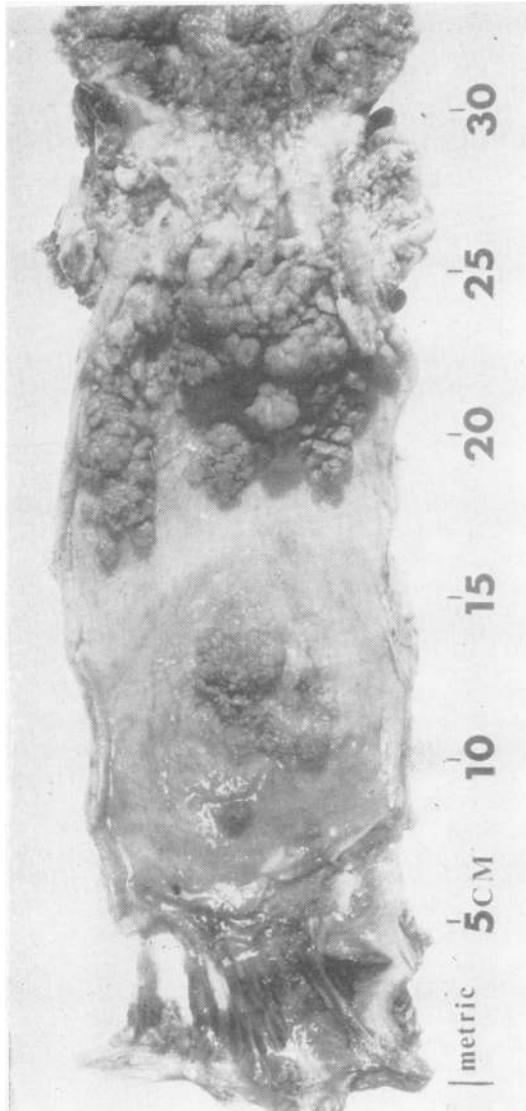


FIG. 1. Case 3 (Table III). Sigmoid colon and rectum. In the upper part of the specimen there is extensive papillary tumour which is partly benign but contains a malignant stricture about 5 cm. long. In the rectum there are smaller areas of villous overgrowth of the mucosa.

FIG. 2. Case 7 (Table III). Mucosal surface of colon showing patchy polypoid change which has nodular and papillary surface configuration.

MICROSCOPIC FEATURES The histological and cytological criteria for the diagnosis of precancer in colectomy specimens and rectal biopsies for ulcerative colitis are fundamentally the same as those used for other precancerous conditions of the intestine such as adenomas and villous papillomas. Moreover, they are no different from those used for precancerous lesions or carcinoma *in situ* in other organs such as cervix, bladder, and skin.

Precancerous polyps There is adenomatous or villous overgrowth (Fig. 3) of the intestinal epithelium in a polypoid form. The epithelial cells show

loss of goblet cell secretion and the nuclei are stratified, hyperchromatic, irregular in shape and size, and show many mitotic figures. Sometimes there is an excess of mucin production associated with the villous type of proliferation, as seen in some solitary villous tumours of the colon and rectum. These histological and cytological changes are associated with a variable amount of inflammation of the lamina propria, but usually more than that seen in ordinary adenomas and villous papillomas.

Precancer in flat mucosa (Figs. 4-10) The microscopic features of precancer or carcinoma *in situ* in a

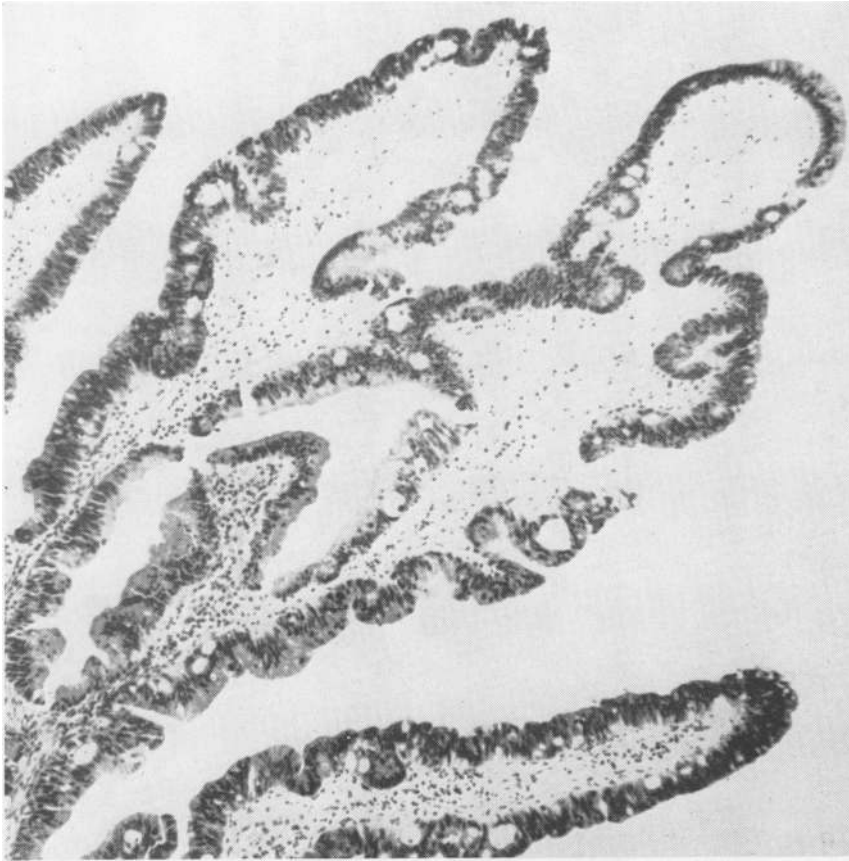

FIG. 3. Case 3 (Table III). Precancerous change in rectal biopsy; there is villous overgrowth of the mucosa and the epithelium shows loss of goblet cell secretion and stratification of nuclei which are also hyperchromatic. H. & E. \times 100.

flat mucosa are of particular importance because the changes can only be identified at the microscopic level of observation. The mucous membrane is intact and either of normal thickness or rather thicker than normal. The epithelial tubules tend to lose their normal parallelism and become irregular in shape and size. They show lateral budding and frequently adopt a vertical or villous growth pattern (Fig. 4). An important characteristic is the tendency to misplacement of the proliferating epithelial tubules through the muscularis mucosa into the superficial submucosa (Fig. 5). Dukes (1954) drew attention to this feature as important in the pathogenesis of invasive carcinoma in ulcerative colitis. However, it is sometimes impossible to decide whether the epithelium is just misplaced as a result of chronic inflammation or that the appearance is, in fact, an early stage of invasive carcinoma.

The amount of inflammation in the flat precancerous mucosa of ulcerative colitis is variable but seldom severe. Indeed it may be completely absent.

It usually takes the form of an increase in the inflammatory cell content of the lamina propria with some hyperplasia of lymphoid follicles and occasional crypt abscesses. There may be some inflammatory infiltration of the superficial submucosa but the deep layers of the bowel wall are not usually affected. The absence of signs of active or acute inflammation, such as vascular congestion and oedema with mucosal destruction, is significant because of the clinical observation that malignant change in ulcerative colitis is most commonly found in patients with a long history of mild or quiescent disease.

The cytological changes of precancer in ulcerative colitis are identical with those seen in other organs. There is loss of function in the form of a diminution of the amount of mucus secretion with irregularity in size and shape of the cells which are often larger than normal. The nuclei are stratified, enlarged, hyperchromatic and vary in shape with prominent nucleoli and a coarse chromatin pattern (Figs. 6 and 7). Moreover, the size of the nuclei is considerably

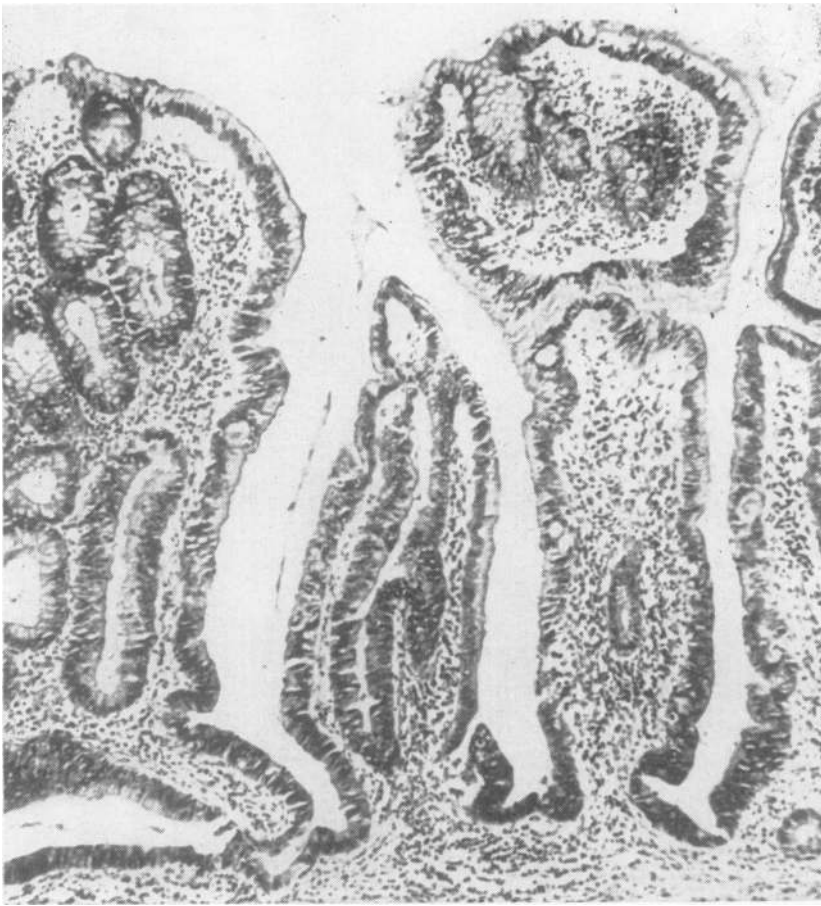

FIG. 4. *Case 3 (Table III). Precancerous change in flat mucosa. The epithelial tubules have lost their normal parallelism, are irregular in shape and size, and have adopted a villous growth pattern. There is inflammation of the lamina propria. H. & E. $\times 80$.*

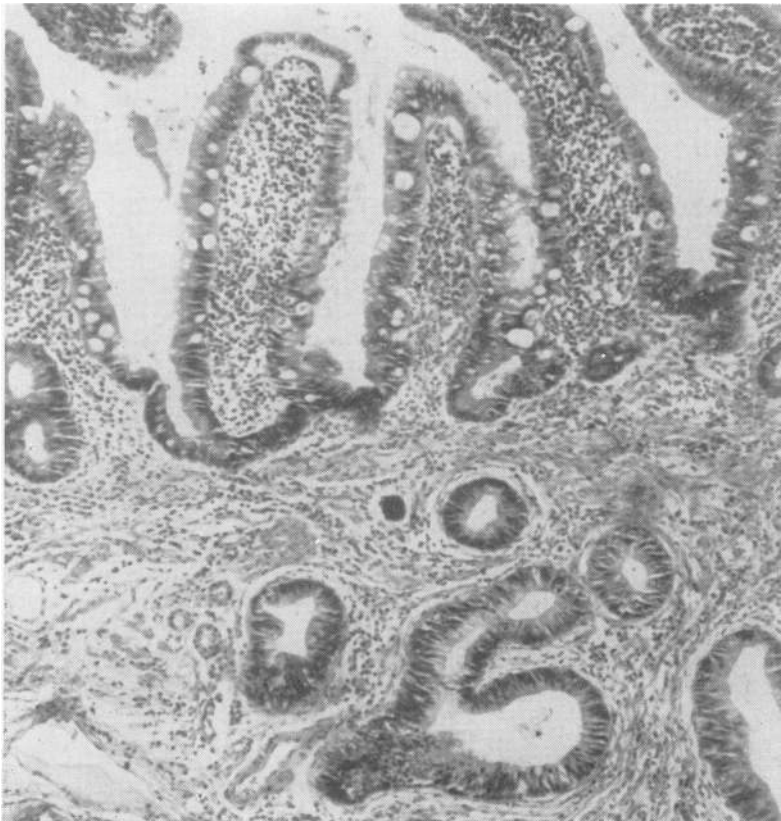


FIG. 5. *Precancerous change in flat mucosa with villous growth pattern and misplacement of proliferating epithelial tubules through the muscularis mucosa into the superficial submucosa. There is inflammation of the lamina propria. H. & E. $\times 100$.*

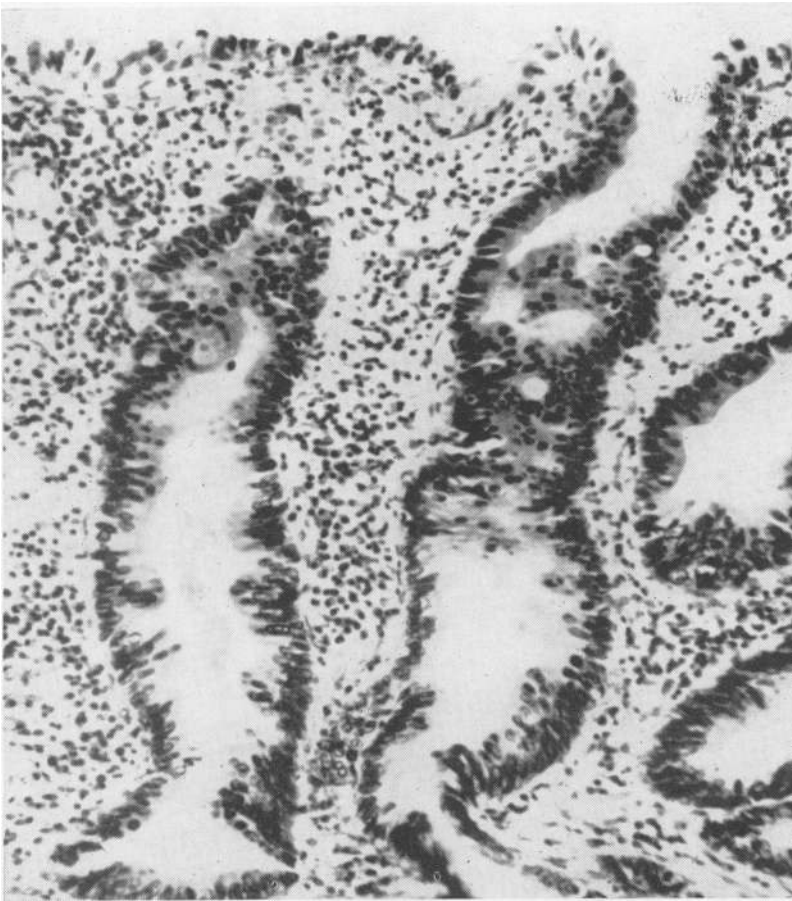

FIG. 6. *Precancerous change in flat mucosa. The epithelial tubules are irregular in shape and the lining epithelium shows stratification of nuclei which are very hyperchromatic. There is almost complete loss of goblet cell secretion; also inflammation of the lamina propria. H. & E. \times 300.*

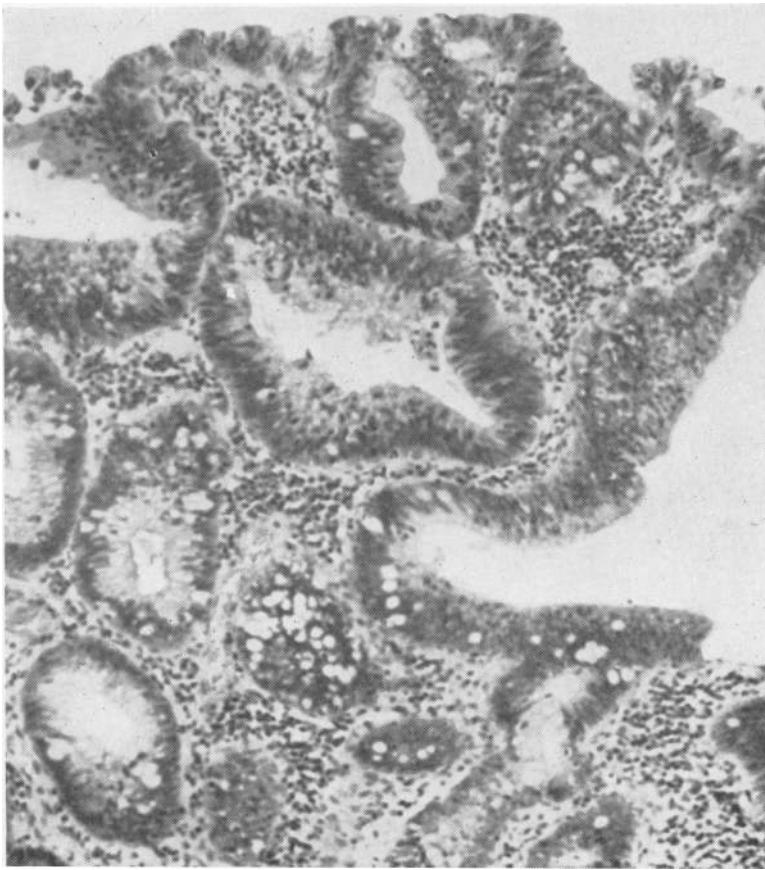


FIG. 7. *Precancerous change in flat mucosa. There is adenomatous overgrowth of the tubules and the lining epithelium shows stratification of nuclei which are very hyperchromatic. The lamina propria contains chronic inflammation. H. & E. \times 180.*

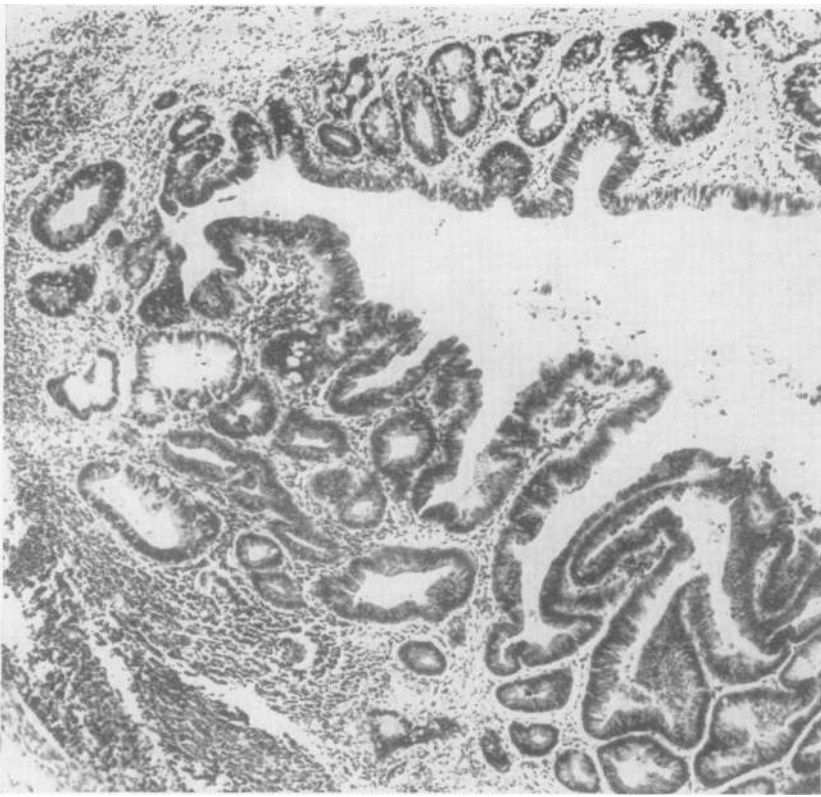


FIG. 8. *Precancerous change in flat mucosa. There is a transition from hyperplastic epithelium to severe precancerous change with adenomatous overgrowth of the tubules. H. & E. \times 25.*

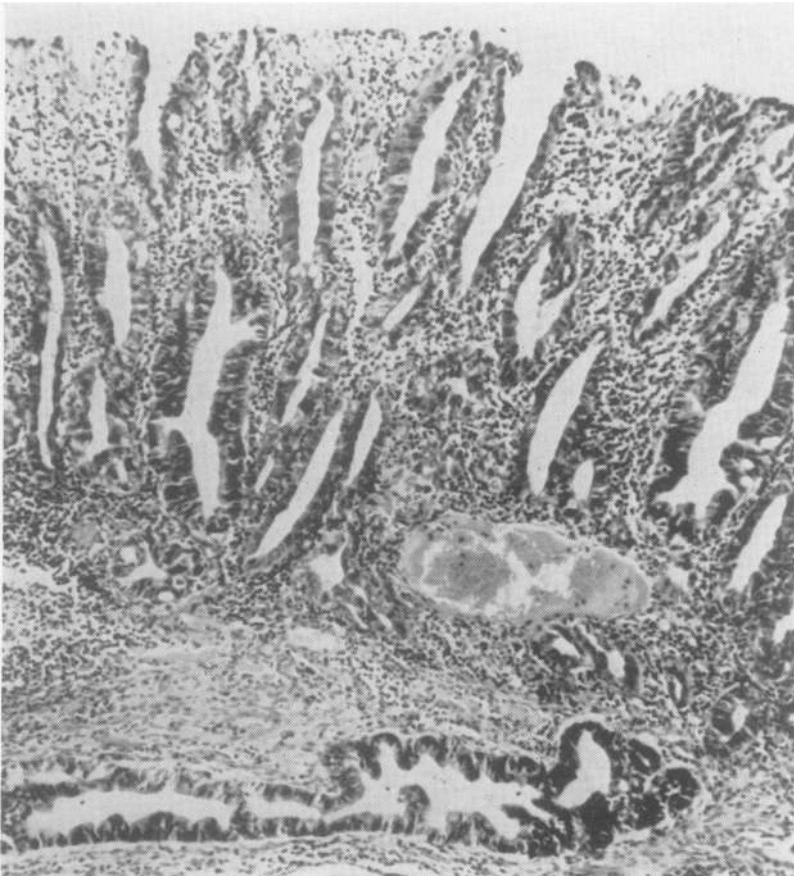


FIG. 9. *Case 5 (Table III). Precancerous change in flat mucous membrane with underlying invasion by adenocarcinoma. There is much inflammation of the lamina propria. H. & E. \times 140.*

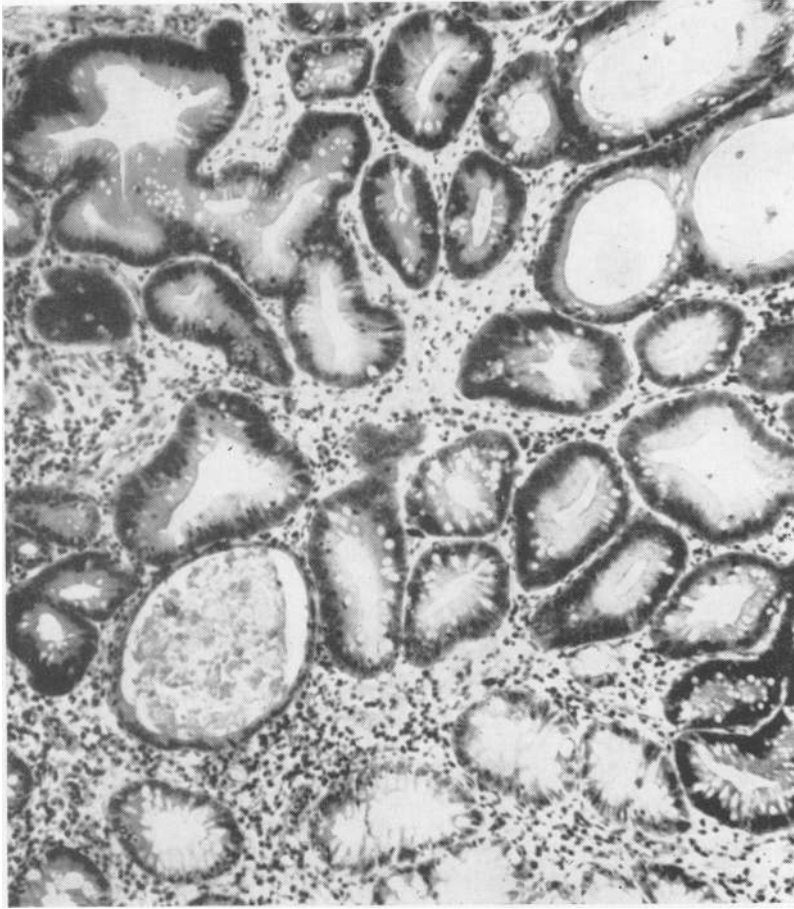


FIG. 10. Case 7 (Table III). Precancerous change in rectal biopsy. There is mild chronic inflammation in the mucosa. The epithelial tubules are irregular in size and shape and lined by nuclei which are stratified and hyperchromatic with many mitotic figures. H. & E. $\times 175$.

increased relative to the amount of cytoplasm. The severity of precancerous change is variable and stages of transition from relatively normal mucosa through precancerous epithelium to invasive carcinoma can be readily demonstrated (Fig. 8). Precancer in flat mucosa is usually a diffuse change and can affect almost the entire large bowel mucosa. Commonly it occurs in patches and mostly in the distal parts of the colon and rectum.

The criteria for the diagnosis of precancer, especially in rectal biopsies, must be adhered to strictly for reactive hyperplasia can produce cytological changes in the epithelial cells which may be confused with neoplastic transformation. However, reactive hyperplasia is usually associated with a much greater degree of inflammation, crypt abscess formation, epithelial destruction and ulceration. The epithelial cells may show nuclear changes, including a tendency to hyperchromatism and an increase in the number of mitotic figures, but there is no stratification with variation in the size and shape of nuclei.

The lateral budding and villous growth pattern of the epithelial tubules mentioned above is also absent.

A considerable increase in the number of Paneth and argentaffin cells has been noted in areas of precancerous mucosa. In the absence of any knowledge of the function of these cells it can only be presumed that this is a feature of the longstanding chronic colitis rather than the neoplastic change (Watson and Roy, 1960). However, it has been shown that Paneth cells are common in those polyps of the large intestine which are generally regarded as precancerous (Gibbs, 1967), and it is therefore possible that in colitis they are sometimes part of the neoplastic process.

PRECANCER IN COLECTOMY SPECIMENS OF COLITIS AND CANCER

A retrospective study was made of 27 surgical specimens of ulcerative colitis with cancer of the colon or rectum. Four of these were rejected because

of inadequate information about the pathology or clinical features. The incidence of precancer in the mucosa of the remaining 23 specimens was estimated together with the relationship to length of history and extent of colitis.

The pathological features of precancer were present in the mucous membrane of all 23 colectomy specimens removed for colitis in which one or more invasive carcinomas were found. The precancerous changes were very extensive involving large areas of mucosa away from sites of invasive carcinoma as well as in their immediate vicinity. It has not been possible to measure the extent of precancer in these colectomy specimens with any precision but it was a very diffuse process in many cases, as judged by the examination of many sections from different parts of the colon and rectum. In some specimens the entire mucosa of the large bowel appeared to be affected although the severity of the changes varied. In general the precancerous changes were more frequent and extensive in the left colon and rectum.

All 23 specimens of ulcerative colitis with invasive cancer had total colitis as judged by clinical, radiological, or pathological evidence. Nineteen patients gave a history of more than 10 years and nine of these for more than 20 years; four had a history of less than 10 years.

PRECANCER IN COLECTOMY SPECIMENS FOR COLITIS

A consecutive series of 172 colectomy specimens for ulcerative colitis were examined retrospectively for the incidence of precancer together with the relationship to extent of colitis and length of history (Table I). In 12 precancer was found but only in patients with total colitis. The incidence of precancer in the 134 patients with total colitis was therefore 9.0%. Of the 12 patients with precancerous change nine had a history of colitis exceeding 10 years and three under 10 years. The extent of precancer was extremely variable ranging from small patches to large areas of involved mucosa.

PRECANCER IN RECTAL BIOPSIES

A retrospective study was made of 148 consecutive

TABLE II

INCIDENCE OF PRECANCER IN RECTAL BIOPSIES FROM PATIENTS WHO HAD A SUBSEQUENT COLECTOMY

Length of History (yr.)	No. of Cases Biopsies	Precancer	
		No. of Cases	Incidence (%)
Under 10	26	1	4.0
10-20	15	9	60.0
Over 20	13	6	46.1
All cases	54	16	29.0

rectal biopsies of patients with ulcerative colitis. Ninety-four have had medical treatment only but none showed any evidence of precancer in the rectal biopsy. The remaining 54 biopsies were carried out on patients who had a subsequent colectomy (Table II). Sixteen (29%) of these showed the appearances of precancer and similar precancerous changes were found in the colectomy specimen. All had total colitis, but there was no invasive carcinoma present. Twelve of these are also included in Table I. All but one of the rectal biopsies regarded as precancerous were from patients with a history of colitis for more than 10 years. Thirty-eight rectal biopsies negative for precancer showed no precancerous change in the subsequent colectomy specimen.

During recent years the diagnosis of precancer has been made by rectal biopsy in nine patients who were under clinical and radiological investigation for the state of their colitis. In these cases the discovery of precancer in a rectal biopsy influenced the decision to carry out surgical treatment. A summary of the clinical history, surgical treatment, and pathology is given in Table III.

There were seven women and two men. Eight had a long history of symptoms exceeding 10 years and one for eight years. All nine patients had total colitis confirmed radiologically or by examination of the colectomy specimen.

Biopsy of polypoid lesions in the rectum of two patients showed precancer. The other seven had precancer in flat mucosa.

One patient (case 1) had an inoperable growth of the sigmoid at laparotomy. The other eight were all treated by total proctocolectomy. Invasive carcinoma as well as extensive precancer were found in

TABLE I

INCIDENCE OF PRECANCER IN COLECTOMY SPECIMENS FOR COLITIS

Length of History (yr.)	Total Colitis		Subtotal Colitis		All Cases	
	No. of Cases	Incidence of Precancer	No. of Cases	Incidence of Precancer	No. of Cases	Incidence of Precancer
Under 10	88	3(3.4%)	22	Nil	110	7 3(2.7%)
10-20	31	7 9(19.6%)	7	Nil	38	9(14.5%)
Over 20	15	2 12(9.0%)	9	Nil	24	2 12(7.0%)
All cases	134		38	Nil	172	

TABLE III

Case No.	Sex	Age at Onset of Colitis	Length of History (yr.)	Extent of Colitis	SUMMARY OF CLINICAL FEATURES AND PATHOLOGY				
					Rectal Biopsy	Surgical Treatment	Pathology of Colectomy Specimen		
					Type of Mucosa Showing Precancer		Severity of Colitis	Extent of Precancer	Invasive Carcinoma
1	F	20	46	Total	Flat	Inoperable		Not available	Sigmoid
2	F	23	24	Total	Flat	Proctocolectomy	++	Not available	Descending colon
3	F	27	24	Total	Polypoid	Proctocolectomy	+	Sigmoid and rectum	Sigmoid
4	M	27	18	Total	Flat	Proctocolectomy	+	Transverse colon to rectum	Rectum
5	F	46	13	Total	Flat	Proctocolectomy	++	Total	Descending colon
6	M	41	8	Total	Flat	Proctocolectomy	+	Caecum to descending colon; rectum	None
7	F	46	12	Total	Flat	Proctocolectomy	++	Total	None
8	F	18	17	Total	Flat	Proctocolectomy	+++	Total	None
9	F	24	27	Total	Polypoid	Proctocolectomy	+	Lower rectum	None

four of these specimens. In four others only precancerous mucosa was found. The invasive carcinomas were in the descending colon (cases 2 and 5) and the sigmoid and rectum (cases 3 and 4). In case 5 the invasive carcinoma was of microscopic size, although it had penetrated the full thickness of the bowel wall.

The extent and severity of the precancerous changes in the eight proctocolectomy specimens varied. In one patient (case 5) there was precancer in flat mucosa throughout the colon and rectum. In two others (cases 7 and 8) there were large patches throughout the large bowel. One of these (case 8) showed widespread precancer of the polypoid type as well as similar changes in flat mucosa. In cases 4 and 6 there was patchy but quite extensive precancer in flat mucosa confined to the left colon and rectum. Case 3 showed patchy polypoid precancer in the sigmoid and rectum, the intervening flat mucosa showing a mild colitis with patchy precancerous change. In case 9 there was patchy polypoid precancer in the lower rectum only. Case 2 could not be assessed for extent of precancer as the histological sections of the bowel were not labelled for site.

Table III also gives an assessment of the severity of the colitis. In only one (case 8) was this at all severe, showing diffuse chronic inflammation with much crypt abscess formation and areas of full-thickness mucosal ulceration. In cases 2, 5, and 7 the severity of the colitis was graded as moderate and in three cases (3, 4, and 6) as slight. The inflammation in the latter appeared to be of a residual character. In case 9 the mucosa of the entire large intestine showed atrophy only with a little increase in the inflammatory cell content of the lamina propria in some areas. Moreover, there was evidence of healed colitis in the macroscopic examination of the specimen in the form of extensive submucosal scarring.

The following three case reports are representative

of the value of rectal biopsy. The first (case 3) is a patient with a long history of colitis in whom sigmoidoscopic and radiographic opinion was suggestive of malignant change. This was reinforced by the presence of polypoid precancer in the rectal biopsy. The second (case 5) is a patient with a long history of colitis in whom there was no clinical or radiographic evidence of carcinoma, but the biopsy showed precancer in a flat mucosa. The colectomy specimen showed only a single small focus of adenocarcinoma in the descending colon about 1 cm. in diameter. The third (case 7) is a patient with a long history of total colitis but no clinical or radiographic evidence of malignancy. Rectal biopsy showed precancer in a flat mucosa. Only extensive precancer was found in the operation specimen.

COLITIS AND CANCER (CASE 3, TABLE III) Twenty-four years intermittent diarrhoea, sometimes with rectal bleeding. Recent loss of weight and pain in left iliac fossa. Sigmoidoscopy showed proctitis with an area of polypoid mucosa at 8 cm. Barium enema radiographs revealed total colitis and narrowing of the sigmoid very suggestive of carcinoma.

Rectal biopsy (Fig. 3) of the polypoid mucosa showed 'villous and adenomatous hyperplasia of the rectal mucosa but no sign of invasion by carcinoma. The appearances are certainly precancerous'.

Operation Total proctocolectomy in two stages.

Pathology of surgical specimens The colon from the caecum to the descending part is shortened with contraction of the lumen and a granular atrophic appearance of the mucous membrane. The sigmoid colon (Fig. 1) shows extensive papilliferous or villous overgrowth of the mucosa over a length of 15 cm. in the middle of which there is a malignant stricture about 5 cm. long. There is extensive invasion of the pericolonic fat by carcinoma. In the rectum there is one area of sessile villous overgrowth of the rectal mucosa about 4 cm. in diameter and a second smaller area 1 cm. diameter. The remainder of the rectal mucosa is intact but has an atrophic appearance.

Microscopy shows mild chronic inflammation throughout the mucosa of the large intestine. There is atrophy of the mucous membrane in the proximal colon but no definite evidence of precancerous change. In the sigmoid there is extensive villous and adenomatous overgrowth of the rectal mucosa with focal invasion by mucus-secreting adenocarcinoma. The rectum shows extensive precancerous change in flat mucosa (Fig. 4) as well as the two areas of villous overgrowth, but no sign of invasion by carcinoma. The regional lymphatic glands are not involved.

Follow-up Well two years after operation.

COLITIS AND EARLY CANCER (CASE 5) Intermittent diarrhoea and bleeding per rectum for 13 years. Sigmoidoscopy showed appearances typical of ulcerative colitis. Barium enema radiographs confirmed colitis but there was no evidence of malignancy.

Rectal biopsy 'Moderate inflammation of the mucosa with some superficial erosion. The epithelial tubules are strikingly irregular with villous change and the lining epithelium shows bizarre nuclear changes. The appearances are those of pre-invasive carcinoma'.

Operation Total proctocolectomy.

Pathology of surgical specimen The entire colon and rectum is shortened with thickening of the bowel wall. The mucous membrane appears abnormal throughout but the severity of the changes varies from the caecum to the rectum. In the right colon the mucosa is intact but thick and slightly granular. In the transverse part it is even thicker and has a finely nodular surface appearance. Just beyond the splenic flexure is an area about 5 cm. diameter where the mucosa is particularly thick and has a velvety surface. In the middle of this the cut surface of the bowel wall shows a hard white nodule about 1 cm. diameter. The mucosal surface in the sigmoid colon and rectum shows scattered areas of serpiginous ulceration and the intervening mucosa is velvety and atrophic.

Microscopy of the caecum and ascending colon shows a slight increase in the chronic inflammatory cell content of the lamina propria but the epithelial tubules are extremely hyperplastic and have the appearance of early precancerous change. In the transverse colon these precancerous changes are more advanced. In addition there are occasional crypt abscesses and much distortion of the glandular pattern to produce a low villous and adenomatous appearance. In the descending colon there are advanced precancerous changes, particularly marked in the area of mucosal thickening just below the splenic flexure mentioned above. The hard white nodule is a moderately well differentiated adenocarcinoma of an average grade of malignancy invading the deep muscle layers and the serosa (Fig. 9). Other sections taken from the region of the descending colon show a tendency to submucosal invasion by precancerous epithelium but no frank carcinoma. In the sigmoid colon and rectum the mucosal epithelium is atrophic with a low villous and adenomatous growth pattern. Many Paneth cells are present and some crypt abscess formation.

Follow-up Well six months after operation.

COLITIS AND PRECANCER (CASE 7) Diarrhoea and rectal

bleeding for 12 years. Sigmoidoscopy showed a granular proctitis with some contact bleeding. Barium enema radiographs revealed total colitis, but no sign of malignancy. Colectomy advised on clinical evidence.

Rectal biopsy (Fig. 10) 'Mild chronic inflammation in a mucosa which contains significant epithelial changes. The tubules are irregular in size and shape with complete loss of parallelism. They are lined by cells which are stratified, show a diminution in the amount of mucus secretion, and have nuclei varying in shape and size with many mitoses. The appearances are certainly those of precancerous change but there is no sign of invasive carcinoma in this biopsy'.

Operation Total proctocolectomy.

Pathology of surgical specimen There is shortening of the large intestine, particularly on the left side, and the muscle layers are thicker than normal. The mucous membrane throughout the colon and rectum shows patchy polypoid change which has a nodular and papillary surface configuration (Fig. 2). Mucosa between the polypoid areas is thick and has a mucoid appearance.

Microscopy shows intact, but hypertrophic, mucosa with a moderate inflammatory cell infiltration and some crypt abscess formation. The inflammation does not penetrate into the submucosa. The epithelial tubules are very irregular and show horizontal budding in some areas. In others there is a villous or papillary type of proliferation. These adenomatous and villous changes are most marked in those areas of polypoid change observed macroscopically. At a cytological level the entire mucosa shows changes of precancer or carcinoma *in situ*. In addition there are many areas where the epithelial tubules are breaking through the muscularis mucosa, but this infiltration does not amount to definite invasion by carcinoma.

Follow-up Well three months after operation.

DISCUSSION

The diagnosis of carcinoma in ulcerative colitis is often made at an advanced and incurable stage. It is not surprising that the prognosis of cancer in colitis is rather poor (Slaney and Brooke, 1959), although perhaps not as bad as previously estimated (Hinton, 1966). The only way to control the death rate at the present time is by earlier diagnosis.

It is well recognized that the detection and treatment of precancerous lesions is an effective method of cancer control. The progress made in recent years in the screening of patients by biopsy and exfoliative cytology for precancer of the cervix is perhaps the best example. In the large intestine a notable advance has been made in the prevention of cancer in polyposis families (Dukes, 1958). In this disease the polyposis is a precancerous phase which is often symptomless and precedes the development of invasive carcinoma by many years. Total colectomy and ileo-rectal anastomosis in this phase has considerably reduced the incidence of malignant change (Bussey and Morson, 1967).

A description of the morphology of precancerous change in ulcerative colitis is given here making a distinction between the appearances seen in polypoid lesions and in flat mucosa. The recognition of carcinoma *in situ* in flat mucosa is particularly important because there may be no macroscopic evidence of this in colectomy specimens or by sigmoidoscopy and radiographic investigation. Our studies indicate that precancer in a flat mucosa is more common than the polypoid form. The fact that it can be detected in rectal biopsies from patients with a long history of total colitis emphasizes the importance of careful follow-up of such colitics with regular rectal biopsy whatever the state of the mucosa as judged by sigmoidoscopy.

It would appear from this study that precancer is present in all colectomy specimens removed for colitis and cancer and can also be found in some patients who have no invasive carcinoma but have a long history of total colitis. Its precise incidence and extent in different parts of the large bowel remains to be worked out but this study suggests that it is mostly found in the distal large intestine. Although invasive carcinomas in colitis are more evenly distributed in the large bowel than in cancer without colitis the incidence is still greater in the sigmoid and rectum than in the proximal colon (Langman, 1966).

It is obviously desirable that surgical treatment should be carried out before the development of invasive carcinoma. The problem so far has been to identify the precancerous phase in the individual patient before the examination of a colectomy specimen. It is likely, from experience with precancer in other organs, that the length of the precancerous phase of ulcerative colitis is very variable and it may be a great many years before invasive carcinoma develops. Indeed, it is not certain that precancer will inevitably proceed to invasion although the risk must be very high.

It would appear that precancerous change in ulcerative colitis is usually very diffuse and may even involve the entire mucosa of the large intestine. The retrospective examination of rectal biopsies reported here shows that there is good correlation between the biopsy diagnosis of precancer and the appearances in the subsequent colectomy specimen. Moreover, the patients with no precancer in the rectal biopsy showed no precancer or cancer in the subsequent colectomy specimen. These operations were mainly performed for colitis although the long history of disease and the risk of malignancy influenced the decision to carry out surgical treatment.

Because of the patchy distribution of precancer in the rectum it is likely that rectal biopsy will sometimes fail to be helpful. Negative reports should not be regarded as excluding the chance that precancerous or cancerous changes may be present in the proximal bowel beyond the reach of the sigmoidoscope. Clinical and radiographic observations by themselves remain the most valuable means of assessing the need for surgical treatment. For example, one patient with a long history of colitis, not included in this study, was regarded as particularly at risk from malignant change. The rectal biopsy report was equivocal but the subsequent colectomy revealed a cancer of the ascending colon.

In nine patients the rectal biopsy diagnosis of precancer accurately predicted the presence of similar changes in the subsequent colectomy specimens. As yet there has been no false diagnosis of precancer in a biopsy. It would appear that rectal biopsy has a valuable part to play in the recognition of the precancerous phase of ulcerative colitis in conjunction with clinical and radiographic opinion. However, the detection of precancer in a rectal biopsy has so far been associated with a high incidence of suspected and unsuspected invasive carcinoma in the more proximal bowel. Thus, five of the nine patients had invasive cancers. In one of these (case 5) the recognition of the patient as a 'high risk colitic' on clinical evidence together with a rectal biopsy report of precancer led to proctocolectomy at an early and almost certainly curable stage of the malignant process. The remaining four patients showed only extensive precancer in the operation specimen. They are examples of how the development of cancer in colitis may be anticipated and surgical treatment carried out in the precancerous phase. In all these patients the intention to perform colectomy was much influenced by the biopsy report although this was, by no means, the only basis for the decision.

If rectal biopsy can help to detect the patient who has entered a precancerous phase then it follows that all patients with a long history of total ulcerative colitis should have a regular biopsy examination. Once a year should be sufficient. The adoption of such a policy could not only help to prevent or control the death rate from cancer in the population of colitics at risk, but it would certainly teach us more about the evolution and fate of the precancerous phase.

SUMMARY

Histological changes characteristic of precancer were recognized by rectal biopsy in nine patients with chronic ulcerative colitis. One or more foci of invasive carcinoma, together with widespread precancerous change, were subsequently found in the colon or rectum of five of these patients. One, however, was at a very early stage of development. In the

other four patients the colectomy specimens showed precancerous changes only.

Rectal biopsy, in conjunction with clinical and radiological studies, may be helpful in the recognition of the patient with ulcerative colitis who has entered a precancerous phase. However, experience to date has shown that the recognition of precancer in a rectal biopsy is associated with a high incidence of suspected or unsuspected invasive carcinoma in the more proximal bowel.

It is suggested that regular rectal biopsy for all patients with ulcerative colitis is desirable in order that more may be learnt about the evolution of the precancerous phase. In particular those patients with a long history of total colitis should have a rectal biopsy at least once a year. Those in a precancerous phase would require total proctocolectomy. Such a policy should help to control the death rate from cancer in the population of colitics at risk.

We would like to thank the consultant staff of St. Mark's Hospital for permission to study their cases. The photographs were taken by Mr. Norman Mackie and Mr. Lloyd Soodeen gave valuable technical assistance. The expenses

of this research were defrayed out of grants from the British Empire Cancer Campaign for Research (B.C.M.) and the Medical Research Council (L.S.C.P.).

REFERENCES

- Bussey, H. J. R., and Morson, B. C. (1967). *Familial Polyposis Coli: The Prevention of Cancer*, edited by R. W. Raven and F. J. C. Roe. Butterworth, London.
- Dawson, I. M. P., and Pryse-Davies, J. (1959). The development of carcinoma of the large intestine in ulcerative colitis. *Brit. J. Surg.*, **47**, 113-128.
- Dukes, C. E. (1954). The surgical pathology of ulcerative colitis. *Ann. roy. Coll. Surg. Engl.*, **14**, 389-400.
- (1958). Cancer control in familial polyposis of the colon. *Dis. Colon Rect.*, **1**, 413-423.
- Gibbs, N. H. (1967). The incidence and significance of argentaffin and Paneth cells in some tumours of the large intestine. *J. clin. Path.* In the press.
- Grinnell, R. S., and Lane, N. (1958). Benign and malignant adenomatous polyps and papillary adenomas of the colon and rectum: an analysis of 1,856 tumors in 1,335 patients. *Int. Abstr. Surg.*, **106**, 519-538.
- Hinton, J. M. (1966). Risk of malignant change in ulcerative colitis. *Gut*, **7**, 427-432.
- Langman, M. J. S. (1966). Epidemiology of cancer of the large intestine. *Proc. roy. Soc. Med.*, **59**, 132.
- Morson, B. C. (1966). Cancer in ulcerative colitis. *Gut*, **7**, 425-426.
- Slaney, G., and Brooke, B. N. (1959). Cancer in ulcerative colitis. *Lancet*, **2**, 694-698.
- Watson, A. J., and Roy, A. D. (1960). Paneth cells in the large intestine in ulcerative colitis. *J. Path. Bact.*, **80**, 309-316.