

This is an Open Access article licensed under the terms of the Creative Commons Attribution-NonCommercial-NoDerivs 3.0 License (www.karger.com/OA-license), applicable to the online version of the article only. Distribution for non-commercial purposes only.

Recurrent Macular Detachment and Retinoschisis Associated with Intrachoroidal Cavitation in a Normal Eye

Masayuki Akimoto^{a, b} Tadamichi Akagi^c
Kazushiro Okazaki^d Etsuo Chihara^d

^aDepartment of Ophthalmology and ^bClinical Research Institute, Kyoto Medical Center, National Hospital Organization, and ^cDepartment of Ophthalmology and Visual Sciences, Kyoto University Graduate School of Medicine, Kyoto, and ^dSensho-kai Eye Institute, Uji, Japan

Key Words

Intrachoroidal cavitation · Macular detachment · Peripapillary detachment · Pit-macular syndrome · Retinoschisis

Abstract

Purpose: To describe a patient with intrachoroidal cavitation in the normal eye that caused self-limiting recurrent macular detachment and retinoschisis.

Case Report: An 80-year-old female patient with intrachoroidal cavitation in the normal eye presented with macular detachment and retinoschisis after cataract surgery. These were treated with intravitreal bevacizumab and then absorbed within 9 months. One year after cataract surgery, the patient presented with macular detachment and retinoschisis in the same eye again. These were absorbed within 4 months without treatment.

Conclusion: This case suggests that similar cases of cystoid macular edema after cataract surgery can occur, and that intrachoroidal cavitation is observed not only in eyes with pathologic myopia but also in normal eyes with peripapillary atrophy; intrachoroidal cavitation can cause macular detachment and retinoschisis.

Introduction

Macular detachment and retinoschisis are often associated with X-linked retinoschisis, pit-macular syndrome and coloboma [1–3]. However, recent studies have reported other causes of macular detachment and retinoschisis [4–7]. Intrachoroidal cavitations are often observed in pathologic myopia, but not in normal eyes, and can

result in retinoschisis and macular serous detachment [5, 8]. Other studies have shown peripapillary retinoschisis in glaucomatous eyes [9, 10], which resolved without treatment in some cases [10]. Here, we present a patient with intrachoroidal cavitation in the normal eye, with peripapillary atrophy (PPA), that caused self-limiting recurrent macular detachment and retinoschisis.

Case Report

An 80-year-old woman presented with visual loss in her right eye to the Sensho-kai Eye Institute. Her best-corrected visual acuity measured 20/100 OD and 20/16 OS. In the right eye, a grade 2 nuclear cataract based on the Emery scale was observed with an axial length of 23.80 mm and a refractive error of -1.0 diopters. The intraocular pressure measured 15 mm Hg OD and 14 mm Hg OS. No significant changes were observed in other parts of her eyes except small temporal conus. Small incision cataract surgery was performed with no complications. One week after surgery, her visual acuity decreased to 20/200. Macular serous detachment and cysts were observed using RTVue-100 Fourier-domain optical coherence tomography (RTVue-OCT; Optovue Inc., Fremont, Calif., USA) (fig. 1a). The left eye showed normal configuration (fig. 1b). Although RTVue-OCT showed prominent serous detachment and cysts, fluorescent angiography showed slight pooling in the cystic space and no robust leakage comparable to configuration obtained by RTVue-OCT (fig. 1c, d). The eye was treated as cystoid macular edema with intravitreal bevacizumab (1.25 mg) 2 months after surgery. The existing serous detachment slightly decreased and visual acuity improved to 20/50. Five months after surgery, intravitreal bevacizumab (1.25 mg) was applied again. Nine months after surgery, macular detachment and retinoschisis were almost absorbed. Her visual acuity had also improved to 20/25.

A year after cataract surgery, the patient presented with decreased vision and central scotoma in her right eye to Kyoto Medical Center. Her visual acuity was 20/100 OD and 20/16 OS. RS-3000 spectral-domain OCT examination (SD-OCT; Nidek Co. Ltd., Tokyo, Japan) showed macular detachment and retinoschisis extending to PPA (fig. 2a–c). Photoreceptor segments were missing at the foveola (fig. 2d). Intrachoroidal cavitations connecting to the cystic space were observed adjacent to the disc (fig. 2c). The connection between the intrachoroidal cavitation and cystic space appeared as breakage of Elschnig's collagenous limiting tissue, which connects the choroid to the optic disc. Since the patient refused further examinations, such as fluorescent angiography, SD-OCT was used to monitor the condition monthly. Serous retinal detachment and retinoschisis gradually absorbed, and was almost fully absorbed 4 months after onset (fig. 2e, f). Her visual acuity recovered to 20/20. A yellow-orange lesion was observed in her right eye (fig. 2g) but not in her left eye (fig. 2h). The left eye also showed intrachoroidal cavitation; however, no incidence of retinoschisis or retinal detachment has been noted (fig. 2i, j).

Discussion

No coloboma or optic disc pit was observed on ophthalmoscopy, but some PPA was found in the patient's eyes. In her right eye, a yellow-orange lesion was also found that was reported as peripapillary detachment in pathologic myopia (fig. 2g). The hyporeflexive space observed with SD-OCT suggested the presence of fluid was not in large blood vessels but in the space of the intrachoroidal cavitation because no corresponding large vessels were visible in the PPA- β area. The right eye showed 2 occurrences of macular detachment and retinoschisis. The first incidence was resolved within 9 months with intravitreal bevacizumab, whereas the second incidence was resolved without treatment.

The first incidence of macular detachment and retinoschisis occurred after cataract surgery. This is similar to Irvine-Gass syndrome that is characterized by cystoid

macular edema following cataract surgery. However, fluorescent angiography did not show the robust leakage associated with serous detachment and retinoschisis, suggesting another source of fluid like pit-macular syndrome could exist. Retinoschisis appeared to extend to the disc, unlike that observed in common cystoid macular edema. Unfortunately, OCT was not used regarding the disc during the first incidence.

Recent studies have reported that peripapillary retinoschisis can be seen in glaucomatous eyes [9, 10] and resolved without treatment [10]. In our case, however, macular detachment and retinoschisis occurred immediately after cataract surgery, and may have therefore caused the fluctuation of intraocular pressure. It remains unclear how the second incidence was induced. The effectiveness of intravitreal bevacizumab treatment was difficult to evaluate. The period of self-resolution of the second incidence was even shorter than that of the first. We have encouraged the patient to follow up periodically to assess any changes.

Although previous studies on peripapillary detachment in pathologic myopia showed small pit formation connecting the cystic space and vitreous, no such pit formation was observed in our case on thorough observation using SD-OCT. The subretinal fluid in other cases may have been derived from the vitreous; however, the fluid in our case may have been derived from intrachoroidal cavitation or spinal fluid. Since there was no connection between vitreous and macular detachment, such a condition may facilitate self-resolution.

Previous studies have reported intrachoroidal cavitation or peripapillary detachment in pathologic myopia but not in normal eyes [4–7]. Here, we reported a case of intrachoroidal cavitation in an eye with normal length and having PPA, resulting in self-limited recurrent macular detachment and retinoschisis. Our case suggests that similar cases of cystoid macular edemas after cataract surgery exist, and that intrachoroidal cavitation is observed not only in pathologic myopia but also in normal eyes with PPA; intrachoroidal cavitation can cause macular detachment and retinoschisis.

In cases of cystoid edema following cataract surgery, we should carefully observe not only the macular area but also the peripapillary area. If PPA is present, intrachoroidal cavitation should be included in the differential diagnosis.

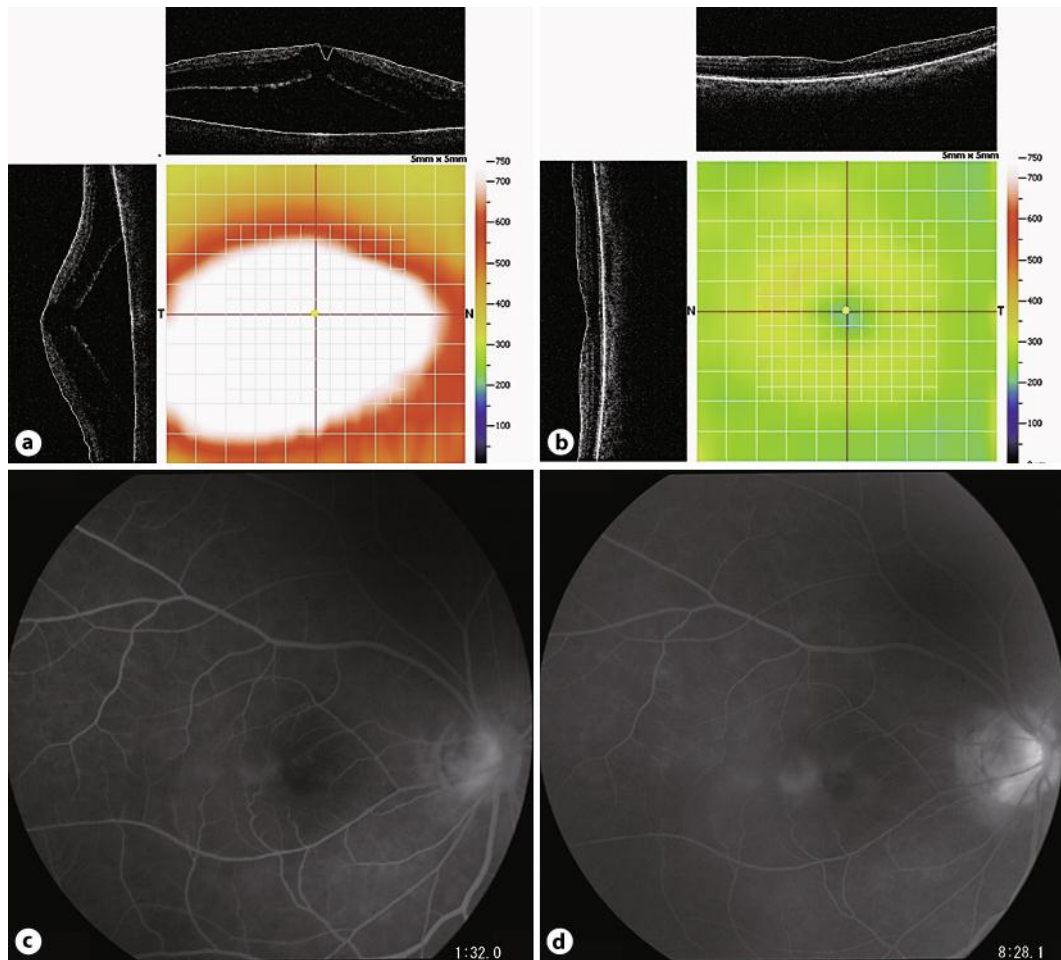


Fig. 1. **a** RTVue-OCT on the right eye shows macular detachment and cystic spaces. A lamellar hole between the subretinal space and retinoschisis is observed. **b** RTVue-OCT on the left eye shows normal configuration of the macular area. **c** Fluorescent angiography at 1 min 32 s does not show hot spots. **d** Fluorescent angiography at 8 min 26 s shows only minimum pooling in cystic spaces.

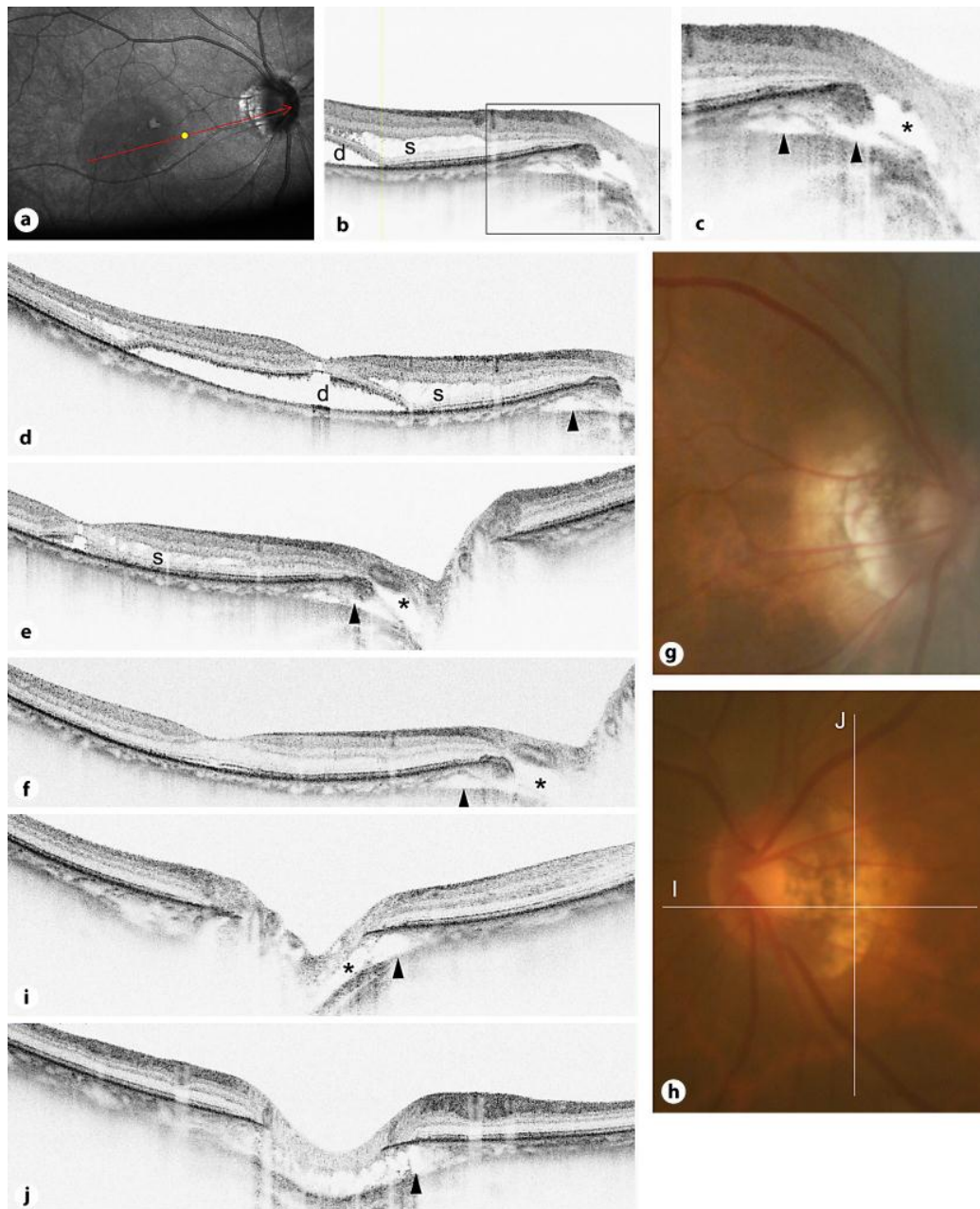


Fig. 2. **a** Scanning laser ophthalmoscopic image of **b** and **c**. **b** SD-OCT near the disc. Serous detachment (d) and retinoschisis (s) are observed. **c** Enlarged figure of **b**. Intrachoroidal cavitations (arrowheads) and cystic space (*) adjacent to the disc are observed. These spaces appear connected. **d** SD-OCT around the macular area. Serous detachment (d), retinoschisis (s) and intrachoroidal cavitation (arrowhead) are observed. Photoreceptor segments at the foveola are missing. **e** SD-OCT 2 months after onset. Serous detachment is almost fully absorbed. Retinoschisis (s), intrachoroidal cavitation (arrowhead) and cystic space (*) can still be seen. **f** SD-OCT 4 months after onset. Photoreceptor segments are almost repaired. Retinoschisis has also diminished. Intrachoroidal cavitation (arrowhead) and cystic space (*) are observed. **g** Color photograph of the right disc. PPA is observed. No pit is detected. A yellow-orange lesion is observed around PPA. **h** Color photograph of the left disc. PPA is observed. No pit is detected. **i** Horizontal section of SD-OCT around the disc in the left eye. Intrachoroidal cavitation (arrowhead) and cystic space (*) are observed. **j** Vertical section of SD-OCT around the disc in the left eye. Intrachoroidal cavitation (arrowhead) is observed.

References

- 1 Lincoff H, Lopez R, Kreissig I, et al: Retinoschisis associated with optic nerve pits. *Arch Ophthalmol* 1988;106:61–67.
- 2 Spaide RF, Costa DL, Huang SJ: Macular schisis in a patient without an optic disk pit optical coherence tomographic findings. *Retina* 2003;23:238–240.
- 3 Tantri A, Vrabec TR, Cu-Unjieng A, et al: X-linked retinoschisis: a clinical and molecular genetic review. *Surv Ophthalmol* 2004;49:214–230.
- 4 Freund KB, Ciardella AP, Yannuzzi LA, et al: Peripapillary detachment in pathologic myopia. *Arch Ophthalmol* 2003;121:197–204.
- 5 Shimada N, Ohno-Matsui K, Nishimuta A, Tokoro T, Mochizuki M: Peripapillary changes detected by optical coherence tomography in eyes with high myopia. *Ophthalmology* 2007;114:2070–2076.
- 6 Toranzo J, Cohen SY, Erginay A, Gaudric A: Peripapillary intrachoroidal cavitation in myopia. *Am J Ophthalmol* 2005;140:731–732.
- 7 Freund KB, Mukkamala SK, Cooney MJ: Peripapillary choroidal thickening and cavitation. *Arch Ophthalmol* 2011;129:1096–1097.
- 8 Shimada N, Ohno-Matsui K, Iwanaga Y, et al: Macular retinal detachment associated with peripapillary detachment in pathologic myopia. *Int Ophthalmol* 2009;29:99–102.
- 9 Kahook MY, Noecker RJ, Ishikawa H, et al: Peripapillary schisis in glaucoma patients with narrow angles and increased intraocular pressure. *Am J Ophthalmol* 2007;143:697–699.
- 10 Farjad H, Besada E, Frauens BJ: Peripapillary schisis with serous detachment in advanced glaucoma. *Optom Vis Sci* 2010;87:E205–E217.