

# Recurring multifocal leiomyosarcoma of the urinary bladder 22 years after therapy for bilateral (hereditary) retinoblastoma: A case report and review of the literature

Švajdler M. Jr<sup>1</sup>, Valanský L.<sup>2</sup>, Andrašina I.<sup>3</sup>, Ilenčíková D.<sup>4</sup>, Copáková L.<sup>5</sup>, Rychlý B.<sup>6</sup>, Piačková B.<sup>5</sup>

<sup>1</sup> Department of Pathology, Louis Pasteur University Hospital, Košice, Slovakia

<sup>2</sup> Department of Urology, Louis Pasteur University Hospital, Košice, Slovakia

<sup>3</sup> East Slovakia Oncology Institute, Košice, Slovakia

<sup>4</sup> 2<sup>nd</sup> Department of Paediatrics, Comenius University Medical School, University Children's Hospital, Bratislava

<sup>5</sup> Department of Genetics, National cancer institute, Bratislava, Slovakia

<sup>6</sup> Cytopathos s.r.o., Bratislava, Slovakia

## SUMMARY

We report on a case of urinary bladder leiomyosarcoma in a 23-year-old woman, 22 years after therapy for bilateral retinoblastoma. The tumor presented with dysuria and macroscopic haematuria. Cystoscopy revealed a tumor localized in the trigonum covered by an ulcerated urothelium. The patient underwent a transvesical tumor resection. Eight months later, a second leiomyosarcoma developed in the vertex, at a site different from the previous one. A cystoscopic trans-urethral tumor resection was performed, followed by combined chemotherapy. One year later another recurrence occurred at the site of the primary resection. Open laparotomic resection of the involved bladder wall was performed. The patient remains both recurrence and metastases free after twenty months of follow-up. Molecular analysis of the peripheral blood showed rare germline point mutation in the intron 24 of the RB1 gene. FISH analysis of the tumor tissue revealed polyploid cells with relative loss of normal RB1 gene locus, indicating deletion and second hit loss of the second RB1 allele function. Along with the ten previously reported cases, this report suggests a non-random association between the hereditary retinoblastoma and urinary bladder leiomyosarcoma. Therapy with cyclophosphamide seems to be an important risk factor. Life-long surveillance for second malignancies, including bladder leiomyosarcoma is therefore mandatory in these patients.

**Keywords:** retinoblastoma – urinary bladder – leiomyosarcoma – secondary cancer – cyclophosphamide

## Recidivujúci multifokálny leiomyosarkóm močového mechúra 22 rokov po liečbe bilaterálneho (hereditárneho) retinoblastómu: popis prípadu a prehľad literatúry

### SÚHRN

Popisujeme prípad leiomyosarkómu močového mechúra u 23 ročnej ženy, 22 rokov po liečbe bilaterálneho retinoblastómu. Nádor sa prezentoval dysúriou a makroskopickou hematúriou. Cystoskopicky bol zistený ulcerovaný nádor lokalizovaný v trigone. Následne bola vykonaná jeho transvezikálna resekcia. Osem mesiacov neskôr na inom mieste močového mechúra, vo vertexe, vznikol u pacientky druhý leiomyosarkóm. Bola vykonaná cystoskopická transuretrálna resekcia nádoru s následnou kombinovanou chemoterapiou. Po jednom roku sa objavila recidíva v mieste prvej resekcie. Bola vykonaná otvorená resekcia postihnutej steny mechúra. Dvadsať mesiacov po poslednej operácii je pacientka bez známkov recidívy alebo metastáz. Molekulárnou analýzou periférnej krvi bola dokázaná vzácna zárodočná bodová mutácia v intróne 24 RB1 génu. FISH analýza nádorového tkaniva dokázala polyploiditu nádorových buniek s relatívnou stratou lokusu RB1, indikujúc „second hit“ deléciu a tým stratu funkcie druhej RB1 alely. Spolu s desiatimi doposiaľ popísanými prípadmi, náš prípad svedčí pre nenáhodnú asociáciu medzi hereditárnym retinoblastómom a leiomyosarkómom močového mechúra. Dôležitým rizikovým faktorom je pravdepodobne liečba cyklofosfamidom. U týchto pacientov je dôležité celoživotné sledovanie na výskyt sekundárnych malignít, vrátane leiomyosarkómu močového mechúra.

**Kľúčové slová:** retinoblastóm – močový mechúr – leiomyosarkóm – sekundárna malignita – cyklofosfamid

*Cesk Patol 2012; 48(1): 44–48*

### ✉ Address for correspondence:

Marián Švajdler Jr., MD  
Department of Pathology  
Louis Pasteur University Hospital  
Trieda SNP 1, 041 90 Košice, Slovakia  
tel/fax: +421 55 640 2945  
e-mail: svajdler@yahoo.com

Leiomyosarcoma is the most common malignant mesenchymal tumor of the urinary bladder, but it accounts for less than 1 % of all malignant bladder neoplasms (1,2). The treatment with cyclophosphamide currently represents the only known risk factor (1,3–5). To date, only ten cases of bladder leiomyosarcoma have been reported as a second malignancy in retinoblastoma survivors (4,6–14). We describe an additional case of bladder leiomyosar-

coma occurring 22 years after the treatment of hereditary retinoblastoma with cyclophosphamide.

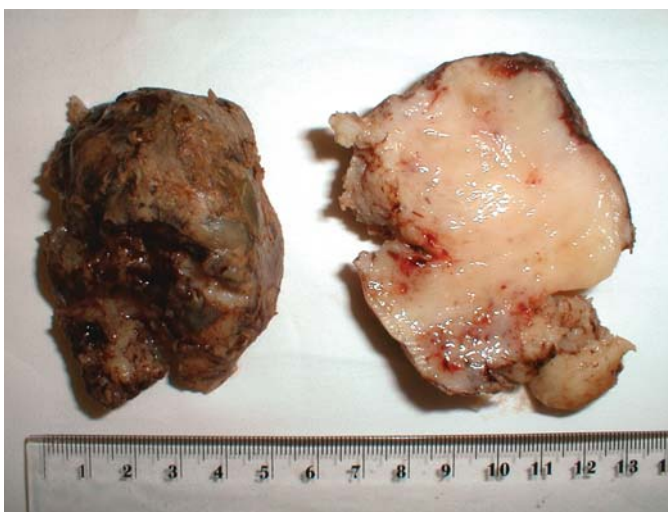## CLINICAL HISTORY

A twenty-three-year-old woman was treated for a bilateral retinoblastoma at 17 months of age. The treatment consisted of unilateral eye enucleation and a combined chemotherapy with vincristin, doxorubicin and cyclophosphamide and intrathecal methotrexat application. The contralateral tumor was successfully managed with this therapy.

Currently, the patient has presented with a 2-week history of dysuria and macroscopic haematuria. Abdominal computed tomography showed a well-circumscribed tumorous mass in the posterior wall of the urinary bladder, measuring 4 centimetres in diameter. Cystoscopy performed two weeks later revealed a pedunculated tumor measuring 8 centimetres in diameter. Transvesical resection of the tumor was performed, with a margin of uninvolved tissue, verified by frozen section biopsy. At that time, no adjuvant therapy was given, considering the risk of other further malignancies in the future. However, eight months later, a second tumor developed in the vertex of the urinary bladder, in a site unequivocally different from the previous one. Cystoscopic transurethral resection of the tumor measuring one centimetre was performed, and the patient received chemotherapy consisting of three cycles of ifosfamid and four cycles of cisplatin, together with mesna (for prevention of haemorrhagic cystitis) and pegfilgrastim (a granulocyte colony stimulating factor). One year after the chemotherapy, another recurrence occurred at the site of primary resection. An open laparotomic resection of the involved bladder wall was performed. The patient was both recurrence and metastases free after twenty months of follow-up. A whole body PET scan did not find any metastatic disease.

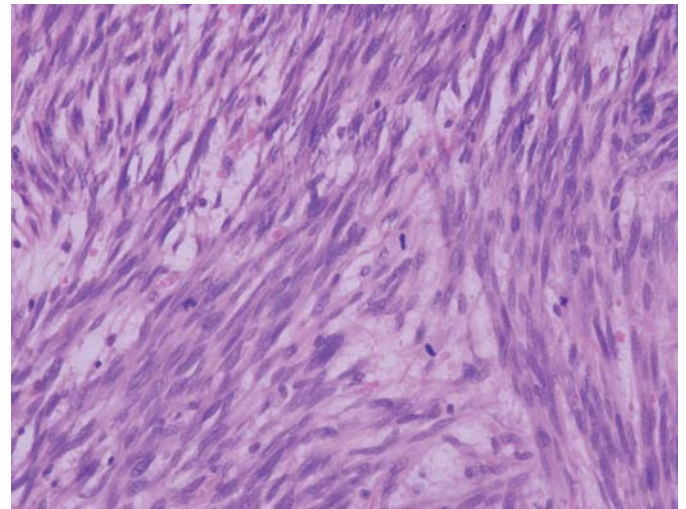
## MATERIALS AND METHODS

From routinely processed formalin-fixed and paraffin-embedded material, five-micrometer-thick sections were stained with hematoxylin and eosin. Immunohistochemical staining was performed using the standard avidin-biotin detection technique with diaminobenzidine as chromogen, according to the manufacturer's data sheets,

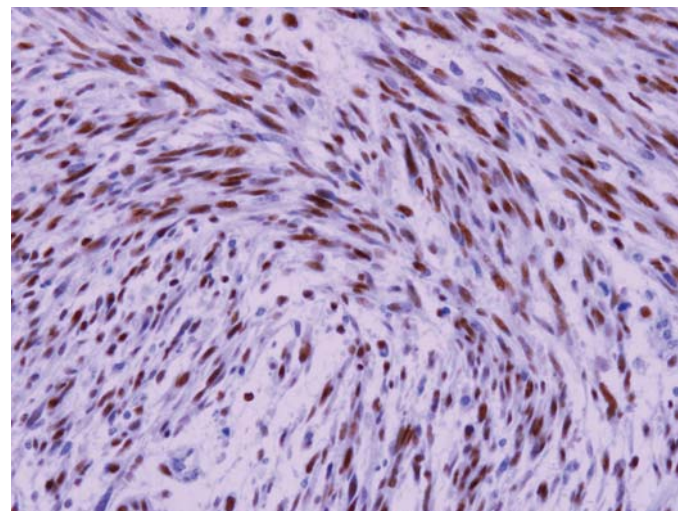


**Fig. 1.** Gross aspect of the first resection specimen, showing fish-flesh appearing tumor.

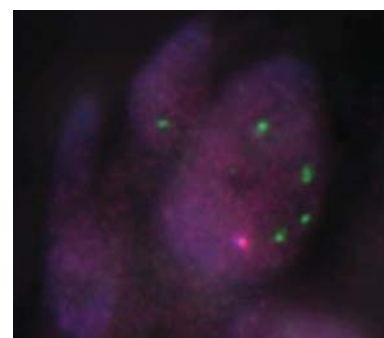
with the following primary antibodies: muscle-specific actin (clone HHF-35, Biogenex), caldesmon (clone h-CD, Biogenex), CD246 (ALK-1, DAKO), desmin (clone 33, Biogenex), Ki-67 (clone MIB-1, DAKO), p53 (clone DO-7, Neomarkers), CD34 (clone QBEND/10, Biogenex) and CD117 (c-kit, polyclonal, DAKO).



**Fig. 2.** Microscopically, the tumor consisted of fascicles of elongated spindle-shaped cells with cigar-shaped nuclei. Many mitotic figures are present. Haematoxylin-eosin, magnification 200x.



**Fig. 3.** Strong p53 positivity in almost all tumor nuclei. Immunohistochemistry, ABC technique, magnification 200x.



**Fig. 4.** Fluorescence in situ hybridization showing polyplloid cells (green signals, marking 13q34) with relative loss of the retinoblastoma gene (orange signals).

Fluorescence in situ hybridization (FISH) was performed using Vysis LSI (13q34) SpectrumGreen probe (Abbott) and Vysis LSI 13 (RB1) SpectrumOrange probe (Abbott) according to the manufacturer's data sheets.

For molecular biology studies, DNA was extracted from peripheral blood, assayed and PCR amplified using specific intronic primers (INGENY) designed to include the splice site for exons 2 to 27. Reactions were performed in a 25 µl volume containing 100 ng of genomic DNA, 2 pmol of each primer, 12.5 µl Thermo Start Master Mix with 2 mM MgCl<sub>2</sub> (Thermo Scientific) and 9.5 µl nuclease free water. Amplified products were separated on a 20–65% polyacrylamide gel (Denaturing Gradient Gel Electrophoresis).

The sequencing analysis for the mutation detection was performed using the primers tailed at the 5' end with sequence of M13 Rev and 21M13. Amplification conditions consisted of one initial denaturing step of 15 minutes at 95°C, followed by 40 cycles of 30 seconds at 95°C, 45 seconds at 60°C and 45 seconds at 72°C, with a final extension step of 10 minutes at 72°C. The 25Kl of PCR products were purified with Exo-Sap (Fermentas) followed by a sequencing reaction with Big Dye Terminator v 3.1 (Applied Biosystems) according to the manufacturer's protocol. The sequencing products were purified through an Ex-Terminator kit (A&A Biotechnology, Poland) before being run on a 3130 Genetic Analyser (Applied Biosystems). The sequencing data were analyzed using the Sequencing Analysis Software v 5.2 Patch 2 (Applied Biosystems).

Sequencing primers:

Forward: 5' – tgtaaacgacgagccagtAAACTTGCCTTGGCCCTCCC – 3'  
Reverse: 5' – caggaacagctatgaccTGCAATATGCCTGGATGAGGT – 3'

## RESULTS

The specimen from the first resection consisted of two pieces of tan-grey tissue covered with an ulcerated mucosa and a pink-white cut surface resembling fish flesh (Fig. 1).

Microscopically, the tumor showed fascicular growth of elongated spindle-shaped cells with typical cigar-shaped nuclei and eosinophilic cytoplasm. There was mild to moderate nuclear atypia and a remarkably high mitotic rate (35–40 mitoses per 10 high-power fields) (Fig. 2). Atypical mitoses were easy to find and few foci of coagulation necrosis were noted. The tumor ulcerated the urothelial mucosa. Vascular or lymphatic invasion was not found.

The resection margin was free of the tumor. Specimens from all consequent biopsies and resections showed essentially the same tumor.

Immunohistochemistry showed diffuse cytoplasmic reactivity for muscle-specific actin, caldesmon, desmin and CD246 (ALK-1). The CD34 and CD117 (c-kit) were both negative. Ki-67 staining showed a proliferation rate of 50 % and p53 labeled approximately 80 % of nuclei (Fig. 3). According to the criteria proposed by Martin et al. (2), a diagnosis of high grade leiomyosarcoma was made. FISH analysis revealed polyploid cells (four to ten green signals marking control locus 13q34) with a relative loss of normal RB1 gene locus staining, with a ratio to control of less than 0.8, indicating a deletion (Fig. 4).

Molecular analysis of the peripheral blood showed point mutation (c.2520+2T>A) in the intron 24 of the RB1 gene, affecting invariant nucleotides in the splicing site, with the predicted result of out of frame exon skipping and a downstream stop codon, first described by Alonso et al. (15)(Fig. 5). The splice effect was at-tested to at <http://spliceport.cs.umd.edu/>.

## DISCUSSION

Currently, approximately 70 % of patients with childhood malignancies are long-time survivors. This population is at risk of developing a second malignant neoplasm with an estimated incidence of approximately 3 % at 20 years of age (16). The risk of subsequent cancer is elevated almost 7-fold in non-irradiated hereditary retinoblastoma patients and radiation further increases this risk 3.1-fold. The cumulative incidence of second malignancies in survivors of hereditary retinoblastoma reaches 36 % at 50 years of age. On the contrary, it seems that survivors with nonhereditary retinoblastoma are not prone to secondary cancer (17). Germline mutation in the RB1 tumor suppressor gene is often associated with the development of osteosarcoma, fibrosarcoma, chondrosarcoma, Ewing sarcoma, pinealoblastoma, epithelial tumors, leukaemia, lymphoma, melanoma, and brain tumors (18).

In a recent study of 963 one-year survivors of hereditary retinoblastoma, a total of 69 soft tissue sarcomas were diagnosed in 68 patients. No soft tissue sarcomas were diagnosed in survivors of nonhereditary retinoblastoma. Leiomyosarcoma was the most common histologic subtype, comprising 33 % of cases. Eighteen of the 23 leiomyosarcoma (78 %) were diagnosed 30 or more years after retinoblastoma. In contrast to other types of soft tissue sarcomas in this group, leiomyosarcoma was diagnosed more frequent-

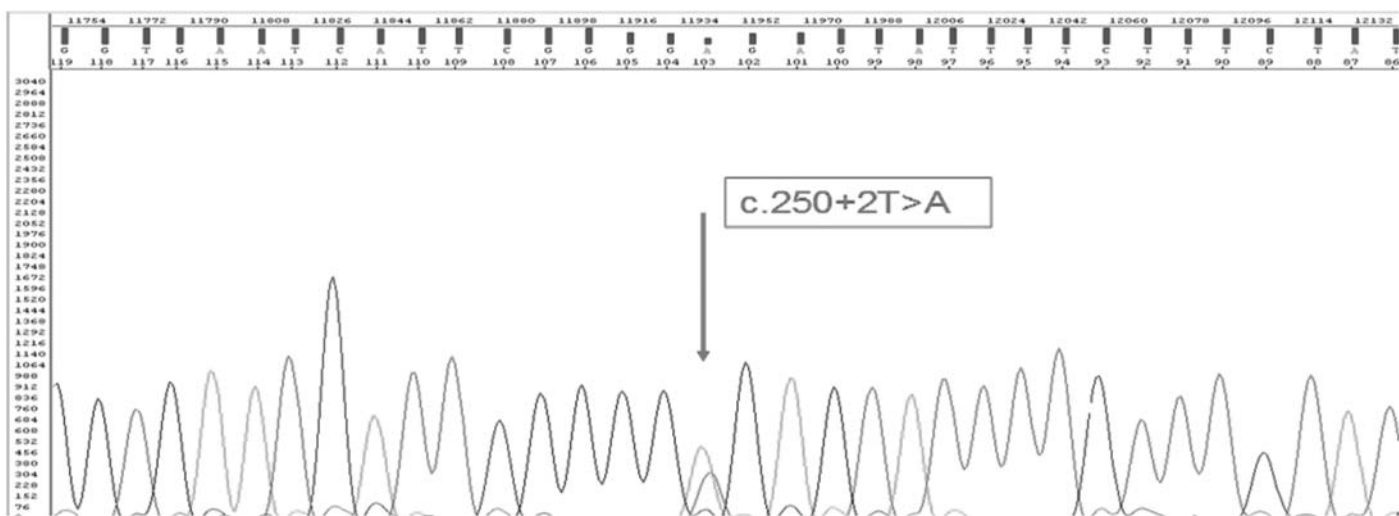


Fig. 5. Sequencing analysis of the intron/exon 24 with point mutation - substitution of the nucleotides (arrow).

ly outside the radiation field, including 5 leiomyosarcomas of the corpus uteri, suggesting a genetic predisposition independent of radiation. The risk for soft tissue leiomyosarcoma was statistically significantly higher in patients treated with radiation and chemotherapy as compared with radiation alone (17).

To date, ten cases of urinary bladder leiomyosarcoma in a hereditary retinoblastoma patient have been reported (4,6–14). These tumors occurred 16 to 47 years after treatment of the retinoblastoma. Seven of these ten patients were younger than 25 years of age. Administration of cyclophosphamide seems to be an important risk factor, although two of the ten patients did not receive cyclophosphamide (10,14).

In soft tissue and uterine corpus leiomyosarcomas, loss of the chromosome 13 material with the RB1 gene has been implicated in their pathogenesis and analysis of the genes and proteins in the Rb-cyclinD pathway has revealed frequent abnormalities (17,19). Similarly, in hereditary retinoblastoma patients, radiation-induced chromosome instability with loss of the chromosome 13 material was implicated in the development of secondary solid tumors in the field of radiotherapy (20). In our case, we have proved germline mutation in the RB1 gene, and FISH analysis of the tumor tissue revealed polyploid cells with a relative loss of normal RB1 gene staining, indicating second-hit chromosomal instability and loss of the second RB1 allele function. Only two previous cases of bladder leiomyosarcoma in retinoblastoma patients were investigated for possible molecular pathogenesis. In both of them, absence of the normal retinoblastoma gene product was demonstrated at the level of the retinoblastoma protein and RB mRNA, respectively (7,10). Moreover, in one of these two cases, significant reduction of the tumor suppressor p53 was demonstrated (7). Our case showed diffuse (approximately 80 %) and strong immunohistochemical nuclear positivity for p53, indicating accumulation of an abnormal p53 protein and its possible role in the pathogenesis.

Interestingly, the tumor in our case showed convincing immunohistochemical cytoplasmic CD246 (ALK-1) positivity (not shown), bringing the inflammatory myofibroblastic tumor (IMT) into the dif-

ferential diagnosis. In two studies, twelve of sixteen cases of urinary bladder IMT and all of six cases of uterine IMT showed ALK-1 immunostaining as compared with negativity in five genitourinary and six uterine leiomyosarcomas (21,22). However, diagnosis of IMT in our case was excluded because the typical inflammatory component was lacking and the tumor was caldesmon positive. Unfortunately, in our case no studies were performed to prove possible ALK-1 gene rearrangement and we have no convenient explanation for this phenomenon.

The treatment of bladder leiomyosarcoma in the ten reported cases varied from endoscopic resection to total cystectomy with adjuvant chemotherapy (4,6–14). Long term prognosis of this tumor is difficult to assess, because of its rarity and relatively short follow-up in reported cases. One patient experienced lung metastases 18 months after the initial diagnosis of leiomyosarcoma and received a combination of chemotherapy with cisplatin and doxorubicin (10). In only one reported case did the patient develop a second bladder leiomyosarcoma, 12 years following partial cystectomy. The second tumor was managed by transurethral resection, just like in our case (8).

In conclusion, we report an additional case of urinary bladder leiomyosarcoma in a hereditary retinoblastoma patient. The occurrence of two leiomyosarcomas in our patient, along with the other ten reported cases, suggests a non-random association between the hereditary retinoblastoma and urinary bladder leiomyosarcoma. Therapy with cyclophosphamide seems to be an important risk factor. Life-long surveillance for second malignancies, including bladder leiomyosarcoma is therefore mandatory. Appropriate management for this type of secondary malignancy should be designated in the future, as still more cases are identified.

## ACKNOWLEDGMENTS

The patient and her family are greatly acknowledged. Dr. Peter Salat from University of Alberta is acknowledged for proof reading.

## REFERENCES

1. **Chevile, J.** Leiomyosarcoma. In: **Eble JN, Sauter G, Epstein JI, Sesterhenn IA**, eds. WHO classification of tumors. Pathology and genetics of tumors of the urinary system and male genital organs. Lyon: IARC Press; 2004: 140.
2. **Martin SA, Sears DL, Sebo TJ, Lohse CM, Chevile JC.** Smooth muscle neoplasms of the urinary bladder. A clinicopathologic comparison of leiomyoma and leiomyosarcoma. *Am J Surg Pathol* 2002; 26(3): 292–300.
3. **Pedersen-Bjergaard J, Jonsson V, Pedersen M, Hou-Jensen K.** Leiomyosarcoma of the urinary bladder after cyclophosphamide. *J Clin Oncol* 1995; 13(2): 532–533.
4. **Tanguay C, Harvey I, Houde M, Srigley JR, Tzitu B.** Leiomyosarcoma of urinary bladder following cyclophosphamide therapy: Report of two cases. *Mod Pathol* 2003; 16(5): 512–514.
5. **Thrasher JB, Miller GJ, Wettlaufer JN.** Bladder leiomyosarcoma following cyclophosphamide therapy for lupus nephritis. *J Urol* 1990; 143(1): 119–121.
6. **Al-Zahrani AA, Kamal BA, Eldarawani HM, Hashim TM.** Leiomyosarcoma of the bladder in a 16-year-old girl with a history of cyclophosphamide therapy for bilateral retinoblastoma during infancy. *Saudi Med J* 2006; 27(4): 531–533.
7. **Bléoo SL, Godbout R, Rayner D, Tamimi Y, Moore RB.** Leiomyosarcoma of the bladder in a retinoblastoma patient. *Urol Int* 2003; 71(1): 118–121.
8. **Brucker B, Ernst L, Meadows A, Zderic S.** A second leiomyosarcoma in the urinary bladder of a child with a history of retinoblastoma 12 years following partial cystectomy. *Pediatr Blood Cancer* 2006; 46(7): 811–814.
9. **Kawamura J, Sakurai M, Tsukamoto K, Tochigi H.** Leiomyosarcoma of the bladder eighteen years after cyclophosphamide therapy for retinoblastoma. *Urol Int* 1993; 51(1): 49–53.
10. **Liang SX, Lakshmanan Y, Woda BA, Jiang Z.** A high-grade primary leiomyosarcoma of the bladder in a survivor of retinoblastoma. *Arch Pathol Lab Med* 2001; 125(9): 1231–1234.
11. **Minagawa T, Okaneya T, Kamigaito M, et al.** Leiomyosarcoma of the urinary bladder in a patient with bilateral retinoblastoma. *Int J Urol* 2008; 15(6): 548–550.
12. **Motta L, Porcaro AB, Ficarra V, D'Amico A, Piubello Q, Comunale L.** Leiomyosarcoma of the bladder fourteen years after cyclophosphamide therapy for retinoblastoma. *Scand J Urol Nephrol* 2001; 35(3): 248–249.
13. **Parekh DJ, Jung C, O'Conner J, Dutta S, Smith ER Jr.** Leiomyosarcoma in urinary bladder after cyclophosphamide therapy for retinoblastoma and review of bladder sarcomas. *Urology* 2002; 60(1): 164.
14. **Venkatraman L, Goepel JR, Steele K, Dobbs SP, Lyness RW, McCluggage WG.** Soft tissue, pelvic, and urinary bladder leiomyosarcoma as second neoplasm following hereditary retinoblastoma. *J Clin Pathol* 2003; 56(3): 233–236.
15. **Alonso J, Frayle H, Menendez I, et al.** Identification of 26 new constitutional RB1 gene mutations in Spanish, Colombian, and Cuban retinoblastoma patients. *Hum Mutat* 2005; 25(1): 99.

16. **Bisogno G, Sotti G, Nowicki Y, et al.** Soft tissue sarcoma as a second malignant neoplasm in the pediatric age group. *Cancer* 2004; 100(8): 1758–1765.
17. **Kleinerman RA, Tucker MA, Tarone RA, et al.** Risk of new cancers after radiotherapy in long-term survivors of retinoblastoma: an extended follow-up. *J Clin Oncol* 2005; 23(10): 2272–2279.
18. **Cawenee WK, Hadjistilianou T, Böglér O, Newsham IF.** Retinoblastoma syndrome. In: **Fletcher CDM, Unni KK, Mertens F**, eds. WHO classification of tumors. Pathology and genetics of tumors of soft tissue and bone. Lyon: IARC Press; 2002: 363–364.
19. **Evans HL, Shipley J.** Leiomyosarcoma. In: **Fletcher CDM, Unni KK, Mertens F**, eds. WHO classification of tumors. Pathology and genetics of tumors of soft tissue and bone. Lyon: IARC Press; 2002: 130–134.
20. **Lefèvre SH, Vogt N, Dutrillaux AM, et al.** Genome instability in secondary solid tumors developing after radiotherapy of bilateral retinoblastoma. *Oncogene* 2001; 20(56): 8092–8099.
21. **Tsuzuki T, Magi-Galluzzi C, Epstein JI.** ALK-1 expression in inflammatory myofibroblastic tumor of the urinary bladder. *Am J Surg Pathol* 2004; 28(12): 1609–1614.
22. **Rabban JT, Zaloudek CJ, Shekitka KM, Tavassoli FA.** Inflammatory myofibroblastic tumor of the uterus. A clinicopathologic study of 6 cases emphasizing distinction from aggressive mesenchymal tumors. *Am J Surg Pathol* 2005; 29(10): 1348–1355.

# MONITOR

aneb **nemělo by vám uniknout, že ...**

## ■ NEUROPATHOLOGIE ▸

... WHO klasifikácia mozgových nádorov je zaťažená nezanebateľným stupňom neurčitosti

Pre onkologickú liečbu, nie len mozgových nádorov, je nevyhnutná patologická diagnóza. Globálnym štandardom pre diagnózu tumorov je klasifikácia Svetovej Zdravotníckej Organizácie (WHO). Napriek podrobným popisom histopatologických znakov vo WHO klasifikácii mozgových tumorov, mnohé jednotky môže byť problematické spoľahlivo diagnostikovať. Je to dôsledok vysokej morfolologickej heterogenity mozgových nádorov a zároveň nejednoznačnosti mnohých diagnostických kritérií pre jednotlivé diagnostické kategórie. Autori publikácie analyzovali túto neurčitost' na základe troch kľúčových bodov: špecifická vs. neurčitá znaky), konštantnosť (konštantné vs. premenlivé znaky) a výlučnosť (výlučné vs. duplicitné znaky). Ako špecifický definovali znak, ktorý môže byť posúdený bez špecializovaných znalostí či skúseností. Napríklad nekroza je špecifický znak, nekrozu mozgového tkaniva môže posúdiť i patológ, ktorý nie je špecializovaným neuropatológom. Neurčitý znak je nejednoznačne definovaný, alebo jeho rozsah nie je presne definovaný. Napríklad „briskná“ mitotická aktivita je nejednoznačný znak, nie je stanovený hraničný počet mitóz pre „brisknosť“. Konštantným znakom je taký, ktorý je prítomný vždy (prípadne nikdy) v danom tumore. Konštantným znakom sú napríklad bipolárne bunky v pilocytickom astrocytome. Premennivý znak môže, alebo nemusí byť prítomný v tumore ako napríklad Rosenthalové fibrily, ktorých prítomnosť nie je nevyhnutná pre pilocytický astrocytóm. Výlučný znak môže byť zachytený len v jednom type tumoru. Nález takéhoto znaku by bol potom sám o sebe diagnostický pre konkrétny tumor. Naprostá väčšina histologických znakov je ale duplicitných, teda takých, ktoré možno pozorovať vo viacerých tumoroch v rámci diferenciálnej diagnostiky. Za podmienok neurčitosti nie je možná 100% istota správnej diagnózy. Na piatich diagnózach (pilocytický astrocytóm, pleomorfný xantastrocytóm, difúzny astrocytóm, anaplastický astrocytóm, glioblastóm) bolo analyzovaných desať diagnostických morfologických znakov z hľadiska ich neurčitosti. Autori tiež odkazujú na informačnú teóriu. Ak by sme nukleárnu atypiu popisovali "N" počtom znakov a každý z týchto znakov by mal len dve hodnoty (prítomný, neprítomný) dostali by sme 2<sup>N</sup> kombinácií. A ak

by sme pre tento model zvolili 10 znakov, celkový počet nukleárných morfológií by bol 1024 (počet rozličných atypických jadier je veľmi veľký na to, aby bol tento znak jednoducho reprodukovateľný). Z analýzy vyplýva, že 75 % použitých znakov je zaťažených rozličným stupňom neurčitosti. V podmienkach neurčitosti patológovia analyzujú histologické obrázky ich porovnaním so všeobecne známymi faktami alebo obrázkami (heuristická analýza), skôr ako aplikovaním nie úplne jednoznačných diagnostických kritérií.

Je otázne, na koľko je možné posudzovať histopatologickú diagnostiku na základe matematických modelov a informačnej teórie. Znáмым faktom ale je, že interpersonálna variabilita hodnotenia mozgových tumorov je značná, i medzi expertnými neuropatológmi. Jej hlavnou príčinou je pravdepodobne nejednoznačnosť diagnostických kritérií pre jednotlivé nádory. V rutínnej praxi často zápasíme s otázkami: Čo je signifikantná mitotická aktivita? Kde je hranica medzi astrocytómom, oligoastrocytómom a oligodendrogliómom? Aký je rozdiel medzi glioblastómom s oligodendrogliovou zložkou a anaplastickým oligodendrogliómom? Je „šedá zóna“ medzi CNS PNETom s gliovou diferenciáciou a glioblastómom s neuronálnou diferenciáciou? Tieto hranice môžu byť pre neuroonkologa veľmi významné, ale pre neuropatologa veľmi vážne. Z vlastných skúseností vieme, že mnohí naši klinickí kolegovia pokladajú patológiu za exaktnú disciplínu, preto je žiaduca osveťta v tejto oblasti. Zo strany patológie je zase do budúcnosti nevyhnutná snaha zlepšovať reprodukovateľnosť diagnostických kritérií v ďalších WHO klasifikáciách a do diagnostiky zapájať objektívnejšie (imunohistochemické a genetické) metodiky, ako len samotné pomerne subjektívne histomorfologické hodnotenie. Už teraz môžeme sledovať tendenciu deliť infiltrujúce gliómy na 1p/19q LOH pozitívne a negatívne, či IDH1/2 mutované a nemutované. Záverom je možné dodať, že väčším alebo menším stupňom neurčitosti nie je zaťažená len neuropatológia, ale tiež histopatologická diagnostika všetkých ostatných orgánových systémov.

Zdroj:

Tanaka G et al. Indeterminacy in the WHO classification of tumors: an example of the histopathological diagnosis of brain tumors. *Brain Tumor Pathol* 2011; 28(3): 247–251.

– B. Rychlý –

Pokračování na str. 53