



Published in final edited form as:

Psychol Med. 2014 October ; 44(13): 2833–2843. doi:10.1017/S0033291714000348.

Reduced gray matter volume in the anterior cingulate, orbitofrontal cortex and thalamus as a function of mild depressive symptoms: a voxel-based morphometric analysis

C. A. Webb*, M. Weber, E. A. Mundy, and W. D. S. Killgore

McLean Hospital, Harvard Medical School, Belmont, MA, USA

Abstract

Background—Studies investigating structural brain abnormalities in depression have typically employed a categorical rather than dimensional approach to depression [i.e. comparing subjects with Diagnostic and Statistical Manual of Mental Disorders (DSM)-defined major depressive disorder (MDD) v. healthy controls]. The National Institute of Mental Health, through their Research Domain Criteria initiative, has encouraged a dimensional approach to the study of psychopathology as opposed to an over-reliance on categorical (e.g. DSM-based) diagnostic approaches. Moreover, subthreshold levels of depressive symptoms (i.e. severity levels below DSM criteria) have been found to be associated with a range of negative outcomes, yet have been relatively neglected in neuroimaging research.

Method—To examine the extent to which depressive symptoms – even at subclinical levels – are linearly related to gray matter volume reductions in theoretically important brain regions, we employed whole-brain voxel-based morphometry in a sample of 54 participants.

Results—The severity of mild depressive symptoms, even in a subclinical population, was associated with reduced gray matter volume in the orbitofrontal cortex, anterior cingulate, thalamus, superior temporal gyrus/temporal pole and superior frontal gyrus. A conjunction analysis revealed concordance across two separate measures of depression.

Conclusions—Reduced gray matter volume in theoretically important brain regions can be observed even in a sample that does not meet DSM criteria for MDD, but who nevertheless report relatively elevated levels of depressive symptoms. Overall, these findings highlight the need for additional research using dimensional conceptual and analytic approaches, as well as further investigation of subclinical populations.

© Cambridge University Press 2014

*Address for correspondence: C. A. Webb, Ph.D., Center for Depression, Anxiety, and Stress Research, McLean Hospital, Harvard Medical School, 115 Mill Street, Belmont, MA 02478, USA. cwebb@mclean.harvard.edu.

Declaration of Interest

None.

The authors assert that all procedures contributing to this work comply with the ethical standards of the relevant national and institutional committees on human experimentation and with the Helsinki Declaration of 1975, as revised in 2008.

Keywords

Depressive symptoms; DSM; gray matter volume; research domain criteria; voxel-based morphometry

Introduction

A large body of research has explored functional and structural brain abnormalities associated with major depressive disorder (MDD). Most previous studies examining structural abnormalities in depression have utilized a region-of-interest (ROI) rather than a whole-brain approach. Findings from such studies may be biased towards investigating only a subset of brain regions, such as those that are more easily defined via anatomical scans or those of primary theoretical interest (e.g. amygdala and hippocampus; Koolschijn *et al.* 2009; Bora *et al.* 2012). An important benefit of voxel-based morphometry (VBM) is that it allows for a more comprehensive whole-brain assessment of structural abnormalities without the *a priori* selection of ROIs (Ashburner & Friston, 2000). Structural magnetic resonance imaging (MRI) studies have the additional benefit of facilitating comparison across studies, as they are paradigm-free, unlike functional MRI studies in which cross-study comparisons may be obscured due to differences in the paradigms employed.

A growing number of VBM studies of MDD have been conducted, allowing for the aggregation of findings using meta-analytic methods. Across three separate and recent meta-analyses of VBM studies, the most consistent finding reported was that subjects with MDD had reduced gray matter volume in the anterior cingulate cortex (ACC) relative to those without MDD (Bora *et al.* 2012; Du *et al.* 2012; Lai, 2013; for examples of individual studies, see Tang *et al.* 2007; Treadway *et al.* 2009). The ACC is a particularly large and heterogeneous structure in terms of function, receptor architecture and cytology (Vogt *et al.* 2005; Palomero-Gallagher *et al.* 2008; Pizzagalli, 2011), and has been subdivided into a more dorsal portion (dorsal ACC; dACC) and a more ventral subregion, the latter of which has been further divided into the rostral ACC (rACC; also referred to as the ‘pregenual’ or ‘perigenual’ ACC) and the subgenual ACC (sgACC; Etkin *et al.* 2011). Broadly speaking, a distinction may be made between the more ‘cognitive’ dACC *versus* the more ‘affective’ ventral subdivision encompassing the rACC and sgACC. Indeed, the ventral portion of the ACC has rich interconnections with limbic and paralimbic structures [e.g. amygdala, nucleus accumbens, orbitofrontal cortex (OFC), periaqueductal gray], whereas the dACC has strong connections with regions in the dorsolateral prefrontal cortex (DLPFC), parietal cortex and supplementary motor areas. Consistent with these differential connectivity patterns, the ventral ACC has been implicated in emotion expression and regulation, as well as assigning emotional valence to both internal and external stimuli. In contrast, the dACC has been associated with the processing of cognitively demanding information and response selection (Etkin *et al.* 2011; Pizzagalli, 2011).

Given these patterns of findings, it is interesting to note that gray matter volume reductions in the ACC in MDD subjects seem to be largely concentrated in a relatively focal region of the rACC (Bora *et al.* 2012), a core hub in Mayberg’s limbic–cortical dysregulation model

of depression (Mayberg, 1997). The structural deficit in the rACC observed in MDD is intriguing given that this region has been implicated in cognitive and emotional processes that are believed to be abnormal in many depressed individuals. These include: (1) emotion regulation and assigning emotional valence to stimuli (Pizzagalli, 2011; D'Avanzato *et al.* 2013); (2) self-referential processing (Northoff *et al.* 2006; Yoshimura *et al.* 2009); (3) inhibitory processes (e.g. Bush *et al.* 2000; Shafritz *et al.* 2006; Eugene *et al.* 2010); (4) error processing (e.g. Holmes *et al.* 2010; Santesso *et al.* 2012); and (5) optimistic biases (i.e. relatively high probability estimates of positive events occurring to oneself compared with others; Sharot *et al.* 2007; Blair *et al.* 2013). Indeed, hyper-responsiveness of this region has been shown to correlate with subclinical depressive mood in adolescent children (Killgore & Yurgelun-Todd, 2006). It is important to note that in addition to ACC abnormalities, other areas found to have reduced gray matter volume within MDD subjects in the above-mentioned meta-analyses include the middle and inferior frontal gyrus, hippocampus and thalamus (Kim *et al.* 2008; Vasic *et al.* 2008; Zou *et al.* 2010; Wagner *et al.* 2011; Du *et al.* 2012), as well as the DLPFC and dorsomedial prefrontal cortex (Bora *et al.* 2012). Given that the thalamus connects the cortex to negative emotion-generating limbic structures such as the amygdala (Price & Drevets, 2009), relatively reduced thalamic gray matter volume may help account for deficits in top-down regulation of negative affect among individuals more prone to experiencing depressive symptoms. Moreover, reduced hippocampal volume in depression may be attributable to stress-related or neurotoxic processes associated with cumulative exposure to stress and depressive symptomatology (MacQueen *et al.* 2003; Warner-Schmidt & Duman, 2006).

As is the case with the bulk of functional MRI research, studies investigating structural brain abnormalities in depression have typically employed a categorical rather than dimensional approach to conceptualizing depression. Namely, studies have usually compared a group of subjects diagnosed with MDD, as defined by current Diagnostic and Statistical Manual of Mental Disorders (DSM) criteria, with a group of individuals who do not meet MDD diagnostic criteria [also see the International Classification of Diseases (ICD) diagnostic system; World Health Organization, 1993]. The extent to which depressive symptoms – irrespective of DSM-defined MDD status – are linearly related to gray matter volume reductions in theoretically important brain regions (e.g. the ACC) is not well understood. Indeed, the National Institute of Mental Health (NIMH), through their Research Domain Criteria (RDoC) initiative, has encouraged a dimensional approach to the study of psychopathology as opposed to an over-reliance on traditional diagnostic categories (e.g. see NIMH funding opportunity ‘Dimensional Approaches to Research Classification in Psychiatric Disorders’ no. RFA-MH-13-080). Previous studies comparing dimensional *versus* categorical models of depression, including findings from taxometric analyses, have tended to support dimensional conceptualizations of depressive symptoms (Prisciandaro & Roberts, 2009), and it is likely that such approaches may ultimately lead to a more valid understanding of the underlying neurobiological basis of depression than research focused on categorical diagnostic distinctions.

It is also important to note that subthreshold levels of depressive symptoms (i.e. severity levels below DSM criteria) have been found to be associated with a range of negative

outcomes (Cuijpers *et al.* 2004; Fergusson *et al.* 2005), including a significantly increased risk of developing MDD (Klein *et al.* 2013). These findings highlight the importance of investigating the neurobiological underpinnings of subclinical levels of depressive symptoms. A few previous studies have explored structural abnormalities in subclinical depression, but these studies differed widely in study samples (e.g. youth *versus* the elderly), analytic strategy (ROI *versus* whole-brain approach, group comparisons *versus* dimensional analyses) and depression measures employed. For example, in a ROI-based study focused on rACC volumes in children and adolescents (aged 7–17 years) with no history of MDD or psychiatric disorder, Boes *et al.* (2008) found that males with depressive symptoms had lower rACC volumes bilaterally than males without depressive symptoms. This pattern was not observed in females. In addition, in a recent VBM study comparing adults with elevated, but subthreshold, levels of depressive symptoms *versus* those with no depressive symptoms, Hayakawa *et al.* (2013) reported that subclinically depressed females had smaller gray matter volume in the bilateral ACC and in the right rectal gyrus. The pattern was not observed in males. There has also been a series of studies examining structural abnormalities in elderly populations with subthreshold depression (e.g. Taki *et al.* 2005; Dotson *et al.* 2009; Ries *et al.* 2009), with mixed findings regarding the ACC (Ries *et al.* 2009). None of the above-mentioned studies employed the commonly used Beck Depression Inventory (BDI; Beck & Steer, 1993; Beck *et al.* 1996).

In line with the NIMH's RDoC initiative, the current study examines – in a dimensional rather than categorical manner – the association between gray matter volume and depressive symptoms in a non-clinical sample. We employed a whole-brain VBM regression approach with a sample of adults (aged 18–45 years) deemed free of any history of DSM-IV Axis I diagnoses. Importantly, to examine the consistency of any emerging findings, two separate instruments were used to assess depressive symptoms, including the commonly used BDI and the Depression subscale of the Personality Assessment Inventory (PAI-DEP; Morey, 1991). The PAI-DEP was selected in addition to the BDI for several reasons. First, the BDI, like the Hamilton Rating Scale for Depression (Hamilton, 1960), tends to exhibit very low mean scores and little variability in healthy samples. In contrast, the PAI-DEP includes items intended to assess the full range of depressive symptoms and with greater variability of scores across non-clinical samples (Morey, 2007). Moreover, whereas the BDI has a relatively heavy representation of cognitive aspects of depression, the PAI-DEP was designed to tap cognitive, affective and physiological symptoms of depression with generally equal weighting across these three domains.

Informed by the literature discussed above, we hypothesized that the severity of mild depressive symptoms, even in a healthy subclinical population, would be associated with reduced gray matter volume in the rACC, hippocampus, thalamus, as well as the DLPFC and dorsomedial prefrontal cortex.

Method

Participants

A total of 54 healthy participants (28 females), aged 18 to 45 years (mean=30.9 years, S.D.=8.13 years), were recruited from the greater Boston region through flyers posted in the

area and from Internet advertisements. The sample was 69.1% Caucasian, 16.4% African-American, 9.1% Asian, 1.8% other, and 3.6% 'more than one race'. In addition, 3.6% classified themselves as Hispanic. All participants identified English as their primary language. A trained Bachelor's-level technician screened all participants for evidence of mental disorders and medical conditions using a structured series of questions adapted from the Structured Clinical Interview for DSM-IV, text revision (SCID-I; First *et al.* 2001). All participants included in the current study were determined to be free of any history of DSM-IV Axis I mental disorders, excessive substance use, drug or alcohol treatment, or severe medical or neurological conditions. The current study was embedded within a larger study on the neural correlates of emotional intelligence in which subjects completed a battery of self-report measures and behavioral tasks. Unrelated findings emerging from that larger study have been reported elsewhere (Killgore *et al.* 2012a,b, 2013; Webb *et al.* 2013) and will not be discussed further here. To reduce subject burden, self-report measures (including the BDI and PAI) were administered 1 day after the MRI scan.

BDI

The BDI (Beck & Steer, 1993; Beck *et al.* 1996) is a commonly used 21-item self-report measure of depressive symptoms with strong psychometric properties (Beck *et al.* 1988). The BDI has been shown to have acceptably high internal consistency reliability in psychiatric ($\alpha=0.86$; Beck *et al.* 1988) and non-clinical ($\alpha=0.88$; Killgore, 1999) samples.

Personality Assessment Inventory (PAI)

The PAI personality assessment (Morey, 1991) contains 344 statements that are rated using one of four response options ('false, not at all true', 'slightly true', 'mainly true', 'very true'). The measure yields 11 clinical subscales (Somatic Complaints, Anxiety, Anxiety-Related Disorders, Depression, Mania, Paranoia, Schizophrenia, Borderline Features, Antisocial features, Drug-Related Problems, Alcohol-Related Problems). Given the current study's focus on depressive symptoms, we restricted our analyses to the Depression subscale of the PAI (PAI-DEP). Raw scores were converted into T scores. The PAI-DEP scale shows high internal consistency reliability for clinical ($\alpha=0.87$) and non-clinical ($\alpha=0.93$) samples (Morey, 2007). The use of the PAI, in addition to the BDI, allows us to test the consistency of our findings across two measures of depression, which sample somewhat different aspects of depression (i.e. whereas the BDI weights cognitive items more heavily, the PAI is designed to tap cognitive, affective and physiological symptoms of depression with generally equal weighting across these three domains).

MRI parameters

Structural magnetic resonance images were acquired at 3.0 T using a 12-channel head coil (Siemens Tim Trio; Germany) and a T1-weighted three-dimensional magnetization-prepared rapid acquisition with gradient echo (MPRAGE) sequence using the following parameters: repetition time=2.1 s; echo time=2.25 ms; flip angle=12°; 128 sagittal slices; 256×256 matrix; in-plane resolution=1×1×1 mm; slice thickness=1.33 mm.

VBM

Preprocessing of structural images was conducted using the VBM8 toolbox (<http://dbm.neuro.uni-jena.de/vbm.html>) in SPM8 (Wellcome Department of Imaging Neuroscience Group, UK; <http://www.fil.ion.ucl.ac.uk/spm>). The VBM8 default settings were used (i.e. modulated VBM – gray matter volume was corrected for total intracranial volume). Each structural image was DARTEL-normalized (diffeomorphic anatomical registration through exponentiated lie algebra) to Montreal Neurological Institute (MNI) space and subsequently segmented into gray matter, white matter and cerebrospinal fluid using a fully automated algorithm within SPM8. Standard quality checks of segmentation and sample homogeneity were conducted, before normalized gray matter images were smoothed with an 8 mm full-width at half-maximum (FWHM) Gaussian kernel. In other words, the data were preprocessed such that the dependent variable of interest was the local concentration of gray matter at each local voxel without concern for differences in morphological shape (Ashburner & Friston, 2000).

Statistical analysis

Scores on both depression scales were initially tested for normality. To assess the severity of skew and kurtosis, z scores were computed (Field, 2009a). Consistent with prior work examining the distribution of BDI scores in the population (Veerman *et al.* 2009), scores in the present sample were positively skewed ($z=4.10$, $p<0.001$; Kline, 2005; Field, 2009b). Accordingly, a square-root transformation was applied to reduce the positive skew (transformed BDI, $z=0.861$, $p>0.05$). For simplicity, the term BDI is used henceforth, rather than repeating the more accurate but unwieldy term ‘square-root transformed BDI’.

Normalized smoothed gray matter images were entered into a series of three random-effects multiple regression analyses in SPM8. A non-stationary cluster extent correction was implemented in SPM8 according to the random field theory (RFT) framework (Hayasaka *et al.* 2004). In the first regression, we tested the association between BDI scores and voxelwise gray matter volume. Normalized smoothed gray matter images were entered as the dependent variable into a whole-brain general linear model. For statistical inference, a whole-brain false discovery rate (FDR)-corrected height threshold of $p < 0.05$ was applied. A cluster extent threshold of $k = 81$ (i.e. determined statistically as the number of voxels per cluster that would be expected by chance based on the theory of Gaussian random fields applied to this analysis as provided in standard VBM8 output) was also applied for the purpose of reducing noise in the images and to minimize reporting of clusters of little interest, but was not considered for statistical inference. For the second regression, we conducted a similar analysis with PAI-DEP as the covariate of interest (height threshold of FDR $p < 0.05$ for statistical inference, with an empirically derived cluster extent of $k = 65$). Finally, to examine the overlap in gray matter volume correlations across the BDI and PAI-DEP analyses, the activation clusters obtained from the first regression analysis (i.e. BDI) were used as a region of interest (ROI) mask in conjunction with the output from the second regression (i.e. PAI-DEP; height threshold FDR $p < 0.05$, cluster extent $k = 65$). Thus, the resulting findings from the latter analysis reflect overlapping regions where gray matter volume correlated significantly with self-reported depression symptoms on both the BDI and PAI-DEP scales. Age and gender were included as nuisance covariates in all analyses.

Results

The mean raw BDI score was 3.89 (S.D.=4.56, range=0–17), with seven participants scoring above the suggested clinical criterion for ‘minimal depression’ (i.e. total BDI score >9; Beck *et al.* 1996). The mean PAI-DEP score was 46.20 (S.D.=7.97, range=36–71)^{1†}. The Pearson correlation between the BDI and PAI-DEP in the current sample was $r=0.67$ ($p<0.001$).

As detailed in Table 1, relatively higher BDI scores were associated with reduced gray matter volume in 16 clusters, including: (i) bilateral anterior cingulate, bilateral medial frontal cortex and left medial OFC (see Fig. 1); (ii) bilateral anterior/mid-cingulate; (iii) left thalamus; and (iv) left insula. As shown in Table 2, relatively higher PAI-DEP scores were associated with reduced gray matter volume in nine clusters, including: (i) left anterior cingulate and left medial OFC (see Fig. 2); (ii) bilateral medial OFC; and (iii) bilateral thalamus.

The conjunction between the two primary analyses was used to identify the regions showing common overlap between the gray matter volume correlations for the two depression measures used in the current study. As shown in Table 3, this analysis showed that the BDI and PAI-DEP scores were both associated with reduced gray matter volume in four common regions: (i) left medial OFC and anterior cingulate (Fig. 3); (ii) left thalamus (Fig. 4); (iii) right superior medial frontal gyrus/superior frontal gyrus; and (iv) right superior temporal gyrus extending to the superior temporal pole.

Discussion

The present study complements prior research on structural brain abnormalities in depression. Specifically, previous studies examining structural deficits in depression have typically relied on categorical comparisons of subjects diagnosed with MDD *versus* healthy controls. The extent to which depressive symptoms in individuals who do not meet DSM criteria for MDD are linearly related to structural differences in key brain regions is not well understood. Inspired by the NIMH’s RDoC initiative, which highlights dimensional/continuous – rather than DSM-based categorical – conceptualization of psychopathology, we examined the linear associations between gray matter volume and depressive symptoms in a sample of adults deemed free of any history of DSM-IV Axis I diagnoses. Paralleling findings from prior studies employing a categorical (i.e. MDD *versus* healthy controls) analytic approach, we found that relatively higher depressive symptoms were associated with reduced gray matter volume in the left rACC (extending into the medial OFC). Perhaps the most consistently reported finding in the existing literature is that subjects with MDD have reduced gray matter volume in the ACC relative to those without MDD (for recent meta-analytic reviews, see Bora *et al.* 2012; Du *et al.* 2012; Lai, 2013). The current findings extend prior work by suggesting that reduced ACC/OFC gray matter volume can be observed even in a sample that does not meet DSM criteria for MDD, but who nevertheless report relatively elevated levels of depressive symptoms. In addition, we also observed an

¹Two outliers were identified. Specifically, one subject was an outlier on both the BDI ($z = 4.68$) and PAI Depression subscale ($z = 4.00$). This subject’s data were deleted from the current dataset.

[†]The notes appear after the main text.

association between relatively elevated depressive symptoms and reduced gray matter volume in the left thalamus, as well as the right superior medial frontal gyrus/superior frontal gyrus, and right superior temporal gyrus extending to the superior temporal pole. The fact that this finding emerged across both of our depressive symptom measures, including the commonly used BDI, as well as the depression subscale of the PAI (PAI-DEP), suggests that these findings probably reflect true and robust associations between gray matter and depressive symptoms within the subclinical range.

Regarding our ACC finding, it is interesting to note that gray matter volume reductions were concentrated in the rACC. The rACC has been implicated in a range of cognitive/affective functions, including: (1) optimistic biases (e.g. Blair *et al.* 2013); (2) error processing (e.g. Holmes *et al.* 2010; Santesso *et al.* 2012); (3) self-referential processing (Northoff *et al.* 2006; Yoshimura *et al.* 2009); (4) inhibitory processes (e.g. Bush *et al.* 2000; Shafritz *et al.* 2006; Eugene *et al.* 2010); and (5) regulation of emotional conflict and dampening of amygdala hyperactivity (Etkin *et al.* 2006). Given these patterns of findings, one could speculate that structural abnormalities in the rACC in part underlie the biased information processing and negative maladaptive cognitive features described in the cognitive model of depression (Beck & Alford, 2009; DeRubeis *et al.* 2010). More specifically, to the extent that the rACC does play a role in the aforementioned functions, relatively reduced gray matter volume in this region may help account for the depressogenic, cognitive features of depression, including: (1) pessimistic (rather than optimistic) biases (e.g. Strunk *et al.* 2006); (2) hypersensitivity to perceived errors and negative feedback (e.g. Elliott *et al.* 1998; Pizzagalli *et al.* 2006); (3) maladaptive self-referential cognitive processes (e.g. Nolen-Hoeksema, 1991; Nolen-Hoeksema *et al.* 2008; Pizzagalli, 2011); (4) difficulties inhibiting negative information (e.g. Goeleven *et al.* 2006); and (5) emotion regulation deficits (D'Avanzato *et al.* 2013). These abnormal cognitive and emotion regulatory features of depression do not appear to be categorical in nature (i.e. present in MDD, yet absent in those who do not meet DSM criteria for the disorder). Rather, behavioral and neural findings suggest that at least some of these features are linearly related to depressive symptoms across a broad range of severity, from no or very low levels of depressive symptoms to very high levels (e.g. Joormann, 2004; Pizzagalli *et al.* 2006; Strunk *et al.* 2006). Overall, and consistent with the NIMH's RDoC initiative, these findings may highlight the limitations of restricting the study of abnormal cognitive, emotional and behavioral processes in depression to DSM-based categorical comparisons, and the need for additional research using dimensional/continuous conceptual and analytic approaches.

Although perhaps not as consistently reported as rACC findings, prior studies have also identified gray matter reductions in the thalamus among MDD subjects (Bielau *et al.* 2005; Kim *et al.* 2008; Vasic *et al.* 2008; Lee *et al.* 2011). The current study suggests that reductions in thalamic gray matter volume can also be observed in individuals with subclinical, yet relatively elevated, levels of depressive symptoms. The latter finding is intriguing given that the thalamus connects the cortex to negative emotion-generating limbic structures such as the amygdala (Price & Drevets, 2009). Thus, relatively reduced thalamic gray matter volume, coupled with volumetric reductions in the rACC, may also help account

for the deficits in top-down regulation of negative emotions among individuals more prone to experiencing depressive symptoms.

In addition, previous depression studies have also reported volume reductions in the superior temporal gyrus/temporal pole (e.g. Caetano *et al.* 2004; Abe *et al.* 2010) and superior frontal gyrus (e.g. Serra-Blasco *et al.* 2013). Interestingly, Caetano *et al.* (2004) found that right superior temporal gyrus volume was inversely correlated with length of depression illness. Similarly, the findings of Serra-Blasco *et al.* (2013) revealed that participants who suffered from chronic, treatment-resistant depression exhibited the smallest volumes in frontotemporal regions. It is tempting to attribute such volumetric reductions to neurotoxic effects of stress and depression accumulating over time. However, conclusions regarding the direction of effects are necessarily tempered when cross-sectional designs are employed.

It may be that reduced gray matter volume in the regions highlighted in the current study (e.g. rACC, thalamus) increase the risk of experiencing depressive symptoms. Conversely, these structural differences may also reflect the neurotoxic effects of prior depressive symptoms and stress. It should be noted that we intentionally restricted our sample to those without prior episodes of depression. Nevertheless, reduced gray matter volume could of course still be due to cumulative exposure to subthreshold depressive symptoms and neurotoxic stress processes. Methodologically sound longitudinal studies are needed to disentangle causal direction and test whether or not reduced gray matter volume in certain brain regions (e.g. rACC) prospectively predicts depression onset, and/or whether structural abnormalities are a consequence of depression due to particular neuropathological processes associated with the disorder. Longitudinal studies could help delineate factors that predict the development of these structural brain abnormalities over time. For example, prior research has found that smaller ACC volumes are associated with retrospective reports of early life stressors (Cohen *et al.* 2006). This finding highlights the possible neurotoxic effects of early life stress on the developing brain. Ideally, however, given that current symptomatology may bias recall of early life stressors (e.g. Southwick *et al.* 1997), prospective longitudinal, rather than retrospective studies would be needed to more conclusively establish the link between early life stress and structural brain abnormalities, ideally complementing self-report measures of stressors with more 'objective' measures (e.g. assessments of stress hormones).

A strength of the current study is that we tested the consistency of our findings across two separate measures of depressive symptoms. In addition, in contrast to many prior studies, we used a whole-brain VBM approach, rather than an ROI approach, the latter of which may bias investigators towards examining only a subset of brain regions and possibly ignoring other relevant regions (Ashburner & Friston, 2000). However, despite these strengths, several limitations of the current study should be noted. As discussed above, our findings were cross-sectional in nature and we cannot draw strong inferences regarding causal direction between structural brain differences and depressive symptoms. Moreover, our study focused on a sample without a history of Axis I pathology. It will be important for future studies to examine the full continuum from no depression to very severe levels of depressive symptoms, to fully examine the extent to which depressive symptoms are linearly related with structural brain differences. In addition, given our non-clinical sample,

variability in depression scores was, as expected, limited. Thus, restriction in the range of depression scores may have limited our ability to detect significant effects in other brain regions. It should be noted that the current findings indicate that we did have sufficient variability to detect reduced gray matter volume in a number of regions, across two separate depression measures.

Acknowledgments

This study was supported by a US Army Medical Research Acquisition Activity (USAMRAA) grant (no. W81XWH-09-1-0730 to W.D.S.K.). The grant provided support for subject remuneration, scan costs, supplies and salary.

References

- Abe O, Yamasue H, Kasai K, Yamada H, Aoki S, Inoue H, Takei K, Suga M, Matsuo K, Kato T, Masutani Y, Ohtomo K. Voxel-based analyses of gray/white matter volume and diffusion tensor data in major depression. *Psychiatry Research*. 2010; 181:64–70. [PubMed: 19959342]
- Ashburner J, Friston KJ. Voxel-based morphometry –the methods. *NeuroImage*. 2000; 11:805–821. [PubMed: 10860804]
- Beck, AT.; Alford, BA. *Depression: Causes and Treatments*. University of Pennsylvania Press; Philadelphia: 2009.
- Beck, AT.; Steer, RA. *Beck Depression Inventory Manual*. Harcourt Brace; San Antonio: 1993.
- Beck, AT.; Steer, RA.; Brown, GK. *Beck Depression Inventory Manual*. 2. Harcourt Brace; San Antonio: 1996.
- Beck AT, Steer RA, Carbin MG. Psychometric properties of the Beck Depression Inventory: twenty-five years of evaluation. *Clinical Psychology Review*. 1988; 8:77–100.
- Bielau H, Trubner K, Krell D, Agelink MW, Bernstein HG, Stauch R, Baumann B. Volume deficits of subcortical nuclei in mood disorders: a postmortem study. *European Archives of Psychiatry and Clinical Neuroscience*. 2005; 255:401–412. [PubMed: 16080015]
- Blair KS, Otero M, Teng C, Jacobs M, Odenheimer S, Pine DS, Blair RJ. Dissociable roles of ventromedial prefrontal cortex (vmPFC) and rostral anterior cingulate cortex (rACC) in value representation and optimistic bias. *NeuroImage*. 2013; 78:103–110. [PubMed: 23567883]
- Boes AD, McCormick LM, Coryell WH, Nopoulos P. Cortex volume correlates with depressed mood in normal healthy children. *Biological Psychiatry*. 2008; 63:391–397. [PubMed: 17916329]
- Bora E, Fornito A, Pantelis C, Yucel M. Gray matter abnormalities in major depressive disorder: a meta-analysis of voxel based morphometry studies. *Journal of Affective Disorders*. 2012; 138:9–18. [PubMed: 21511342]
- Bush G, Luu P, Posner MI. Cognitive and emotional influences in anterior cingulate cortex. *Trends in Cognitive Sciences*. 2000; 4:215–222. [PubMed: 10827444]
- Caetano SC, Hatch JP, Brambilla P, Sassi RB, Nicoletti M, Mallinger AG, Frank E, Kupfer DJ, Keshaven MS, Soares JC. Anatomical MRI study of hippocampus and amygdala in patients with current and remitted major depression. *Psychiatry Research*. 2004; 132:141–147. [PubMed: 15598548]
- Cohen RA, Grieve S, Hoth KF, Paul RH, Sweet L, Tate D, Williams LM. Early life stress and morphometry of the adult anterior cingulate cortex and caudate nuclei. *Biological Psychiatry*. 2006; 59:975–982. [PubMed: 16616722]
- Cuijpers P, de Graaf R, van Dorsselaer S. Minor depression: risk profiles, functional disability, health care use and risk of developing major depression. *Journal of Affective Disorders*. 2004; 79:71–79. [PubMed: 15023482]
- D'Avanzato C, Joormann J, Siemer M, Gotlib IH. Emotion regulation in depression and anxiety: examining diagnostic specificity and stability of strategy use. *Cognitive Therapy and Research*. 2013; 37:968–980.

- DeRubeis, R.J.; Webb, C.A.; Tang, T.Z.; Beck, A.T. Cognitive therapy. In: Dobson, K.S., editor. *Handbook of Cognitive–Behavioral Therapies*. 3. Guilford; New York: 2010. p. 277–316.
- Dotson VM, Davatzikos C, Kraut MA, Resnick SM. Depressive symptoms and brain volumes in older adults: a longitudinal magnetic resonance imaging study. *Journal of Psychiatry and Neuroscience*. 2009; 34:367–375. [PubMed: 19721847]
- Du MY, Wu QZ, Yue Q, Li J, Liao Y, Kuang WH, Gong QY. Voxelwise meta-analysis of gray matter reduction in major depressive disorder. *Progress in Neuro-Psychopharmacology and Biological Psychiatry*. 2012; 36:11–16. [PubMed: 22001316]
- Elliott R, Sahakian BJ, Michael A, Paykel ES, Dolan RJ. Abnormal neural response to feedback on planning and guessing tasks in patients with unipolar depression. *Psychological Medicine*. 1998; 28:559–571. [PubMed: 9626713]
- Etkin A, Egner T, Kalisch R. Emotional processing in anterior cingulate and medial prefrontal cortex. *Trends in Cognitive Sciences*. 2011; 15:85–93. [PubMed: 21167765]
- Etkin A, Egner T, Peraza DM, Kandel ER, Hirsch J. Resolving emotional conflict: a role for the rostral anterior cingulate cortex in modulating activity in the amygdala. *Neuron*. 2006; 51:871–882. [PubMed: 16982430]
- Eugene F, Joermann J, Cooney RE, Atlas LY, Gotlib IH. Neural correlates of inhibitory deficits in depression. *Psychiatry Research*. 2010; 181:30–35. [PubMed: 19962859]
- Fergusson DM, Horwood LJ, Ridder EM, Beautrais AL. Subthreshold depression in adolescence and mental health outcomes in adulthood. *Archives of General Psychiatry*. 2005; 62:66–72. [PubMed: 15630074]
- Field, A. *Discovering Statistics Using SPSS*. 3. Sage Publications, Inc; Thousand Oaks, CA: 2009a. p. 138–139.
- Field, A. *Discovering Statistics Using SPSS*. 3. Sage Publications, Inc; Thousand Oaks, CA: 2009b. p. 154–156.
- First, M.; Spitzer, R.; Gibbon, M.; Williams, J. *Structured Clinical Interview for DSM-IV-TR – Axis I Disorders, Research Version, Patient Edition with Psychotic Screen (SCID-I/P W/PSY SCREEN)*. Biometrics Research, New York State Psychiatric Institute; New York: 2001.
- Goeleven E, De Raedt R, Baert S, Koster EH. Deficient inhibition of emotional information in depression. *Journal of Affective Disorders*. 2006; 93:149–157. [PubMed: 16647141]
- Hamilton M. A rating scale for depression. *Journal of Neurology, Neurosurgery, and Psychiatry*. 1960; 23:56–62.
- Hayakawa YK, Sasaki H, Takao H, Mori H, Hayashi N, Kunimatsu A, Ohtomo K. Structural brain abnormalities in women with subclinical depression, as revealed by voxel-based morphometry and diffusion tensor imaging. *Journal of Affective Disorders*. 2013; 144:263–268. [PubMed: 23141669]
- Hayasaka S, Phan KL, Liberzon I, Worsley KJ, Nichols TE. Nonstationary cluster-size inference with random field and permutation methods. *NeuroImage*. 2004; 22:676–687. [PubMed: 15193596]
- Holmes AJ, Bogdan R, Pizzagalli DA. Serotonin transporter genotype and action monitoring dysfunction: a possible substrate underlying increased vulnerability to depression. *Neuropsychopharmacology*. 2010; 35:1186–1197. [PubMed: 20090673]
- Joermann J. Attentional bias in dysphoria: the role of inhibitory processes. *Cognition and Emotion*. 2004; 18:125–147.
- Killgore WD. Empirically derived factor indices for the Beck Depression Inventory. *Psychological Reports*. 1999; 84:1005–1013. [PubMed: 10408220]
- Killgore WD, Schwab ZJ, Kipman M, DelDonno SR, Weber M. Voxel-based morphometric gray matter correlates of daytime sleepiness. *Neuroscience Letters*. 2012a; 518:10–13. [PubMed: 22542893]
- Killgore WD, Schwab ZJ, Weber M, Kipman M, Deldonna SR, Weiner MR, Rauch SL. Daytime sleepiness affects prefrontal regulation of food intake. *NeuroImage*. 2013; 71:216–223. [PubMed: 23353029]
- Killgore WD, Schwab ZJ, Weiner MR. Self-reported nocturnal sleep duration is associated with next-day resting state functional connectivity. *Neuroreport*. 2012b; 23:741–745. [PubMed: 22872066]

- Killgore WD, Yurgelun-Todd DA. Ventromedial prefrontal activity correlates with depressed mood in adolescent children. *Neuroreport*. 2006; 17:167–171. [PubMed: 16407765]
- Kim MJ, Hamilton JP, Gotlib IH. Reduced caudate gray matter volume in women with major depressive disorder. *Psychiatry Research*. 2008; 164:114–122. [PubMed: 18930633]
- Klein DN, Glenn CR, Kosty DB, Seeley JR, Rohde P, Lewinsohn PM. Predictors of first lifetime onset of major depressive disorder in young adulthood. *Journal of Abnormal Psychology*. 2013; 122:1–6. [PubMed: 22889243]
- Kline, RB. *Principles and Practice of Structural Equation Modeling*. 2. Guilford Press; New York: 2005. p. 50-51.
- Koolschijn PC, van Haren NE, Lensvelt-Mulders GJ, Hulshoff Pol HE, Kahn RS. Brain volume abnormalities in major depressive disorder: a meta-analysis of magnetic resonance imaging studies. *Human Brain Mapping*. 2009; 30:3719–3735. [PubMed: 19441021]
- Lai CH. Gray matter volume in major depressive disorder: a meta-analysis of voxel-based morphometry studies. *Psychiatry Research*. 2013; 211:37–46. [PubMed: 23146253]
- Lee HY, Tae WS, Yoon HK, Lee BT, Paik JW, Son KR, Ham BJ. Demonstration of decreased gray matter concentration in the midbrain encompassing the dorsal raphe nucleus and the limbic subcortical regions in major depressive disorder: an optimized voxel-based morphometry study. *Journal of Affective Disorders*. 2011; 133:128–136. [PubMed: 21546094]
- MacQueen GM, Campbell S, McEwen BS, Macdonald K, Amano S, Joffe RT, Nahmias C, Young LT. Course of illness, hippocampal function, and hippocampal volume in major depression. *Proceedings of the National Academy of Sciences USA*. 2003; 100:1387–1392.
- Mayberg HS. Limbic–cortical dysregulation: a proposed model of depression. *Journal of Neuropsychiatry*. 1997; 9:471–481.
- Morey, LC. *Personality Assessment Inventory*. Psychological Assessment Resources Inc; Lutz, FL: 1991.
- Morey, LC. *Personality Assessment Inventory: Professional Manual*. 2. Psychological Assessment Resources Inc; Lutz, FL: 2007.
- Nolen-Hoeksema S. Responses to depression and their effects on the duration of depressive episodes. *Journal of Abnormal Psychology*. 1991; 100:569–582. [PubMed: 1757671]
- Nolen-Hoeksema S, Wisco BE, Lyubomirsky S. Rethinking rumination. *Perspectives on Psychological Science*. 2008; 3:400–424.
- Northoff G, Heinzl A, de Greck M, Bermpohl F, Dobrowolny H, Panksepp J. Self-referential processing in our brain – a meta-analysis of imaging studies on the self. *NeuroImage*. 2006; 31:440–457. [PubMed: 16466680]
- Palomero-Gallagher N, Mohlberg H, Zilles K, Vogt B. Cytology and receptor architecture of human anterior cingulate cortex. *Journal of Comparative Neurology*. 2008; 508:906–926. [PubMed: 18404667]
- Pizzagalli DA. Frontocingulate dysfunction in depression: toward biomarkers of treatment response. *Neuropsychopharmacology*. 2011; 36:183–206. [PubMed: 20861828]
- Pizzagalli DA, Peccoralo LA, Davidson RJ, Cohen JD. Resting anterior cingulate activity and abnormal responses to errors in subjects with elevated depressive symptoms: a 128-channel EEG study. *Human Brain Mapping*. 2006; 27:185–201. [PubMed: 16035102]
- Price JL, Drevets WC. Neurocircuitry of mood disorders. *Neuropsychopharmacology*. 2009; 35:192–216. [PubMed: 19693001]
- Prisciandaro JJ, Roberts JE. A comparison of the predictive abilities of dimensional and categorical models of unipolar depression in the National Comorbidity Survey. *Psychological Medicine*. 2009; 39:1087–1096. [PubMed: 18845012]
- Ries ML, Wichmann A, Bendlin BB, Johnson SC. Posterior cingulate and lateral parietal gray matter volume in older adults with depressive symptoms. *Brain Imaging and Behavior*. 2009; 3:233–239. [PubMed: 19701486]
- Santesso DL, Bogdan R, Birk JL, Goetz EL, Holmes AJ, Pizzagalli DA. Neural responses to negative feedback are related to negative emotionality in healthy adults. *Social Cognitive and Affective Neuroscience*. 2012; 7:794–803. [PubMed: 21917847]

- Serra-Blasco M, Portella MJ, Gómez-Ansón B, de Diego-Adeliño J, Vives-Gilabert Y, Puigdemont D, Granell E, Santos A, Alvarez E, Pérez V. Effects of illness duration and treatment resistance on grey matter abnormalities in major depression. *British Journal of Psychiatry*. 2013; 202:434–440. [PubMed: 23620451]
- Shafritz KM, Collins SH, Blumberg HP. The interaction of emotional and cognitive neural systems in emotionally guided response inhibition. *NeuroImage*. 2006; 31:468–475. [PubMed: 16480897]
- Sharot T, Riccardi MA, Raio CM, Phelps EA. Neural mechanisms mediating optimism bias. *Nature*. 2007; 450:102–105. [PubMed: 17960136]
- Southwick SM, Morgan CA 3rd, Nicolaou AL, Charney DS. Consistency of memory for combat-related traumatic events in veterans of Operation Desert Storm. *American Journal of Psychiatry*. 1997; 154:173–177. [PubMed: 9016264]
- Strunk DR, Lopez H, DeRubeis RJ. Depressive symptoms are associated with unrealistic negative predictions of future life events. *Behaviour Research and Therapy*. 2006; 44:861–882. [PubMed: 16126162]
- Taki Y, Kinomura S, Awata S, Inoue K, Sato K, Ito H, Fukuda H. Male elderly subthreshold depression patients have smaller volume of medial part of prefrontal cortex and precentral gyrus compared with age-matched normal subjects: a voxel-based morphometry. *Journal of Affective Disorders*. 2005; 88:313–320. [PubMed: 16150493]
- Tang Y, Wang F, Xie G, Liu J, Li L, Su L, Liu Y, Hu X, He Z, Blumberg HP. Reduced ventral anterior cingulate and amygdala volumes in medication-naïve females with major depressive disorder: a voxel-based morphometric magnetic resonance imaging study. *Psychiatry Research*. 2007; 156:83–86. [PubMed: 17825533]
- Treadway MT, Grant MM, Ding Z, Hollon SD, Gore JC, Shelton RC. Early adverse events, HPA activity and rostral anterior cingulate volume in MDD. *PLoS One*. 2009; 4:e4887. [PubMed: 19325704]
- Vasic N, Walter H, Hose A, Wolf RC. Gray matter reduction associated with psychopathology and cognitive dysfunction in unipolar depression: a voxel-based morphometry study. *Journal of Affective Disorders*. 2008; 109:107–116. [PubMed: 18191459]
- Veerman JL, Dowrick C, Ayuso-Mateos JL, Dunn G, Barendregt JJ. Population prevalence of depression and mean Beck Depression Inventory score. *British Journal of Psychiatry*. 2009; 195:516–519. [PubMed: 19949201]
- Vogt B, Vogt L, Farber NB, Bush G. Architecture and neurocytology of monkey cingulate gyrus. *Journal of Comparative Neurology*. 2005; 485:218–239. [PubMed: 15791645]
- Wagner G, Koch K, Schachtzabel C, Schultz CC, Sauer H, Schlusser RG. Structural brain alterations in patients with major depressive disorder and high risk for suicide: evidence for a distinct neurobiological entity? *NeuroImage*. 2011; 54:1607–1614. [PubMed: 20832482]
- Warner-Schmidt JL, Duman RS. Hippocampal neurogenesis: opposing effects of stress and antidepressant treatment. *Hippocampus*. 2006; 16:239–249. [PubMed: 16425236]
- Webb CA, Schwab ZJ, Weber M, DelDonno S, Kipman M, Weiner MR, Killgore WDS. Convergent and divergent validity of integrative *versus* mixed model measures of emotional intelligence. *Intelligence*. 2013; 41:149–156.
- World Health Organization. *The ICD-10 Classification of Mental and Behavioural Disorders: Diagnostic Criteria for Research*. World Health Organization; Geneva: 1993.
- Yoshimura S, Ueda K, Suzuki S, Onoda K, Okamoto Y, Yamawaki S. Self-referential processing of negative stimuli within the ventral anterior cingulate gyrus and right amygdala. *Brain and Cognition*. 2009; 69:218–225. [PubMed: 18723260]
- Zou K, Deng W, Li T, Zhang B, Jiang L, Huang C, Sun X. Changes of brain morphometry in first-episode, drug-naïve, non-late-life adult patients with major depression: an optimized voxel-based morphometry study. *Biological Psychiatry*. 2010; 67:186–188. [PubMed: 19897176]

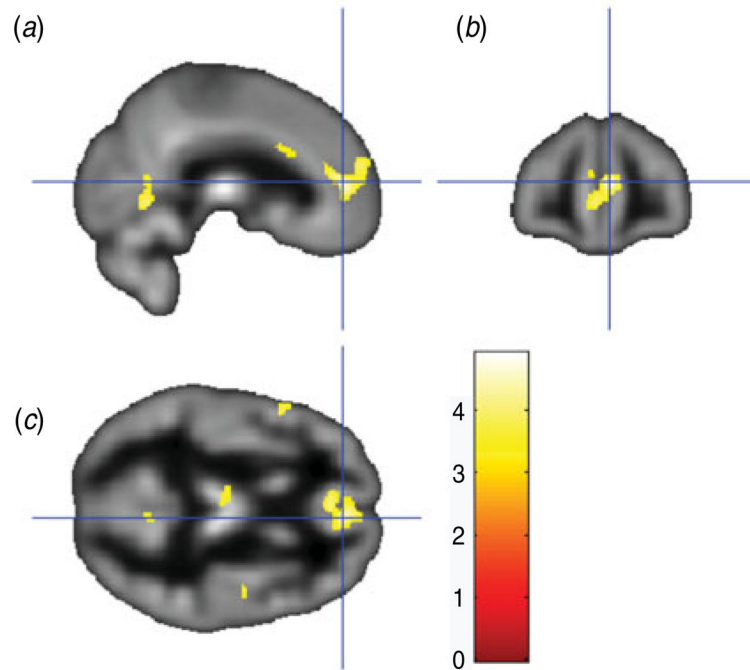


Fig. 1. Sagittal view (a), coronal view (b) and axial view (c) of the anterior cingulate/medial orbitofrontal cortex cluster (overlaid on sample-specific T1 mean image) that was negatively correlated with depressive symptoms on the Beck Depression Inventory. Montreal Neurological Institute (MNI) coordinates $x=6$, $y=46$, $z=10$; cluster size=1669 voxels.

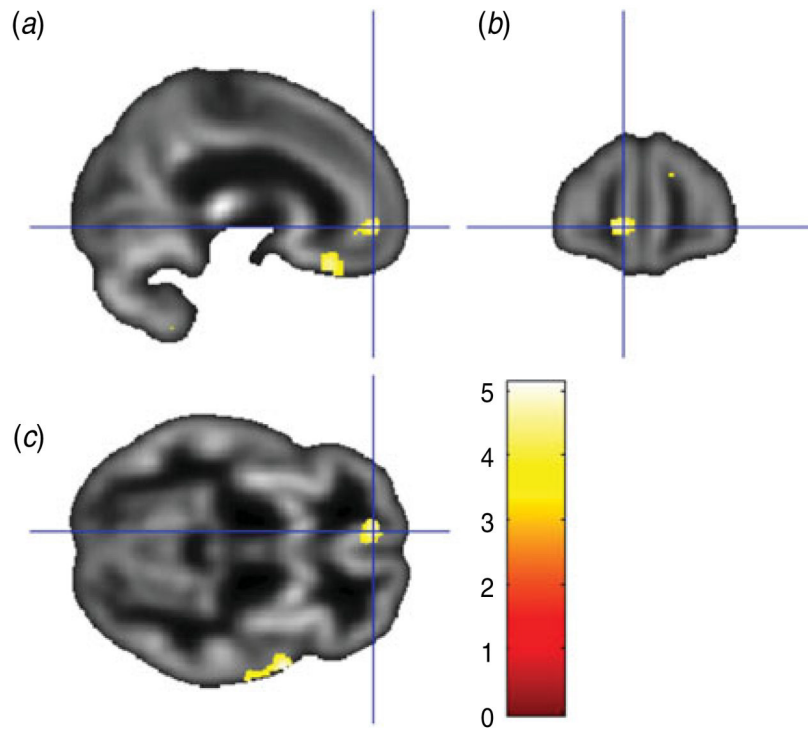


Fig. 2. Sagittal view (a), coronal view (b) and axial view (c) of the left anterior cingulate/medial orbitofrontal cortex cluster (overlaid on sample-specific T1 mean image) that was negatively correlated with depressive symptoms on the Depression subscale of the Personality Assessment Inventory. Montreal Neurological Institute (MNI) coordinates $x=-9$, $y=51$, $z=-5$; cluster size=209 voxels.

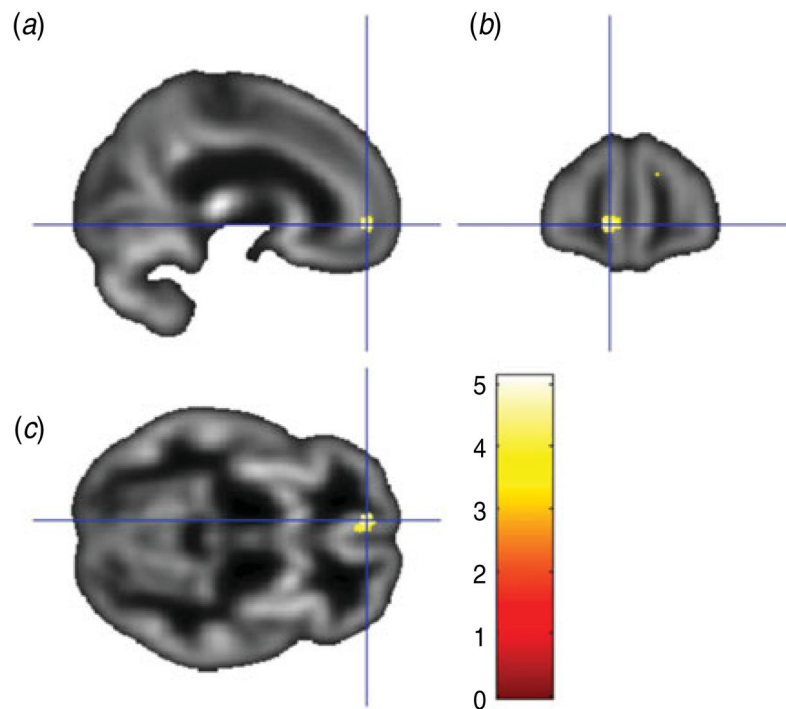


Fig. 3. Sagittal view (a), coronal view (b) and axial view (c) of the results of a conjunction analysis showing a cluster where gray matter volume in the left rostral anterior cingulate/medial orbitofrontal cortex (overlaid on sample-specific T1 mean image) was negatively correlated with depressive symptoms on both the Beck Depression Inventory and Depression subscale of the Personality Assessment Inventory. Montreal Neurological Institute (MNI) coordinates $x=-9, y=51, z=-5$; cluster size=116 voxels.

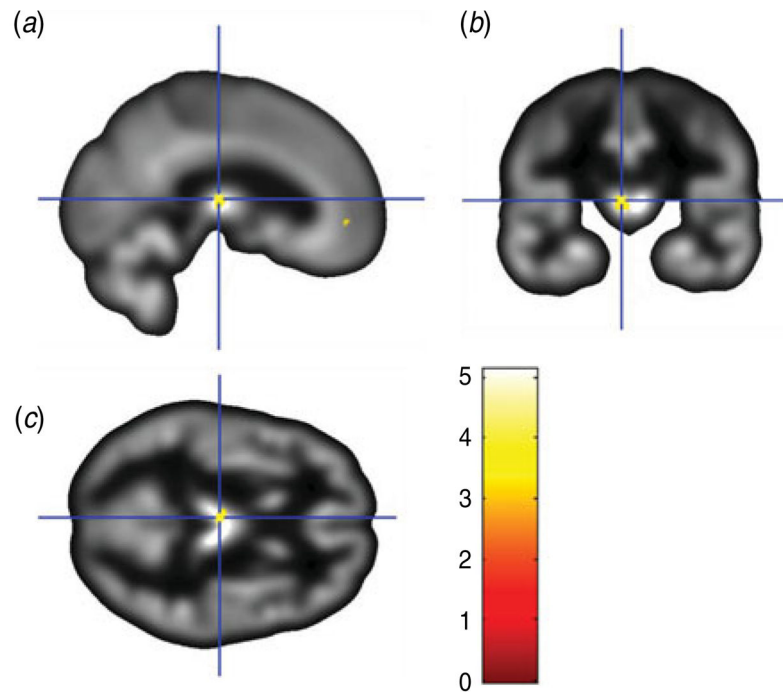


Fig. 4. Sagittal view (a), coronal view (b) and axial view (c) of the results of a conjunction analysis showing a cluster where gray matter volume in the left thalamus (overlaid on sample-specific T1 mean image) was negatively correlated with depressive symptoms on both the Beck Depression Inventory and Depression subscale of the Personality Assessment Inventory. Montreal Neurological Institute (MNI) coordinates $x=-2$, $y=19$, $z=10$; cluster size=79 voxels.

Table 1
Brain regions with reduced gray matter volume associated with higher Beck Depression Inventory scores

Region	Peak-level MNI coordinates ^d				T
	Cluster size	x	y	z	
Bilateral anterior cingulate	1669	6	46	10	4.33*
Right superior temporal/insula/Heschl's gyrus	737	51	-9	4	4.35*
Bilateral dorsal anterior cingulate/mid-cingulate	598	0	20	28	4.62 [†]
Left superior temporal gyrus	562	-51	6	-6	4.33 [†]
Right middle frontal gyrus	549	44	21	46	4.34*
Left middle cingulate gyrus	346	-8	-33	49	4.30
Right superior temporal pole/insula	297	48	15	-9	4.92 [†]
Left inferior frontal operculum	260	-52	14	15	4.20
Left postcentral gyrus	190	-50	-18	43	4.16
Left superior temporal pole	168	-32	14	-30	4.38
Right lingual gyrus	135	8	-61	0	4.03
Left thalamus	122	-8	-18	9	3.59
Right precentral gyrus	101	52	-9	40	3.78
Right middle temporal gyrus	101	68	-18	-3	3.96
Left insula	84	-33	18	4	3.71
Left middle occipital gyrus	83	-44	-81	0	4.16

MNI, Montreal Neurological Institute.

^a All false discovery rate-corrected $p < 0.05$; $k = 81$.

* $p < 0.05$,

[†] $p < 0.10$ cluster level, family-wise error corrected.

Brain regions with reduced gray matter volume associated with higher scores on the Depression subscale of the Personality Assessment Inventory

Table 2

Region	Cluster size	Peak-level MNI coordinates ^a			T
		x	y	z	
Right cerebellum	747	24	-78	-27	4.58
Right superior temporal gyrus/temporal pole	660	62	4	-2	5.13*
Bilateral thalamus	395	0	-19	10	4.47
Left superior orbitofrontal gyrus	248	-9	28	-24	4.56
Right superior frontal gyrus	213	14	56	25	4.21
Left medial OFC/ACC	209	-9	51	-5	4.68
Left cerebellum	163	-15	-55	-60	3.79
Bilateral caudate	96	0	10	1	4.61
Bilateral medial OFC	83	0	62	-12	4.32

MNI, Montreal Neurological Institute; OFC, orbitofrontal cortex; ACC, anterior cingulate cortex.

^a All false discovery rate-corrected $p < 0.05$; $k = 65$.

* $p < 0.05$.

† $p < 0.10$ cluster level, family-wise error corrected.

Brain regions with reduced gray matter volume associated with higher scores on both the Beck Depression Inventory and the Depression subscale of the Personality Assessment Inventory

Table 3

Region	Cluster size	Peak-level MNI coordinates ^a			T
		x	y	z	
Right superior temporal gyrus/temporal pole	251	62	4	-2	5.13*
Right superior frontal gyrus	153	14	56	25	4.21*
Left medial OFC/ACC	116	-9	51	-5	4.68*
Left thalamus	79	-2	-19	10	4.39 [†]

MNI, Montreal Neurological Institute; OFC, orbitofrontal cortex; ACC, anterior cingulate cortex.

^a All false discovery rate-corrected $p < 0.05$; $k = 65$.

* $p < 0.05$,

[†] $p < 0.10$ cluster level, family-wise error corrected.