

## REFINED SURGICAL TECHNIQUE FOR INSERTION OF BANDED ELECTRODE ARRAY

B. K-H. G. FRANZ, MD, DIP AUD; G. M. CLARK, PHD, FRACS

A refined electrode insertion technique is presented for the multichannel cochlear implant. It comprises two basic steps. The first step is the removal of the anteroinferior overhang of the round window and crista fenestrae, or alternatively an opening drilled into the scala tympani anteroinferior to the round window. The second is rotation of the electrode during insertion, counterclockwise in the right ear and clockwise in the left ear.

Intracochlear implantation via the round window or a separate opening anteroinferior to the round window is used by most surgeons<sup>1-3</sup> because the procedures are relatively easy and the electrode can be placed very close to the tonotopically organized auditory nerve fibers in the spiral lamina. Our concern in the past has been to make electrode insertion a relatively safe and simple surgical procedure. Temporal bone studies have shown us that the posterior tympanotomy provides good access to the round window. We have further been able to demonstrate that the posterosuperior overhang of the round window niche should not be removed for safety reasons and that its removal is unnecessary (B. Franz, G. M. Clark, unpublished data). In the present study we present further refinements in surgery and electrode insertion technique.

### METHODS

Nine human temporal bones were used. The temporal bones were removed 24 hours after death and kept in a deep freeze before dissection. A mastoidectomy and posterior tympanotomy were performed on each bone. The cochlea was skeletonized by removing the bone over the scala vestibuli. This enabled us to study the movement of the inserted electrode along the cochlear turns. Each insertion study was photographed and recorded on a videotape. For the insertion a practice electrode from Cochlear Pty. Limited was used, a new electrode being used for each bone. The electrode had 32 platinum rings and the diameter tapered from 0.64 to 0.40 mm. Each platinum ring was 0.3 mm wide and the interelectrode space was 0.45 mm. Insertions were carried out with a straight and

slightly bent electrode tip. The bend in the electrode tip followed the curve of the basal turn. Insertions were performed with and without the recommended insertion claw,<sup>3</sup> and were stopped when resistance was felt. Insertions were repeated up to five times in three bones.

Surgery at the round window included incision of the round window membrane, removal of the anteroinferior overhang and crista fenestrae, and alternatively drilling an opening into the scala tympani 2 to 3 mm anteroinferior to the round window.

### RESULTS

The results are summarized in the Table. The figures represent the average number of electrode rings inserted into the scala tympani. The longest insertions (26.5 rings) occurred when the anteroinferior overhang and the crista fenestrae had been removed, when the electrode was rotated during the insertion, and when the insertion claw was used. The same results were obtained when an opening was made into the scala tympani anteroinferior to the round window, the insertion claw used, and the electrode rotated during the insertion. The shortest insertions (14.6 rings) were observed when the crista fenestrae and the anteroinferior overhang were left in situ, and when the insertion claw was not used. Insertions without the use of the insertion claw did not cause tears in the spiral ligament. In these cases insertion lengths could be increased a little (19.1 and 18.6 rings) when more extended surgery was performed at the entrance into the scala tympani and a bent electrode tip had been used.

INSERTION STUDY ON NINE HUMAN TEMPORAL BONES WITH MULTICHANNEL COCHLEAR ELECTRODE

	Average No. of Electrode Rings Inserted Without Claw			Average No. of Electrode Rings Inserted With Claw*	
	Electrode Tip		Tears	Electrode Tip	
	Straight	Bent		Straight and Bent	Tears
IRWM	14.6 SD 0.74	15.8 SD 0.91	—	—	—
IRWM + RAIO and CF	15.9 SD 0.42	19.1 SD 1.23	—	23 SD 1.55	+
IRWM + RAIO and CF + ROT	19.8 SD 0.98	—	—	26.5 SD 0.42	—
OAI	15.2 SD 1.06	18.6 SD 1.68	—	23 SD 1.55	+
OAI + ROT	—	—	—	26.5 SD 0.42	—

IRWM — incision of round window membrane, RAIO and CF — removal of anteroinferior overhang and crista fenestrae, OAI — opening anteroinferior to round window, ROT — rotation.

\*When insertion claw was used, straight and bent criteria resulted in same number of rings and thus have been combined. Tears in spiral ligament occurred when electrode was inserted with claw and not rotated during insertion.




Fig 1. Tracing of skeletonized cochlea demonstrating directions of electrodes and their relations to critical point of resistance (star). When crista fenestrae (cf) is not removed electrode hits outer wall in critical area at  $30^\circ$  to  $40^\circ$  angle. This angle is reduced when crista fenestrae is removed.

#### DISCUSSION

An electrode inserted from the posterior tympanotomy via the round window with the anteroinferior overhang and the crista fenestrae still in situ has limited space on its way into the scala tympani. The crista fenestrae, the anteroinferior and the posterosuperior overhangs, and the modiolus cause friction and thus prevent a deep insertion. After passing these obstacles the electrode then hits the outer wall of the basal turn at an angle of  $30^\circ$  to  $40^\circ$ , and is stopped here because resistance becomes too large. This explains the short insertion length of 14.6 rings (Table). The critical point of resistance in the outer wall of the basal turn is about 8 to 10 mm away from the entrance and is found where the inferior section of the basal turn starts to turn into the ascending section. A bent electrode tip allows the insertion of another electrode ring (15.8 rings), but only because the electrode tip contacts the outer wall of the basal turn slightly further in.

The critical point of resistance within the scala tympani is more easily overcome when the crista fenestrae and the anteroinferior overhang are removed or, alternatively, an opening is drilled anteroinferior to the round window and the electrode tip is bent in the direction of the basal turn (19.1 and 18.6 rings). This operation minimizes friction and reduces the angle between the electrode and the outer wall of the basal turn significantly. It allows the electrode to be in tangential contact with the outer wall of the basal turn before it reaches the critical area (Fig 1).

Although the electrode can pass the point of resistance once the crista fenestrae and anteroinferior overhang have been removed, the direction of its tip might still be in an unfavorable position. This is due to the shape of the outer wall of the basal turn, which is slightly splayed outward.

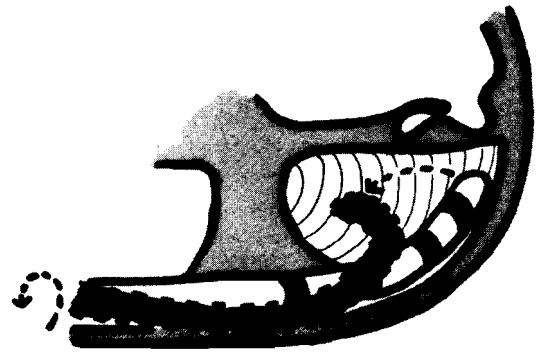


Fig 2. Diagram demonstrating unfavorable position of electrode tip resulting from shape in outer wall of basal turn of right cochlea. Counterclockwise rotation effectively directs electrode tip downward away from spiral ligament and basilar membrane.

This anatomical characteristic can cause the tip to be directed upward toward the spiral ligament and possibly the soft tissues lying across the middle of the cochlear turn (Fig 2).

By using the insertion claw more force is exerted on the electrode tip. This allows a deeper insertion of the electrode (23 rings); however, the possibility of an unfavorable electrode tip position may cause a tear in the spiral ligament. In this study we have observed that this difficulty is easily and effectively overcome by rotating the electrode. A rotation of about  $90^\circ$  directs the electrode tip away from the spiral ligament as it passes around the cochlear turns. In the right ear the effective rotation is carried out counterclockwise, and clockwise when the electrode is inserted into a left ear. This simple maneuver permits a deeper insertion (26.5 rings) and is relatively safe at the same time. Rotation, however, should not exceed  $180^\circ$  because the electrode tip can then make a sudden flick as a result of friction along the spiral ligament and penetrate the partition.

#### REFERENCES

1. Michelson RP. Electrical stimulation of the human cochlea. *Arch Otolaryngol* 1971;93:317-23.
2. House WF, Urban J. Long term results of electrode implantation and electronic stimulation of the cochlea in man. *Ann Otol Rhinol Laryngol* 1973;82:504-17.
3. Clark GM, Pyman BC, Bailey QR. The surgery for multiple electrode cochlear implantations. *J Laryngol Otol* 1979;93:215-23.
4. Michelson RP, Schindler RA. Multichannel cochlear implant. Preliminary results in man. *Laryngoscope* 1981;91:38-42.
5. Burian K, Hochmair-Desoyer IJ, Hochmair ES. Hoeren ueber ein Cochlea Implantat. *Klin Exp Ohren Nasen Kehlkopfheilkd* 1981;231:569-70.



Minerva Access is the Institutional Repository of The University of Melbourne

**Author/s:**

Franz, B. K-H. G.;Clark, Graeme M.

**Title:**

Refined surgical technique for insertion of banded electrode array

**Date:**

1987

**Citation:**

Franz, B. K. G., & Clark, G. M. (1987). Refined surgical technique for insertion of banded electrode array. *Annals of Otology, Rhinology & Laryngology*, January-February, 96(1, part 2, suppl.128), 15-16.

**Persistent Link:**

<http://hdl.handle.net/11343/27248>