

Regeneration of peripheral nerve fibres following Haloxon-induced degeneration

Regeneração de fibras nervosas periféricas após degeneração induzida por Haloxon

Maria Verônica de SOUZA¹; Dominguita Lühers GRAÇA²; Sandro Marcio Nunes FERRÃO²; Emerson Antônio CONTESINI³

CORRESPONDENCE TO:
Dominguita Lühers Graça
Departamento de Patologia
Universidade Federal de Santa
Maria
Caixa Postal 5092
97119-900 - Santa Maria - RS -
Brasil
e-mail: graça@super.ufsm.br

1 - Universidade Federal de
Viçosa - MG
2 - Departamento de Patologia
Universidade Federal de Santa
Maria - RS
3 - Universidade Federal de
Mato Grosso - MT

SUMMARY

Delayed neurotoxicity has been associated with organophosphorus poisoning for years. In order to study such condition in sheep, 11 animals were given either one or two high doses of Haloxon. Exposed sheep were observed daily and between 16 and 25 days after administration neurological signs as incoordination and ataxia were detected in six of them. Biopsies of tibial and laryngeal nerves were performed as soon as neurotoxicity was diagnosed, and after death fragments of selected nerves were collected together with CNS tissues for light and electron microscopy and teased fiber studies. Laryngeal, tibial and sciatic nerves showed the most pronounced changes, consisting chiefly of wallerian degeneration that was seen either as a single fiber or as a complete fascicle feature. Exams performed after death clearly showed regenerating fascicles with axonal sprouts growing within a Schwann cell old basal lamina, and some thinly myelinated axonal sprouts.

UNITERMS: Haloxon; Poisoning; Sheep; Neurotoxins; Nerve regeneration.

INTRODUCTION

Organophosphorus compounds are known to inhibit naturally occurring esterases, mainly acetylcholinesterase^{15,16}, inducing a syndrome of salivation, diarrhea and muscular stiffness due to the stimulation of the parasympathetic and sympathetic nervous systems^{1,9}. Delayed toxicity due to prolonged esterase inhibition is expressed as a neuropathy⁵. It affects chiefly the long myelinated fibers, leading to disturbances of proprioception, ataxia, muscle weakness and paralysis due to a distal axonopathy starting 7 to 30 days after intoxication^{3,13}.

Degenerative changes in peripheral nerves can be demonstrated along large fibres which show variable degrees of wallerian degeneration^{2,6}. Peripheral nervous system (PNS) changes have been studied in cattle, pigs, hens, horses, sheep, cats, goats and laboratory animals in spontaneous and experimental conditions^{3,8,17}. In horses, Haloxon poisoning has been associated with laryngeal paralysis when both left and right nerves are affected¹². Bilateral laryngeal degeneration without clinical signs were observed in experimental intoxication in sheep⁷.

Although a few reports exist that state the degenerative and regenerative changes that follow spontaneous human organophosphorus intoxication¹⁸ and experimental animal

intoxication², the aim of this investigation was to document the morphological events of the experimental poisoning in sheep using light and electron microscopy and teased fiber techniques. It was also a goal to define the burden of the peripheral damage on the fate of the intoxicated sheep.

MATERIAL AND METHOD

Twelve healthy, nattered males, 6 months to one-year-old Corriedale sheep were used. They were fed 1kg/day of lucerne and water *ad libitum*. They were intoxicated with one or two doses of either 353³ or 500⁸ mg/kg of Haloxon in warm distilled water. Male number 5 received only distilled water and was used as a control. The animals were examined clinically in a daily basis. When signs of neurotoxicity were detected (16-25 days after intoxication), left tibial nerve biopsies were performed in all animals. Those sheep without clinical signs also had a biopsy of the right laryngeal nerve. When the animals showed severe ataxia followed by recumbency, they were killed and necropsied. Fragments of Central Nervous System (CNS), PNS and internal organs were withdrawn and embedded in paraffin. Selected PNS tissues were embedded in resin for teased fiber studies, light and transmission electron microscopy¹⁴.

RESULTS

Most of the animals showed signs of parasympathetic stimulation, consisting of lack of appetite and diarrhea, soon after Haloxon administration.

Signs of delayed neurotoxicity detected at 16-25 days after intoxication, in six of the animals that were given the highest doses, consisted of feet weakness, ataxia, crossing of the hind limbs, fallings and occasional, mild hoarseness. With time these animals showed severe, progressive motor impairment, laying for long periods even during feeding. They died or were killed 31 to 41 days after intoxication. Five did not show any clinical signs before laryngeal biopsies.

Tibial nerve biopsies showed wallerian degeneration affecting the larger fibers, starting at the distal end of the fiber and at times affecting most of the fibers within a fascicle. Same changes were depicted in laryngeal nerve biopsies. Wallerian degeneration was clearly seen after teasing (Fig. 1) and confirmed in semi-thin (Fig. 2) and thin nerve sections. Macrophages were present and proliferating Schwann cells spread underneath their old basal laminae constituted Büngner bands.

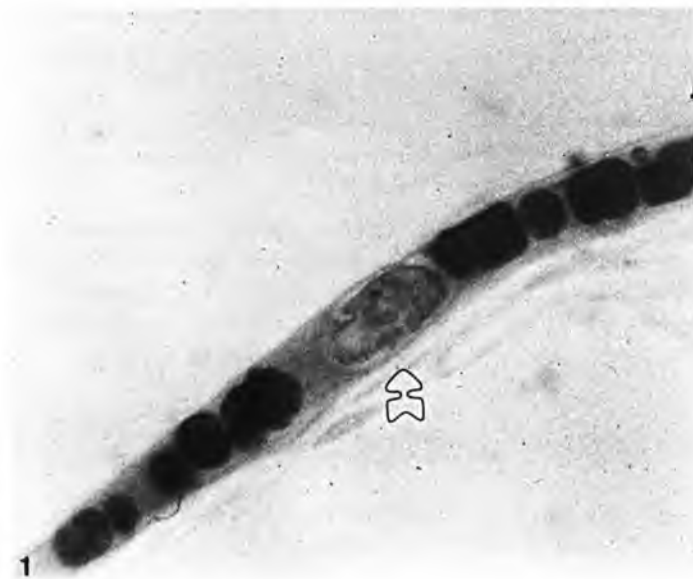


Figure 1

Teased fiber from a laryngeal nerve showing wallerian degeneration. The nucleus of the Schwann cell is seen on the lower half of the picture (arrow). Obj. 40.

No nervous changes were seen at necropsy, but were eventually detected histologically. Gross changes of internal viscera unrelated to Haloxon intoxication were also seen.

Features of neuroaxonal degeneration were found in cerebellar and medullar nuclei, as well as swollen spinal cord axons.

PNS tissues removed at necropsy revealed degenerative changes similar to those seen in the biopsy sections, namely in the sciatic nerves, together with regeneration of some of the fibres.

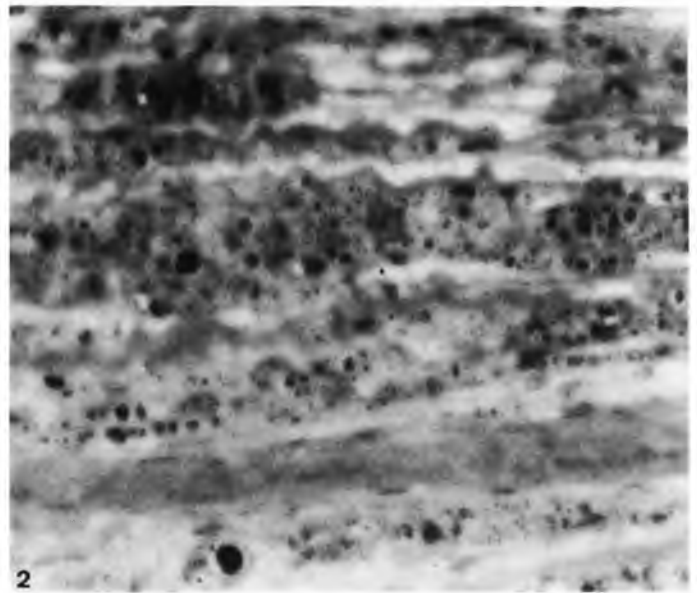


Figure 2

Semi-thin section from a tibial nerve showing wallerian degeneration of most of the fibers of the fascicle. Obj. 10.

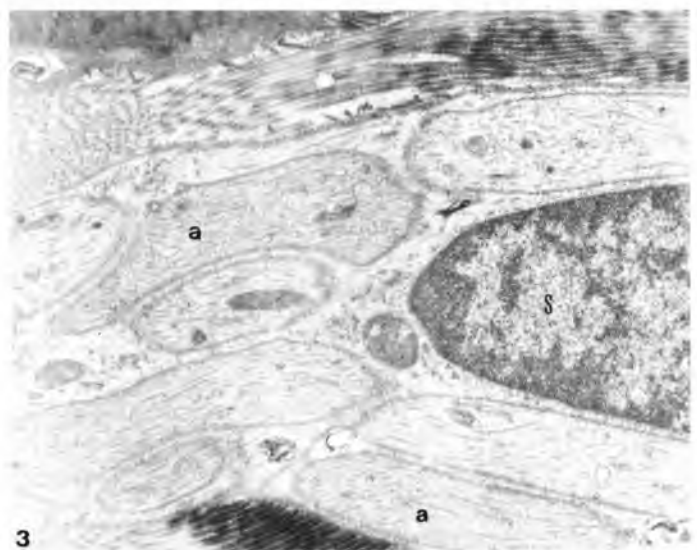


Figure 3

Schwann cell (S) related to a group of axonal sprouts (a) X 16.000.

Ultrastructural examination of nerve sections revealed a thickened extracellular matrix of the endoneuron, composed of intermingling bundles of mean diameter collagen fibers separating axonal sprouts. Macrophages seen in thin sections had a dense cytoplasm and phagocytosed myelin membranes, some already broken down into neutral fat. Schwann cells were seen related with axonal sprouts which had grown along the long axis of the nerve (Fig. 3). Those Schwann cells showed a medium density cytoplasm with numerous microtubules and filaments, an irregular nucleus with clumped chromatin and were related to small diameter collagen fibers along their basal

lamina.

A few axonal sprouts had induced the regeneration of thin myelin sheaths immersed in unusual amounts of collagen fibers (Fig. 4) and with occasional redundant myelin loops.

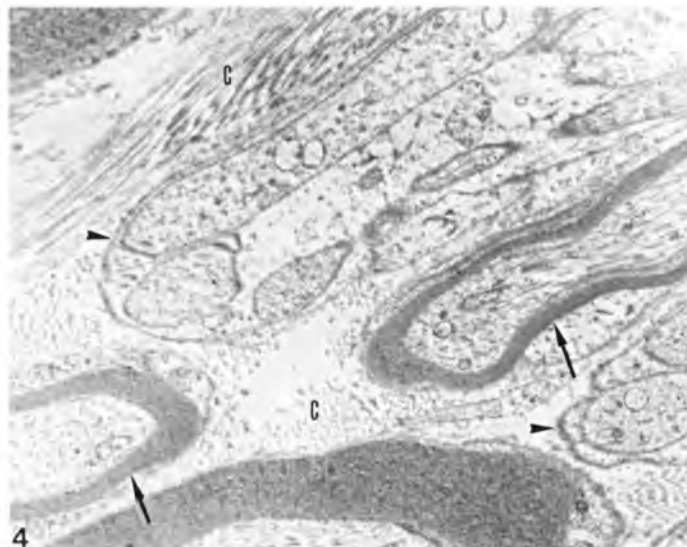


Figure 4

Two regenerated fibers with a thin myelin sheath (arrows) lay parallel to axonal sprouts growing within an old Schwann cell basal lamina (arrow heads); C: bundles of collagen fibers. X 10.000.

DISCUSSION

Organophosphorus compounds are used in many major industries and in agriculture in many countries⁵, including

Brazil¹⁰. Spontaneous exposure is considerable and neurotoxicity of this origin has been repeatedly reported, thus many experimental models have been developed to study the pathology of the condition⁵.

With most organophosphorus compounds there is inhibition of acetylcholinesterases by phosphorylation¹⁶ and thus, clinical signs of acetylcholine poisoning^{5,14}. Most sheep in this study showed signs of parasympathetic stimulation consisting mainly of lack of appetite and diarrhea¹⁴. After recovery from the acute phase of the intoxication six animals presented signs of delayed neurotoxic effects, as seen in other experimental models⁴. Altered gait and feet weakness detected from day 16 after intoxication heralded the severe distal axonopathy developed due to wallerian degeneration of whole fascicles⁷, defined as a "dying back process"⁴. Nerves that showed the more pronounced changes were tibial, laryngeal and sciatic ones. Pathological changes on these nerves evidenced the severe clinical condition of the sheep.

Nerve biopsies examined in semi-thin and thin sections and by teasing revealed all aspects of degeneration and regeneration^{7,14}, including the formation of redundant myelin loops, as seen in other conditions where Schwann cells repair lost myelin sheaths¹¹. Although events of regeneration were depicted, they took place along with CNS changes that contributed to the bad general condition of the sheep and impaired good prognosis for the syndrome.

ACKNOWLEDGEMENTS

The authors thank the technicians of the Veterinary Hospital and the Electron Microscopy Unit, at the Universidade Federal de Santa Maria, Brazil.

RESUMO

Eventos de neurotoxicidade tardia têm sido frequentemente associados com intoxicação crônica por organofosforados. Com a finalidade de estudar essa condição em ovelhas, 11 animais receberam uma ou duas doses de 353 ou 500 mg/kg de Haloxon via oral. Os animais intoxicados foram observados diariamente e, entre 16 e 25 dias após a intoxicação, sinais neurológicos de incoordenação e ataxia foram detectados em seis deles. Foram realizadas biópsias de nervos tibiais e laringeos tão logo a neurotoxicidade foi diagnosticada e, após a morte, fragmentos de nervos periféricos selecionados foram colhidos, juntamente com o sistema nervoso central, para estudos de microscopia óptica, eletrônica de transmissão e de fibras desfiadas. Os nervos tibiais, laringeos e ciáticos mostraram as alterações mais pronunciadas, que consistiram em degeneração walleriana, ora de uma única fibra, ora de todo um fascículo. Após a morte, exames histológicos revelaram fibras em regeneração com brotamentos axonais crescendo dentro de membranas de células de Schwann, alguns exibindo bainhas finas de mielina.

UNITERMOS: Haloxon ; Envenenamentos; Ovinos; Neurotoxinas; Regeneração nervosa.

REFERENCES

- 1-ABDELSALAM, E.B. Organophosphorus compounds. I. Toxicity in domestic animals. **Veterinary Research Communications**, v.11, n.3, p.211-9, 1987.
- 2-ABOU-DONIA, M.B.; GRAHAM, D.G.; ABDO, K.M.; KOMEIL, A.A. Delayed neurotoxic, late, acute and cholinergic effects of S,S,S-tributyl phosphorotrithioite (DFP): subchronic (90 days) administration in hens. **Toxicology**, v.14, p.229-43, 1979.
- 3-BOULDIN, T.W.; CAVANAGH, J.B. Organophosphorus neuropathy. I. A teased-fiber study of the spatio-temporal spread of axonal degeneration. **American Journal of Pathology**, v.94, n.2, p.241-8, 1979.
- 4-CAVANAGH, J.B. The significance of the "dying back" process in experimental and human neurological disease. **International Review of Experimental Pathology**, v.3, p.219-67, 1964.
- 5-CAVANAGH, J.B. Toxic and deficiency disorders. In: WELLER, R.O. **Nervous system, muscle and eyes**. Edinburgh, Churchill Livingstone, 1990. Cap.11, p.244-308.
- 6-DUNCAN, D.; BROOK, D. Bilateral laryngeal paralysis in the horse. **Equine Veterinary Journal**, v.17, n.3, p.228-33, 1985.
- 7-GRAÇA, D.L.; SOUZA, M.V.; CERVO, H.; FERRÃO, S.M.N. Laryngeal and tibial nerve wallerian degeneration in sheep associated with experimental Haloxon poisoning. **Patologia**, v.25, p.203, 1992.
- 8-MALONE, J.C. Toxicity of Haloxon. **Reviews in Veterinary Science**, v.5, n.1, p.17-31, 1964.
- 9-MUNRO, N.B.; SHUGART, L.R.; WATSON, A.P.; HALBROOK, R.S. Cholinesterase activity in domestic animals as a potential biomotor for nerve agent and another organophosphate exposure. **Journal of the American Veterinary Medical Association**, v.199, n.1, p.103-15, 1991.
- 10-PALERMO NETO, J.; BERNARDI, M.M.; SPINOSA, H.S. Intoxicação por praguicidas: uma visão crítica. **Ciência e Cultura**, v.39, n.12, p.1017-22, 1987.
- 11-PEREIRA, L.A.V.; GRAÇA, D.L. Presença de "loops" redundantes de mielina em processos de regeneração nervosa. In: JORNADA DE PESQUISA DA UFSM, L., Santa Maria, 1991. **Resumos**, p.95.
- 12-ROSE, R.J.; HARTLEY, W.J.; BAKER, W. Laryngeal paralysis in Arabian foals associated with oral Haloxon administration. **Equine Veterinary Journal**, v.13, n.3, p.171-6, 1981.
- 13-SOLIMAN, S.A.; SVENDAGAARD, D.; FARMER, J.D.; CURLEY, A.; DURHAM, W.F. Six-month daily treatment of sheep with neurotoxic organophosphorus compounds. **Toxicology and Applied Pharmacology**, v.69, n.3, p.417-31, 1983.
- 14-SOUZA, M.V. **Neurotoxicidade tardia experimentalmente induzida por Haloxon em ovinos**. Santa Maria, 1993. 146p. Dissertação (Mestrado) - Universidade Federal de Santa Maria.
- 15-SOUZA, M.V.; GRAÇA, D.L. Organofosforados e neurotoxicidade tardia. **Cadernos Técnicos da Escola de Veterinária da Universidade Federal de Minas Gerais**, v.13, n.1, p.29-38, 1995.
- 16-SOUZA, M.V.; PEREIRA, M.E.; FERRÃO, S.M.N.; GRAÇA, D.L. Estudo da atividade da acetilcolinesterase (AChE) *in vitro* em ovinos: efeito do Haloxon. **Ciência e Cultura**, v.44, p.773-4, 1992. Suplemento. Apresentado à 44ª Reunião Anual da SBPC, 1992 - Resumo
- 17-STUBBINGS, D.P.; GILBERT, F.R.; GILES, N.; HOLMES, R.G.; JACKSON, G.; NICHOLSON, T.B. An organophosphorus worming compound and paraplegia in pigs. **Veterinary Record**, v.99, n.13, p.127-8, 1976.
- 18-VASILESCU, C.; ALEXIANU, M.; DAN, A. Delayed neuropathy after organophosphorus insecticide (dipterex) poisoning: a clinical, electrophysiological and nerve biopsy study. **Journal of Neurology, Neurosurgery and Psychiatry**, v.47, p.543-8, 1984.

Recebido para publicação: 15/06/95
Aprovado para publicação: 15/12/95