

# Regional anaesthesia for 12,000 cataract extraction and intraocular lens implantation procedures

Robert C. Hamilton MB FRCPC,  
Howard V. Gimbel MD FRCSC,  
Leo Strunin MD FFARCS FRCPC

*Twelve thousand regional anaesthetics for cataract extraction and intraocular lens implantation surgery were administered by one anaesthetist over a period of 52 months in a free-standing outpatient surgical facility. The ophthalmologist, who did all the operations, assessed the quality of the blocks using an objective scoring system which is described. The first 3,595 patients had retrobulbar and seventh nerve blocks. The following 1,640 patients had higher volume retrobulbar blocking alone. The next 3,478 had peribulbar blocks, followed by 2,226 who had a modified form of peribulbar blocking. A final group of 1,061 had a combination of peribulbar and periorbital blocks with added retrobulbar injection if indicated. As the method of blocking evolved, the more closely was the goal of safe, painless and effective regional anaesthesia approached. The requirements for effective anaesthesia of this type are presented, the complications described and the importance of familiarity with the anatomy of the orbit and its contents stressed.*

## Key words

ANAESTHESIA: block assessment, regional anaesthesia, ophthalmic; ANAESTHETIC TECHNIQUE: peribulbar anaesthesia, periorbital anaesthesia, regional, retrobulbar anaesthesia; ANAESTHETICS, LOCAL: bupivacaine, epinephrine, hyaluronidase, lidocaine; COMPLICATIONS: brain stem anaesthesia, contralateral orbital block, extraocular muscle paresis, orbital haemorrhage, retinal vascular occlusion, scleral perforation, shivering.

From the Departments of Anaesthesia and Ophthalmology, University of Calgary, Calgary, Alberta.

Address correspondence to: Dr. R.C. Hamilton, Gimbel Eye Centre, Suite 450, 4935 - 40th Avenue N.W., Calgary, Alberta, Canada T3A 2N1.

Conduction block anaesthesia for ophthalmic surgery commenced with cocaine in 1884<sup>1,2</sup> but failed to become popular until the 1930s when retrobulbar block, first with procaine,<sup>3</sup> and later lidocaine<sup>4</sup> and bupivacaine,<sup>5,6</sup> became established as an effective method. Published articles indicated that retrobulbar anaesthesia was not without side effects and complications. The most serious complications were brain stem anaesthesia,<sup>7-12</sup> which could result in death if inadequately treated, scleral perforation,<sup>13-15</sup> retinal vascular occlusion,<sup>16-19</sup> optic nerve damage,<sup>20</sup> extraocular muscle paresis<sup>21-23</sup> and retrobulbar haemorrhage.<sup>24</sup> Although effective anaesthesia by local anaesthetic injection outside the muscle cone had been used as early as 1971,\* it was not until 1986 that its use was first published.<sup>24</sup> This paper reports 12,000 regional anaesthetics for cataract extraction and intraocular lens implantation. Block effectiveness was assessed by the ophthalmologist at the completion of surgery using an objective scoring system. Five blocking techniques (Groups A through E) were used in the series and chronologically progressed from one to the next in the quest for safety, patient comfort and effectiveness.

## Methods

All procedures took place in a free-standing ambulatory outpatient ophthalmic surgical facility from January 2nd 1984 to April 8th 1988 inclusive. The rationale was to make the setting home-like and non-clinical, with no changing from regular clothes and ambulation being maintained except at the time of the block and again during surgery. The patients were not fasting. For routine operations the duration of stay on the day of surgery was 1½ hr. Table I displays the sex, age and physical status of the five groups. Consent for anaesthesia and surgery was recorded and preoperative medication given if required. Sedative drugs were used as indicated in Table I. The block room, with full resuscitation equipment on hand,

\*Dr. Charles Kelman, New York, personal communication, 1987.

TABLE I Sex, age, physical status, sedation

	Group				
	A	B	C	D	E
	<i>Retrobulbar plus 7th N. block</i>	<i>↑ Volume retrobulbar block</i>	<i>Dual peribulbar block</i>	<i>Dual peribulbar block</i>	<i>Customized block</i>
Number of patients	3595	1640	3478	2226	1051
Female:male ratio (per 100)	59:41	61:39	62:38	63:38	63:37
Age ≥ 70 years (per cent)	67.2%	72.7%	70.8%	70.3%	70.4%
Physical status					
ASA: I	11.5%	11.3%	14.8%	15.3%	11.0%
ASA: II	57.8%	58.0%	53.6%	64.5%	69.0%
ASA: III	30.7%	30.7%	21.6%	20.2%	20.0%
Percentage given pre-op sedation		Sublingual lorazepam 1.0 mg		Triazolam 0.125 mg PO	
	4.9%	3.9%	1.8%	1.6%	0.5%

was adjacent to the two operating rooms. Patients were monitored with lead I ECG (Kontron Micromon 7142 with Medical Research Laboratories wrist electrodes) and non-invasive automatic blood pressure (Critikon Dine-mapp Vital Signs Monitor 1846) in the block room, and lead I ECG (Narco Scientific Triscope Model TS121, wrist electrodes), digital peripheral pulse monitor (Narco Scientific Model PP171) and digital pulse oximetry (Nellcor Model N-100C) in the operating rooms. Data were recorded on a combined consent/anaesthetic chart, including vital signs, the type of block used, volume injected, details of supplemental injections and the ophthalmologist's assessment of block quality. In addition, for Groups B, C, D, and E, this information, plus occurrence of early or late complications, were entered into a database on a Point Four 500 megabyte minicomputer. The database was programmed to receive information on: patient physical status, type of sedation, block complications (brainstem anaesthesia, subconjunctival haemorrhage, lid ecchymosis, optic atrophy, prolonged extraocular muscle weakness, retrobulbar haemorrhage, scleral perforation, shivering, vasovagal problem, vessel perforation), axial length, volume and location of block injection, type of eye drops, and score assessment data. Patients were seen the next day, and again two and eight weeks postoperatively and complications pertaining to anaesthesia entered on the computer database.

Prior to the conduction block, two drops of 0.5 per cent proparacaine (along with other drops as pertinent for surgical purposes), were applied to the inferior fornix of the conjunctiva. Blocks were administered with the patients in a semi-recumbent position in a motorized articulated chair, which could be placed horizontally or with a Trendelenberg tilt if necessary.

A local anaesthetic mixture containing 0.375 per cent bupivacaine, 1.0 per cent lidocaine, hyaluronidase 5

units·ml<sup>-1</sup> and epinephrine 1:400,000 was used. This was made up from equal parts of preservative-free 0.75 per cent bupivacaine and preservative-free 2.0 per cent lidocaine, to which were added the other two ingredients in appropriate amount. The injectate was warmed to 37°C by placing a 10 ml disposable plastic syringe, containing the injectate, on an electric heating pad,<sup>25</sup> which had been calibrated to its operating temperature using an in-series rheostat and a thermometer. Before doing any block the axial length (cornea to retina distance as previously measured by Sonometrics DBR 400 Axial Length Scanner) was noted and, particularly in long eyes, careful attention paid so as to avoid scleral puncture. All blocks, with the exception of the inferior periorbital injection of Group E, used a transparent hub, 27-gauge disposable 38 mm needle (Sherwood Medical Monoject 260 OR/ER needle).

In all five block groups the first needle entry point was standard. With the patient's gaze directed upward and with no deviation to either side, the entry point was at the inferior fornix of the conjunctiva, in line with the lateral limbus (4 o'clock position left eye, 8 o'clock position right eye), taking care to avoid any conjunctival blood vessels. Continuous aspiration was applied to the syringe during withdrawal of the needle in all blocks; if a vessel had been entered, as evidenced by blood appearing in the clear hub of the needle, immediate digital pressure was applied to a gauze pad placed on front of the globe after closure of the eyelids so as to minimize bleeding.

In Group A patients the needle was advanced tangentially to the sclera until past the equator of the globe; the hub was then depressed and the needle advanced with medial and upward components until just within the muscle cone (maximum depth of 2.5 cm) and, following a negative aspiration check, 3.0 to 4.0 ml of solution injected over a two-minute period. Either a Nadbath<sup>26</sup>

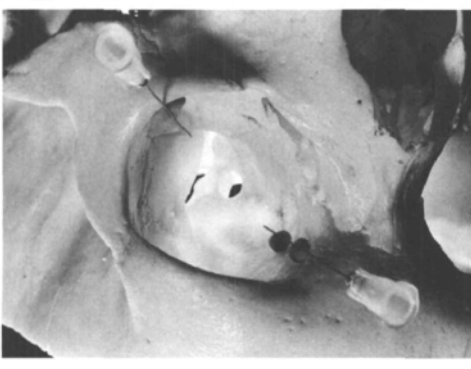


FIGURE 1 The positions of the 38 mm 27-gauge needles in the left orbit are shown. For demonstration purposes the needles are held in position by pieces of modelling clay (the upper needle on two pieces and the lower on one piece). Note that the needles are not advanced their full length into the orbit (see text). The inferotemporal needle lies close to the junction of the lateral wall of the orbit with its floor; the supernasal needle is positioned close to the junction of the medial wall of the orbit with its roof.

or Atkinson<sup>27</sup> technique was used to block the seventh nerve.

Group B patients had 5.0 to 7.0 ml solution injected inside the muscle cone but seventh nerve blocking was not done.

In Group C patients two intraorbital injections were given, the first needle entering as in groups A and B but directed with lesser medial (30°) and upward (10°) components and for a maximum distance of 2.5 cm. The needle then lay close to the junction of the lateral wall of the orbit with its floor (Figure 1). It lay outside the intermuscular septum between the inferior and lateral recti muscles and had not engaged any muscle during its passage. Following a negative aspiration check 4.0 to 5.0 ml of solution were injected over a period of 2 min. The second injection was done 2 min after the first, the needle passing through skin of the upper lid with its entry point midway between the medial canthus and the supraorbital notch of the frontal bone. Again care was taken to avoid penetration of superficial blood vessels. The needle was angled tangentially to the globe and at first invaginated, then pierced the skin. The needle was advanced backwards in a sagittal plane, directed toward an imaginary line through the external auditory meati, for a maximum distance of 2.5 cm. In this position the needle had passed inferior to the tendon of the superior oblique muscle and lay close to the junction of the medial wall of the orbit with its roof (Figure 1). This needle lay inferior to the belly of superior oblique muscle and outside the intermuscular septum between the superior and medial recti muscles.

After an aspiration check was negative 3.0 to 4.0 ml solution was injected over 30 to 60 sec.

Group D patients had an identical first injection to that used in Group C. The second injection was through the upper eyelid, just superior to the tarsal plate, aligned with the medial limbus passing backwards in a sagittal plane tangentially to the globe, initially directed toward the crown of the patient's head for a distance of 1.5 cm; the hub of the needle was then elevated and the tip advanced downward toward an imaginary line through the tops of the patient's pinnae to a total maximum depth of 2.5 cm. In this position the needle had passed superior to the tendon of superior oblique muscle and lay close to the roof of the orbit, outside the intermuscular septum between medial and superior recti muscles, and between the levator palpebrae superioris muscle and the belly of the superior oblique muscle. After an aspiration check was negative 3.0 to 4.0 ml solution was injected over 30 to 60 sec.

If total akinesia had not been obtained ten minutes after their completion, blocks were supplemented by injection of 1.0 to 3.0 ml of the standard mixture, in position and volume according to the location and magnitude of persisting muscle activity.

In Group E an initial block was done as in the peribulbar groups, and after 2 min the globe examined for ability to move into all four quadrants. If there was persistent function of the extraocular muscles in all four quadrants then a retrobulbar injection (within the muscle cone) of 3.0 ml of solution was given. After a further 60 sec an upper lid peribulbar injection was added if required to achieve adequate globe or upper lid akinesia. Finally 3.0 to 4.0 ml solution were injected at the inferior orbital margin in line with the lateral canthus into the lower lid using a 30-gauge 13 mm disposable needle (Becton Dickinson & Co. PrecisionGlide) at the depth of the orbicularis muscle (2.0 mm from surface) taking care to avoid any visible surface blood vessels. No attempt was made to track with this needle across the lid; rather the injectate itself was allowed to spread in the plane of the muscle.

In all block groups, after completion of the injections, digital compression atop a 5 cm × 5 cm gauze wipe applied to the closed eye assessed tension in the orbit and globe and served as a tactile monitor of bleeding within the orbit. The "Super-Pinky" mechanical orbital compression device<sup>28</sup> was then applied for at least 30 minutes. A specified area on the anaesthetic chart was signed by the anaesthetist when akinesia was seen to be established; this signature was a prerequisite for patient admission to the operating room.

At the completion of surgery, the ophthalmologist (HVG) assessed the quality of the anaesthesia according

<b>BLOCK ASSESSMENT</b>	
ORBICULARIS OCULI	<input type="checkbox"/>
ORBIT	<input type="checkbox"/>
GLOBE	
superior rectus	<input type="checkbox"/>
inferior rectus	<input type="checkbox"/>
lateral rectus	<input type="checkbox"/>
medial rectus	<input type="checkbox"/>
obliques	<input type="checkbox"/>
CONJUNCTIVAL	
edema	<input type="checkbox"/>
hemorrhage	<input type="checkbox"/>
VITREOUS PRESSURE	<input type="checkbox"/>
PAIN	<input type="checkbox"/>
<b>TOTAL SCORE</b>	<input type="checkbox"/>

Most desirable total score: 0

FIGURE 2 Block assessment score card.

to the criteria of an objective scoring system devised by the authors and described in Figures 2 and 3.

This system has been an invaluable tool, providing hard data on which to modify the block techniques and the strength, volume and constitution of the local anaesthetic injectate used. The category "excellent" was used where the individual components of the score card had values of 0 or 1; "good" was used where one only component of the block carried the value 2, with the others 0 or 1; and "fair" for the balance of cases. The data were subjected to statistical analysis using Chi-square testing with Yates' correction and Pearson's coefficient of contingency, as

#### SCORE KEY:

- 0 — PERFECT CONDITIONS
- 1 — NOTICEABLE; NO INTERFERENCE
- 2 — SLIGHT INTERFERENCE
- 3 — MARKED INTERFERENCE
- 4 — ADDITIONAL BLOCK REQUIRED

For example: considering orbicularis oculi muscle, if total akinesia were obtained the score would be 0; if minor activity were present which did not interfere with surgery the score would be 1; if there was minor interference with surgery from that muscle the score would be 2; if marked interference, 3 and if so bad that supplemental blocking was required, 4.

FIGURE 3 Score key.

appropriate. A significance level of  $< 0.05$  was accepted as clinically relevant.

#### Results

The comparative results and observed complications in the five series are summarized in Tables II and III. The achieved scores in Group A were satisfactory; however, there was a considerable incidence of direct spread to the central nervous system, including some cases of brain stem anaesthesia, three of which have been reported.<sup>10</sup> Undoubtedly, needle placement in the early cases in this group was too far posterior in the orbit, allowing deposition of anaesthetic within the sheath of the optic nerve in some cases. Blocking the main trunk of the seventh nerve by the Nadbath method<sup>26</sup> was used in five early cases but abandoned because of pain during its execution and postoperative disfigurement (unilateral facial drooping for the duration of the block); postoperative patients were seen by those awaiting surgery. For the

TABLE II Block score and supplementation rate

	<i>Group</i>				
	<i>A</i>	<i>B</i>	<i>C</i>	<i>D</i>	<i>E</i>
	<i>Retrobulbar plus 7th N. block</i>	<i>↑ Volume retrobulbar block</i>	<i>Dual peribulbar block</i>	<i>Dual peribulbar block</i>	<i>Customized block</i>
Number of patients	3595	1640	3478	2226	1061
Block score:					
excellent	90.0%	90.8%	83.3%	84.0%	89.8%
good	6.5%	6.2%	11.2%	11.5%	7.1%
fair	3.5%	3.0%	5.5%	4.5%	3.1%
Block supplement required	19.8%	9.0%	24.0%	24.0%	1.6%*

\*p < 0.05

TABLE III Complications

	Group				
	A	B	C	D	E
	<i>Retrobulbar plus 7th N. block</i>	<i>↑ Volume retrobulbar block</i>	<i>Dual peribulbar block</i>	<i>Dual peribulbar block</i>	<i>Customized block</i>
Number of patients	3595	1640	3478	2226	1061
Brain stem anaesthesia	6	2	0	0	0
Other CNS spread	2	3	1	0	0
Spread to contralateral orbit	1 patient	0 patients	0 patients	0 patients	0 patients
Moderate retrobulbar haemorrhage	5 patients	—	—	—	—
Eyelid, conj. & peribulbar ecchymoses	—	3.3%	2.6%	2.3%	3.5%
Extraocular muscle paresis	0 patients	15 patients*	4 patients	3 patients	1 patient
Shivering	—	0.23%	0.25%	0.33%	0.64%
Scleral perforation	1 patient	0 patients	0 patients	0 patients	0 patients
Optic atrophy	1 patient	0 patients	0 patients	0 patients	0 patients
Vasovagal problems	0.5%	0.7%	0.6%	0.5%	0.85%
"Breakthrough" pain	2.1%*	1.1%*	0.1%	0.1%	0.1%

\* $p < 0.05$  (see text).

balance of Group A patients, the upper branches of the seventh nerve were blocked by the Atkinson method.<sup>27</sup> This also was painful and was the reason for proceeding into Group B, in which seventh nerve blocking was not required.

Group B patients experienced a higher degree of comfort during the blocking procedure as there was no transcutaneous injection of seventh nerve. However, because of an unacceptably high incidence of extraocular muscle paresis this technique was abandoned.

In Groups C a hitherto unattainable standard of comfort at the time of the block and intraoperatively was obtained, but there was a 24 per cent requirement of supplemental blocking; this high incidence was interruptive of smooth patient flow and became time consuming. Group D introduced a modification in the placement of the second needle in the hopes of reducing the supplemental block rate but that rate remained unchanged.

Although Group E again introduced the more complication-prone optional use of retrobulbar blocking it was found to approach most closely to the desired level of a safe, painless, efficient and effective block technique. Retrobulbar injection was employed in 46.8 per cent of patients in this group. The use of premedication was at its lowest in the series, and the block supplementation rate was 1.6 per cent.

As the method of blocking evolved chronologically from Group A through Group E, and confidence was gained, there was a progressive reduction in the percentage of patients in whom preoperative sedation was used (Table II). Sublingual lorazepam (1.0 mg) in Groups A, B

and C, was changed to oral triazolam (0.125 mg) in Groups D and E, because of a high incidence of amnesia with the former drug.

Chi-square analysis of the results shown in Table II revealed no significant difference in the Block Scores in Groups A to E. However, Group E was statistically better than the others in the Block Supplement Required category.

In seven of the eight patients in whom brain stem anaesthesia occurred (Table III) vomiting was part of the syndrome; in only one of the those eight patients did surgery have to be postponed, and this was because of persistent nausea. Local anaesthetic drug spread into the brain did not always result in full-blown brain stem anaesthesia; five patients in Groups A and B had loss of consciousness of a confusional state without respiratory arrest. The single case of cerebral spread in the first peribulbar group (C) had a 20-min period of drowsiness, presumably due to inappropriately deep needle placement in the orbit. There was one case of spread of local anaesthetic drug to the contralateral orbit in a Group A patient, similar to the case reports of Antoszyk and Buckley.<sup>31</sup>

Orbital haemorrhages vary in severity. In this series, done with fine-gauge needles, none was so severe as to necessitate cancellation of surgery. In Group A five cases of moderate retrobulbar haemorrhage occurred — cases which later in the series would have been detected earlier.

Chi-square analysis of the results shown in Table III reveals no significant difference between the five groups in all categories with the exception of Extraocular Muscle

Paresis and "Breakthrough Pain." For Extraocular Muscle Paresis, Group B had a statistically significantly higher incidence than all of the other groups. For "Breakthrough Pain" there was no significant pain rate difference between Groups C, D, and E; but there was significantly more pain in Groups A and B than the others. With regard to comparing "Breakthrough Pain" for Groups A and B, Group A was significantly worse than Group B.

### Discussion

The triple goals of regional anaesthesia for cataract extraction with intraocular lens implantation are: globe and conjunctival analgesia; globe, lid and periorbital muscle akinesia; and orbit and globe hypotension. If these could be achieved with absence of complications related to the anaesthetic technique and drugs used, and freedom from discomfort during the execution of the block, conditions would then be ideal.

With akinesia (meaning total loss of tone) the globe is not subjected to any external force generated from muscle activity – this situation is highly desirable in the production of ideal operating conditions. One of the goals in this series was total abolition of muscle tone in the eyelid and extraocular musculature, which frequently is not obtained in regular clinical practice. In this series it was measured and recorded according to an objective scoring system.

The rationale for the four components of the local anaesthetic drug mixture were: lidocaine for its fast onset and good penetrating properties; bupivacaine for its prolonged duration allowing for less critical timing of surgery and for postoperative comfort; hyaluronidase to promote spread of the injectate within and outside the orbit; and epinephrine to prolong periorbital akinesia from less than two hours, to diminish bleeding from small vessel puncture and to promote orbital volume reduction by causing vasoconstriction. Adding epinephrine freshly to the local anaesthesia mixture resulted in the injectate having a higher pH than commercially available compounds.<sup>29</sup> With a higher pH the amount of drug present in the base form is increased and this promotes more effective nerve blocking.<sup>30</sup>

Prior to this series the anaesthetist (RCH) had had moderate exposure to regional blocks of the orbit over a seven-year period in a large general hospital. This had been exclusively with traditional retrobulbar and separate seventh nerve blocking. Therefore the earliest group (A) in the reported series was a continuation of this experience, with the one exception that the first injection, rather than transcutaneous, was through the previously topicalized (with proparacaine eye drops) inferior fornix of the conjunctiva – a most significant means of rendering the whole anaesthetic procedure virtually pain-free. For this

reason the transconjunctival route was used for the initial injection in all five groups.

Fine-gauge needles cause less pain<sup>32</sup> and a reduced need for sedative or narcotic premedication. This is particularly important in elderly patients having cataract surgery in an ambulatory setting; drug side effects such as delayed recovery, postural hypotension and emetic sequelae are avoided. In the literature there is considerable support for the use of dull needles to reduce the incidence of bleeding.<sup>33,34</sup> However, compared with fine needles, their use inevitably increases patient discomfort. This anaesthetist (RCH) prefers to use fine disposable needles and to observe meticulously for vessel perforation and to deal with that complication promptly by applying pressure. In Group D the incidence of minor bleeding was 2.3 per cent, but in addition, not shown in Table III, were an additional 1.9 per cent in whom there was blood vessel penetration (positive aspiration test), but in whom immediate pressure application prevented any clinical evidence of bleeding. When blood vessels are penetrated by fine needles the subsequent bleeding is more easily controlled. For this reason 30 gauge needles were used for the inferior periorbital injections of Group E. Inadvertent puncture of vital orbital structures such as the globe or optic nerve is less common with larger than with smaller gauge needles.<sup>32,34</sup> By having the patient gaze directly upward during placement of the initial needle the optic nerve is not as proximate to the needle tip as with the "up and in" method described by Atkinson.<sup>35,36</sup> Deep penetration of the orbit must be avoided<sup>3</sup> as larger diameter vessel and optic nerve involvement become more likely. A safe rule is never to enter a distance greater than 2.5 cm, although this was exceeded in the Davis and Mandel technique.<sup>24</sup> In all 14 cases of cerebral spread in the series, the complication occurred between two and eight minutes after the injection responsible and never at a time remote from the block. In clinical situations requiring regional anaesthesia of the orbit it is essential that constant vigilance be maintained for at least ten minutes following blocks and that full resuscitative equipment be readily available.

It is advocated that all injections be done slowly, mainly for patient comfort but also to promote more even spread within the orbit and to minimize systemic effects should the drug be inadvertently injected intravascularly.

In blocking techniques which use large volumes within the orbit, some form of orbital compression device<sup>24,28,37-39</sup> becomes mandatory in order to achieve optimum surgical conditions of low orbit and intraocular pressures. The compression also promotes akinesia of the periorbital muscles by displacing the anaesthetic mixture from within the orbit out on to the face, thus avoiding a separate and painful seventh nerve block.<sup>28,40</sup>

An essential prerequisite to safe practice of regional anaesthesia in ophthalmic surgery is a precise knowledge of orbital anatomy.<sup>41,42</sup> Of particular importance is the disposition of orbital fat in two compartments: the intramuscular, within the muscle cone (site of traditional retrobulbar blocking), and the extramuscular, outside the cone (site of peribulbar blocking). These compartments are separated one from the other by the extraocular muscles and their intermuscular septa. The intermuscular septa are well developed anteriorly and less well defined posteriorly. The extramuscular fat compartment is confined anteriorly by two structures: the conjunctiva centrally and the superior and inferior orbital septa peripherally.

Peribulbar blocking utilizes the tissue compartment principle<sup>43</sup> common to several regional block techniques – in which a needle is introduced into a compartment, following which the injectate spreads by virtue of volume and pressure throughout that compartment. Because conjunctiva is the central portion of the anterior limit of the extramuscular fat compartment, subconjunctival oedema occurs if the capacity of the compartment for injected fluid is surpassed. With epinephrine as a component of the injectate along with the post-block application of an orbital compression device, this oedema clears prior to surgery. The principle of tissue compartment spread is clearly operative in orbital blocks and was responsible for the early anaesthesia of the upper lid. By allowing a 2 min interval following on the transconjunctival initial peribulbar injection there was a most dependable anaesthesia of the skin of the upper lid (infratrochlear, supratrochlear and supraorbital nerves all effectively blocked within the orbit as they course through the extramuscular fat compartment). Anaesthesia in the distribution of the infra-orbital nerve was of slower onset because of its greater diameter and seclusion in a groove and canal in the floor of the orbit. Davis and Mandel,<sup>24</sup> however, used the more painful method of transcutaneous wheals in the upper and lower eyelids prior to their peribulbar technique, which probably necessitated their regular use of intravenous diazepam medication prior to the blocks.

Spread of injectate from the extramuscular compartment, through the intermuscular septum, into the intramuscular compartment within the cone, seemed to be variable, yet necessary for full akinesia of the extraocular muscles. This probably accounts for the earlier onset of good operating conditions with retrobulbar blocking and for the reported ten per cent failure rate with peribulbar blocking.<sup>24</sup>

Familiarity with orbital anatomy and the utilization of a peribulbar technique make it less likely that vital structures within the orbit will be damaged. Complications such as scleral perforation, brain stem anaesthesia, trauma to extraocular muscles and optic nerve damage are

avoided by using a technique which is based on proximity to the bony orbital walls rather than attempting to enter within a poorly visualized muscle cone with inherent risk of engaging muscle and optic nerve sheaths or the nerve itself. However, where retrobulbar injection is deemed necessary, penetration of the needle should be limited to a maximum of 2.5 cm and injection avoided in the presence of resistance which could indicate positioning within an extraocular muscle. Extraocular palsy is a manifestation of local anaesthetic drug myotoxicity<sup>21–23</sup> and was seen in 22 patients in this series (Table III). Gills' technique of relatively high volume retrobulbar injection<sup>28</sup> does not report this problem, although it was with this type of block (Group B) that the highest incidence was seen in this series. Avoidance of direct intramuscular injection should all but eliminate this problem.

Shivering, a recognized, but poorly understood complication of regional anaesthesia,<sup>44</sup> was seen with incidence ranging from 0.23 per cent to 0.64 per cent (Table III).

Scleral perforation, which occurred once in the series (Table III) in a patient with a known elongated globe, is reported in the literature as ranging from none in a series of 2,000<sup>33</sup> to three in a series of 4,000.<sup>13</sup> The latter series comprised patients with retinal detachment who would have had a propensity of elongated globes, making penetration of the sclera more likely. A safe prerequisite to regional anaesthesia of the orbit is to have an axial length measurement prior to the block to warn the anaesthetist of the higher risk in longer than average eyes. This measurement is usually available as part of the work-up in cataract surgery practices. Peribulbar blocking should reduce the incidence of scleral perforation but does not rule it out.<sup>34</sup> Where the emphasis in needle placement is on tangential alignment with the globe, scleral perforation becomes physically more difficult compared with more angled needle directioning.

One case of optic atrophy was encountered in the series (Table III) in a patient with advanced atherosclerosis; although there was no identified trauma to the nerve at the time of the block, nor evidence of retrobulbar haemorrhage, the late findings were of retinal vascular occlusion.

Evidence of the oculo-cardiac reflex was not seen in this series either during the blocks, after application of the orbital compression device or intraoperatively; however, there was an incidence of vasovagal activity of between 0.5 and 0.85 per cent (Table III) which was twice commoner in men than women in the five groups; it occurred in patients who gave a history of fainting.

Compared with retrobulbar blocking, peribulbar injection results in a high incidence of preserved visual activity during surgery<sup>24</sup> because the concentration of injectate around the optic nerve is lower. Patients should be

forewarned that their vision may not be abolished, that this does not mean that the "local" is not working and that they will have no pain. Because the concentration outside the cone is greater, patients in whom at least part of the injectate is placed in a peribulbar location, have a significantly lower incidence of "breakthrough pain" during opening of the conjunctival wound (Table III) compared with the retrobulbar technique.

### Conclusions

Spread of local anaesthetics in the orbit is within tissue compartments and is seldom uniform in distribution. A "cook-book" approach (Group C or D) was less effective in producing an early onset of akinesia than a customized technique (Group E).

Regional anaesthesia for cataract extraction and intraocular lens implantation can be accomplished virtually painlessly and therefore without the use of sedative or narcotic drugs (thus avoiding the side-effects of these agents).

Topical conjunctival anaesthesia with the judicious combination of peribulbar, periocular and retrobulbar injections approached most ideally the goal of a safe, painless and effective technique.

Sound knowledge of the anatomy of the orbit and its contents is a prerequisite for obtaining excellent results.

### Acknowledgements

The authors wish to thank Mr. Ken Kroes for retrieval of computer data; Dr. G.L. Wolf and Mrs. C. Clarke for help with the references; and nursing staff of Gimbel Eye Surgical Centre for their enthusiastic cooperation.

### References

- 1 *Altman AJ, Albert DM, Fournier GA.* Cocaine's use in ophthalmology: our 100-year heritage. *Surv Ophthalmol* 1985; 29: 300-7.
- 2 *Knapp H.* On cocaine and its use in ophthalmic and general surgery. *Arch Ophthalmol* 1884; 13: 402-48.
- 3 *Feibel RM.* Current concepts in retrobulbar anesthesia. *Surv Ophthalmol* 1985; 30: 102-10.
- 4 *Russel DA Jr, Guyton JS.* Retrobulbar injection of lidocaine (Xylocaine) for anesthesia and akinesia. *Am J Ophthalmol* 1954; 38: 78-84.
- 5 *Carolan JA, Cerasoli JR, Houle TV.* Bupivacaine in retrobulbar anesthesia. *Ann Ophthalmol* 1974; 6: 843-7.
- 6 *Smith RB, Lynn JG Jr.* Retrobulbar injection of bupivacaine (Marcaine) for anesthesia and akinesia. *Invest Ophthalmol* 1974; 13: 157-8.
- 7 *Smith JL.* Retrobulbar bupivacaine can cause respiratory arrest. *Ann Ophthalmol* 1982; 14: 1005-6.
- 8 *Rosenblat RM, May DR, Barsoumian K.* Cardiopulmonary arrest after retrobulbar block. *Am J Ophthalmol* 1980; 90: 425-7.
- 9 *Meyers EF.* Brain stem anesthesia after retrobulbar block (Letter to Editor). *Arch Ophthalmol* 1985; 103: 1278-82.
- 10 *Hamilton RC.* Brain stem anesthesia following retrobulbar blockade. *Anesthesiology* 1985; 63: 688-90.
- 11 *Wittpenn JR, Rapoza P, Sternberg P Jr., Kuwashima L, Saklad J, Patz A.* Respiratory arrest following retrobulbar anesthesia. *Ophthalmology* 1986; 93: 867-70.
- 12 *Javitt JC, Addiego R, Friedberg HL, Libonati MM, Leahy JJ.* Brain stem anesthesia after retrobulbar block. *Ophthalmology* 1987; 94: 718-24.
- 13 *Ramsay RC, Knobloch WH.* Ocular perforation following retrobulbar anesthesia for retinal detachment surgery. *Am J Ophthalmol* 1978; 86: 61-4.
- 14 *Seelenfreund MH, Freilich DB.* Retinal injuries associated with cataract surgery. *Am J Ophthalmol* 1980; 89: 654-8.
- 15 *Lincoff H, Zweifach P, Brodie S et al.* Intraocular injection of lidocaine. *Ophthalmology* 1985; 92: 1587-91.
- 16 *Goldsmith MO.* Occlusion of the central retinal artery following retrobulbar anesthesia. *Ophthalmologica* 1967; 153: 191-6.
- 17 *Kraushar MF, Seelenfreund MH, Freilich DB.* Central retinal artery closure during orbital haemorrhage from retrobulbar injection. *Trans Am Acad Ophthalmol Otolaryngol* 1974; 78: 65-70.
- 18 *Klein ML, Jampol LM, Condon PI et al.* Central retinal artery occlusion without retrobulbar hemorrhage after retrobulbar anesthesia. *Am J Ophthalmol* 1982; 93: 573-7.
- 19 *Sullivan KL, Brown GC, Forman AR et al.* Retrobulbar anesthesia and retinal vascular obstruction. *Ophthalmology* 1983; 90: 373-7.
- 20 *Pautler SE, Grizzard WS, Thompson LN, Wing GL.* Blindness from retrobulbar injection into the optic nerve. *Ophthalmic Surg* 1986; 17: 334-7.
- 21 *Yagiela JA, Benoit PW, Buoncrisiani RD, Peters MP, Nelson FF.* Comparison of myotoxic effects of lidocaine with epinephrine in rats and humans. *Anesth Analg* 1981; 60: 471-80.
- 22 *Carlson BM and Rainin EA.* Postoperative diplopia and ptosis; a clinical hypothesis on the myotoxicity of local anesthetics. *Arch Ophthalmol* 1985; 103: 1337-9.
- 23 *Carlson BM, Rainin EA.* Rat extraocular muscle regeneration. *Arch Ophthalmol* 1985; 103: 1373-7.
- 24 *Davis DB, Mandel MR.* Posterior peribulbar anesthesia: an alternative to retrobulbar anesthesia. *J Cataract Refract Surg* 1986; 12: 182-4.
- 25 *Bloom LH, Scheie HG, Yanoff M.* The warming of local anesthetic agents to decrease discomfort. *Ophthalmic Surg* 1984; 15: 603.



- 26 *Nadbath RP, Rehman I.* Facial nerve block. *Amer J Ophthalmol* 1963; 55: 143.
- 27 *Atkinson WS.* Akinesis during cataract operation. *Arch Ophthal* 1934; 12: 240.
- 28 *Gills JP, Loyd TL.* A technique of retrobulbar block with paralysis of orbicularis oculi. *Am Intra-ocular Implant Soc J* 1983; 9: 339-40.
- 29 *Moore DC.* The pH of local anesthetic solutions. *Anesth Analg* 1981; 60: 833-4.
- 30 *Hilgier M.* Alkalinization of bupivacaine for brachial plexus block. *Regional Anesthesia* 1985; 10: 59-61.
- 31 *Antoszyk AN, Buckley EG.* Contralateral decreased visual acuity and extraocular muscle palsies following retrobulbar anesthesia. *Ophthalmology* 1986; 93: 462-5.
- 32 *Callahan A.* Ultrasharp disposable needles. *Am J Ophthalmol* 1966; 62: 173.
- 33 *Davis DB, Mandel MR.* Posterior peribulbar anesthesia: an alternative to retrobulbar anesthesia. *Geriatr Ophthalmol* 1987; 86: 61-4.
- 34 *Kimble JA, Morris RE, Witherspoon CD, Feist RM.* Globe perforation from peribulbar injection. *Arch Ophthalmol* 1987; 105: 749.
- 35 *Atkinson WS.* The development of ophthalmic anesthesia. *Am J Ophthalmol* 1961; 51: 1-14.
- 36 *Unsöld R, Stanley JA, DeGroot J.* The CT-topography of retrobulbar anesthesia. *Graefes Arch Clin Exp Ophthalmol* 1981; 217: 125-36.
- 37 *Davidson B, Kratz R, Mazzocco T.* An evaluation of the Honan intraocular pressure reducer. *Am Intra-Ocular Implant Soc J* 1979; 5: 237-8.
- 38 *Emery J* (Ed). *Current Concepts in Cataract Surgery*. St. Louis: CV Mosby, 1980, pp 258-9.
- 39 *Drews RC.* The Nerf ball for preoperative reduction of intraocular pressure. *Ophthalmic Surg* 1982; 13: 761.
- 40 *Martin SR, Baker SS, Muenzler WS.* Retrobulbar anesthesia and orbicularis akinesia. *Ophthalmic Surg* 17: 1986; 232-3.
- 41 *Wolff E.* *Anatomy of the Eye and Orbit*. Revised by Roger Warwick. 7th ed. Philadelphia: W.B. Saunders, 1976, pp 270-4.
- 42 *Parks MM.* *Ocular Motility and Strabismus*. Hagerstown, Md.: Harper and Row, 1975, pp 1-6.
- 43 *Winnie AP.* Regional anesthesia. *Surg Clin N Am* 1975; 54: 861-92.
- 44 *Fruhstorfer H, Zenz M, Nolte H et al.* Dissociated loss of cold and warm sensibility during regional anaesthesia. *Pflugers Arch* 1974; 349: 73-82.

### Résumé

*Douze mille anesthésies régionales pour extraction de cataractes et implantation intraoculaire de lentilles ont été accomplies par un anesthésiste pour une période de 52 mois dans une clinique de chirurgie d'un jour. L'ophtalmologiste, qui a accompli toutes les opérations a évalué la qualité des blocs utilisant une échelle objective décrite dans cet article. Les premiers 3,595 patients ont subi des blocs rétrobulbaires et du septième nerf. Les 1,640 patients subséquents ont reçu seulement un bloc rétrobulbaire avec des volumes plus élevés. Les 3,478 patients ont reçu des blocs péribulbaires et 2,226 ont reçu un bloc péribulbaire modifié. Un dernier groupe de 1,061 a reçu une combinaison d'un bloc péribulbaire et périorbital avec la possibilité d'une réinjection rétrobulbaire si indiquée. Avec l'évolution des techniques de blocage on a pu se rapprocher du but final d'atteindre une anesthésie régionale efficace, sécuritaire et sans douleur. Les conditions d'une anesthésie efficace de ce type sont présentées, les complications sont décrites et l'importance d'une reconnaissance anatomique de l'orbite et de son contenu est mise en valeur.*